ARCHIVES OF PATHOLOGY

VOLUME 10
1930

PUBLISHERS
AMERICAN MEDICAL ASSOCIATION
CHICAGO, ILL

CONTENTS OF VOLUME 10

JULY, 1930 NUMBER 1

AUGUST, 1930 NUMBER 2

AUGUST—Continued

SEPTEMBER, 1930 NUMBER 3

OCTOBER, 1930 NUMBER 4

OCTOBER—Continued

NOVEMBER, 1930 NUMBER 5

DECEMBER, 1930 NUMBER 6

DECEMBER—Continued

ARCHIVES OF PATHOLOGY

VOLUME 10 JULY, 1930 NUMBER 1

DIET AND TISSUE GROWTH

VII RESPONSE TO HIGH PROTEIN DIETS AND UNILATERAL NEPHRECTOMY DURING REPRODUCTION AND LACTATION IN THE RAT WITH PARTICULAR REFERENCE TO KIDNEY CHANGES IN BOTH MOTHER AND OFFSPRING*

HELEN T PARSONS, PH D
Mary Pemberton Nourse Fellow of the American Association of University Women

ARTHUR H SMITH, PH D

T S MOISE, M D
AND
LAFAYETTE B MENDEL, PH D
NEW HAVEN, CONN

The possible relationship of dietary protein to changes in renal function or renal structure has received increasing attention during the past few years A review by Mitchell[1] indicates the disagreement that still exists not only concerning the production of any change by increased protein intake, but also concerning the nature of the observed changes Mitchell brought out also the difficulty of harmonizing the results of different investigators, because of the lack of uniformity in the experimental conditions imposed and the inherent complexity of the variables There seems to be justification for the recent trend toward study of special aspects of the problem, since more general methods of approach have led to seemingly contradictory conclusions It is possible that only by observing the physiologic response of animals under widely varying but carefully controlled experimental conditions can the factors

* Submitted for publication, March 3, 1930

† From the Laboratory of Physiological Chemistry and Department of Surgery, Yale University

* The data in this paper are taken from a dissertation presented by Helen T Parsons in partial fulfilment of the requirements for the degree of Doctor of Philosophy, Yale University, 1928

* The study was aided by grants from the Committee on Scientific Research of the American Medical Association and from the Russell H Chittenden Research Fund for Physiological Chemistry in Yale University A preliminary report of this investigation was published in the Proceedings of the Society for Experimental Biology and Medicine **25** 681, 1928 Other papers in this series are I and II, J Exper Med **40**·13 and 209, 1924, III, Proc Soc Exper Biol & Med **23** 561, 1926, IV, J Exper Med **45** 263, 1927, V, ibid **46** 27, 1927, VI, Proc Soc Exper Biol & Med **24** 746, 1927

1 Mitchell, H H J Nutrition **1** 271, 1929

be demonstrated which contribute to the renal changes caused by certain diets The types of observations made may also be extended to advantage For instance, comparatively few detailed studies of blood constitutents have accompanied investigations of renal changes

It was from such standpoints that the present research was undertaken Several methods have been utilized for the intensification of the physiologic task of excretion In the first place, advantage has been taken of the demonstrated influence of unilateral nephrectomy on renal injury and on the compensatory enlargement of the remaining kidney during a high protein regime (Smith and Moise [2]) In addition, the functional stress has been augmented through an increase in the nutritional needs and metabolism of the animal by the introduction of gestation and lactation, factors that have been used by MacKay, MacKay and Addis [3] and MacKay [4] in connection with studies involving a comparatively low protein intake The rat was chosen as the experimental animal in the present research because of the extensive comparative data available for this species The scope of the research has been amplified by an extensive study of the fluctuations in one constitutent of the blood, namely urea, the results of which will be reported in a succeeding paper

EXPERIMENTAL METHODS

Plan of Experiment—Unilateral nephrectomy or laparotomy alone was performed on animals, which were immediately placed on rations containing varying concentrations of protein, the rats were bred as soon as possible thereafter When the young were born, the number in the litter was reduced to eight The litters were weaned on the twenty-first day or, in certain cases in which data on the kidneys of the young were desired, on the seventeenth day The mothers were either killed when the young were weaned or were remated In some of the control experiments, females were killed at the time the litters were expected to be born or just after the birth of the litter, and in certain others, the animals were not mated The remaining left kidneys were removed together with the hearts at autopsy for study

Selection and Care of the Animals—The albino rat (*Mus norvegicus-albinus*) was used For the preliminary part of the investigation, the rats were obtained from the colony of the Laboratory of Physiological Chemistry and from the (Osborne and Mendel) colony at the Connecticut Agricultural Experiment Station, later, from a second generation bred from the latter stock in the Laboratory of Physiological Chemistry The unusual vigor of these animals, their capacity for growth and the high standard of uniformity procured by years of selection and feeding are significant elements of success for this type of experimentation The rats were used only after they had reached adult weight, for the reason that it was desirable to eliminate as far as possible increase in kidney size due to normal growth of the animal itself

---

2 Smith, A H, and Moise, T S J Exper Med **45** 263, 1927

3 MacKay, L L MacKay, E M, and Addis, T Proc Soc Exper Biol & Med **22** 536, 1925

4 MacKay, L L Am J Physiol **86** 215, 1928

The rats were kept in individual cylindric cages with wire mesh bottoms which stood high enough above a layer of shavings so that there was no possibility of any consumption of this material by the rats. Bedding in the form of paper crepe was provided for the mother rats the day before the litters were expected to be born. Water was supplied from a device with a large capacity in order to insure an adequate source at all times, for the unusually large water intake of these animals under the experimental conditions employed rendered this precaution necessary.

The Rations—Rations were devised to make as striking contrasts as possible in the concentration of protein in the diet. It was necessary, however, to avoid endangering success in lactation by too low a protein intake, on the one hand,

TABLE 1—*Composition of Rations*

Components	Concentrations of Components in Various Diets											
	1	2*	3	4	5	6a*	6b	7	8	9	10	11
Protein, per cent	70	67	74	70	6[illegible]	67	70	11	16	21	21	22
Crude casein (including irradiated), per cent	86	76			72	80 †		70	20	20	20	
(Crude casein irradiated†), per cent	(20)							(20)	(20)			
Cooked egg albumin, per cent			86	76			80 †					20
Wheat embryo, per cent		20		20	20	5				20	20	20
Cooked starch, per cent								76	66	56	51 [illegible]	56
Salt mixture, per cent (Osborne and Mendel J Biol Chem 37 572, 1919)	4	4	4	4	4	4	4	4	4	4	4	4
Added calcium carbonate, per cent					4	0 61	0 61				1 67	
Butter fat, per cent	10		10			10	10	10	10			
Daily additions to basal rations												
Lettuce,¶ Gm	15		15			15	15	15	15			
Yeast,† Gm	1 [illegible]	1 1	1 [illegible]	1 1	1 1	1 [illegible]	1 [illegible]	1 [illegible]	1 [illegible]	1 5	1	1 1
Cod liver oil,† cc		0 1		0 1	0 3	0 3	0 3			0 [illegible]	0 1	0 7
		1 5		1 5	1 5	1 5	1 5			1 5	1 5	1 5

* Additions of a potent alcoholic extract of wheat embryo, of 'marmite' (a commercial yeast product supplied by Dr Katharine Coward, London), of a tested lot of Harris yeast concentrate (lot no 1030, assayed in this laboratory and found to be potent) and of a commercial wheat germ oil were fed to certain rats on rations 2 and 6a

† Variations in these ingredients were introduced as follows

Irradiated foods Before Oct 16, 1927, additions of vitamin D were made to the basal ration by means of irradiating a portion of the casein of certain diets (20 Gm per hundred grams of ration being so treated) After this date, 40 mg of irradiated yeast was incorporated in each gram of yeast fed in the ration, instead of irradiated casein

Amounts of yeast Before parturition, the animals had 1 Gm per day during the first and second weeks of lactation, 2 Gm, and during the third week of lactation, 3 Gm

Cod liver oil Up to Nov 11, 1927, 0 3 cc was fed daily Between Nov 11, 1927, and Dec 10 1927, 0 5 cc was fed daily during the interval up to parturition, 1 cc during the second week of lactation and 1 5 cc during the third week of lactation After Dec 10, 1927, 0 5 cc was fed daily during the interval up to the occurrence of the placental sign, and 1 5 cc during the interval between the occurrence of the placental sign and the weaning of the young

¶ Analysis of lettuce (bought in New Haven) by personal communication to the authors by Dr A J Wakeman, Connecticut Agricultural Experiment Station Water content, 9[illegible] 6 per cent (average of analyses on 7 samples), ash content on moisture free lettuce, 22 5 per cent (average of analyses on 2 samples)

and by such an excess of protein, on the other, that too small an amount of food substances carrying the necessary vitamins would be included in the ration Table 1 presents the composition of the various food mixtures

The composition of ration 1 was arranged to approximate closely the mixture fed extensively by Smith and Morse,[2] but was abandoned later because trial proved that reproduction on it was relatively unsuccessful Rations 2, 4, 5, 6a, 9, 10 and 11 introduced wheat embryo and cod liver oil as carriers of an additional vitamin supply In rations 3, 4, 6b and 11, cooked egg albumin was substituted for casein in corresponding rations for the purpose of avoiding the high content of phosphorus supplied by the casein, since an influence of phosphorus on renal enlargement had

been suggested (MacKay, MacKay and Addis [5]), although this was questioned by others (Osborne, Mendel, Park and Winternitz [6]) In ration 5 also, the high ratio of phosphorus to calcium was changed to one in which calcium was in twice as great concentration by weight as phosphorus (a ratio suggested as optimum by Dr A T Shohl) by the addition of appropriate amounts of calcium carbonate to the casein ration and to the yeast added apart from the rest of the food Table 1 also lists certain substances as carriers of the vitamins B and G, in addition to the yeast supplied These were used in the case of a few rats to insure an adequate supply of vitamin B "complex" if necessary to meet the requirements of animals on high protein levels, as Hartwell [7] suggested that the need for this "complex" is augmented by high protein intake She estimated that every 20 Gm of casein in

TABLE 2—*Previous Rations of Rats Used in Experiments*

Rats from Osborne and Mendel Laboratory at Connecticut Agricultural Experiment Station*	Ration 1	
6, 8, 16, 19, 20, 22, 23, 29, 30, 31, 34, 35, 36, 69, 70, 71, 72, 73, 74, 80, 81, 82	Casein	30 per cent
	Salt mixture	4 per cent
	Starch	22 per cent
	Butter fat	9 per cent
	Lard	15 per cent
	Wheat germ	20 per cent
	Ration 2 Same as ration 1 plus daily additions of	
76, 77	Yeast	0 2 Gm
	Lettuce	30 0 Gm
	Ration 3 Same as ration 1 plus daily addition of	
78, 95	Yeast	0 2 Gm
	Ration 4 Same as ration 1 plus daily additions of	
79, 96	Yeast	0 2 Gm
	Lettuce	40 0 Gm
88, 89, 90, 91, 92, 93, 94	Dog biscuit and green food	
	Stock Ration (Modified Sherman Ration)	
Rats 61 to 68, inclusive, were virgin females from the stock of this laboratory	Whole dried milk	32 5 per cent
	Ground whole wheat	65 5 per cent
	Sodium chloride	1 0 per cent
	Calcium carbonate	1 0 per cent
	Lettuce	5 or 6 times, wk
Rate 97 to 165, inclusive, the second generation from the stock of the Connecticut Agricultural Experiment Station, were virgin females when used for the present experiment	Modified Sherman ration	

* These rats produced one or more litters on the rations listed before being used for the present experiment

the mother's diet required from 6 to 8 Gm of "marmite" (a commercial yeast preparation) for the rearing of suckling young (Hartwell [8]) Reader and Drummond [9] secured normal rates of growth and freedom from renal damage or hypertrophy on high casein rations by increasing the proportion of "marmite" fed,

5 MacKay, L L , MacKay, E M and Addis, T Proc Soc Exper Biol & Med **24** 130, 1926

6 Osborne, T B , Mendel, L B , Park, E A , and Winternitz, M C J Biol Chem **71** 317, 1927

7 Hartwell, G A Biochem J **18** 785, 1924

8 Hartwell, G A Biochem J **19** 1075, 1925

9 Reader, V , and Drummond J C Biochem J **20** 653, 1927

until the ratio of protein to this yeast extract had a value of 5 or less Hassan and Drummond[10] reported that the factor in yeast concerned with rendering high protein diets adequate for growth seemed to be the one resistant to heat and alkali The wheat germ oil was added in certain cases because of the suggestion of Evans and Burr[11] that a relative lack of vitamin E might be a cause of failure in suckling young on certain diets Ration 8 carries the lowest level of protein assumed to possess a safe margin for entirely successful reproduction and rearing of young Ration 7 was planned to replace ration 1 in case no reproduction could be secured on the higher level

The casein employed was a washed crude product Dried, commercial egg albumin was dissolved in a small amount of distilled water, poured into boiling distilled water and thoroughly coagulated, with additions of glacial acetic acid to make the mixture slightly acid to litmus The entire mass was dried without separation of the liquid from the solid portions Starch was converted to a translucent paste by heating in water Both the cooked egg albumin and starch after drying were ground finely and incorporated in the basal rations in this form Butter fat, free from water, was filtered through filter paper in a hot water funnel

The alcoholic extract of wheat embryo was prepared according to the method of Sure[12] Each kilogram of wheat embryo was percolated with 5 liters of 75 per cent ethyl alcohol at room temperature, and, after being filtered, the alcohol was evaporated in vacuo The preparation was fed as a water solution made up to known volume Its potency was assayed, and growth was obtained with as small a daily portion of this extract as the equivalent of 2 Gm of wheat embryo

Yeast and casein, in 100 Gm lots, were each spread on pans 20 by 20 inches (50 8 by 50 8 cm) and irradiated for half an hour under a mercury vapor quartz lamp using 4 amperes and 110 volts, direct current, at a distance of 2 feet Each lot was stirred once at the end of fifteen minutes

Methods of Analysis—Calcium was determined by the Tisdall and Kramer method (Tisdall[13]), as modified by Clark and Collip[14]

Phosphorus was determined by the method of Bang as described by Greenwald[15] and modified by Shohl and Bennett[16]

Urinary albumin was determined by the method employed by Smith and Moise[17]

Surgical Technic—The procedure of Smith and Moise[2] was followed in performing unilateral nephrectomy Laparotomy alone was performed on some of the animals (rats 108, 112, 116, 120, 124, 128, 132 and 135) as a control experiment to test the part which an operative procedure might play in any possible effects of nephrectomy The laparotomy included the anesthesia and incisions described by Smith and Moise,[2] together with a careful lifting of the kidney and a somewhat less extensive dissection of the surrounding fat

Removal and Fixation of Kidney at Autopsy—As much of the adjacent fat as possible was cut away from the kidney with sharp pointed scissors, but the capsule

---

10 Hassan, A , and Drummond, J C Biochem J **21** 653, 1927
11 Evans, H M , and Burr, G O J Biol Chem **76** 273, 1928
12 Sure, B J Biol Chem **74** 55, 1927
13 Tisdall, F F J Biol Chem **56** 439, 1923
14 Clark, E P , and Collip, J B J Biol Chem **63** 461, 1925
15 Greenwald, I , and Gross, J J Biol Chem **66** 185, 1925
16 Shohl, A T , and Bennett, H B J Biol Chem **74** 247, 1927
17 Smith, A H , and Moise, T S J Exper Med **46** 27, 1927

was not removed In case of the right kidney, this dissection was carried out on a glass plate, and the kidney removed at once to a weighing flask and covered However, in the case of left kidneys in which considerable hypertrophy had taken place, it was found that so much urine was held in the hilus of the kidney that it was necessary to absorb this with filter paper Even in cases of hydronephrosis, this was found to be an effective method of removing the excess of urine, since on making a longitudinal section little of this fluid was visible The two halves of the kidney were fixed for from three to eight days in a 10 per cent formaldehyde solution before being embedded and sectioned Eosin and hematoxylin were used as stains The method followed in the excision of the heart was to lift it by its apex with mouse tooth forceps and make a transverse incision through the blood vessels as close to the auricles as possible The stub of the aorta was trimmed when necessary to a short uniform length An incision was made into the auricles and ventricles, so that any clotted blood might be removed

Calculation of Renal Enlargement—The method of Smith and Moise[2] was used in calculating the percentage of renal enlargement based on body weight An example of the calculation based on heart weight is given in table 3

Use of Vaginal Smears—In those of the present experiments which involved reproduction, observation of vaginal conditions by means of the technic of Long

TABLE 3—*Calculation of Per Cent of Renal Enlargement Based on Heart Weight*

	Weight of Heart at Autopsy, Gm	Weight of Left Kidney at Autopsy, Gm
Rat 77	0 741	2 504
Donaldson's nearest corresponding values	0 734 0 744	0 775 0 787
Donaldson's values by interpolation	0 741	0 784
Difference (enlargement)	2 504 — 0 784 = 1,720 Gm	
Degree of enlargement, $\frac{1\ 720}{0\ 784} \times 100 = 219\ 4$ per cent		

and Evans[18] proved of advantage in establishing the time of reappearance of the regular estrous cycle after operation, selecting a time for mating, detecting insemination and obtaining evidence of implantation

The technic of the vaginal smear was adapted to the needs of the problem A plentiful number of cells in a smear could be easily obtained if a blunt syringe made from glass tubing and rubber bulb were substituted for the small glass spatula ordinarily used, and a small amount of physiologic solution of sodium chloride was injected into and then withdrawn from the vagina[19]

RESULTS

Effects of a Diet Rich in Protein on Ovulation and Gestation—A valuable index of physiologic well-being was discovered by Long and Evans[18] through the use of the vaginal smear technic They observed a regular tendency to the prolongation of the time interval of the estrous

18 Long J A and Evans, H M Memoirs of the University of California, Berkeley, University of California Press, 1922

19 Dr Myra Sampson of Smith College suggested this procedure

cycle in all cases of undernutrition and concluded therefrom that a regular cycle of from three to five days is a more sensitive index to the well-being of young adult female rats than bodily activity, glossy hair, normal weight or other recognized signs of health

In the present experiments, as might be expected, the estrous cycle was somewhat disturbed for a shorter or longer interval following the operation of unilateral nephrectomy, but when it became established again it was of interest to note that with the exception of the rats fed egg albumin the regular interval was four or five days in length This observation therefore furnishes evidence of physiologic well-being in the rats fed high casein diets after the removal of one kidney

No toxic signs were observed during gestation in any of the animals [20] Determinations of the albumin in a two or three days' collection of urine were made in the case of ten of the animals for the period immediately preceding parturition These determinations revealed only the traces of albumin normally found in the urine of the rat Albuminuria occurs so frequently in cases of human pregnancy that a failure to find significant increases here is of interest

The weight of the young was regularly noted the day after the litter was born, so that the mother rat should not be disturbed during the first hours after parturition This procedure did not give a true birth weight, but the latter was not obtainable in many cases in any event, since birth occurred frequently during the night, and the young had already sucked when they were found in the morning Therefore, the records of "birth weight" in this investigation represent the weight of the young at an age of from 1½ to something less than 1 day plus an increment in weight of a variable amount of milk The reliability of the figures given so frequently in the literature on the birth weight of young on given diets is open to question Only with some technic such as that which Long and Evans [18] described for removing the young at birth can adequate figures be obtained, free from the objections offered Since the same variables apply to the young of mothers on all diets, a comparison has been made in table 4 of the average weight of the newly born young on the various rations It will be seen from table 4 that the average weights of the baby rats 1 day old born from mothers on these various rations do not differ strikingly The highest average weight occurred on a low protein ration, containing

20 There were two instances of abnormally prolonged parturition with the greatly oversized young born dead In one of the cases, the female gave birth to a normal second litter In the other, mating was not attempted again, and the animal was killed for the examination of the tissues Diet was probably not responsible for the abnormal condition, since one of the females received a low protein ration and the other a diet rich in protein The condition may have been associated with the occurrence of a first pregnancy at a relatively advanced age

21 per cent, but not on the lowest, containing 16 per cent The factor of nephrectomy seemed to have no influence on birth weight (ration 2)

Effects on Lactation—That certain abnormalities of diet may be most clearly elicited by the demands of lactation has been frequently pointed out The efficiency of milk production on an adequate diet is evidenced in a number of ways The flow of milk begins promptly at parturition The abundance of the supply can easily be judged by the distention of the abdomen of the baby rats and by the appearance of the full stomach as a white spot of varying size viewed through the semitransparent abdominal walls Well-fed baby rats sleep a great deal of the time, not nursing excessively but appearing satisfied The hair shows as a tinge of white at the end of one week At this time, the body has more than doubled in weight At about 2 weeks of age, the eyes are open, and a distinct covering of hair has formed The body weight is more than trebled The body looks plump The back

TABLE 4—*Average Weights of Young Approximately One Day of Age Born from Mothers on Rations Containing Different Concentrations of Protein*

Condition of Mother Rat	Average Weight of Newly Born Young, Gm	Ration	Amount of Protein in Diet, %
Nephrectomized	5 1	1	70
Nephrectomized	5 7	2	67
Intact	5 7	2	67
Nephrectomized	5 6	5	63
Nephrectomized	5 7	6a	67
Nephrectomized	5 7	7	41
Nephrectomized	5 4	8	16
Nephrectomized	6 5	9	21
Nephrectomized	5 6	10	21

especially at the hips is noticeably broad, and the whole body looks well proportioned The skin is loose, but has subcutaneous fat, so that it is not drawn into thin, wrinkled folds At about the sixteenth or seventeenth day, the young are wandering freely about the cage and are frequently found in the mother's food cup, nibbling of her ration begins some time before the twenty-first day The hair at this time is luxurious and smooth and neither "stands on end" nor looks greasy and sticky The mother rat usually maintains her weight during lactation

Although a study of the possible effects of high protein diets on lactation was incidental to the general problem, a comparison of the results summarized in table 5 is of interest

The records of the rats on rations 1, 7 and 8 carrying 70, 41 and 16 per cent, respectively, of protein derived from casein make it clear that reproduction and lactation may be relatively unsuccessful on certain rations that are very rich in protein and that include amounts

of vitamin-containing foods approximately adequate when incorporated in control rations of lower protein content The same amount of salt mixture was added to each of the three rations, hence the only important variable in the content of inorganic material was in the different amounts of phosphorus and calcium introduced into the diet with the crude casein In the experiments of Maynard and Bender,[21] the salt concentration of both the high protein and the low protein rations was made identical by adding appropriate amounts of calcium and phosphorus, as well as the usual salt mixture to the ration with the lower protein This was not done in the present experiment, although enough calcium was added to one of the high protein rations (5) to make the

TABLE 5—*Reproduction and Lactation Records of Rats, on the Various Rations Listed in Table 1*

Ration	Females on Ration	Condition of Female Rats	Females Failing to Breed, %	Number of Litters	Total Young Born on Ration	Total* Young Living After One Day	Young Living on 21st Day, %†	Average Weight of Young on 21st Day, Gm	Main Source of Protein in Diet	Amount of Protein in Ration, %
1	12	Nephrectomized	25	9	61	55	47 3	22	Casein	70
7	8	Nephrectomized	37 5	5	41	40	78 4	33 3	Casein	41
8	5	Nephrectomized	20	4	56	29	100 0	33 0	Casein	16
2	33¶	Nephrectomized	21 1	40	300	272	74 7	28 1	Casein	67
2	9	Intact	33 3	6	42	37	73 0	27 3	Casein	67
5	8	Nephrectomized	37 5	5	36	27	85 2	28 8	Casein	63
9	3	Nephrectomized	00 0	3	27	24	91 0	33 4	Casein	21
10	10	Nephrectomized	20 0	9	63	62	76 9	36 3	Casein	21
4	4	Nephrectomized	75 0	1	6	6	00 0		Egg albumin	70
3	6	Nephrectomized	83 3	1	8	8	37 5‡	9 7	Egg albumin	74
6b	3	Nephrectomized	33 3	2	13	12	58 3	12 9	Egg albumin	70
11	2	Nephrectomized	50 0	1	7	7	100 0	15 7	Egg albumin	22
6a	4	Nephrectomized	00 0	4	34	31	45 1	29 7	Casein	67

* Any differences between the totals in this column and the preceding column may be due either to a reduction of the litter to a total of eight, a practice applied to all litters of more than eight young, or to mortality of the young or both

† The percentage is based on the number living after one day (see preceding column)

¶ Twenty more nephrectomized females listed in other tables on this diet are not included here, because part of them were killed when the litters were about to be born, and the young of part of them were killed for autopsy records on the seventeenth day of nursing instead of the twenty first

‡ Three of the young were kept alive by being fed a solution of cane sugar three times daily with a syringe, starting on the fourteenth day of lactation

ratio of calcium to phosphorus 2 to 1, a proportion considered optimal by Shohl Maynard and Bender[21] concluded that there was no appreciable difference in the effect on reproduction of their high protein and low protein diets, but it is to be noted in their experiments that lactation was somewhat superior on the lower concentration of protein, 82 2 per cent of the young living to the 20th day and weighing 32 2 Gm on 18 per cent of protein, whereas 80 2 per cent of the young lived on 50 per cent of protein and weighed 28 7 Gm It should also be noted that the concentration of protein in their "high protein" ration (50 per cent) approximates much more closely the 41 per cent protein

21 Maynard, L A, and Bender, R C Proc Soc Exper Biol & Med **25** 388, 1928

of ration 7, grouped here as one of the rations with lower protein content, than it does the 70 per cent of ration 5 used in these experiments as the high protein type The young on both rations 7 and 8 averaged approximately 33 Gm at 21 days of age, a record fairly comparable with Maynard and Bender s results The chief difference noted between rations 7 and 8 was in the mortality of the young The contrast of litters on these two rations with litters born on ration 1 is much more striking

That additions of yeast, cod liver oil and wheat embryo improved the records made by the animals on high protein ration 1 is indicated by the response to ration 2, in which these additions are included, although here also the performance falls short of that on the corresponding low protein ration 9 to which the same additions have been made On ration 2, the fact is also established that reproduction and lactation are fully as good in the partially nephrectomized as in the intact animals This lends validity to comparisons of the results on the animals with one kidney herein obtained with the results of other laboratories on intact animals The adding of calcium to rations 2 and 9, in rations 5 and 10, respectively, to bring up the ratio of calcium to phosphorus to a 2 1 proportion, made no consistent improvement in the records of rats on either the high protein or the low protein ration The largest young of the series were produced on ration 10, but reproduction and survival of the young were not so good as on ration 9

The detrimental effects on reproduction and lactation of the introduction of cooked egg albumin in place of casein in the high protein rations is seen in the records of rats on rations 3, 4, 6b and 11 The reason for this condition demands further investigation

The averages on ration 6a (table 1) represent a few animals to the rations of which were added high concentrations of vitamin E and of vitamin B "complex," particularly the antineuritic vitamin B, since Evans and Burr [22] have shown that crude casein itself contains vitamin G As no noteworthy improvement resulted from either addition, fuller details need not be presented The results of a more crucial experiment are presented in table 6 Several litters were divided as fairly as possible into two groups each One group was used as a control, the other was given doses of wheat germ oil "marmite," Harris' yeast concentrate or alcoholic extract of wheat embryo daily from a glass syringe tipped with fine rubber tubing Quantitative records of intake could not be secured,[23] but it appeared evident that each rat consumed liberal amounts of the supplemental food Although at the end

22 Evans, H M, and Burr, G O J Biol Chem **76** 263, 1928

23 Some of the liquid that had been placed in the mouths of the young rats sometimes ran out and was lost in spite of the utmost care in feeding

of the feeding period the two groups sometimes differed in weight by a few grams, the difference was nearly always small and was not uniformly in favor of the group receiving the supplementary dose In the case of the young of rat 142, the difference seems to be considerable

TABLE 6—*A Comparison of the Growth of Nursing Rats Fed Doses of Yeast Concentrate, Alcoholic Extract of Wheat Germ or Wheat Germ Oil, with the Growth of Litter Mates not Fed Such Supplements*

Mother Rat	Stage of Lactation, Days	Average Weight of Young Without Added Source of Vitamins B, G or E, Gm	Average Weight of Young With Added Source of Vitamins B, G or E, Gm	Nature of Supplement	Remarks
97	14	17	17	Marmite	
	19	20	19		
97	11	14	12	Harris' yeast concentrate	
	15	15	12		2 young rats on dose dead
	21	23	21		
123	10	11	11	Harris' yeast concentrate	
	14	14	14		1 young rat dead in each group
	20	18	19		1 young rat dead in each group
131	10	15	15	Harris' yeast concentrate	
	14	19	19		
	17	22	22		
	21	29	29		
138	9	10	10	Harris' yeast concentrate	
	13	15	15		
	23	28	25		
142	8	11	11	Harris' yeast concentrate	
	12	15	17		1 young rat on dose dead
	22	24	40		
100	14	18	17	Wheat germ oil	
	21	30	29		
107	15	33	29	Wheat germ oil	
	21	32	30		
111	14	19	19	Wheat germ oil	
	21	27	28		
120	4	6	6	Alcoholic extract of wheat germ	
	11	17	16		
	21	30	29		
124	4	9	9	Alcoholic extract of wheat germ	
	11	18	18		
	21	35	36		

It should be stated, however, that there were only two rats in each of these groups, and that the death of the smaller rat on the dosage left one unusually large rat to represent the average It seems clear that the failure to obtain normal growth in the suckling young on high protein ration 2 was not due to a lack of either vitamin B, G or E as the single limiting factor

Effects on the Kidneys of the Adult Females—One of the most striking results of subjecting adult female rats simultaneously to reproduction, partial nephrectomy and a high protein intake is seen in the tremendous enlargement of the remaining kidneys In view of the difficulties, which will be discussed later, of expressing these increases as degrees of enlargement based on some standard such as body weight, it was thought of interest to examine the data first merely on the basis of gross enlargements actually occurring, without recalculation These data are expressed graphically in charts 1 and 2, in which all experimental animals are included, except a set of twenty rats added to the group after the graph was drawn A wide number of variables occurred in this set of animals, the total number presented here including some older rats that had had previous litters (see table 2) as it was thought desirable to use only females with a proved reproductive capacity in the earlier part of the experiment A more nearly homogeneous group is presented later in this discussion

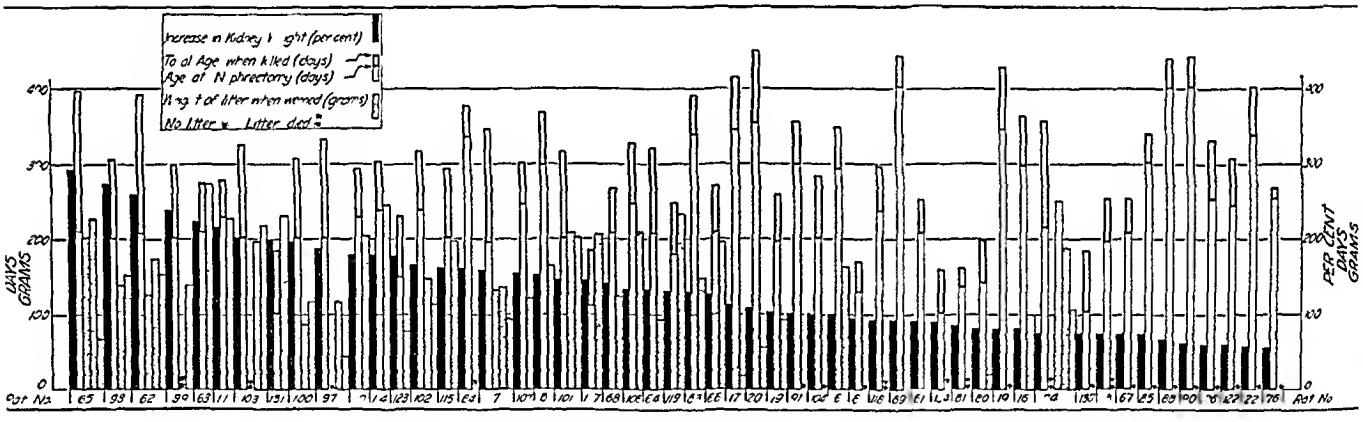

Chart 1—Actual renal enlargement and reproduction after nephrectomy in rats on high protein rations

On examination of charts 1 and 2, it is seen that the range of gross increase in weight of the left kidney over the right kidney removed at nephrectomy was from 295 to 57 per cent for the rats fed high protein rations, and from 137 to 13 per cent for those fed low protein rations The records of most of the rats with successful litters are grouped near the left end of the graph, where the highest renal increases are arranged, and, for the most part, the records of the rats that either had no litters or else lost them are at the right, where the renal enlargements are of a lower order of magnitude From even this heterogeneous set of animals it seems clear that the difference in concentration of protein between the two sets of diets is the factor of greatest significance in the renal enlargements following the removal of one kidney in this experiment, and that the influence of lactation is next in importance pregnancy alone having less influence

When an attempt was made to evaluate these gross enlargements on the basis of expected kidney weight, difficulties arose, as has been stated In the first place, a discrepancy was found between the weights given by Donaldson[24] for body organs and those obtained on the rats in this experiment A control group of ten rats obtained from the same stock as the majority of the nephrectomized animals, ranging in age from 75 to 97 days, were killed and examined and a record made of the gross body weight and the weights of the digestive tract, left kidney, right kidney and heart The weights of the digestive tracts varied from 12 Gm to 17 Gm, and hence this variable was relatively negligible in this instance The deviations of the actual weights of the hearts from Donaldson's standard based on gross body weight ranged from —0 094 Gm to —0 172 Gm The heart weight having the greatest deviation was only 77 per cent of the standard That this variation was not due to the method of trimming the heart was indicated by the results of a further experiment in which possible variation due to the length of the aortic stub was determined The heart was weighed with the stub trimmed distinctly less closely than usual and again after it had been trimmed as closely as possible The difference was found to be approximately 1 per cent of the weight

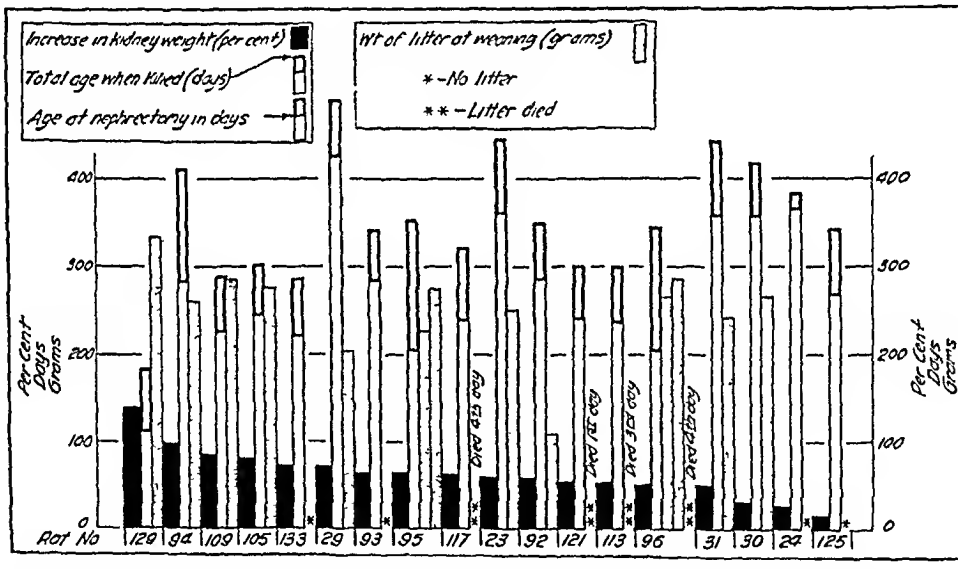

Chart 2—Actual renal enlargement and reproduction after nephrectomy in rats on low protein rations

of the heart The actual weights of the two kidneys of each of the ten rats in this group were compared both with Donaldson's standard based on the body weights and with that based on the heart weights of the animals The deviations from the former standard varied from —0 074 Gm to —0 359 Gm The kidney weight having the greatest deviation was only 78 per cent of the standard The deviations of the actual kidney weights from the standard based on the heart weights of the animals ranged from —0 002 Gm to —0 362 Gm The kidney weight having the greatest deviation was 133 per cent of the standard Thus it can be seen that unwieldy factors of error must be used in calculating the expected kidney weight for comparison with the surviving left kidneys of the partially nephrectomized rats in this research Furthermore, body weights were felt to be unreliable, as fluctuations of as much as 20 Gm were frequently observed in these rats during a

24 Donaldson, H H The Rat, Philadelphia, Wistar Institute, 1924

single day without reference to continued gain or loss The practice of MacKay and MacKay[25] in making allowance at autopsy for the observed weight of the digestive tract, a technic published after these experiments were under way, would doubtless have obviated a part of this difficulty

In the present series of animals, other disturbing factors contributed to render the body weight obtained at autopsy unsatisfactory as a basis on which to calculate true renal enlargement The mother rats fed high protein rations had a strikingly low amount of body fat at the twenty-first day of lactation in comparison with both the lactating rats fed low protein rations and the pregnant rats on high protein diets The size of the normal kidney may not bear the same relationship to inert fatty tissue that it does to more rapidly metabolizing tissue In addition, decided fluctuations in body weight at the time of autopsy had been incurred as the result of certain manipulations incident to the experiment, such as keeping some individual animals in metabolism cages for the collection of urine, or as subjecting others to the drawing of repeated blood samples during the day As will be discussed later, some of the quantitative aspects of the experiment were deliberately sacrificed to certain qualitative aspects which were deemed essential

Since it was evident that the body weights of the animals in these experiments were subject to such wide variations, it seemed wise to calculate the renal enlargements of the entire group of animals (table 7) on the basis of heart weights, on the assumption that the weight of the heart would be less variable This stability of heart weight is obviously useful only to the degree that it is desirable to minimize transient gains and losses of body weight in which the kidney does not share to any great extent It is of course possible that it might unduly minimize the significant fluctuations that would normally affect the weight of the functioning renal substance On the other hand, MacKay[4] showed that a 5 1 per cent increase in the weight of the heart in proportion to body size was present in the mother rat from eight to twelve days after the birth of a litter, whereas if forty-five days elapsed after the normal termination of pregnancy no increase in heart size was found If, however, the mothers were allowed to nurse their young for a period of from forty-one to forty-seven days following pregnancy, a decidedly larger increase, 10 9 per cent, in heart size was found, whether or not this augmented size was transient was not ascertained Hypertrophy of the heart, therefore, doubtless occurred under the conditions of the present experiment, although the exact figures of MacKay do not necessarily apply in this case, in which the organs of the pregnant group were weighed either on the day following the birth of young or the day before they were expected to be born, or to the other group, in which lactation was terminated on the seventeenth or the twenty-first day

The effect of pregnancy on renal enlargement will be brought out more clearly in table 8, in which many of the variables of table 7 have been eliminated But it is interesting to note in passing that the general conclusions based on gross enlargements of the kidney are in agreement with those to be drawn from the data in table 7 on renal increases based on heart weight As in the first case, so here, the greatest enlargements tend to coincide with the greatest reproductive strain in both high protein and low protein groups The percentage enlargements for the high protein group, ranging from 219 to 29 per cent, greatly exceed those for the low protein group, which range

25 MacKay, L L, and MacKay, E M Am J Physiol **83** 179, 1927

TABLE 7.—*Renal Enlargement in Relation to Reproduction After Unilateral Nephrectomy*

Rat	Renal Enlargement Based on Weight of Heart, %	Weight of Right Kidney at Nephrectomy, Gm	Weight of Left Kidney at Autopsy, Gm	Weight of Heart at Autopsy, Gm	Total Weight of Young at 21 Days, Gm	Time After Nephrectomy on Diet, Days	Age of Rat at Nephrectomy, Days	High Protein Ration
77	219	0.967	2.504	0.741	357	172	197	2
65	193	0.745	2.947	0.925	52[illegible]	187	211	2
131	169	0.686	2.047	0.723	232	83	101	2
62	151	0.607	2.187	0.814	547	180	211	2
111	148	0.811	2.571	0.950	223	53	226	2
148	143	0.542	1.412	0.567	Young died*	61	95	2
159	142	0.628	1.830	0.718	Young died†	59	96	2
63	139	0.603	1.947	0.769	272	62	211	2
100	132	0.773	2.294	0.912	206	106	201	2
115	129	0.855	2.170	0.877	195	56	237	2
68	129	0.792	1.896	0.781	126	55	211	2
79	129	0.796	1.617	0.678	90	62	197	6b
123	129	0.683	1.901	0.782	75	83	149	2
106	127	0.730	1.884	0.780	213	83	246	5
162	124	0.637	1.891	0.794	184 (17 days)	59	96	2
127	123	0.858	2.110	0.878	210	70	115	2
98	118	0.610	2.287	0.960	241	109	201	2
151	118	0.673	1.458	0.644	116 (17 days)	53	213	2
107	117	0.740	1.907	0.821	120	56	246	2
147	116	0.726	1.867	0.811	Young died†	60	95	2
156	114	0.669	1.734	0.764	Young died*	60	95	2
114	114	0.777	2.150	0.925	244	65	237	5
99	113	0.607	2.065	0.896	129	99	201	2
83	112	0.748	1.717	0.766	148	54	337	6a
158	111	0.577	1.566	0.707	‡	60	96	2
66	108	0.878	1.976	0.879	196	60	211	2
149	108	0.616	1.752	0.792	65 (17 days)	64	95	2
119	108	0.850	1.964	0.875	235	70	178	2
102	106	0.619	1.639	0.752	308	118	201	2
104	105	0.648	1.295	0.611	‡	82	201	2
78	103	1.061	1.854	0.850	Young died§	56	197	4
150	101	0.686	1.480	0.698	134 (17 days)	57	213	2
8	101	0.764	1.923	0.886	165	69	299	1
163	99	0.543	1.337	0.647	Young died*	52	105	2
81	97	0.925	1.752	0.830	Young died§	28	134	2
101	97	0.760	1.875	0.879	311	117	201	2
157	97	0.615	1.664	0.795	‡	60	96	2
91	96	0.814	1.635	0.783	‡	58	300	3
155	95	0.645	1.486	0.725	Young died*	62	95	2
152	93	0.786	1.600	0.781	Young died*	63	213	2
165	92	0.586	1.435	0.711	Young died*	56	106	2
84	91	0.828	2.156	1.027	Young died§	40	337	2
134	89	0.620	1.198	0.612	Young died§	57	105	5
76	89	0.888	0.699	0.699	‡	64	203	4
85	88	0.902	1.565	0.782	‡	35	304	3
103	87	0.604	1.817	0.897	416	126	201	2
118	86	0.842	1.625	0.819	Young died§	62	236	5
161	86	0.555	1.506	0.766	‡	60	100	2
160	85	0.661	1.406	0.722	Young died*	61	96	2
153	82	0.668	1.575	0.812	158 (17 days)	57	95	2
126	81	0.944	1.527	0.791	‡	73	255	5
97	81	0.668	1.924	0.973	161	135	201	2
110	80	0.759	2.131	1.070	205		226	5
61	77	0.560	1.095	0.602	‡	40	211	2
146	76	0.721	1.580	0.838	‡	61	95	2
89	75	0.734	1.414	0.763	‡	40	403	3
164	74	0.585	1.474	0.793	Young died*	56	106	2
64	71	0.590	1.367	0.756	90	112	211	2
74	69	1.087	1.964	1.051	543	149	219	6a
6	66	0.846	1.695	0.939	164	58	291	1
82	63	0.761	1.482	0.849	‡	37	133	2
80	60	0.822	1.519	0.880	18	57	141	6a
130	60	0.568	0.997	0.602	‡	80	106	5
154	60	0.567	1.399	0.820	Young died*	62	95	2
88	55	0.884	1.487	0.888	‡	36	401	3
19	53	0.844	1.527	0.920	‡	83	345	1
16	49	1.182	2.147	1.271	100	69	298	1
20	49	0.887	1.836	1.111	56	94	356	1
67	46	0.690	1.203	0.777	‡	44	211	2
22	40	0.928	1.469	0.962	‡	69	336	1
122	29	0.716	1.166	0.841	‡	68	242	5
96	58	1.082	1.749	1.008	511	141	203	9
125	55	0.899	1.016	0.630	‡	74	255	10
94	51	0.933	1.827	1.088	260	128	283	9
105	47	0.807	1.471	0.919	275	56	246	10
93	47	0.880	1.460	0.917	‡	58	283	11
113	39	0.796	1.233	0.824	Young died§	63	237	10
92	39	0.811	1.290	0.861	110	67	283	11

TABLE 7.—*Renal Enlargement in Relation to Reproduction After Unilateral Nephrectomy—Continued*

Rat	Renal Enlargement Based on Weight of Heart, %	Weight of Right Kidney at Nephrectomy, Gm	Weight of Left Kidney at Autopsy, Gm	Weight of Heart at Autopsy, Gm	Total Weight of Young at 21 Days, Gm	Time After Nephrectomy on Diet, Days	Age of Rat at Nephrectomy, Days	Low Protein Ration
129	37	0.559	1.327	0.892	332	72	111	10
109	32	0.836	1.540	1.058	284	63	226	10
117	25	0.557	0.912	0.694	Young died§	83	239	10
133	24	0.553	0.960	0.741	‡	65	136	10
31	23	0.915	1.377	1.022	241	86	356	8
121	20	0.658	1.022	0.796	Young died§	61	239	10
95	16	0.758	1.254	0.989	498	150	203	9
23	13	0.783	1.241	1.005	249	86	360	8
30	9	0.828	1.059	0.903	266	61	356	8
29	7	0.785	1.345	1.130	203	64	425	8

* Rat killed day before young were expected to be born
† Rat killed day young were born
§ Litter died from lack of milk supply or other causes
‡ Rat did not become pregnant

from 58 to 7 per cent, a contrast seen also in the case of gross enlargements of the kidney.

To what extent a generalization can be made on the basis of these data concerning the influence of varying concentrations of any protein in the diet is open to question. As the mineral content of the low protein diets was not corrected for the excess calcium and phosphorus in the crude casein of the high protein diets, the influence of the phosphorus in the high casein rations has not been eliminated. This is also true of the experiment of MacKay, MacKay and Addis.[26] They stated, "The protein concentrations were varied by the amount of casein in the diet and were roughly as 1 : 2 : 4. The *mineral content* and the concentration of vitamin-containing foods *were identical in each case*." (The italics are ours.) However, an examination of the tables given in their papers shows that the mineral content of the high protein diet was 7 per cent, and that of the low protein diet (the "experimental male diet"), 5.4 per cent. Their statement must therefore be interpreted to mean that the percentage of added salt mixture was the same in the two cases, but that the mineral content of the low protein ration was not made identical with that of the high protein ration. There is no agreement at present in regard to the rôle of phosphorus in renal enlargement, but MacKay, MacKay and Addis[5] have assigned a positive influence thereto.

It was hoped that the use of cooked egg albumin as the protein in the present experiment would eliminate the high phosphorus factor to a large extent, but the performance of all the animals on egg albumin was so strikingly abnormal that no conclusions can be drawn from this part of the experiment.

The results of the present experiment afford no evidence that a high intake of yeast (1 to 3 Gm. per day) reduces the degree of renal

26. MacKay, E. M., MacKay, L. L., and Addis, T. Am. J. Physiol. **86**: 459, 1928.

enlargement occurring on high protein diets These results are in agreement with those of Francis, Smith and Moise [27]

For selected groups of animals listed in table 8, calculations were made on the basis both of heart weight and of body weight

In table 8 are summarized the records of all the animals that fall within a comparatively narrow grouping with respect to age and time on the diet It will be seen that estimates of renal enlargement vary considerably depending on whether the calculation is made on the basis of body weight or of heart weight By either method of calculation,

TABLE 8—*A Comparison of the Renal Enlargements of Rats on High Protein Ration in Regard to Reproduction and Lactation*

Rats in Experiment	Average Time on Experiment, Days	Average Age of Rats in Group, Days	Average Body Weight at Nephrectomy, Gm	Average Final Gross Body Weight, Gm	Average Renal Enlargement Based on Body Weight, %	Probable Error	Average Renal Enlargement Based on Heart Weight, %	Probable Error	Identity of Rats in Group
				Experiment 1, No Reproduction					
10	62 8	235	216	219	105 5	6 66	76 9	5 8	Nos 61, 67, 104, 122, 126, 130, 146, 157, 158, 161
				Experiment 2, Gestation Only					
13	59 3	164	217	250	111 4	3 85	98 5	4 58	Nos 118, 147, 148, 152, 153, 154, 155, 156, 159, 160, 163, 164, 165
				Experiment 3, Gestation and Lactation					
12	59 6	256	241	245	154 0	5 78	121 0	2 67	Nos 63, 66, 68, 107, 111, 115, 119, 127, 149, 150, 151, 162

Summary

	Difference Between Renal Enlargement in Exper 1, No Reproduction, and That in Exper 2, Pregnancy Only		Difference Between Renal Enlargement in Exper 1, No Reproduction, and That in Exper 3, Lactation		Difference Between Renal Enlargement in Exper 2, Pregnancy Only, and That in Exper 3, Lactation	
	Difference, Gm	Probable Error of Difference	Difference, Gm	Probable Error of Difference	Difference, Gm	Probable Error of Difference
Based on body weight	3 9	7 7	48 5	8 7	42 6	7 0
Based on heart weight	21 6	7 3	44 1	7 4	22 5	5 3

however, the increase in the renal enlargement of the third group in which lactation, as well as pregnancy, occurred is considerably greater than in either of the other two groups Statistically, the differences between them are from four to six times the probable error of the difference between the means, in spite of the fact that the probable error runs high for these small groups When a comparison is made of the group in which no reproduction occurred with the group subjected to pregnancy only, the difference is barely significant if the estimate is based on heart weight, and not significant if based on body

27 Francis, L D, Smith, A H, and Moise, T S Proc Soc Exper Biol & Med **26** 725, 1929

weight Under the conditions of the experiment, therefore, lactation and gestation have a much more pronounced influence on renal enlargement than has gestation alone Although the time of autopsy of these animals in reference both to pregnancy and to lactation is different from that selected by MacKay,[4] and no such quantitative standards have herein been achieved as were possible in those experiments, the present results confirm her conclusions

TABLE 9—*Kidney Damage in Relation to Reproduction, Age of Female, Time After Nephrectomy and Degree of Renal Enlargement*

Subgroup, Indicating Degree of Renal Injury	Rat	Type of Injury	Time on Experiment, Days	Age at End of Experiment, Days	Total Weight of Young at 21 Days, Gm	Weight of Right Kidney at Nephrectomy, Gm	Weight of Surviving (Left) Kidney, Gm	Renal Enlargement on Basis of Body Weight, %
Group 1 Rats Having Previous Pregnancies at Connecticut Agricultural Experiment Station, High Protein Ration, Partial Nephrectomy								
A	77	Severe	172	369	357	0 967	2 504	
B	74	Slight	149	368	543	1 087	1 964	
Group 2 Rats Having Previous Pregnancies at Connecticut Agricultural Experiment Station, Low Protein Ration, Partial Nephrectomy								
C	94	No injury	128	411	260	0 933	1 827	
	95	No injury	150	353	498	0 758	1 254	
	96	No injury	141	344	511	1 082	1 749	
	Average group 2		140	369	423	0 924	1 610	—
Group 3 Rats Having No Previous Pregnancies, Obtained from Stock Colony on Modified Sherman Ration High Protein Ration, Partial Nephrectomy								
A	62	Severe	180	391	547	0 607	2 187	228
	65	Severe	187	398	523	0 745	2 947	229
	Average group 3A		184	395	535	0 676	2 567	229
B	100	Slight	106	307	206	0 773	2 294	160
	103	Slight	126	327	416	0 604	1 817	162
	Average group 3B		116	317	311	0 689	2 056	161
C	64	No injury	112	323	90	0 590	1 367	168
	97	No injury	135	336	161	0 668	1 924	157
	98	No injury	109	310	241	0 610	2 287	240
	99	No injury	99	300	139	0 607	2 065	194
	101	No injury	117	318	311	0 760	1 875	1[illegible]5
	102	No injury	118	319	308	0 619	1 639	140
	Average group 3C		115	318	208	0 642	1 860	173

In the present investigation, the remaining kidney of each of the experimental animals fed a high protein ration for a period of ninety days or longer after nephrectomy and of thirty-nine individuals for shorter intervals was examined histologically Since none of these animals fed the high protein rations for less than 106 days after nephrectomy showed injury of the kidney, sections were not made of the kidneys of the remaining animals of the group The data on the kidneys of all of the rats that were on the experiment for intervals longer than ninety-five days are recorded in table 9 for comparison

In only three individuals of the whole number examined were severe lesions of the kidneys found, in three others, moderate injury The severe lesions corresponded closely to those found in rats 150 days after nephrectomy by Moise and Smith[28] and Smith and Moise,[17] and the moderate ones to those described as occurring after intervals of from 90 to 120 days The lesions presented in photomicrographs by these authors represent accurately the changes observed in this investigation

Two of the animals showing renal injury, one with severe and one with moderate lesions, are listed separately as group 1 in the tables, because they belong to the set of older rats with a record of pregnancies prior to the experiment It is noteworthy that three other rats from this same set of animals which had previously borne young and were fairly comparable in regard to the time during which they were the subject of experiment, age and total weight of young, but which were fed a low protein diet (group 2), did not show any renal injury Therefore, the renal changes observed in the animals in group 1 presumably did not antedate the present investigation The rats in group 3 were a uniform group of virgin females fed a modified Sherman ration, and later partially nephrectomized and fed the same experimental ration as group 1 The variations in time on the diet are accounted for by the fact that repeated pregnancies were attempted Rat 64 had one pregnancy, rats 97, 98, 99, 100, 101 and 102 had two pregnancies each, and rats 62, 65 and 103 had three pregnancies each When the records in this table are examined, it is evident that, in general, it is the rats subjected to the greatest reproductive strain for the longest time on a high protein ration that show evidence of renal damage In group 3 the two rats having the greatest injury of the kidney also have, with a single exception, the greatest renal enlargements in this group, rat 98 with no renal damage is the only one the renal enlargement of which exceeds these It should be noted that renal enlargement in this set of lactating animals is strikingly greater than that found by Smith and Moise[2] in male rats on a diet containing 85 per cent of crude casein, yet kidney damage certainly appears no earlier in this experiment, and if the record of so few animals may be taken as evidence, its onset is even slower in these females than in the experimental animals of Moise and Smith It seems probable, therefore, that the influences determining the degree of renal enlargement on a high casein ration are not altogether identical with those producing kidney damage This point will receive fuller discussion in a following paper

---

28 Moise, T S, and Smith, A H Effect of High Protein Diet on Kidneys Experimental Study, Arch Path 4 530, 1927

Effects on the Kidneys of the Young—In chart 3 are arranged the ratios of the average body weights [29] to kidney weights at the twenty-first day post partum of litters from mothers with different nutritional and operative histories It is plain that there is a tendency at 21 days of age for the young of the nephrectomized mothers on a high casein ration to have larger kidneys in proportion to their body weights than

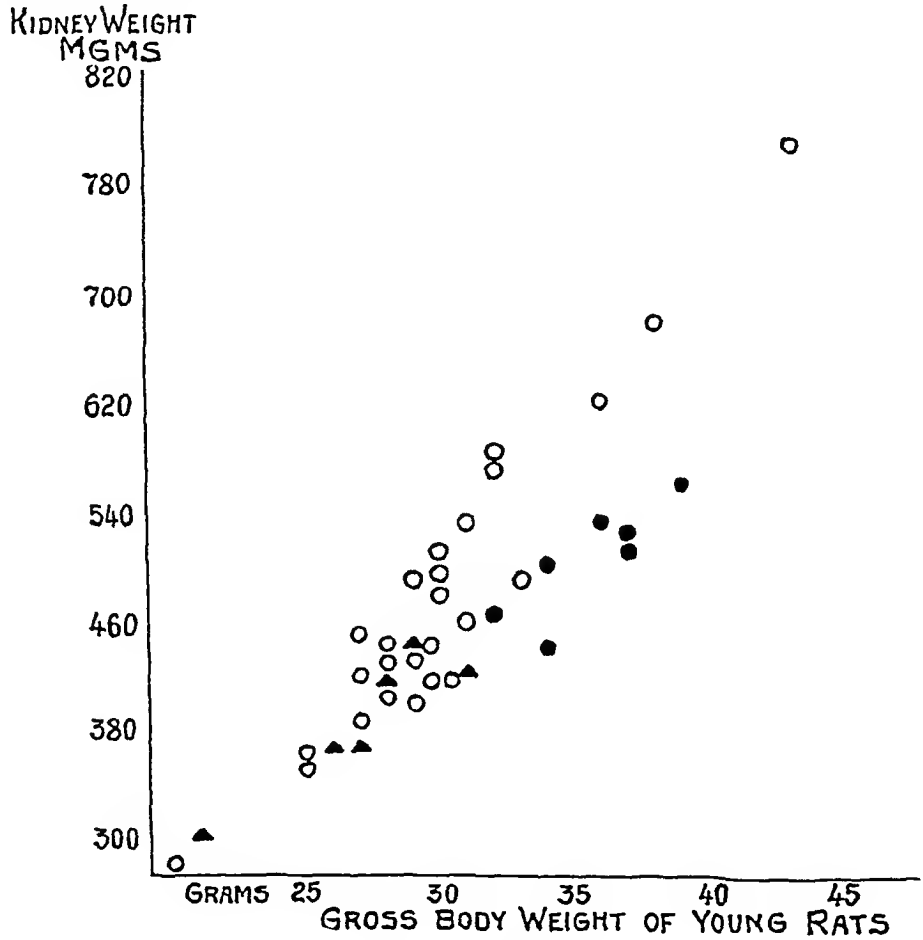

Chart 3—Ratios of the average body weights to kidney weights at the twenty-first day post partum, of litters from mothers with different nutritional and operative histories The circles represent the offspring of mothers (one kidney) fed a high protein diet, the triangles, offspring of mothers (two kidneys) fed a high protein diet, and the solid circles, offspring of mothers (one kidney) fed a low protein diet

the young born from mothers on a low casein ration The former, however do not differ noticeably in regard to proportional kidney weight from the young born from intact mothers on a high casein

29 In most cases, the litter was divided, and the data were obtained for the males and the females separately Any individual strikingly different in size from the rest of the litter was discarded

ration The exact interpretation of this divergence is not clear At this age, the young have been nibbling a variable amount of the mother's ration for three or four days in addition to the mother's milk supplied to them Osborne, Mendel and associates[6] observed an increase over the standard given by Donaldson in the weight of the kidneys of rats that had been fed a high protein diet for so short a period as three days,

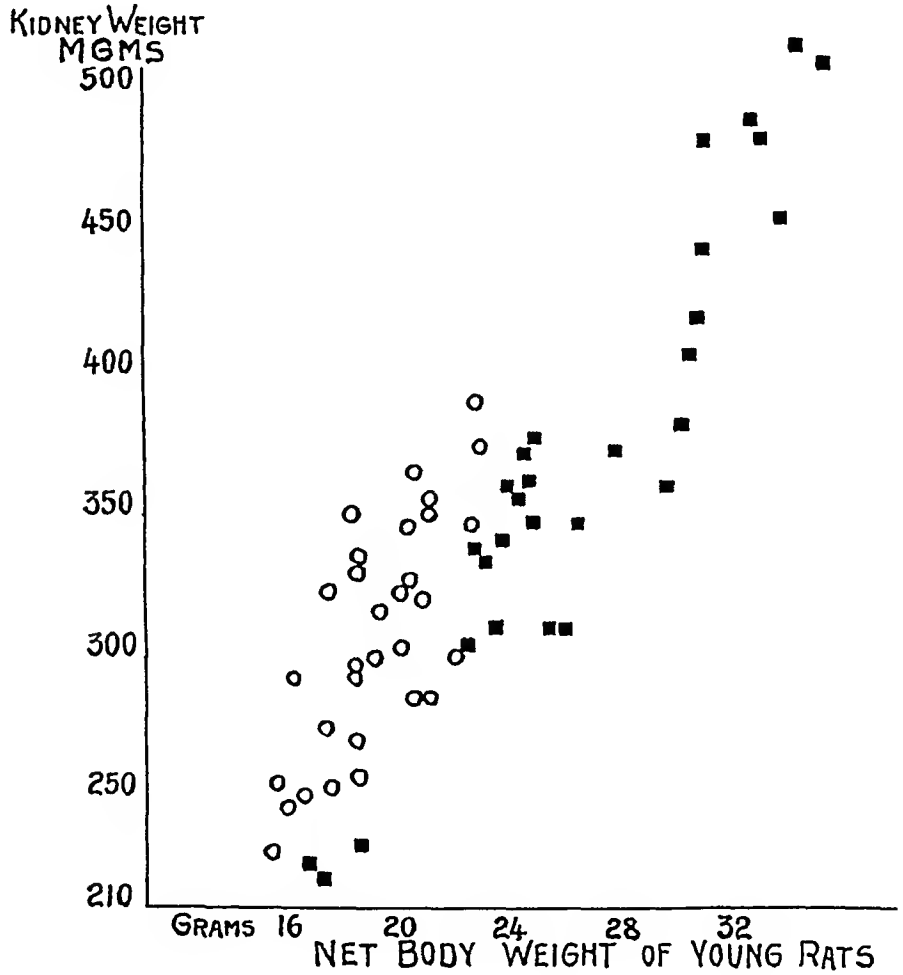

Chart 4—Ratios of the average body weights to kidney weights at the seventeenth day post partum, of litters from nephrectomized mothers on a high protein diet, compared with similar data on litters from intact mothers on a stock ration comparatively low in protein The circles represent the offspring of mothers (one kidney) on high protein diet, the squares, offspring of mothers (two kidneys) on low protein diet

in contrast with the performance of other rats fed rations low in protein Smith and Moise[2] recorded a 49 per cent renal enlargement accompanied by a 44 per cent increase in total solids in a three day interval after nephrectomy on a high protein diet Although the suckling young in the present investigation were deriving only a part of their food supply from the mother's ration during the brief interval,

it was realized that this might have been sufficient to account for the enlargement observed, in view of the results noted A further experiment was therefore carried out The young of rats 149, 150, 151, 153 and 162 on high protein ration 2 were killed at the age of 17 days before any were observed to have visited the mother's food cup Litters from intact females on the modified Sherman ration were also killed at the same age The net body weight was obtained by the method of MacKay and MacKay,[25] and the weight of the two kidneys was obtained for each animal

The results shown in chart 4 and table 10 indicate that at 17 days of age the young of nephrectomized mothers on a high casein diet have larger kidneys in proportion to their body weights than the young of intact mothers on a stock ration comparatively low in protein Certain implications of these results will be considered in succeeding papers

TABLE 10—*A Comparison of the Relative Kidney Weights of 17 Day Old Rats from Intact Mothers on Modified Sherman Ration and Partially Nephrectomized Mothers on a High Protein Ration, Respectively*

Character of Group	Mean Ratio of Body Weight to Kidney Weight	Probable Error	Significance Ratio $\frac{D}{PED}$
Twenty nine offspring of mothers (two kidneys) on modified Sherman ration	73 8	0 735	8 5
Thirty one offspring of mothers (one kidney) on high protein ration 2	64 8	0 735	

CONCLUSIONS

Lactation and gestation have a greater influence than gestation alone on the degree of enlargement of the remaining kidneys in rats fed a high casein diet following unilateral nephrectomy These results are in agreement with those of MacKay in her quantitative study of intact female rats on a lower protein ration

Renal lesions were observed in a few of the rats that were subjected to the greatest reproductive strain and that were fed a diet rich in protein for periods varying from one hundred and six to one hundred and eighty-seven days

The kidneys of the young born from mothers fed high casein rations weigh more in proportion to body weight at weaning than do those of the young of females given rations comparatively low in protein

The rations rich in casein (86 and 76 per cent) are less satisfactory for successful lactation than others containing less of this protein (20 per cent) but the same allowance of vitamin-rich foods

A COMPARISON OF THE INTRANUCLEAR INCLUSIONS PRODUCED BY THE HERPETIC VIRUS AND BY VIRUS III IN RABBITS *

E V COWDRY, PH D
ST LOUIS

Thus far the subject of the production of intranuclear inclusions in virus diseases has been treated rather lightly The interest of many investigators has ceased with the demonstration that the particular inclusions in question are definitely associated with the action of a special virus Some have delved a little more deeply, with the object of discovering, if possible, whether the inclusions are combinations between virus and nuclear material, or simply altered nuclear substance —without being able to reach a decision which is generally acceptable Few have felt impelled to investigate closely the formation of single kinds of inclusions, that is, to concentrate on limited aspects of the problem

Instead there has been a marked tendency to generalize concerning a large and expanding group of diseases some of which have but little in common Why certain of these diseases cause inclusions in the nuclei, others in the cytoplasm, others in both and why still others fail to produce inclusions in either situation one does not know One is equally in the dark as to the cytologic changes involved in the stimulation to cell division effected by some viruses, the cellular hypertrophy caused by others, the rapid death and quick lysis caused by others and conversely the slow death and strange persistence of dead cells resulting from the action of still another virus How the viruses do these things one does not know There has been no correlation between their action on living cells and their physical properties

Even the fundamental cytologic question of the similarity or the dissimilarity between the intranuclear inclusions that are produced by a half dozen or more viruses has been only partly answered despite the fact that these inclusions can almost be regarded as the footprints of the viruses and thus afford a desirable point of departure for cytologic studies

After describing the intranuclear inclusions in "visceral disease," von Glahn and Pappenheimer [1] concluded "There can be no doubt

* Submitted for publication, Feb 3, 1930

* From the Anatomical Laboratory, Washington University School of Medicine

1 Von Glahn, W C, and Pappenheimer, A M Intranuclear Inclusions in Visceral Disease, Am J Path **1** 445, 1925

that the inclusions are identical in their morphology and staining reactions with the bodies seen by previous observers in the viscera of infants, and by Lipschutz and others in the tissues of spontaneous and experimental herpes, and in various neural and visceral lesions produced by the herpetic and related viruses" They further stated that the virus isolated by Rivers and Tillett (later called virus III) produced " intranuclear inclusion bodies apparently identical with those described in herpes "

Obviously, the force of the word identical is measured by at least three considerations first, the number of the properties considered, second, the accuracy attained in their determination, and third, the degree of parallelism in the conditions of observation of the substances compared Von Glahn and Pappenheimer did not mention the fixative used, but it is likely that they employed several kinds This makes it difficult to evaluate the results which they secured by using the stains of Gram, Mallory, Bensley, the Levaditi technic and scharlach R For instance, they described the inclusions as "vividly red" by the Bensley method, whereas by the same technic Goodpasture characterized the herpetic bodies as remaining "unstained or faintly green" This does not look like identity unless the conditions of examination were different From perusing the paper, one gains the impression that the only inclusions actually studied by von Glahn and Pappenheimer were those in visceral disease, reliance being placed for the properties of the others on descriptions in the literature which are themselves meager in the extreme

This is just an example Other unsupported assertions of similarity between the inclusions caused by different viruses, which if true would argue against their specificity, are current in the literature Goodpasture [2] stated that "similar" intranuclear inclusions occur in "three human diseases, herpes simplex, herpes zoster and varicella" Cole and Kuttner [3] wrote "Nuclear changes which cannot at present be differentiated from those occurring in the lesions of spontaneous and experimental herpes simplex also occur in the skin lesions of herpes zoster, in the skin lesions of varicella, and in the lesions experimentally produced in rabbits by the Virus III of Rivers and Tillett " Later, describing the inclusions in the meningeal exudate produced by the submaxillary virus in guinea-pigs, they said "These cells resemble in all particulars the cells containing nuclear inclusion bodies which occur in herpes simplex and related conditions," but they did not specify what the particulars are More recently,

2 Goodpasture, E W Intranuclear Inclusions in Experimental Herpetic Lesions of Rabbits, Am J Path **1** 1, 1925

3 Cole, R, and Kuttner, A G A Filterable Virus Present in the Submaxillary Glands of Guinea Pigs, J Exper Med **44** 855, 1926

Torres[4] expressed the belief that the intranuclear inclusions in experimental yellow fever in monkeys are of the same nature as others discovered in herpes simplex, symptomatic herpes, varicella and virus III disease of the rabbit and described sometimes under the heading of oxychromatic degeneration

It remains to be shown just how close these "identities" and "similarities" are, because it is possible that with the use of more discriminating methods, unsuspected differences will be brought to light, although from the cytologic point of view a certain monotony or fixity in nuclear response to diverse agencies is to be expected because the nuclei are sheltered from environmental changes by a layer of adaptable and shock-absorbing cytoplasm Moreover, the available reactive material in the nucleus is strictly limited in quality as compared with that found in the cytoplasm, which means that the intranuclear inclusions, bound as they must be to some extent by this restriction, would tend to be alike chemically, and this is in fact the case

In a recent study, I observed[5] that the intranuclear inclusions in chickenpox, herpes, submaxillary disease of guinea-pigs and virus III disease of rabbits are characterized by their resistance to solvents in various kinds of fixatives and by the fact that they contain little or no thymonucleic acid and iron in organic combination But while comparing the intranuclear inclusions caused by the virus of yellow fever with those in other virus diseases, in cooperation with Dr S F Kitchen,[6] I observed some unexpected morphologic differences

It is in the belief that before one makes any generalizations one needs more accurate information concerning individual types of inclusions that this contribution is offered The inclusions characteristic of herpetic and virus III infections were selected for study because their properties can be conveniently compared under exactly parallel conditions in the testicles of rabbits

EXPERIMENTAL METHOD

Three experiments were carried out The technic of the first is given in detail

Two rabbits were selected of about the same weight The testicles of one were inoculated with a saline emulsion of glycerinated rabbit's brain infected with H F herpes virus, and those of the other with a saline emulsion of fresh rabbit

4 Torres, C M Inclusions nucleaires acidophiles (degenerescence oxychromatique) dans la foie de Macacus rhesus inocule avec le virus bresilien de la fievre jaune, Compt rend Soc de biol **99** 1344, 1928

5 Cowdry, E V The Microchemistry of Nuclear Inclusions in Virus Diseases, Science **68** 40, 1928

6 Cowdry, E V, and Kitchen, S F Intranuclear Inclusions in Yellow Fever, Am J Hyg **11** 227, 1930

testicle infected with virus III After forty-eight hours, the animals were killed and the testicles removed Both pairs of testicles were definitely affected, but those from the animal inoculated with virus III showed the most pronounced lesions macroscopically

The testicles from the herpetic rabbits and those inoculated with virus III were cut in transverse sections, about 2 mm thick The sections from the herpetic rabbit were immediately placed in bottles containing special fixatives, but those of the testicles of the rabbit inoculated with virus III were first hemisected so that pieces of tissue were secured of half the size and of conspicuous shape (for identification), but of the same thickness as those employed from the herpetic rabbit so that the fixative would penetrate both at the same rate One of these was placed in the same bottle with each piece of herpetic tissue at as nearly as possible the same moment The tissues fixed in this manner side by side in the same bottle were washed, dehydrated, cleared and finally embedded together in the same block of paraffin Sections were cut at the same thickness (4 microns) and were mounted on the same slide so that in all the subsequent tests the comparison between the herpetic and the virus III inclusions was direct The fixatives employed in this first experiment were as follows (1) carnoy (absolute alcohol 18 cc, chloroform 9 cc, acetic acid 3 cc), (2) carnoy 70 cc, plus chloroform 10 cc, (3) carnoy 10 cc, plus chloroform 20 cc, (4) carnoy 5 cc, plus chloroform 20 cc, (5) pure chloroform, (6) 95 per cent alcohol (ethyl), (7) saturated aqueous corrosive sublimate 10 cc, plus absolute alcohol 10 cc, (8) Zenker's solution without acetic acid 10 cc, plus 2 5 cc commercial formaldehyde, (9) Zenker's solution 15 cc, plus 5 cc acetic acid, (10) Zenker's solution 10 cc, plus 10 cc acetic acid, (11) Zenker's solution 5 cc, plus 15 cc acetic acid, and (12) Zenker's solution 1 cc, plus 19 cc acetic acid The object of using the first five fixatives was to test the effect on both types of inclusion, of a progressive increase in the concentration of chloroform The purpose of employing the last four fixatives was to determine the effect on the inclusions of an increase in the concentration of acetic acid

In experiment 2, the same method was followed, except that the herpetic emulsion was made from fresh infected rabbit's brain instead of from glycerinated material This gave more pronounced herpetic inclusions The same kinds of fixatives were employed

Experiment 3 was made as a further control, because in experiment 2 some bacteria were noted in the testicles infected with virus III The tissues were fixed in a different series of fixatives, namely (1) Acetic acid 2 drops, 2 per cent osmic acid 4 cc, and 2 5 per cent potassium dichromate 16 cc, (2) Regaud's solution (3 per cent potassium dichromate 20 cc, commercial formaldehyde 5 cc), (3) a dilute solution of formaldehyde, U S P (1 10), (4) Zenker's solution without acetic acid, (5) Zenker's solution plus 5 per cent acetic acid, (6) Zenker's solution plus a dilute solution of formaldehyde, U S P (1 10), (7) 95 per cent alcohol, (8) 95 per cent alcohol saturated with corrosive sublimate, (9) 1 per cent silver nitrate, (10) 95 per cent alcohol 25 cc, plus 1 drop of ammonia, three hours, then washed in water and placed in 1 per cent silver nitrate

These experiments yielded an abundance of tissue for microchemical analysis The overlapping and duplication were essential because the lesions were never spread uniformly throughout the entire extent of the testicles so that sometimes areas severely injured by one virus would be compared with tissues lightly affected by the other When

this occurred, the material from the other experiments was usually found to fill in the gaps The herpetic virus caused more infiltration and injury of the interstitial tissue, while virus III proved in all cases to be more invasive, that is to say, a larger variety of cells exhibited typical intranuclear inclusions By it they were produced in the following situations (1) endothelial cells, (2) macrophages, (3) interstitial cells, (4) spermatogonia, (5) spermatocytes I and II (occasionally) and (6) epithelial cells of the tubuli recti, canals of the rete, ductuli efferentes and ductus epididymis The herpetic inclusions were confined to the endothelial cells and macrophages, which necessitated a limitation of the comparison to these two kinds of cells Both inclusions in all three experiments were first examined after coloration in the same manner with samples of Giemsa's stain taken from the same bottle In this way, the proportion of red and blue dyes was held constant and care was taken to differentiate the stain as far as possible to the same degree

MORPHOLOGY

On comparing the sections colored by Giemsa's stain, a marked difference in the morphology of the inclusions caused by herpes and by virus III was at once observed This is illustrated in figures 1 to 4 The half figures in the column to the left and marked *A* show herpetic inclusions, and those to the right and marked *B*, virus III inclusions In the case of each figure, *A* and *B* are directly comparable, being photomicrographs of tissues prepared in the same way and mounted side by side on the same slide

Even a cursory examination shows that in the herpetic lesions the inclusion material is finely granular and occupies almost all of the intranuclear space (*A*, figs 1 to 4), while, in the case of virus III, it is drawn together into a dense mass in the center of the nucleus, leaving a clear area between it and the surrounding nuclear membrane (*B*, figs 1 to 4) These dense intranuclear inclusions in testicles infected with virus III frequently assume the general shape of the nuclei in which they are found

A detailed study of the figures reveals still more In figure 1, the nucleus to the extreme left containing a herpetic inclusion is much more hyperchromatic than the nucleus to the right (in the upper part of *B*) containing a virus III inclusion, in other words, the chromatin is more thickly and irregularly marginated on the nuclear membrane

In figure 2, substantially the same differences are noted, notwithstanding the fact that the amount of chloroform in the fixative was greatly increased The herpetic inclusion in *A* is finely divided, whereas the virus III inclusion in the upper left corner of *B* is compact The halo about the latter is, however, not so clear from visible formed material as in *B*, figure 1 The contour of the virus III inclu-

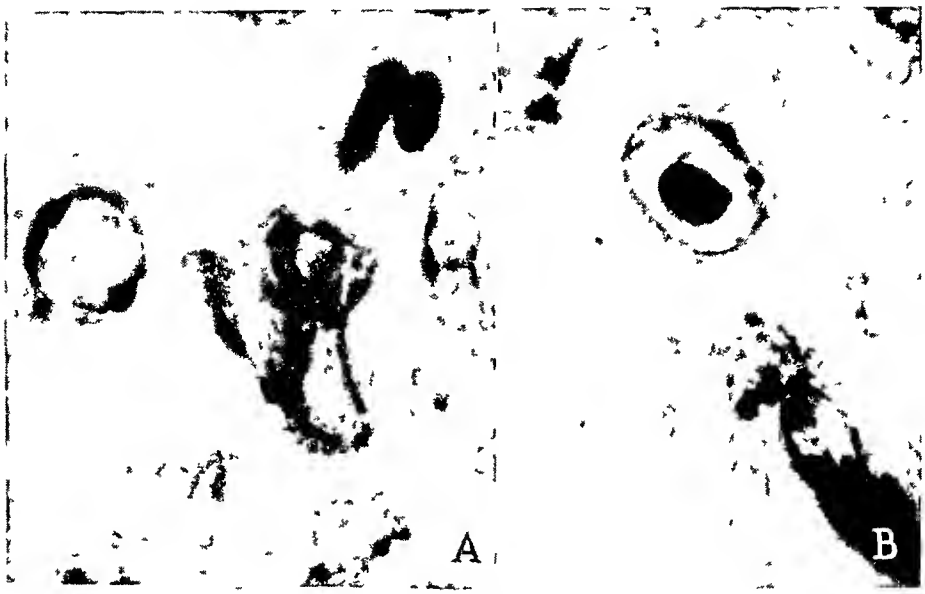

Fig 1—Intranuclear inclusions after fixation in Carnoy's fluid and coloration by Giemsa's stain *A* herpes, and *B*, virus III, × 2,000

Fig 2—Intranuclear inclusions after fixation in equal parts of Carnoy's fluid and chloroform and coloration by Giemsa's stain *A* herpes, and *B*, virus III × 2,000

sion follows that of the limiting nuclear membrane Another nucleus provided with a virus III inclusion is to be seen in the lower right hand corner of figure 2 *B* Hyperchromatism is marked

Figure 3 illustrates the same differences, except that the coloration is much lighter because Zenker's fluid was used as a fixative instead of Carnoy's fluid with high content of chloroform The outline of the nucleus containing the herpetic inclusion a little to the right of the center of *A* is less sharp owing to the direction of the section than the outlines of the two nuclei with virus III inclusions

Finally in figure 4, corresponding differences between the two types of inclusions are again revealed The nuclei laden with herpetic and virus III inclusions are in the lower right hand corners of *A* and *B*, respectively

Such differences in morphology were the rule in all three experiments, after the use of the wide range of fixatives enumerated, with the exception of the last named (alcohol followed by silver), which did not reveal inclusions of either kind They were not conditioned by the stain employed, because this was the same in all instances and because stains do not alter structural details once these have been fixed, but merely color them The differences were equally apparent after the use of hematoxylin and eosin, iron hematoxylin, fuchsin-methyl green and other dye combinations

Both types of inclusion show some variability dependent on their size or maturity at this time of forty-eight hours after inoculation of the viruses A few of the nuclei (perhaps 0 5 per cent) are provided with finely divided inclusions which would be difficult to distinguish from the herpetic ones, but none of the herpetic inclusions are so compact as the inclusions caused by virus III

STAINING REACTIONS

The staining reactions were measured by comparing the stained inclusions with colors as standardized by Ridgway [7] The source of illumination was held constant and consisted of a large Spencer lamp containing a General Electric projection Mazda 400 watt, 115 volt bulb

The experiments showed that both types of inclusions may easily be colored in any way that is desired by selecting the necessary fixatives and stains and by varying the degree of differentiation Thus, they tend to be redder after Zenker's fluid, bluer after Carnoy's fluid and greener after fixation in the acetic-osmic-bichromate mixture when Giemsa's stain has been applied in exactly the same way These

7 Ridgway, R Color Standards and Color Nomenclature, Washington, D C, 1912



Fig 3—Intranuclear inclusions after fixation in Zenker's fluid 20 cc, plus acetic acid 5 cc, and coloration by Giemsa's stain *A*, herpes, and *B*, virus III, × 2,000



Fig 4—Intranuclear inclusions after fixation in Zenker's fluid 10 cc, plus acetic acid 10 cc, and coloration by Giemsa's stain *A*, herpes, and *B*, virus III, × 2 000

tendencies resulted from mordanting during the process of fixation and were to be expected

Though both the herpetic and the virus III inclusions are chiefly acidophilic in their affinities, that is to say, they are themselves basic and take up acid dyes like eosin, there is a variation in this property

For example, in experiment 2 after fixation in Carnoy's fluid and staining by Giemsa's method, the herpetic inclusions exhibited a transition in color from LaFrance pink to Phlox pink, whereas the virus III inclusions were of a color like Bradley's violet, which is much darker and bluer The same difference held when the concentration of chloroform in Carnoy's fluid was increased It was also noted after preservation in Regaud's fluid, a dilute solution of formaldehyde, U S P (1 10), sublimate alcohol and Zenker's fluid containing different concentrations of acetic acid Evidently, therefore, there is a tinctorial distinction between the inclusions characteristic of herpetic and of virus III infections, the latter being rather more basophilic

Both viruses yield nuclei in various stages of the reaction, often side by side When only a few fine acidophilic particles are present, the color of these particles is always less intense than when they are present in larger numbers or are fused to form a large compact mass This is true for both kinds of inclusions The reason why the virus III inclusions are in general bluer after Giemsa's stain than the herpetic inclusions may be merely because they are denser and more compact With greater density, the blue component of the dye might be extracted more slowly on differentiation

Thus far, reference has been made only to the tinctorial properties of the predominating material making up the inclusions When the inclusions are well formed, two other components may occasionally be recognized, though in the majority of cases they are absent

The first of these is a series of small chromophobic vacuoles Each inclusion may contain only one or two such vacuoles, or else its whole substance may exhibit a foamy appearance, the only stainable material being in the continuous matrix These watery vacuoles are not so often seen in the finely divided particulate herpetic inclusions as in the denser virus III inclusions

The second consists of very tiny, roughly spherical masses of material which color intensely with basic dyes These basophilic bodies are of inconstant occurrence in both types of inclusion

MICROCHEMISTRY

The aforementioned tinctorial reactions of the inclusions are not of great significance from the point of view of microchemistry The fact that when the inclusion material is present rather diffusely in finely

divided form it stains less intensely and in a more acidophilic way than when it is aggregated in a compact mass does not of necessity indicate a difference in chemical constitution The difference in staining reaction may be due to a mass effect, the blue component of the stain being extracted more slowly from large masses of inclusion material than from smaller ones The observation that the inclusions in virus III infections tend to be more basophilic than herpetic inclusions when tested under parallel conditions may be explained on the same basis, for they are in general much denser when both are examined forty-eight hours after inoculation

Both types of inclusion are resistant to the solvent action of fixatives, indicating a protein constitution They are not destroyed by 95 per cent alcohol or a dilute solution of formaldehyde, U S P (1 10), when these chemicals are used alone The concentration of chloroform in Carnoy's fluid can be increased to slightly over 80 per cent without injuring them Pure chloroform distorts the nuclei greatly, but traces of virus III inclusions may still remain The persistence of the herpetic inclusions is doubtful The percentage of acetic acid in Zenker's fluid can be increased to 95 without dissolving either kind of inclusion This would at first appear to indicate great resistance to acetic acid, but the acetic acid is applied in association with potassium bichromate and corrosive sublimate, which may inhibit its solvent action The reason for this reservation is that Cowdry and Kitchen[6] observed that the intranuclear inclusions characteristic of experimental yellow fever in monkeys withstand a high percentage of acetic acid in both Zenker's and Carnoy's fluid, but are readily dissolved when 0 1 per cent acetic acid is applied to them in the fresh state

Neither the herpetic nor the virus III inclusions give definitely positive Feulgen reactions for thymonucleic acid It is noteworthy, however, that only rarely are inclusions observed which remain entirely uncolored after application of the reagents to the same degree that the red blood cells and all cell membranes remain uncolored This complete absence of color reaction was established after long study in some of the least developed and most finely granular herpetic inclusions The larger herpetic inclusions are often extremely lightly stained, but to measure the color is a difficult matter In quality, it resembles closely the rose pink of Ridgway's scale but its intensity is less It never approaches in strength the dark aster purple of the chromatin marginated on the nuclear membrane which is giving a typically positive Feulgen reaction Whether the color of the herpetic inclusions is sufficiently marked to justify the listing of the majority of herpetic inclusions as feebly positive is doubtful

The virus III inclusions react a little more strongly It is rare to find any which do not exhibit just a tinge of rose pink In the case of the most compact ones, the rose pink is replaced by a light mallow purple But this mallow purple is still very much lighter than the color taken by the nuclear chromatin It is not unusual to find in the testicles inoculated with virus III that some of the halos separating the inclusions from the surrounding nuclear membranes are themselves evenly colored a pale rose despite the fact that they are devoid of visible contents

The Feulgen reaction only in rare instances gives evidence of the existence of two kinds of material within individual inclusions both in herpetic and in virus III infections Almost always the color or lack of color is uniform throughout the inclusions Tiny vacuoles are, however, sometimes present, which do not stain and which have been previously referred to In addition, one or as many as five or six intensely colored particles may be distinguished within the inclusion These are the inconstant basophilic bodies already described They are colored just like the marginated chromatin, and there is no reason to believe that they are anything other than very occasional traces of incompletely marginated material

These tinctorial differences given by the Feulgen reaction would be devoid of significance were it not for the remarkable constancy and regularity in the results secured Indeed, this reaction is the easiest of all microchemical tests to employ, provided that care is taken not to use fixatives containing potassium bichromate or osmic acid The results described were obtained without any noticeable deviation after fixation in 95 per cent alcohol Carnoy's fluid and alcoholic sublimate

COMMENT

From the observations described it is clear that forty-eight hours after inoculation of the testicles of rabbits with active virus, the intranuclear inclusions produced by herpes and by virus III in these testicles can easily be distinguished from each other on morphologic criteria The virus III inclusions are much more compact than the herpetic ones Too much confidence should not be placed in the tinctorial differences brought to light because of the large experimental error existing in cytologic technic But the Feulgen reaction showed that both types of inclusion contain little or no thymonucleic acid, and their solubilities indicate a protein composition Whether the intranuclear inclusions caused by these two viruses can be equally clearly distinguished in the earliest and in the latest stages of the injury remains to be determined, for in this investigation the tests have been applied, under comparable conditions, only to a single stage in their evolution

The principal theory concerning the nature of the inclusions originated with Lipschutz and has been supported by Goodpasture and his associates Goodpasture and Teague[8] wrote

The constancy with which the intranuclear bodies occur and the characteristic morphological and tinctorial properties which they present in experimental lesions of herpes febrilis in rabbits have convinced us that they represent, as Lipschutz claims, the presence and growth, within the nucleus, of the specific virus of the disease It seems probable also that the virus itself may be obscured by a mantle of nuclear material which gives to the inclusions their usually homogeneous appearance and acidophilic staining quality We have observed, especially in the cells of the ovary and brain, a more basophilic staining reaction and a more granular appearance of the inclusions within nuclei filled with the included mass, and this may possibly be due to an overgrowth of virus and a suppression in the formation of surrounding material

In another place,[9] these authors referred to their contention "that the intranuclear bodies are essentially masses of virus"

A little later Goodpasture[10] expressed the same view with qualifications

It seems evident, however, that the material which constitutes the "inclusion" may partly at least be composed of coagulated nucleoplasm which may impart the acidophilic staining property of the inclusions It is to be noted, however, that when the minute granulations are discrete enough to be recognized as such they stain faintly basophilically, whereas the precipitate from the nucleoplasm of normal cells is more acidophilic They are to be regarded at present as elementary bodies taking part in the structure of the herpetic inclusions

Finally, in his most recent paper Goodpasture[11] said, in respect to herpes and rabies, that morphologic data indicative of micro-organisms as active agents are not convincing, and, further,[12] he said

So long as we conceive of virus diseases as infections due to living agents there is the obvious implication of a possibility of identifying these agents morphologically and of cultivating them on a non-living medium, thus submitting them to a more intensive study On the other hand, if they are interpreted to be reproduced only through the action of living cells of the host, it would seem useless to continue efforts in the direction of cultivation on a lifeless medium

Here, I agree entirely with Goodpasture, except that, with the meager knowledge, I do not think it advisable to espouse any interpretation

---

8 Goodpasture, E W, and Teague, O Experimental Production of Herpetic Lesions in Organs and Tissues of the Rabbit, J M Research **44** 121, 1923

9 Goodpasture, E W, and Teague, O Transmission of the Virus of Herpes Fibrilis Along Nerves in Experimentally Infected Rabbits, J M Research **44** 139, 1923

10 Goodpasture (footnote 2)

11 Goodpasture, E W Cellular Inclusions and the Etiology of Virus Diseases, Arch Path **7** 114, 1929

12 Goodpasture, E W Herpetic Infection, with Special Reference to Involvement of the Nervous System, Medicine **8** 223, 1929

The evidence as it stands is insufficient to justify the contention that the inclusions are masses of virus or even that they are partly made up of virus The minute granulations within the inclusions, which stain faintly basophilically and on which Goodpasture is inclined to rely are, as he admits, to be seen only rarely—indeed, their presence is much more the exception than the rule—whereas active virus is present somewhere in the affected tissues in great abundance No proof has been offered that in the case of these ill defined granules one is dealing with anything other than finely divided nucleoprotein which is a little more acid in its reactions (i e, more basophilic) than the rest of the inclusion material In nuclei in the process of degeneration it is natural to find variations in the reaction of nucleoprotein, which is so characteristically an amphoteric substance A slight shift in the iso-electric point would be expressed by variation in the response to acid and basic dyes When it comes down to details, the color taken by materials within the nucleus when stains are applied depends so much on fixation, mordanting and degree of differentiation that it is unsafe to base conclusions on any except pronounced differences in tinctorial properties I do not wish to deny that virus III and the virus of herpes enter the affected nuclei They may or they may not do so, but the evidence which has been offered that the viruses are actually microscopically visible within the injured nuclei is not, in my opinion, convincing

One can only speculate as to how the inclusions are produced There are many possibilities which are difficult to test experimentally The viruses being substances, nonliving or living, which it has never been feasible to secure in the pure state and which are only recognizable by their injurious action, may, remaining invisible, enter the nuclei or act merely at the surface of the nucleus, on the cytoplasm or on the cell membrane At present one cannot say which No extraneous material has been detected within the injured nuclei It is true that the nuclei are sometimes swollen, indicating an entrance of fluid Some kinds of nuclei are more prone to do this than others, but one does not know what the fluid is It may contain virus just as watery filtrates contain virus

Evidently, therefore, until facts to the contrary are presented, it is logical to look to the normal contents of the nuclei for the material giving rise to the inclusions In all nuclei, there is some acidophilic and some basophilic material, though the basophilic material predominates Under the influence of the virus, the former is greatly increased in amount and concentrated in the central parts of the nuclei, while the latter is marginated on the nuclear membrane and is decreased in amount, finally disappearing entirely This could be explained on the basis of a change in hydrogen ion concentration, but of such a change

one has no evidence The increase in acidophilic (in reality basic) material might also be due to either increased formation or unmodified formation coupled with decreased elimination, but again one has no measurements to go on

The intranuclear inclusions in several other virus diseases seem to be formed in much the same way as those of herpes and virus III, but the details of the process remain to be ascertained Further detailed comparisons, under controlled conditions, will be required before the exact degree of specificity of the inclusions for the action of individual viruses can be measured

When, finally, one learns how the viruses injure and kill just as one knows the pharmacologic action of a few substances, it will presumably be possible to produce intranuclear inclusions experimentally by other agents than viruses If this production of typical intranuclear inclusions should even be realized by purposefully altering the activity of cells, it is possible that a virus will at the same time have been created but this would not necessarily be so For the present it seems to me than one must hold an open mind As I have insisted elsewhere,[13] the presence of intranuclear inclusions in unknown conditions should not be taken at face value as indicating the action of some filtrable virus This point of view differs from that of Cole and Kuttner,[3] who, in the case of nuclear changes like those occurring in herpes simplex, assume a virus to be present unless its absence can be demonstrated

SUMMARY

The comparison of inclusions caused by herpes and virus III in the testicles of rabbits under controlled conditions forty-eight hours after inoculation shows that

1 The herpetic inclusions are more finely granular and less compact than the virus III inclusions

2 The clear halo separating the herpetic inclusions from the nuclear membranes is narrower than in the case of the virus III inclusions

3 The herpetic inclusions being less dense, are tinged more lightly when the Feulgen reaction is applied than the virus III inclusions, though both usually give a negative reaction A few fine particles are occasionally visible intensely colored by this test in the midst of the ground substance of the inclusions, particularly in those produced by virus III

13 Cowdry, E V, and Scott, G H A Comparison of Certain Intranuclear Inclusions Found in the Livers of Dogs with the Inclusions Caused by Virus III, Arch Path 9 1184 1930

4 Both types of inclusions may occasionally exhibit a basophilia, either in a diffuse way of the ground substance of the inclusions or of fine particles embedded in them This basophilia is not necessarily indicative of the presence of virus The diffuse and punctate basophilias seem to correspond respectively with the light coloration of ground substance and the intense coloration of fine particles obtained in it by the employment of the Feulgen reaction

5 Both types of inclusions in rare instances contain a few chromophobic vacuoles This is particularly noticeable in virus III inclusions

6 Both types of inclusions are equally resistant to solvents contained in fixatives employed in the preservation of tissues

ADDISON'S DISEASE ASSOCIATED WITH CONGENITAL ABSENCE OF THE SUPRARENAL GLANDS *

EDWARD H CROSBY, M D
Junior Eugene Littauer Research Fellow in Pathology, Albany Medical College
ALBANY, N Y

Thomas Addison [1] in 1849 first described the symptom complex which today bears his name His description in 1855 of the characteristic features of the morbid state, namely, anemia, general languor and debility remarkable feebleness of the heart action, irritability of the stomach and a peculiar change of color in the skin, occurring in connection with a diseased condition of the suprarenal capsules, remains complete In the eleven cases reported by him the lesions found in the suprarenal glands were as follows tuberculosis, six, cancer, four, and atrophy, one

The suprarenal glands were discovered by Eustachius [2] in 1563 The oldest record of an illness which might have been Addison's disease was reported by Maranon [3] This writer found an account of the illness of a young priest, which was recorded in the "Historia primitivia y exacto monasterio del Escorial" The priest's illness occurred in the years from 1554 to 1557 and dated from a fright incurred during a storm when lightning struck the monastery The illness was one of melancholia and emotional instability, the color of the skin changing to a sad pallor The patient lingered along from bad to worse, and finally died after an illness that lasted three years

Wilks [4] reviewed thirty-three instances of this condition, including five of Addison s original cases Although he did not recognize the nature of the lesion in the suprarenal glands, there is little doubt from his description that they were all tuberculous

---

Submitted for publication, Jan 20, 1930

* From the Department of Pathology, Albany Hospital

1 Addison, Thomas Anemia, Disease of the Suprarenal Capsules, London M Gaz **43** 517, 1849, On the Constitutional and Local Effects of Disease of the Suprarenals, London, S Highly, 1855

2 Eustachius quoted by Garrison, F H History of Medicine, ed 2, Philadelphia, W B Saunders Company, 1917

3 Maranon, G Siglo med **70** 605, 1922, abstr, J A M A **80** 881, 1923

4 Wilks, Samuel On Diseases of the Suprarenal Capsule or Morbus addisonii, Guy's Hosp Rep **8** 1, 1862, Cases of Suprarenal Disease with Remarks, ibid **11** 23, 1865 Wilks Samuel, and Daldy, T M On the Constitutional and Local Effects of Disease of the Suprarenal Capsules in "A Collection of the Published Writings of Thomas Addison ' London, The New Sydenham Society, 1868

Barlow [5] reported a case in a woman, 42 years old, who died showing the classic addisonian syndrome At necropsy, extreme atrophy of both suprarenal bodies was found The atrophy was so marked that the suprarenal glands were not discovered until the abdominal organs had been removed from the body and a careful dissection made In one of the kidneys was a gummatous lesion, but Barlow did not associate this with the atrophy of the glands He mentioned Legg, Godhart, Eastes, and Davy as having described similar cases Coupland [6] reported a case of Addison's disease with necrospy, in which there was no trace of the right suprarenal and in which the left gland was about one third the normal size At that time, he was able to find five similar cases reported in the literature, one with entire absence of both suprarenals

Lewin [7] made an extremely comprehensive review of the literature to 1892 In his first report he cited 683 cases of Addison's disease In two of these there was complete absence of both suprarenal glands, in four cases the right gland, and in two the left gland could not be found In the first series were twenty-three cases of Addison's disease in which both glands were markedly atrophied In his second report of three hundred and ninety-two was one case of Addison's disease with complete absence of both suprarenal glands, three with the right and one with the left suprarenal gland absent In the second report were ten cases with both suprarenal glands markedly atrophied

Phillips [8] reported one case of Addison's disease with atrophy of the suprarenal gland as the essential lesion In the literature at that time he found reports of fourteen instances of simple atrophy of the suprarenal glands associated with symptoms of Addison's disease He stated that his case was the first reported in this country and that in three cases the glands had been entirely absent

Spencer [9] reported a case of Addison's disease in which at necropsy entire absence of the suprarenal glands was noted

Chvostek [10] described a young man in whom Addison's disease developed following a bilateral perinephric infection which resulted in total destruction of the suprarenal glands with death in a short time

---

5 Barlow, Thomas Simple Atrophy of the Suprarenal Capsule and Gumma of the Kidney in a Case of Addison's Disease, Tr Path Soc London **36** 433, 1885

6 Coupland, Sidney Atrophy of Adrenals with Addison's Disease, Tr Path Soc London **36** 423, 1885

7 Lewin, G Ueber Morbus addisonii, Charite-Ann **17** 536, 1892

8 Phillips, Carlin Addison's Disease with Simple Atrophy of the Adrenal Bodies, J Exper Med **4** 581, 1899

9 Spencer, cited by Hektoen and Riesman Text Book of Pathology, Philadelphia, W B Saunders Company, 1901

10 Chvostek, cited by Tieken, T Addison's Disease Report of a Case with Acute Onset Terminating in Rapid Improvement and Complete Recovery, Am J M Sc **152** 422, 1916

Bittorf [11] collected from the literature reports of forty-seven cases of Addison's disease in which necropsy revealed atrophy of the suprarenal glands To this series, he added five of his own, three coming to necropsy with the same condition In a study of the suprarenal glands, three showed involvement of the cortex only, the remainder, involvement of the whole organ In all but one case there was present a hyperplastic condition of the lymphoid tissues He believed with Loffler [12] that there is a relation between status thymicolymphaticus and Addison's disease

Swan and Bortree [13] reported seven cases of Addison's disease Tuberculosis of the suprarenal glands was present in all three cases They found that the death rate from Addison's disease was 0 4 per hundred thousand population for the registration area of the United States Rowntree [14] gave the death rate for the British Isles as 0 6 per hundred thousand and of Japan as 0 04 per hundred thousand population

Mohler [15] and Fleming [16] each reported a case of Addison's disease in which necropsy showed gross absence of suprarenal tissue However, microscopic examination of the fatty tissue in the area where the suprarenal glands are normally found revealed small islands of chromaffin tissue

Pappenheimer [17] published a study of hypoplasia of the suprarenal glands in association with malformations of the brain In the older references, the statement was frequently made that in cases of anencephaly and kindred malformations the suprarenal glands may be entirely wanting In concluding he made the statement that the small size of the suprarenal gland is due wholly to the failure of development of the fetal zone of the cortex, and suggested that it is this transitory cortical tissue which is in some way correlated with the normal development of the brain Kohn [18] stated that severe malformations or absence of suprarenal glands occur almost solely in monsters especially anencephaly

---

11 Bittorf, A Addison's Disease of Suprarenals, Munchen med Wchnschr **73** 1928, 1926

12 Loffler, W Beitrag zur Kenntnis der Addison'schen Krankheit, Ztschr f klin Med **90** 265, 1920

13 Swan, W H, and Bortree, L W Addison's Disease with Report of Cases, Boston M & S J **194** 712, 1926

14 Rowntree, L G, and Snell, A M Clinical Experience with Addison's Disease, Ann Int Med **3** 6, 1929

15 Mohler, H K Addison's Disease Discussion of Symptoms, Report of a Case with Autopsy Findings, M Clin North America **4** 1255, 1921

16 Fleming, C M Fatal Case of Addison's Disease, Brit M J **1** 951, 1922

17 Pappenheimer, A M Hypoplasia of Adrenals in Anencephaly, Proc New Path u path Anat **40** 387, 1927

18 Kohn A Anencephalie und Nebenniere, Arch f mikr Anat u. Entwicklungsm **102** 113, 1924

Conybeare[19] collected a series of cases of Addison's disease which occurred between the years 1904 and 1923 at Guy's Hospital, all with necropsy Of the twenty-nine patients, twenty were males and nine, females, and in more than half death occurred between the ages of 20 and 40 In twenty-two the suprarenal glands were found tuberculous, and in several they appeared to be in a condition of simple atrophy In one case of simple atrophy, the condition was so extreme that complete and careful search failed to reveal any evidence of either gland The cases with atrophy of the suprarenal glands showed remarkable freedom from tuberculous lesions and in only two of the seven cases was there old tuberculous scarring in the lungs and in none any evidence of active or recent tubercle

Wahl[20] cited a case of Addison's disease in which there was a condition of the suprarenal glands resembling atrophy, but which he believed to be a perverted and prolonged embryonic process

Harbitz[21] stated that in twenty-five years he had examined twenty-two cases of Addison's disease, and had always found extensive destructive lesions in both suprarenal glands Tuberculous lesions were present in twenty, and severe and chronic inflammation and atrophy in two cases. Krause[22] associated atrophy of the suprarenal glands in Addison's disease with a pathologic condition in the hypophysis

Voigt[23] reported the case of a woman, 43 years old, who died following one year of progressive weakness, loss of weight, vertigo and increasing pigmentation of the skin The Wassermann reaction of the blood was strongly positive The clinical diagnosis was Addison's disease At autopsy, in spite of careful search in the region of the kidney and the entire abdomen, no suprarenal tissue was found on either side Suprarenal arteries could not be demonstrated A definite status lymphaticus was present

Wakefield and Smith[24] reported three cases of Addison's disease with necropsy on two of the patients One showed caseous degeneration of both suprarenal glands The other showed two types of lesions,

---

19 Conybeare, J J, and Millis, G C Observation of Twenty-Nine Cases of Addison's Disease Treated in Guy's Hospital Between 1904-1923, Guy's Hosp Rep **74** 369, 1924

20 Wahl, H R Malformation of Adrenal Glands with the Clinical Picture of Addison's Disease, M Clin North America **7** 1357, 1924

21 Harbitz F The Suprarenals in Addison's Disease, Norsk Mag f Laegevidensk **87** 371, 1926, abstr, J A M A **87** 290, 1926

22 Krause, E J Zur Pathologie des Morbus addisonii, Beitr z path Anat u z allg Path **78** 282, 1927

23 Voigt, W Angeborenes Fehlen beider Nebennieren, Centralbl f allg Pathol u path Anat **40** 387, 1927

24 Wakefield, E G, and Smith, E E Addison's Disease, Suprarenalopathies, Sclerosis of the Glands of Internal Secretion, Am J M Sc **174** 343, 1927

one gland could not be found, and the other showed an acute process superimposed on an old sclerosis They believed that the gland which could not be found was destroyed by the same process as was present in the other gland The family history is interesting in that seven males in four generations had had bronzing of the skin from birth It suggests a congenital lack of chromaffin tissue and perhaps a similar cause for the absence of the one gland

Kovacs [25] reported eight cases of Addison's disease In four, tuberculous degeneration of both suprarenal glands was found, and in the other four the glands were markedly atrophied In one case, the atrophy was of the so-called idiopathic type and in the other three, the suprarenal vessels were thrombosed He said nothing about the embryonal development of the suprarenal glands or the possibility of a congenital absence of these glands

Keifer [26] reported the case of a woman, 58 years old, who died of Addison's disease Necropsy disclosed a high grade of atrophy of the suprarenal glands with some fibrous regeneration

Medlar [27] reported two cases of Addison's disease, one with status thymicolymphaticus, in which the suprarenal glands were small and firm Microscopic examination showed marked atrophy of the cortex and large areas with no suprarenal parenchyma Marked fibrosis of the cortex and medulla and lymphocytic infiltration throughout both organs were present In the second case with generalized lymphoid hyperplasia, no suprarenal glands could be found on gross examination and no accessory suprarenal tissue around or in the kidneys, along the ureters or in the pelvic tissue A section of the tissue in the region where the suprarenal glands are normally found showed here and there small clumps of cortical or of medullary tissue in which there was extensive lymphocytic infiltration The areas containing suprarenal parenchyma showed some of the parenchymal cells necrotic and invaded by mononuclear and polymorphonuclear leukocytes Both of these cases were associated with lymphoid hyperplasia, and Medlar was of the opinion that "Addison's syndrome is produced only in cases of extreme suprarenal insufficiency and that status thymicolymphaticus is but an indication of adrenal insufficiency"

Brenner [28] reported five cases of Addison's disease in which atrophy played the important rôle In his fifth case, no suprarenal tissue was

25 Kovacs, W Zur Nebennierenpathologie, Beitr z path Anat u z allg Path **79** 213 1928

26 Keifer, Hans Addisonsche Erkrankung infolge chronischer Nebennieren Dystrophie mit adenomartigen Regeneraten, Arch f path Anat **265** 472, 1927

27 Medlar E M A Report of Two Cases of Essential Adrenal Insufficiency (Addison's Disease), Am J Path **3** 135, 1927

28 Brenner O Atrophy of Cortex of the Suprarenals, Quart J Med **22** 121, 1928

found in spite of prolonged search He suggested that the pathologic process is a necrosis of cortical cells caused by some unknown toxin which has a special affinity for them The few cortical cells left after the primary damage are probably overworked and the subsequent degeneration is possibly due to exhaustion atrophy

Lawrence and Rowe [29] reported nine cases of Addison's disease In six cases, no necropsy was performed, but in the others the suprarenal lesions were as follows atrophy one, tuberculosis one and carcinoma one

Karsner [30] pointed out that atrophy of the suprarenal glands may occur in old age, and he found one instance of Addison's disease with atrophy of the suprarenal glands as the essential feature

Philpott [31] reviewed 2,550 cases in which autopsy was performed and found fourteen which could be classified as Addison's disease The suprarenal lesions in these were as follows tuberculosis seven, metastatic carcinoma four, mycosis fungoides one, simple atrophy one and amyloidosis one He went on to discuss the case of amyloidosis and failed to mention further that of simple atrophy

Petter [32] made a brief review of the literature and found one hundred and twenty-one cases of Addison's disease reported showing pathologic evidence in the suprarenal glands as follows atrophy twenty-two, tuberculosis eighty-nine, carcinoma seven, mycosis fungoides one and amyloidosis, one According to his report, he found no cases in which the suprarenal glands could not be found

Barker [33] reviewed the literature of Addison's disease to 1929 and added twenty-eight cases collected in the previous eighteen years at the Mayo Clinic In one, complete absence of suprarenal tissue was noted In another, one suprarenal gland was a solid calcified mass about the size of a normal gland, and the only remains of the other gland were two small nodules of rather dark colored tissue, each about 5 mm in diameter Histologically, these consisted of deeply pigmented medullary tissue with a narrow margin of normal sized but deeply pigmented cortical cells

---

29 Lawrence C H, and Rowe, A W Studies of the Endocrine Glands, Endocrinology **13** 1, 1929

30 Karsner, H T Text Book of Human Pathology, Philadelphia, J B Lippincott Company, 1926

31 Philpott, N W Addison's Disease in Association with Amyloidosis, Ann Int Med **1** 613, 1927-1928

32 Petter, C K Addison's Disease, with Report of Two Cases and Review of the Literature, Minnesota Med **12** 194, 1929

33 Barker, N W The Pathologic Anatomy in Twenty-Eight Cases of Addison's Disease, Arch Path **8** 433, 1929

Debarge[34] discussed the case of a previously healthy man, aged 90, who died apparently of bronchopneumonia Autopsy disclosed, in addition to the pneumonia, complete absence of the right suprarenal gland There was none on the left in the normal place, but a small mass was found in the retroperitoneal tissue near the tail of the pancreas Serial sections of this mass revealed nothing which could be identified as suprarenal tissue, but there was considerable tuberculous caseation The right kidney contained a tumor mass which almost doubled its normal size It consisted microscopically of fibrous tissue, necrotic material and typical suprarenal cortical cells Chromaffin cells could not be identified by staining The tumor cells showed malignant changes The author concluded in his second paper that prolonged life is possible with an infinitesimal number of suprarenal cortical cells, and that a strictly cortical malignant hypernephroma can reproduce exactly the function of normal suprarenal cortical cells

REPORT OF CASE

The case here described is from the medical service of Dr Thomas Ordway, of the Albany Hospital, who permitted me to use the clinical record, Dr F Constance Stewart supplied the clinical history

History—A white woman, aged 35, unmarried, entered the Albany Hospital in a state of marked asthenia She gave a history of progressive weakness for a period of five months This had been intensified during the few days before admission owing to the increased nausea and vomiting that had developed

Because of the extreme illness of the patient and the lack of any family from whom to obtain an adequate history, little information as to the previous events in her life was ascertained She had lived with her parents until they died a few years previously Recently she had attempted light housekeeping

Examination—When one first saw the patient, one was impressed not only by her extreme prostration, but also by the uniform brown pigmentation of her skin This was most marked on the exposed surfaces of the face, neck, hands and arms She appeared as one recently returned from a vacation by the seaside, but she had not had prolonged exposure to the sun's rays since making a tour through the southwestern states the preceding winter The mucous membranes, which were slightly cyanotic, showed no pigmentation

In addition to the asthenia and pigmentation, the most marked physical abnormalities were the weakness of the heart sounds and the very low blood pressure When the patient was first seen, no sounds could be heard by the auscultatory method of obtaining the blood pressure An effort was made to raise the blood pressure by injections of epinephrine hydrochloride, but at no time did the systolic pressure get above 76 mm of mercury, or the diastolic above 50 mm She complained greatly of soreness and stiffness in various parts of the body where the injections were given Because of this low pressure, all attempts to obtain blood for chemical and serologic studies were unsuccessful

34 Debarge, Claire Hypernephroma with Suprarenal Aplasia, J de physiol et de path gen **26** 639, 1928, abstr, Arch Path **7** 1115, 1929

The urinalysis showed a slight trace of albumin with a rare leukocyte and an occasional cast The hemoglobin was 93 per cent (Sahli), the red blood cells, 4,590,000, the white blood cells, 3,320, with a differential count of 65 per cent neutrophils and 35 per cent lymphocytes The temperature ranged between 95 5 and 101 F The pulse rate fluctuated between 70 and 130, and the respirations varied from 20 to 30 per minute

After the fluids had been forced for a few days, first by proctoclysis and then by mouth, the patient improved so that a careful roentgenographic study of the lungs and the gastro-intestinal tract could be made No pathologic changes were revealed to aid in the diagnosis The heart appeared smaller in size than the usual normal

Although the patient had shown a few signs of improvement, she suddenly became much weaker on the twelfth day after admission and died

Diagnosis—A clinical diagnosis of Addison's disease was made Anatomic diagnoses Addison's disease, congenital aplasia of the suprarenal glands and edema of the lungs Microscopic diagnosis congenital aplasia of the suprarenal glands, with ectopic foci of suprarenal cortical tissue, acute congestion of the lungs, congestion of the spleen and cutaneous melanosis

Necropsy—Necropsy was performed seven and one-half hours after death by Dr V C Jacobsen and Dr E H Crosby The body was that of a fairly well developed, poorly nourished white woman, 64 inches (162 6 cm) long Rigor mortis and postmortem lividity were present, with moderate edema of the feet and ankles There was a marked brownish tinge of the skin over the face and neck, and spots of brownish pigment over the chest and abdomen

The right inguinal glands were enlarged The hair was brown, turning gray Ears, nose and mouth were normal A small conjunctival hemorrhage was present in the left eye

The abdominal fat appeared normal The mesenteric lymph nodes were slightly enlarged, and the retroperitoneal lymph nodes were about 1 5 cm in diameter and were hard, but not caseous

The pleural and pericardial cavities were normal The mediastinal glands were not enlarged

The heart was in systole It was somewhat reduced in size The coronary vessels were not palpable

The lungs were moderately edematous throughout The hilic lymph glands were of normal size

The spleen weighed 145 Gm It was slate blue externally and soft On section, the lymphoid follicles were prominent

The gastro-intestinal tract, pancreas and liver were normal

The gallbladder was dilated and its wall thickened Three large stones could be felt in its cavity and one in the cystic duct The external surface was streaked with red, especially in the fundus On section, the wall was thickened and firm It was filled with a mucous, watery fluid Three large mulberry stones, 2 cm in diameter, lay free in the lumen The gall ducts were patent

The kidneys weighed 110 Gm each They were of similar appearance The capsule stripped with slight difficulty and left a smooth surface On section, fine whitish streaks were seen throughout the cortex The cortex averaged from 4 to 5 mm in thickness, and the general topography was normal The pelvis and ureters were normal

The urinary bladder was contracted and empty

The uterus was small and firm, the tubes normal The ovaries were small and, on section, contained several cysts filled with a clear yellow fluid

The aorta revealed a few yellowish atheromatous patches in the abdominal portion

Search was made for the suprarenal glands in situ, but they could not be found after close inspection of the abdomen and the retroperitoneal tissues The kidneys, the perirenal fat and the surrounding tissues were removed en masse The perirenal tissue was carefully dissected and explored Nothing resembling suprarenal tissue could be discovered Several enlarged lymph nodes were encountered All the loose retroperitoneal tissue was therefore put in Zenker's fluid for microscopic

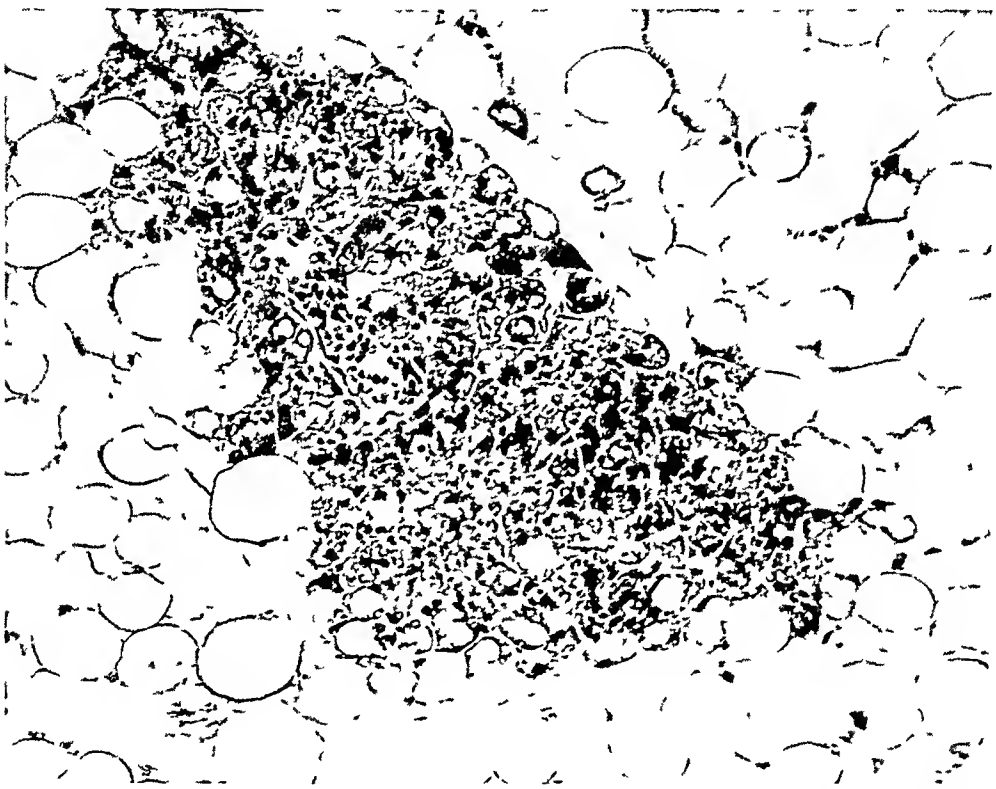

Fig 1—Photomicrograph of a section taken from the retroperitoneal tissues about the superior poles of the kidneys showing a compact islet of cells which much resembles the zona reticularis of the suprarenal cortex Near the center is a nutrient vessel

study Nothing was seen on any of the viscera, suggestive of aberrant suprarenal tissue

Microscopic Examination—The lungs presented acute congestion, edema, slight hemosiderin pigmentation and catarrhal bronchitis The spleen showed acute congestion and an increased number of polymorphonuclear leukocytes in the blood spaces The gastro-intestinal tract showed some engorgement of vessels in the large intestines The pancreas and the liver were normal In the gallbladder there were chronic inflammatory changes Melanin was present in moderate amount in the malphigian layer of the skin In the kidneys were cortical areas of round cell infiltration A few glomeruli showed capillary sclerosis

In two of the sections of the retroperitoneal tissues, islands of cells were found such as the one illustrated in figure 1 These islands were composed of compact collections of cells which had many points of resemblance to those of the suprarenal cortex the same fine granulation, deeply eosinophilic staining of the cytoplasm, lipoid and fat droplets In addition, some of them contained a pale brownish-yellow pigment suggesting that of the zona reticularis of a suprarenal gland These cell aggregates were not encapsulated, but a nutrient vessel occupied a prominent position in each

COMMENT

Lying as they do, surrounded by fat, the question arises, are these cell groups exhausted fat cells? A conclusive answer is impossible, but in their pigmentation and staining properties they more closely resemble suprarenal cortex than exhausted or fetal fat cells No rests of the appearance of medullary tissue were found, but the chromaffin tissue of suprarenal origin is not so characteristic as to be identified with certainty The patient was undernourished but not emaciated, and fat exhaustion is usually seen only in the most cachectic persons It is my opinion that these cell aggregates in the perirenal fat represent suprarenal cortical tissue

Loeper and Ollivier [35] reported the case of a woman, 31 years old, who died showing the classic symptoms of Addison's disease At necropsy, both suprarenal glands were found involved in a fatty metamorphosis in which no inflammatory or infectious process could be demonstrated Figure 2 is a copy of a picture in their article showing the infiltration of fat cells into a portion of a suprarenal gland It can be safely said that at some time in their patient's life suprarenal glands of normal contour probably existed I believe that in the case here reported suprarenal glands as such were never formed, but that the scanty amount of tissue nevertheless was sufficient to maintain life for thirty-five years

It has been shown by Webber [36] that when the suprarenal glands are apparently absent, careful search will often disclose the tissue in other situations, on the liver, on the kidneys or somewhere along the alimentary tract This heterotopia of the suprarenal glands was emphasized by Miloslavich,[37] who collected and reported fourteen cases of heterotopia of the suprarenal glands

35 Loeper, M, and Ollivier, J Metamorphose adipense des deux capsules surrenales avec melanodermie, Bull et mem Soc med d hôp de Paris, **50** 312, 1926

36 Webber, C V Heterotopia of Adrenals in Liver and Kidneys, Am J M Sc **169** 696, 1925

37 Miloslavich, L H Ueber Bildungsanomalien der Nebenniere, Virchows Arch f path Anat **218** 131, 1914

The factors leading to congenital anomalies of the suprarenal glands can be better understood if the embryology of these bodies is reviewed briefly

The cortex and the medulla have entirely different developmental histories [38] In the lower vertebrates (fishes), the two parts of the gland continue separate throughout life In the ascending mammalian scale, the two parts become more and more closely united until in mammals they form a single organ The cortex develops from mesoderm, first appearing in embryos of from about 5 to 6 mm

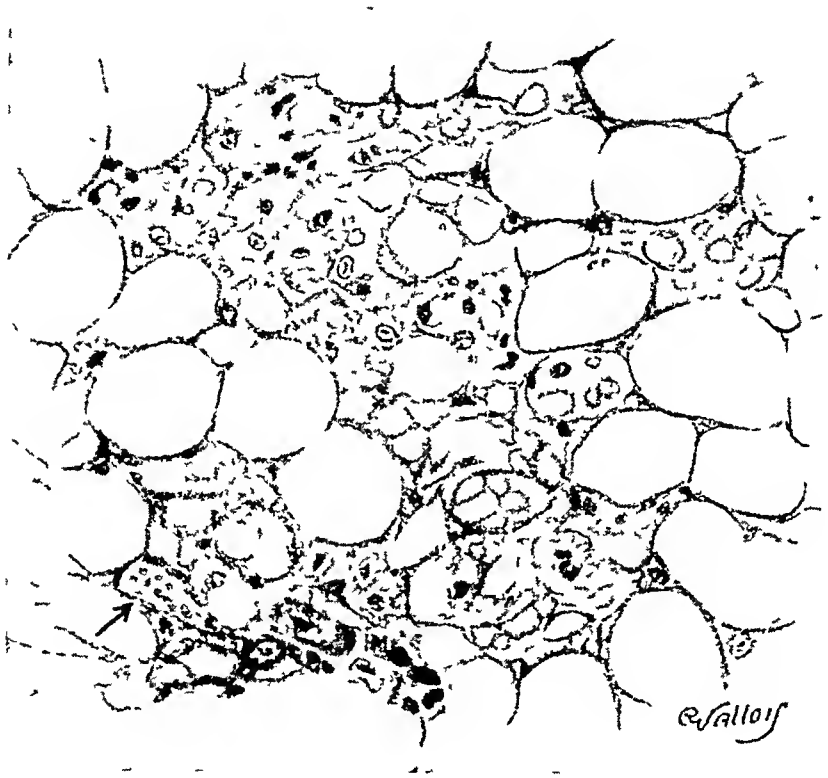

Fig 2—Infiltration of fat cells into the suprarenal gland The arrow points to a blood vessel There is a marked resemblance to the islet in figure 1 The picture is taken from Loeper and Ollivier (Bull et mem Soc med d hôp de Paris **50** 312 [Feb] 1926)

At about the level of the cephalic third of the mesonephros, the mesothelium sends outgrowths into the mesenchyme These outgrowths soon lose their connection with the main mass of mesothelium and constitute the anlage of the suprarenal cortex The medulla has an entirely independent origin, being derived from ectoderm as part of the peripheral sympathetic nervous system The cells of some of the sympathetic ganglions differentiate into sympathoblasts and pheochromoblasts,

38 Bailey, F R Textbook of Histology, ed 3 New York William Wood & Company, 1910

which give rise to the sympathetic cells and the chromaffin cells, respectively These cells soon separate from their ganglions of origin and come to be first near, then within, the developing cortex, thus forming the medulla

From the development of the suprarenal gland, it is apparent that a great deal depends on the two anlagen from the ectoderm and the mesoderm being brought together and surrounded by a capsule Let us suppose that the union failed to take place The cortex and the medulla could lie near each other, but distinctly separate Or they might wander far from their normal resting places and come to lie in widely removed regions The same influences that govern such union might conceivably create a much fragmented suprarenal apparatus These fragments might be very small but sufficient to sustain life up to a certain age after which signs of insufficiency would develop with the typical Addison's syndrome The many insults of disease to which the human body is subjected in the struggle to adulthood might cause degenerative changes in such suprarenal rests or lead to their ultimate exhaustion Graham [39] pointed out that extensive necrotic changes may occur in the suprarenal cortex in diphtheria, scarlet fever, measles and other infectious conditions He mentioned a fatal case of measles in which the suprarenal glands in a woman 35 years old showed complete necrosis of all three cortical zones, as well as of the medulla It is true that a very small amount of suprarenal tissue is sufficient to sustain life, but exactly how much that is for a given age is not known Also knowledge is in an unsettled state as to whether medulla or cortex or both layers can produce epinephrine

It cannot be stated categorically that the retroperitoneal islands present in the case reported here were truly suprarenal tissue I believe that they were, but the evidence as adduced is offered only for what it is worth In the absence of definite suprarenal glands, some form of rest must have sustained life, in this instance, to the age of 35 years

SUMMARY

Of all the diseases affecting the suprarenal glands, atrophy is one of the least common, and absence of these glands is rare It is not known exactly how much suprarenal tissue is essential to life, but a very small amount often seems to be sufficient It is not necessary for suprarenal tissue to be in the normal position, aberrant rests may be found almost anywhere within the abdomen

The case of a woman who died at the age of 35 years is reported, in whom at necropsy no gross evidence of suprarenal tissue could be

39 Graham, G S Toxic Lesions of the Adrenal Gland and Their Repair, J M Research **34** 241, 1916

discovered Microscopically, small islands of suprarenal cortex were found near the superior poles of the kidneys embedded in retroperitoneal fat

It is evident that in cases such as this, the embryonic development of the suprarenal gland has been faulty, but that cortical and medullary tissue has existed in sufficient amount to sustain life for many years, finally to become exhausted, a condition resulting in typical Addison's disease and death

RHEUMATIC PERICARDITIS WITH POLYPOID FORMATIONS *

MILTON G BOHROD, M D
CHICAGO

In the pericardium of a man with typical rheumatic heart disease, a peculiar polypoid mass was found The patient, 27 years old, white, died of cardiac decompensation from rheumatic endocarditis of long standing, with mitral stenosis and regurgitation The endocarditis followed two attacks of rheumatic fever Although the patient was under observation most of the time, clinical evidence of pericarditis was never found

Necropsy disclosed an old mitral and aortic valvulitis with calcification of the large irregular vegetations Engrafted on this old process was a recent mitral, aortic and tricuspid endocarditis in the form of fine pearly nodules at the free margins of the valves The left auricle and both ventricles were greatly hypertrophied, and the left auricle, right ventricle and, most of all, the right auricle were dilated The heart, with the pericardium, weighed 1,400 Gm

The unusual features were in the pericardium (fig 1) There were adhesions between the pericardial layers, in most places fibrinous and easily broken, but in the region of the interventricular septum anteriorly the two layers were firmly bound together From about 75 to 100 cc of cloudy, slightly brownish fluid was found in the sac Both layers were covered by shaggy fibrinous material easily stripped off The color of the pericardium was chocolate brown

At the reflection of the parietal pericardium from the right auricle posteriorly hung a large hydatidiform mass, 7 cm long, 8 5 cm wide and about 2 5 cm thick The distal two thirds of this mass was made up of several dozen bluish, polypoid bodies from 4 to 15 mm in diameter, a few of them solid but most of them filled with blood in various stages of inspissation In some, the contents were thick and chocolate brown From the posterior part of the mass hung a loop of firm tissue, 1 5 mm thick, from the lowest point of this loop, a thinner strand of tissue, 1 mm thick and 4 cm long, descended, and from its tip hung, like a pendant, a flat triangular solid body 17 by 10 by 5 mm A smaller pendant hung by a fine threat from the extreme left of the large mass Over the surface of the auricle and underneath the auricular appendage there were tiny brownish projections, from 0 5 to 3 mm in length, usually solid but occasionally cystic the contents of the cysts being old

* Submitted for publication, March 12, 1930

* From the Department of Pathology and Bacteriology, University of Illinois, College of Medicine

blood When the adhesions anteriorly were removed there were seen isolated blood-containing cysts similar to those in the large mass On the anterior surface of the left ventricle there was a single, button-like projection surmounted by several tiny polypoid masses

Microscopically, the polypoid bodies were cysts with walls of varying thickness, lined by a single layer of flattened cells and filled with erythrocytes (fig 2) The solid bodies showed all the stages from

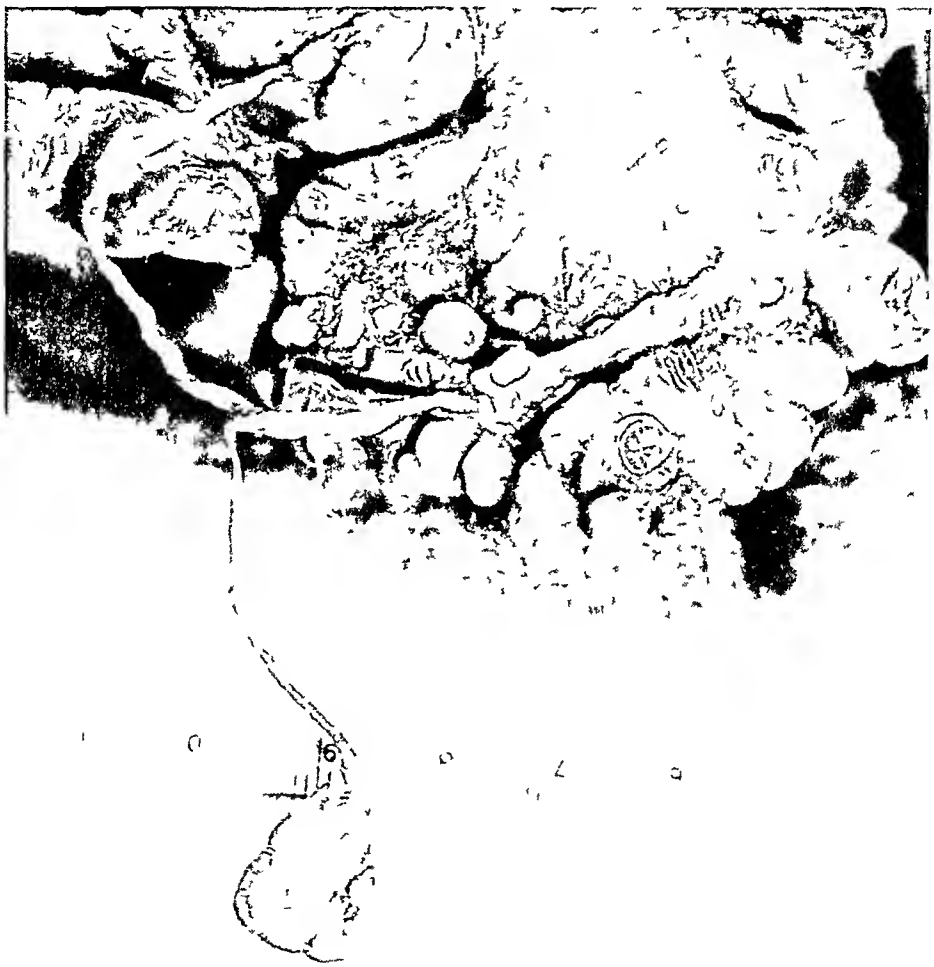

Fig 1—The under surface of the polypoid mass

only partly organized thrombotic masses to old hyaline connective tissue. In the walls of the cysts were many macrophages filled with blood pigment

Between the cysts were dense infiltrations principally of large pale cells of the histiocyte or macrophage type but containing also lymphocytes and a few plasma cells The cells were often large, with two or three nuclei Frequently these accumulations were nodular and near blood vessels giving the appearance of Aschoff nodules, much larger.

however, than those ordinarily found in the myocardium Several of the nodules had necrotic centers

The free surface of the epicardium and often also the external surfaces of the polypoid masses were covered by clumps of fibrin, most of them fused into hyaline masses But in addition to fibrin there were large numbers of red blood corpuscles, some monocytes and lymphocytes The granulocytes were few The fibrin could at times be seen to bridge over two masses of old granulation tissue In such cases, a cystlike space was left filled with red blood cells When the fibrin was adherent

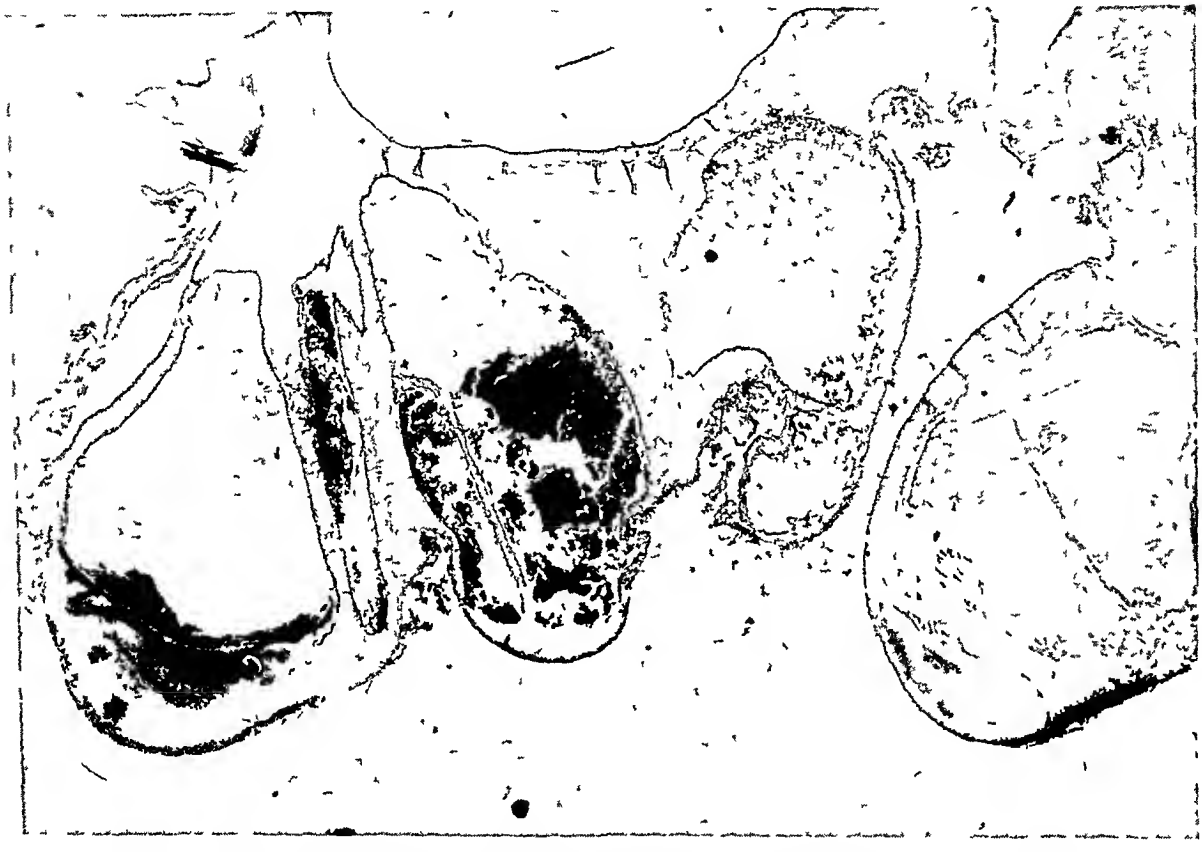

Fig 2—Section through a group of larger polypi Most of the blood has fallen out of the large cysts On the right is one of the solid bodies Hemalum and eosin

to the pericardium or to the older granulation tissue, the endothelium was destroyed, but sometimes endothelial cells, apparently from the periphery, covered part of these newer fibrinous bridges, in a few cases complete endothelium-lined cysts were thus formed, enclosing the hemorrhagic exudate

COMMENT

In a healing or healed pericarditis there are often found endothelium-lined spaces, small or large, in the common large pericardial plaques, they

are frequent Occasionally these spaces become larger, forming small cysts In one case, Lauche[1] found numerous cysts ranging in size to that of a pea, over the surface of the right ventricle The explanation for these spaces and for Lauche's cysts has been that the endothelium-covered, organized fibrinous masses in a fibrinous pericarditis have fused at their tips, enclosing small spaces With the continuous motion of the heart, these spaces gradually became larger This explanation can I think, be substantiated in my case

The only feature left to explain is the blood in the cysts Lauche's cysts were filled with clear fluid If, however, the inflammation had been hemorrhagic, blood would have been enclosed in the cystlike spaces and would gradually have undergone organization That, in the present case, one has to deal with a hemorrhagic inflammation is indicated by the recent recurrent hemorrhagic pericarditis and by the chocolate brown color of the pericardium and the fluid in the pericardial sac Thorel[2] pointed out that rheumatic pericarditis is often hemorrhagic

Grossly the mass in the pericardium resembles somewhat a neoplasm Timme[3] reported a much smaller mass in the pericardium as a cavernous hemangioma It is interesting that in his case, too, mitral stenosis and insufficiency were present Histologically, the "structure showed a collection of dilated blood vessels The walls of these vessels contained no muscle or elastic tissue whatever, they were fibrous in character The contents of the vessels were typical blood clots" Except for the cellular infiltrate between the cysts in my case, the two cases are much alike Perhaps Timme's hemangioma, too, was the end-result of an old pericarditis in which inflammation had long since subsided

The specificity of the Aschoff nodule or its histogenesis cannot be discussed here, but the presence in the pericardium of cellular aggregations in close relation to blood vessels, made up of large cells resembling macrophages, and associated with definite clinical and pathologic evidence of rheumatic endocarditis may be taken as indications of the rheumatic nature of the pericarditis

SUMMARY

A hydatidiform mass in the pericardium is reported, which is apparently unique It is considered to be a peculiar result of the healing of rheumatic hemorrhagic pericarditis

---

1 Lauche, A Cystenbildung auf der Oberflache des Herzens nach Pericarditis Centralbl f allg Path u path Anat **30** 321, 1919

2 Thorel Pathologie des Herzens in Lubarsch und Ostertag Ergebn d allg Path u path Anat **17** 714, 1915

3 Timme A R Cavernous Hemangioma of the Pericardium, Cleveland M J **14** 453, 1915

PERIARTERITIS NODOSA *

REPORT OF A CASE

WILLIAM B KOUNTZ, M D
ST LOUIS

The literature of periarteritis nodosa has been reviewed by Gruber [1] The case reported here, aside from the interest attaching to its clinical course, is important because the distribution of its vascular lesions suggests an explanation concerning the pathogenesis of the disease The author is indebted to Dr Leo Loeb for his advice in the study of this case

CASE REPORT

History—A white man, aged 67, entered Barnes Hospital on March 22, 1927, with the chief complaints of pain in the legs, inability to walk, jaundice and fever His family history seemed irrelevant He had had typhoid fever in youth Since the age of 46, he had suffered from peptic ulcers which, however, could be well controlled by medication He had had nocturia for four years and slight dyspnea on exertion for two years He said that he had not had venereal infection

In February, 1927, he began to experience tingling sensations and shooting pains in the ankles and feet, which were slightly swollen and could not be moved He was unable to leave his bed Two weeks later, his arms became similarly involved Although there were never any definite joint pains, he was treated for five weeks before admission by hot packs and oil of wintergreen rubs, under the impression that the condition was arthritis Two weeks after he became ill, definite jaundice with bile in the urine developed, but when I saw him the jaundice had disappeared

Physical Examination—Examination revealed a heavy-set man, deeply pigmented but sallow His temperature was elevated, and the general picture was that of a severe infection His expression was masklike, his eyes staring, he hiccuped at intervals and had a moderately severe cough, productive of a large amount of thin, greenish, sweet-smelling sputum There was a questionable edema of the optic disks The chest was emphysematous, and a few moist râles could be heard at both bases The heart was enlarged The sounds were distant, but no murmurs were heard The blood pressure was 115 systolic and 70 diastolic The abdomen was full and difficult to palpate The liver was not felt, percussion indicated no enlargement The hands were large and flat, with definite atrophy of the intrinsic muscles There was a toe-drop and wrist-drop All of the deep reflexes were absent, and no plantar response of any kind was present He had hyperesthesia of both hands and feet

The urine was cloudy and at one time was of a dark port wine color which did not change on exposure to light There was no bile, the test for albumin was

---

* Submitted for publication, Feb 11, 1930

* From the Departments of Pathology and Internal Medicine, Washington University School of Medicine

1 Gruber, G B Zentralbl f Herzkrankh u Gefasskrankh 9 45, 1917

4+, for sugar, negative The excretion of phenolsulphonphthalein was 42 per cent in forty-five minutes The nonprotein nitrogen of the blood was 33 mg, and the chlorides of the plasma, 470 mg The carbon dioxide of the plasma was 59 per cent by volume The count of red blood cells was 4,500,000, that of white blood cells, 25,000, with polymorphonuclears 87 per cent and eosinophils 2 per cent

Course—Under observation, the patient's condition became steadily worse The temperature curve became definitely more septic in type The leukocytes remained persistently high Edema of the extremities, especially of the hand, increased with increasing inability to use them Numerous blood cultures were negative both under aerobic and anaerobic conditions After two transfusions, red blood cells appeared and persisted in the urine The blood pressure shortly after admission rose to 160 systolic and 100 diastolic and in subsequent days continued to rise, slowly but rather steadily Three weeks after admission, the patient suddenly became stuporous His blood pressure rose to 200 systolic and 100 diastolic, the temperature began to fall, the pulse rate became more rapid, albumin and red cells increased in the urine, the nonprotein nitrogen rose to 95 mg, and the patient died

Pathologic Examination—The pathologic examination showed the body to be that of a well developed and fairly well nourished white man about 67 years of age When the body was opened, no excess fluid was found in the cavities The heart was enlarged, weighing 473 Gm The heart muscle, on section, appeared normal, although a slight degree of coronary sclerosis was noted grossly The endocardium was normal A patent foramen ovalis was present Microscopically, accumulations of small groups of lymphocytes were seen about some of the smaller blood vessels Adhesions were present at the apices of both lungs, binding them to the chest wall On section, frothy fluid exuded, and one saw small granular areas, probably areas of bronchial pneumonia Microscopically, only occasional areas of bronchial pneumonia were found

The liver was enlarged, weighing 2,480 Gm On the uncut surface, there were numerous raised granular areas about the size of a dime On section of the organ, the granular portions stood out distinctly from the remainder of the liver tissue Toward the center of the organ, these areas became confluent The granular portion was much softer than the surrounding liver tissue, and could be removed by scraping with a knife Many of the vessels in the upper portion of the right lobe were thrombosed This was true of the portal veins and probably to some extent of the arteries

Under the microscope, the liver cells in the granular necrotic areas were swollen and contained numerous small vacuoles, which with a sudan III stain revealed an increase in fat Throughout the liver, the central veins were dilated, as were also the sinusoids about them A moderate degree of chronic passive congestion of the organ was noted, with some destruction of the parenchymatous cells about the central vein There was a marked increase in the peripheral connective tissue throughout the entire liver, and the periportal spaces were greatly widened with new formation of connective tissue In some of these periportal areas in the right lobe, the hepatic artery and bile ducts appeared uninvolved in any process, but the portal vein could barely be recognized as such, because of the change that had taken place The veins had a necrotic wall, and in many of them the lumen contained a small amount of fibrin and clot In the tissue about the vessels, many lymphocytes and polymorphonuclear leukocytes were present In some periportal areas the veins were seen as thick-walled vessels with

connective tissue growing into the lumen Many newly formed bile ducts were present in the periportal tissue, and an amitotic division of the cells was seen in the fibrous tissue in the periportal areas Also in this area some of the branches of the hepatic arteries showed an acute and a subacute inflammatory change The media of the affected vessels took a deep red stain and stood out as a hyaline mass Some of the vessels which in places had disintegrated showed an infiltration of the hyaline layer with polymorphonuclear leukocytes In the vessels undergoing this change, the media had completely or almost completely disappeared The intima of the involved vessels showed a marked proliferative change In many of the vessels in the acute state, the proliferation did not uniformly involve the whole wall, only a small irregular projection of fibrous tissue in the lumen being visible In the late or granulomatous stage, the lumen was practically obliterated by a concentric ingrowth of the tissue Lymphocytes were present in large numbers in the fibrous tissue in the external portion of the vessels In the earlier stages of the disease, many of the vessels were thrombosed, and organization of the thrombus was taking place About the thrombosed vessels and those showing the acute process were many polymorphonuclear leukocytes, chiefly located in the immediate vicinity of the necrotic hyaline wall or the thrombus, or about both In a zone more distal to the lumen of the vessel were many lymphocytes and a few polymorphonuclear leukocytes

About the vessels in which the lesion had passed into the subacute stage, lymphocytes alone were in the walls Most of the involved vessels showed a concentric lesion In a few of them, however, only one side was involved Many of the arteries in the right lobe of the liver, measuring from 2 to 5 mm in diameter, were involved in the process to a greater or lesser degree The smaller branches of the hepatic artery, with a diameter of from 1 to 2 mm, were rarely involved Although none was seen in the acute state, with the degenerative process in the wall, many were undergoing the process of endarteritis obliterans, and in the lumen of others there was a clot which was undergoing organization

The wall of the gallbladder was thickened, the lumen was small, and on the mucosal surface were seen many fine white flakes of fibrin-like membrane The cystic vein was thrombosed Under the microscope, one saw that the wall of the gallbladder was thickened and infiltrated with many lymphocytes The arteries of the organ had undergone a process of obliteration similar to that observed in the liver The process was, however, in the more advanced stage About the vessels there was a cellular fibrillar material with many lymphocytes Around the intima were found a few broken, pink-staining fragments of the necrotic media containing lymphocytes and a few polymorphonuclear leukocytes Over this necrotic media, there was a thickened intima which in many instances had nearly obliterated the lumen of the vessel In some areas, the newly formed intima was covered with endothelium, and the lumen had become round and of more or less normal contour In other vessels, no endothelium was noted on the surface, and the lumen was irregular, suggesting that the process had gone so far that only a small opening represented the lumen Usually, these were noted on the outside of a concentric ring of fibrous tissue and were in all probability the vasa vasorum of the degenerated artery In this organ again, the smaller vessels ranging to 0 2 mm in size showed an endarteritic change, but did not show the granulomatosis periarteritica revealed by the large vessels The cystic vein was thrombosed, and fibroblasts could be seen growing into the thrombus and organizing it This vessel also showed a definite granulomatosis with thickened fibrous tissue wall and lymphocytes

The spleen was enlarged and soft On section, it presented the appearance of an acute splenic tumor Microscopically, it showed a rather marked increase in fibrous tissue, especially about the blood vessels The walls of the vessels were thickened by a clear hyaline connective tissue No evidence of an acute arteritis was noted Many large mononuclear leukocytes and eosinophils, as well as considerable blood pigment, were scattered diffusely throughout the organ The malpighian corpuscles were about normal in size, but appeared to have decreased in number

In the gross, the pancreas appeared normal, except for an occasional thrombosed artery There was some increase in the fibrous tissue Microscopically, a

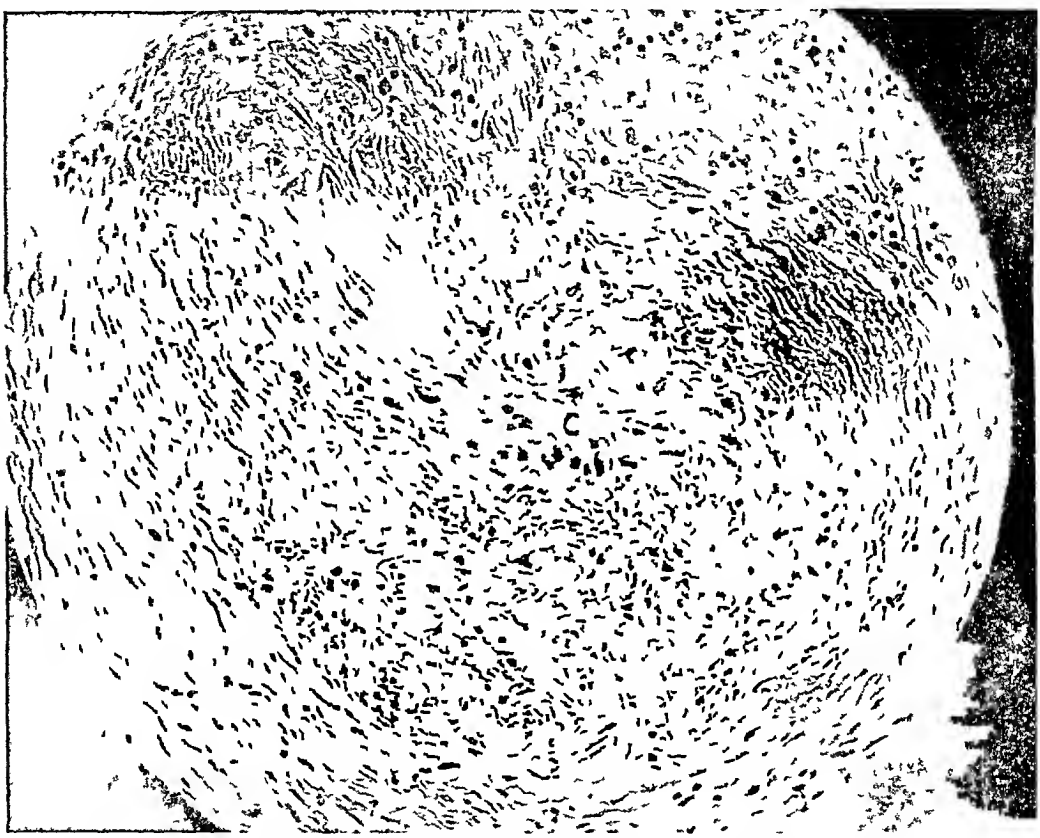

Fig 1—Cystic vein of gallbladder, which has been thrombosed and is nearly completely organized *C* represents the remains of the lumen of the vessel

considerable interlobular and intra-acinous fibrosis of the pancreas was present with much lymphocytic infiltration The fibrosis was most apparent about the blood vessels, especially the arteries The pancreatic cells in the immediate vicinity of the vessels were completely destroyed, while more distally the cells were swollen, large and granular The island cells in the involved areas were degenerating, and only remnants of many cells were left The arteries in the organ showed changes similar to those described in the liver Here the process was in a relatively acute stage In the small arteries, the endothelial cells were large, swollen and vacuolated, the intima of the vessels was thickened, and the arteries were undergoing an endarteritis obliterans In the larger arteries with a lumen

from 2 to 5 mm in diameter, the endothelium was completely absent, although many fibroblasts were present In many of these vessels, thrombi were found in the lumen, but in other vessels, although no clot was seen, the granulomatosis was present and the wall of the vessel was more or less completely involved Microscopically, many of the vessels were seen to be undergoing the same pathologic change that had been observed in other organs.

The kidneys were enlarged and together weighed 596 Gm The capsule stripped readily, leaving a red, granular surface with small reddish areas the size of a pinhead On section, the small red spots were seen to extend deep into the

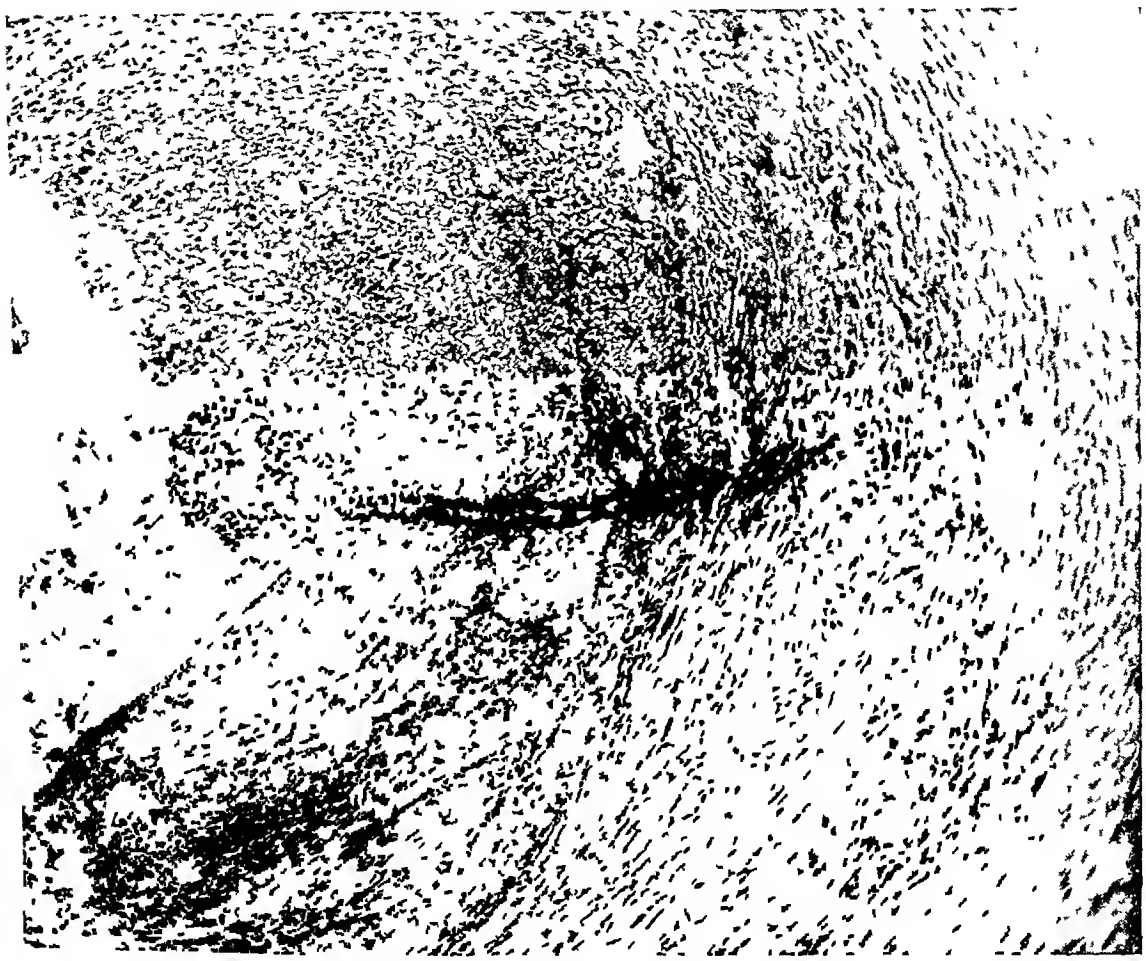

Fig 2—Low power magnification of a branch of the right portal vein, showing a thrombus in the lumen, *A,* thrombus, *B,* organization of the thrombus, *C,* necrotic wall of the vein, *D,* fibrous tissue and compressed liver tissue

kidney tissue, although they were much more prominent in the cortex The glomeruli could be seen as small hemorrhagic points The outer surface of the organs showed numerous shallow scars Under the microscope, one noted a considerable increase in the interstitial tissue, and in some areas it took the form of large scars extending down from the cortex In these areas, the kidney tissue was destroyed, and only a few small shrunken tubules and sclerosed glomeruli remained A moderate degree of lymphocytic infiltration into the area was noted In the remaining kidney substance, the greater number of glomeruli were enlarged,

and some of them had small plugs of fibrin at the base These plugs lay in their afferent vessels about which the wall of the vessel had become necrotic In other glomeruli, one or more capillary loops contained small plugs of fibrinous material occluding the lumen The other involved capillary loops were small and shrunken and had fallen against the capsule of the glomerulus, where they appeared to have become adherent Many of the capillaries containing emboli had ruptured with hemorrhage into the capsular cavity In some glomeruli, the capillary lumen contained polymorphonuclear leukocytes in abundance The endothelial cells in the glomeruli were swollen, and in places presented themselves as a mass in the capillary lumen In areas, two or more of the desquamated epithelial cells had

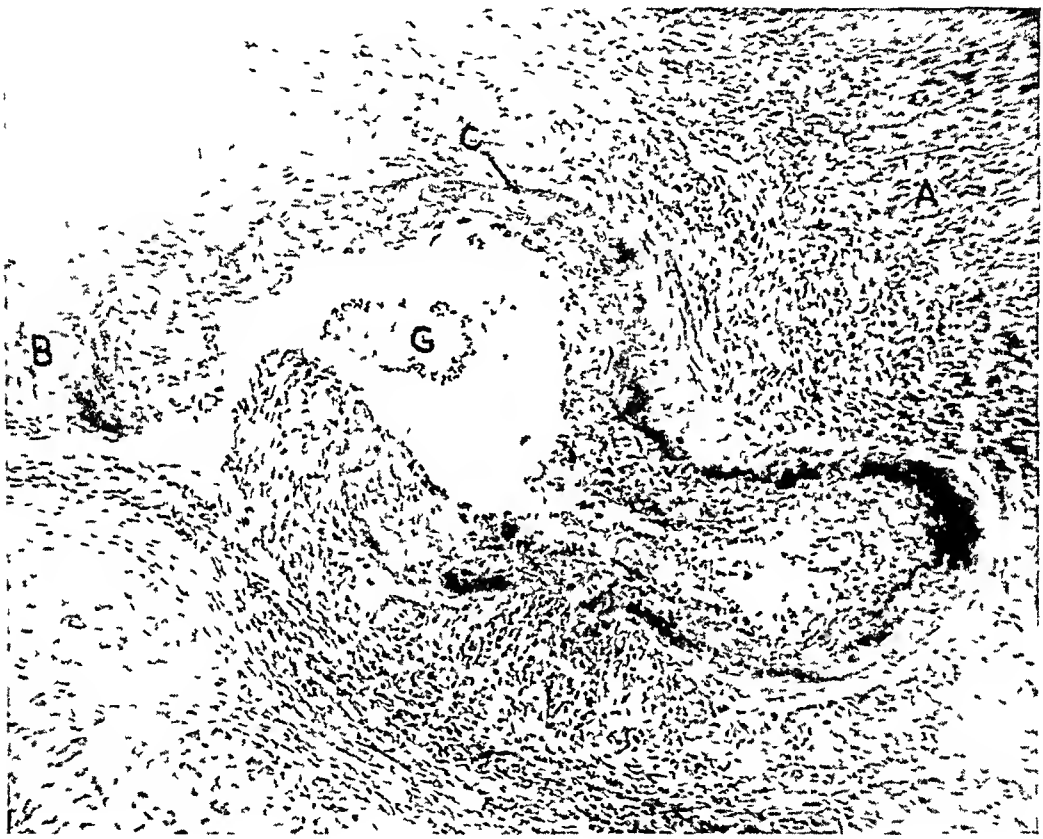

Fig 3—Section of artery in the pancreas showing acute degeneration of the arterial wall, *A,* pancreatic tissue, *B,* fibrous tissue about artery, *C,* necrotic media of vessel with ingrowth of fibrous tissue, *G,* thrombus

fused together In places, the capsular spaces were completely filled with red blood cells In some areas, the tubules were small and presented a low cuboidal epithelium, while in the same field there were some large dilated tubules with necrotic material in the lumen The lumen of many glomeruli was merely occluded by large, granular, swollen epithelial cells Some of the cells in the epithelium of the tubules gave evidences of regeneration by the presence of from two to four nuclei A marked lymphocytic infiltration was present in the interstitial tissue between the tubules and about the glomeruli In the region of the involved arteries, many polymorphonuclear leukocytes were seen in and about the tubules

The vessels of the kidney showed diffuse and rather acute involvement Beginning with the arcuate vessels there was a periarteritic degeneration and proliferation and also a proliferation of the intima of the arteries The lumen of many of the vessels was partially filled with a thrombus which in many cases had become organized The endothelium had desquamated and could be seen as a clump of cells in the clot The intima at points was proliferating and extending into the lumen of the vessels It was composed of stellate cells resembling growing fibroblasts The media of many of the vessels was necrotic, extending as a pink-staining ring of fibrin-like substance around the artery There was a marked leukocytic reaction about the diseased arteries Near the lumen of the vessel were many polymorphonuclear leukocytes These were particularly numerous about the

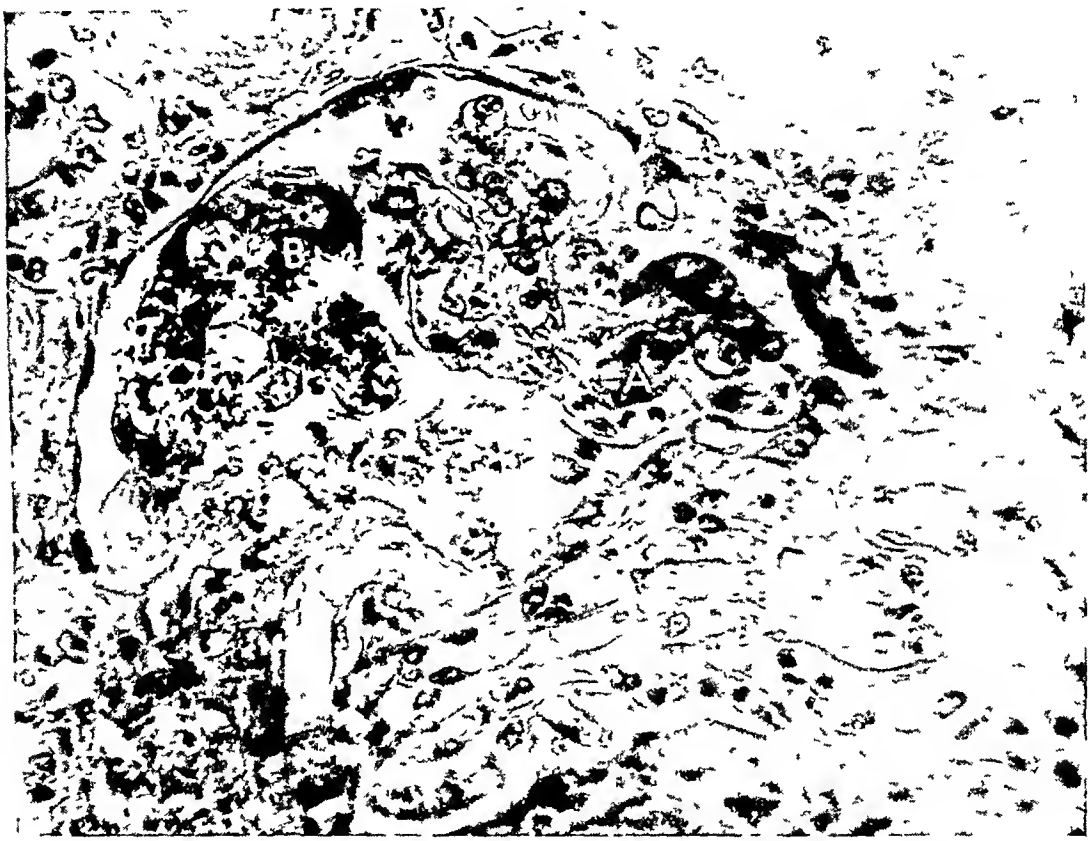

Fig 4—Section of the kidney showing *A*, leukocytes in the dilated capillaries, *B*, necrotic glomerular loop, *C*, hemorrhage into the glomerular cavity

necrotic media, and in areas appeared to have invaded the substance and caused its absorption The adventitia was also greatly thickened, and fibrous tissue extended from it into the surrounding kidney tissue, producing large scars Many lymphocytes were present in the scarred areas The kidney tissue in the periphery of the involved arteries was destroyed, and the glomeruli had become small and hyalinized, the tubules contracted and the epithelium degenerated Many lymphocytes were noted in the tubules in these areas In other parts of the kidney, aside from the acute process, the picture was that of a lesion of chronic interstitial nephritis

The stomach showed a typical hour-glass constriction with thickening near the pyloric end On the mucosal surface, there was a shallow ulcer measuring from 0 5 to 1 5 mm in diameter About 3 cm above the pylorus, at the point of constric-

tion of the stomach, a second ulcer, measuring 4 3 cm, was present on the lesser curvature Its borders were ragged, but it had a clean base A considerable thickening of the mucosa at the edge of the ulcer was noted Under the microscope, the mucosa was seen to be eroded, and the base of both ulcers was clean The duodenal ulcer extended also into the submucosa, while the one on the lesser curvature extended into the muscularis At the base of the gastric ulcer, an artery showing an obliterative endarteritis was observed In one section near the serous coat below the ulcer, a large artery was undergoing degeneration and inflammation of its wall

The prostate was about two and a half times the normal size On section, many nodules were found Microscopically, a hypertrophy of the gland was noted

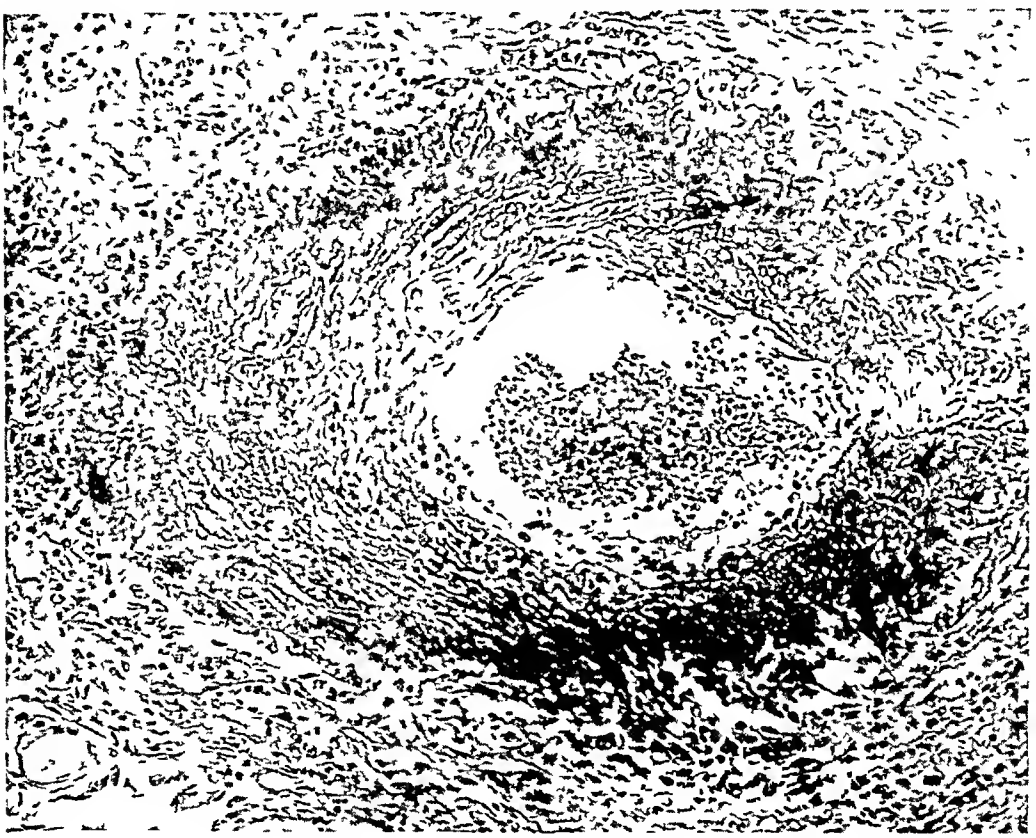

Fig 5—Arcuate artery of kidney showing degenerative and proliferative process in wall

Some of the arteries showed changes similar to those noted in other organs Here again the necrotic media, proliferation of the intima, infiltration of the vessel with polymorphonuclear leukocytes and thrombus in the vessel lumen were the prominent features

The bladder was normal both grossly and microscopically In the submucosa of the ileum under the endothelium of the vessels, irregular outlines of staining material which gave the staining reaction of fibrin were found Around the material was a collection of leukocytes in which polymorphonuclears and lymphocytes played the most prominent part There was here a marked proliferation of the intima with new fibroblasts The lumen of the small capillaries was narrowed, and their walls were thickened by hyaline material

In the gross, both suprarenal glands appeared normal Microscopically, the vessels were congested, and there was a slight thickening of the intima, although no acute degeneration was present

COMMENT

The correlation of the pathologic features with the clinical history of this case presents many points of interest The essential lesion was a widespread periarteritis nodosa, with which the following clinical conditions were apparently connected (1) jaundice, (2) hypertension and (3) changes in the peripheral nerves

The widespread changes in the blood vessels of the liver and the gallbladder were presumably directly or indirectly responsible for the jaundice There is justification for attributing the marked terminal hypertension to the changes in branches to the renal arteries, especially in the afferent glomerular vessels These resembled closely the lesions described by Fahr[2] as a type of malignant hypertension If the chief vascular lesions had been limited to the kidney, the picture would have corresponded to a moderately developed malignant hypertension in the sense of Fahr Fahr suggested that periarteritis nodosa may be a cause of malignant hypertension The clinical symptoms indicated disease of the peripheral nerves, a condition that has been associated with periarteritis nodosa in other cases In our patient, because of the restriction imposed on the completion of the autopsy, it was not possible to study the peripheral nerves Some doubt also exists concerning the relation of the vascular lesions to the gastric ulcer A vessel at the base of the ulcer showed the typical vascular lesion found elsewhere The clinical history indicated that the patient had suffered from gastric ulcer many years before, whereas the vascular lesions were certainly of more recent origin

Of interest, also, is the relation of the periarteritic lesion to other pathologic changes in some of the organs In the liver, pancreas and kidney, the focal increase and proliferation of connective tissue and the accumulation of lymphocytes, polymorphonuclear leukocytes, large monocytes and occasional plasma cells around vessels were apparently connected with the arterial lesions The cirrhotic changes in the liver may have represented an extension of this process In the heart, on the other hand, one found only a slight increase in connective tissue around the blood vessels, as might be expected from the absence of noticeable changes in the walls of the coronary vessels In the spleen, there was an increase of connective tissue and later hyaline changes about the blood vessels The enlargement of the prostate was independent of vascular changes

2 Fahr, T, in Henke and Lubarsch Handbuch der speziellen pathologischen Anatomie und Histologie Berlin Julius Springer, 1926, vol 6

In considering the character of the vascular lesions, one may distinguish between those found in vessels of medium size with a diameter of from 3 to 5 mm and those in the smaller vessels In the former necrosis of the media was combined with infiltration by a hyaline material which behaved like fibrin and was associated with proliferation of the intima and in many cases with remarkable proliferation of the periarterial tissue Here there was in places such a large accumulation of plasma cells and of large mononuclear cells as to suggest the term granulomatosis periarteritica In the intima, the lining endothelium was often lost The hyaline material reached into the lumen of the vessels and in places was taken up by phagocytes In some areas showing injury to the endothelium and to the intima in general, thrombi developed and extended into the larger vessels In later stages, when thrombi had become organized, their presence was indicated only by marked thickening of the intima Connective tissue may also have partly or wholly organized the hyaline material with the media

In the pancreas and the prostate, one noted hemorrhagic infiltration in the walls of certain blood vessels This seems to have been due to an injury to the walls Possibly similar were the lesions in the capsular space of the kidneys, where hemorrhage had occurred from the capillaries of the glomeruli in which afferent vessels had been occluded In the smaller vessels, one found merely intimal proliferation or desquamation of vacuolated endothelial cells In the afferent vessels of the glomeruli of the kidney frequent plaques of fibrin were seen The glomerular capillaries were often occluded by endothelial cells In the spleen, the smaller vessels showed only hyaline change, which seemed to have no relation to the general process It is difficult to decide whether the difference between the smaller and the larger vessels is due to the fact that the former were less affected by the agent responsible for the disease, or whether it can be explained by a difference in structure of the two types of vessels In different locations however, the size of affected vessels varied considerably The larger vessels the aorta for example, showed only the usual changes of arteriosclerosis, and these changes were especially marked in the abdominal portion near the origin of the larger branches They apparently bore no relation to the specific lesion of periarteritis nodosa

The organic distribution of the lesions is of great interest It is quite apparent that abdominal organs were mainly affected The lungs were free from the disease, and the heart showed only a small amount of lymphocytic infiltration about some of the coronary vessels In the organs of the abdomen, with the exception of the liver and the gallbladder, the arteries and arterioles were alone primarily involved In

the gallbladder, the arteries and the veins showed extensive lesions, and the cystic vein was completely thrombosed The thrombosis of the cystic veins is significant in connection with the location of the hepatic lesion in the dome of the right lobe The cystic vein drains into the right branch of the portal vein, which is distributed to the right lobe of the liver The localization in the dome of the organ may have been due to the "stream line" effect of the portal blood, as has been pointed out by Copher and Dick [3] From the pathologic point of view, the oldest and most extensive lesions were found in the gallbladder, and it is suggested that the process started there and that the agent was borne by the blood to the other organs The fact that the lungs were uninvolved might be explained on the basis of a patent foramen ovale Perhaps the agent, at first generally distributed in the form of a toxin, manifested itself as a peripheral neuritis, and later became localized in the biliary tract

SUMMARY

A detailed examination of a case of periarteritis nodosa revealed the usual pathologic changes described in the literature The lesions were most prominent in vessels of the abdominal organs, an observation which has been reported in a number of other cases [4]

In addition, the oldest and most extensive lesions were found in the gallbladder, where both arteries and veins were affected The portal veins in the dome of the right lobe of the liver were extensively involved That area in the liver represents the area of drainage from the gallbladder It is suggested that perhaps the primary lesion was in the gallbladder and that the agent was borne by the blood to the other tissues of the body

3 Copher, G H, and Dick, B M "Stream Line" Phenomena in Portal Vein and Selective Distribution of Portal Blood in Liver, Arch Surg **17** 408 (Sept) 1928

4 Weilder, V Ztschr f Path **25** 305, 1923

INFARCTS OF THE LIVER AND THE MECHANISM OF THEIR PRODUCTION

REPORT OF A CASE *

H M ZIMMERMAN, M D
NEW HAVEN, CONN

Infarcts of the liver, if the term is used in the restricted sense in which it is customarily used for other organs of the body, namely, to signify necrosis of a part resultant from the shutting off of the blood supply to that part, are of infrequent occurrence This fact has led observers from time to time to include conditions affecting the liver other than infarcts but superficially resembling them, so that at present a wide variety of dissimilar anatomic pictures are described in the literature under the all-inclusive term of infarcts of the liver These pseudo-infarcts will be enumerated and discussed briefly There are, of course, reports of cases of true infarct of the liver in the literature, and those that were accessible have been summarized and tabulated chronologically

Only in recent years has attention been called to the combination of factors that must be operative in order that true infarcts of the liver may result Nowhere, however, are these factors brought together in one place and evaluated A lack of appreciation of all the factors involved led the early workers in the experimental production of this type of lesion to erroneous conclusions, and it accounts also for the confusion that exists in the literature on the subject Brief mention will be made of some of the results in the experimental production of this type of damage of the liver, and with these results as a background, the mechanism of infarction of the liver will be outlined Finally, a case of infarct of the liver occurring in a child aged 31 hours will be reported in some detail

OBSERVATIONS RECORDED IN THE LITERATURE

Effects of Occlusion of the Portal Vein—That occlusion of large branches of the portal vein, and even occlusion of the main stem of this vessel, will not produce infarcts in the liver is adequately proved by the numerous case reports of this condition as well as by the experimental

* Submitted for publication, Jan 10, 1930

* From the Department of Pathology, Yale University School of Medicine

evidence Borrmann,[1] Botkin,[2] Heller,[3] Paulicki,[4] Pick,[5] Rolleston,[6] Saxer,[7] Versé[8] and Wagner[9] all cited examples of thrombosis of the portal vein without resultant infarcts or necrosis of the liver, nearly all, however, called attention to the decreased size of the liver in this condition about which more will be said There are many more examples in the literature of occlusion of the portal vein in which no other effect than the diminution in the size of the liver is mentioned The statement is now generally accepted that in a gradual exclusion of the venous supply to the liver the hepatic artery is capable of assuming the required venous function This was believed by Cohnheim and Litten[10] and also by Woolridge,[11] and has since often been quoted as a fact Experimental occlusion of this vein, even when more or less instantaneous, by Rous and Larimore,[12] by Lewis and Rosenow,[13] and even by Cohnheim and Litten, failed to produce infarcts In the report of a case of obliteration of the portal vein, Osler[14] stated the reason for the failure of infarction to take place as follows After complete exclusion of portal blood from the organ, the lobular capillary plexus continues filled, as the venules which collect the blood from the

1 Borrmann Beitrage zur Thrombose des Pfortaderstammes, Deutsches Arch f klin Med **59** 283, 1897

2 Botkin Krankheitsgeschichte eines Falles einer Pfortaderthrombose, Virchows Arch f path Anat **30** 449, 1864

3 Heller, A Ueber traumatische Pfortaderthrombose, Verhandl d deutsch path Gesellsch **7** 182, 1904

4 Paulicki Thrombose des Pfortaderstammes, bedingt durch in die Pfortaderverzweigungen hineinwuchernde Krebsmassen, Berl klin Wchnschr **4** 505, 1867

5 Pick, L Ueber totale hamangiomatose Obliteration des Pfortaderstammes und uber hepatopetale Kollateralbahnen, Virchows Arch f path Anat **197** 490, 1909

6 Rolleston, H D Liver in Hepatic and Portal Thrombosis, Tr Path Soc London **50** 148, 1898-1899

7 Saxer, F Beitrage zur Pathologie des Pfortaderkreislaufs, Centralbl f allg Path u path Anat **13** 577, 1902

8 Verse, M Ueber die cavernose Umwandlung des periportalen Gewebes bei alter Pfortaderthrombose, Beitr z path Anat u z allg Path **48** 526, 1910

9 Wagner, E Beitrage zur Pathologie und pathologischen Anatomie der Leber, Deutsches Arch f klin Med **34** 520, 1884

10 Cohnheim, J, and Litten, M Ueber Circulations-Storungen in der Leber, Virchows Arch f path Anat **67** 153, 1876

11 Woolridge, L C On Hemorrhagic Infarction of the Liver, Tr Path Soc London **39** 421, 1888

12 Rous, P, and Larimore, L D Relation of the Portal Blood to Liver Maintenance, J Exper Med **31** 609, 1920

13 Lewis, D D, and Rosenow, E C Primary Portal Thrombosis, Arch Int Med **3** 232 (April) 1909

14 Osler, W Case of Obliteration of the Portal Vein, J Anat & Physiol **16** 208, 1882

capillaries of the hepatic artery empty directly into the portal interlobular vessels, and the blood supply is in this way maintained

Occlusion of the Interlobular Venules—From the observations mentioned it is apparent that any block to the interlobular portal vessels will result in a focal area of infarction As early as 1869, Klebs [15] attributed infarcts in the liver to this cause On this basis did Schmorl [16] account for the liver changes in puerperal eclampsia In mentioning Schmorl's observations Chiari [17] called attention to the occurrence of similar focal zones of necrosis in the liver in man following occlusion by emboli of interlobular branches of the portal vein Mallory [18] considered the focal zones of necrosis occasionally seen in the livers of guinea-pigs as miliary infarctions due, in one class of cases, to cell emboli brought from the spleen to the liver by the portal vein and lodged in the minute branches of the portal vein Osler [19] attributed hemorrhagic infarcts in the liver in a case he reported in 1887 to thrombi in the interlobular venules, associated with obliteration of branches of the hepatic artery by an increase in the interlobular connective tissue Similarly, Steinhaus [20] reported a case of infarction of the liver due to complete occlusion of the interlobular branches of the portal vein by fibrosis following an endophlebitis, and Winternitz [21] mentioned softened hemorrhagic infarcts in the liver resulting from "thrombosis of minute portal vessels"

Occlusion of the Hepatic Artery—The matter of changes in the liver produced by interference with the arterial supply is in a much more confused state The experiments of Cohnheim and Litten [10] on the ligation of the hepatic artery in rabbits at a point beyond the origin of the right gastric artery showed that infarcts of the liver were an invariable result These experiments were repeated by Janson [22] on rabbits with like results, but when performed on dogs no liver changes

15 Klebs, E Handb d path Anat **1** 454, 1869

16 Schmorl Pathologisch-anatomische Untersuchungen uber Puerperaleklampsie, Leipzig, 1893

17 Chiari Erfahrungen uber Leberinfarcte, Centralbl f allg Path **9** 839, 1898

18 Mallory, F B Necroses of the Liver, J M Research **6** 264, 1901

19 Osler, W Notes on Hemorrhagic Infarction, Tr A Am Phys **2** 133, 1887

20 Steinhaus, F Ein seltener Fall von Pfortaderthrombose mit hamorrhagischer Infarzierung und Nekrotisierung der Leber, Deutsches Arch f klin Med **80** 364, 1904

21 Winternitz, M C The Effect of Occlusion of Various Hepatic Vessels upon the Liver, Bull Johns Hopkins Hosp **22** 395, 1911

22 Janson, C Ueber Leberveranderungen nach Unterbindung der Arteria hepatica, Beitr z path Anat u z allg Path **17** 505, 1895

were observed His results in rabbits were confirmed by Behrend,[23] and Whipple and Sperry[24] in their experiments on chloroform poisoning confirmed his observations in dogs De Dominicis[25] in 1891, four years before the report of Janson's work, obtained the same results in dogs Behrend, Radasch and Kershner[26] summarized the effects of ligation of the hepatic artery on the livers of different animals in this manner Rabbits and guinea-pigs always succumb to successful peripheral ligation Dogs and cats resist the ligation and continue to live indefinitely in spite of a combination of a peripheral and central ligation

A rather fanciful explanation for the failure to produce infarcts in dogs was supplied by Stolnikow,[27] who failed to find damage of the liver following the simultaneous ligation of the portal vein and the hepatic artery and attributed that result to an adequate blood supply to the liver by way of a reverse current in the hepatic veins In this connection, it is interesting to note the work of Chandler,[28] who ligated temporarily the hepatic artery and the portal vein in Eck fistula dogs for periods as long as twelve hours and failed to find necrosis of the hepatic parenchyma He attributed his results purely to the power of the hepatic cells to resist local anemia

De Dominicis believed that ligation of the hepatic artery in dogs failed to produce hepatic infarcts because the blood supply by way of the portal vein was adequate for nutrition The belief in the adequacy of either part of the double hepatic circulation for liver maintenance is widespread, and the double circulation is the often quoted reason for the infrequent occurrence of infarcts of the liver That another explanation is more probably the correct one for this observation is obvious from what follows

Doyon and Dufourt[29] were the first to maintain that the reason infarct did not occur in the liver in dogs following ligation of the hepatic artery was because the liver received an adequate arterial blood supply

23 Behrend, M Experimental Ligation of Hepatic Artery, Surg Gynec Obst **31** 182, 1920

24 Whipple, G H, and Sperry, J A Chloroform Poisoning Liver Necrosis and Repair, Bull Johns Hopkins Hosp **20** 278, 1909

25 De Dominicis, N Observations experimentales sur la ligature de l'arterie hepatique, Arch ital de biol **16** 28, 1891

26 Behrend, M, Radasch, H E, and Kershner, A G Comparative Results of the Ligation of the Hepatic Artery in Animals, Arch Surg **4** 661 (May) 1922

27 Stolnikow Die Stelle vv hepaticarum im Leber- und gesammter Kreislaufe, Arch f d ges Physiol **28** 255, 1882

28 Chandler, L R Resistance of Hepatic Tissues to Local Anemia, Proc Soc Exper Biol & Med **18** 23, 1920-1921

29 Doyon and Dufourt Contribution a l'étude de la fonction ureopoietique du foie, Arch de physiol norm et path **10** 522, 1898

from the other branches of the celiac axis In 1905, Haberer [30] explained more fully such observations by pointing out that ligation of the main stem of the hepatic artery central to the origin of the right gastric artery produces no effect on the liver because of the collateral circulation through this right gastric Ligation of the hepatic artery peripheral to the right gastric also fails to produce hepatic infarcts because the gastroduodenal artery immediately establishes a collateral circulation Ligation of the hepatic artery just before it divides into the right and left branches produces infarcts, he stated, in many dogs and cats In the animals in which this procedure is without effect, the explanation can be found in the fact that in these animals each lobe of the liver receives an artery, any one of which may arise from the main stem of the hepatic artery and may thus escape being caught in the ligature Segall [31] correctly attributed failure of infarcts to take place following ligation of the hepatic artery to an anastomosis between the branches of the hepatic artery and the phrenic vessels, which forms a communication between the thoracic and the abdominal circulations He was led to conclude that "infarcts of the liver follow obliteration of those arteries which terminate in the liver without sending any branches to the subcapsular system of anastomoses, and which are therefore proper end-arteries" Other vessels cited by von Hofmeister [32] as being capable of establishing an arterial collateral circulation to the liver are those present in adhesions between the hepatic capsule and adjacent abdominal organs, and also an artery in the ligamentum teres To this list may be added anomalous arteries to different lobes of the liver In all essential details, the hepatic arterial circulations of dogs and man are identical (fig 1)

Examples of Occlusion of the Hepatic Artery in Man without Resultant Infarcts of the Liver —In 1903, Kehr [33] reported the first case of a successful ligation of the arteria hepatica propria in a patient who had an aneurysm of the right branch of the hepatic artery that had perforated into the gallbladder This patient survived and showed no evidence of damage of the liver In 1920, Smith [34] reported a deliberate

30 Haberer, H Experimentelle Unterbindung der Leberarterie, Arch f klin Chir **78** 557, 1905

31 Segall, H N An Experimental Anatomical Investigation of the Blood and Bile Channels of the Liver, Surg Gynec Obst **37** 152, 1923

32 Von Hofmeister, F Unterbindung der Arteria hepatica propria ohne Leberschadigung, Zentral f Chir **49** 154, 1922

33 Kehr, H Der erste Fall von erfolgreicher Unterbindung der Arteria hepatica propria wegen Aneurysma, Munchen med Wchnschr **50** 1861, 1903

34 Smith, R E Ligature of the Hepatic Artery, Brit J Surg **8** 532, 1920-1921

ligation of the hepatic artery with no ill effects in a person in whom this vessel was injured in the course of a gallbladder operation Von Hofmeister [32] reported a similar successful ligation of the hepatic artery distal to the origin of the right gastric artery in a case in which the gastroduodenal artery was also ligated in the course of an extensive gastric resection In detailing the finding of a thrombosed aneurysm of the hepatic artery at autopsy, Tuffier [35] stressed the slowness of the occlusion as the factor responsible for the lack of damage to the liver Merkel [36]

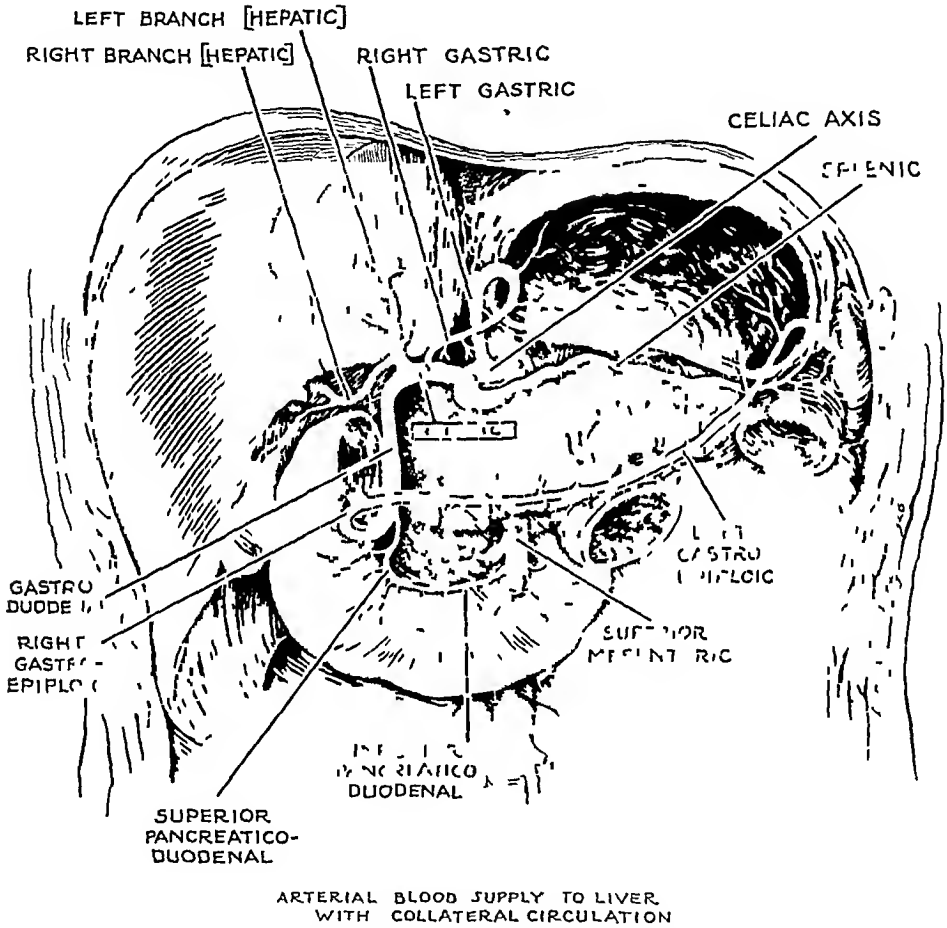

Fig 1—A drawing showing the arterial blood supply of the liver with the collateral circulation

described a thrombosed aneurysm of the arteria hepatica propria central to the origin of the right gastric artery found accidentally at autopsy in a man 56 years of age who died of postoperative peritonitis He attributed the lack of changes in the liver in this case to an adequate collateral circulation through the right gastric and the gastroduodenal

35 Tuffier, T Aneurisme de l'artère hepatique, Presse med **17** 153, 1909

36 Merkel, H Zur Kenntnis der Aneurysmen im Bereich der Arteria hepatica, Virchows Arch f path Anat **214** 289 1913

arteries, and he also stated as his belief that this collateral circulation was aided by the slow formation of the thrombus in the aneurysm

Examples of Pseudo-Infarcts—In 1895, Pitt[37] reported an infarct of the liver in a man, aged 36, who died following an injury to his abdominal wall "A branch of the portal vein to the right lobe of the liver was found to contain a recent thrombus and an infarction had resulted" Four years later, Lazarus-Barlow[38] reported a similar case in a man 25 years of age who was crushed between bufferis while pursuing his occupation of railway shunter In the center of a pale yellow mass of tissue 2 inches (5 cm) in length and nearly 1½ inches (3 7 cm) in greatest width were "certain branches of the portal vein obstructed by thrombus It is an indubitable anemic infarct" Heile[39] and Orth[40] both described "traumatische anamisch-necrotische Infarkte" of the liver and attributed their production to tears in branches of both the portal vein and the hepatic artery Numerous other examples of infarcts of the liver following trauma are described which will not be enumerated here It is without question, however, an erroneous concept to attribute these infarcts to occlusion of branches of the portal vein The possibility always exists that the necrosis of the liver cells is the direct result of trauma and that the thrombi in the portal radicles are the result of, or are simultaneous with, this necrosis and not its cause

Mention has already been made of the atrophy that results in the liver following occlusion of the portal vein In discussing this atrophy in 1898, Zahn[41] called attention to the similarity in the gross appearance between this condition of the liver and the condition of "red infarcts" in the lung He stated precisely that in the liver it is atrophy and not true necrosis, and he termed it "atrophic red infarcts of the liver" (atrophische rote Leberinfarkte) only because it resembled the condition of true infarcts of the lung That same year, Chiari[42] reported seventeen cases of "genauer untersuchte Falle von atrophischen

37 Pitt, G N Cases of Portal Thrombosis with and without Infarction of the Liver, Tr Path Soc London **46** 74, 1895

38 Lazarus-Barlow, W S A Case of Anemic Infarct in the Liver, Brit M J **2** 1342, 1899

39 Heile Ueber einen traumatischen, anamisch-nekrotischen Leberinfarkt mit ausgedehnten Regenerationserscheinungen, Beitr z path Anat u z allg Path **28** 443, 1900

40 Orth, J Ueber traumatische anamisch-necrotische Infarcte der Leber, Verhandl d deutsch path Gesellsch **3-4** 82, 1900-1901

41 Zahn, F W Ueber die Folgen des Verschlusses der Lungenarterien und Pfortaderaste durch Embolie, Verhandl Gesellsch deutsch Naturforsch u Arzte **2** 9, 1898

42 Chiari Erfahrungen uber Infarctbildungen in der Leber des Menschen, Verhandl d deutsch path Gesellsch **1-2** 13, 1898-1899

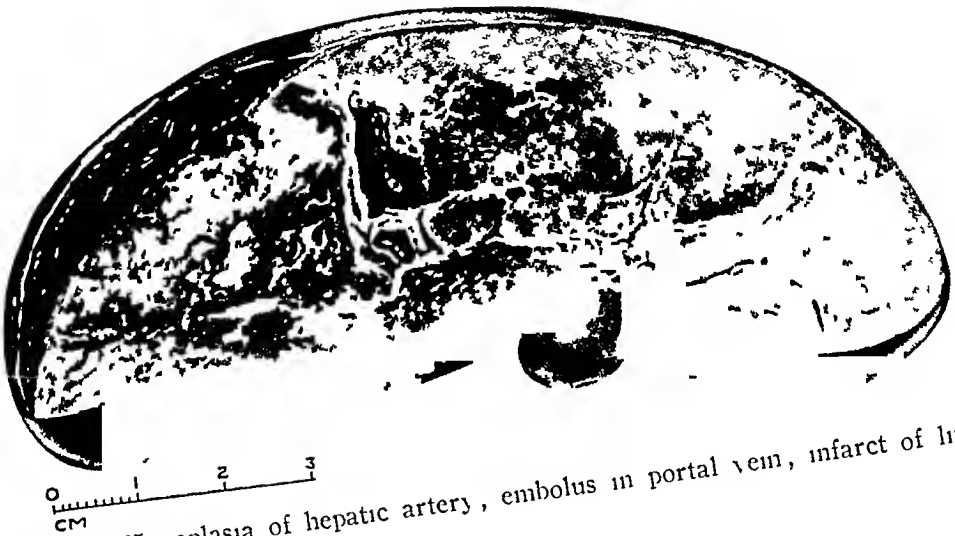

Fig 2—Hypoplasia of hepatic artery, embolus in portal vein, infarct of liver

roten Infarkten," and somehow the impression was further extended by other reports of similar cases bearing the misleading term of atrophic red infarcts

Occlusion of the Hepatic Veins—Longcope,[43] Sternberg[44] and Versé[45] reported cases of thrombosis of the hepatic veins with necrosis of adjacent liver tissue as examples of infarcts of the liver That necrosis of the liver is associated with thrombosis of the hepatic vein is proved without question by the case reports of these and of numerous other writers, but if we conform to our definition that an infarct is necrosis produced by an interference with the blood supply to a part, then these examples of interference with the blood supply from the liver fall outside the realm of our discussion

In the accompanying table are listed in chronologic order all the available reports of cases of true infarct of the liver in the literature

REPORT OF CASE

History—The patient was the product of the fifteenth pregnancy, which was complicated by a dry labor lasting four days and resulting in a breech delivery Premature rupture of the membranes occurred in the morning of Dec 24, 1927, and the pains which set in shortly afterward were not severe until the evening of December 27 At this time, a physician was called for the first time He found the fetus in the right sacro-anterior position, the anterior foot presenting and protruding through the cervix An unsuccessful attempt was made to dilate the cervix with a Voorhees' bag, and so manual dilatation of the cervix was performed, at 9 a m the following day Meconium was being passed at the time of the pains The child was delivered with forceps on the after-coming head, because pressure could not be applied through the mother's abdomen, which was unyieldingly rigid Following delivery, the baby failed to make any attempt at respiration, hence tubbing and mild stimulation were resorted to, the child breathing normally after an hour and a quarter of this treatment

On examination, the infant was found to be entirely inert Spanking produced arching of the back and turning of the head to the right, with movement of the right arm In the course of the day, the infant became cyanotic and the respirations feeble During the night it had several convulsions, during which the head was retracted and the arms and legs became rigid Spinal fluid showed definite xanthochromia There was a marked positive Chvostek sign, with left facial weakness The abdomen was full, and the abdominal reflexes could not be obtained All the other reflexes were hyperactive The upper as well as the lower extremities were spastic When the baby was touched, convulsive twitchings were induced The Kernig sign was strongly positive, as was also the Babinski sign on both sides Tapping the tendons of the knee induced spastic flexion of the legs and tension of the muscles to such a degree that the knee

43 Longcope, W T Hepatic Infarctions, Pennsylvania Univ Med Bull **14** 223, 1901-1902

44 Sternberg, C Ueber obliteration der Vena cava inferior und Thrombose der Venae hepaticae Verhandl d deutsch path Gesellsch **10** 131, 1906

45 Verse, M Ueber totale Pfortaderobliteration und anamische Infarkte der Leber, Verhandl d deutsch path Gesellsch **13** 314, 1909

Chronologic List of Reports of True Infarct of the Liver

Case	Year	Reported by	Condition in Liver	Mechanism of Infarction	Remarks
1	1877	Ross, G, and Osler, W Aneurysm of Hepatic Artery, Canada J Med & Surg 6 1, 1877	"Numerous areas of necrosis which subsequently became, by inflammation and a sequestrating suppuration converted into abscesses"	Laminated thrombus in aneurysm at bifurcation of hepatic artery, but occupying chiefly the right branch	
2	1887	Osler [19]	Hemorrhagic infarction	'Interlobular connective tissue growth obliterated a majority of the hepatic artery branches in the affected region and had thus converted certain trunks of the venae portae into terminal vessels which, when plugged with solid thrombi, induced a condition of infarction in the area supplied by them"	
3	1891	Kohler, B Ueber die Veranderungen der Leber infolge des Verschlusses von Pfortaderasten, Inaug - Diss, Gottingen, 1891	Zone of necrosis and multiple abscesses	Ulcerative endocarditis and embolus in branch of hepatic artery	Multiple abscesses in spleen and kidneys also, question of whether the infection or the thrombus was first in liver
4	1895	Ogle, C Infarcts in the Liver Tr Path Soc London 46 73, 1895	Infarcts from pea to hazel nut size	The hepatic artery is blocked at its bifurcation by adherent brick colored clot"	Infarcts also in spleen and kidneys
5	1898	Chiari Erfahrungen uber Infarctbildungen in der Leber des Menschen, Ztschr f Heilk 19 475, 1898	Multiple anemic infarcts	Ligature thrombus in gastric veins following pyloric resection, with emboli in interlobular branches of portal vein	
6	1898	Chiari (See reference for case 5)	Multiple anemic infarcts	Thrombi in veins of large intestine in a case of dysenteria follicularis, with emboli in interlobular branches of portal vein	
7	1898	Chiari (See reference for case 5)	Complete necrosis	Mitral endocarditis, embolus in arteria hepatica propria beyond the origin of the right gastric artery	
8	1898	Chiari (See reference for case 5)	Multiple hemorrhagic and necrotic infarcts	Endocarditis with emboli in smaller branches of hepatic artery	
9	1899	Castaigne, J Infarctus hemorrhagique tres etendu du foie, Bull Soc anat d Paris 1 150, 1899	Hemorrhagic infarct	Apical cardiac aneurysm, cardiac thrombus, multiple emboli	Emboli also to spleen, kidneys and lungs
10	1902	Baldwin, F A Multiple Anemic Infarcts of the Liver, J M Research 8 431, 1902	Multiple anemic infarcts	Aortic stenosis, cardiac dilatation thrombus in right auricle	Infarcts also in brain, lungs, spleen, kidneys, stomach and duodenum
11	1904	Steinhaus [20]	Extensive necrosis and true hemorrhagic infarcts	Complete occlusion of interlobular branches of portal vein by fibrosis following endophlebitis	
12	1905	Ruczynski B Zur kenntnis der arteriellen Infarctbildungen in der Leber des Menschen Ztschr f Heilk 26 147, 1905	Multiple zones of necrosis	Emboli and thrombi in hepatic artery	The corresponding portal vein branches and hepatic veins were thrombosed 'secondarily to the embolism of the hepatic artery"
13	1909	Verse [45]	Widespread early ischemic infarct	Ligation of common hepatic artery and resection of left branch in course of operation for gastric carcinoma	

Chronologic List of Reports of True Infarct of the Liver—Continued

Case	Year	Reported by	Condition in Liver	Mechanism of Infarction	Remarks
14	1911	Winternitz [21]	Softened hemorrhagic infarcts	Thrombosis of minute portal vessels	Primary carcinoma of stomach, with secondary invasion of liver
15	1916	Narath, A Ueber Entstehung der anamischen Leber nekrose nach Unterbindung der Arteria hepatica und ihre Verhutung durch arterio-portale Anastomose, Deutsche Ztschr f Chir **135** 305, 1916	Multiple abscesses and dry yellow necrosis	Ligature on hepatic artery between right gastric and gastroduodenal artery	Death in twenty days
16	1916	Narath (See reference for case 15)	Necrosis of right lobe	Aneurysm of right branch of hepatic artery with ligation	Patient recovered, recovery attributed to the fact that the formation of the aneurysm provided sufficient time for establishment of collateral circulation
17	1916	Narath (See reference for case 15)	Large necrotic shreds of liver with rupture through abdominal incision of an old necrotic zone of softening of the liver	Ligation of hepatic artery in course of a cholecystectomy	Patient recovered, possibly because of adequate collateral circulation from the numerous adhesions between superior surface of liver and anterior abdominal wall
18	1916	Narath (See reference for case 15)	Complete necrosis	Ligation of hepatic artery in course of operation for gastric carcinoma	
19	1916	Narath (See reference for case 15)	Complete necrosis of left lobe	Ligation of left branch of hepatic artery in course of operation for gastric ulcer	Death in seven days
20	1916	Narath (See reference for case 15)	Widespread necrosis of left lobe	Ligation of left branch of hepatic artery in course of operation for gastric carcinoma	Death in seventeen days
21	1916	Narath (See reference for case 15)	"Signs of liver necrosis" in right lobe	Ligation of right branch of hepatic artery in cholecystectomy	Patient recovered after "months" of illness
22	1916	Narath (See reference for case 15)	Complete necrosis of left lobe	Ligation of left branch of hepatic artery in course of operation for hydatid cyst in lobus quadratus	Death in four days
23	1916	Narath* (See reference for case 15)	Complete necrosis of right lobe	Ligation of right branch of hepatic artery in course of removal of a "tumor" in right lobe of liver	Death in seventy-two hours
24	1924	Mittasch, G Beitrage zur pathologie der Leber, Virchows Arch f path Anat **251** 638, 1924	Multiple red infarcts	Organization of emboli and obliterating endarteritis in hepatic arteries	Infarcts also in kidneys, passive congestion of liver
25	1925	Cain, A, and Baltanski Necrose hemorrhagique du foie, Bull et mem Soc med d hop de Paris **49** 1450, 1925	Hemorrhagic necrosis	Not stated	Occurred in the course of a tuberculous bronchopneumonia
26 and 27		Rattone and Mondino (quoted by Ruczynski)	Hemorrhagic infarcts in both cases	Simultaneous occlusion of portal vein (thrombosis) and hepatic artery (cirrhosis)	

* All nine cases cited by Narath were taken by him from the literature without mention of source. The 16th, 17th and 21st cases cited by him are questionable examples of true infarcts, since in each instance the patient recovered and the liver was not examined microscopically.

jerks could not be obtained Ankle clonus was moderately sustained on both sides There was a large extravasation of blood in the left fundus oculi The baby died thirty-one hours after she was born

Necropsy—The examination was performed sixteen hours post mortem The positive observations were limited to the heart, liver, left suprarenal gland and cranial contents, and these are described in order

In the heart a widely patent ductus arteriosus joined the pulmonary artery to the aorta, and this ductus had the same diameter as the aorta which it joined Numerous red, flame-shaped subepicardial hemorrhages were present on the anterior surface A large interauricular septal defect converted the two auricles into a single cavity A delicate velamentous strand of connective tissue at the inferior margin of the interauricular septal defect represented all that was present of the interauricular septum The foramen ovale was patent The muscular interventricular septum was intact The thickness of the right ventricular wall was equal to that of the left, but the right cavity was only about half the size of the left

The right lobe of the liver projected 3 cm below the costal margin in the midclavicular line, the left lobe was not visible below the costal margin Beneath the capsule of the left lobe on the diaphragmatic surface was a boggy mass of semisolid blood This subcapsular extravasation involved the whole superior surface of the left lobe and had a sharply defined margin Blood-tinged fluid exuded from the capsule overlying this hemorrhage and oozed into the peritoneal cavity The inferior vena cava, the umbilical vein, the mesenteric vessels, the portal vein and the hepatic artery were all free from blood clots The prominent umbilical vein entered the liver at the porta hepatis, and its connection with the ductus venosus and with the portal vein was readily traced Section of the liver (fig 2) revealed a left lobe which was completely infarcted and which had a soft yellow opaque center The periphery of this central necrotic zone was composed of a deep red margin of varying thickness and of irregular outline which shaded off on the right with the normal parenchyma of that lobe of the liver It was a portion of this hemorrhagic periphery that immediately underlay the subcapsular hemorrhage Examination of the blood vessels supplying the liver brought to view a number of interesting conditions The hepatic artery was markedly hypoplastic and had an unusually narrow lumen Where it bifurcated into the right and left branches, the lumen became of pinpoint size At the entrance of the portal vein into the liver was a firm, friable antemortem blood clot which completely blocked its lumen and extended farther into the umbilical vein and into the ductus venosus, shutting off their lumina also These three vessels were lined by pale intima, and none showed any gross evidence of infection

Microscopically, a large number of well preserved red blood cells were seen lying beneath that portion of the liver capsule which overlay the infarct The adjacent liver cells (fig 3) no longer formed definite columns Their cytoplasm was granular and vacuolated, the nuclei were fragmented and pyknotic, in many instances lying extruded outside their cells The spaces between these cells were wide and irregular and markedly engorged with blood In areas far removed from the liver capsule, the picture was somewhat different Here the lobular structure was more or less intact, but the liver cells were of irregular outline, pale and devoid of nuclei The liver sinusoids were widely dilated, and were empty in some places and filled with laked red blood cells in others In areas in which the lobules were sufficiently preserved to make a study of their structure possible, the central veins were found intact and unobstructed The branches of the hepatic arteries lying in the periportal spaces had greatly narrowed lumina,

and as a consequence their walls appeared thickened Leukocytic cellular infiltrations, composed in the main of polymorphonuclear leukocytes with unusually large numbers of eosinophils, were present in the periportal areas surrounding the ramifications of the portal vein The periportal or interlobular venules were free from thrombi or emboli

The left suprarenal gland weighed 10 Gm, which was three times the weight of the right suprarenal gland An extensive hemorrhage was present in both the cortex and the medulla Microscopic examination showed the cortical cells to be well preserved, though separated by hemorrhage In the medulla, many suprarenal cells were necrotic

Fig 3—Section of liver showing complete loss of the normal architecture as a result of necrosis, hematoxylin and eosin, × 85

A hematoma of the scalp was present over the right frontal and parietal bones The occipitoparietal suture on the right side was widened for about 3 cm, and on the left side the parietal bone overrode the occipital bone for about the same distance The fontanels were neither depressed nor bulging A small hemorrhage was present in the trapezius muscle on the left side The brain and the attached spinal cord were removed inside their intact dura There was an extensive ragged tear of the right leaf of the tentorium cerebelli, starting posteriorly in front of the transverse venous sinus several centimeters to the right of the junction of the falx cerebri and tentorium and continuing anteriorly and medially to the junction of the vein of Galen and the straight sinus An extensive subtentorial hemorrhage surrounded the pons and lay on the superior surfaces of both cerebellar lobes Hemorrhage was also present intradurally the entire length of the spinal cord

Summary of Observations at Necropsy—The anatomic diagnosis in this case may be written as follows tear of the tentorium, subtentorial hemorrhage, hemorrhage into the suprarenal gland (left), hypoplasia of the hepatic artery, thrombus in the portal vein, infarct of the liver

The cerebral accident, as well as the hemorrhage into the suprarenal gland, are frequent observations in difficult deliveries and do not concern us here Actual tears into the parenchyma of the liver during breech deliveries have also been described,[46] but there was no tear demonstrable in the liver of this patient With an enfeebled arterial circulation due to the hypoplastic hepatic artery, and a complete absence of venous blood because of the thrombus in the portal vein, the infarct of the left lobe of the liver seems to be explained That the right lobe did not suffer similarly is difficult to explain other than by the possibility that the phrenic arterial-subcapsular anastomoses may have been adequate No explanation for the thrombus in the portal vein is available

SUMMARY

Traumatic injuries to the liver resulting in necrosis, even when associated with thrombosis of large branches of the portal vein, are not examples of true infarcts of the liver

Occlusion of the portal vein in the presence of an adequate arterial blood supply does not produce infarcts of the liver, but may produce an atrophy which is often misnamed "atrophic red infarct"

Occlusion of the branches of the interlobar portal vein produces infarcts of the liver

Necrosis of liver cells due to occlusion of the hepatic veins is not an example of infarct of the liver in that the interference in these cases with the blood supply to the liver is only an indirect one

Complete block of the arterial blood supply to the liver always leads to infarction, even in the presence of the full venous circulation by way of the portal vein When infarction fails to take place, it is due to an efficient collateral arterial circulation by way of (*a*) the right gastric or gastroduodenal arteries, (*b*) the artery in the ligamentum teres, (*c*) the phrenic anastomoses, (*d*) the arteries in adhesions between abdominal viscera and the liver capsule or (*e*) anomalous arteries to the liver

Twenty-seven cases of infarct of the liver collected from the literature are listed in chronologic order Of these, three cases quoted by Narath are based only on clinical observation, in each instance the patient having made an eventual recovery

Finally, an original example of infarct of the liver is reported

---

46 Green, H Hemorrhage of the Liver as a Cause of Death in the New-Born, Arch Pediat **43** 627, 1926

General Review

THE MICROBIC ETIOLOGY OF RHEUMATIC FEVER AND ARTHRITIS *

EDWIN P JORDAN, M D
CHICAGO

In grouping together rheumatic fever and arthritis in any study, serious difficulties are sure to arise Moreover, clinical and etiologic evidence to the present have failed to develop any hard and fast line of demarcation between these conditions It is not proposed to discuss the clinical features more than to refer to the difficulty involved in differentiation of some of the borderline cases, which all will readily admit This clinical confusion has to some degree been carried over into the etiologic investigations, and it is now an almost impossible task to separate entirely the bacteriologic studies of rheumatic fever and of arthritis

Many theories of causation have been proposed, and for rheumatic fever and some forms of arthritis especially, most have involved, in the last analysis, a conception of infection with pathogenic micro-organisms, though other factors, such as trauma in arthritis, are generally recognized Cause and effect are frequently difficult to differentiate, and noninfectious etiologic possibilities cannot as yet be eliminated, but at least in regard to rheumatic fever, the known clinical and epidemiologic facts point to this condition as an infectious disease

The space available for this paper prohibits any claim to exhaustive consideration of all the literature in this complicated field Indeed, such consideration is felt to be unnecessary because of the reviews of the early work by Poynton and Paine, Loeb, Bulloch and others, and inclusion of the more recent work in such monographs as those of the Pickett-Thomson Research Laboratory [1]

Undoubtedly the most impressive bacteriologic evidence, though not perhaps the earliest, relates to the presence of streptococci in rheumatic fever These observations, naturally, center around the isolation of micro-organisms from the tissues of patients Triboulet and Coyon (*b*) and Apert isolated pleomorphic diplococci from the blood of several

* Submitted for publication, Jan 29, 1930

* From the John McCormick Institute for Infectious Diseases (Frank Billings Arthritis Fund)

1 See Thomson and Thomson in the bibliography appended

living patients with acute rheumatism and endocarditis and several bodies post mortem Westphal, Wassermann and Malkoff isolated from the blood post mortem a streptococcus that produced a nonsuppurative multiple polyarthritis in rabbits, but did not state that they considered this organism the cause of rheumatic fever Soon afterward, the researches of Poynton and Paine, Beattie, Beaton and Walker, Coombs (*a*), Walker and Ryffel in England and others resulted in numerous isolations of a micrococcus from various cultures from tissues of patients with rheumatic fever Tonsils, pericardial fluid, heart valves, cerebrospinal fluid, appendix and blood both ante and post mortem yielded micrococci, the microscopic and cultural characteristics of which were variously described In spite of the fact that many of these isolations were from postmortem material and from relatively few living patients, the micro-organism was for the most part in each instance considered specific and believed to be the cause of rheumatic fever A healthy note of scepticism was, however, sounded by Lewis and Longcope, by Philipp and by Cole The former said

> In view of the fact that streptococci isolated from sources other than the blood or complicating lesions from cases of rheumatic fever do, under certain circumstances, produce arthritis and endocarditis in animals when injected intravenously, it is surprising that the English observers, particularly, have made so few experiments to control their work

But they concluded that a streptococcus which they isolated from a fatal case of rheumatism, endocarditis and chorea "is the same as that described by Wassermann, Meyer, Poynton and Paine, and Walker" Philipp failed to find organisms in any of his 21 blood or 6 synovial fluid cultures from rheumatic fever patients This was apparently an extremely thorough piece of work Cole stated as purely negative evidence, that all his attempts to grow organisms from the blood and joints in acute rheumatic fever failed Although taken altogether these early cultural results were impressive, the high percentage of postmortem isolations, particularly in view of the more recent studies of postmortem bacteriology, makes the value of this type of evidence doubtful Epstein and Kugel found nonhemolytic streptococci in blood, bone-marrow, heart muscle or valve in 86 per cent of their routine postmortem examinations They concluded "that no significance can be attached to the recovery at necropsy of such organisms as *Streptococcus alpha, Streptococcus gamma, Enterococcus, Staphylococcus aureus, Bacillus coli* and *Bacillus pyocyaneus* unless the same organism has been found during life" Slightly less condemnatory of postmortem bacteriology are Hunt, Barrow, Thompson and Waldron who, working independently found positive postmortem blood cultures in 31, 43 7, 24 and 20 7 per cent of cases, respectively In every case but one in which

blood cultures were positive, foci of infection were found They concluded that postmortem bacteriology is reliable and often leads to the solution of the exact cause of death Postmortem bacteriologic observations of this nature make it appear doubtful that convincing cultural evidence of the cause of rheumatic fever is forthcoming by necropsy studies alone

Since the early bacteriologic isolations, there has been a steady succession of cultural studies of patients with rheumatic fever Organisms supposed to be causative have been cultivated from tonsils, throat, blood, feces and synovial fluid usually of the living patient, and on account of cultural or immunologic characteristics have often been considered specific Some of the organisms thus isolated have been described as follows a coccus "closely related, but not identical with the coccus described by Poynton and Paine" by Frissell, three types of streptococci (from the joints) each readily convertible into the other by Rosenow (*c*), a diplostreptococcus usually anhemolytic and with constant morphologic and cultural characteristics from blood, tonsils and spinal fluid in chorea by Quigley, green, or hemolytic streptococci from the blood of two thirds of patients with polyarticular rheumatism by Freund and Berger, a short-chain nonhemolytic streptococcus with constant serologic and biologic reactions from the blood, tonsils and stools by Small (*a*), and Kreidler, three groups of streptococci from the tonsils and postnasal spaces of patients with acute and subacute rheumatism by Lazarus-Barlow, streptococci, usually of the viridans group, apparently not specific, from the blood by Clawson (*a*), and a nonmethemoglobin-forming streptococcus producing a specific exotoxin from the blood by Birkhaug (*a*) Recently Cecil, Nicholls and Stainsby (*b*) reported the finding in a high percentage of blood and joint cultures from patients with rheumatic fever, of streptococci predominantly of the alpha or viridans type and apparently falling into definite biologic groups This array of observations, some agreeing and some conflicting, is difficult enough to interpret even without a considerable number of failures to isolate similar organisms If one assumed that the organism isolated in each instance was causative, one would be forced to conclude either that rheumatic fever is not due to a specific micro-organism, but is a symptom complex known by that name which can be produced by any one of several types of organisms, or that the bacterium involved can readily change in morphologic, cultural and invasive qualities

To complicate matters further, numerous others besides Philipp and Cole, apparently using extremely careful and often varied technic, have failed to find organisms similar to any of those described Some observers also have found bacteria without demonstrating any valid differential or specific features Loeb, who found diplostreptococci in

several of his blood and joint cultures, noted that they were in no way different from other strains He said "All the characters supposed to belong particularly to the coccus of rheumatism have been shown to occur in other strains as well ' Harrison failed to isolate "streptococcus rheumaticus" from the blood of 26 patients Swift and Kinsella did not succeed in cultivating organisms from the joints, and recovered nonhemolytic streptococci from less than 10 per cent of their blood cultures They concluded ' No type of streptococcus has been constantly associated with acute rheumatic fever " Lynch and Irvine-Jones, following Clawson's technic failed also to isolate micro-organisms from the blood stream during life Nye and Seegal, using varied and apparently adequate methods, failed to find nonhemolytic streptococci in the blood of 25 patients with the disease They recovered nonhemolytic streptococci from the throats of patients with the disease and from normal persons with about equal frequency, but found both types relatively nonpathogenic for rabbits Neither Harrison nor Nabarro and MacDonald could observe any essential difference between streptococci isolated from rheumatic tonsils and those from nonrheumatic tonsils

Positive observations are admittedly of greater import than negative ones, but if the cultural evidence of the specific nature of rheumatic fever is to prove important, future research should show a greater uniformity of results or some adequate explanation for the discrepancy recorded

Experimentation on animals which has constituted a part of almost every etiologic study, has again resulted in a wide disparity of opinion The earlier workers were, for the most part, intent on producing in animals, usually rabbits, by intravenous inoculation of the organisms that they isolated, a multiple nonsuppurative arthritis which should differ from the usual changes observed by similar inoculation of streptococci from other sources (Beaton and Walker, Poynton and Paine, Beattie, Beattie and Yates, Lewis and Longcope, Shaw, Westphal, Wassermann and Malkoff, and others) Cole, however, using seven strains of streptococci isolated from nonrheumatic sources, found that arthritis and endocarditis could be produced in rabbits by these strains He concluded "The description of a distinct variety or species of streptococci based on this property of causing endocarditis and arthritis is unwarranted " Opposed to this view were Coombs, Miller and Kettle, who said, "Such differences as exist between the experimental rheumatic infection and the human variety are accountable for by the difference in the mode of entry of the infective agent in the two conditions "

Gradually, largely as the result of an increasing number of reports of polyarthritis experimentally produced by the inoculation of many

types of organisms, it became recognized that the criteria of the animal equivalent of rheumatic fever were not wholly known and should be more carefully defined This has involved serious difficulties, as the generalized nature of rheumatic lesions is only now becoming thoroughly recognized (Pappenheimer and von Glahn, Swift, McClenahan and Paul and others), and the translation of these physiologic and morphologic changes into the conditions observed in the experimental animals is subject to wide variation of opinion Certainly, nonsuppurative polyarthritis and endocarditis are suggestive as equivalent changes, but because they have been produced by so many apparently diverse organisms something more seems necessary The focal myocardial lesions described by Aschoff and called Aschoff bodies have been considered as practically pathognomonic of rheumatic carditis These and similar myocardial lesions have been frequently described and discussed (Bracht and Wachter, Coombs (*b, c*), Pappenheimer and von Glahn, Thalhimer and Rothschild, Clawson (*b*) and others), but there does not appear to be any agreement as to what constitutes Aschoff bodies or their equivalent in the rabbit Thus, Thalhimer and Rothschild said that "the only point of similarity between the experimental lesions and those found in cases of rheumatic carditis in man is their focalized nature" Miller also, in considering this question, stated that "in about one half of the rabbits and two thirds of the guinea-pigs myocardial lesions were encountered which consisted of interstitial accumulations of lymphocytes and endothelial cells Similar lesions were found in control animals" Clawson, in a recent review of the Aschoff nodule, went even further and declared that "it is doubtful whether the Aschoff nodule should definitely be considered a specific lesion resulting from a specific rheumatic virus" This opinion is also held by Klinge One can only conclude that no single feature of experimental rheumatic fever has been shown to be specific The interpretation even of certain groups of lesions is doubtful, though Gross, Loewe and Elias oph considered that the reproduction of Aschoff bodies, nonbacterial pericarditis and nonbacterial verrucous endocarditis afford essential criteria It is evident that controversy over the specific nature of an experimental rheumatic fever can only come to an end when agreement can be reached as to what is meant by the lesions experimentally provoked The ease with which arthritis can be produced in rabbits perhaps makes the general use of this animal in this disease unfortunate

Mention must be made of the failure encountered by Miller in the attempt to transmit the virus from whole blood, serum joint fluid, pleural fluid or throat washings of patients in the acute stage of rheumatic fever to rabbits and guinea-pigs One may also note the failure of Gross, Loewe and Eliasoph to produce anything which they con-

sidered as analogous to rheumatic fever by injecting streptococci from various sources into a large number of animals of seven different species Nye and Seegal found the nonhemolytic streptococci which they isolated from the throats of rheumatic patients relatively nonpathogenic for rabbits

On the other side of the balance are large numbers of reports of experimental arthritis with or without other lesions produced by streptococci from various sources (Rothschild and Thalhimer, Lazarus-Barlow, Cole, Clawson, Jackson, Rosenow (*c*), Small, Kelly, Belk, Jodzis and Fendrick, Davis Topley and Weir, Coombs, Miller, Kettle and others) The arthritis produced was sometimes considered a specific reaction to the organism isolated from rheumatic tissues, but most of those observers who controlled their work with streptococci from other sources obtained a similar reaction (Jackson Davis, Topley and Weir and others) Of great importance in this experimental field are the observations of Schloss and Foster To quote from their summary

> Inoculation of cultures of *Streptococcus pyogenes* [hemolytic organism obtained from the tonsils of patients with rheumatic fever] into the blood stream of four monkeys induced a polyarthritis suggestive in certain respects of rheumatic fever in man In three instances immunity to the infectious agent was observed after repeated inoculations The infecting organism could be recovered from the blood stream at the onset of symptoms, but not afterwards This fact possibly has some bearing on the failure to isolate organisms from the blood of man with "rheumatic fever" Recovery from the induced arthritis may be complete and in such cases no lesion is found in the joint or periarticular tissues at autopsy Agglomerations of specifically staining cells were noted in the heart muscle, kidney, liver, spleen, and periarticular tissues

The difficulties involved in performing this type of experiment are perfectly obvious, but it seems that the barriers to human experimentation in this disease make it wise to investigate all the possibilities of experimentation in the species most closely related to man

Various theories have been proposed in the attempt to explain the apparently conflicting clinical, bacteriologic and experimental observations That which has received the most attention in recent years is the allergic theory, though suggestive observations along this line have been made now and again over many years Menzer, in 1902, suggested that streptococci were distributed to the joints first without producing symptoms, but that inflammatory symptoms developed only after the elaboration of antibodies in the tissues The allergic hypothesis received further analysis and observation by Weintraud Friedberger, Herry and Faber The latter, especially, working with rabbits, contributed significant observations He found that by injecting *Streptococcus mitis seu viridans* obtained by Libman from the blood of a patient with subacute endocarditis into the joints of rabbits these animals apparently

became sensitized to this organism in such a way that subsequent intravenous inoculation with this organism, and with this organism only, invariably produced arthritis This sensitization could be developed only after three or more intra-articular inoculations He therefore suggested an analogy between this phenomenon and the relapses in acute rheumatic fever In a discussion, he stated

> It seems to be clearly proved that this preparatory or sensitizing process is, within narrow limits, a strictly specific one, i e, the organism used for the exciting, intravenous injection must be the same as that used for the sensitizing, intra-articular injection, else the reaction fails to occur

This early work passed with relatively little notice for a time, but during the past five years has received considerable concentrated study Zinsser, and Swift, Derick and Hitchcock and their colleagues, have been particularly interested in this aspect of the subject The allergic problem has been attacked mainly from two angles, the study of experimental streptococcal allergy in rabbits, and the study of allergy in man as evidenced by reactivity to streptococcal antigens in skin tests

The analogy between the onset and manifestations of rheumatic fever and those of syphilis and tuberculosis was early pointed out by Swift This led to the consideration of rheumatic fever as perhaps similar to tuberculosis and syphilis in some aspects and requiring similar focalized primary sensitizing lesions which in human rheumatic fever might well be located in the tonsils Swift, Mackenzie and Hanger, Hanger, Zinsser, and Kinsella and Hagebusch were chiefly responsible for the demonstration of corresponding phenomena in rabbits It was found that when autolysates, filtrates or suspensions of certain nonhemolytic or green-producing streptococci were injected intradermally into rabbits, a type of skin reaction occurred which could be divided into definite phases depending on the state of immunity, normality or hyperergy (Swift) of the particular animal Hyperergy can be produced in normal rabbits by continued intradermal injections of streptococcal antigen The animal is then subject to dermal, ocular or lethal reactions of much greater severity from a relatively small amount of stimulating antigen than is a normal animal This state can be maintained, however, only by continuing the intradermal focal sensitization Type specificity was not, as a rule, observed The state of immunity could be produced from normal or hyperergic conditions by intravenous injections of the streptococcal antigen, in this way, the reaction of the rabbit to the antigen was markedly reduced in intensity Analogy therefore, can translate this picture into rheumatic fever in man, with the tonsil serving as the primary focal sensitizing lesion for an antigen perhaps common to streptococci which have heretofore been considered distinct

The evidence thus far advanced for this theory is based on animal experimentation alone and can be applied to rheumatic fever in man only by analogy Zinsser and Yu summed the matter up in the following manner

> It seems to us possible that the curious frequency with which non-hemolytic streptococci are associated with the disease, while at the same time the non-hemolytic streptococci so found represent many varieties, may be due to the fact that with these organisms that peculiar balance between invasiveness and resistance is established in man, which most easily results in chronic infection

Skin tests with streptococci or their products made on patients with rheumatic fever, convalescents and control groups have been interpreted as bearing directly on the allergic theory Birkhaug, Lucas, Kaiser, Hart and Irvine-Jones have made studies of this nature Birkhaug (*c*), as a result of 3,114 skin tests divided among 42 patients with active rheumatic fever, 146 patients with inactive or "cured" rheumatic fever, 69 patients with chronic arthritis and 337 nonrheumatic controls, concluded

> It appears that a non-specific common allergenic factor is present excessively in the bacterial products of indifferent and viridans streptococci and moderately present in solutions of hemolytic streptococci, to which cases with either acute rheumatic infections or chronic infectious arthritides react hyperergically

Irvine-Jones suggested similarly "that the rheumatic syndrome is an allergic response of certain predisposed persons to the common streptococci of the upper respiratory tract" Kaiser found no parallelism between the skin tests with the filtrate from the cultures of streptococci isolated by Birkhaug and the Schick and Dick tests, but Hart did not believe that it was clear whether the reaction obtained with this test is purely an allergic phenomenon as in the tuberculin test or whether it indicates a susceptibility as in the Schick and Dick tests

The skin tests so far made have been with preparations from streptococci only, and are hence subject to the criticism of inadequate control, though the results are certainly suggestive In conclusion, it can be said that the experimental support of the allergic theory already obtained opens a field which may aid materially in explaining the mechanism of infection in rheumatic fever It does not seem that the essential conception of rheumatic fever as a disease caused by pathogenic microorganisms will be altered, though many as yet obscure features may be explained by further studies along this line

Closely related to the studies on allergy have been those involving a consideration of a soluble bacterial toxin Again, the conception of a toxic agent has resulted largely from the high percentage of failures to isolate bacteria from the joints or from attempts made to explain the

mechanism of action Though not a wholly novel suggestion, the question of toxin production has received most attention during the last few years Birkhaug, Kaiser, Steinfield and Jacobs, and Hart have described and employed a soluble toxin from various streptococci isolated from patients with rheumatic fever Rheumatic persons showed relatively high susceptibility to these toxins (generally prepared as a Berkefeld filtrate), as measured by skin reactions In some instances, animals showed marked toxic effects from intravenous or intra-articular inoculation A further extremely interesting observation was that of Birkhaug (*a*) following intravenous inoculation of himself with such a filtrate He employed for this purpose a strain of nonhemolytic streptococci isolated repeatedly from a patient with rheumatic fever About twenty-four hours after the injection acute multiple arthritis developed with fever, pain, swelling and redness This condition subsided in a few days Birkhaug's description of the course of events is so striking as to make repetition of the experiment on a larger scale highly desirable, if other self-sacrificing volunteers can be found

Irvine-Jones observed that persons suffering from rheumatic fever showed a marked sensitivity of the skin to filtrates of widely diverse streptococci from normal as well as from rheumatic subjects Lazarus-Barlow found no exotoxin associated with the streptococci that he isolated from the tonsils and postnasal spaces of patients with rheumatic fever, but believed that there was evidence of an endotoxin which stimulated the production of antitoxin and affected the heart muscle, lungs and other organs of rabbits Nye and Seegal found, with few exceptions no soluble toxins giving rise to the skin reactions comparable to Birkhaug's test toxin, in the nonhemolytic streptococci that they isolated from the upper respiratory passages The study of toxins in relation to rheumatic fever is hampered by the multiplicity of streptococci which have been found, but again it is possible that extension of these studies may throw considerable light on the specificity of the streptococci involved

Before passing to the consideration of streptococci in arthritis, it must again be stated that no thoroughly satisfactory classification exists This is reflected on clinical grounds by a frequent tendency on the part of the disease to change from acute to chronic, from multiple joint involvement to involvement of a few or single joints and even sometimes from nonbony changes to osteoarthritis In fact, the clinical gradations between acute rheumatic fever, on the one hand, and chronic osteoarthritis on the other are so close together that they sometimes involve great diagnostic difficulty Even pathologic studies do not provide an invariably satisfactory basis for classification That differences between types exist can scarcely be doubted but even thorough anatomic

studies of joint disease have failed to yield a classification valuable in directing the clinician in the course he must pursue Etiologically, too, the classification even at the extremes is not distinct, since streptococci and other organisms have been found in tissues from all types of joint disease with as yet no valid differential features This confusion has been noted by many and is well expressed by Elliott

> If such a pathological picture is accepted for so-called rheumatic fever, then it would seem but a step to enter the field of chronic polyarthritis—depending upon the attenuated or mutated organism acting We have, however, no such proof limiting the chronic types of arthritis to a single organism, as in rheumatic fever On the contrary, there is much pointing to the probability of its multiple origin from many germs

As in the case of rheumatic fever, however, streptococci of various sorts have been more frequently implicated in arthritis than other organisms Attempts to isolate micro-organisms from the tissues in arthritis have been fraught with even more complications than in rheumatic fever, since the conception of focal infections has stimulated the isolation of micro-organisms from a greater variety of tissues

One of the earliest definite bacteriologic reports on arthritis was that of Poynton and Paine,[2] who at necropsy found a diplococcus in the synovial membrane of the knee joint of a man, aged 67, several of whose joints showed the chronic destructive changes recognized as occurring in one type of rheumatoid arthritis On two occasions when injected into rabbits, it produced a severe arthritis, but no cardiac lesion This arthritis differed in type from that which they had hitherto produced with the diplococcus of rheumatic fever They believed that this diplococcus was the cause of the arthritis in the case from which it was isolated Forkner, Shands and Poston cultivated the synovial fluids from 63 persons who had "chronic infectious arthritis" and found that fourteen were positive Eleven of these positive fluids yielded *Streptococcus viridans,* two *Gonococcus* and one *Staphylococcus aureus* Cecil, Nicholls and Stainsby found attenuated hemolytic streptococci in a number of cultures from joints of patients with "chronic infectious arthritis" Sekiguchi and Irons in cultures from joints of swine with chronic arthritis obtained a high percentage of mixtures of minute bacilli and streptococci, but believed that the latter were usually secondary invaders Bacteriologic studies on arthritis in lower animals may prove of some aid in solving the problem in man

As in rheumatic fever, the question of bacteremia in arthritis has developed investigations based on blood culture methods Moon and Edwards using a somewhat complicated blood culture technic concluded

2 Poynton and Paine Page 149

In arthritis, pararthritis, and myositis, organisms may be isolated from the blood stream by improved cultural methods, This is possible more frequently in the acute stages when the patient is in a febrile condition, and less frequently in the subacute and chronic stages of the infection Streptococci may frequently be cultivated from the blood stream in rheumatoid arthritis There is evidence that the so-called diphtheroid bacilli and bacillus mucosus occasionally cause infection of the joint structures

Richards obtained *Streptococcus viridans* from the blood in 14 of 104 cases of chronic arthritis Hadjopoulos and Burbank, by neutralizing the alexin in the blood of patients suffering from chronic arthritis, obtained a high percentage of positive cultures in the fall and winter months Streptococci predominated, but diphtheroids and *Staphylococcus aureus* were also found Suranyi and Forro obtained 68 per cent positive cultures from 25 patients with polyarthritis The organisms all fell into the nonhemolytic or the green-producing class, though apparently no attempt was made to place them more accurately Cecil, Nicholls and Stainsby made blood cultures in 78 cases of "chronic infectious arthritis" with positive results in 61 5 per cent Of the streptococci recovered, 83 3 per cent were culturally and biologically identical and appeared to be attenuated hemolytic streptococci The remaining 16 7 per cent fell either into the *viridans* or the indifferent group Diphtheroids were obtained in a few instances

Lymph glands draining involved joints were excised aseptically and cultured by Rosenow (*b*), Forkner, Shands and Poston, Gibson and Poston Rosenow isolated organisms in 35 of 38 cases divided as follows streptococci 14, streptococcus-like anaerobe 9, *Bacillus welchi* 9, *Staphylococcus* 3, *B mucosus* 1 and *Gonococcus* 1 In no instance were the streptococci hemolytic, and often there was a marked difference between the organisms isolated from lymph glands and those found in foci of infection Forkner, Shands and Poston obtained 10 positive growths from 21 lymph gland cultures Nine of these were *Streptococcus viridans* and 1 was *Gonococcus* In 5 of these cases, the same type of organism was grown also from the joint More recently, Poston has studied 120 lymph glands by cultural methods and obtained organisms in 72 (60 per cent) *Streptococcus viridans* was recovered 67 times *Streptococcus nonhemolyticus* twice, *Staphylococcus aureus* twice, and *Gonococcus* once It would be valuable to control this work with normal lymph glands and glands enlarged in other diseases to a greater extent than has apparently been done in studies of this condition

The relation of organisms isolated from foci of infection to the morbid process elsewhere is one of extreme difficulty, since in so many instances a number of different types and strains can be obtained from the same source Nevertheless, the doctrine of focal infection as

elaborated particularly by Billings, Rosenow[3] and others has received wide attention, and has been studied exhaustively The tonsils have been subjected to much bacteriologic study in chronic arthritis probably partly because of the apparent relation of tonsillitis to rheumatic fever Experiments have utilized a variety of methods from simple cultivation of organisms from the tonsil in situ to quantitative bacteriologic methods and experimental lesions in laboratory animals Hence any comparison of results of different observers is fraught with great difficulty and further complicated by its relationship to the "elective localization" postulated by certain workers Rosenow, Davis, Byfield, Rhoads and Dick and a host of others have reported the recovery of streptococci from the tonsils of patients with various types of arthritis The streptococci described have been of all types as far as reaction on blood is concerned—green-producing types perhaps predominating, but indifferent and hemolytic types being frequently described Polvogt and Crowe examined tonsils removed from 10 patients with chronic tonsillitis and infectious arthritis and found hemolytic streptococci "in almost pure culture" 8 times and *Staphylococcus aureus* twice Rhoads and Dick observed a high percentage of tonsil remnants in "tonsillectomized" patients, and made quantitative bacteriologic tests of tonsils or tonsil remnants removed surgically They found streptococci of all blood reactions and some other organisms, at times, in the tonsils from arthritic patients as well as in those from patients suffering from other conditions When these streptococcal strains were injected into rabbits, the most frequent lesion found at autopsy was arthritis The rôle of the tonsil in harboring the infectious agent in some cases of arthritis is almost beyond dispute, but what exactly this agent is or the mechanism by which it acts is as yet not accurately determined

Streptococci have also been obtained from dental abscesses or pulpless teeth from patients with arthritis The work of Rosenow and Ashby, Rosenow (*d*), Price, Willcox Franke, Hurst, Haden, Watson-Williams, Davis, Meisser and Brock and many others has done much to establish the facts of dental focal infection Unfortunately, the same lack of uniformity in the type of streptococci isolated has provoked a sense of confusion and futility difficult to surmount Nevertheless, streptococci have been found often in pure culture, in dental foci, removal of these foci has resulted in clinical cure so often that indirect evidence of their causative connection in some instances seems convincing The hypothesis of "elective localization" advanced by Rosenow has perhaps received its greatest support in the study of dental streptococci This hypothesis involves the conception of an affinity

3 See many papers published from 1910 on in the Journal of Infectious Diseases, the Journal of the American Medical Association, etc

of some organisms for definitely selected organs or tissues of the body The assumption of fixed properties of invasion for these streptococci is necessary for this theory and a recognition of groups of streptococci differentiated on the basis of their ability to produce arthritis, nephritis, myocarditis, duodenal ulcer and so forth Rosenow and his followers and recently Precht have succeeded in producing arthritis alone in rabbits or dogs when streptococci from arthritic patients were used and nephritis or ulcers of the stomach alone when streptococci from homologous sources in man were employed Altogether, such a mass of evidence has been collected on this subject both pro and con, many having failed to substantiate these results of elective localization, that the only possible position at present is to suspend judgment Holman, who recently reviewed the subject of focal infection and elective localization, said

> Does the localization of bacteria such as streptococci depend on an inherent property in the microorganism which is independent of, or which is demonstrable in spite of, alterations of technic or varying susceptibilities due to different species of animals, the effects of diet, previous or concurrent spontaneous infection, age, and a variety of environmental conditions? Each possible factor must be controlled independently, and it is a difficult undertaking However, what Rosenow and his followers particularly showed and what all the other investigators of the problem have definitely demonstrated is that streptococci do localize in various organs and tissues and can produce lesions at least sufficiently suggestive of those found in man so that their potential danger in infected foci cannot be neglected

Streptococci, as well as many other organisms, have been recovered from numerous other tissues of the body and often have been deemed causally related Accessory nasal sinuses, gallbladder, cervix, urine, prostate and feces have served to provide streptococci for those working on cases of arthritis (Watson-Williams, Wilkie, Moench, Kauntze, Culver, Wear, Keating and Mutch) The organisms thus obtained have been studied in different degrees, varying from the determination of the effect of removal or treatment of the focus on the course of the disease to experimental production of the disease in animals and serologic tests In general, except for certain of the serologic tests, to be discussed later, the same statements apply as were made in considering the significance of streptococci from other infected foci

Streptococci obtained from practically all these sources have been shown to produce arthritis in animals In some instances, the streptococci were given intravenously, in others intra-articularly and in others they were inoculated around the teeth in an attempt to reproduce the infective focus (Livingston) Acute reactions have resulted even after the injection of moderate doses of dead autogenous streptococci (Davis [c]) In fact joint reactions to streptococcal antigens from

so many different sources have been produced so readily, that this fact alone casts considerable doubt on any conception of a specific arthritic streptococcus (Harding, Nathan) Davis (*c*) said

The mere fact that the various strains of streptococci from the tonsils can cause joint-lesions in animals is perhaps in itself not of great significance Indeed, hemolytic streptococci from the normal throat may do so, as I have myself demonstrated It is possible that the reason why in one individual streptococci cause arthritis, and in another nephritis lies in the varying local susceptibility of the organs of the individual rather than in any peculiar specificity of the infecting cocci

As is the case with rheumatic fever, the multiplicity of bacteriologic observations in arthritis has stimulated a search for some rational basis of explanation Serologic differentiation early received attention through the work of Hastings As a result of complement-fixation tests on streptococci, he stated

One is justified in concluding that *Streptococcus viridans* is an infectious agent and excites the production of a complement-fixing substance in the organism in cases of arthritis deformans, and, therefore *Streptococcus viridans* is the probable causative agent of the disease in many cases of arthritis deformans Probably 40 per cent and more of cases of arthritis deformans should be considered as chronic infective deforming arthritis Rarely the clinical manifestations of arthritis deformans may be due to gonococcus infection The serum from one case may react positively to two different organisms, most frequently to *Streptococcus viridans* and to *Gonococcus,* when the reaction to the former should be considered the indicator of the causative agent, since with the latter, infection is often latent in the genito-urinary tract Incidence of gonococcus infection is high and the clinical manifestations of arthritis deformans are rarely produced by gonococcus infection

More recently Burbank and Hadjopoulos in a number of papers have described a technic for bacterial fixation of streptococcus types whereby various arthritic and rheumatoid conditions may be classified serologically into three major groups These groups they described as

(*a*) Arthritis reacting to hemolytic streptococci and belonging to the iso-atrophic class This type in pure form is periarticular

(*b*) Arthritis reacting similarly to hemolytic streptococci, but of different fixing properties This type is aniso-atrophic or deformans

(*c*) Arthritis reacting to streptococci of the *S viridans* type and belonging to the osteo-arthritic or productive form

They go even further in this differentiation, saying

A fair percentage of arthritic patients, especially those suffering from colitis and chronic constipation, have a marked tendency to effect complement fixation in certain strains of nonhemolytic streptococci isolated from the intestinal tract of similar arthritic cases This type of organism seems to be a transition form of *Streptococcus hemolyticus,* with certain properties lost through secondary intestinal implantation

The vast scale on which this work has been done together with the confirmatory evidence of Green, who also found *Streptococcus viridans* and *Gonococcus* predominating in serologic tests, entitles this differential method to serious consideration Hitchcock, in studying a large group of indifferent streptococci serologically, found a homologous group which he designated type I, though he feels that further division into subtypes is possible The remaining strains he placed in group 10 because of their failure to react strongly with type I serum This he believes is a heterogenous group He found, however, that

> Indifferent streptococci occur in comparatively the same abundance in the throats of patients suffering from rheumatic fever or early in convalescence from the disease as they do in those who have recovered from the disease, or in those patients suffering from other diseases Type I occurs with comparatively equal frequency and abundance in the throats of all four classes of individuals studied

Others in their attempts to classify and differentiate streptococci obtained from arthritic patients have employed various criteria Solis-Cohen and Loewe have made use of a method which they term "pathogen selection" and which is an avowal of their belief that many different organisms may cause arthritis This method is based on the essential conception that a patient with arthritis does not contain in his blood the immunologic properties to the particular organism causing his disease and hence his blood will allow that organism to grow whereas other organisms to which he is presumably immune are inhibited The technic of this method, as described by Loewe (*a*), is as follows

> An equal quantity of any specimen to be examined is inoculated, as far as possible simultaneously, on to suitable media on the one hand, from which after incubation, will be obtained the ordinary direct or "A" cultures, and on the other hand, into 5 cc of the patient's own blood freshly drawn, which, after incubation and subsequent subculture on to similar media, will provide the pathogen selective or "B" cultures, according to whether the patient's blood happens to be able to inhibit, or otherwise, any or all of the bacteria shown by the "A" cultures to have been present in the specimen

Frequently, by this method, more than one organism was demonstrated to be pathogenic for an individual, and frequently, also, more than one focus contained organisms deemed by this method to be pathogenic This theory is difficult to reconcile with the delicate balance existing between infection and immunity This balance would point more toward periods when the patient's immunity would be reflected in the inhibition of the growth of the causative microbe, as well as the others

The possible occurrence of streptococcal allergy as explaining the mechanism of streptococcal arthritis enters this study, as well as that of rheumatic fever It is obviously just as reasonable to consider

allergy as the important mechanism in the production of arthritis as in rheumatic fever No great amount of observation or experimentation has been directed toward arthritis from this point of view, though the possibility has been suggested practically from the beginnings of this theory (Zinsser, Swift, Small [c]) Freiberg, however, claimed to have produced by the repeated injection of a bacterial extract an experimental arthritis in rabbits simulating the proliferative arthritis in man This, he believed, is a local allergic manifestation of a generalized state of allergy to a specific bacterium or bacterial extract

The presence and action of a soluble toxin are again difficult to determine because of the number of organisms that have been found associated with arthritis In this connection, however, the observation of Fisher is of special significance He deduced as the result of the intra-articular injection into rabbits of a few cubic centimeters of sterile human synovial fluid (from an osteo-arthritic joint) with the production in the rabbits of degenerative changes in the articular cartilage, that some kinds of joint fluid contain a toxic substance but no bacteria

Streptococci, then, have been found associated with many cases of arthritis of various types, as well as with rheumatic fever This association while not constantly noted by all observers has occurred sufficiently often to suggest a causal relationship in some instances, at least Though no uniformity of type has been established for all such streptococci two possible explanations are compatible with this etiologic interpretation, viz , that arthritis can be caused by streptococci of many types, not specific or that the streptococcus of arthritis has many inconstant features (Davis [d], Rosenow [a]) The doctrine of microbic dissociation, as developed by Hadley and others, may serve as the ultimate explanation for such apparent inconsistency

Although recent opinion has veered in the direction of the etiologic significance of streptococci, importance has been attached by various observers to certain other organisms both for rheumatic fever and for some forms of arthritis Of these, undoubtedly the most important historically in its relation to rheumatic fever is the Achalme bacillus

This organism was obtained by Achalme only by anaerobic cultural methods from the blood, pericardial fluid and other tissues post mortem About the same time, this work obtained confirmation by Triboulet and Coyen (a) and Thiroloix, the latter, however, carried his studies of this organism further and found that growth could be obtained aerobically after several generations on milk and broth . When injected intramuscularly into guinea-pigs the organism produced a serosanguineous edema, but had no effect on dogs or mice In view of subsequent observations Thiroloix' remarks are significant "Il peut provoquer

des infections secondaries streptococciques" (It can provoke secondary streptococcal infections)

By early failures to corroborate the finding of this organism, and later neglect in attempting to find it, this etiologic theory has fallen into the limbo of lost causes Recently, however, this microbe has again been brought into the limelight by Bertrand, who said

Seventeen years of uninterrupted research work upon the specificity of acute articular rheumatism, has convinced me that this affection is due to the anaerobic bacillus, described by Achalme thirty years ago, and studied later by Thiroloix, Rosenthal, Triboulet, and many others, but which has now dropped into obscurity through official indifference In my opinion, inefficient technique in isolating this microbe, was above all, the cause of the lack of credit accorded to it This polymorph microbe can assume the coccic form, on more than one occasion, I have witnessed the transformation of these two forms one into the other, in vitro as well as in vivo by intramyocardial inoculation of rabbits

Bertrand also believed that chronic rheumatism is caused by this organism and stated that Vivien and Lautier, as well as himself, had been successful in the treatment of such patients with antirheumatic vaccine prepared from this organism

What the final conclusions concerning the Achalme bacillus will be it is, of course, impossible to say The evidence of its association with rheumatic fever or arthritis is certainly less convincing than that of the association of the streptococci with these conditions, though in view of the wide field opened by the newer studies of transmutation and dissociation it may prove in time that the Achalme bacillus has just as much relation to rheumatic diseases as have the streptococci

Bacilli apparently other than that described by Achalme have been found in the tissues of patients with rheumatic fever or arthritis at various times Probably the earliest of these was Schuller's bacillus This was described by Schuller as a short bacillus with bipolar bodies and associated with single round cocci which he obtained from the periarticular structures in chronic arthritis It was gram-negative and grew with difficulty at first on the usual laboratory mediums When injected into rabbits' joints in fairly large quantities it never produced pus, but did produce chronic joint changes It could be isolated again from these disordered joints A similar organism was found a few years later by Blaxall His observations were summarized as follows

(1) In the synovial fluid of eighteen cases of rheumatoid arthritis an organism has been demonstrated which is constant in its characteristics (2) The organism is a minute bacillus exhibiting marked polar staining It is difficult to stain and easily decolorized (3) The organism can be grown in culture media and presents striking characteristics In beef broth it gives the appearance of gold dust and on agar-agar and serum its growth is almost invisible It does not grow on nutrient gelatin at ordinary temperatures (4) It is present in the blood in severe

cases (5) It has not been found in the synovial fluid from distended joints due to other causes

Fayerweather obtained short bacilli from joint cultures in four cases of arthritis These bacilli were somewhat but not entirely alike, and he was unable to identify them with any previously described By inoculation of these bacilli directly into the joints of rabbits, arthritis was produced Intravenous inoculation had no effect on the rabbits Goadby isolated organisms from the gums and other tissues of patients with "rheumatoid arthritis,' which he believed were "streptobacilli" with bipolar staining "though very difficult to tell from streptococci" Nye and Seegal, although failing to find streptococci in blood cultures from 25 patients with rheumatic fever, recovered small gram-positive bacilli from two cases and in one of these from two cultures from the same patient No important significance was attached to these organisms Cecil, Nicholls and Stainsby in blood cultures from patients with "chronic infectious arthritis" isolated most frequently a type specific streptococcus, though in several instances they obtained "diphtheroid" organisms Key in 29 positive cultures from 88 joint aspirations on 50 patients with chronic arthritis of all kinds obtained minute bacilli in masses or mixed with staphylococci, 14 times These bacilli produced arthritis in rabbits when injected directly into the joints in 34 of 50 instances Bacilli of these types have been frequently lumped together somewhat indiscriminately as "diphtheroids," and since similar appearing "diphtheroids" have been found from a great many sources they are generally considered as having no pathogenic significance As streptococci, too, have been found from many sources, it is perhaps unwise to dismiss such bacilli without according them more study than they are usually allowed

Staphylococci also have been considered by some observers to be the cause of arthritis of certain types The foremost advocate of the staphylococci in this connection is Crowe, who believed in a dual etiology for arthritis, i e, the streptococci as the cause of "osteoarthritis" and a specific white staphylococcus which he names *Micrococcus deformans* as the cause of "rheumatoid arthritis" If it is assumed that the differentiation between these forms of arthritis is accurate (about which, however, there is considerable doubt), the evidence for the staphylococci, as advanced by Crowe, rests chiefly on the following points—the isolation of a staphylococcus from the urine feces or scurf of patients with "rheumatoid arthritis" which because of its type of growth on a special medium (Crowe's medium) and its agglutinative characteristics and the effect of vaccines on such patients is considered a specific type of staphylococcus differing from staphylococci found in other conditions or from other sources A vast amount of work has evidently

been done by Crowe and others along these lines, but it is safe to reserve judgment until this work has been extended, particularly as far as original isolations are concerned, and confirmed by others It is only fair to state that Crowe is not the only one who has collected evidence implicating staphylococci in arthritis Thus, as early as 1893, Dor isolated an "attenuated staphylococcus" from the vegetations of the synovial membrane of a chronic arthritic joint which when injected intravenously into two rabbits produced an arthritis deformans of both knees Crowe quoted Collins, Watson-Williams, and Watson as contributing evidence of staphylococcal infection in arthritis, particularly from the view of sinus infection Mutch found pyogenic staphylococci in the small intestines associated with "chronic stasis" in patients with chronic arthritis He stated

> The suggested explanation of these phenomena is that ingested staphylococci sometimes escape destruction in the stomach, and, in their growth being encouraged by intestinal stasis, they infect the mucous membrane and surrounding tissues, and thereby produce morbid changes in the joints

The comment by Poynton indicates, perhaps, too hopeless an attitude

> It appears to me that, just as a particular streptococcus may cause acute rheumatism, so very possibly some staphylococcus may be an important cause of rheumatoid arthritis Then I remember that the streptococcus of rheumatism, if cultivated in various solid media, may become indistinguishable morphologically from a staphylococcus, and I wonder whether in human diseases there is any essential line to be drawn between the streptococci and staphylococci

Key, in addition to finding in chronically diseased joints the minute bacilli previously mentioned, found also staphylococci, either alone or mixed with the bacilli, in the majority of his positive cultures These staphylococci when injected into rabbit joints produced arthritis in 66 of 84 cases—a slightly higher percentage than was found by inoculation of the bacilli

A theory that intestinal protozoa, particularly the amebas, are responsible for a large group of chronic arthritides has been developed largely on the western coast of the United States The evidence for this is largely due to the work of Barrow and Armstrong, Ely and his colleagues, and Koford Amebas have been found by these observers in the stools of patients with chronic arthritis and in sections from necrotic areas of bone The group in which such protozoan infestation is most common has been called by Ely (*a*) the great second type of arthritis, which he defines as having "two distinguishing clinical features (*a*) bone production (lipping, spurring) at the joint line, and (*b*) absence (except in spinal involvement) of union between the ends of the bones, either fibrous or bony" This apparently is similar to the osteo-arthritis or hypertrophic arthritis of more common usage Though

this form of arthritis is common in places where amebic infestation is believed to be rare, it is possible that this form of infection will prove a more important agent among the vast number of stimuli which are associated with arthritic disease Others, e g , Moorehead, have reported amebas also in association with arthritis Moorehead's evidence was based on amebic dysentery and arthritis occurring coincidentally in soldiers with an improvement of both conditions following treatment with emetin However, he does not report that he aspirated involved joints to search for amebas

One other etiologic theory, this time affecting rheumatic fever, should be given brief consideration Clarke suggested because of the peculiar geographic and seasonal distribution of rheumatic fever, which corresponds with certain habits of the common rat flea, *Ceratophyllus fasciatus,* that this insect is in some way connected with the etiology of the disease While it is difficult to alter our views to accept this agent in such an important rôle, it must be admitted that Clarke has collected epidemiologic and entomologic evidence that should arouse considerable interest

The etiologic theories for rheumatic fever and arthritis heretofore detailed form the basis for most of the studies which are being made at the present time to determine causation more definitely Though there is practically no doubt that arthritis may in some instances be due to causes wholly nonbacterial (such as hemophilic arthritis), there have been numerous reports of types of arthritis occurring in other diseases Certainly joint disorders are sometimes due to specific micro-organisms, and may be in some instances clinically indistinguishable from the types of arthritis the etiology of which is still subject to debate This fact has been discussed a number of times, e g , by Irons Schottmuller, Coates and Gordon, Stockman, Milne, Umber, Le Noir and Liege, and there has been a gradual splitting off of these specific arthritides from the types the etiology of which is not known That this process is not yet complete is evidenced by the continued reports of the specific nature of certain cases of arthritis

To discuss tuberculous arthritis, one of the earliest to be differentiated from other forms of joint involvement, is not the purpose of this paper Whether, however, typical tuberculous arthritis serves as the only relation between tuberculous infection and arthritic disorders has been questioned by several Menzer (*b*) believed that latent pulmonary tuberculosis is a frequent cause of arthritis and that hence general measures for the improvement of the patient would do much more for the disease than salicylate therapy Ascoli reported a case in which an "arthritis deformans" of the knee was evidently secondary to a tuberculous involvement Platt similarly stated that "in adolescence

and in adult life infective arthritis often simulated tuberculosis Operative exploration in knee joint conditions was often the most valuable diagnostic measure " Recently Wilkinson contended that many so-called cases of rheumatism are really caused by hidden foci of tuberculosis He did not state that tuberculosis is the exclusive cause of such chronic inflammatory states, but believed that the symptom-complex hitherto associated with "rheumatism" may be the effect of tuberculosis

The fact that infections with gonococci can cause arthritis of practically all types, both acute and chronic, is also too well known to discuss at length Nevertheless there has been considerable direct and indirect evidence of late to indicate that many cases of arthritis not commonly classed as gonorrheal are, from an etiologic standpoint, of this nature Thomas has discussed the clinical aspects of this condition and the difficulties in diagnosing the more chronic types after the acute initial infection has subsided Pepper reported on three cases of gonococcal arthritis associated with old rheumatic endocarditis He suggested that gonococcal focal infection may cause either a specific gonococcal arthritis or a nonspecific infectious arthritis and also that there is reason to believe that rheumatic infection prepares the soil not only for recurrences of rheumatic fever, but also for other types of arthritis, including gonococcal From the bacteriologic point of view, the finding of gonococci from the lymph glands in "chronic infectious arthritis" by Rosenow (*b*), Forkner, Poston, and Cecil, Nicholls and Stainsby should be viewed as significant in this connection It is undoubtedly true that a considerable percentage of at present undifferentiated cases of arthritis belong in the class of gonococcal infections An attempt should be made to define the differential features more accurately

Though syphilis as a cause of special forms of arthritis has long been recognized, e g, Charcot joint, syphilitic arthritis per se when recognized still ranks as a rare enough condition to warrant case reports Chesney, Kemp and Resnick reported two such cases characterized by subacute polyarthritis, enlarged tender lymph nodes and eosinophilia Triturated lymph glands from both patients produced orchitis in rabbits from which *Spirochaeta* was recovered Joint fluid from one patient produced similar orchitis in a rabbit, though no spirochetes were found in the joint fluids Arthritis deformans of heredosyphilitic origin has been reported numerous times, recently by Ricciardi Francisco also considered the importance of arthritis in congental syphilis, but stressed the point that in adults, especially, arthritis and syphilis occurring concurrently is not proof of the syphilitic nature of the arthritis, Stanojevic reported a case of bilateral syphilitic sacro-iliac arthritis with the symptoms of periostitis From the consideration of such case reports it becomes evident that differentiation of arthritis along this line has not progressed far

It does not seem necessary to prolong much further comment on the numerous reports of arthritis occurring in or probably due to specific infections with known organisms Holst, after reviewing the literature, described a spondylitis occurring in typhus fever which he believed was characteristic clinically and radiologically Spondylitis as the result of typhoid fever is well known (Haselhorst, Kramer), and Barker suggested a broader view of typhoid fever as possibly responsible for secondary metastatic arthritis Cases of arthritis due to paratyphoid infections have been reported by Madier and Ducroquet, Rowlands and Lewis Arthritis of various types apparently due to the pneumococcus have been described numerous times (Carleton, Milch and Lepidus, Thomson and Thomson, and others) Kauntze obtained favorable results in treating patients with "rheumatoid arthritis, chronic rheumatism and allied diseases" with "autogenous" vaccines from coliform bacilli isolated from the patient's stools and agglutinated by his serum Hill, Seidman, Stadnichenko and Ellis in 6 of 7 infections of the urinary tract with arthritis obtained pure cultures of the coli group from the urine Four of these were *Escherichia* and 2 *Aerobacter* Some relation between joint disorders and influenza has long been recognized and this has been recently discussed by Weil

Unusual organisms have been occasionally recovered from patients with arthritis Dick obtained *B mucosus* (Friedlander's bacillus) repeatedly from the tonsils of a patient with multiple deforming arthritis of seven years' duration Removal of the tonsils and the administration of autogenous vaccines produced marked clinical improvement This organism produced arthritis in rabbits and dogs Thjøtta and Gunderson in two blood cultures from a patient with "acute rheumatism with pleuritis, pericarditis and bronchitis" obtained a streptothrix The third blood culture was sterile Mutch and Mutch isolated *B fallax* from a joint removed surgically from a patient with chronic arthritis

Recently, occurrence of arthritis in undulant fever has come to be generally recognized Arthritis is apparently so usually a concomitant of this disease that it is mentioned in nearly all clinical discussions, Von Mueller, Baker and Bierring, among others, discuss the clinical characteristics in some detail Jensen speaks of a spondylitis from *B abortus* infection

COMMENT

In a large way, the problem of etiology of rheumatic fever and arthritis is one of the most important in medicine The amount of disability from the joint involvement, cardiac damage and perhaps other complications is almost beyond comprehension Add to that the suffering and the mental effect on the patient resulting from the usual hopeless outlook shared alike by medical men and the laity and one has a subject

deserving intensive study It is impossible to anticipate at what points the link in the chain of rheumatic disorders will be broken to allow more satisfactory treatment, but a determination of the etiologic factors at least offers the best avenue for the efforts of preventive medicine

There seems to be little doubt that rheumatic fever and some forms of arthritis are usually due to infections with micro-organisms That many different organisms can cause joint disorders in animals and in man seems also beyond the possibility of doubt More than that has not been absolutely established Rheumatic fever obviously offers the most favorable possibility for proving a specific etiologic agent, but it cannot be said that this has been done to complete satisfaction as yet It may then well be asked on what basis one may consider the etiology as proved Presumably, the answer to this question is in the satisfaction of Koch's postulates This in its turn involves preliminary questions about which there also should be general agreement The first of these is What is meant by rheumatic fever? Is this limited by the textbook picture of acute rheumatic fever in children? Is acute polyarthritis in adults with or without tonsillitis and carditis included? In what category are growing pains in children with demonstrable endocardial damage placed? Or can these questions be settled only on the basis of the isolation of a specific microbe? These and other questions have perhaps not received sufficient attention in the bacteriologic studies directed at rheumatic fever It is beyond the scope of this paper to attempt to answer these problems To go further From what tissues should the causative organisms be isolated? The clinical characteristics of the disease point to the joints, endocardium and tonsils with the question of the blood stream much in doubt Yet organisms of different kinds have been isolated from all of these sources and several others, and have in most instances been considered causative Other workers have failed to isolate organisms from these tissues, which they considered significant Hence, it is questionable whether the bacterium or bacteria responsible for rheumatic fever are present in all of these locations for more than brief periods of time In this connection, studies involving mechanisms such as those on allergy or toxin production, may prove of especial value Chances of contamination in tissue cultures are great, and the utmost care should be used in controlling technic It must be also borne in mind that growth of organisms on artificial mediums over even a short period of time may alter their biologic, as well as their invasive, qualities Finally, in considering reproduction of rheumatic fever, since this cannot be done in man (unless Birkhaug's experiment on himself points to a practicable way) the criteria constituting a satisfactory equivalent in lower animals should be agreed on It seems reasonable to believe that such agreement is most likely to be reached

when species of animals closely related to man are employed for this purpose

In forms of arthritis other than rheumatic fever, the problem seems of slightly different character It is apparent that many agents both bacterial and of other nature may produce changes in the joints which are often as yet clinically indistinguishable It is even possible that an organism also the specific cause of rheumatic fever may cause in adults, particularly, a form of arthritis which cannot be differentiated on clinical grounds from arthritis due to other etiologic agents At least there is considerable basis for a belief that though there may be a large group of arthritic disorders due to specific organism or a closely knit group of organisms (with the streptococci indicated especially), microbes of many different kinds with primary locations in many different parts of the body are responsible for a certain percentage of the cases It does not seem that this fact should prove too discouraging, since clinical and etiologic distinctions should offer considerably greater possibilities in prevention and treatment

BIBLIOGRAPHY

Achalme, P Examen bacteriologique d'un cas de rhumatisme articulaire aigu mort de rhumatisme cerebral, Compt rend Soc de biol **43** 651, 1891
Pathogenie du rhumatisme articulaire aigu, ibid **49** 276, 1897

Andrewes, C H, Derick, C L, and Swift, H F J Exper Med **44** 35, 1926
See also Derick

Apert Recherches bacteriologiques dans deux cas de choree avec endocardite, Compt rend Soc de biol **50** 128, 1898

Ascoli, M Tuberculous Arthritis Deformans, Policlinico **30** 441, 1923, abstr J A M A **81** 2067 (Dec 15) 1923

Baker, B M, Jr Undulant Fever Presenting the Clinical Syndrome of Intermittent Hydarthrosis, Arch Int Med **44** 128 (July) 1929

Barker, L F Chronic Infectious Arthritis, Internat Clin **35** 212, 1925

Barrow, J V, and Armstrong, E L The Etiology and Pathology of Chronic Deforming Arthritis, California & West Med **26** 323 1927

Beaton, R M, and Walker, E W A The Etiology of Acute Rheumatism and Allied Conditions, Brit M J **1** 237, 1903

Beattie, J M The Micrococcus Rheumaticus Its Cultural and Other Characters, Brit M J **2** 1510, 1904
A Contribution to the Bacteriology of Rheumatic Fever, ibid **2** 1781, 1906
Acute Rheumatism Caused by the "Diplococcus Rheumaticus," J Path & Bact **9** 272, 1904

Beattie, J M, and Yates, A G Bacteriological Examination of the Synovial Membrane from the Knee Joints in 88 Consecutive Postmortems, J Path & Bact **16** 404, 1911
The Bacteriology of Rheumatism—Further Evidence in Favour of the Causal Relationship of Streptococci, ibid **17** 538, 1913
The Streptococcus in Rheumatism, ibid **17** 416, 1912

Belk, W P, Jodzis, F J, and Fendrick, E The Lesions in Animals Inoculated with Streptococcus Cardio-Arthritidis, Arch Path **6** 812 (Nov) 1928

Bertrand, L Chronic Rheumatism—A Microbic Infection, Proceedings, Conference on Rheumatic Diseases, Bath, 1928, p 154

Bierring, W L Undulant Fever, J A M A **93** 897 (Sept 21) 1929

Billings, F Chronic Focal Infections and Their Etiologic Relations to Arthritis and Nephritis, Arch Int Med **9** 484 (April) 1912

Chronic Focal Infection as a Causative Factor in Chronic Arthritis, J A M A **61** 819 (Sept 13) 1913

Focal Infection, Lane Medical Lectures, New York, D Appleton & Company, 1916

Billings, F, Coleman, G H, and Hibbs, W G Chronic Infectious Arthritis, J A M A **78** 1097 (April 15) 1922

Birkhaug, K E (*a*) Rheumatic Fever, J Infect Dis **40** 549, 1927

(*b*) Rheumatic Fever Allergic Reactions with a Toxin-Producing Strain of Non-Methemoglobin-Forming Streptococcus Isolated from Rheumatic Fever, ibid **43** 280, 1928

(*c*) Rheumatic Fever, ibid **44** 363, 1929

Blaxall, F R Rheumatoid Arthritis Its Clinical History, Etiology and Pathology, Lancet **1** 1120, 1896

Bracht, E, and Wachter Beitrag zur Aetiologie und pathologischen Anatomie der Myocarditis rheumatica, Deutsche Arch f klin Med **96** 493, 1909

Bulloch, W Rheumatic Fever, in Albutt and Rolleston System of Medicine, New York, The Macmillan Company, 1906, vol 2, p 594

Burbank, R A Study of the Streptococcus in the Etiology of Arthritis, Bull New York Acad Med **5** 176, 1929

Burbank, R, and Hadjopoulos, L G Serologic Significance of Streptococci in Arthritis and Allied Conditions, J A M A **84** 637 (Feb 28) 1925

Byfield, A H The Etiology of Arthritis Deformans in Children, Am J Dis Child **19** 87 (Feb) 1920

Carleton, D Nontuberculous Spondylitis, New England J Med **200** 320, 1929

Cecil, R L, Nicholls, E E, and Stainsby, W J (*a*) The Bacteriology of the Blood and Joints in Chronic Infectious Arthritis, Arch Int Med **43** 571 (May) 1929

(*b*) Bacteriology of the Blood and Joints in Rheumatic Fever, J Exper Med **50** 617, 1929

Chesney, A M, Kemp, J E, and Resnick, W H Syphilitic Arthritis with Eosinophilia Recovery of T Pallidum from the Synovial Fluid, Bull Johns Hopkins Hosp **35** 235, 1924

Clarke, J T The Geographical and Climatic Distribution of Rheumatic Fever, M J & Rec **128** 457, 1928

Rheumatic Fever and Tonsillitis, Brit J Child Dis **26** 99, 1929

Clawson, B J (*a*) Studies on the Etiology of Acute Rheumatic Fever, J Infect Dis **36** 444, 1925

(*b*) The Aschoff Nodule, Arch Path **8** 664 (Oct) 1929

Coates, V, and Gordon, R G Differential Diagnosis of Rheumatoid Arthritis as a Clinical Entity, Brit M J **2** 561, 1923

Cole, R I Experimental Streptococcus Arthritis in Relation to the Etiology of Acute Articular Rheumatism, J Infec Dis **1** 714, 1904

Coombs, C F (*a*) Some Clinical Aspects of the Rheumatic Infection, Lancet **1** 565, 1904

(*b*) The Myocardial Lesions of the Rheumatic Infection, Brit M J **2** 1513, 1907

(*c*) The Histology of Rheumatic Endocarditis, Lancet **1** 1377, 1909

Coombs, C, Miller, R, and Kettle, E H The Histology of Experimental Rheumatism, Lancet **2** 1209, 1912

Crowe, H W Bacteriology and Surgery of Chronic Arthritis and Rheumatism, London and New York, Oxford University Press, 1927

Culver, H B A Study of the Bacteriology of Chronic Prostatitis and Spermatocystitis with Special Reference to Their Relationship to Arthritis, J A M A **66** 553 (Feb) 1916

Davis, D J (*a*) Bacteriological and Experimental Observations on Focal Infections, Arch Int Med **9** 505 (April) 1912

(*b*) Relation of Varieties of Streptococci with Special Reference to Experimental Arthritis, J A M A **58** 1283 (April 27) 1912

(*c*) Chronic Streptococcus Arthritis, ibid **61** 724 (Sept 6) 1913

(*d*) Interrelations in the Streptococcus Group, J Infect Dis **12** 386, 1913

Derick, C L, and Andrewes, C H The Skin Response of Rabbits to Non-Hemolytic Streptococci, Proc Soc Exper Biol & Med **23** 116, 1925-1926, J Exper Med **44** 55, 1926

Derick, C L Hitchcock, C H, and Swift, H F The Allergic Conception of Rheumatic Fever, Canad M A J **20** 349, 1929

Derick, C L, and Swift, H F Reactions of Rabbits to Non-Hemolytic Streptococci, J Exper Med **49** 615, 1929

See also Andrewes and Swift

Dick, G F Multiple Arthritis Due to a Friedlander Bacillus, J Infect Dis **14** 176, 1914

Dor, M L Nature infectieuse de certaines arthrites deformantes, Gaz med de Paris **8** 556, 1893

Elliott, G R The Present Status of Chronic Multiple Arthritis with Special Consideration of Infection as an Etiological Factor, M Rec **90** 529, 1916

Ely, L W (*a*) The Second Great Type of Chronic Arthritis, Arch Surg **1** 158 (July) 1920

(*b*) The Second Great Type of Chronic Arthritis, J A M A **81** 1762 (Nov 24) 1923

Ely, L W, Reed, A C, and Wyckoff, H A See Barrow

Epstein, E Z, and Kugel, M A The Significance of Postmortem Bacteriological Examination, J Infect Dis **44** 327, 1929

Faber, H K Experimental Arthritis in the Rabbit A Contribution to the Pathogeny of Arthritis in Rheumatic Fever, J Exper Med **22** 615, 1915

Fayerweather R Infectious Arthritis A Bacteriological Contribution to the Differentiation of the "Rheumatic Affections," Am J M Sc **130** 1051, 1905

Fisher, A G T Osteoarthritis, Lancet **2** 53, 1922

Forkner, C E Gonococci from Lymphoid Tissue in a Case of Chronic Infectious Arthritis, Bull Johns Hopkins Hosp **43** 257, 1928

Forkner, C E Shands, A R, and Poston, M A Synovial Fluid in Chronic Arthritis, Arch Int Med **42** 675 (Nov) 1928

Francisco, C B Syphilis as a Cause of Arthritis, J Missouri M A **26** 2, 1929

Franke, W Klinische Stellungnahme zur Frage der dentalen Fokalinfektion, Deutsche med Wchnschr **55** 1033, 1929

Freiberg, I A Allergy as a Factor in Production of Proliferative Arthritis, Arch Surg **18** 645 (Feb) 1929

Freund, R, and Berger, E Ueber Befunde von Streptokokken im Blute, Deutsche med Wchnschr **50** 625, 1924

Friedberger Ueber aseptisch erzeugte Gelenkschwellungen beim Kaninchen, Berl klin Wchnschr **50** 88, 1913

Frissell L F The Etiology of Acute Rheumatism, M Rec **69** 737, 1906

Gibson, A The Etiology of Rheumatoid Arthritis, J Bone & Joint Surg **10** 746, 1928

Goadby, K W The Association of Disease of the Mouth with Rheumatoid Arthritis and Certain Other Forms of Rheumatism, Lancet **1** 639, 1911

Green, F Serology in Arthritis, Canad M A J **17** 907, 1927

Gross, L, Loewe, L, and Eliasoph, B Attempts to Reproduce Rheumatic Fever in Animals, J Exper Med **50** 41, 1929

Haden, R L Dental Infection and Systemic Disease, Philadelphia, Lea and Febiger, 1928

Hadjopoulos, L G, and Burbank, R A Preliminary Study Bearing on the Specific Causative Factors of Multiple Infective Arthritis, J Bone & Joint Surg **9** 278, 1927

Hadley, P Microbic Dissociation, J Infect Dis **40** 1, 1927, also in Jordan, E O, and Falk, I S Newer Knowledge of Bacteriology and Immunology, Chicago, University of Chicago Press, 1928, p 84

Hanger, F M, Jr Allergic Reactions in Rabbits to Bacterial Antigens, Proc Soc Exper Biol & Med **25** 230 and 775, 1927-1928

Harding, A E B Arthritic Muscular Atrophy, J Path & Bact **28** 179, 1925

Harrison, W S On "Streptococcus Rheumaticus" and Rheumatic Fever, J Roy Army M Corps **20** 1, 1913

Hart, A P Results with Birkhaug's Rheumatic Toxin, Canad M A J **20** 159, 1929

Haselhorst, G Ueber Spondylitis typhosa, Beitr z klin Chir **138** 417, 1927

Hastings, T W Complement Fixation Tests in Chronic Infective Deforming Arthritis and Arthritis Deformans, J Exper Med **20** 52, 1914

Herry Contribution a l'etude du rhumatisme articulaire aigu Essai de pathogenie et de serotherapie, etude clinique, anatomique, et experimentale, Bull Acad roy de med de Belgique (ser 4) **28** 76, 1914

Hill, J H, Seidman, L R, Stadnichenko, A M S, and Ellis, M G A Study of Two Hundred Cultures of Gram-Negative Bacilli Isolated from Cases of Genito-Urinary Infection, J Bact **17** 205, 1929

Hitchcock, C H Studies on Indifferent Streptococci, J Exper Med **48** 393 and 403, 1928

Hitchcock, C H, and Swift, H F Studies in Indifferent Streptococci, ibid **49** 637, 1929

See also Derick and Swift

Holman, W L Focal Infection and "Elective Localization," Arch Path **5** 68 (Jan) 1928

Holst, L V Die Spondylitis nach Fleck- und Ruckfallfieber im Rontgenbilde, Ztschr f orthop Klin **46** 321, 1924-1925

Hunt, H F, Barrow, E, Thompson, L, and Waldron, G W Bacteriologic Study of 567 Postmortem Examinations, J Lab & Clin Med **14** 907, 1929

Hurst, A F Achlorhydria, Lancet **1** 111, 1923

Irons, E E The Bacteriology and Pathology of Arthritis, Illinois M J **19** 12, 1911

Irvine-Jones, E I M Skin Sensitivity of Rheumatic Subjects to Streptococcus Filtrates, Arch Int Med **42** 784 (Nov) 1928

Jackson, L Experimental Streptococcal Arthritis in Rabbits, J Infect Dis **12** 364, 1913

Jensen, J P Spondylitis e bacillo abortus, Hospitalstid **71** 637, 1928

Kaiser, A D Skin Reactions in Rheumatic Fever, J Infect Dis **42** 25, 1928

Kauntze, W H Infection with Coliform Bacilli as a Cause of Rheumatoid Arthritis and Chronic Rheumatism Its Diagnosis and Its Treatment by Autogenous Vaccines, J Hyg **23** 289, 1924-1925

Keating, P M Streptococcic Foci in Arthritis, South M J **21** 263, 1928

Kelly, T H The Results of Animal Inoculations with Material Obtained from the Tonsils in Cases of Acute Rheumatic Fever, Ohio State M J **14** 221, 1918

Key, J A Pathogenic Properties of Organisms Obtained from Joints in Chronic Arthritis, Proc Soc Exper Biol & Med **26** 863, 1929

Kinsella, R A, and Hagebusch, O F Studies of Experimental Arthritis, Proc Soc Exper Biol & Med **26** 642, 1929

Klinge, F Die Eiweissuberempfindlichkeit (Gewebsanaphylaxie) der Gelenke, Beitr z path Anat u z allg Path **83** 185, 1929

Kofoid, C A and Swezy, O The Amoeba as the Cause of the Second Great Type of Chronic Arthritis, California State J Med **20** 59, 1922

Kramer, P H Typhoidal Form of Acute Articular Rheumatism, nederl tijdschr v geneesk **73** 648, 1929

Kreidler, W A Biologic and Serologic Studies of Streptococcus Cardioarthritidis, J Infect Dis **43** 415, 1928

Lazarus-Barlow, P An Investigation Into the Cause of Rheumatic Fever in Children, J Hyg **28** 237, 1928

Le Noir, P, and Liege, R Contribution a l'etude des pseudo-rheumatismes infectieux primitifs, Ann de med **25** 140, 1929

Lewis, J T Arthritis Due to Paratyphoid B Bacillus Without General Symptoms, Brit M J **2** 1080, 1927

Lewis, M J, and Longcope W T Experimental Arthritis and Endocarditis Produced by a Streptococcus Isolated from the Blood of a Case of Rheumatism Endocarditis and Chorea, Am J M Sc **128** 601, 1904

Livingston, A The Experimental Production of Arthritis, Proc Roy Soc Med **15** 65 (odont), 1922

Loeb, L M The Bacteriology of Acute Rheumatic Fever, Arch Int Med **2** 266 (Oct) 1908

Loewe, E C (*a*) Pathogen Selective Cultures as an Aid to the Diagnosis of Infective Foci, Brit M J **2** 98, 1928

(*b*) Foci and Nature of Infection in 100 Cases of Rheumatic Conditions, ibid **2** 43, 1929

Lucas, A Untersuchungen uber die Rolle von Infekten bei rheumatischen Erkrankungen, Med Klin **28** 1689, 1927

Lynch, R Negative Blood Cultures in Acute Rheumatic Fever, Canad M A J **17** 1352, 1927

Mackenzie, G M, and Hanger, F M, Jr Allergic Reactions to Streptococcus Antigens, J Immunol **13** 41, 1927

Madier, J, and Ducroquet, R Osteo-arthrite de la hanche a la suite d'une fievre paratyphoide B, Bull Soc de pediat de Paris **26** 157 (March) 1928

McClenahan, W N, and Paul, J R A Review of the Pleural and Pulmonary Lesions in Twenty-Eight Fatal Cases of Active Rheumatic Fever, Arch Path **8** 595 (Oct) 1929

Meisser, J G, and Brock, S A Clinical and Experimental Study in Chronic Arthritis, Collected Papers Mayo Clin **15** 990, 1923

Menzer, A (*a*) Serumbehundlung bei akuten und chronischen Gelenkrheumatismus, Ztschr f klin Med **47** 109, 1902

(*b*) Rheumatismus und Tuberkulose, Berl klin Wchnschr **50-52** 2219, 1913

Milch, H, and Lepidus, P W Pneumococcic Spondylitis, J Bone & Joint Surg **11** 292, 1929

Miller, C P (a) Spontaneous Interstitial Myocarditis in Rabbits, J Exper Med **40** 543, 1924
(b) Attempts to Transmit Rheumatic Fever to Rabbits and Guinea-Pigs, ibid **40** 525, 1924
Milne, L S Chronic Arthritis, J A M A **62** 593 (Feb 21) 1914
Moench, L M The Relationship of Chronic Endocervicitis to Focal Infection with Special Reference to Chronic Arthritis, J Lab & Clin Med **9** 289, 1924
Moon, V H, and Edwards, S R Results of Blood Cultures in Rheumatoid Arthritis, J Infect Dis **21** 154 1917
Moorehead, T G A Note on Dysenteric Arthritis, Brit M J **1** 483, 1916
Mutch, N (a) Staphylococcal Infection of the Alimentary Tract as a Cause of Chronic Arthritis, Am Med **21** 373, 1915
(b) Arthritis and Infection of the Digestive Tract, M J & Rec **121** 625, 1925
Mutch, N, and Mutch, J B Fallax in Chronic Arthritis, Lancet **1** 1021, 1927
Nabarro, D, and MacDonald, R A Bacteriology of the Tonsils in Relation to Rheumatism in Children, Brit M J **2** 758, 1929
Nathan, P W Arthritis Deformans as an Infectious Disease, J M Research **36** 187, 1917
Nye, R N, and Seegal, D Non-Hemolytic Streptococci and Acute Rheumatic Fever, J Exper Med **49** 539, 1929
Pappenheimer, A M, and von Glahn, W C Lesions of the Aorta Associated with Acute Rheumatic Fever and with Chronic Cardiac Disease of Rheumatic Origin, J M Research **44** 489, 1924
Studies in the Pathology of Rheumatic Fever, Am J Path **3** 583, 1927
See also von Glahn
Pepper, C H P Diagnosis of Gonococcal Arthritis, Ann Int Med **3** 328, 1929
Philipp, C Zur Aetiologie des akuten Gelenkrheumatismus, Deutsches Arch f klin Med **76** 150, 1903
Platt, H Forms of Arthritis Simulating Tuberculosis, Lancet **1** 771, 1925
Polvogt, L M, and Crowe, S J Predominating Organisms Found in Cultures from Tonsils and Adenoids, J A M A **92** 962 (March 23) 1929
Poston, M A Gland Cultures in Infectious Arthritis, J A M A **93** 692 (Aug 31) 1929
Poynton, F J Discussion on the Etiology and Treatment of Osteo-Arthritis and Rheumatoid Arthritis, Proc Roy Soc Med **17** 1, 1923
Poynton, F J, and Paine, A Researches on Rheumatism, New York, The Macmillan Company, 1914
Precht, E Fokalinfektion, Deutsche med Wchnschr **55** 1035, 1929
Price, W A Dental Infections and Denegerative Diseases, Cleveland, Penton Publishing Press, 1923
Quigley, W J Observations on the Bacteriology of Chorea, J Infect Dis **22** 198, 1918
Rhoads, P S, and Dick, G F Efficacy of Tonsillectomy for the Removal of Focal Infection, J A M A **91** 1149 (Oct 20) 1928
Ricciardi, L Chronic Arthritis Deformans of Heredosyphilitic Origin, Pediatria **36** 395, 1928
Richards, J H Bacteriologic Studies in Chronic Arthritis and Chorea, J Bact **5** 511, 1920
Rosenow, E C (a) Transmutations Within the Streptococcus-Pneumococcus Group, J Infect Dis **14** 1, 1914
(b) Etiology of Arthritis Deformans J A M A **62** 1146 (April 11) 1914

(c) The Etiology of Acute Rheumatism, Articular and Muscular, J Infect Dis **14** 61, 1914

(d) Experimental Observations on the Etiology of Chorea Am J Dis Child, **26** 223 (Sept) 1923

Rosenow, E C, and Ashby W Focal Infection and Elective Localization in the Etiology of Myositis, Arch Int Med **28** 274 (Sept) 1921

Rowlands, M J Rheumatoid Arthritis Is It a Deficiency Disease? Proc Roy Soc Med **21** 1711, 1926-1927

Rothschild, M A and Thalhimer, W Experimental Arthritis in the Rabbit Produced with Streptococcus Mitis, J Exper Med **19** 444, 1914

Schloss, O M and Foster, N B Experimental Streptococcic Arthritis in Monkeys J M Research **29** 9, 1913

Schottmuller Ueber akute Gelenkentzundung, ihre Aetiologie und Behandlung, Munchen med Wchnschr **76** 445 1929

Schuller, M Untersuchungen uber die Aetiologie der sogenannten chronisch-rheumatischen Gelenkentzundungen, Berl klin Wchnschr **30** 865, 1893

Sekiguchi, S, and Irons, E E Chronic Arthritis in Swine, J Infect Dis **21** 526, 1917

Shaw W V Acute Rheumatic Fever and Its Etiology, J Path & Bact **9** 158 1904

Small J C (a) The Bacterium Causing Rheumatic Fever and a Preliminary Account of the Therapeutic Action of Its Specific Serum, Am J M Sc **173** 101, 1927

(b) Rheumatic Fever, Ann Int Med **1** 1004, 1928

(c) Role of Streptococci in Rheumatic Diseases, J Lab & Clin Med **14** 1144, 1929

Solis-Cohen, M Visceral Disease, J A M A **83** 824 (Sept 13) 1924

Accentuating Pathogenic Organisms in Culture by Utilizing the Inhibitory Influence of Whole Blood, Brit J Exper Path **8** 149, 1927

Stanojevic B Ueber einen Fall von Arthritis sacroiliaca syphilitica bilateralis, Med Klin **25** 348, 1929

Steinfield E, and Jacobs, M S A Study of Toxic Filtrates of Anhemolytic Streptococci, Recovered from Patients with Rheumatic Fever, J Lab & Clin Med **12** 850, 1927

Stockman, R Chronic Muscular Rheumatism and Panniculitis, Brit M J **1** 293, 1928

Suranyi L, and Forro, E Streptokokken im Blute mit besonderer Berucksichtigung der rheumatischen Gelenkentzundung, Klin Wchnschr **7** 453, 1928

Swift H F The Pathogenesis of Rheumatic Fever, J Exper Med **39** 497, 1924

Rheumatic Fever, J A M A **92** 2071 (June 22) 1929

Swift H F, and Boots, R H The Question of Sensitization of Joints with Non-Hemolytic Streptococci J Exper Med **38** 573, 1923

Swift, H F, Hitchcock, C H, and Derick, C L General Tuberculin-Like Reaction in Rheumatic Fever Patients Following Intravenous Injection of Streptococcus Vaccines or Nucleoproteins, Proc Soc Exper Biol & Med **25** 312, 1927-1928

Swift, H F, Derick, C L, and Hitchcock, C H Bacterial Allergy (Hyperergy) to Non-Hemolytic Streptococci, J A M A **90** 906 (March 24) 1928

Swift H F, and Derick, C L Reactions of Rabbits to Non-Hemolytic Streptococci J Exper Med **49** 883, 1929

See also Andrewes, Derick and Hitchcock

Swift, H F, and Kinsella, R A Bacteriologic Studies in Acute Rheumatic Fever, Arch Int Med **19** 381 (March) 1917

Notes and News

W K Kellogg Foundation for Cancer Research—This foundation has been created by W K Kellogg of Battle Creek, Mich, and Pomona, Calif The foundation will collaborate with the College of Medical Evangelists in cancer and other research work The sum of approximately $100,000 will be available for the first year, and further provision will be made as the work goes forward

Josiah Macy Junior Foundation—This foundation has been established through a gift of $5,000,000 by Mrs Walter Graeme Ladd, and Ludwig Kast, professor of clinical medicine in the New York Post-Graduate Medical School, has been elected president The purpose of the foundation is indicated by the following statement in a letter from Mrs Ladd "It is my desire that the foundation in the use of this gift should concentrate on a few problems rather than support many undertakings, and that it should primarily devote its interest to fundamental aspects of health, of sickness and of methods for the relief of suffering To these ends the foundation might give preference in the use of this fund to integrating functions in medical sciences and medical education, for which there seems to be particular need in our age of specialization and technical complexities"

National Institute of Health—Congress has created a new institution by this name to take the place of the Hygienic Laboratory of the U S Public Health Service An appropriation of $750,000 has been made for new building projects, and the government has been authorized to accept donations by private persons toward the further development of the institute Fellowships are to be provided for individual investigators who may wish to work in the new institute without permanent appointment in the Public Health Service

John Phillips Memorial Prize—The American College of Physicians announces the John Phillips Memorial Prize of $1,500 for meritorious work in internal medicine or contributory sciences The work must have been done in whole or in part in the United States or Canada The thesis must be in the English language, and typewritten or printed copies in triplicate must be mailed to E R Loveland, executive secretary, 133 South 36th Street, Philadelphia, on or before Aug 31, 1930

Grunow Foundation—It is reported that William C Grunow, Chicago, has donated $1,000,000 to create the Lois Grunow Memorial Foundation for the furtherance of medical science, and that it is planned to establish laboratories at Phoenix, Ariz

Medical Fellowship Board of National Research Council—The next meeting of this board will be held on Oct 14, 1930 Applications for consideration at this meeting must be in the hands of the secretary of the board (B and 21st Streets, Washington, D C) before September first next

Charles Nicolle, director of the Pasteur Institute of Tunis, and well known for his work on typhus fever for which he was awarded a Nobel Prize in 1928, has been elected a member of the French Academy of Sciences

At the recent meeting in Atlantic City of the Association of American Physicians, the Kober Medal was awarded to James B Herrick, Chicago, for his investigations in clinical medicine

George R Minot, Boston, has been awarded a gold medal by the National Institute of Social Sciences, New York

The Trudeau Medal of the National Tuberculosis Association has been awarded to Henry Sewall, Denver, in recognition of his work on tuberculosis

H J B Fry, pathologist to the Research Institute, Cancer Hospital, London, died on May 5 1930, from streptococcal infection contracted while making a postmortem examination

Abstracts from Current Literature

Experimental Pathology and Pathologic Physiology

EXPERIMENTAL OBSTRUCTIVE CIRRHOSIS H E MACMAHON, JOHN S LAWRENCE and S J MADDOCK, Am J Path **5** 631, 1929

Obstructive cirrhosis may be defined as a characteristic form of cirrhosis uniformly limited to all the portal areas throughout the liver It is caused by an obstruction to the outflow of bile In the early stages, bile stasis, necrosis and regeneration of individual liver cells, edema and infiltration of the portal areas are the most prominent features Later there is an apparent increase in the number of bile ducts, the portal connective tissue is increased and with enlargement of the portal areas the liver becomes divided into small, separate and distinct lobules In the guinea-pig and rabbit, large and small areas of necrosis are early and constant observations Evidence is presented to show that the proliferation of bile duct epithelium results merely in an apparent increase in the number of bile ducts in the portal area and not in an absolute increase as has been described previously The proliferation of fibroblasts in the portal areas is interpreted on a mechanical rather than a toxic basis The origin of the areas of necrosis is discussed, and the opinion is expressed that they are simply areas of infarction Their relative frequency in lower mammals may be explained on an anatomic and physiologic basis

AUTHORS' SUMMARY

THE RATE OF GLYCOLYSIS IN ERYTHREMIA (POLYCYTHEMIA VERA) J E COOK and MICHAEL SOMOGYI, Arch Int Med **44** 813, 1929

The blood of patients with erythremia shows a greatly increased rate of glycolysis This increased rate is independent of the red cell count as influenced by phenylhydrazine, and shows no direct relation to the proportion of young red cells, when the reticulated count is used as an index of such cells The increased rate of glycolysis in the usual case of erythremia is not dependent on the increased white count since the increased rate is also present with a low white cell count

AUTHORS' SUMMARY

THE TREATMENT OF PNEUMONIA BY INHALATION OF CARBON DIOXIDE YANDELL HENDERSON, HOWARD W HAGGARD, POL N CORYLLOS and GEORGE L BIRNBAUM, Arch Int Med **45** 72, 1930

As the background for this study, the following facts are cited If the lungs are not fully distended soon after birth, pneumonia is likely to develop After surgical operations, massive, lobar or lobular atelectasis of the lung is a rather frequent occurrence, and is the condition from which postoperative pneumonia develops This atelectasis or, better, apneumatosis is prevented and relieved, and the risk of pneumonia is eliminated, by the inhalation of carbon dioxide The inhalation of 5 per cent carbon dioxide in oxygen, which is now the standard treatment for carbon monoxide asphyxia, is also an effective preventive of post-asphyxial pneumonia In pneumonia it is the blocking of the lung airways, bronchi or bronchioli, by plugs of thick and sticky secretion which is the critical morbidic factor producing atelectasis and the conditions characteristic of an undrained infection The experiments reported demonstrate these facts Atelectasis that is induced experimentally in dogs by blocking a bronchus is quickly cleared up and the lung is redistended by the deep breathing induced by inhalation of carbon dioxide in proper dilution Pneumonia that is induced in dogs by insufflation of a virulent culture of pneumococci is generally overcome, the lung is redistended and the animal is restored to health by inhalation of carbon dioxide sufficient to cause

deep breathing and continued until the pneumonic area is cleared Success with this therapy for the relief of pneumonia in patients depends on administering the inhalation as early as possible If medical pneumonia is thus treated early enough, it appears probable that the results may be as effective as those already attained in postoperative and postasphyxial pneumonia

AUTHORS' SUMMARY

THE EFFECT OF LESSENED RESPIRATORY RESERVE ON THE BLOOD AND ON THE CIRCULATION WILLIS S LEMON, Arch Int Med **45** 115, 1930

In this study of the respiratory reserve, the muscles ordinarily responsible for the production of inspiration and expiration have been rendered functionless in whole or in part by evulsion of their motor nerve trunks All of the several functions of the diaphragm have been interfered with so that a state characteristic of a mammal has been changed, and the final state is one that, in respect to the diaphragm, virtually is characteristic more of birds than of mammals Vital capacity has been lessened, but never beyond the point where it failed to be equivalent to tidal air The ventilation in liters of air breathed each minute reached a high normal amount but was not distinctly abnormal at any time The hemoglobin decreased from high to low normal percentages, but the amount of hemoglobin for each hundred cubic centimeters of blood was within normal limits The hematocrit percentages varied slightly but were never abnormal The arterial and the venous oxygen content and the oxygen of the blood were essentially normal However, the oxygen saturation of both arterial and venous blood was lowered The number of erythrocytes failed to indicate either temporary or permanent erythrocytosis such as might have been anticipated had respiratory competence been destroyed

The heart has remained normal functionally and has not shown evidence of hypertrophy, and the electrocardiogram cannot be interpreted as evidence to indicate any definite failure of the right ventricle The experiment illustrates the degree to which muscular dysfunction may be carried before respiratory incompetence develops in an animal that has a normal heart and lungs It seems to confirm the independence of two fundamental functions having interrelated duties, great loss of reserve in one is required before demonstrable evidence of cooperative support is provided by the other

AUTHOR'S SUMMARY

THE PERIPHERAL SURFACE TEMPERATURE IN ARTHRITIS LILLIE M WRIGHT and RALPH PEMBERTON, Arch Int Med **45** 147, 1930

The observations recorded reveal that, under adequately controlled conditions of study, 75 per cent of arthritic subjects maintain at the periphery (the base of the nail), a temperature lower than that of normal persons under comparable circumstances They also show that under conditions of exposure to cold, the temperature of the arthritic subject at the periphery drops less than does that of normal subjects, partly, but not wholly, because of starting at a lower level The return of the peripheral temperature of the arthritic subject to the precold room level appears to be relatively slower than that of normal subjects It is difficult to explain these differences between arthritic and normal subjects on a basis other than that of diminution in, or at least disturbance of, the capillary blood flow These observations, further, throw light on the mechanism operative in the exacerbations experienced by arthritic subjects during fluctuations in the weather They imply that the capillary bed and presumably its control by the vasomotor system are less labile in respect to adaptations demanded of it by changes in the environment Inadequacy of response of this nature doubtless expresses itself in terms of further disturbances in the physiology of the part concerned In the already handicapped tissues of the arthritic subject, this may mean added dysfunction and pain Finally, these observations lend further support to the evidence already advanced that an important part of the phenomena of arthritis and the rheumatoid syndrome is referable to disturbances in the peripheral blood flow

AUTHORS' SUMMARY

DISTRIBUTION OF THE BLOOD IN SHOCK A BLALOCK and H BRADBURN, Arch Surg **20** 26, 1930

In a series of experiments designed to determine the effects of hemorrhage, injection of histamine, trauma to the intestines, trauma to the brain and trauma to muscular tissue on the oxygen content of the blood, the authors find that after trauma to the intestines or to an extremity, the blood from the portal vein and from the femoral vein each has a higher oxygen content than blood taken from the jugular vessel or renal vein, and the vein from the extremity opposite that which was damaged The control experiments demonstrated that the oxygen content of the renal vein is higher than that from the right side of the heart or from the portal vein Both of the latter were of about the same concentration The blood from the femoral vein was slightly lower than that from the heart, and that from the jugular vein was slightly higher After hemorrhage and after the injection of histamine, and after traumatizing the brain, the relative values of the oxygen content of the blood taken from these various vessels was the same as in the control experiments The authors feel that these experiments contradict the theory that the condition of shock is due to a reduction of the oxygen supply and are evidence against the action of a histamine-like substance that produces a general bodily effect The experiments were all done on dogs under barbital anesthesia, with blood pressure control The interesting data to be noted in their charts are the averages of the determinations After hemorrhage, the average oxygen content of all of the blood vessels was considerably lower than that of the control After the injection of histamine it was only slightly lower, and still somewhat lower after trauma of the brain, and after trauma of the leg, so that while the relative values show very little effect, it would seem that further work would have to be done on the effect of the total reduction of the volumes of oxygen circulating in the blood

N ENZER

ADIPOSOGENITAL DYSTROPHY WITH RETINITIS, MENTAL DEFECT AND POLYDACTYLISM (LAURENCE-MOON-BIEDL SYNDROME) H LISSER, Endocrinology **13** 533, 1930

An instance of this rare condition is described clinically in a girl 8 years old

THE EFFECT OF AN EXCLUSIVE MEAT DIET LASTING ONE YEAR ON THE CARBOHYDRATE TOLERANCE OF TWO NORMAL MEN E TOLSTOI, J Biol Chem **83** 747, 1929

The mechanism for the utilization of carbohydrate may require daily stimulation for normal function Two men, maintained for a period of one year on a carbohydrate-free diet, manifested a definite diminution in their tolerance for dextrose, which disappeared after the induction of a more normal diet

ARTHUR LOCKE

COLLOIDS AS REGULATORS OF THE DIVISION ENERGY OF CELLS G L ROHDENBURG J Cancer Research **13** 242, 1929

Colloids of various kinds (aqueous suspensions of lecithin, cholesterol, egg albumin and gelatin) inhibit the division energy of paramoecia to a varying degree when added to hay infusion

B M FRIED

IS THE LOCAL VASODILATATION AFTER DIFFERENT TISSUE INJURIES REFERABLE TO A SINGLE CAUSE? PEYTON ROUS and H P GILDING, J Exper Med **51** 27, 1930

Experiment shows that the vascular contraction responsible for Bier's spotting prevails over the local vasodilatation due to mechanical injury of the skin, and

causes the local reddening to blanch It is without effect, however on the local vasodilatation caused by histamine pricked into the skin The results raise doubts concerning the validity of the hypothesis referring all local vasodilatations to the action of a single chemical substance or set of substances ("H substance") liberated within the tissue

AUTHORS' SUMMARY

THE EFFECT OF UNILATERAL NEPHRECTOMY ON THE SENILE ATROPHY OF THE KIDNEY IN THE WHITE RAT ROBERT A MOORE and LOUIS M HELLMAN, J Exper Med **51** 51, 1930

In senility in the white rat there is a decrease in the total number of glomerular units The decrease in glomerular units is associated with an increase in the average diameter and a greater variation in size of the remaining glomeruli Unilateral nephrectomy during adult life has no effect on these senile changes

AUTHORS SUMMARY

A COMPARISON OF THE METHOD OF EXCRETION OF NEUTRAL RED AND PHENOL RED BY THE MAMMALIAN KIDNEY EATON MACKAY and JEAN OLIVER, J Exper Med **51** 161, 1930

The manner of excretion of phenol red and urea by the frog's kidney differs from that of neutral red The elimination of the former is by the glomeruli and that of the latter by the tubules There is a similar difference in the manner of excretion of these substances by the mammalian kidney It is inferred that this is due to a similar difference in the method of elimination—that in mammals, too phenol red is eliminated chiefly through the glomeruli and neutral red through the tubules

AUTHORS' SUMMARY

EXPERIMENTS RELATING TO A VARIETY OF RAYNAUD'S DISEASE THOMAS LEWIS, Heart **15** 7, 1929

The type of Raynaud's disease described is that in which the digits become periodically pale or cyanotic and, after several or many winters of repeated attacks terminal portions of the digits may be lost by a process of slow dry gangrene In mild cases recovery may be complete, while in more severe ones the circulation is persistently reduced to a low point at ordinary room temperatures The fingers remain at the temperature of the surrounding air under all ordinary conditions The immediate cause of the defective circulation is shown to be spasm of the digital arteries, the venous and capillary vessels not being involved The spasm is profoundly influenced by temperature, in response to which the vessels behave abnormally The abnormal element is apparently due to a peculiar condition of the vessel wall locally, it is not the result of a reflex through the vasomotor nerves

PEARL ZEEK

MEASURE OF EXPERIMENTAL PULMONARY COLLAPSE L BLAVIER Arch internat de med exper **5** 269, 1929

The effects of a phrenicotomy on the pleural cavity of the same and opposite sides were studied in animals In these experiments, thin rubber balloons were placed in the pleural cavities at different levels and each one was connected to a water manometer Readings were taken before and after phrenicotomy It was found that section of the phrenic nerve leads to a total diminution of variations of pressure in the pleural cavity The diminution is most marked at the same apex, a little less marked at the same base and opposite apex and scarcely noticeable at the opposite base It is suggested that the results of the phrenicotomy may extend to the opposite side through inflexion of the mediastinum

J N PATTERSON

THE REACTIONS OF LEUKOCYTES IN THE EYE W JAHNKE, Arch f Ophth **123** 70, 1929

Experiments on medium-sized dogs were made to study the leukocyte reaction in the eye to parenteral stimuli as compared with that in the peripheral blood These reactions were always analogous and different from the reactions in the visceral region The blood vessels of the eye undergo a change in tonus after the administration of atropine, pilocarpine, epinephrine and cocaine, being constricted after the use of cocaine and dilated after the use of pilocarpine But the leukocyte count in the eye is not affected by these drugs, whether constricted or dilated vessels result from their administration, and still corresponds to that in the skin Such pharmacodynamic drugs affect the physiologic relation between caliber of vessel and leukocytosis, as occurs in physiologic reactions, for instance, in active hyperemia Active hyperemia induced by the local application of heat produces leukocytosis on the one hand and a dilatation of the vessels on the other The latter causes an increased passage of blood, in contrast to the leukocytosis that results from the parenteral introduction of protein which shows relatively low leukocyte values The injection of milk did not disturb the equilibrium of leukocytes in the eye and the skin

CHARLES WEISS

TRANSPLANTATION OF DRIED OVARY ALEXANDER LIPSCHUTZ, Virchows Arch f path Anat **272** 245, 1929

Fresh ovary can be transplanted into the kidney of the guinea-pig with from 80 to 100 per cent positive results Castrated males are used They show swelling of the mammary glands after two weeks generally In two out of eight experiments with partly dried ovary swelling of the breast took place, with secretion of milk in one This ovary had lost 56 per cent of its weight (67 per cent of its water content) by the drying process In five experiments with ovaries from newborn or very young guinea-pigs, three were positive (loss of weight 52, 56 and 56 per cent) The effect on the nipples was visible only after several weeks This long incubation period proves that hormones are formed in the transplanted dried ovary If the drying is made more complete, the effect does not take place Even after little drying the primordial follicles shrink and their nuclei become pyknotic It is doubtful whether such damaged follicles become active again or if the hormonic effect comes from a few primordial follicles that have escaped the injuries of drying

ALFRED PLAUT

EXPERIMENTAL TRANSPLANTATION OF UTERINE MUCOSA H O NEUMANN, Virchows Arch f path Anat **272** 265, 1929

Endometrium of the rabbit transplanted into the peritoneum of the same animal or an animal from the same litter forms cysts when ovarian hormones are present When castration has been done a few weeks before operation, no cysts are formed and the transplants are resorbed Transplantation into males is unsuccessful Such experiments cannot be used as proof for Sampson's theory

ALFRED PLAUT

THYROID GLAND AND THYMUS GLAND IN EXPERIMENTAL HYPERTHYROIDISM E KLIWANSKAJA-KROLL, Virchows Arch f path Anat **272** 430, 1929

Using Hammar's quantitative method, the author has found a definite hypertrophy of the thymus gland in hyperthyroidism of white rats The animals were fed with dry thyroid gland The cortex hypertrophies more than the marrow, the Hassal bodies increase in number As early as ten days after the first thyroid feeding, the increase of thymus substance is noticeable The normal changes of thymus, which go parallel with age, remain

ALFRED PLAUT

Pathologic Anatomy

TUMORS OF THE BRAIN AMONG FILIPINOS C REYES, Arch Neurol & Psychiat **22** 1217, 1929

Of 13,168 autopsies performed at the city morgue of Manila, P I, from Aug 1, 1907, to Dec 31, 1927, the brains were examined in 4,602 (3,081 from males and 1,521 from females) Sixteen tumors were found in the males (0 52 per cent) and twelve in the females (0 79 per cent), a total of twenty-eight tumors, or 0 61 per cent The presence of tumor was diagnosed or suspected in four, or 18 per cent, of the patients, and in 64 per cent some cerebral symptoms were present which were diagnosed as tuberculous meningitis, cerebral hemorrhage, cerebral embolism, meningism, meningo-encephalitis and in two cases uremia Modern exploratory methods of diagnosis (ventriculopneumography or even the systematic taking of roentgenograms) were not used Primary intracranial tumors were found to be more frequent during the second and third decades among females, and during the fourth decade among males, they were generally more frequent among females Sixty-one per cent were supratentorial, 32 per cent were pituitary and 7 per cent were infratentorial Forty-seven per cent were gliomas and 33 per cent endotheliomas Twenty-three per cent of patients with available histories showed no evidence of intracranial tumor and died of acute conditions, the discovery of the tumors having been accidental and unexpected

G B HASSIN

THE CELLS IN THE EXUDATE OF LEPTOMENINGITIS THEODORE T STONE, Arch Neurol & Psychiat **23** 106, 1930

Stone studied twelve cases of meningitis (purulent, tuberculous, cerebrospinal and syphilitic) to ascertain the origin of some of the meningeal cellular elements, especially the macrophages, in early cases of leptomeningitis The meninges from the convexity of the brain, from its base and from the pial septum were utilized after the tissues had been fixed in 10 per cent commercial formaldehyde Various nuclear staining methods and, in addition, osmic acid and silver nitrate were used Especial attention was paid in these studies to the condition of the pia and the arachnoid In epidemic meningococcus and septic types of meningitis, the cells of the arachnoid participate in the formation of macrophages, none was seen in the tuberculous and syphilitic forms The arachnoid cells become large, the nucleus becomes eccentric and the cells become detached and engulf various debris of cell bodies, fat globules, micro-organisms, etc

G B HASSIN

PARAPLEGIA IN FLEXION WITH SUBACUTE, COMBINED DEGENERATION OF THE CORD GEORGE W HALL and EDWIN F HIRSCH, Arch Neurol & Psychiat **23** 257, 1930

Paraplegia in flexion has been described in a number of lesions of the spinal cord (tumors, Pott's disease, multiple sclerosis) and the brain In the case of Hall and Hirsch the paraplegia was due to subacute, combined degeneration of the cord, it was the second case to be recorded in the literature (the first was reported by H de Jong in *Acta psychiat de neurol* **2** 105, 1927) The patient, a woman, aged 51, showed the first sign (paresthesia) of involvement of the cord one year prior to her admission to the hospital The paresthesia grew worse, and after a lumbar puncture a paraplegia in flexion of the lower extremities set in The laboratory examination made at this time revealed a blood picture typical of pernicious anemia, with an absence of free hydrochloric acid and a total acidity of 60 degrees When the patient was examined after the onset of the paraplegia, she exhibited lively tendon reflexes, with a positive Babinski and similar signs bilaterally, a diminution of epicritic sensibility especially over the lower extremities, where the sense of position was lost, and retention of urine The serologic tests

gave negative results Six days later, incontinence of the bowels and bladder and severe pains in the legs developed, which steadily grew worse The patient developed fever, became delirious and died (six weeks after she had entered the hospital)

Necropsy revealed hypostatic pneumonia, slight bronchopneumonia and practically no gross changes in the brain or the spinal cord Microscopic examination of the various portions of the brain (stained with hematoxylin and eosin and phosphotungstic acid-hematoxylin, the peduncles were stained with Pal-Weigert method) did not show changes, while that of the spinal cord (the additional staining method used here was that of Bielschowsky) showed degeneration of various tracts in the posterior and lateral columns, such as is commonly described in subacute combined degeneration of the cord Numerous vacuolated "foam' cells (gitter cells) were aggregated around the capillaries and small blood vessels The anterior columns showed but slight degeneration of the nerve fibers

G B Hassin

Myasthenia Gravis with Status Lymphaticus and Multiple Thymic Granulomas Nicholas M Alter and Michael Osnato, Arch Neurol & Psychiat **23** 345, 1930

Alter and Osnato s case of myasthenia gravis was associated with status lymphaticus A careful pathologic study revealed no changes in the central or peripheral nervous system, but these were abundantly present in the striated muscles The muscle fibers were surrounded by "lymphoid infiltrations", many of the fibers were atrophied, showed striation and stained badly A conspicuous feature was the involvement of the thymus, in which two nodules were present and which showed signs of an extinct and active inflammation This resulted in involutional fibrosis The left lobe of the thyroid, which was enlarged and inflamed, contained a large parathyroid body The lymph nodes, the heart and the aorta were small There was hypoplasia of the ovaries and of the chromaffin substance of the suprarenals, with atrophy and fibrosis of the hypophysis There is strong evidence, according to the authors, that the mediastinal nodules may be responsible for the widespread distribution of lymphoid tissue (in the muscles) Early removal of such nodules, which are usually single, may prevent further absorption

G B Hassin

Primary Intramuscular Hemangioma of Striated Muscle J S Davis and E A Kitlowski, Arch Surg **20** 39, 1930

The authors add 11 cases of this tumor, and tabulate 212 cases reported in the literature They give an extensive clinical review and a discussion of the etiology, pathology, differential diagnosis and treatment Analysis of the 212 cases shows that the tumor is more frequent in the muscles of the extremities and that the tumor may present symptoms in the first and second decades, but may not enlarge for many years However, the analysis shows that the tumor is much more prominent in early life, chiefly occurring before the age of 20 It is equally common in both sexes Trauma does not seem to be an etiologic factor The tumors may become very large, since they invade the surrounding muscle and their early excision is the treatment of choice

N Enzer

The Pathogenesis of Glomerular Nephritis Warfield T Longcope, Bull Johns Hopkins Hosp **45** 335, 1929

In conclusion, then, one may summarize the information that can be obtained about primary glomerular nephritis as follows The disease occurs in two forms —the focal form and the diffuse form The focal form occurs during acute infections, and in the embolic type is usually ascribed to the deposition of bacteria

in the capillary loops of the glomeruli, where they lead to a necrosis, or to an inflammatory reaction The diffuse form follows acute infection, proved to be due in such a large proportion of instances to hemolytic streptococci, that for the present it is justifiable to consider at least one variety of acute glomerular nephritis as a manifestation of streptococcic infection In view of the great frequency of acute streptococcic infection, it must be considered as a rare manifestation It cannot be proved that acute glomerular nephritis depends on infection by a particular form of streptococcus, or on the invasion of the blood or the involvement of the kidney by streptococci There is some evidence, however, which indicates that patients suffering from acute nephritis are abnormally susceptible to the products of the growth of hemolytic streptococci and it seems possible that some altered reaction of the tissue, such as occurs in allergy, or some unusual antibody response to the infection is the determining factor in the development of acute glomerular nephritis in individual cases Permanent recovery is apparently more common in children than in adults We have no observations to explain the difference In a small number of adults we have found that recovery has followed elimination of the infection and the infecting organism, while progression of the disease has been coincidental with the persistence or the recurrence of hemolytic streptococcus infections It further appears evident that there are instances of Bright's disease that run their entire course as progressive or recurrent diffuse inflammatory glomerulitis, without involvement of the renal arteries or arterioles, and with changes in the renal tubules that may be regarded as secondary to the glomerular lesion and to the diffuse inflammatory reaction of the interstitial tissue As a working hypothesis, therefore, we would suggest that it may be possible to differentiate, as one form of Bright's disease, a primary and specific glomerular nephritis which is to be interpreted probably as a manifestation of streptococcus infections in persons who may be allergic to the streptococcus or its products of growth, or who possess some other peculiar form of tissue response to a local streptococcic infection

AUTHOR'S SUMMARY

PARATHYREOPRIAL TETANY LASTING ONE YEAR, NECROPSY H LISSER and H C SHEPARDSON, Endocrinology **13** 427, 1929

On removal of a goiter, tetany developed The patient was a woman, aged 30 Under treatment with parathyroid extract, which gradually lost its effect, life was maintained for one year when death occurred from acute sepsis Three parathyroid bodies were found in the goiter after its removal, and autopsy failed to disclose any parathyroid tissue There was no evidence of secondary disturbances in other ductless glands

CALCIFICATION IN PITUITARY ADENOMAS E M DLERY, Endocrinology **13** 455, 1929

In roentgenograms of nineteen adenomas of all types, areas of calcification were indicated by shadows within the growth, but calcification was not detected at necropsy or in microscopic sections of bits of tissue No opportunity was given to examine the entire growth for calcification in any of these cases In an instance studied since the report went to press, calcification was found on microscopic examination

HYPERPLASIA OF THE FEMALE GENITAL TRACT IN ACROMEGALY H M TEEL, Endocrinology **13** 521, 1929

In a woman, aged 49, with advancing acromegaly for seven years, the entire genital tract was markedly hyperplastic, especially the uterus It is assumed that this overgrowth was the effect of an eosinophilic pituitary adenoma and consequently in nature was similar to the genital hyperplasia inducible in dogs by alkaline extracts of the anterior lobe of the hypophysis

PITUITARY ADENOMA WITH GYNECOMASTIA R C MOEHLIG, Endocrinology **13** 529, 1929

The patient was 52 years of age Impotence, feminine distribution of pubic hair and gynecomastia gradually developed with evidences of a large pituitary growth which post mortem was found to be a chromophobe adenoma

PRESSURE ATROPHY OF THE BRAIN TEMPLE FAY, J A M A **94** 245, 1930

By encephalography it has been determined that an extensive atrophy of the brain may follow relatively slight injury The atrophy affects preferably the frontal and parietal areas of the cortex and is regarded as due to pressure from increase in the arachnoid fluid owing to obstruction in its circulation

STUDIES ON INFLAMMATION VALY MENKIN and MIRIAM F MENKIN, J Exper Med **51** 285, 1930

By means of a colorimetric method, the concentration of trypan blue in capillaries can be estimated by direct observation and its changes followed as the dye passes out of the circulating blood stream The change in concentration of trypan blue in the capillaries of both the normal and the inflamed mesentery of frogs can be described by two separate exponential equations of the type $y = be^{-ax}$ From these equations, it is found that the rate of fall of concentration following intraventricular injection of the dye is almost twice as great in the capillaries of the inflamed as in those of the normal mesentery This difference is a measure of increased permeability with inflammation

AUTHORS' SUMMARY

TUMORS OF THE CAROTID BODY A D BEVAN and E R MCCARTHY, Surg Gynec Obst **49** 764, 1929

A brownish, red purple, walnut sized tumor was revealed, by exploratory operation, at the junction of the common, external and internal carotid arteries The tumor was not removed because of the extensive vascular resection necessary in these cases The reports of 133 cases is reviewed

RICHARD A LIFVENDAHL

THE RELATION OF MATERNAL PELVIC DISEASE TO DEFORMITIES IN THE NEWBORN L GOLDSTEIN and D P MURPHY, Surg Gynec Obst **49** 804, 1929

Three of 310 children born of women suffering from idiopathic uterine hemorrhage, myoma, adnexitis, amenorrhea or carcinoma of the cervix or vulva were deformed The abnormalities included anencephaly, microcephaly and hydrocephaly This incidence of gross deformities corresponds to the birth rate of malformed children in the general population, indicating, that the presence of uterine or adnexal pathologic process has no relation to the production of deformities in new-born children

RICHARD A LIFVENDAHL

PRIMARY CARCINOMA OF THE URETER L M ROUSSELOT and J D LAMON, Surg Gynec Obst **50** 17, 1930

In the upper part of the right ureter was a squamous cell carcinoma In reviewing the forty-nine recorded cases it was found that these growths usually are of the papillary type and spread usually by way of the lymphatic or venous channels In this case there were metastatic growths in the regional and bronchial lymph nodes, suprarenals, pancreas, liver, lungs and pleura Although calculi, as a rule, are not associated with ureteral carcinoma, calculi were present in the corresponding kidney

RICHARD A LIFVENDAHL

RIGHT PARADUODENAL HERNIA AND ISOLATED HYPERPLASTIC TUBERCULOUS OBSTRUCTION J C MASSON and A H MCINDOE, Surg Gynec Obst **50** 29, 1930

Thirty-four cases of right paraduodenal hernia have been described In the case reported, an oval hernial opening 10 cm long was present to the left of the superior mesenteric artery, in the left lumbar region, having its long axis in the direction of the mesentery The mesenteric artery was kinked over the edge and extended into the hernial sac, which extended 22 5 cm caudad and slightly to the left and was located behind the posterior parietal peritoneum Three fourths of the small intestine was found in this outpouching, and the proximal jejunum was markedly dilated and hypertrophied as the result of a firm tuberculous fibrous constricting ring located 120 cm proximal to the ileocecal valve Calcified tuberculous lymph glands were found in the regional mesenteric lymph glands A discussion of the other types of this hernia and intestinal tuberculosis is given

RICHARD A LIFVENDAHL

THE EFFECT OF CHOLECYSTENTEROSTOMY ON THE BILIARY TRACT GATEWOOD and S E LAWTON, Surg Gynec Obst **50** 40, 1930

Cholecystgastrostomy on dogs showed thickened gallbladders, round cell infiltration of the vesical mucosa, in a few of the common ducts and in the periportal areas of the liver Acute and chronic retrogressive changes were noted in the centers of the liver lobules *B coli* and *Proteus vulgaris* were cultured from the gallbladder and the common duct but no bacterial growth was obtained from the liver In man, however, from the small amount of data available, these changes have been rarely recorded

RICHARD A LIFVENDAHL

TWO CASES OF MYELOMATOSIS D F CAPPELL, J Path & Bact **32** 293, 1929

One case of myelomatosis was of a diffuse character, involving the marrow of the ribs uniformly and the femur in its upper third in irregular nodules There were multiple, unhealed fractures of the ribs and a collapse of the sixth thoracic and fourth lumbar vertebrae Plasma cells, often containing mitoses, dominated the picture in histologic preparations of the marrow, liver and spleen, although myeloblasts and transition forms were seen In the second case, nodules were encountered in the ribs, femur and periportal spaces of the liver Mononuclear and reticulated cells, in addition to plasma cells, were abundant in this case There were many mononuclear cells in the pneumonic exudate

GEORGE RUKSTINAT

INTRAVITAM STAINING D F CAPPELL, J Path & Bact **32** 595, 1929

Three main classes of intravitam stains were employed those rapidly absorbed, as trypan blue, vital red and lithium carbonate, those slowly absorbed, as isamine blue, diaminefast scarlet acid, and insoluble suspensoid preparations, as india ink and saccharated oxide of iron It was concluded that intravitam and supravital staining of cells (apart from mitochondria) was due to the concentration of dye within vacuoles and granules in the cells—the "segregation apparatus" The appearance of dye in the cells was not regarded as a simple precipitation but as an active binding which varied with the functional activity of the cells It was found that, contrary to the popular belief, the soluble dyes were demonstrable in the plasma several days after intravenous injection Because of this fact it is necessary to wait until the dye has disappeared from the plasma before starting experiments involving intravitam-stained cells and pathologic processes, otherwise, previously unstained cells and emigrated cells or proliferated cells called forth by the pathologic stimulus might be stained and lead to false conclusions Results from experiments with intravitam and supravital stains on all body tissues are recorded

GEORGE RUKSTINAT

A CASE OF PERIARTERITIS NODOSA J GRAY, J Path & Bact **32** 787, 1929

A case of periarteritis nodosa is reported in a woman, aged 21, who died after decapsulation of the kidney Lesions were abundant in the coronary and renal arteries and branches of the hepatic An interesting feature was the occurrence of plasma cells and particularly eosinophils in great abundancee

GEORGE RUKSTINAT

ASCHOFF NODULE IN RHEUMATIC PNEUMONIA A D FRASER, Lancet **1** 70, 1930

A specific form of pneumonia may occur in acute rheumatic fever In the acute stage the lesion is marked by vascular changes, proliferation and necrosis of alveolar walls, and destruction of bronchi in the areas involved It resembles acute interstitial pneumonia Typical Aschoff bodies occur in the interstitial tissue, most prominently in the interlobular septums A chronic stage may supervene with more or less fibrosis and now the Aschoff nodule appears to be absent

ECHINOCOCCUS CYST OF THE HEART C BACALOGLU and OTHERS, Ann de med **26** 242, 1929

A case with multiple embolism is described The emboli had cystic contents

STENOSIS AND OCCLUSION OF INTERNAL UTERINE OS EVA GLUCK, Beitr z path Anat u z allg Path **81** 121, 1928

The relatively frequent occurrence of hydrometra in elderly women, as seen at necropsy, led to a study of the region of the internal os, with the aim of determining the cause of the dilatation of the uterine cavity In the routine post-mortem examination of 100 successive women over 50 years of age, hydrometra of varying grades was found in half In most of these the degree of dilatation was only moderate, extreme grades being rare In only one third of the 100 uteruses examined was the region of the internal os normal, in the remaining two-thirds it revealed varying degrees of change resulting in extreme cases to complete occlusion of the os The changes that lead to narrowing and obliteration of the internal os were studied by means of serial sections of fifteen uteruses The earliest change is a loss of the superficial epithelium This is followed by proliferation of the subepithelial stroma, the newly formed tissue becoming transformed into fibrous scar tissue which narrows or occludes the lumen The area of such involvement was usually not more than 1 mm in length In a few instances the lumen was closed off by two or more transverse fibrous septums The uterine glands in the involved area may persist Their openings become occluded by the fibrotic process and they become transformed into cysts, the presence of which may be a factor in the narrowing of the lumen The process which leads to the changes noted at the internal os is considered senile The cervical canal was normal in those cases in which the internal os was obliterated Narrowing of the external os, which was noted in a few cases, was due to chronic inflammatory changes in this region which were not identical with the senile fibrosis at the internal os

O T SCHULTZ

HYALINE FIBROSIS OF BRAIN, LUNG AND SUPRARENALS E RANDERATH, Beitr z path Anat u z allg Path **81** 145, 1928

Randerath presents, as a very unusual condition, a case with multiple areas of hyalinized fibrosis in various organs Histologic observations and discussion of their interpretation are given in detail The patient was a woman, aged 50, who seven years before death, had had a prolonged attack of respiratory trouble

termed grip Progressive weakness of various groups of muscles developed some time before her admission to the hospital, and death was apparently due to bronchopneumonia The clinical diagnosis was bronchopneumonia and questionable abscess, tuberculosis or embolism of the brain Necropsy revealed, in addition to terminal bronchopneumonia, marked fibrosis of the left lung, fibrosis of the thyroid and both suprarenals and the presence of multiple gravish, scar-like areas in the cerebral cortex Microscopically, the left lung, brain, thyroid and suprarenals contained multiple areas of dense fibrous tissue which was markedly hyalinized In the superficial portion of the cerebral cortex, the blood vessels were surrounded by mantles of lymphocytic infiltration Both the cortex and the medulla of both suprarenal glands were extensively involved in the hyaline fibrotic process, and lymphocytic infiltration was present in the cortex and in the surrounding adipose tissue There had been no evidence of Addison's disease during life The fibrosis of the thyroid was like that of the condition which Wegelin has termed inflammatory sclerosis of the thyroid In his discussion of the etiology and nature of the process described, Randereth excludes syphilis and adopts the view that the conditions described were the results of a generalized infection of long duration following influenza This led to the formation of areas of fibrosis in various organs In such areas, deficient circulation led to destruction of tissue, which in its turn caused the deposition of hyalin through an antigen-antibody reaction, as postulated by Loeschke

O T SCHULTZ

ARTERIOSCLEROSIS OF THE PULMONARY ARTERY U STEINBERG Beitr z path Anat u z allg Path **82** 307, 1929

Steinberg's discussion of arteriosclerosis of the pulmonary artery is limited to the secondary form of the disease, that form in which some known factor, mechanical, toxic infectious or chemical, may be accepted as having a causative role Discussion of the much rarer primary form, which leads to hypertrophy of the right ventricle, and for which no cause can be assigned, is reserved for a later paper The present study is based on 500 necropsies of persons whose age ranged from 15 to more than 94 years Arteriosclerosis of the pulmonary artery is usually nodular, the nodules varying in diameter from a millimeter or two to a centimeter or more The number of nodular lesions varies from a few to so many that the lesions are almost confluent Vessels of the third and fourth order, with a circumference of from 2 to 4 cm, are most often involved More rarely the main trunks are the seat of the process, and the finer vessels are rarely involved The nodular lesions always contained lipoid substances and were usually associated with elastic tissue hyperplasia and intimal proliferation In rare instances the process was diffuse rather than nodular In the statistical study of the material, especial attention was paid to the presence of lesions which might be presumed to cause an increased pressure within the pulmonary circuit Such processes, to which an important role has been ascribed in the causation of pulmonary artery arteriosclerosis, are chronic circulatory disturbances, emphysema, pulmonary fibrosis, pleural thickening, and deformities leading to decrease in the size of the chest cavity Attention was paid to toxic infectious processes, and the concomitant occurrence of arteriosclerosis of the general circulation received careful consideration Steinberg concludes that mechanical factors which lead to increased pressure within the pulmonary circuit are less important in the causation of arteriosclerosis of the pulmonary artery than has been held to be the case by most previous observers The condition is more frequently associated with arteriosclerosis of the general circulation than with any other condition Steinberg accepts Anitschkow's view that disturbance of lipoid metabolism is the fundamental factor in arteriosclerosis, of the lesser as well as of the general circulation Given such a disturbance, then mechanical factors play a secondary part in the establishment of the process

O T SCHULTZ

OSTEITIS FIBROSA M WEBER, Beitr z path Anat u z allg Path **82** 383, 514, 1929

The changes noted in the osseous system of an 8½ months old female Boston terrier form the basis of a 172 page discussion of osteitis fibrosa, for which the author prefers the term osteodystrophia fibrosa as a more generally applicable name for a disease of which the condition previously known as osteitis fibrosa is only one type The upper jaw was deformed by a large tumor-like mass, composed in part of cellular osteoid tissue and ossifying fibroblastic tissue, being in these respects similar to the intra-osseous epulis described by a number of writers in the jaw of lower animals, and made up in part of cystic spaces In the rest of the skeleton, two kinds of change occurred together One was an osteoporotic process, which was characterized by the presence of numerous giant cells within the bone, and of spaces from which the bone had been resorbed The second process was one of hyperplastic bone formation, characterized by the production of osteoid tissue that became fibrotic and partly ossified This process was associated with fibrosis of the marrow The points of similarity to and difference from rickets, osteomalacia, and scurvy are discussed in relation to the differential diagnosis of the condition described Weber accepts Christeller's classification of osteodystrophia fibrosa The latter writer recognized two main groups of the condition, an osteoporotic form and an osteosclerotic form, the latter being the healed or healing stage of the former Each of these groups was subdivided into a hyperostotic form and a hypo-ostotic form, depending on whether bone formation or bone resorption is predominant Any of these forms may be associated with cyst and pseudotumor formation Juvenile and adult forms are recognized Taking into account the classification and the changes noted by himself, Weber gives to the condition described the name of juvenile, cyst and pseudotumor forming, hyperostotic-porotic form of osteodystrophia fibrosa The type with cyst and pseudotumor formation is extremely rare in the dog, although it has been described in a variety of other species of lower animals, as well as in man A detailed description of the microscopic observations is followed by a general discussion of the process of normal bone formation, to a disturbance of which osteodystrophia fibrosa is ascribed The phases of bone formation from the undifferentiated mesenchymal ground substance are differentiation, the formation of ossification centers, the formation of cortical bone and resorption of bone Osteodystrophia fibrosa is looked on as the reaction of the osseous system to a stimulus, the latter possibly a metabolic disturbance The immediate reaction is resorption of bone The bone responds by a proliferative reaction which results in the formation of undifferentiated mesenchymal ground substance From this there is formed by differentiation fibrous tissue and fibrillated bone Cortical bone is not formed except as osteoid tissue The cysts and pseudotumors result from abnormal differentiation of undifferentiated mesenchyme, in situations such as the jaw, when mechanical factors, as the act of chewing, play a part The culmination of the progressive phase of osteodystrophia is reached when all the original cortical bone has been replaced by fibrous bone The end of the progressive stage and the beginning of healing are manifested in the cessation of resorption and in the reformation of cortical bone It should be the aim of feeding experiments to bring about a state to which the bone would react by such changes as those that characterize osteodystrophia fibrosa Feeding experiments designed to bring about a cessation of the process would, if successful, be of the greatest benefit in the therapy of the disease, especially of the human being The article closes with a bibliography of 228 titles

O T SCHULTZ

CARTILAGINOUS NODULES OF THE INTERVERTEBRAL DISKS R ANDRAE, Beitr z path Anat u z allg Path **82** 464, 1929

In the series of vertebral columns examined, small cartilaginous nodules were found present in the posterior ends of the intervertebral disks in 12 per cent of males and in 19 per cent of females The nodules are usually multiple, are most

numerous in the thoracic portion of the column, and lie beneath the posterior longitudinal ligament They may become vascularized or ossified They seem to be of little significance The study excites interest chiefly because it was based on the examination of 174 male and 1,949 female vertebral columns and comes from Schmorl's institute, where the right femur is removed routinely at necropsy, and the left femur and the entire vertebral column in most bodies coming to post-mortem examination

O T SCHULTZ

COMPARATIVE HISTOLOGY OF GASTRIC MUCOSA H BILLENKAMP, Beitr z path Anat u z allg Path **82** 475, 1929

Billenkamp made a histologic study of the normal gastric mucosa of fifteen species of mammals representing the following classes insectivora, rodentia, carnivora, ungulata and primates He compared the histology of the mucosa of the greater curvature with that of the 'Magenstrasse," the region characterized by the four folds which run from the cardia along the lesser curvature to spread out in the pyloric region It is in this region of the lesser curvature and pylorus that carcinoma, ulcer and epithelial metaplasia occur most frequently in the human stomach In most of the animals examined, the histologic structure of the region in question differed from that of the greater curvature In several of the species, no glands of the kind present in the body of the stomach occur in the lesser curvature or pyloric region In those species in which fundus glands are present in the region studied, they are limited to a short stretch near the cardia In all species the fundus mucosa extends farther distally along the greater than along the lesser curvature In a few species, the junction between fundic and pyloric mucosa takes a straight course around the stomach at right angles to the long axis of the stomach In some species, there is present between the fundic and pyloric types of mucosa an intermediate zone in which the glands contain no chief cells In most of the species examined, the thickness of the chief cell layer increases progressively from lesser to greater curvature

O T SCHULTZ

GLYCOGENIC HEPATONEPHROMEGALY E VON GIERKE, Beitr z path Anat u z allg Path **82** 497, 1929

Von Gierke presents the case report of a condition which he believes to have no counterpart in the literature The case is that of a girl who died at the age of 8 years The family history was negative, and birth and early development had been normal Unusual prominence of the abdomen had been noted by the family physician at the age of 2 or 3 months and had been present since birth, according to the mother Throughout its life the child had been susceptible to infections of the upper respiratory tract She had had a number of attacks of nosebleed, and had been treated for rickets, from which she recovered The child had been admitted to the hospital when 5 years old At this time the abdomen was large The liver was greatly increased in size There was questionable enlargement of the spleen There was moderate secondary anemia, with relative lymphocytosis The suggested clinical diagnosis at this time was Banti's disease The final admission was for an acute infection of the upper respiratory tract, which resulted in death At necropsy, the liver weighed 2,000 Gm instead of 634 Gm which is the average weight for the age and sex of the patient The kidney weighed 245 Gm instead of the average 133 Gm There was no ascites The spleen was of normal size and weight The thymus and suprarenal glands were small Microscopic examination revealed the presence of moderate amounts of fat in the liver cells The latter did not give the lipoid reactions of Niemann-Pick disease (lipoid histiocytosis, Bloom) The liver cells were filled with glycogen, as were also the tubular epithelia of the renal cortex The glycogen could be stained by carmine and gave the iodine reaction The liver contained 10 43 per cent of glycogen calculated for moist weight of the tissue, and 33 72 per cent calculated for the dry weight The kidney contained 6 53 per cent glycogen, moist

weight, and 36 82 per cent, dry weight The glycogen did not disappear from fresh liver tissue kept for six days in the incubator in normal physiologic solution of sodium chloride and chloroform water The pancreas was histologically normal After von Gierke had completed the study of his case, he learned of an apparently similar one that had come to necropsy in Vienna in 1928 This case he also presents The child was a boy, aged 4 years and 10 months The liver and kidneys were enlarged, and the parenchymatous cells of these organs contained large amounts of glycogen As a working hypothesis to explain the condition reported, the author postulates a disturbance of intracellular glycogen metabolism, which leads to deposition of the glycogen in the cells of the liver and kidney Early embryonic tissues, especially liver, kidney and muscle, are rich in glycogen, indicating the early development of the property of intracellular glycogen synthesis The glycogen store disappears from the tissues at or shortly before birth, indicating a later development of the property of intracellular glycogenolysis In the condition reported, it is supposed that the cells of the liver and kidney failed to develop the normal property of splitting glycogen

O T SCHULTZ

HYALINE BODIES IN TESTICLE C BLUMENSAAT, Virchows Arch f path Anat **273** 51, 1929

In six of fifty-one boys ranging from 1 to 15 years of age, the testicles contained hyaline bodies similar to corpora amylacea, located in the lumen of convoluted tubules They appeared to originate from desquamated spermatogones In all six cases death had been caused by a disease located in the skull (three times otitis, extradural abscess glioma, sarcoma) Lipoid and iron deposits in the testicle show the same preference

ALFRED PLAUT

NEUROMA AND CARCINOID OF VERMIFORM APPENDIX HEINZ BARTH, Virchows Arch f path Anat **273** 62 1929

The histogenesis of carcinoid is obscure The different theories contradict each other In a woman, aged 70, the center of the obliterated appendix was occupied by a neuroma, parts of which contained argentaffine cells The amount of nervous tissue in the wall was large This coexistence of neuroma and carcinoid is not accidental, there is some connection between the yellow cells of the intestinal mucosa and the nervous apparatus of the intestine In a girl, aged 19, the appendix had the thickness of a little finger and contained a diffuse, carcinoid-like tumor with metastasis in the ovary This tumor contained giant cells with vacuoles and granules The patient is alive twelve years after operation The presence of metastasis from carcinoid in a lymph node, for instance, generally does not mean an unfavorable prognosis In a girl, aged 16, an acute inflammation of the appendix was restricted to the portion between a small carcinoid and the tip On the other hand, a small carcinoid in a girl, aged 10, seemed to be secondary to an acute appendicitis

ALFRED PLAUT

CELL CONTENTS AND IRON IN THE SPLEEN OF FETUS AND NEW-BORN I E LEWIN, Virchows Arch f path Anat **273** 168, 1929

In eighty-five fetuses and new-born infants the spleens were examined, thirty-five were mature and fifty were premature The follicles are smaller in the new-born than in the adult, the external zone often is indistinct Granulocytes are found in different numbers Eosinophil cells are always present Basophils are few they are found only after fixation in absolute alcohol Their number does not increase with toxic conditions or with congenital syphilis Plasma cells are absent No megakaryocytes are found Immature red cells are found in varying numbers and varying distribution

In the mature new-born the spleen generally gives a strong iron reaction It was the same in the spleen of four infants born during the eighth and ninth

month In the spleen of forty-four immature infants and of four mature infants little or no iron was found (Hueck's iron reaction was used) In the sixth and seventh month iron reaction is negative Stasis and duration of labor bear no relation to the iron reaction In two prematurely born infants there were hemorrhages in the spleen, but the iron reaction was negative These results partly are at variance with those of Lubarsch

ALFRED PLAUT

THE HEALING OF JOINT FRACTURES LEO LOW-BEER, Virchows Arch f path Anat **273** 191, 1929

Few microscopic examinations of joint fractures are reported in the literature, therefore the author gives (in more than fifty pages) a detailed description of six joint fractures from autopsy material There are twenty-one photographs The many details must be studied in the original paper with the aid of the photographs The periosteal callus participates little in the bony consolidation The final regeneration of bone and marrow is so complete that the site of fracture may become indiscernible even under the microscope Tendinous callus bridges over the gaping fracture cleft, intercalar bones in it start the bony consolidation The fracture line in the cartilage remains visible since the fibrocartilage which fills it is more bluish than the old hyaline cartilage In some instances the cleft remains filled with fibrous tissue which originated from bone-marrow The occurrence of secondary arthritis depends on dislocation Small accessory microscopic fractures in the neighborhood are frequent

ALFRED PLAUT

ISOLATED TUBERCULOSIS OF MYOCARDIUM L BERGER and J CHARLES MILLER, Virchows Arch f path Anat **273** 250, 1929

The heart, which was that of a mentally defective man, aged 57, had six caseous foci from 0 5 to 2 cm in diameter The pericardium was partly adherent, the valves and aorta were normal No gross or microscopic lesions were seen in any other organ At the edge of the foci was a narrow margin of epithelioid cells and lymphocytes with few atypical giant cells, some of those contained tubercle bacilli Only two similar cases are reported in the literature

ALFRED PLAUT

Pathologic Chemistry and Physics

THE COMPOSITION OF HUMAN SWEAT RALPH PEMBERTON, F A CAJORI and C Y CROUTEN, Ann Int Med **2** 1243, 1929

Under normal conditions sweat may have either an acid or an alkaline reaction, the p_H values ranging from 4 8 to 8 4 which is essentially the range that has been observed for urine Acid sweats contain very small amounts of carbon dioxide, and this reaction is not effected by boiling or aeration, the acidity appears to depend on some component other than carbon dioxide Alkaline sweats contain more carbon dioxide The cause of the acidity of sweat remains undetermined The change in reaction from acid to alkaline during long-continued sweating appears to be the result of the actual excretion of alkaline substances The nitrogen and chloride content of the sweat of arthritic patients does not differ appreciably from the values obtained for normal sweat Normally high nitrogen values were obtained in the sweat of nephritic patients These observations suggest the possibility that in nephritis the skin may serve as a valuable path for the excretion of nitrogenous substances

WALTER M SIMPSON

PHOSPHORUS IN THE BLOOD AND URINE IRWIN SCHULZ, Ann Int Med **3** 667, 1930

The inorganic phosphorus values of the plasma are equal to or less than the values for whole blood in normal, fasting persons In patients with nephritis

with retention of phosphorus, the level of inorganic phosphorus in the plasma is greater than that in the whole blood Retention of phosphorus associated with retention of creatinine in patients with chronic nephritis indicates a fatal prognosis If a nontoxic mixture of solution of acid sodium phosphate, 9 per cent, and of solution of alkaline sodium phosphate, 9 6 per cent, in a ratio of 3 parts of the former to 17 parts of the latter, is injected intravenously into a normal man, it will produce an immediate rise, followed by a gradual fall, in the inorganic phosphorus of the blood It causes an increase in the amount of inorganic phosphorus excreted in the urine and feces In the normal, fasting subject, 50 per cent of the injected phosphorus may be recovered from the urine within four hours In nephritis the amount of phosphorus recovered is decreased as the amount of renal injury is increased Furthermore, the return of the level of inorganic phosphorus in the blood to that preceding injection is slower in patients with nephritis than in the normal subject

WALTER M SIMPSON

BILIRUBIN IN EFFUSIONS OF THE JOINTS D H KLING, Arch Surg **20** 17, 1930

In traumatic, hemorrhagic effusions of the joints, the fluid has a higher icterus index than the circulating blood, and this icteric index increases as the disintegration of the extravasated red cells increases In inflammatory effusions, the icteric index is the same or slightly less than that of the blood In traumatic effusions of the joints accompanied by intra-articular fractures, the bilirubin content of this fluid is still higher, due, the author believes, to the leakage of venous blood from the bone-marrow

N ENZER

VARIATIONS IN THE PLASMA CHOLESTEROL AND CHOLESTEROL ESTHER CONTENT IN HOG CHOLERA RICHARD E SHOPE, J Exper Med **51** 179, 1930

The cholesterol content and cholesterol ester content of the plasma of swine experimentally infected with hog cholera exhibit a regular succession of changes During the period of incubation of the disease, for three or more days following inoculation with the virus of hog cholera, hypocholesterolemia prevails This is followed by a period of hypercholesterolemia, which is coincident with the onset of the clinical manifestations of the disease The hypercholesterolemia after from four to seven days gives way to a second period of hypocholesterolemia more marked and more prolonged than that observed immediately after inoculation In the present experiments, this second period lasted eight and eleven days in the two animals surviving long enough for the study of it, and was followed by a second period of hypercholesterolemia In the one animal surviving this period for eight days, a third period of irregular and fluctuating hypocholesterolemia set in A comparison with the results in other acute infections indicates that hog cholera is unique in showing alternating periods of hypocholesterolemia and hypercholesterolemia A normal hog inoculated with *Bacillus suisepticus* rapidly developed the typical marked hypocholesterolemia, whereas an animal infected with hog cholera and then inoculated with *B suisepticus* failed to show the decrease in the cholesterol content of the plasma

AUTHOR'S SUMMARY

ON THE ACTION OF SERUM ON THE FIBRINS OF VARIOUS SPECIES J VAN DER SCHEER, J Immunol **18** 17, 1930

The author tried without success to duplicate the experiments by Fuch and von Falkenhausen, from which it would follow that the distinction of proteins (fibrin) of various species and races can be made by means of serum ferments

AUTHOR'S SUMMARY

THE COLLOIDAL THEORY OF SILICOSIS PATRICK HEFFERNAN, Tubercle **11** 61, 1929

The "colloidal" theory of the action of inhaled silica dust is briefly the silica particles, crystalline, cryptocrystalline or amorphous, are engulfed by phagocytes in the wall of the alveoli, and conveyed into the lymphatic channels, where they come to an arrest The silica particle, within the phagocyte, is "hydrated" at its surface into colloidal silica hydrosol, the production of a "soluble" alkaline silicate being a temporary intermediate stage in the process of hydration The hydration occurs at the expense of the protoplasmic fluid of the phagocyte, which becomes vacuolated and dies, leaving a "ghost" of cell behind The foregoing processes are retarded if the silica particle has a protective coating, e g, of carbon, clay, etc, and are accelerated by the presence of alkali, e g, if the silica particle has a coating of alkaline soap After the death of the phagocyte, the action spreads to the surrounding cells, which are similarly influenced So far, the facts are capable of verification, and the net result is destruction of tissue cells and, in due time, replacement Whether the action is one of simple dehydration of tissue cells or whether certain constituents of the cell protoplasm are selectively absorbed by the silica hydrosol, or whether reactions such as coagulation of cell colloids and the formation of silico-organic compounds, stoichiometric or adsorptive occur, is still unknown The process may continue until all the silica particle is dissolved, when equilibrium is attained by some such means as the formation of relatively stable silico-organic substances (e g, cholesterol silicate in bird's feathers) or adsorption compounds, or by the coagulation of the silica hydrosol into an irreversible gel, or by the elimination of the silica, in its "soluble" state, in the urine On the other hand, the hydration of the silica particle may cease, temporarily or permanently, before the particle is completely "dissolved" In this case there would be a central core of undissolved silica surrounded by silica hydrosol or gel, next to this a zone of the "ghosts" of dead cells, outside of which would be a zone of small cell infiltration or fibrosis Such a system would constitute a typical "silicotic" nodule Such a dormant silica nodule next could be reactivated should the protective barrier break down and alkaline tissue juices again come into contact with the silica particle "Silicotosis" is believed to be a true silicosis, possibly modified by the calcium, iron, magnesion, aluminum, etc, from which the colloidal silica has been set free The question of the elimination of silica from the body urgently needs investigation

H J CORPER

PLASMA PROTEINS AND SEDIMENTATION RATE OF RED CELLS F REICHE and F FRETWURST, Beitr z Klin d Tuberk **72** 484, 1929

The fractions of the plasma protein and their relative amounts are not the main factors in determining the sedimentation rate

MAX PINNER

OXALATURIA AND INCREASED URINARY EXCRETION OF OXALIC ACID IN TUBERCULOSIS J A LANGER and T LITTIG, Beitr z Klin d Tuberk **72** 492, 1929

The increased excretion of oxalic acid in tuberculosis is probably related to the catabolism of the fatty acids in the liver and is a manifestation of an impairment of the intermediary metabolism The microscopic demonstration of oxalates in the urine has no diagnostic significance

MAX PINNER

Microbiology and Parasitology

A STUDY OF BACTERIOPHAGE IN TISSUE CULTURES I DRESEL and M R LEWIS, Am J Hyg **11** 189, 1930

The activity of bacteriophage (mouse typhoid phage) on homologus bacteria (mouse typhoid bacilli) was not demonstrated in tissue cultures, either from susceptible or from refractory animals On the other hand, such tissue cultures

made on agar plates, instead of hanging drop preparations, showed the bacteriophage to be active The bacteriophage was not influenced by the growth of the cells in tissue cultures, regardless of whether the tissue was of adult or of embryonic type, nor did the condition of the growth of the tissue in the culture influence the stability of the phage The tissue cells were not injured by the presence of the mouse typhoid phage In tissue cultures containing phage alone or in conjunction with mouse typhoid bacilli, the phage was not inactivated even though it did not exhibit its lytic action in the cultures

AUTHORS' SUMMARY

PARASITIC CIRRHOSIS OF THE LIVER IN A CAT INFECTED WITH OPISTHORCHIS PSEUDOFELINEUS AND METORCHIS COMPLEXUS HIRAM E ESSEX and JESSE L BOLLMAN Am J Trop Med **10** 65, 1930

The clinical course, as well as the histologic picture of the disease, appeared to be true biliary cirrohsis of the type described by Hanot, it was quite different from the cirrhosis of Laennec or from obstructive jaundice The hyperplasia of the biliary duct system suggested some specific cause associated with parasitic infection In this event, the specicity must be closely associated with the parasites because obstructive jaundice with the usual types of bacillary infection of the bile ducts does not produce extensive hypertrophy Since the hyperplasia extended into the smaller bile ducts, in which parasites or ova could not migrate, it would appear that the specific irritant either extended up the biliary channels by diffusion or reached the finer bile ducts by way of the portal vein The latter hypothesis seems more probable in view of the fact that other forms of cirrhosis are produced by intestinal absorption of more or less specific hepatotoxic agents

AUTHORS' SUMMARY

LIVER AUTOLYSIS IN VIVO J C ELLIS and L R DRAGSTEDT, Arch Surg **20** 8, 1930

In a series of experiments on dogs, the authors demonstrated that the autolysis which takes place when uncontaminated liver is deprived of its circulation and allowed to float free in the peritoneal cavity is due to the combined action of the anaerobic organisms and intracellular enzymes All of the dogs in which the liver was ligated or pieces of liver placed in the peritoneal cavity died in less than forty-eight hours, and the majority in less than twenty-four hours The liver becomes spongy and gas-filled Cultures under anaerobic conditions gave a growth of gram-positive, anaerobic bacilli In one series of experiments cultures were made of the liver first, and the same organisms recovered postmortem as were recovered in the culture If the liver was autoclaved and thus sterilized, no ill effects were produced on the dog, and very little autolysis of the liver took place The authors conclude that so-called in vivo aseptic autolysis of the liver is always accompanied by anaerobic infection, and that the anaerobic organisms are always present in living, uncontaminated liver They also conclude that these organisms or their products are the immediate cause of death

N ENZER

POSTVACCINAL ENCEPHALITIS AND ALLIED CONDITIONS SIMON FLEXNER, J A M A **94** 305, 1930

The decade through which we are passing has shown an increase in the number and variety of myelitic and encephalitic disorders In part this is attributable to outbreaks of epidemic or lethargic encephalitis, and in part it can be accounted for by what appear to be unusual attendances of antismallpox vaccination, measles and other infections, by inflammations of the central nervous organs To our present knowledge of clinical and microscopic features it is hoped that knowledge of the directly inciting events may come also to be added

AUTHOR'S SUMMARY

THE EFFECT OF THE X-RAY ON THE NODULES OF VERRUGA PERUANA HENRY R MULLER and JOSEPH R TYLER, J Exper Med **51** 23, 1930

The supposition that the x-rays would affect the developing and the developed verruga nodules experimentally induced in the monkey, has proved correct The experiments show that the early verruga nodules when exposed to a single, properly graduated dose of the x-rays producing merely erythema of the skin, are inhibited in their evolution Moreover, the skin of *Macacus rhesus* monkeys is modified by a single erythema dose of the x-rays in such a way that infection of it with *Bartonella bacilliformis* is rendered more difficult These results are sufficiently striking to warrant the trial of the x-rays in suitably guarded doses in the treatment of verruga nodules in man Should the employment of convalescent serum influence the course of Carrion's disease favorably and the use of the x-rays bring about a more certain and rapid devolution of verruga nodules in man, two practically applicable therapeutic measures will have been provided for the treatment of the two forms of the human disease

AUTHORS' SUMMARY

ON THE ISOLATION, CULTIVATION AND CLASSIFICATION OF THE SO-CALLED INTRACELLULAR 'SYMBIONT" OR "RICKETTSIA" OF PERIPLANETA AMERICANA R W GLASER, J Exper Med **51** 59, 1930

In *Periplaneta americana,* the large American roach, bacteriocytes are found in both sexes These bacteriocytes are scattered throughout the fat tissue, and their cytoplasm is filled with micro-organisms Evidence is presented to show that the intracellular forms are diphtheroidal bacilli These diphtheroids are transmitted from one generation to another through the ova A method is described whereby tissues, free from contaminants, may be obtained from *Periplaneta* A medium and a new method, the "spotting technic," are described, by means of which initial cultures of the parasites were obtained from eggs within capsules, from ova and fat tissue bacteriocytes Two conditions appear necessary, one to initiate adaptation to the new environment, the other to bring its complete realization to fruition When development has been properly initiated, further adaptation occurs with successive transfers until finally certain other mediums appear suitable Approximately 14 per cent of attempts at isolation and cultivation succeeded All the micro-organisms isolated were studied, and it was found that three morphologically distinct types had been cultivated In general, one host yielded only one type, but one female revealed three types and another two One type was also isolated once from a fecal emulsion The probable reason for this is discussed The three types isolated were diphtheroidal bacilli resembling one another closely enough to be considered a single species but invariably offering distinct minor differences to warrant a separation into three distinct types These three types have remained true to their original forms and sizes through fifty-two transfers The sizes, general morphology, and tinctorial reactions of the three types cultivated correspond to the intracellular parasites of *Periplaneta americana* The cultural and biochemical activities of the strains did not reveal any sound characters for differentiating types Serologically, however, useful distinctions were found Some additional evidence along immunologic lines is offered to show that the micro-organism cultivated is a representative of the identical species parasitic within *Periplaneta americana* The evidence appears sound to the writer that the *Periplaneta* parasite has been isolated and cultivated over twenty times and that it is bacterium belonging to the genus *Corynebacterium* (the diphtheroids) For the species the name *Corynebacterium periplanetae,* nov sp, variety *americana* is proposed The three cultural types did not produce forms small enough to pass through the pores of Berkefeld "N" candles

AUTHOR'S SUMMARY

THE TRANSFORMATION OF PNEUMOCOCCAL TYPES MARTIN H DAWSON, J Exper Med **51** 99, 123, 1930

R forms of pneumococcus may be converted into S forms of the homologous type by the subcutaneous injection, in white mice, of large amounts of living R organism R forms of pneumococcus may similarly be converted into S forms of the homologous type by the subcutaneous injection, in white mice, of small amounts of living organisms together with the heat-killed bacteria from large amounts of S cultures By these methods types 11 S and 111 S vaccines are equally effective in producing conversion when heated for fifteen minutes at 60 C, or for fifteen minutes at 100 C Type 1 S vaccine is effective in producing conversion when heated for fifteen minutes at 60 C, but not when heated for fifteen minutes at 100 C R vaccines and the vaccines of other organisms are not effective in producing conversion All "in vitro" attempts to produce conversion by the use of vaccines have been unsuccessful The rôle which the phenomenon of conversion may play in infectious processes is indicated Type-specific S pneumococci may be transformed from one specific S type into other specific S types through the intermediate stage of the R form R forms of pneumococci, derived from any specific S type, may be transformed into S organisms of other specific types by the following procedure The subcutaneous injection, in white mice, of small amounts of living R forms together with vaccines of heterologous S cultures S vaccines heated for fifteen minutes at temperatures between 60 and 80 C, are effective in causing R forms, derived from heterologous S types, to revert to the type of the vaccine S vaccines heated for fifteen minutes at temperatures between 80 and 100 C are not effective in causing R forms, derived from heterologous S types, to revert to the type of the vaccine S vaccines heated for fifteen minutes at temperature between 80 and 100 C, may cause 2 R and 3 R cultures to revert to their original S type S vaccines of any type, including type 1, heated for fifteen minutes at temperatures between 80 and 100 C, are not effective in causing 1 R cultures to revert to their original S types S vaccines heated for periods as long as two hours at 60 C are effective in causing R forms, derived from heterologous types, to revert to the type of the vaccine A single cell R strain, derived from a type 11 S pneumococcus, has been successively transformed into a type 111 S, a type 1 S and a group IV S culture Corresponding with the various degrees of "degradation" of the R form there are varying degrees of "development" of the S form The nature of the conditions responsible for alteration of type as induced by these procedures has been investigated, and the causes responsible for the transformations are discussed All attempts to produce transformation of type in vitro have been unsuccessful The rôle which the phenomenon of transformation of type may play in problems of infection and epidemiology is indicated

AUTHOR'S SUMMARY

SURVIVAL OF VACCINE VIRUS SEPARATED FROM LIVING HOST CELLS BY COLLODION MEMBRANES R S MUCKENFUSS and T M RIVERS, J Exper Med **51** 149, 1930

Vaccine virus, suspended in a mixture of serum and Tyrode's solution and separated by collodion membranes from a suspension of living kidney cells in serum and Tyrode's solution, remained active at 37 C for a longer period of time than did vaccine virus incubated only in a mixture of serum and Tyrode solution

AUTHORS' SUMMARY

ON THE RELATION OF THE ORGANISM IN THE TUNICA VAGINALIS OF ANIMALS INOCULATED WITH MEXICAN TYPHUS TO RICKETTSIA PROWAZEKI AND TO THE CAUSATIVE AGENT OF THAT DISEASE H MOOSER and CLYDE DUMMER, J Exper Med **51** 189, 1930

Healthy lice became infected with *Rickettsia prowazeki* after feeding on monkeys inoculated with a strain of Mexican typhus The same result was obtained

in 100 per cent of lice by rectal inoculation of an emulsion of tunica vaginalis of guinea-pigs reacting to the same strain In the tunica vaginales of guinea-pigs and rats inoculated intraperitoneally with an emulsion of lice containing *Rickettsia prowazeki*, the intracellular organism constantly associated with the passage strain appeared regularly *Rickettsia prowazeki* found in lice and the organism constantly present in the tunica of guinea-pigs and rats reacting to our strain of tabardillo are morphologically and tinctorially indistinguishable, and their modes of intracellular multiplication are alike in every respect It is concluded that they are identical This organism is constantly associated with the causative agent of Mexican typhus, both in mammals and in lice, and all of our attempts to separate them have failed

AUTHORS' SUMMARY

THE EPIDEMIOLOGY OF FOWL CHOLERA LESLIE T WEBSTER, J Exper Med **51** 219, 1930

The studies so far carried out indicate that the epidemiology of fowl cholera rests on essentially the same basis as that of rabbit pasteurellosis In each instance, the severe epidemic form of infection is associated with a relatively virulent type of organism which survives with difficulty in the tissues of the host, whereas the endemic disease is associated with strains of relatively low virulence and high vegetative capacity In fowl cholera, as in other animal diseases studied, the spread and severity of the infection appear to be controlled by the resistance of the host and the dosage of the organisms

AUTHOR'S SUMMARY

THE EPIDEMIOLOGY OF FOWL CHOLERA THOMAS P HUGHES, J Exper Med **51** 225, 1930

A bacteriologic study has been made of 210 fresh strains of *Pasteurella* obtained from typical cases of fowl cholera on seven widely separated poultry farms The strains have proved identical in consisting of small, pleomorphic, bipolar-staining, gram-negative, nonmotile bacilli They grew rapidly in infusion broth plus a trace of hemoglobin They formed acid but no gas in mediums containing dextrose, saccharose and mannite, indol was produced The strains fall into three distinct groups, according to the kinds of colonies formed by them on hemoglobin agar The "fluorescent" colony was large, whitish and opaque and under suitable conditions exhibited marked fluorescence The "blue" colony was smaller, clear slate-blue and nonfluorescent The "intermediate" colony was moderately fluorescent after from fifteen to eighteen hours growth, and "blue" thereafter It was "blue" at all times when crowded and occasionally of "ring" form Cultures from the "fluorescent" colony developed the forms of the "blue" colony under certain conditions, otherwise, all forms were stable Strains from "fluorescent" colonies were resistant to precipitation by acids and to sedimentation by centrifugation, and although they combined with specific antiserum, did not agglutinate They were relatively highly virulent and occurred in flocks in which fowl cholera was epidemic Strains from "blue" colonies were precipitated by acids over a wide range of concentration and agglutinated strongly in antiserums They were of relatively low virulence and occurred in flocks in which fowl cholera was endemic Strains from "intermediate" colonies varied in behavior between the "fluorescent" and the "blue" strains They came from a flock in which fowl cholera was epidemic

AUTHOR'S SUMMARY

THE EPIDEMIOLOGY OF FOWL CHOLERA THOMAS P HUGHES and IDA W PRITCHETT, J Exper Med **51** 239, 1930

In the experiments here presented, *Pasteurella avicida* proved incapable of inciting fowl cholera when introduced directly into the alimentary tract On

the other hand, when introduced into the upper respiratory passages, it induced typical disease When *P avicida* was introduced into the nasal passage of controlled, selected chickens, some died of typical septicemic cholera, a few developed chronic pneumonias and other conditions and succumbed, a few developed localized inflammations of the upper part of the respiratory tract, such as rhinitis, roup and wattle involvement, while yet a few others became "healthy" nasal carriers Usually, however, more than 50 per cent resisted infection Repeated titrations of this sort gave, in general, uniform results, save that in spring and summer the mortality decreased *P avicida* was recovered from a number of cases of "spontaneous" roup rhinitis and wattle disease Groups of chickens reacted similarly to doses of virulent *P avicida* varying from 20,000,000 to 20,000 Outside these limits, dosage exercised a marked influence on mortality

AUTHORS' SUMMARY

THE EPIDEMIOLOGY OF FOWL CHOLERA IDA W PRITCHETT, F R BEAUDETTE and T P HUGHES, J Exper Med **51** 249, 1930

Field studies of fowl cholera on two commercial poultry farms are described One farm, previously free of cholera, was studied during an active epidemic which occurred during the winter months The strains of *Pasteurella avicida* recovered, both at "autopsy" and from "healthy carriers," proved generally similar, and to be of the types producing "fluorescent" and "intermediate" colonies These types are of relatively high virulence After the subsidence of the epidemic, these strains tended to disappear The second flock consisted of a small group of birds which had survived an epidemic of cholera the previous year, and in which the infection subsequently prevailed in endemic form No deaths occurred during the period of observation, but the number of birds with localized lesions and the number of carriers greatly increased during the winter months The strains of *P avicida* were apparently of the type producing "blue" colonies, although some, as shown by their acid and serum agglutination reactions, resembled the "intermediates" These strains appeared to be spreading rather than dying out The individual fowls differed in their response to the presence of infection some showed localized lesions, others were carriers, while still others seemed entirely refractory

AUTHORS' SUMMARY

THE EPIDEMIOLOGY OF FOWL CHOLERA IDA W PRITCHETT, F R BEAUDETTE and T P HUGHES, J Exper Med **51** 259, 1930

An investigation of endemic fowl cholera has been made at a poultry farm in Belle Meade, N J The focus or reservoir of *P avicida* proved to be the healthy pullets which had become carriers the previous year and which had been selected as the breeding stock for the ensuing season From these carriers, the organisms spread and gave rise during the winter months to the various forms of the infection, including the carrier state, disease localized in the upper part of the respiratory tract and typical cholera The strains of *P avicida* were, in general, similar and of the type that forms "blue" colonies They were all of the same low degree of virulence, no differences were demonstrable between (*a*) strains obtained from "carriers" and those obtained at "autopsy", (*b*) strains where the infection was spreading and severe, and those where disease was rare, and (*c*) "autumn" and "winter" strains In general, a relatively high carrier rate was accompanied by a high mortality, although in one instance, a community with high incidence of carrier, plus a probable high degree of resistance of the host suffered but little fatal infection An attempt was made to reduce the amount of cholera by the removal of carriers The results of this measure indicate that such a procedure is both effective and practical

AUTHORS' SUMMARY

TULAREMIA IN SHEEP IN NATURE R R PARKER and J S DADE, Pub Health Rep **44** 126, 1929

The proved occurrence of *B tularense* in the tissues of sheep in nature opens the question of the possibility of human infection from the handling of infected carcasses Infection is definitely possible through the primary contamination of the hands with the tissues of crushed infected ticks held in the wool or with thick excrement which is commonly present in large masses The fingers might also become contaminated by contact with necrotic tissue which sometimes develops at the points where infected ticks have been attached The chance that infected meat might reach the markets and be a source of danger to persons in slaughterhouses and packing houses and to the consuming public seems less likely, but cannot be altogether dismissed, especially if animals are slaughtered for immediate local consumption

Further and more carefully planned field and laboratory observations of tularemia in sheep caused by the wood tick are desirable, (1) to determine the extent to which it is concerned in wood-tick-caused pathologic conditions, (2) to determine the geographical limits of the occurrence, which certainly are wider than indicated by present data, (3) to secure more detailed epidemiologic, symptomatologic, and pathologic data and (4) to determine whether the meat of infected slaughtered sheep is a possible source of human infection

AUTHORS' SUMMARY

THE SELECTION OF A HEAT-RESISTANT STRAIN OF VACCINE VIRUS (RABBIT TESTICULAR) CHARLES ARMSTRONG, Pub Health Rep **44** 1183, 1929

Through continued selection and propagation, a strain of rabbit testicular smallpox vaccine of exalted virulence for animals has been developed which shows an increase of several hundred per cent in the period of time during which it will withstand a temperature of 37 5 C and still give typical skin "takes" on rabbits The sixty-first transfer is potent after holding for thirty-three days and three hours at this temperature The selective process is being continued, since the upper limit appears not yet to have been reached

AUTHOR'S SUMMARY

TRANSMISSION OF FOWL-POX BY MOSQUITOES I J KLIGLER and M ASHNER, Brit J Exper Path **10** 347, 1929

Mosquitoes transmit fowl-pox from infected to healthy chickens The same infected insect may produce a number of consecutive infections over a period of at least sixteen days Feeding on another animal species does not impair the infectivity of the insect The virus appears to be localized on the proboscis Infection may be produced readily by the inoculation of the proboscis from sixteen to nineteen days after the insect has become infected, but only rarely by the inoculation of any other part of its body The virus of fowl-pox behaves in the same manner on infected silver pins as it does on the insect's proboscis The possibility of direct mechanical transmission of virus, as well as other diseases in which the mode of transmission is unknown, should be more fully investigated

AUTHORS' SUMMARY

THE RELATION BETWEEN "GRASS DISEASE" OF HORSES AND BOTULISM A B WALKER, Brit J Exper Path **10** 352, 1929

Eight horses were poisoned by oral administration of filtered cultures of *B botulinus* The minimal lethal dose by the mouth of culture type B was about 0 01 cc for a horse of 500 pounds (0 00005 cc per kilogram) The hypodermic minimal lethal dose of this culture for a mouse of 28 Gm and for a guinea-pig

of 250 Gm was 0 001 cc (0 0036 and 0 0004 cc per kilogram, respectively) The symptoms produced by botulism in horses are quite different from those produced by grass disease, and some of the clinical symptoms which are apparently the same in the two diseases are probably due to different causes The postmortem observations in the two diseases are also quite different Parasympathetic paralysis is one of the chief features of grass disease, but this does not occur in equine botulism

AUTHOR'S SUMMARY

LEPTOSPIRA ICTEROHAEMORRHAGIAE IN OXFORD RATS A D MIDDLETON, J Hyg **29** 219, 1929

In the Oxford district, 41 7 per cent of the rats were found to carry *Leptospira icterohaemorrhagiae* in their kidneys The percentage of infection increases until the animals are mature, reaching a maximum of 56 per cent among one class of the population, but is less among the oldest rats There is evidence that the organism is acquired comparatively early in life, and that immunity is obtained after a long period of infection

AUTHOR'S SUMMARY

GENERALIZATION OF VACCINE VIRUS H A GINS H HACKENTHAL and NATALIE KAMENTZEWA, Centralbl f Bakteriol **110** 115, 1929

The authors show that after the injection of vaccine virus into the skin, the virus can be demonstrated in the tonsils of children before the pustule appears at the site of infection In guinea-pigs and rabbits, vaccine viruses injected into the skin could be demonstrated in the mucous membrane of the upper respiratory passage from the second day after injection Experiments in guinea-pigs make it seem probable that the presence of the virus in the mucous membranes should be regarded as a phase of generalization in as much as the virus could at the same time be demonstrated in the blood and internal organs

PAUL R CANNON

EXPERIMENTS IN GUINEA-PIGS ON THE VIRULENCE OF B C G LUDWIG LANGE and KARL W CLAUBERG, Centralbl f Bakteriol **110** 183, 1929

Subcutaneous injections of 25 mg of B C G were made into guinea-pigs, and the animals were then subjected to various types of injury such as inhalation of dust, vitamin deprivation, hunger, poisoning with diphtheria toxin and snake venom These injuries were begun between the eighteenth and one hundred and sixty-ninth day after injection In spite of the weakening of the animals by these means, no increase in virulence of the B C G strains was noted

PAUL R CANNON

THE BEHAVIOR OF ROCKY MOUNTAIN SPOTTED FEVER VIRUS IN THE WHITE RAT AND THE WHITE MOUSE Y FUKUDA Centralbl f Bakteriol **111** 408, 1929

An emulsion of spleen and testis from a guinea-pig infected with spotted fever virus was injected into twenty male white rats and eight white mice These were then killed at intervals of time in order to determine the length of time the virus persisted The determination was made by emulsifying testis and spleen into saline solution and injecting this intraperitoneally into guinea-pigs The results showed that in the spleen-testis emulsion of white rats and in the spleen of the white mouse, the virus persisted for twenty-five days On the seventh day after infection the spleen of the white rat contained 10 000 doses of virus

PAUL R CANNON

A WATER-BORNE TYPHOID-LIKE EPIDEMIC CAUSED BY BACILLUS PROTEUS K BECKMANN and R HURTHLE, Deutsche med Wchnschr **55** 1628, 1929

Following the contamination of a water supply there was observed an epidemic of a mild type of gastro-enteritis Most of the patients were ambulatory, but eighteen entered the hospital In thirteen of these *Bacillus proteus-vulgaris* was considered responsible for the disease In some instances, there was a slight positive agglutination reaction for typhoid or paratyphoid which usually became negative by the end of the third week In two jaundiced patients with cholangeitis, *Bacillus proteus-vulgaris* was grown from bile obtained through the duodenal tube

PAUL J BRESLICH

Immunology

PARESIS TREATED WITH MALARIA WILLIAM MALAMUD and R B WILSON, Arch Neurol & Psychiat **22** 1135, 1929

Practically all patients with dementia paralytica treated with malaria show changes in the serum, though they may be of both negative and positive nature Fifty-four patients with neurosyphilis (of which forty-eight had dementia paralytica and six, other forms of syphilis) were treated at the hospital with tertian malaria Thirteen of these received no other treatment either before or after the malaria treatment, eighteen were previously treated by other methods but received no other treatment following the malarial method, in twenty-three, the malarial treatment was followed by some form of chemotherapy, in most cases tryparsamide The patients were under observation for periods ranging from six to twenty-seven months and were inoculated (intravenously) by tertian malaria from other patients The number of chills ranged from nine to twenty Serologic examinations, including the permeability index, have been done immediately preceding malarial treatment, directly following the malarial treatment and two and six months after the conclusion of the treatment The analyses of the serologic observations recorded shows that there is a difference between the behavior of the permeability index and that of the other serologic reactions

The authors found that while one cannot claim a parallelism between the ordinary serologic observation and the clinical results, one can claim such between the latter and the permeability index (as determined by the Walter bromide method) For instance, the index is high in cases that show a good clinical result and is unchanged or shows a decrease in cases with a poor clinical outcome The changes in the permeability index occur early and generally precede the clinical changes They thus may be of prognostic value, and in cases in which the permeability index began to decrease, reinoculations with malaria have been done However, it is not permissible to tell in cases in which index is becoming normal, whether or not the patient is going to stay well In dementia paralytica, the authors found an increase of iron pigment in the walls of the blood vessels and in the microglia, this was probably due to an increased passage of the substance through the walls of the blood vessels themselves In five cases of dementia paralytica in which the permeability for bromides had been determined before death and found high, the histologic studies showed the amounts of iron also high Such a relationship evidently occurs only in dementia paralytica, for in four instances of other central nerve lesions (dementia praecox, senile dementia, two cases of psychosis with arteriosclerosis and myocarditis), it did not exist The index in these cases was normal or low, while granules were practically absent

G B HASSIN

INTRADERMAL REACTION IN THE DIAGNOSIS OF HUMAN BRUCELLIASIS A S GIORDANO, J A M A **93** 1957, 1929

Killed suspensions of *Brucella abortus* were injected intracutaneously in twenty-five proved cases of undulant fever, producing severe local reactions by the method

employed One hundred controls similarly injected yielded negative reactions in 99 per cent It would seem desirable that this procedure should be carried out in all proved cases of undulant fever to determine its specificity in a larger series of cases

AUTHOR'S SUMMARY

ANTIMENINGOCOCCUS SERUMS G SCHWARTZMAN, J A M A **93** 1965, 1929

The neutralizing potency of antimeningococcus serums can be demonstrated and quantitatively measured by means of the phenomenon of local skin reactivity

The titer of neutralizing antibodies of serums determined by this method bears no apparent relationship to the titer of agglutinins

It is intended to standardize further the method described and to use it for the development of therapeutic serums highly potent in neutralizing antibodies

AUTHOR S SUMMARY

ASTHMA DUE TO ALTERNARIA J G HOPKINS and others, J A M A **94** 6, 1930

In the case of asthma reported here, the attacks occurred in locations in which mold spores were abundant The patient showed extreme skin sensitiveness to a strain of *Alternaria* recovered from a house in which he had attacks Attacks were induced in this patient by the extract of *Alternaria* in powdered form and also by the broth in which it had been grown An attack was also induced by the dry powder of one of the *Curvulella* isolated from another room in which he had attacks He did not give any marked skin reaction to an extract of the latter fungus

SKIN REACTIONS TO FILTRATES OF HAEMOLYTIC STREPTOCOCCI IN ACUTE AND SUBACUTE NEPHRITIS O C HANSEN-PRUSS, W T LONGCOPE and D P O'BRIEN, J Clin Investigation **7** 543, 1929

Skin reactions to the filtrates of hemolytic streptococci were studied in three groups of persons (1) normal persons or patients suffering with various diseases, as controls, (2) patients with acute tonsillitis, and (3) patients with acute and subacute nephritis In the control group, 62 per cent gave positive reactions, only 25 per cent of which were strongly positive, in the tonsillitis group, 95 4 per cent gave positive reactions, and in the nephritis group, 81 4 per cent gave positive reactions, 66 6 per cent of which were strongly positive The positive reaction is regarded as an evidence of allergy toward the hemolytic streptococcus or its products This allergy may play a role in nephritis

FROM THE AUTHORS' SUMMARY

INTRADERMAL IMMUNIZATION OF MONKEYS WITH ONE SET OF INJECTIONS OF POLIOMYELITIS VIRUS C P RHOADS, J Exper Med **51** 1, 1930

By means of a single large dose of poliomyelitis virus, distributed at a number of intradermal sites, active immunity has been produced in *Macacus rhesus* monkeys, as shown by skin neutralization and intracisternal tests In the small series (four animals) of monkeys so treated, neither abortive nor paralytic signs of experimental poliomyelitis appeared

AUTHOR'S SUMMARY

THE RÔLE OF THE RETICULO-ENDOTHELIAL SYSTEM IN IMMUNITY CLAUS W JUNGEBLUT, BARBARA R MCGINN and GLADYS NEWMAN, J Exper Med **51** 5, 15, 1930

Blockade of the reticulo-endothelial system by means of a single injection of india ink caused a marked retention of neoarsphenamine in the blood of guinea-pigs during the first twenty minutes of observation after intravenous injection, as contrasted with the rapid disappearance of the drug from the blood of normal controls Rabbits blocked by a single dose of india ink showed a slower elimination of the

drug from the circulation following the first few hours after intravenous injection than corresponding controls The arsenic content of the liver of mice, which received neoarsphenamine intravenously after a preceding blocking injection with india ink, was appreciably lower than the arsenic content of the normal organ under similar experimental conditions Guinea-pigs blocked by intravenous injection of either india ink or trypan blue succumbed with fatal shock after the intravenous injection of heterophile immune serum, although the time of death was somewhat delayed as compared with normal controls Local blockade of the skin of guinea-pigs with trypan blue inhibited completely the development of the characteristic skin reaction following intracutaneous injection of Forssman serum within the blocked area Infiltration of the skin of guinea-pigs with india ink afforded no protection against the full development of the toxic skin reaction

AUTHORS' SUMMARY

THE RECOVERY OF VACCINE VIRUS AFTER NEUTRALIZATION WITH IMMUNE SERUM PERRIN H LONG and PETER K OLITSKY, J Exper Med **51** 209, 1930

When vaccine virus and its specific antiserum are brought together, no evidence of stable union between them can be determined by the experimental methods employed A definite relationship exists between the degrees of dilution of a neutral vaccine virus-antiserum mixture and the size of the lesion produced by endermic inoculation of such a mixture into rabbits AUTHORS' SUMMARY

EARLY PULMONARY LESIONS IN PARTIALLY IMMUNE ALCOHOLIZED MICE FOLLOWING INHALATION OF VIRULENT PNEUMOCOCCI ERNEST G STILLMAN and ARNOLD BRANCH, J Exper Med **51** 275, 1930

The examination by means of serial sections, of 71 partially immune alcoholized mice which were killed at intervals following the inhalation of virulent pneumococci showed pulmonary localization in 7, or 9 per cent In the case of the mouse the initial lesion of pneumococcus pneumonia is in the alveolar wall, and the exudate into the alveolar lumen occurs secondarily AUTHORS' SUMMARY

THE IMMUNOLOGICAL SPECIFICITY OF CHEMICALLY ALTERED PROTEINS HALOGENATED AND NITRATED PROTEINS ARTHUR WORMALL, J Exper Med **51** 295, 1930

The serologic properties of iodoproteins prepared by a method which involves less drastic treatment of the protein than the methods previously used confirm the observations of Obermayer and Pick and later authors, that iodination of proteins results in a more or less complete loss of species specificity and that a new specificity characteristic for iodoproteins is produced A serologic investigation of brominated proteins has been made for the first time These preparations are only slightly different from iodized proteins in their serologic properties Evidence is submitted which indicates that the radical in iodoproteins which is responsible for the specificity is not iodine but the 3 5 dihalogenated tyrosine grouping Thus, marked inhibition of the iodoprotein (or bromoprotein) precipitin reactions is effected by 3 5 dihalogenated tryosine, not by iodophenol or potassium iodide A reinvestigation has been made of the serologic properties of nitrated and diazotized proteins Proteins nitrated by nitric acid, or by a method which does not appear to have been used for proteins hitherto, namely, nitration with tetranitromethane in neutral or slightly alkaline solution, acquire a new common serologic specificity The nitrated proteins and diazotized proteins show, in confirmation of the results of Landsteiner and Prasek and in contrast to the findings of Obermayer and Pick, little difference in their reactions Thus diazotized proteins and proteins nitrated by either of the two methods mentioned react equally well with any nitroprotein antiserum This interaction exists in spite of the difference in the substituents, either because the substitution with the nitro-group or the diazo-group occurs in the same position in the aromatic nucleus, possibly in the ortho-position to the

hydroxyl group, or because of some other structural similarity In the last connection, it is suggested that both compounds may have a quinoid structure, as has been assumed for orthonitrophenols While this assumption could account for the marked serologic difference of nitrated and halogenated proteins, it should also be mentioned that iodination (and bromination) lead to a disubstitution of halogen in the two ortho positions relative to the hydroxyl group of the tyrosine, whereas nitration of proteins probably results in the formation of mononitrotyrosine and substitution in the tryptophane group as well It is probably impossible, therefore, to draw a strict analogy between nitration (or diazotization) and halogenation of proteins, since a comparison of their immunologic properties is not exactly a comparison of the effect of substituting a different group in the same position Accordingly, it would appear that as yet no definite conclusions can be drawn as to the serologic effect of differences in the chemical nature of various substituents in the aromatic nucleus, although some influence is likely for general reasons All of the chemically altered proteins still retain a small amount of the original species specificity, and the antiserums always react to a slightly greater extent with the homologous antigen than with similarly treated antigens prepared from heterologous serums This difference occurs even when the possibility of some unaltered protein's being present in the antigen can be practically excluded

AUTHOR'S SUMMARY

THE BACTERIAL GROWTH INHIBITOR (LACTENIN) OF MILK F S JONES and HENRY S SIMMS, J Exper Med **51** 327, 1930

In this paper, the substance in milk which inhibits bacterial growth is called lactenin It is stable for one and a half hours at p_H 4 and at p_H 10 and for longer periods in neutral solution It is not associated with salts and carbohydrates and may be separated from them by dialysis Lactenin is removed by agents which precipitate the proteins of whey Part of these proteins may be hydrolyzed by tryptic digestion, and the resulting split products, together with the salts and sugar, may then be removed by dialysis without appreciable loss of lacteninic activity This dialysis may be performed in a concentrating dialyzer, under sterile conditions and at low temperature, thus reducing the solution to small volume The material may then be completely desiccated and kept three months with practically no loss of activity The residue, on treating this dried material with salt solution, is 200 times as active as the original milk, on a dry weight basis The size of the hemolytic zones of the scarlet fever streptococcus grown on a medium containing lactenin is found to furnish a simple and reliable measure of lacteninic activity

AUTHORS' SUMMARY

CHOLESTEROL AND ERGOSTEROL IN FIXATION TEST FOR SYPHILIS E MALTANER, J Immunol **18** 11, 1930

The sensitizing action of cholesterol is not due to ergosterol, which itself has sensitizing power

THE TOXICITY OF HUMAN SERUM FOR THE GUINEA PIG AS AFFECTED BY ABSORPTION OF AGGLUTININS I DAVIDSOHN and SUSAN GRIFFITH RAMSDELL, J Immunol **18** 23, 1930

Serums from persons treated with immune serums and showing a toxicity of the heterophilic type for the guinea-pig, when treated with the red cells of this animal for the removal of agglutinins do not lose such toxicity When the same serums are absorbed in the same way with sheep cells, as a heterophilic antigen the toxicity is usually, but not always completely, removed thereby The experiments further indicate the heterophilic nature of the antibodies concerned in the toxicity But there is also the possibility that in these cases sheep cells constitute an incomplete antigen or that another factor, as yet unidentified, is contained in such serums

AUTHORS' SUMMARY

THE ACTION OF A CYTOTOXIC ANTISERUM ON TISSUE CULTURES J S F NIVIN, J Path & Bact **32** 527, 1929

Cytotoxic properties were developed in rabbit's serum as a result of injections of suspensions of mouse embryos Early evidence of cytotoxic action was shown by the inhibition of emigration of fibroblasts in tissue cultures, later actively growing cells were killed after exposure to the serum and never exhibited further growth when transferred to suitable mediums Slow death of cells was followed by autolysis, rapid death seemed to inhibit autolysis Experiments on normal epithelial and carcinoma cells produced changes in staining reaction The carcinoma cells became shrunken, their cytoplasm clear and incapable of staining and the nuclei pyknotic The cytotoxic activity of the serum was greatest in the presence of complement although it contained a thermostable body capable of producing a certain amount of cellular damage by itself In addition to its cytotoxic qualities the serum was also hemolytic and precipitating The serum had more effect on tissues of the rat than on those of unrelated species such as the rabbit, guinea-pig and chicken

GEORGE RUKSTINAT

SMALLPOX DURING ANTIRABIES TREATMENT E CONSEIL, Arch Inst Pasteur de Tunis **18** 387, 1929

A boy bitten by a dog known to be rabid was first treated for rabies on the thirty-third day following the bite He had received two injections when he developed a mild case of smallpox Treatment for rabies was suspended for nearly four weeks, after which it was continued for twenty days The patient recovered without symptoms of rabies

M S MARSHALL

PROPHYLACTIC IMMUNIZATION OF APES WITH B C G AND SCHRODER'S VACCINE O KIRCHNER and E A SCHNEIDER, Beitr z Klin d Tuberk **72** 109, 1929

In these experiments, thirteen mamadryas pavianes were used Four animals were immunized with 50 mg B C G, four animals were immunized three times with Schroder's vaccine, and five animals were kept as controls Two and one-half months after immunization, all animals were infected intracutaneously with 0 003 mg of tubercle bacilli The development of tuberculosis was definitely delayed in the B C G animals, but not prevented, their period of survival was definitely longer than that of the other two groups Schroder's vaccine did not exert a noticeable influence on the virulent reinfection

MAX PINNER

ATTEMPTS TO ALTER THE COURSE OF SPONTANEOUS TUBERCULOSIS IN RHESUS MACACUS BY PROPHYLACTIC VACCINATION WITH B C G H H KALBFLEISCH and A NOHLEN, Beitr z Klin d Tuberk **72** 121, 1929

The general plan of this study was to expose both vaccinated and nonprepared control animals to a tuberculous infection through coresidence with a monkey which had been made tuberculous by an intrapulmonic injection of tubercle bacilli Three vaccinated and three control animals were kept in cages in the open air, eight vaccinated animals and an equal number of control animals were kept in cages in heated stables The interval between immunization and exposure varied between two weeks and seven months The period of exposure varied between one and twenty-three days Of eleven B C G animals, five developed tuberculosis, of eleven controls, five developed the disease All six animals, three vaccinated and three normal, which were kept in the open air failed to develop tuberculosis (period of exposure eleven and eighteen days) Of the sixteen animals which were kept in warm stables, ten developed tuberculosis, including five controls and five vaccinated animals

Conclusions B C G proved to be harmless for the animals studied in this regard An immunizing effect was not observed under the stated conditions

MAX PINNER

ON THE FORMATION OF ANTIBODIES IN THE POSTERIOR CHAMBER J KIMURA, Zentralbl f d ges Ophth **22** 164, 1929

If serum containing precipitins is injected suboccipitally into the subarachnoid space of a normal rabbit, the precipitins are thrown out into the circulation rapidly, and seventy-two hours later no trace of them can be found in the posterior chamber

After active immunization, hemolysins and agglutinins appear seven days after the last injection into the aqueous humor of the rabbit, and the quantity of both immune bodies is much less than that in the blood The relative quantity rises during the course of immunization and is at its height more than thirty days afterward counting from the date of the last injection Meanwhile, of course, the absolute quantity of the immune bodies in the aqueous humor and in the blood decreases with the termination of the immunization This relative increase is perhaps due to the changed permeability of the tissue and to the disappearance of antigen from the organism

Precipitins against various serums and bacteria were found by the author in the aqueous humor of the rabbit after active immunization Their relative quantity to that of the blood was from $1/1\,000$ to $1/250$ (serum precipitin) and from $1/1\,250$ to $1/500$ (bacterial precipitin)

In most cases, after a single injection of the antigen directly into the subarachnoidal space of the normal rabbit no precipitin was found in the cerebrospinal fluid (in only two of ten cases, and in weak reaction) But if these injections are repeated from two to three times, the precipitin occurs both in the blood and in the cerebrospinal fluid The author could not decide whether the immune body was formed locally in the subarachnoidal space, or whether the precipitin filters over from the blood stream

If the antigen is injected directly into the posterior chamber of a previously well immunized rabbit, the precipitins of the blood, because of meningeal irritation, pass over in great quantities into the posterior chamber With the decrease in this irritation, the precipitins that have passed over are thrown out again from the posterior chamber

The author also immunized rabbits with two kinds of antigens (beef serum and egg albumin), and then injected one kind of serum directly into the posterior chamber For instance, if beef serum is injected and the course of the production of precipitins in the posterior chamber is followed, it can be established that the precipitin for egg albumin now disappears as early as within a week, and only the antibeef precipitin increases again and remains for some time

This proves that the tissue cells of the periposterior chamber which previously had acquired a certain status will, through a single injection of antigen actively and persistently, form the corresponding antibody

On the basis of the foregoing observations, the author concludes that there are two sources for the precipitin in the posterior chamber (1) that which passes over from the blood stream, and (2) that which is formed locally in the periposterior chamber The latter source cannot be given with complete assurance

CHARLES WEISS

THE CAUSE OF THE NONCOAGULABILITY OF MENSTRUAL BLOOD M VON FALKENHAUSEN and A PARGIALIS, Zentralbl f Gynak **52** 2738, 1928

Menstrual blood obtained from the uterus with the methods of Driesen and Hermstein does not contain any complement This lack was found to be responsible for the absence of coagulability in menstrual blood During the menstrual period, the uterus contains an increased amount of anticomplement and antithrombin

W C HUEPER

THE TITRATION OF DIAGNOSTIC TUBERCULIN Y WATANABE and H KAWAMURA, Ztschr f Immunitatsforsch u exper Therap **60** 131, 1929

The authors found that no reaction occurred in ninety healthy calves into which intracutaneous injections of 3 cc of tuberculin twice diluted were made The results were the same with healthy guinea-pigs

If the calves were infected subcutaneously or intravenously with bovine tubercle bacilli, a positive reaction to an intracutaneous injection of tuberculin was obtained without exception, one month after infection Guinea-pigs that were infected by intravenous injection showed no reaction the first week, but 80 per cent were positive to tuberculin by the second or third week An intracutaneous injection of a 1 100,000 dilution into tuberculous calves generally gave positive reactions Most of the tuberculous guinea-pigs reacted to a 1 200 dilution but not all to a 1 1,000 dilution

The intracutaneous injection of glycerin bouillon into tuberculous guinea-pigs that showed a positive tuberculin reaction called forth a local reddening This reaction was negative if the bouillon was diluted more than twice Protein-free glycerin bouillon containing salt solution and 0 5 per cent phenol gave no reaction on intracutaneous injection Tuberculin that was prepared from nonpathogenic acid-fast bacilli gave a positive reaction in tuberculous calves but to a much less degree than true tuberculin The importance of the control of tuberculins for diagnostic purposes is indicated by the fact that in tuberculous animals a variability in reaction occurs The authors employ for this control the intracutaneous injection method of Mantoux and Roux Calves were found to be the best experimental animals, guinea-pigs are useful although much less responsive For the titration a standard tuberculin is required which must give in tuberculous calves a positive reaction in a 1 10,000 dilution, and in guinea-pigs in a 1 40 dilution For testing calves, dilutions of 1 1,000, 1 10,000, 1 100,000 and 1 1,000,000 should be used, for guinea-pigs, from 1 40 to 1 400 The amount for injection was 0 3 cc for calves and 0 02 cc for guinea-pigs The standard tuberculin and the test tuberculin should be injected in two parallel rows into the skin of the abdomen, in this way the effect of tuberculin can be fairly accurately titrated

The authors recommend this method for the control of diagnostic tuberculins For the test at least two animals should be used in order to minimize the individual variation The minimal dilution of the tuberculin which evokes the same reaction as the standard tuberculin should be read and the value of the tuberculin specified

ROY C AVERY

Tumors

STUDY OF A MENINGIOMA IN SUPRAVITAL PREPARATIONS, TISSUE CULTURE AND PARAFFIN SECTIONS RICHARD C BUCKLEY and LOUISE EISENHARDT, Am J Path **5** 659, 1929

Tissue cultures have been made of twenty-two meningiomas presenting a histologic structure similar to that of the other meningiomas cultured In twenty-one of these tumors there was an abundance of collagen, psammoma bodies and cellular whorls, certainly not the type of a tumor from which a growth of tumor cells in tissue culture could be expected In but one instance, that in the case herein reported, has there been an outgrowth of cells which could be considered as tumor cells, although cells regarded as clasmatocytes were observed As stated, the tumor of the case presented was considered to be a meningioma from its gross appearance and from the histologic study of both the paraffin sections and the supravital preparations In the tissue cultures there was an abundant growth of similar cells always in the form of a reticular pattern These cells resembled the cells of the tumor as seen in the supravital preparations They were found not to have phagocytic properties They were considered to be the tumor cells of the meningioma, and of mesodermal origin as their pattern of growth was like that of cells of mesodermal origin They did not resemble cells which are fibroblastic in origin, for no substances were seen to be laid down by the cells

AUTHORS' SUMMARY

NEED FOR STATISTICS OF CANCER MORBIDITY F C WOOD, Am J Pub Health **20** 11, 1930

The advantages from making cancer notifiable would be Increase in knowledge of the diseases now grouped under cancer, earlier diagnosis because the physician would be checked up later if a tumor should escape prompt diagnosis, inhibition of the activities of quacks who would be exposed to publicity through the notification, improvement in death certificates, and valuable information would accumulate in regard to the rate of growth of tumors, the life-length of patients and the types of cancer that offer chances of cure Mortality records are not as important by far as records showing the number of persons who have cancer in a community and how long they live after cancer is discovered How otherwise can the value of operation, the roentgen rays or radium be determined accurately?

TUMORS OF THE CAUDA EQUINA CHARLES A ELSBERG and KATE CONSTABLE, Arch Neurol & Psychiat **23** 79, 1930

Tumors of the cauda equina form, in the experience of Elsberg and Constable, 15 per cent of all the extradural and intradural tumors A tumor was found in the cauda equina in twenty-eight of forty-five cases studied, in two, instead of a tumor, enlarged blood vessels were found In seventeen cases no tumor was found, and the condition was classified as inflammatory (neuritis) Two instances of each type are recorded by Elsberg and Constable with operative observations Histologically, the tumors (sarcomas, fibroblastomas, gliomas) could not always be classified definitely, and because of their unusually large size they were named "giant" tumors They are usually encapsulated and most likely develop within the arachnoid Extradural tumors, derived from the bone or the intervertebral cartilages were rare (only four of the twenty-eight tumors of the cauda equina were extradural tumors) The tumors occurred in patients less than 40 years of age, while neuritis was more frequent after the fortieth year The clinical picture was the usual combination of pain, weakness in the lower extremities, atrophies, changes in the tendo achilles reflex and urinary disturbances Roentgenologic changes could be demonstrated in the tumors but not in the neuritis group The spinal fluid in tumors was often xanthochromic, and the globulin and total protein contents were increased (important!) without an increase in cells, while in neuritis, xanthromia was unusual, increase of globulin was not frequent, and that of total protein was never observed In 59 per cent of patients with tumors a positive subarachnoid block was present, and in 44 per cent of the cases of neuritis this was partial or even complete As to the injection of iodized poppy seed oil 40 per cent, this has been done in only five patients with tumors and in three with inflammatory lesions of the cauda equina In all the cases of tumor, the information gained from such injections was of some value, but was considered by the authors much less important than a careful neurologic examination and the study of the total protein content The spinal puncture should be done below the usual level, as low as the fifth lumbar or even in the first sacral interspace If no fluid is obtained, a puncture at a higher level should be tried

G B HASSIN

RETINOBLASTOMA IN HOMOLOGOUS EYES OF IDENTICAL TWINS W L BENEDICT, Arch Ophth **2** 545, 1929

Benedict reports the cases of twin girls, one of whom had a tumor in the left eye and the other a tumor in each eye There are several reasons for considering these girls identical or enzygotic twins The occurrence of the tumors in similar situations in the left eyes lends support to the theory that these tumors develop from fetal rests that probably go back to the single ovum from which such twins develop

BILATERAL ACOUSTIC NEUROFIBROMA (FIELD SURVEY OF A FAMILY OF FIVE GENERATIONS WITH BILATERAL DEAFNESS IN THIRTY-EIGHT MEMBERS) W J GARDNER and CHARLES H FRAZIER, Arch Neurol & Psychiat **23** 266, 1930

In one family (covering five generations with 217 members), thirty-eight persons developed bilateral deafness, fifteen of these subsequently became blind, in each case the blindness was preceded by vomiting The prevailing lesion, according to the evidence obtained, was bilateral acoustic fibromas A clinical pathologic report of a case is described by Gardner and Frazier, with an addition of a clinical report of forty-seven members of the patient's family One patient, a man, aged 28, died three days after an operation for an acoustic tumor which was diagnosed The necropsy revealed two tumors, one on each side On the left side, the eighth nerve was seen to plunge into the tumor at a distance of 1 5 cm from the point of exit from the brain stem No tumors were found elsewhere in the brain, dura or cerebral nerves The histologic examination showed a neurofibroma, and with the Gross-Bielschowsky staining method the nerve fibers in the tumor itself were demonstrated Another patient, a woman, aged 26, was deaf (three years) and blind (six months), had had headaches and hallucinations of persecution, the speech was thick, the pupils did not react to light She died with symptoms of a tumor of the brain At necropsy, two symmetrically placed tumors were found in the pontile angles (about 1½ inches [3 8 cm] each) According to the microscopic report, they were "probably similar to tumor of nervus acusticus" No associated evidence of von Recklinghausen's disease in the family was found In this family, bilateral deafness was the prominent symptom and transmitted from generation to generation

G B HASSIN

GENERALIZED MELANOSIS S C WAY and S E LIGHT, J A M A **94** 241, 1930

A remarkably extensive generalized melanosis is described in a woman, aged 66, the primary focus apparently being a pigmented mole, 3 5 cm in diameter, on the back The condition set in rapidly, and in the early stages resembled purpura hemorrhagica

CYTOLOGIC OBSERVATIONS OF A LUMSDEN RAT SARCOMA IN VITRO E S HORNING and K C RICHARDSON, Australian J Exper Biol & M Sc **6** 143, 1929

The behavior of the cell types during growth in cultures in vitro was observed, and the apparent malignant component was determined

CHEMICO-PHYSICAL STABILITY AND CANCER ARTHUR EASTWOOD, J Hyg **29** 117, 1929

The prominence recently given to the Rous sarcoma has increased the confusion of hypotheses about malignancy With a view to clarification, one may say that there are three simple hypotheses of outstanding importance, viz (1) the living virus hypothesis, which regards living viruses as the actual and effective cause of both the avian and the mammalian disease, (2) the autogenous enzyme hypothesis, which ascribes both diseases to the development within living cells of an ens malignatis resembling an enzyme rather than a virus, and (3) the "chronic irritation" hypothesis, which explains mammalian malignancy on this principle and considers fowl sarcoma to be of a different nature

In the present paper, I start with acceptance of the third hypothesis and proceed to treat the subject as part of a more general problem in cellular variation, confining myself to the influence of chemicophysical stabilization as a factor in the production of variants After illustrating the importance of this factor as a general principle of variation, I discuss in more detail its significance in "bacteriophage" phenomena, fowl sarcoma and mammalian malignant disease From this aspect, the "ubiquitous virus" and the mysterious ens malignatis may be replaced by a common principle determining cellular variation

AUTHOR'S SUMMARY

THE HISTOGENY OF TERATOMA G W NICHOLSON, J Path & Bact **32** 365, 1929

A retroperitoneal cystic tumor 11 5 by 8 5 by 5 cm was found attached to the abdominal aorta, left kidney and left suprarenal gland of a 4 months old female child Histologically derivatives of all germinal layers were demonstrable The nervous elements were more abundant than the epidermis and its derivatives and ependyma, in places forming a choroid plexus, lined the major cavity Of particular interest was a metanephros which was thought to be an inclusion of the upper renculi of the child's left kidney, since the suprarenal gland was separated from this kidney by 4 cm of tumor tissue and because only five pyramids were found in the left kidney

GEORGE RUKSTINAT

AFFINITY OF TUMOR CELLS FOR LEAD N KAWATA, Beitr z path Anat u z allg Path **82** 259, 1929

The action of colloidal lead in causing regression of tumors has been ascribed by some to a specific affinity of the tumor cell for lead and other heavy metals In order to determine whether tumor tissue has any greater affinity for lead than other tissues, Kawata used for the quantitative determination of lead in the tissues the extremely delicate method of von Hevesdy A radioactive indicator, thorium B, was added to the lead chloride solution to be injected and the radioactivity of the mixture determined electroscopically From the radioactivity of the ashed tissues after injection of the mixture, the lead content of the tissue could be determined Mice with transplanted carcinoma were used The tissues examined were tumor, lung, liver and kidney The time of the examination was from twelve to seventy-two hours after the injection, examination after longer periods was not possible because the material lost its radioactivity after seventy-two hours The tumor tissue had no greater affinity for lead than the other tissues, liver, in fact, showed a much higher lead content than tumor or the other tissues Any action that colloidal lead may have on tumor cells is not therefore due to a greater affinity on their part for lead It might be due to greater susceptibility to the harmful effects of lead, but necrobiotic changes were no greater in the tumors of mice into which injection was made than in those of controls Kawata believes that the deleterious effect that colloidal metals may have on tumor tissue is due to the effect of the metal on the blood vessels of the tumor

O T SCHULTZ

CHONDROBLASTOMA GROWING IN THE VEINS M KOSA, Virchows Arch f path Anat **272** 166, 1929

In a girl, 13 years of age, a large tumor of right femur grew through the lumen of the veins into the heart, even into the sinus venosus The pulmonary arteries filled with tumor down to the capillaries There was no destructive growth and no metastases, the tumor could be separated easily from the vessel wall The tumor thrombus measured 70 cm in length from the femur to the heart The structure was that of different forms of cartilage, mostly adult In the veins, the tumor has lost its blood vessels It was, so to speak, a tissue culture of cartilage rather than a tumor

ALFRED PLAUT

REPEATED OCCURRENCE OF SARCOMA IN A COLONY OF CHICKENS C CHAMPY and C BLUMENSAAT, Virchows Arch f path Anat **272** 205, 1929

Many tumors in chickens are overlooked unless systematic autopsies are done In four castrated animals, one rooster and three hens, sarcoma was found All four had been in good health before No work with Rous sarcoma had been done in the place in question None of the uncastrated animals developed sarcoma, and only fifteen of seventy had been castrated The tumors developed between eight and eighteen months after operation In the operative scars in hens small

nodules of sarcoid tissue have been observed The authors suggest that tissue of that kind may be susceptible to some "rather unspecific and rather ubiquitous virus" One of the tumors was situated in the radix of mesentery, a rare location for fowl sarcoma There were no metastases in the lymph nodes, but there were many small nodules in the liver and parietal peritoneum, and much ascites The tumor was mostly myxomatous

ALFRED PLAUT

PRIMARY TUMORS OF THE PLEURA EDELTRAUD KLX, Virchows Arch f path Anat **272** 650, 1929

Three primary diffuse tumors of the pleura are described, two of them carcinomatous and one sarcomatous The author lays stress on the intermediate character of the pleural lining cells, which in Maximow's tissue cultures have yielded epithelium as well as connective tissue The name mesothelioma is considered best, the name endothelioma for these tumors should be abolished

ALFRED PLAUT

RELATION OF SEX TO TUMOR DEVELOPMENT H GUNTHER, Ztschr f Krebsforsch **29** 91, 1929

Basing his conclusions on the study of a wide range of statistical material, the writer makes the following summary of the relations of sex to tumor The undue frequency of cancer in the female is due entirely to the tendency of the female sex organs and biliary tract to this disease, in the male, there is an established greater incidence of cancer of the stomach, kidney, urinary bladder, and especially of the lip, tongue, larynx and esophagus Cancer is more frequently missed in the male than in the female The importance of exogenous factors in the sex distribution of cancer is usually overemphasized Sex plays no part in the distribution of metastases, except for the high frequency of such involvement of the ovary With sarcoma there is little difference between sexes, but sex plays a part in determining the type of tumor more likely to involve certain organs, carcinoma and hypernephroid tumors of the kidney being commoner in the male, sarcoma of that organ in the female The female thyroid is more prone than the male to the development of miscellaneous tumors Lipomatosis dolorosa and atrophicans are considerably more frequent in the female than in the male

H E EGGERS

THE ROFFO REACTION L M CORREA, Ztschr f Krebsforsch **29** 112, 1929

The Roffo diagnostic reaction for cancer is here considered under three sections, the first dealing with the origin of the test, the second with its diagnostic value, and the third with its theoretical aspects The writer concludes that while the test is not specific, it is of some real confirmatory value Its cause is to be sought in a physicochemical alteration of the serum, in connection with the adsorptive power of this for carbon dioxide

H E EGGERS

THE PRODUCTION OF TUMORS BY THE BLOOD OF TUMOR ANIMALS F BLUMENTHAL, Ztschr f Krebsforsch **29** 549, 1929

When blood drawn from the superficial veins of the inoculable tumors of rats and mice, and less constantly that drawn from the heart, was injected into other animals, tumors were induced which in all but one case corresponded to the parent tumor Inoculation of the serum gave negative results, but clotted blood taken up in Ringer's solution, red cells and white cells all gave positive results There are, of course, two possible explanations the presence of free tumor cells in the blood, or the existence of a tumor-producing agent which attaches itself to suitable colloidal material In order to achieve positive results the parent tumor must have attained a suitable size

H E EGGERS

STUDIES OF TUMOR CYTOLOGY B LIPSCHUTZ, Ztschr f Krebsforsch **29** 554 and 564, 1929

In cases of human round cell sarcoma and in a case of nevocarcinoma, the writer found intracellular structures similar to those previously reported by him in various animal tumors He believes that their absence in a case of lymphosarcoma may indicate a differential criterion in such tumors From the fact that they were absent in nonmalignant nevus cells in the early case observed, he believes that their presence may be a hallmark of malignancy Beyond this he carefully abstains from attaching to them any special significance

H E EGGERS

CANCER STATISTICS OF THIRTY-FIVE YEARS H JUNGHANS, Ztschr f Krebsforsch **29** 623, 1929

From the autopsy statistics of the Dresden Institute, comprising 4,192 cases of cancer in 36 408 examinations, the writer derives the following principal conclusions In this time, there has been a considerable increase in cancer in men and a slight decrease in women In men, the organs were involved in the following relative frequencies the digestive system, the respiratory tract, the urogenital system and other organs In women in the hospital, the order was the digestive tract, the urogenital system, other organs, the respiratory tract, in women in the nursing home the frequency of the first two was reversed In men there was a diminution of cancer of the entire digestive tract, and a considerable increase in that of the respiratory tract, in women there was a diminution of urogenital cancer and a slight increase of cancer of the digestive tract and the respiratory passages Each bodily tract appeared to have its own age incidence, these have not changed during thirty-five years Except for the organs peculiar to either sex, age incidence was alike in the two sexes

H E EGGERS

MORPHOLOGIC STUDY OF CELL DIVISION IN CANCER CELLS IN VITRO R GOLDSCHMIDT and A FISCHER, Ztschr f Krebsforsch **30** 281, 1929

Studying from the morphologic point of view the phenomena of cell division in tissue cultures of two mouse carcinomas, it was found that atypical mitoses were relatively rare, only two instances of tripolar division being observed among hundreds of mitoses The number of chromosomes appeared to be usually reduced, since the normal count for the mouse is accepted as 40, and most of the dividing cancer cells showed chromosomes numbering from 32 to 36 Occasionally very low counts, from 24 to 28, were observed, but normal counts were not infrequent Some very large cells showed counts in the neighborhood of 80 The number of chromosomes was not increased in the two instances of tripolar division

H E EGGERS

Medicolegal Pathology

THE MEDICOLEGAL SIGNIFICANCE OF LESIONS PRODUCED BY ELECTRICITY DOMENICO MACAGGI, Boll r Accad med, Genova **1** 927, 1929

The lesions produced by the electric current are minutely analyzed, and its physical effect, such as mechanical, thermal, etc, as well as the chemical (electrolytic) action on the tissues, is well presented There are no characteristic appearances which can be conclusively demonstrated in instances of death by electricity From a medicolegal point of view, in cases of electrocution one has to establish first the electric trauma and then whether the current was strong enough to produce lethal effects, further, to evaluate the eventual concurrent causes of death and finally to consider carefully the differential diagnosis between accident and suicide

E L MILOSLAVICH

INFANTICIDE BY CUTTING THE THROAT D PEROTTI, Riforma med **45** 648, 1929

Three large, deep cuts were found on the throat, shoulders and abdomen of a new-born infant Many superficial cuts were scattered all over the body and involved only the upper layers of the skin The wounds appeared anemic The umbilical cord was not ligated The cadaver was otherwise clean All the internal organs showed pronounced anemia The floating test of the lungs proved that the infant had breathed It was assumed that the severe anemia was the result of the umbilical hemorrhage, and at first it could not be positively stated if the many wounds were inflicted during life or after death In the latter instance there was the possibility of an attempt to dismember the body It was considered that histologic examination of the lungs would solve the problem As the wound of the throat had severed the large blood vessels of the neck and the trachea and esophagus, the blood would have reached the bronchi and been aspirated into the pulmonary alveoli if the child had been alive and breathing If, however, the throat had been cut post mortem, the blood would not have penetrated beyond the bronchioles, due to the absence of respiratory movements Microscopic examination of the lungs disclosed that the alveoli were filled with blood, this proved that the deep cut through the entire neck and throat was inflicted during life The multiplicity of the cut wounds, their irregular distribution and their apparent superfluous nature led one to assume that the mother was in a perturbed state of mind

E L MILOSLAVICH

ISO-AGGLUTININ IN PERICARDIAL FLUID F J HILZER, Klin Wchnschr **8** 2427, 1929

The pericardial fluid may be of value in determining the blood group, especially in the case of cadavers in which the blood has undergone severe changes or in infants and fetuses The fluid, it appears, may be even richer than blood serum in agglutinin

STATUS THYMICUS IN SUICIDES AS MORPHOLOGIC EXPRESSION OF THE DISTURBED INTERNAL SECRETION A PARABUTSCHEW, Virchows Arch f path Anat **273** 134, 1929

In twenty-five suicides, the thymus, sex glands, thyroid, hypophysis and suprarenal gland were examined The thymus was considerably heavier than normal (compared with Hammar's figures) Some cases showed persistence of the thymus but with some increase of medulla In others, different degrees of regression were found There is a relation between the lack of involution in the thymus and the degree of morphologic changes in the sex glands In the testicles the interstitial tissue was found thick, with compression of the canaliculi Occasionally round cell infiltration was found Leydig cells were few In many instances spermatogenesis was absent The status thymicus is not a part of a status thymicolymphaticus

ALFRED PLAUT

HISTOLOGIC CHANGES AFTER DEATH BY BURNING WILHELM VOGT, Virchows Arch f path Anat **273** 140, 1929

Eight cases were examined The main changes were in the spleen and liver Circumscribed hyaline masses were found in the walls of small arteries in the spleen Debris of red cells and phagocytosis of red cells were seldom found The germ centers of the spleen often contained fragments of nuclei and accumulations of epithelioid cells, these changes were found in children only The vessels of the liver contained many leukocytes with highly fragmented nuclei This corresponds well with the rapid decrease in the white cell count The suprarenal glands were examined in four cases, they showed no important changes

ALFRED PLAUT

Technical

A Silver-Starch-Gelatin Method for the Demonstration of Spirochaetes in Single Tissue Sections Alfred Scott Warthin, Am J Syph **13** 454, 1929

A modification of the author's previously reported method is described, by which a much higher percentage of positive results may be obtained when used on histologic lesions of syphilis The success of the method depends on establishing a set of conditions — the most important being the hydrogen ion concentration — under which, silver precipitation takes place more rapidly on the parasite than on its surroundings, thus making possible its demonstration in the tissue The proper hydrogen ion concentration is obtained by the use of dilute nitric acid just before placing the tissue in the silver nitrate mixture

Pearl Zeek

The Effect of Intrabronchial Injections of Iodized Poppy Seed Oil 40 per Cent R B Bettman, J Kelly and N Crohn, Arch Surg **19** 471, 1929

The authors worked on dogs, and found that the instillation of poppy seed oil 40 per cent did not cause any pneumonia or any cellular reaction Most of the oil was expelled rapidly by coughing, but small amounts may remain for several months

N Enzer

Value of Blood Amylase Estimations in the Diagnosis of Pancreatic Disease R Elman, N Arneson and E A Graham, Arch Surg **19** 943, 1929

The authors have devised a new method for the determination of blood amylase The method consists essentially in plotting a curve of the change in viscosity of a starch solution which is undergoing inversion under the influence of the amylase in the blood In a series of cases showing no pancreatic symptoms and no indication of pancreatic disease they plotted a normal value varying from 4 3 to 6 8 units They found the same values in a series of eleven cases that came to autopsy and in which no evidence of pancreatic disease was found In twenty-three cases giving a clinical picture of pancreatic involvement, they found an increase in blood amylase varying from 7 8 to 15 and in a few a decrease of from 0 5 to 3 1 units Twenty-one of these cases were verified at autopsy to have some lesion of the pancreas These observations seem to indicate that the chief source of amylase is in the pancreas, and the explanation for the increase in the blood amylase seems to reside in the increased absorption from the pancreas following obstruction to the pancreatic ducts In those in which the low values were found, atrophy of the pancreatic parenchyma was demonstrated, and this would seem to be a late stage of pancreatic disease Jaundice of itself did not affect the blood amylase, as shown in a series of several cases of hemolytic jaundice The article contains the protocols of their cases studied and a detailed description of the method

N Enzer

A Simplified Stain for Oxidase Granules S Moschkowski, Munchen med Wchnschr **76** 1800, 1929

Fix in 90 per cent ethyl alcohol for three minutes, wash in water, flood the preparation with a freshly prepared aqueous benzidine-peroxide solution (water saturated with a crystal of benzidine, filtered, and to each cubic centimeter of the filtrate add from ½ to 1 drop of 1 per cent hydrogen dioxide [perhydrol diluted thirty times]), wash in water, and counterstain with Giemsa

Edwin F Hirsch

The Meinicke Test for Syphilis E Meinicke Munchen med Wchnschr **76** 1965, 1929

Several improvements in technic are described

Society Transactions

CHICAGO PATHOLOGICAL SOCIETY

Regular Meeting, March 10, 1930

HENRY C SWIANY, *President, in the Chair*

CAVERNOUS HEMANGIECTASIS IN NODULAR GOITER GEORGE M CURTIS and P A DELANEY

The complete report will appear in the ARCHIVES

CONGENITAL ATRESIA OF THE TRICUSPID ORIFICE, DEFECTS OF THE INTRAVENTRICULAR AND INTERAURICULAR SEPTUM AND BICUSPID PULMONIC VALVE PAUL J BRESLICH

The complete report will appear in the ARCHIVES

LIPOID NEPHROSIS PHILLIP SHAPIRO

Three cases of lipoid nephrosis were described One had proceeded to nephrotic contraction and another was combined with amyloidosis The pathogenesis of lipoid nephrosis was traced, and histologic criteria for it were defined The confusion between nephrosis, nephrotic component and amyloidosis was discussed The congo red test was described as an aid in clinical differentiation of these conditions

HISTOLOGIC CHANGES IN THE DUODENUM OF RATS EXPOSED TO HIGH ENVIRONMENTAL TEMPERATURES W C HUEPER

In experiments with rats which I conducted several years ago to determine the effect of high environmental temperatures on the p_H of the duodenal content and the type of the duodenal bacterial flora I observed some interesting changes in the histologic preparations of the duodenums of these rats, which were kept in cages at from 40 to 41 C The examination of the p_H of the duodenal content revealed a distinct increase above the normal level determined by examinations of control animals Moreover there was marked increase in the number of bacteria above the normal number present and an ascendence of the colonic bacterial flora into the duodenum The results of these original and fundamental experiments were later confirmed on dogs by Arnold in his subsequent and more elaborate studies originating from the same laboratory

As the histologic phase of this problem has not found consideration in the work of this author and my own observations have remained thus far unpublished, I wish to supplement from a histologic point of view the bacteriologic observations reported in the literature on this subject

The duodenums of the rats killed were removed in toto and placed in Zenker's solution After proper technical preparation, serial sections were made The microscopic examination of the sections showed the cylindric epithelium defective in places, especially at the crests of the folds Occasionally small superficial ulcers were observed, restricted in their extent to the mucosa and covered by a fibrinopurulent exudate The mucosa and submucosa contained always a more or less dense lymphocytic and leukocytic infiltration The tissues were hyperemic

The histologic changes in the duodenum described are interpreted as evidence of the effect of the marked disturbance of the process of duodenal self-sterilization and possibly may be due to an increased permeability of the duodenal mucosa to bacteria and their toxins The action of the neutral or alkaline content on the duodenal epithelium may represent a contributory factor in the causation of these changes

---

AMERICAN ASSOCIATION OF PATHOLOGISTS AND BACTERIOLOGISTS

HOWARD T KARSNER, *Secretary*

Annual Meeting, New York, April 17 and 18, 1930

GEORGE H WHIPPLE, *President*

THE IDENTITY OF ANIMAL ANAPHYLAXIS AND HUMAN ALLERGY (PROTEIN HYPERSENSITIVENESS) BRET RATNER and (by invitation) HELEN L GRUEHI, NEW YORK

The blood serums of a patient with bronchial asthma who was sensitive to horse dander and of guinea-pigs sensitized to horse dander by inhalation were passively transferred to the normal human skin and to normal guinea-pigs Positive passive transfers were obtained both from the transfer of the human serum and from that of guinea-pig serum This criss-crossing of the human reagin and of the anaphylactic antibody suggests that the two antibodies are identical

SKIN REACTIONS TO THE SOLUBLE TOXIC SUBSTANCE OF THE COLON BACILLUS BERNHARD STEINBERG, TOLEDO, OHIO

Skin reactions to the soluble toxic substance and to the washed, killed bacterial bodies of a twenty-four hour culture of a colon bacillus were made Reactions read at the end of twenty-four hours appeared in a large number of normal adults and children who were tested In people with infections caused by the colon bacillus, the reactions to the soluble toxic substance and to the vaccine were either absent or greatly diminished in size and degree It is assumed that the skin reaction is of an antigen-antibody mechanism Only occasionally, a normal person had agglutinins against the colon bacillus Immunization with the soluble toxic substance of the colon bacillus reduces the size and degree of the skin reaction against it The soluble toxic substance apparently has weak antigenic properties

PENETRATION OF ANTIBODIES IN THE CENTRAL NERVOUS SYSTEM JULES FREUND, PHILADELPHIA

Antibodies can be extracted from the brain and spinal cord of rabbits actively or passively immunized with typhoid bacilli

The titers of the antibodies in the extracts of the brain and cord depend on the titer of the blood serum In actively immunized rabbits the following numerical relationships exist between the titers of the serum and of the organ extracts The ratio of the titer of the serum is to the titers of extract of brain and of the spinal cord about as 100 is to 0 8, the titer of the serum is to the titer of the cerebrospinal fluid as 100 is to 0 3 In passively immunized rabbits the titer of the serum is to the titer of brain and spinal cord extract as 100 is to 0 7

The antibodies recovered from the brain are not due to the presence of blood in it for perfusion of the brain does not reduce its antibody content appreciably

Antibodies penetrate into the spinal fluid from the blood even in the absence of inflammation of the meninges When the penetration is completed, the following numerical relationship exists between the titer of the serum and that of the cerebrospinal fluid 100 0 25

The penetration into the cerebrospinal fluid of antibodies injected intravenously proceeds at a slow rate, being completed only several hours after the immune serum had been injected The penetration of antibodies into the tissue of the brain occurs at a very rapid rate It is completed within fifteen minutes

It is unlikely that when the immune serum is injected intravenously the antibodies reach the brain tissue by way of the cerebrospinal fluid, or that the antibody titer of the cerebrospinal fluid is lower than that of the brain extract, and that antibodies penetrate faster into the tissue of the brain than into the cerebrospinal fluid

ETIOLOGY OF PSITTACOSIS CHARLES KRUMWEIDE and (by invitation) MARY McGRATH AND CAROLYN OLDENBUSCH, NEW YORK

About Jan 15, 1930, the Department of Health became cognizant that there was illness among persons in contact with sick parrots The first consideration, naturally, was whether or not *Bacterium psittacosis* was causing the disease Of a total of twenty-nine sick or dead parrots received only one showed the presence of *B psittacosis* This parrot had died in a pet shop, and none of the persons coming in contact with it developed any sign of illness Among the cases of illness in human beings, there were eleven who had had contact with ill parrots and who were finally considered as having cases of psittacosis Cultural and serologic tests showed no evidence of infection by *B psittacosis* The agglutination tests were repeated up to one month after the onset of the disease These observations seemed definitely to exclude *B psittacosis* as the etiologic agent of the disease

Fortunately, in one instance there became available an ill parrot and two ill persons who had come in contact with the parrot Inoculation of parrots with materials from these three cases caused disease and death, and material from these parrots likewise caused death when inoculated into other parrots When filtered through Berkefeld V filters, the organ emulsions likewise caused disease and death Two successive filter passages with the parrot strain and with one of the human strains were successful These results and the failure to find any common bacterial factor seemed definitely to indicate that the disease, psittacosis, was due to a filtrable virus Mice were found to be susceptible to the virus

After this demonstration was completed, Bedson, Western and Simpson (London) reported similar observations Since then, Levinthal (Berlin), Armstrong McCoy and Branham (Washington) have also demonstrated the presence of a filtrable virus

A STUDY OF THE EFFECT OF TUBERCLE BACILLUS LIPOIDS ON THE TUBERCULIN REACTION ESMOND R LONG and (by invitation) ARTHUR J VORWALD, CHICAGO

Doses of from 0 02 to 0 05 mg of purified soluble tuberculin protein cause an intense interstitial cellular infiltration and profound degeneration of the cells of the spermatic tubules in the testes of tuberculous guinea-pigs (tuberculin reaction) Equal doses of purified lipoids in fine colloidal suspension cause a slight interstitial wandering cell infiltration and no degeneration Mixing tubercle bacillus fatty acid with tuberculin protein enhances the tuberculin action of the latter in that the fluid element of the exudate is greater and the amount of fibrin present is increased No change in the intensity of cellular infiltration or necrotizing effect on the testicular tubules or spermatocytes has been noted The increased output of fluid suggests that an increased degree of toxic action on the capillary endothelium has occurred Ultramicroscopic examination has shown no change in the degree of dispersion of the colloidal particles incident to mixing the two colloidal preparations

THE SPECIFIC CYTOTOXIC ACTION OF TUBERCULIN ON TISSUE CULTURE JOSEPH D ARONSON, PHILADELPHIA

The specific cytotoxic action of tuberculins prepared from the various acid-fast bacteria on the bone-marrow and the spleen of tuberculous and of non-tuberculous guinea-pigs was studied by means of tissue culture

It was found that bone-marrow and spleen of tuberculous guinea-pigs, when planted in plasma from tuberculous or nontuberculous guinea-pigs, fail to migrate and to multiply in concentrations of tuberculin prepared from either the human or the bovine type of tubercle bacillus, and on the other hand that such concentrations of tuberculin do not interfere with the migration and multiplication of cells from the bone-marrow or the spleen of nontuberculous guinea-pigs When high dilutions of tuberculin are added to explants of bone-marrow or spleen of tuberculous guinea-pigs, migration of cells occurs but the cells are shrunken and rounded whereas the cells of tissues from the nontuberculous animals are larger, irregular in outline and vesicular

Tuberculins prepared from the avian type of tubercle bacillus, from the various acid-fast bacilli found in fish, snakes, frogs and turtles from several different strains of the leprae bacillus and from a number of different acid-fast saprophytes did not interfere with the migration and multiplication of the cells from explants of bone-marrow or spleen of tuberculous or of nontuberculous guinea-pigs Similarly, tuberculoprotein, the phosphatid and the carbohydrate fraction of the human type of tubercle bacillus fail to inhibit the migration and multiplication of the cells from the bone-marrow or spleen of tuberculous or of nontuberculous animals

The addition of plasma from a tuberculous guinea-pig to explants of the bone-marrow or spleen of a nontuberculous guinea-pig does not render such explants susceptible to the cytotoxic action of tuberculin prepared from the bovine or the human type of tubercle bacillus

PROGRESS IN CHARACTERIZING ANTIBODIES AND ANTIBODY ACTION STUART MUDD, BALDUIN LUCKE and (by invitation) MORTON MCCUTCHEON and MAX STRUMIA, Philadelphia

Analysis of the mechanism by which blood serum promotes the phagocytosis of bacteria and other foreign particles has been continued Serums which promote phagocytosis of bacteria or of red blood cells have been found invariably to cause certain definite changes in the surface properties of their homologous antigens, namely, increased cohesiveness, decreased surface potential difference and increased resistance to wetting by oil Similarly, but with certain exceptions, the serums that cause these characteristic changes in the antigen surfaces also promote phagocytosis The phagocytosis-promoting, agglutinating and surface effects are in quantitative correspondence A similar striking correspondence has been found between the agglutinating, surface and phagocytosis-promoting effects caused by the euglobulin and pseudoglobulin fractions of antibacterial serums

Following the technic of F S Jones, collodion particles were coated with precipitinogen and then treated with homologous precipitin serums and their protein fractions The same serums and serum globulin fractions cause specific precipitation, agglutination or phagocytosis according to the conditions under which they are allowed to react with their homologous antigens

Agglutinating, surface and phagocytosis-promoting effects have thus been found to be quantitatively parallel This quantitative correspondence of the several effects of a serum or serum globulin fraction has been found both for antibacterial and for antiprotein serums and their globulin fractions All of the effects are consequences of the deposit of sensitizing serum substances on the antigen surface The surface deposit so produced by maximal sensitization with homologous rabbit antiserum has similar properties whether deposited on acid-fast bacteria, on erythrocytes or on precipitinogen-coated collodion particles, i e, the sensitized surface has wetting properties characteristic of protein, is cohesive and has an iso-electric point between p_H 5 5 and 5 8 These are the properties also found for specific (immune) precipitate

These studies thus bring evidence of a new sort in support of the following simple generalization The combination of antigen and antibody is determined by specific chemical affinities The effects following this combination, namely, precipitation, agglutination, changes in surface properties and phagocytosis, are consequences of the properties primarily of the antibody-protein combined with and deposited on the antigen surface

THE BUCHNER RENAISSANCE IN IMMUNOLOGY W H MANWARING, Stanford University

There is convincing evidence that injected antigens undergo a series of biochemical "hybridizations" in animal tissues, and suggestive evidence that the resulting antigen-"hybrids" become semipermanently "symbiotic" with these tissues, both terms, of course, being used metaphorically

There is convincing evidence that some of these antigen-"hybrids" have properties simulating those of specific antibodies, but no proof thus far that they are identical with these antibodies

The "hybridization" metaphor, however, furnishes a logical and consistent explanation of all known facts of specific immunologic adaptation, and is the nearest approach to a complete immunologic theory that can be formulated at the present time

There is no proof at the present time, however, that antigen "hybridization" is the only mechanism of specific immunologic adaptation, and no suggestion that such "hybridizations" are not supplemented by nonspecific functional mutations and hypertrophies

THE CYTOCHROME OF BACTERIA C B COULTER and F STONE (by invitation), New York

The intracellular pigment cytochrome, which is found in all living plant and animal cells except the anaerobic bacteria, was originally observed by McMunn, and was rediscovered and renamed by Keilin The presenters studied the occurrence of this pigment particularly in the *corynebacterium* group of bacteria The four absorption bands observed by McMunn and Keilin are found by spectroscopic examination in suspensions of living bacteria of all the members of the group In addition is found a band lying in the red portion of the spectrum Filtrates of cultures show no selective absorption except in the case of toxin-producing diphtheria bacilli, and in filtrates of these the intensity of selective absorption runs parallel with the amount of toxin present The characteristic absorption spectrum may, therefore, be that of the toxin itself It has been possible by spectroscopic examination alone of different filtrates to determine the presence and approximate the amount of diphtheria toxin

RHINOSPORIDIUM SEEBERI REPORT OF THIRD NORTH AMERICAN CASE CARL V WELLER, Ann Arbor, Mich

The clinical and structural features of the third case of *Rhinosporidium seeberi* from North America are described The stages of the development of the parasite, as well as the character of the accompanying granulation tissue are illustrated, as far as is possible The foreign body giant cell reaction, which succeeds the rupture of the old cysts, is described for the first time

CELLULAR IMMUNITY IN ACQUIRED AVIAN MALARIA P R CANNON and (by invitation) W H TALLIAFERRO and L G TALLIAFERRO, Chicago

Previous papers in this series by Talliaferro and Talliaferro demonstrated a definite immunity to superinfection in canaries infected with *Plasmodium cathemerium* and indicated that this immunity is not associated with a humoral antibody, as serum from birds with latent malarial infections was without both protective and curative action on the development of the parasites in normal birds

The authors presented observations on the cellular reactions in the tissues of normal birds and of ones superinfected The tissues were fixed, sectioned and stained with Maximow's hematoxylin-eosin azur II In the normal birds it was found that phagocytosis begins as soon as parasitized red blood cells are injected, being most pronounced in the spleen and liver, and consisting in the ingestion of the parasite-red cell combination rather than of individual merozoites In spite of a constant rate of phagocytosis, many parasitized red blood cells escape ingestion and sporulation occurs with extension of the infection Thus, the process advances until a crisis occurs on approximately the eighth day, after which time the rate of phagocytosis apparently exceeds the rate of reproduction and the infection becomes latent

In the superinfection, however, the parasitized red blood cells injected are removed from the circulating blood stream extremely rapidly, so that within twenty-four hours there are few survivors to sporulate This altered reactivity seems to be due to an actually increased number of actively phagocytic cells within the spleen and to a lesser degree in the liver Because of this, the parasitized red cells are quickly removed from the blood and the superinfection terminated The mechanism of the immunity, then, is an increased rate of phagocytosis by the cells of the reticulo-endothelial system, and results from an increased number of actively functioning phagocytic cells, which are present in birds with latent infections

THE PROTECTIVE EFFECT OF SPLENIC TRANSPLANTS IN ALBINO RATS AGAINST BARTONELLA MURIS ANEMIA DAVID PERLA and (by invitation) J MARMORSTON-GOTTESMAN, New York

Bartonella muris anemia is an infectious disease occurring in albino rats following the removal of the spleen It may be transmitted into normal young rats and young rabbits by the injection of whole blood from anemic splenectomized rats, and the strain of the virus may be maintained by repeated passage in young rats

The presenters succeeded in isolating a strain of *Bartonella muris* anemia from normal nonsplenectomized adult rats by injecting the blood of the anemic rabbit into young rats This demonstrates the fact that the adult rat is a carrier of the virus *Bartonella muris* anemia It is further found that splenectomy in suckling rats is not followed by *Bartonella muris* anemia since during the suckling period the rat is not a carrier of the virus

Trypanosoma lewisi infection in normal adult rats is accompanied by *Bartonella muris* anemia The trypanosome infection produces profound changes in the pulp tissue of the spleen Functional injury to this pulp tissue produces the same effect in the adult albino rat as splenectomy in lowering the resistance to the *Bartonella* infection

Less than one fourth of the spleen left in situ is sufficient to prevent the development of *Bartonella muris* anemia Autoplastic transplants of small pieces of splenic tissue made six weeks prior to the removal of the spleen prevent the development of *Bartonella* anemia in more than 50 per cent of the rats, whereas transplants made four weeks prior to splenectomy do not protect Histologic examination of the transplants in the animals that were protected from the anemia reveals complete regeneration of all elements of the splenic tissue, both malpighian bodies and pulp cells In the rats that were unprotected the splenic transplants showed complete regeneration of the malpighian bodies, but exhaustion destruction of the pulp tissue This demonstrates that the pulp cells of the spleen are specific in the protective mechanism of the rat to *Bartonella muris* anemia

AVIAN TUBERCULOSIS IN NORMAL AND VACCINATED RABBITS E M MEDLAR, Mt McGregor, N Y

Virulent avian tubercle bacilli when inoculated subcutaneously into rabbits cause a local abscess which ruptures and heals The rabbits do not develop generalized tuberculosis and do not succumb to the subcutaneous inoculation

Rabbits inoculated intravenously with 1 mg or more of virulent avian tubercle bacilli always succumb to the infection within from two weeks to a month A study of the microscopic changes of such animals shows extensive involvement of the spleen, liver and bone-marrow The cell chiefly concerned in the reaction is the mononuclear leukocyte or monocyte Many lesions show slight abscess formation due to the participation of the neutrophil The presence of "myeloid" giant cells, which are megalocarvocytes, in the spleen liver and lungs, suggests a similarity between the process and Hodgkin's disease

The daily leukocyte records of the animals show a close parallelism with the microscopic changes found In practically every instance, the leukocyte picture became septic a short time before death occurred

A group of rabbits, that had been inoculated six months previously with living human tubercle bacilli, was given an intravenous injection of avian tubercle bacilli, the same amount being given to a group of controls on the same diet The injection of human tubercle bacilli had caused a local abscess which ruptured and healed, as did the subcutaneous inoculation of avian tubercle bacilli The animals were in excellent physical condition and had normal blood counts at the time the inoculations were given

One of these rabbits died within seven days The remaining animals lived from four to five months These animals showed marked involvement of the kidneys and joints There were a few tuberculous foci in the lungs and liver The microscopic changes were similar to those seen in chronic tuberculosis in human beings

Daily leukocyte records showed the establishment of a septic leukocyte picture long before the death of the animal This corresponds closely with the leukocyte picture in chronic, progressive cases of tuberculosis in human beings Here again the leukocyte picture closely parallels the microscopic changes present

THE USE AND THE REASONS FOR THE USE OF THIOCRESOL TO STIMULATE WOUND HEALING STANLEY P REIMANN, Philadelphia

Since Hammett has shown that the sulphydryl group (—SH) is essential for cell division, this group, when presented in the proper concentration to cells, should stimulate mitosis The healing of wounds is essentially a matter of cell proliferation, consequently —SH compounds should hasten healing The question to which group the —SH radicle should be attached is apparently not of essential importance although it is of practical interest Of a number of compounds tried, thiocresol proved advantageous Theoretically, at least, when this compound is split, the small amount of cresol present tends to inhibit bacterial growth while not interfering materially with mitosis of the tissue cells On old wounds, ulcers, etc, it is used as a wet dressing in a solution of 1 10,000 Certain practical points must be observed, such as the maintenance of proper growth balance between epithelium and granulations, etc

EXPERIMENTAL STUDIES IN POLIOMYELITIS RICHARD THOMPSON (by invitation), New York

Efforts to adapt the virus of poliomyelitis to the rabbit organism and to produce poliomyelitis in rabbits by testicular injection and by injection into the brain after testicular passage produced no evidence that the virus could be adapted in this manner Suggestive symptoms produced in very young rabbits were duplicated in nonspecifically treated and in uninoculated controls The admixture of a vaccine virus adapted to the rabbit organism, with the poliomyelitis virus in similar injections and passages, did not aid the adaptation The virus of poliomyelitis, whether alone or mixed with vaccine virus, does not survive twenty-four hours in the testicle of the rabbit

No neutralizing substances against poliomyelitis virus could be produced in rabbits by the repeated intraperitoneal and intradermal injection of poliomyelitis virus or of poliomyelitis-vaccinia virus mixtures

Although attempts to infect monkeys by intrastomachic injections, after bile irritation of the mucosa, were entirely negative, evidence was obtained that repeated intrastomachic injection after bile irritation may produce an appreciable degree of immunity

No evidence could be obtained that the cellular elements of the blood contain the virus in any greater proportion than the whole blood

SPECIFIC AND SPECIAL INFLAMMATIONS OF THE NERVOUS SYSTEM SIMON FLEXNER, New York

During the past twenty-five years, largely because of the extensive epidemics of meningitis, poliomyelitis and encephalitis which have prevailed in that period, much attention has been directed to infections of the central nervous organs At the present time, attention is being concentrated on encephalitis, of the epidemic form or of the variety to which the designation "postvaccinal and allied conditions" is being applied The important fact that herpes virus is capable of inducing encephalitis in rabbits, guinea-pigs, rats and mice, and occasionally in monkeys, has come to play a significant part in the supposed etiology of epidemic encephalitis

The purpose of this report is to draw attention to the multiple incitants of encephalitis, and hence to distinguish between encephalitis as a clinicopathologic condition and epidemic encephalitis, which appears to be a specific infectious disease Just as there are multiple incitants for the clinico-anatomic condition to which the term "diphtheritis" is applied, and a specific incitant of the disease diphtheria, so, probably, there are also many sources of encephalitis and, probably, a single etiologic source of epidemic encephalitis If this view is correct, then the mere production of encephalitis in animals does not imply the experimental reproduction of epidemic encephalitis

CHRONIC FOCI OF INFECTION PRODUCED EXPERIMENTALLY VIRGIL H MOON, Philadelphia

The usual methods of animal inoculation are not suited to the study of chronic focal infections They do not approximate the conditions present in diseases in human beings A new method for producing foci of infection in animals is reported

Applicators of cotton are loosely wound on no 20 or 22 rustless wire so that slight force will slip the swab from the wire A trocar and cannula are inserted into the region to be inoculated, the trocar is then withdrawn, leaving the cannula in place The applicator is dipped into the material to be inoculated and is inserted through the cannula The swab is pushed beyond the end of the cannula Then when the wire is withdrawn, the end of the cannula pushes off the cotton into the tissue or body cavity The cannula is then withdrawn

The method is a simplified procedure for implanting infection in a porous substance within the tissues The foreign substance serves to maintain the infection against effective body resistance The method is well suited for producing chronic foci in subcutaneous and intramuscular areas and in the body cavities By exposing the viscera infection may be implanted in the spleen, liver, gallbladder or other structures In such instances, a smaller cannula and correspondingly smaller applicators are used

Dogs, which are so resistant to ordinary inoculations that they are seldom used for the purpose, are easily infected by this method When inoculated with streptococci, masses of infected granulation tissue from 3 to 5 cm in diameter develop in a few weeks The inoculated organisms are regularly recovered from the area and frequently from the substance from other organs Streptococci have been recovered in pure culture from six to ten months after implantation

Only young dogs and rabbits have been used in these experiments The pathologic changes resulting from these chronic foci of infection include verrucose endocarditis with rheumatic nodules in the heart musculature the skeletal muscles and the subcutaneous tissue, acute vegetative endocarditis with multiple infarctions,

periarthritis, osteo-arthritis with ankylosis and deformity, nephritis of various forms, splenic atrophy and fibrosis, proliferative endarteritis and others

REPORT OF THE LYMPHATIC TUMOR REGISTRY GEORGE R CALLENDER, Washington, D C

At the last report to this Society 100 cases had been contributed to the Lymphatic Tumor Registry of this Association, the period covered being approximately four years During the past year, sixty-three cases have been received, a rate of increase of 250 per cent I wish to take this opportunity to thank the members of this Association for this increased support The response to my plea is gratifying, but the rate of receipt of these cases is still far below what it ought to be Very few of the cases received during the past year have been cases in which the diagnosis was easy

The greatest value can be reached from this Registry only if the maximum effort is made by those registering cases to follow-up the cases to their conclusion, or over a sufficient number of years to ascertain the character of the condition I believe that the difficulties in diagnosis and prognosis of this class of tumors are present because individuals and groups do not follow-up their cases I further believe that we shall be able to offer definite assistance in diagnosis when and only when we have a sufficient number of cases which have been so followed-up as to determine their nature and the changes which occur during the course of the pathologic processes

Tumor Registry, 1930

Lymphosarcoma	16	
No mobilization in blood	1	
With leukemia (acute)		
Lymphoblastoma (confined to lymphatic structures)		
No mobilization in blood	0	
With mobilization in blood	15	
Leukemic	6	
Reticulum cell sarcoma	22	
(One case with lymphatic leukemia)		
Hodgkin's Disease		
Cellular	10	
Sclerosing	18	
Sarcomatous	12	
Mycosis fungoides (and tuberculosis)	1	
Lymphoblastic erythrodermia	1	
	—	102
Myelogenous leukemia	4	
Myeloma	1	
Chloroma	3	
Infectious mononucleosis?	2	
Undiagnosed	14	
Lympho epithelioma	5	
Carcinoma	12	
Inflammation (1 tuberculosis)	7	
	—	48
		150

The accompanying table presents a summary of the first 150 cases in the Registry This summary is not intended as a classification, but it does show the divisions found to apply to the cases so far received

Please make an additional effort to send in, particularly, your doubtful cases

HISTOLOGIC STUDIES OF THE THYROID GLAND J WILLIAM HINTON (by invitation), New York

Since the question frequently arises as to what constitutes normal and abnormal thyroid tissue, sections were obtained for study from people whose deaths were due to accidental causes The patients varied in age from stillbirth to 89 years As a means of comparison, there were also sections from people who had died of acute and chronic diseases

By Jan 1, 1930, sections from 107 cases had been studied It was intended to get sections on a large series of cases, rather than serial sections on a few cases, as these would represent more nearly the pathologic reports that are received from operative specimens So far there have been eighty cases of accidental death from which sections of the thyroid have been studied There were also twenty-seven cases in which the patients had died of some systemic disease, it was thought best to divide these into two groups (1) cases of acute diseases, or in which the patient died in less than three weeks from the onset of the disease, (2) cases of chronic disease or of disease extending over months or years There were sixteen deaths due to acute diseases, but the sections in this group failed to reveal any definite histologic changes There were eleven patients who died of chronic diseases, no striking changes were found in the thyroid

It was stated that sections were taken from people of various ages, and that a rather large group has been studied with the hope of finding a uniform histologic picture for normal people of different ages So far, no conclusions have been drawn as to what is normal tissue for the different ages, the author disagrees with Hertzler's statement that "For practical purposes I am convinced that if one keeps in mind the various changes normal to the different periods of life as above indicated, the histology of the thyroid gland will be found to be fairly constant, rendering it unnecessary to assume that it undergoes changes unknown in other organs"

In studying patients with thyroid diseases, one is at times unable to place the case in one of the groups given for the classification of goiter, such as adolescent, adenomatous or exophthalmic, and one frequently sees cases change from one type to another while under observation From this histologic study it would also seem that a diagnosis made purely on the histologic picture without taking into consideration the clinical history and laboratory data is also open to error, and it seems that one will be forced to consider the different types of goiter merely as a stage of a continuous disease and not as a definite clinical entity, as has been believed in the past

PSEUDOTUBERCULOSIS OF THE THYROID GLAND PLINY F MORSE, Detroit

The favorable prognosis that has heretofore been attached to so-called tuberculosis of the thyroid has been the subject of frequent comment by various writers It has been known that although the thyroid gland operated on for some type of goiter might show, on microscopic sections, large numbers of so-called tubercles, the patients usually run a favorable course and react in the usual manner to the thyroid operation, without later succumbing to tuberculous infection, either in the thyroid region or elsewhere

The cases of so-called tuberculosis of the thyroid have usually failed to present tuberculous lesions in other parts of the body, and the postoperative search for other signs of tuberculous infection has been negative

The cases that have been diagnosed at Harper Hospital as tuberculosis of the thyroid have run a favorable course, and all of the patients are living and well at the present time, several years after operation, with the exception of one patient, who died seven years after operation from acute intestinal obstruction—cause unknown

The histologic study of the lesion seems to justify the assumption that probably the epitheloid reaction resembling tuberculosis is a result of either some other infection, or some metabolic disturbance which causes the colloid of the gland to assume the role of a foreign body From a study of the cases, the impression was gained that the tubercle results as an effort to absorb and wall off colloid which has presumably undergone some change that makes it a foreign body On the basis of these arguments, the presenter was inclined to think that the question of tuberculosis of the thyroid should be left open for further review, in that strong doubt is cast on the assumption that the Koch bacillus is the etiologic factor

CHRONIC THYROIDITIS CHARLES L CONNOR and (by invitation) H H SEARLES, San Francisco

The designation "thyroiditis" dates back to the early days of Kocher His students, and surgeons in general, retain the name There is some doubt, however, among pathologists as to whether such a condition actually exists We wish to present a selected group of cases which, for want of a better name, have been classified as chronic toxic thyroiditis, and to illustrate a possible way in which they might develop

It has long been known that acute infections and intoxications may cause degeneration of the thyroid epithelium and acini, and that as a result colloid and cell debris are spilled into the interstitial tissues This phenomenon is usually regarded as terminal, but it is evident from a study of the literature and twenty-five cases of thyroiditis in the University of California Hospital that minor infections or intoxications, perhaps even emotional shock and overstimulation of the sympathetic system, may induce a similar degeneration of glandular elements Since such patients do not die, there is an opportunity for a reaction to take place, and this is usually in the form of lymphoid cell infiltration or proliferation Plasma cells and monocytes may be present, the latter, sometimes in the form of giant cells, with pseudogiant cells are formed by masses of colloid which contain the degenerate nuclei of epithelial cells

The most constant picture is a rather diffuse desquamation of epithelium, the nuclei appearing in the previously contained colloid within the acini, and a diffuse infiltration with lymphocytes The latter cells, as well as the plasma cells, seem to arise in situ, as evidenced by the number of mitotic figures present in them Stages in the degeneration of thyroid epithelium appear to consist of swelling with fatty degeneration, desquamation, loss of nuclei and later a breaking down of the substantia propria, so that agglomerations of cytoplasmic masses occur These eventually disappear, but the process in some cases becomes progressive and prolonged even after (as far as can be determined) the initial stimulus has disappeared This tendency to progression gives rise to the condition known as chronic thyroiditis, and with the great overgrowth of lymphocytes and the concomitant proliferation of fibroblasts, the condition known as Riedl's struma may be the end-result

Coincident with the degeneration of thyroid cells a more or less active regeneration usually takes place This may be insufficient to take care of physiologic demands, and so symptoms of hypofunction or even myxedema may occur Or there may be a sufficient regeneration, and therefore a histologic picture of a moderately hyperplastic gland (associated with thyroiditis), but no symptoms of thyroid dysfunction This regeneration may proceed to any degree, a group of our cases exhibited the signs of thyroiditis (pain, pressure on the trachea, hoarseness, etc) along with the vague symptoms of hyperfunction, another group showed histologically a marked overregeneration and hyperplasia associated with frank and definite symptoms of exophthalmic goiter During this process of regeneration the lymphocytes gradually become less diffuse and clump together, and in late stages definite lymph follicle formation occurs—the "lymphoid exhaustion" picture of Dr Warthin A further stage, merely conjectured, would be a frank hyperplasia of the thyroid with characteristic lymphoid cell accumulations and without signs of thyroiditis or cellular degeneration It would seem that a small proportion of typical thyroid hyperplasias might develop in this manner It would be unwise, however, to infer that any considerable number pass through these stages

STRUMA OF OVARY ALFRED PLAUT, New York

Three specimens of ovarian struma (from three hospitals) were studied The time elapsed since the operations was too short for definite clinical judgment The patients were 47, 35 and 55 years of age The gross aspect of the specimens adds nothing new to the descriptions in the many reports in the literature In all three specimens, other tissues were found besides the thyroid tissue, thus confirming the generally accepted opinion that the ovarian struma is a thyroideal teratoma In

two of the specimens, all of the tissues were benign, in the one from a woman, aged 47, a large portion of the tumor was solid and gave a picture of carcinoma in the gross as well as microscopically

The thyroid character of the ovarian struma was obvious in all three specimens The staining qualities of the contents of the follicles were typical The three differently colored types of secretion were found with the staining method of E J Kraus Papillary protrusions with high cylindric epithelium and epithelial buds with high cells were present, giving the picture often seen in struma of the thyroid gland It was possible to compare the structure of the malignant tumor in the one specimen with the rare type of trabecular adenoma of thyroid gland as described by Masson The fact that this tumor was gelatinous did not preclude the possibility of its having a common origin with a thyroid-like structure True mucin has been described in adenoma of the thyroid by Nikolsky and by Wegelin This possibly common origin was further suggested by the fact that mucin-producing solid tumor and typical thyroid struma were intimately mixed in large areas And, of more consequence, there were follicles in which the mucin and the typical thyroid secretion were found together The ropy appearance of the mucin in the fixed tissue and the red color of the mucicarmine form a distinct contrast with the homogeneous, pale blue-staining thyroid secretion It must be stated that the structure of the carcinoma-like tumor is similar also to some ovarian carcinomas, but the variety of ovarian carcinoma is so great that there is hardly any carcinoma which cannot be compared with one or another type of ovarian cancer

All three specimens were examined for iodine The method of Kendall and Richardson (J Biol Chem **43** 161, 1920) was used In one specimen, four analyses showed no iodine, while controls with normal thyroid gland gave figures from 1 7 to 1 88 In the second specimen, 0 025 mg of iodine was found per gram of dried ovarian struma This figure compares with the figures of Robert Meyer (0 014 mg) and those of Neu (0 02 mg) In the specimen which contained the carcinoma-like mass, the thyroid-like tissue and the solid carcinoma-like tissue were examined separately Two analyses of the thyroid-like tissue showed 0 673 and 0 634 mg, while the solid, cancer-like tumor gave only 0 004 mg Controls with normal thyroid showed 2 652 and 2 116 mg Further controls were made with a carcinoma of the breast and an adenocarcinoma of the uterus Both were negative The figure 0 673 seems to be the highest for the iodine content of an ovarian struma ever obtained, and it seems high enough to help in asserting that these thyroid-like ovarian tumors can behave functionally in a way similar to thyroid gland The fact that one specimen, in spite of looking exactly like the others under the microscope, contained no iodine is certainly important (No difference could be noted in the Mallory stain) Most of the examinations for iodine that have been reported in the literature do not reveal any iodine in the ovarian struma In the face of the positive observations, however, it did not seem admissible to draw definite conclusions from the frequent absence of iodine The microscopic pictures were not suggestive of embryonic thyroid tissue, which may be found free from iodine

Some of the cystic cavities in the specimens contained material which looked different from the clear, brownish-yellow thyroid secretion in the struma-like portions This material gave no reaction for pseudomucin None of the specimens contained structures which could be compared with a pseudomucinous or serous cyst adenoma Glandular structures, as may be found in any ovary that is examined in many sections, were present No statement could be made concerning their possible connection with ovarian strumas

The older literature on the subject deals mainly with the problem whether or not the thyroid-like tissue originated in the ovary itself This question is settled There remains the problem Why does thyroid tissue occasionally grow to such large masses in the ovary? This problem is similar to the one concerning the predominance of the skin, teeth and bone in the dermoid cysts The observations of Erwin Bauer, that in his specimen the struma started from the surface epithelium, are obviously correct, judging from the pictures given in his paper The literature deals mainly with the general conclusions that Bauer has drawn

from his serial sections and justly disapproves of them But the fact remains that ovarian struma can originate from the surface epithelium With the exception of Walthardt's three specimens, no complete serial sections are reported, and therefore nothing is known concerning the relations between the surface epithelium of the ovary and the ovarian struma

The frequent presence of ascites is clinically important because, generally, ascites together with an ovarian tumor is taken as a sign of bad prognosis, while ovarian struma has proved to be benign in most instances

BLOOD VESSEL INVASION IN ADENOMAS OF THE THYROID GLAND SHIELDS WARREN, Boston

From 1923 to 1927 inclusive, thirty-four cases of adenomas of the thyroid showing definite invasion of blood vessels by clusters of tumor cells, but lacking any other evidence of a malignant condition, were found among the thyroid material received from the Lahey Clinic Clinically, none of these cases showed any evidence of a malignant condition Two cases showed recurrence, one in three months and one in ten months, both patients died with multiple metastases of the lungs, ten months and two years, respectively, after operation The other thirty-two patients were living and well, from seven to two and one-half years after operation, except for one patient who died of carcinoma of the uterus two and one-half years after the thyroid operation Thus, blood vessel invasion may be the only sign of a malignant condition in a small proportion of adenomas of the thyroid gland

SKELETAL METASTASES IN CARCINOMA OF THE THYROID ISAAC LEVIN, New York

This study represents a continuation of several years of investigation of the pathogenesis of skeletal metastasis in carcinoma The formation of these metastatic tumors in the bone, in the opinion of the author, depends not so much on the channels of transportation of the tumor emboli as on the interaction between the proliferation of the transported tumor cells and the protective resistance of the adjoining normal tissue

The significance of the thyroid in this study is due to the phenomenon that presumably benign tumors of the thyroid and even normal thyroid tissue may form metastases

From the clinical standpoint, the importance of the subject lies in the fact that the whole clinical symptom-complex may be due to the skeletal metastatic tumors, while the primary carcinoma in the thyroid may cause no symptoms In the cases reported, the condition in the bone was considered clinically to be primary, and the diagnosis was made only on the biopsy material

THE INTERACINAR EPITHELIUM OF THE THYROID GLAND ALAN RICHARDS MORITZ, Cleveland

By means of silver impregnation of the periacinar reticulum and wax plate reconstruction of thyroid gland, it was shown that new acini are formed by intra-acinar and extra-acinar proliferation of the epithelium The extra-acinar proliferation is in the form of small solid or tubular buds, which, when cut tangentially, may have the appearance of rests of undifferentiated interacinar epithelium In hyperplastic areas of normal glands and in glands the seat of pathologic hypertrophy and hyperplasia, a labyrinthine intercommunication of acini exists

THE SIGNIFICANCE OF THE LYMPHOID TISSUE IN EXOPHTHALMIC GOITERS AND SO-CALLED TOXIC ADENOMAS ALDRED SCOTT WARTHIN, Ann Arbor, Mich

Exophthalmic goiter and "toxic adenoma" always present the pathologic picture of hyperplasia of the primitive lymph nodes of the thyroid, hyperplasia of the thymus and the other anatomic stigmas of the thymico-lymphatic constitution In addition, they present certain constitutional peculiarities of their own kind Not

all cases of thymicolymphatic constitution will present the syndrome of Graves' disease, although all cases of the latter will possess the chief anatomic stigmas of this constitution All forms of Basedowian or Graves' symptoms represent the abnormal reactions of a primary pathologic anomaly Basedowian or Graves' disease, "toxic goiter" and "toxic adenoma" are pathologic reactions potentially predetermined in the individual at birth by virtue of his constitutional anomaly The potential Graves' constitution may be recognized histologically in the thyroids of very young children To the underlying pathologic and clinical entity of exophthalmic goiter, toxic goiter and toxic adenoma I have applied the term "Graves' constitution"

THE ESSENTIAL THYROID CHANGES IN GOITER DAVID MARINE, NEW YORK

Perhaps the greatest difficulty in understanding and classifying the essential changes in goiter has arisen from the fact that the thyroid is a very labile tissue, capable of rapid progressive and even more rapid regressive changes in all periods of life In the life history of most goiters there are many of these cycles, and, obviously, in a gland normally composed of retention cysts, each succeding cycle becomes morphologically more complicated and more difficult of interpretation This tissue lability and the long duration of goiter have led to the inclusion, as Virchow pointed out seventy years ago, of a great variety of secondary and terminal degenerative changes with the essential changes

The clue for their separation was furnished by Baumann's discovery of iodine as a normal constituent of the thyroid The extensive studies on the relation of the morphologic changes to the iodine store, in both naturally occurring and experimentally produced goiter, which resulted from this discovery, have made it possible to work out a scheme of the sequence and relative importance of the major features of the thyroid cell and to separate the primary from the secondary changes

Another cause of confusion has been the attempt to bring the morphologic features into specific relationship with prevailing clinical classifications of human thyroid diseases, rather than to bring the clinical classifications into relation with the morphology, which is clearly a more constant and a more natural standard Thyroid hyperplasia is analogous to leukocytosis and has no more specific relation to metabolic diseases than leukocytosis has to infectious diseases

Comparative studies have shown that the essential changes in goiter are similar in all the species of animals studied, and that they can be arranged in a comparatively simple scheme When large series of human thyroids (autopsy) are studied in the light of the comparative pathology, the same cycle of changes is found, so that one can arrange these morphologic changes in a scheme that adequately presents the type and sequence of the changes which compromise the cell cycle in goiter

The thyroid is so labile that to insist on too strict a definition of "normal" invites quibbling and defeats the object of establishing a practical standard If the gland does not exceed 25 gm in weight, if the follicles are filled with colloid, if the iodine store is at least 0 2 mg per gram of fresh tissue and if the epithelium is low cuboidal, there is an adequate standard of normal

All of the work that has been done, whether experimental regeneration following partial removal or the spontaneous or experimental production of goiter, shows that thyroid enlargement begins as a work hypertrophy and hyperplasia, and that in their developmental stages they are essentially the same for all animals The sequence of events appears to be as follows There are a decrease in the store of iodine, a decrease in the stainable colloid, an increase in the blood supply and a change in the epithelium from low cuboidal to high cuboidal and columnar All gradations of this series of changes are observed from the earliest departure from normal to the extreme overgrowths of the marked hyperplasias

Considerable confusion has arisen because pathologists have not always borne in mind the fact that progressive and regressive changes may succeed each other in rapid order and that the progressive and regressive changes are highly variable

both in degree and in duration Most goiters undergo hyperplasia and involution many times during their life history and each of these cycles entails certain morphologic differences which may be misleading when too great emphasis is laid on any one detail Thus, variations in the stroma, variations in the size of the follicle and colloid content alter the blood supply and possibly the nervous control which in turn modify secondary regeneration by giving rise to patchy or insular hyperplasia

Colloid goiter may be defined as the involution or as the return of an active hyperplasia to the condition nearest to normal, physiologically, chemically and anatomically, that a gland which has once been actively hyperplastic can assume As is now well known, involution induced by the administration of iodine is identical with that occurring spontaneously There is nothing degenerative or atrophic in the process of involution, although such glands may be the seat of highly degenerative or atrophic changes Complete proof of this is established by the fact that colloid goiters regenerate as readily as normal glands following partial removal or when placed under a potent goitrogenic influence The processes involved in the formation of a colloid goiter are the reverse of those involved in active regeneration or hyperplasia, that is, the blood supply decreases, the store of iodine rises, the epithelium becomes cuboidal and the colloid increases in density The development of a colloid goiter by the passive dilatation of normal thyroid follicles is impossible

While involution to colloid goiter or physiologic recovery is the usual mode of termination of compensatory hyperplasias, it occasionally happens, especially in endemic cretinism and in exophthalmic goiter, that the maximum degree of hyperplasia reached and the maximum capacity for function fail to bring about physiologic compensation, and sooner or later a state of thyroid exhaustion supervenes, that is, atrophy in spite of attempts at regeneration The essential changes appear to be analogous to those seen in atrophic cirrhosis of the liver, that is, they are the result of long-continued hyperactivity and injury without sufficient physiologic rest In the first stages the appearance of such a thyroid differs very little from any other extreme degree of hyperplasia, save for the increase in stroma Later, desquamation, atrophy and necrosis result The cells become highly variable in size and staining intensity The nuclei also become irregular, sometimes enlarged, hyperchromatic and sometimes pyknotic The colloid is greatly reduced, and as the process continues the follicles are reduced to nests of irregular cells in a dense stroma

One of the secondary features of goiter in man requires especial notice, namely, the development of nodules of glandular tissue in long-standing human goiters, so-called adenomas These growths have something in common with true tumor and usually retain many of the physiologic attributes of normal thyroid tissue Knowledge of these growths is inadequate at the present time The fact that they are limited almost entirely to human goiters renders experimental approach difficult That they are an integral part of diffuse goiters is shown by the fact that all nodular goiters, in their earlier stages, were diffuse goiters This is shown in Wegelin's well known study As to their origin, the idea of Woeffler that they arise from fetal rests and the unfortunate term "fetal adenoma" introduced by Billroth have so influenced thyroid pathology during the last fifty years that it is difficult to undo the harm which this conception has introduced While one cannot deny that occasionally congenital adenomas may arise from fetal rests, there can be no question that practically all adenomas arise from fully differentiated thyroid tissue and that their origin is intimately bound up with repeated hyperplasia and involution in long-standing goiters By altering the blood supply and nervous control and through pressure effects this process leads to insular, irregular and localized hyperplasias which eventually become so independent as to lose some of their physiologic attributes and take on certain of the characteristics of tumor

Finally the presenter called attention to the efforts that Wegelin has been making to arrive at an acceptable international classification of the principal stages

of goiter If the principal features could be grouped in some acceptable way, the intermediate or subgroups could be left largely to individual fancy without endangering the ability to understand what is meant The following classification would include the essential major divisions in their sequential relations (1) Struma diffusa struma diffusa parenchymatosa, struma diffusa parenchymatosa et colloides, struma diffusa colloides, struma diffusa sclerosa (exhaustion atrophy), (2) Struma nodosa (adenomatosa) Struma nodosa parenchymatosa, struma nodosa parenchymatosa et colloides, struma nodosa colloides, struma nodosa sclerosa

A STUDY OF THE ISLANDS OF LANGERHANS IN VIVO BENJAMIN N BERG, NEW YORK

The islands of Langerhans were studied in the pancreas of the living white mouse under iso-amyl-ethyl barbituric acid anesthesia Microscopically, they appeared as brilliant yellowish-white bodies on the surface of the less refractile yellow pancreas or attached to veins Accurate observations were possible only when the islands were situated at the surface of the pancreas Great variations were encountered with respect to the number of islands that were superficial

In suitable preparations the circulation in the islands was distinguished clearly The capillaries appeared as thin, threadlike loops which were U, S, V or spiral shaped and which dipped into the substances of the glands The circulation was extremely rapid, and changes were noted in the capillary pattern Rhythmic, spontaneous contractions were observed in the small arteries

Observations were also made concerning the action of epinephrine and pituitary extract on the blood vessels of the pancreas, including the circulation in the islands of Langerhans Vasoconstrictor effects were noted with both drugs In the higher order of concentrations, blanching and cessation of the circulation in the islands were observed With more dilute solutions, the effects on the circulation in the islands were irregular and difficult to follow Pituitary extract was tolerated by the mice in much higher concentrations than epinephrine

The results of the studies with epinephrine and pituitary extract indicate that the circulation in the islands of Langerhans is probably regulated by changes in the afferent arterioles or the small arteries in response to physiologic stimuli

THE CHANGES OF THE SPLEEN IN SUBACUTE BACTERIAL ENDOCARDITIS HERBERT FOX, Philadelphia

This article will be published in full in a later issue of the ARCHIVES

SYSTEMATIC CLASSIFICATION OF SPLENIC PATHOLOGY HERBERT FOX, Philadelphia

The difficulty of giving a name or classifiable description to many spleens that are chronically enlarged, received from operation or autopsy, suggested the possibility of grouping them according to a system based on numerical values given arbitrarily to the principal anatomic features The thought grew from a request made by a surgical colleague to score spleens as epithelioma is scored The idea was first rejected as impossible but, after an attempt had been made, the presenter found that a rough grouping occurred in two relatively easily separated groups, one showing splenomegaly, hematemesis and fibrosis, and another showing splenomegaly, purpura and pulp hyperplasia without participation of the lymph element Mathematicians assured Dr Fox that if the anatomic features adopted represented the correct selection and if the changes adopted were correct, it was acceptable to build formulae on their digital arrangement or on their sum This is by way of answering the question of the numerical value of a quality, because the changes in splenic pathology would be as much qualitative as quantitative

A large chart was made and all of the gross characters of the whole organ and its section surface and all the characters seen under the microscope were put

into columns If the observations were within normal limits, they were evaluated at 2, if inactive or atrophic, or less than normal, their score was 1, and if larger, more active or hyperactive in any way, the figure was 3 To this were added columns for adventitious changes, such as infarct, which were graded 0 or 1 It was soon found that scoring of the whole organs or section surfaces led to no grouping, so that the scoring was confined to microscopic observations

The features were reduced from an original charting of 20 to 13, and this figure will have to be reduced still further Sums of the numerical values of the characters do not permit distinct groupings of the spleens of the various forms of splenic anemia, nor do these scores differ sufficiently from those of purpura or bacterial endocarditis In the limited group of cases of *vividans* there is a rough separation of the spleens of acute and those of more protracted cases Thus, the more acute cases range from 12 to 15, while the more chronic examples range from 14 to 19

The only contribution this work can offer now is that an attempt is being made to schedule organic changes in the spleen in a numerical formula with the hope that some grouping will appear There are two further steps the formulation, around the main characters, of the changes in less variable characters, and the comparison of numerical formulas assembled according to the clinico-pathologic diagnoses Attempts to show that, deductively, spleens will fall into groups that have a pathologic significance have not been discarded The features used are the following follicles and germ centers, pulp and its splenocytes, sinuses and their endothelium blood vessels, number and condition of the wall, fibrous tissue, reticulo-endothelial cells, blood, pigment, neutrophils and eosinophils The adventitious characters do not receive numerical values

A Comparison of Four Lines of Mouse Leukemia, Transmitted by Inoculation Maurice N Richter, New York, and (by invitation) E C MacDowell, Cold Spring Harbor, N Y

In previous communications the presenters reported the presence of an inbred strain of mice in which lymphatic leukemia occurs with great frequency, and the fact that the leukemias occurring spontaneously in this strain may be transmitted to normal young mice of the same strain by inoculation with emulsions of tissues

From each of the spontaneous cases used as donors for the transmissions, a line of inoculable leukemia was obtained, transmissible apparently indefinitely by inoculation

In these lines of experimental transmissions they observed varieties of manifestations similar to those occurring in spontaneous cases Some manifestations, however, have occurred so frequently in certain lines, and infrequently in others, as to indicate the presence of differences in the inocula prepared from each

The transmissions of the several lines were carried on in parallel experiments, the host animals being from the same inbred strain, and frequently from the same litter Consistently reappearing differences in the lines are not, therefore, due to differences in the hosts

Experimental Osteitis Fibrosa (Fibrosa Osteodystrophy) in Guinea-Pigs on Normal Diet, Injected with Parathormone H L Jaffe and (by invitation) A Bodansky and J E Blair, New York

It has been suspected for about twenty-five years that the parathyroids are in some way related to the dystrophies of the bone Recently Mandl, and after him others, removed enlarged parathyroids in cases of osteitis fibrosa cystica and reported rapid clinical improvement of their patients, with cessation of the negative mineral balance

No reports have appeared on the experimental production of the fibrous osteodystrophies by the use of parathyroid extract Nor have bone changes that fulfil the requirements for the diagnosis of osteitis fibrosa been experimentally produced by other means

By subcutaneous injection of parathormone, the presenters regularly produced in the guinea-pig the generalized changes of the bones which satisfy all of the criteria of osteitis fibrosa, including the appearance of new bone (osteoid) The latter appears as soon as the reparative processes are permitted to operate with sufficient intensity A guinea-pig that is permitted to go for a few days without parathormone, after previous treatment with parathormone, shows an abundance of osteoid tissue beneath the periosteum and endosteum, in the haversian canals and in the fibrous tissue in the metaphysis just distal to the epiphyseal cartilage plate

It was necessary to use relatively large doses of parathormone to produce fibrous changes in the bones of guinea-pigs The doses can be given to the guinea-pig without producing fatal hypercalcemia, and the animal's ability to withstand such large doses may be related to its alkaline diet

Even one dose of 60 units when given to a guinea-pig weighing 300 Gm produces extensive resorption cessation of bone formation and infraction of the cortex within forty-eight hours Such guinea-pigs may die, of extensive bone destruction, if the large doses are continued Bone changes were produced in guinea-pigs with as little as 10 units of parathormone daily, and with from 20 to 30 units daily for two or three weeks extensive resorption and fibrosis of the bones were obtained

In the dog if the doses are large enough to produce rapid changes in the bones, fatal hypercalcemia may result However, the presenters were able to prevent hypercalcemia in dogs on as much as 20 units of parathormone daily and produced in these dogs generalized bone resorption with lacunar erosion, fibrosis, cysts and osteoid tissue—criteria for the diagnosis of osteitis fibrosa cystica

THE HISTOGENESIS AND DEVELOPMENT OF RETICULUM, ITS WIDESPREAD OCCURRENCE IN THE ADULT ORGANISM A NEW METHOD OF DEMONSTRATION JAMES F RINEHART (by invitation), SAN FRANCISCO

The method of impregnating connective tissue substance, including reticulum and collagen, was given in which there is apparently a complete impregnation of such substances and in which adequate counter-staining is achieved

The mesenchyme was shown to possess a fibrillar cytoplasm closely related to reticulum and collagen The differentiation of capillaries in loco in the mesenchyme and the differentiation of mesenchyme into adult connective tissue were indicated Reticulum was shown to be a direct descendant of the mesenchyme, and evidence was presented of the probable transformation of reticulum into collagen Reticulum fibrils were demonstrated as of universal occurrence in the capillary endothelium Reticulum was identified with the basement membrane in the kidney, gastric mucosa and pancreas The epithelioid cells of tuberculosis were shown to be capable of forming reticulum fibrils which may be transformed into collagen By securing complete impregnation of this fiber substance and combining it with adequate counter-staining, a more complete concept of the capillary bed was achieved in which reticulum-lined spaces were shown to connect apparently isolated capillaries as seen by ordinary staining methods

RAPID DIAGNOSIS OF INTRACRANIAL TUMORS BY SUPRAVITAL STUDY LOUISE EISENHARDT (by invitation) and HARVEY CUSHING, BOSTON

A description was given of a method of immediate diagnosis of intracranial tumors by supravital study of fresh smears The method has been in use for the past two and one-half years it is possible by this means to differentiate the various types of gliomas, for example, almost more easily than by the usual methods of fixed preparations

SPONTANEOUS AND EXPERIMENTAL SCHWANNOMAS PIERRE MASSON and (by invitation) CHARLES SIMARD, MONTREAL

J Nageotte has shown that if a fragment of the sciatic nerve of the rabbit is excised from one side and grafted near the intact sciatic nerve of the other side a voluminous tumor is produced by the sheaths of Schwann without participation of the axons—an artificial schwannoma Comparative study of one of these tumors and of several spontaneous encapsulated neurinomas from man shows a complete identity of their fundamental constituents The structure, the mode of collagen production and the manner of growth and development are the same in both types of tumor A study of their characters shows that these constituents are different from connective tissue cells In the building up of experimental schwannomas, connective tissue plays an important part, but in encapsulated spontaneous schwannomas the connective tissue plays only a minor part The pure connective aspect (fibromatous, myxomatous) of certain neurinomas corresponds to the special morphologic modification of Schwann cells which have been altered by subjection to certain circulatory conditions The palisades that are found in many spontaneous schwannomas are derived from the sheath of Schwann and are perhaps characteristic of the type of tumor derived from sensory nerves

QUANTITATIVE OBSERVATIONS ON THE SEMILUNAR VALVES OF THE HEART PAUL GROSS (by invitation), CLEVELAND

A method for the determination of the surface area of valves is described The surface area of the cusps of a semilunar valve with a large ring is commensurately greater than that of a valve with a normal ring Valves with normal and large rings present no significant differences in the height of the cusps Elongation of the valve rings of hearts at autopsy is associated with a decrease in the height of the cusps It is probable therefore, that as a valve ring increases in size the cusps increase in height The surface area of the semilunar valves is from 40 to 70 per cent in excess of a calculated minimal closing surface The percentage of excess has no correlation with the size of the valve ring A semilunar valve is incompetent if the average height of the cusps is equal to or less than the radius of the valve ring

STUDIES ON THE PATHOGENESIS OF BACTERIAL ENDOCARDITIS I FUNCTIONAL CHANGE OF THE RETICULO-ENDOTHELIAL SYSTEM SUBSEQUENT TO INJECTIONS OF CASEIN OR STREPTOCOCCI VACCINE ROBERT KOCH, PITTSBURGH

Injections of casein or killed streptococci, a prerequisite for the development of bacterial endocarditis in the experiments, led neither to degenerative changes of the endocardium nor to a transformation of the endothelial coat of the endocardium into phagocytes Experimental studies on the vital staining of the cells of the reticulo-endothelial system, however, revealed that subsequent to injections of casein or killed streptococci the reticulo-endothelial system loses to a considerable extent the ability to develop granular deposits of dyes, if the dyes are injected in the form of solutions, while the phagocytosis of colloidal particles of the same dyes is not disturbed

STUDIES ON THE PATHOGENESIS OF BACTERIAL ENDOCARDITIS II EXPERIMENTAL PRODUCTION OF TOXIC HEART LESIONS IN THE PRESENCE OF A CHANGED FUNCTIONAL STATE OF THE RETICULO-ENDOTHELIAL SYSTEM K SEMSROTH, PITTSBURGH

Experiments were carried out to determine whether or not the functional disturbance of the reticulo-endothelial system, reported in the preceding paper, influences the degree of the deleterious effect of toxic bacterial substances on the heart Control rabbits were given doses of a diphtheria toxin or typhoid vaccine which would not lead to inflammatory reactions of the endocardium or to

myocarditis Analogous doses were given to rabbits which previously had received a series of injections of casein or streptococcic vaccine These animals developed a focal interstitial myocarditis Furthermore, proliferative and exudative inflammatory reactions of the endocardium with marked degenerative changes were observed It was inferred that the functional disturbance of the reticulo-endothelial system reported in the preceding paper was associated with an increased vulnerability of the heart to the action of bacterial products

CHARACTERISTICS OF STREPTOCOCCI ISOLATED FROM PATIENTS WITH RHEUMATIC FEVER AND CHRONIC INFECTIOUS ARTHRITIS R L CECIL and (by invitation) E E NICHOLLS and W J STAINSBY, NEW YORK

During the past three years, streptococci have frequently been isolated from the blood and joints of patients with acute rheumatic fever and chronic infectious arthritis The technic consisted essentially in taking large quantities of blood and in observing the cultures over a long period

Eighty-three and three-tenths per cent of the strains isolated from cases of chronic infectious arthritis appeared to belong to one biologic group These strains were designated as "typical strains" They seemed to fall into the alpha prime group of streptococci

The streptococci recovered from cases of acute rheumatic fever belonged to the *Streptococcus viridans* group, although the methemoglobin formation was frequently difficult to demonstrate Cross-agglutination tests showed that some of these organisms tended to fall into biologic groups

Agglutination reactions with the serums of patients with chronic infectious arthritis against the antigen of any of the typical strains were very striking The serums agglutinated to a very high titer, as high as 1 5,120 or more This condition was not found with control serums The serums of patients with acute rheumatic fever agglutinated some of the rheumatic fever strains to a higher titer than the serums from control cases

HISTOLOGIC STUDIES ON THE ASCHOFF BODY LOUIS GROSS and (by invitation) JOSEPH C EHRLICH, NEW YORK

In many cases the descriptions of Aschoff's bodies in the literature are confusing There are many disagreements on the histologic appearance of these bodies, mainly because various authors depict different structures as well as different phases in the evolution of the same structure This also accounts to a certain extent for differences of opinion concerning the origin of the cells found in the Aschoff bodies By using various histologic methods on a large amount of autopsy material, a series of pictures was found which suggested a fairly definite life cycle for the Aschoff body In certain cases, at least, the Aschoff body took the form of a well developed syncytium surrounding swollen collagen as one characteristic phase in the life cycle Several phases of this cycle appeared to be pathognomonic of rheumatism It is believed that if this cycle is thoroughly understood there will be less difficulty in recognizing these structures The Aschoff body was shown to possess a characteristic reticulum, which also appeared to go through a recognizable life cycle

EXPERIMENTAL STREPTOCOCCIC INFLAMMATION IN NORMAL, IMMUNE AND HYPERSENSITIVE ANIMALS BENJAMIN J CLAWSON, MINNEAPOLIS

This article was published in full in the June, 1930, issue of the ARCHIVES

SUBCUTANEOUS NODULES IN CHRONIC INFECTIOUS ARTHRITIS M H DAWSON (by invitation) and A M PAPPENHEIMER, NEW YORK

The occurrence of subcutaneous nodules in patients suffering from rheumatic fever has long been recognized and has been the subject of intensive investigation

by many workers Less attention, however, has been paid to the subcutaneous nodules that occur in patients afflicted with rheumatoid (chronic infectious) arthritis

During the past year in the Arthritic Clinic of the Presbyterian Hospital (supported by the Faulkner Memorial Fund), subcutaneous nodules have been observed in twenty-three patients All of the patients presented the typical clinical picture of rheumatoid or chronic infectious arthritis Nodules were excised from eleven of these patients and subjected to careful histologic and bacteriologic examination

All of the material examined showed a striking, uniform and characteristic picture The essential histologic features were summarized as follows (1) an area of central necrosis, apparently due in its earliest stages to a gelatinous swelling and degeneration of individual collagen bundles, (2) a surrounding zone of peculiar and characteristically arranged large mononuclear cells, (3) an enclosing zone of dense and relatively avascular fibrous tissue

The blood vessels in the area of the nodule itself rarely show significant changes, but the arterioles and capillaries in the surrounding tissue are the site of characteristic lesions

There is a striking resemblance between the histologic appearance of these nodules and those that occur in rheumatic fever

The results of the bacteriologic investigations have been entirely negative

A New Meningococcus-Like Organism (Neisseria Flavescens, n sp) from Epidemic Meningitis Sara E Branham (by invitation), Washington, D C

Of 155 strains of meningococci isolated from cases of epidemic cerebrospinal meningitis in the United States during 1928 and 1929, 14 strains were uniformly atypical These were among fifty spinal fluid strains received from one city during a single outbreak, thirty-six of which or 72 per cent, fell into the four antigenic groups of Gordon's classification The remaining fourteen, or 28 per cent, formed a homogeneous serologic group There was no cross-agglutination with any of the four usual groups of meningococci, none of these strains was agglutinated by polyvalent commercial antimeningococcus serums

Aside from this serologic difference, these fourteen uniform strains varied from the typical meningococci in pigment production and in total lack of fermentative ability They did not correspond to any of the gram-negative cocci previously described

The cases with which these strains were associated were subacute and ran a relatively long course Eleven of the patients were given polyvalent antimeningococcus serum freely, and seven made a complete recovery

This homogeneous group of fourteen strains does not conform with the usual conception of the meningococcus, although the strains were isolated from the spinal fluid of patients with meningitis during an epidemic in which all four of the usual serologic types of meningococci were found To call them meningococci would alter the definition of a meningococcus and plunge the classifications of the meningococcus group into confusion For the present this new group of fourteen strains will be referred to as *Neisseria flavescens, n sp*

The fact that 28 per cent of the strains isolated in one locality, or more than 9 per cent of those received from the country at large, were members of this restricted group suggests the importance of giving special attention to it

Attempted Chemotherapy in Experimental Rabies A Hoyt (by invitation) and C W Jungeblut, New York

A typical and constant infection was produced in white mice by the intracerebral injection of fixed virus The animals usually showed beginning paralysis in about six days, and died on the eighth or ninth day

In experiments involving 255 mice, which were inoculated intracerebrally with 0 02 cc of different dilutions of virus, the approximate minimum fatal dose was a dilution of 1 320 of this virus Although the majority of the animals given injections of amounts of virus up to as little as 1 1,280 died of rabies, a few survived Beyond this point, the percentage of survivals increased rapidly

Attempts were made to protect mice against rabic infection produced by intracerebral injection of one or more minimum lethal doses of fixed virus, by prophylactic treatment with silver arsphenamine, neoarsphenamine, tryparsamide, a dye-substance derived from naphthylamine-sulphonic acid (Baver 205), plasmochin, optochin and quinine bisulphate The drugs, with the exception of quinine bisulphate, were injected intravenously in doses as large as could be tolerated Treatment was ordinarily started on the day of the infection, in some cases, it was continued with one or more subsequent doses of the drug

Under the conditions of the experiment, none of the drugs used displayed the slightest prophylactic or therapeutic effect on the infection There was, however, often a slight prolongation of the incubation period of the disease in some of the treated mice, as compared with that of the controls This was especially noticeable with silve arsphenamine and a dye-substance derived from naphthylamine-sulphonic acid, while the incubation period appeared to be actually shortened by the administration of the quinine compounds Caution should be used in interpreting the foregoing results, as the incubation period of a few mice, which were treated only with distilled water, was likewise slightly lengthened

Blood Changes during Trypanosome Septicemia Richard W Linton (by invitation), New York

A study of some aspects of the blood chemistry of rats with acute septicemia due to infection with *Trypanosoma equiperdum* yielded the following results The carbon dioxide capacity of the serum was markedly lowered early in the disease The nonprotein nitrogen and the uric acid constituents in the blood were increased in the terminal stages The kidneys also showed terminal degenerative changes The cholesterol remained unchanged throughout The amount of lecithin was markedly increased, most of the observations showing a 20 to 50 per cent rise in this substance The glycogen of the liver was lower than normal in the early stages and could not be demonstrated in the later stages of the infection The blood sugar remained normal until a very late period in the disease

An Experimental Study of the Effects of Heat Induced by High Frequency Alternating Currents V C Jacobsen and (by invitation) K Hosoi, Albany, N Y

About two years ago in a laboratory of radio research, it was noted that when a workman happened to get in the field of a short wave radio transmitter, a rise in his temperature occurred, the height of temperature depending on the time he was in the field and his proximity to the apparatus A rise of 2 2 degrees was caused in fifteen minutes, and the response was pronounced when a water-cooled 20 kilowatt radio tube was discharging from a 6 foot rod to ground with 60,000,000 alternations per second a current of 15 kilovolts Since diathermy with its relatively low rate of alternation of current is reputed to have valuable therapeutic applications due to the heat generated in the tissues, Dr W R Whitney, director of the Research Laboratory of the General Electric Company, devised a modification of the radio transmitter which has become available for the study of experimental aseptic hyperthermia The apparatus is a high frequency heater or oscillator on the principle of a short wave transmitter except that the energy is concentrated between two plate electrodes instead of being directed from an aerial (Complete details of the machine are being published elsewhere) In the experiments presented, a wave length of 25 meters was used almost entirely, an amperage of from 0 2 to 0 35 oscillating about 10,000,000 per second, a rate so rapid that no muscular contractions are produced

Twenty-three dogs, twenty-one rats and four guinea-pigs were exposed between the plate electrodes for variable periods A temperature once reached could be maintained either by decreasing the voltage or by increasing the distance between the electrodes A dog's temperature taken by rectum, or determined by thermocouple, could be raised as much as 7 1 degrees in thirty-seven minutes, and 8 3 degrees in less than an hour, such rapid heating often, but not always, causing death Three dogs were kept at about 109 F for from five to twelve hours Twelve dogs were given from two to nine heatings that lasted from four to thirty hours, the temperatures varying from 107 to 112 F

The white rat and the guinea-pig could withstand about the same temperature as the dog, and the tissue changes were practically the same for the three species under the same conditions of the experiment

After removal from the oscillator, the temperature with few exceptions returned to normal in three hours Repeated exposures rarely gave indication of loss of control of the heat-regulating center as shown by a prolonging of the pyretic state

While being heated, the animal would become restless, salivate, pant and perspire, and the visible membranes became congested

In some dogs that were placed too close to the electrodes, perspiration caused arcing, which resulted in severe skin burns that healed very slowly Rapid heating of rats often caused a disruption of the skin of the tail and severe burns at the base of the tail, with the skin finally sloughing off

Postmortem examinations were performed as promptly as possible, since postmortem degeneration was very rapid in the highly heated tissues

The animals that died or were killed while still at a high temperature showed the following changes Acute congestion of all the organs occurred In addition, the heart showed focal hemorrhage, interstitial edema and fatty degeneration of the muscle fibers The lungs showed emphysema, atelectasis, small hemorrhages and an increased secretion of bronchial mucus There were hemorrhages and necrosis of the lymphoid tissue of the spleen Endothelial hyperplasia was found Often fibrin thrombi were present in the sinusoids A few mucosal hemorrhages and necrosis of the lymphoid tissue were present in the gastro-intestinal tract There was an excess of mucous secretion Mesenteric hemorrhage was found Acute inflammation of the mucosa was often a coincident infection The liver presented cloudy swelling, fatty degeneration, focal necrosis, focal hemorrhage and depletion of glycogen The pancreas was normal The kidneys showed cloudy swelling, hydrops and fatty degeneration in Henle's and convoluted tubules The adrenals showed focal hemorrhage, and an increase in visible fat There was hemorrhage in the capsular fat The testes of the dogs were usually normal The testes of the rats showed much exfoliation of the germinal epithelium and proliferation of Sertoli's cells

One female bulldog that was heated to 108 F for nineteen hours had a carcinoma of the breast which appeared unaffected

The striated muscle showed glycogen depletion The bone-marrow was hyperactive The thyroid was normal

The brain showed congestion, focal hemorrhage and chromatolysis of the ganglion cells There was chromatolysis of the ganglion cells of the spinal cord

Dogs and rats that were heated many times and in which the temperatures were allowed to return to normal showed fewer changes in their organs Congestion was regularly present, but cloudy swelling and fatty degeneration were seen less frequently The loss of weight was pronounced, and the fat depots showed a loss of fat The weight was usually recovered rapidly, however, by the drinking of water The pulmonary emphysema in the animals given one heating was probably due in part to an acidosis of the nature of lactic acid and not to ketosis

The heat induced by this method is an internal heat probably caused, as Hosmer suggested, by an increased vibration of the molecules of the cells,

produced by their alternate attraction to each of the electrode plates in turn

From a study of the tissues of these experimental animals, it was seen that there is little to suggest any fundamental difference between the heat induced by this oscillating current and the hyperthermia in febrile disease or that produced by external applications Concomitant pulmonary or gastro-intestinal infection was present in slight degree in only a few animals The dangers of the method are not entirely known The cutaneous burns were preventable Schereschewsky found experimental mouse cancer unfavorably influenced by this form of heating Its application to various chronic diseases such as arthritis and dementia paralytica seems logical, and such work is under way

The pathologic changes of fever can be studied more thoroughly than ever before by this method, and yet their clinical application must be preceded by much fundamental work, since acidosis, and later alkalosis and tetany, cloudy swelling and fatty degeneration of parenchymatous organs and deleterious effects on the germinal epithelium of testes and ovaries are definite pathologic states to be avoided in therapy if possible

Finally, it seems in order, in this anniversary year of William H Welch, to say that his Cartwright lectures in 1888 still constitute the greatest source of information concerning the pathology and etiology of fever, little of note having been added

Book Reviews

IMMUNITY IN INFECTIOUS DISEASES A SERIES OF STUDIES By A BESREDKA, Professor at the Pasteur Institute, Paris Authorized translation by Herbert Child, M R C S, L S A Cloth Price, $5 Pp 364 Baltimore Williams & Wilkins Company, 1930

This book contains fifteen chapters The first seven contain translations of as many articles published during the years from 1898 to 1914, inclusive The contents of these articles are now of historical interest, and no convincing reason for republishing them at this time is apparent The other chapters contain translations of articles published between 1922 and 1927, inclusive, except chapter 14, which carries no indication of being a reprint In these chapters the author assumes the simultaneous role of scientist and advocate The skill of the advocate may be admired, but unfortunately it cannot rescue the scientist from serious and deserved criticism Once more the fallacy of post hoc ergo propter hoc has been given full sway Chapter 10, for instance, on immunization by the cutaneous method, reads like the advertising pamphlet of an American manufacturer of bacterial vaccines in the balmy days of their commercial exploitation In illustration of the beneficial effects of the local use of so-called antivirus, which is the filtrate of the culture of the microbe in question, such cases as the following are cited

"Two months ago, Dr M——— writes to us, I was called to a patient who had a carbuncle which began a fortnight before I opened up with the thermocautery a wound occupying the whole of the nape of the neck, from one ear to the other, of the width of one's hand, full of sanguineous pus and sphacelated debris, I was truly alarmed at the sight of such a wound I applied a dressing of broth-vaccine, 48 hours later I applied another dressing and recorded a slight improvement, the patient was more comfortable I entrusted the three other dressings to the patient's daughter, as they lived a considerable distance from my domicile When I returned, 10 days after the first application, I was absolutely stupefied by the result, as there was nothing to be seen but a beautifully clean wound, without the least trace of pus Today the wound is completely cicatrised" (p 221)

"L——— (Francoise) was admitted into the Saint-Germain Hospital, January 5th, for an abscess of the breast, 8 to 10 days old Very acute local pain Temperature, 39° C (102 2° F) An incision of 2 cm gave abundant evacuation of pus, streptococci were found in this The abscess cavity was plugged with gauze saturated with filtrate vaccine Almost immediately disappearance of pain and fever was reported In 20 days the recovery was complete" (p 223)

The claim by the author that anticholera and antityphoid immunization by the buccal route may be accomplished without the production of antibodies, and that ergo must be different in nature from immunization by the subcutaneous or intravenous route, lacks the support of adequate observations To demonstrate satisfactorily the absence or presence of antibodies in the blood after immunization, it is essential to make repeated tests at frequent intervals for some time afterward, at least for three weeks, not merely for one form of antibody or antibody action, but for all established forms—lysis, agglutination, opsonification, precipitation and complement-fixation Judging from the statements in his articles, Besredka has made only occasional tests, mostly for agglutination, with negative results, but, as stated, that is not a sufficient basis on which to claim the existence of a new form of immunity

AN INDEX TO THE CHEMICAL ACTION OF MICROORGANISMS ON THE NON-NITROGENOUS ORGANIC COMPOUNDS By ELLIS I FULMER, Professor of Biophysical Chemistry, and C H WERKMAN, Associate Professor of Bacteriology, assisted by ANELLA WIEBEN and CALVIN R BREDEN, Instructors in Chemistry, Iowa State College Cloth Price, $4 50 Pp 212 Springfield, Ill Charles C Thomas, 1930

This book consists of three tables and a list of approximately 500 references The tables are substantially identical in content but different in arrangement The items included are organisms, substrate, product and authority, the tables being keyed alphabetically to the first three items, respectively Adequate cross-references are used for different names of the same organism

The authors have confined this survey to "those instances in which a named organism acted on a named substance to produce a named compound" They state that they "have purposely omitted much material on the more common types of fermentation with only typical references, while for more uncommon types the treatment has been practically complete"

The user of the book, then, should expect to find every well established fermentation mentioned at least once The reviewer used some of the fermentations with which he was most familiar as a basis for a critical examination

In the section devoted to lactic acid as a product (pp 145-151), *Streptococcus lactis* is mentioned once, as a fermenter of sucrose *Lactobacillus acidophilus* and *Lactobacillus bulgaricus* were not found here or elsewhere One would gather (pp 85-86) that lactose is fermented to lactic acid only by *Bacterium caucasicum, Bacillus coli, Lactobacillus leichmani, Amylobacter butylicus* and *B tartricus* On page 48, *Streptococcus lactis* is listed as fermenting dextrose and sucrose, no other sugar being mentioned

Streptococcus paracitrovorus is mentioned as producing acetic and lactic acids from dextrose *Streptococcus citrovorus* is not to be found The action of these organisms on citric acid is not given

B welchii is listed as producing acrolein from glycerin It is not mentioned in connection with the butyric fermentation

The fermentation of galactose, sucrose, maltose and succinic acid to propionic acid by *Bacterium acidi-propionici d* is not mentioned

In view of the omissions discovered in an examination that was far short of being exhaustive, it appears that this index, although undoubtedly very useful, fails to list completely either the well known or the less known proved fermentations To the reviewer this seems a serious fault

BERGEY'S MANUAL OF DETERMINATIVE BACTERIOLOGY By DAVID H BERGEY Third edition Cloth Price, $6 Pp 561 Baltimore Williams & Wilkins Company, 1930

This edition of Bergey's well known manual, sponsored by the Society of American Bacteriologists, contains 127 more pages than the second edition It has most of the merits and the defects of its predecessors It suffers from the uncritical acceptance of incomplete descriptions and from inaccuracies in recorded biologic characters and recognition marks Curious lapses are frequent To state that the habitat of *Clostridium tetani* is "the cause of tetanus" and the habitat of *Cl botulinum* "the cause of botulism" is neither correct nor helpful Especially does the manual lack authority from its failure to take into consideration numerous recent comprehensive studies in many groups There is no evidence that Moltke's monograph on *Proteus vulgaris* was consulted in drawing up the list of characteristics of this organism The genus *Salmonella* (paratyphoid bacilli), with which the reviewer is more or less familiar at the moment, is not handled in a way that inspires confidence in the general make-up of the book Much space is wasted by unnecessary repetition It is not clear why it should be thought necessary to state under each species of *Salmonella* that the rods are "gram-negative," since

the tribe *Bacterium*, under which *Salmonella* is placed, is characterized (p 315) as consisting of "gram-negative rods" Dulcitol fermentation is employed as a differential character, although practically all recent observers agree in attaching little significance to the variations in fermenting this carbohydrate The group is said (p 339), quite correctly, to be characterized by inability to attack salicin, but *S columbensis* (p 346) is recorded as producing acid and gas in salicin Six species of *Salmonella* enumerated by Castellani and Chalmers are included in the twenty species recognized by Bergey, although they have not yet been verified as true species by other workers on this group *"S typhimurium"* is classed (p 395) as an independent species, but no one has yet shown that the cultures labeled by this name are any other than *S aertrycke* or *S enteritidis* Basenau's *"B morbificans-bovis,"* which is regarded as *Salmonella* by all recent investigators (e g, White and Sladden and Scott), is placed in the genus *Flavobacterium* (p 147) In a word, the descriptions, nomenclature and classificatory arrangement cannot be depended on as representing the best current opinion

On the other hand, students of bacteriology have much to be grateful for to the author of this book It is a good deal to have available a check list of generic and specific names under some sort of orderly arrrangement with references (which might be greatly and advantageously increased) to important classificatory sources It is a book every bacteriologist must have access to, however much he may regret its shortcomings

HUMAN BIOLOGY AND RACIAL WELFARE Edited by EDMUND V COWDRY, Professor of Cytology, Washington University, St Louis, Mo Price, $6 Pp 612, with illustrations New York Paul B Hoeber, Inc, 1930

According to the preface of the editor, the purpose of this book is to help break down the barriers separating the group of sciences that bear definitely on human welfare and which may be included under the collective term of "human biology" The book is intended principally for two groups of readers for students, especially medical students, for whom it is essential to know as much as possible about human life in general, and for readers of more mature years who wish to look a little below the surface of things The scope of the book is shown best by a brief summary of its contents Edwin R Embree, president of the Julius Rosenwald Fund, contributes an illuminating and comprehensive introduction There are five parts (1) Perspective Life in space and time (H N Russell), (2) The Origin of Man evolution traced biochemically (A B Macallum), the animal ancestry of man (William K Gregory), the evolution of the brain (George H Parker), mental evolution in the primates (R M Yerkes), societal evolution (W M Wheeler), human races (A Hrdlička), (3) Man as a Physiological Unit the vital units called cells (E V Cowdry), the relation of cells to one another (A Carrell), the integrative action of the vascular system (W B Cannon), nervous integration in man (J F Fulton, C S Sherrington), the integration of the sexes (Clark Wissler), (4) Effects of Environment the effect of climate and weather (E Huntington), the reaction to food (E V McCollum), the influence of urban and rural environment (Haven Emerson, Earl B Phelps), antisocial behavior (William Healey), adjustment to infectious diseases (H Zinsser), what medicine has done and is doing for the race (H Rolleston), the relation of science to industry (R A Millikan), the influence of education (John Dewey), (6) The Future the inheritance of disease (Paul A Lewis), some aspects of the biology of human populations (R Pearl), the mingling of races (C B Davenport), the purposive improvement of the human race (E G Conklin), the intentional shaping of human opinion (H A Overstreet) This list contains many leaders in contemporary science, and obviously it is not possible to review in detail the chapters contributed by the individual authors The topics have been well selected and assigned, and the book contains much important matter of wide interest

Books Received

THE PRINCIPLES OF BACTERIOLOGY AND IMMUNITY By W W C Topley, M A, M D, M S, F R C P, Professor of Bacteriology and Immunology, University of London, Director of the Division of Bacteriology and Immunology, London School of Hygiene and Tropical Medicine, and G S Wilson, M D, M R C P, D P H, Reader in Bacteriology and Immunology in the University of London, London School of Hygiene and Tropical Medicine Two volumes Price, $15 Pp 1300 New York William Wood & Company, 1929

NINETEENTH ANNUAL REPORT OF THE STATE INSTITUTE FOR THE STUDY OF MALIGNANT DISEASES, Department of Health, State of New York For 1929 Pp 35 Albany, N Y J B Lyon Company, 1930

A HEALTH INVENTORY OF NEW YORK CITY By Michael M Davis and Mary C Jarrett Pp 367 New York Welfare Council, 1929

MEDICAL EDUCATION AND RELATED PROBLEMS IN EUROPE Commission on Medical Education (Willard C Rappleye, Director of Study), New Haven, Conn, 1930

METHODS AND PROBLEMS OF MEDICAL EDUCATION (Sixteenth Series) New York The Rockefeller Foundation, 1930

REFLEX ACTION A STUDY IN THE HISTORY OF PHYSIOLOGICAL PSYCHOLOGY By Franklin Fearing, Ph D Price, $6 50 Pp 350, with illustrations Baltimore Williams & Wilkins Company, 1930

THE CREED OF A BIOLOGIST A BIOLOGIC PHILOSOPHY OF LIFE By Aldred Scott Warthin, Ph D, M D, LL D, Professor of Pathology, University of Michigan Price, $1 50, cloth Pp 60 New York Paul B Hoeber, Inc, 1930

IMMUNITY IN INFECTIOUS DISEASES A SERIES OF STUDIES By A BESREDKA, Professor at the Pasteur Institute, Paris Authorized translation by Herbert Child, M R C S (Eng), L S A Price, $5 Pp 364 Baltimore Williams & Wilkins Company, 1930

AN INDEX TO THE CLINICAL ACTION OF MICROORGANISMS ON THE NON-NITROGENOUS ORGANIC COMPOUNDS By Ellis I Fulmer, Ph D, Professor of Biophysical Chemistry, C H Werkman, Ph D, Associate Professor of Bacteriology, assisted by Anella Wieben and Calvin R Bieden, Instructors in Chemistry, Iowa State College Price, $4 50, cloth Pp 212 Springfield, Ill Charles C Thomas, 1930

ARCHIVES OF PATHOLOGY

VOLUME 10 AUGUST, 1930 NUMBER 2

PULMONARY SIDEROSIS

TWO CASES WITH RETICULO-ENDOTHELIAL SIDEROSIS *

MILTON G BOHROD, M D
DECATUR, ILL

Pulmonary diseases due to inhaled solid substances in fine suspension have been known for many years, although scientific studies date back only to 1867, when Zenker [1] described two cases of what he named siderosis and proposed for the entire group of dust diseases the term pneumonoconiosis Of the types included in the latter term, only anthracosis and silicosis, the most common, have been adequately studied [2] Siderosis, first described, is less common, and while clinical and roentgenologic studies on metal workers and iron miners abound, pathologic studies still cover only about thirty cases

Before methods of reducing the amounts of dust in mines and factories were in common use, pulmonary disease was exceedingly common among the workers in these establishments Hirt (quoted by Jotten and Arnoldi [2]) estimated that 53 3 per cent of metal workers had lung trouble, and that of these 28 per cent were tuberculous Among 100 drillers in iron mines, Cronin [3] found a large proportion with symptoms related to the respiratory system, although only 30 per cent gave abnormal physical signs Even now, in spite of the improvement in working conditions and the reduction of the amounts of dust there are still sufficient cases to warrant intensive study of the dust hazards In part, this is due to the imperfections or insufficient use of dust-diminishing apparatus, but another potent factor is the "latent period" in pneumonoconiosis (Watt, Irvine, Johnson and Steuart [4]), so that persons exposed years ago are only now developing dangerous symptoms

* Submitted for publication, Feb 14, 1930

* From the Department of Pathology and Bacteriology, University of Illinois College of Medicine

1 Zenker, F A Ueber Staubinhalationskrankheiten der Lungen, Deutsches Arch f klin Med **2** 116, 1867

2 For complete reviews of the literature on pneumonoconiosis see
Jotten and Arnoldi Gewerbestaub und Lungentuberkulose, Berlin, Julius Springer, 1927
Ickert, F Staublunge und Staublungentuberkulose, Berlin, Julius Springer, 1928

3 Cronin, A J Dust Inhalation by Hematite Miners, J Indust Hyg **8** 291, 1926

4 Watt, A H , Irvine, M A , Johnson, and Steuart, W General Report of the Miner's Phthisis Prevention Committee, appendix no 6, Pretoria, 1916, p 81

The amounts of metallic substances recoverable from the lungs of miners, metal workers and others long exposed to a dusty atmosphere are surprisingly large Langguth [5] found 7 9 per cent of the dry weight of a siderotic lung to be iron oxide In silicosis, the amount is much higher (over 23 per cent, according to Oehmann,[6] and from 7 4 to 39 8 per cent, according to Riddle and Rothwell [7]) But the amounts of dust to which such persons are exposed are also large Ickert [2] estimated that a miner in Mansfield inhales from 48 to 480 Gm of dust in the course of forty years of employment In a hematite mine, at least 56 per cent of the dust is iron sesquioxide (Cronin [3])

The reproduction of siderosis in animals has not met with much success, a typical siderosis has never been produced Carleton [8] exposed guinea-pigs to far more massive doses of hematite and iron dusts than are ever encountered industrially, with no definite pathologic results With the former dust, only a little bronchitis was noted Iron dust in large doses caused death from a toxic influence, in smaller doses, it caused some bronchitis but no induration His conclusion from these experiments that these dusts do not constitute serious hazards is not warranted in view of the difficulty with which animals develop pneumonoconiosis and in view of Cronin's analysis [3] of the great incidence of symptoms and pathologic changes in workers with hematite Other experimenters have found only slight fibrosis following long exposures of animals to dust-laden air, with a high grade proliferative reaction of endothelium and lung capillaries (see the summary of the experimental work by Jotten and Arnoldi [2]) In such experiments, the right lung has been found to contain more dust than the left, the apexes more than the bases (Ickert [2]) The reasons advanced for the failure of experimental animals to develop pneumonoconiosis have generally had to do with the difference of attitude, the erect position of man favoring the settling of dust in the lower air passages In the light of such unsatisfactory evidence obtainable from experiments on animals, human material, clinically and at necropsy, offers a more fertile field for investigation

While differences in the pathologic picture of pneumonoconiosis have long been recognized, and the nature of the dust concerned has been considered an important factor in determining the kind and the

5 Langguth, F Ueber die Siderosis Pulmonum, Deutsches Arch f klin Med **55** 255, 1895

6 Oehmann, R C Ueber die pathologische Anatomie der Silikose, Acta tuberc Scandinav **4** 67, 1928

7 Riddle, A R, and Rothwell, H E Some Clinical and Pathological Observations on Silicosis in Ontario, J Indust Hyg **10** 147, 1928

8 Carleton, H M The Effects Produced by the Inhalation of Hematite and Iron Dusts in Guinea Pigs, J Hyg **26** 227, 1927

degree of involvement, such differences have not been studied minutely enough This is perhaps due to the fact that the overwhelming number of cases of pneumonoconiosis have been due to silicates, and only this type has been adequately studied A less common but no less interesting type is due to the inhalation of dusts containing iron Zenker's report,[1] which first recognized the importance of dust diseases, was of such a case Merkel[9] several years later reported nine such cases But, in all, the reports on siderosis still concern only about thirty cases

Two types of dust contain iron in considerable quantities The first is found in iron ore mines and in factories using certain iron pigments (English red) The usual form of this iron is the oxide The second type is found in metal grinding and polishing establishments where tiny particles of metallic iron are removed from the products manufactured and blown into the air In these establishments, the air also contains large quantities of silicates removed from the grindstones

Hart[10] has described two kinds of siderosis The first, which he calls the red type of iron lung, is the result of the first type of dust In this type, pneumonoconiotic induration predominates, and there is little tuberculosis The other, the black type, is found in metal grinders and polishers, the indurative process is less pronounced and tuberculosis is unrestrained In this type the mortality from tuberculosis is high

The two cases here presented illustrate these two types of siderosis

REPORT OF CASES

CASE 1—*History*—A colored man, aged 37, who worked as a metal polisher in a machine shop, entered the hospital on Sept 11, 1928 For six or eight months he had been growing progressively weaker, so that he worked only for short periods During this time, he had lost about 25 pounds (11 3 Kg) He had severe cough which was productive of much sputum, but he had never expectorated blood His appetite was poor For three months he had been short of breath and had had fleeting pains in the chest, abdomen and flanks He had had typhoid fever and malaria at the age of 12 and pleurisy in both sides a year before entrance Fourteen months previously, he had had a peritonsillar abscess He had had gonorrhea and a bubo, which had been incised, but he said that he had not had a syphilitic infection One brother died of tuberculosis at the age of 28

Physical Examination—The patient showed large tonsils Expansion of the lungs on both sides was poor Dulness was present over both lungs, especially over the apexes The breath sounds were increased throughout He had anemia (hemoglobin, 55 per cent, red blood cells, 3,650,000) The Wassermann and Kahn reactions were three plus A roentgenogram showed diffuse infiltration in both lungs with probable cavity formation The temperature went up to about

9 Merkel, G Die tuberkulose Erkrankung siderotischer Lungen, Deutsches Arch f klin Med **42** 179, 1888

10 Hart, C Die anatomischen Grundlagen der Disposition der Lungen zu tuberkuloser Erkrankung, Ergebn d allg Path u path Anat **14** 405, 1910

100 F in the afternoon The clinical diagnosis was advanced pulmonary tuberculosis, and tubercle bacilli were found in the sputum

Course—The patient's condition remained the same until December 23, then, in the evening, the temperature suddenly went up to 104 F Râles were found throughout the thorax and evidence of cavitation in both upper lobes He coughed considerably and expectorated about a cupful of sputum daily With only occa-

Fig 1 (case 1) —Cut surface from the right lung

sional days of normal temperature, he grew progressively weaker, until he died on March 14, 1929

Necropsy—Necropsy was performed within an hour after death The body was that of an emaciated colored man, aged 37, 72 inches (182 9 cm) long and weighing 100 pounds (45 4 Kg) There was a subicteric tinge to the sclerae The supraclavicular and infraclavicular fossae were deep and the ribs prominent On removing the breastplate, one saw in the thymic region six large, discrete, firm, decidedly brown nodes from 1 5 to 3 5 by 2 by 2 cm On section, these

glands were deep brown with small grayish areas The right border of the heart was 2 cm to the right of the right sternal margin, the enlargement of the heart was due to a dilatation of the right ventricle and auricle, especially the latter The heart weighed 290 Gm, and except for a pale, rather soft myocardium, showed no pathologic changes

The posterior parts of both lungs were firm and woody The anterior parts were distended with air, and the part near the apex presented large and small bullous enlargements, puncture of such a bullous body allowed the escape of air and caused the collapse of the bulla Both apexes were occupied by firm masses of solid grayish and grayish-brown tissue in which pearly gray streaks could be seen These masses extended down into the lower lobes, but were here broken up by small areas of air-containing lung tissue Near the bases of the lungs, dark gray to black areas formed smaller, discrete nodules from 2 to 10 mm in diameter, and often in the center of such a nodule could be seen a streak or speck of brown In the apex of the lower lobe of the left lung there was an area made up of numerous grayish-white gelatinous patches ranging up to 6 mm in diameter Similar gelatinous areas were found in the right middle and the lowermost part of the right lower lobe (fig 1)

The tracheobronchial lymph nodes were large the largest being 5 by 3 5 by 3 cm They were discrete, very hard and brown or grayish-brown, the brown being much more pronounced than in the lung tissue In the centers of some of them were pinhead-sized grayish nodules

The spleen weighed 240 Gm and was firm On the capsule were numerous pinhead-sized brown spots, like flakes of tobacco, slightly raised above the surface The markings on the cut surface were indistinct, the pulp was firm and the trabeculae were thickened

The liver weighed 1,900 Gm The markings were distinctly seen, and the only abnormality was the coppery-brown hue of the organ

Near the middle of the pancreas there was a single small, brown lymph node The remaining organs showed nothing pathologic

The anatomic diagnosis was pulmonary siderosis of the black type, siderosis of the tracheobronchial, anterior mediastinal and peripancreatic lymph glands, tuberculous bronchopneumonia, tuberculosis of the tracheobronchial lymph glands, bullous emphysema of the lungs, chronic pleuritis, dilatation of the right auricle and ventricle, brown atrophy of the heart, chronic splenic tumor

Microscopic Examination—The lobular structure of the liver was well preserved The cords of liver cells were of normal appearance and arrangement Within the liver cells were golden brown granules of pigment, and occasionally these were clumped together, but they stained a deep orange with sudan III and were in all probability lipofuscin Smaller dustlike granules of pigment giving the prussian blue reaction for iron were scattered diffusely through the cell The sinusoids were dilated, but contained little blood Into them protruded many cells which were prominent because they contained pigment The cells were spindle-shaped, branched or stellate and adherent to the liver cords or slightly separated from them Their nuclei were oval but obscured by the accumulation within the cytoplasm of tiny round particles of golden brown or deep brown pigment Only occasionally could a cell be seen which was similar in all respects to those described but which contained no pigment All of the granules stained deep blue with potassium ferrocyanide Occasional Kupffer cells loaded with iron pigment were so large as to obstruct the lumen of the sinusoid The portal areas were of normal size and were normal, except for the presence of a few large cells with round or oval nuclei which contained brown pigment giving the iron reaction There was

nowhere any increase in connective tissue or lymphocytes The pigment granules everywhere were round or oval, crystalloid or angular shapes were absent Nor were there pigment granules outside of the cells The capsule contained no pigment

The malpighian corpuscles of the spleen were small Their central arterioles were normal and were surrounded by a narrow zone of lymphocytes among which there were occasional large, oval, often branched cells containing tiny round pigment granules The splenic sinuses were narrow, and were lined by low cells which showed no pigment even in the iron stain Sometimes a large pigment-containing cell was visible within the lumen of a sinus The splenic pulp was very cellular, made up of lymphocytes and macrophages, many of the latter containing fine, dustlike granules of brown pigment Part of this pigment stained blue with potassium ferrocyanide, but some of it remained unstained A single cell contained one or the other kind of pigment, never both The amount of pigment giving the iron reaction was large, most of it was found at a distance from the malpighian corpuscles, while the greatest amount of pigment not giving the iron reaction was found in that part of the pulp immediately adjacent to the corpuscles The connective tissue trabeculae were not thickened, but many of them contained large cells which were filled with round pigment granules giving the reaction for iron There was no pigment free between the connective tissue fibers The capsule was greatly thickened in small areas and contained a large amount of pigment all in the form of round, deep brown granules within cells and all giving the reaction for iron The pigment-containing cells tended to occur in clumps

The glomeruli of the kidney appeared normal The tubules were slightly dilated, the lining epithelium stained poorly and was irregular and in places necrotic The blood vessels appeared normal Nowhere was pigment to be seen, and staining with potassium ferrocyanide revealed no iron

The lymph nodes in the tracheobronchial, anterior mediastinal and peripancreatic regions all showed the same structure, except that there was less pigment in the last The structure of the glands was made distinct by the dilatation of the marginal and the interfollicular lymph sinuses These were lined by prominent endothelial cells which bulged into the lumen and were filled with golden brown pigment granules Some of these endothelial cells were huge and widely distended by the pigment The lumen of the sinuses was filled by pale cells, from about four to ten times as large as a small lymphocyte, with large, pale, oval, vesicular, eccentrically placed nuclei and with homogeneously pink cytoplasm About one in every ten or fifteen of these cells contained pigment granules, usually only three or four round granules, sometimes many, so that the cell was sometimes filled A few small lymphocytes were seen in the sinuses Nowhere were there transition forms between lymphocytes and the large pale cells All this pigment gave the prussian blue reaction for iron, and, in addition, many of the macrophages in the sinuses stained diffusely light blue, with the exception of the nuclei, as though the iron were in solution in the cytoplasm The follicles were made up of a loose group of small lymphocytes between which there were many large round or irregularly branching cells packed with golden brown pigment In the center of the follicles, these pigment-containing macrophages were close together and formed nodules In the medulla there was a large amount of iron-containing pigment both within the sinuses and in the medullary cords

The branches of the afferent lymph vessels outside of the capsule (fig 2) were much distended, the lining endothelium was prominent and filled with iron pigment Within the lumen were cells like those in the lymph sinuses, with about the same proportion of iron-containing cells The branches of the efferent lymph

vessels in the hilus of the gland were similarly dilated, lined by pigment-containing endothelium and filled with iron-containing cells, but many of the latter were necrotic and there was much debris within the lumen

Several of the lymph glands examined showed tubercles, for the most part small, only one large caseous area was found Each tubercle consisted of a central necrotic area surrounded by macrophages filled with pigment The necrotic areas, too, contained pigment, occasionally still within cells, more often free in the necrotic mass The amount of pigment varied inversely with the size of the tubercle Giant cells were few, but they contained clumps of iron pigment in the

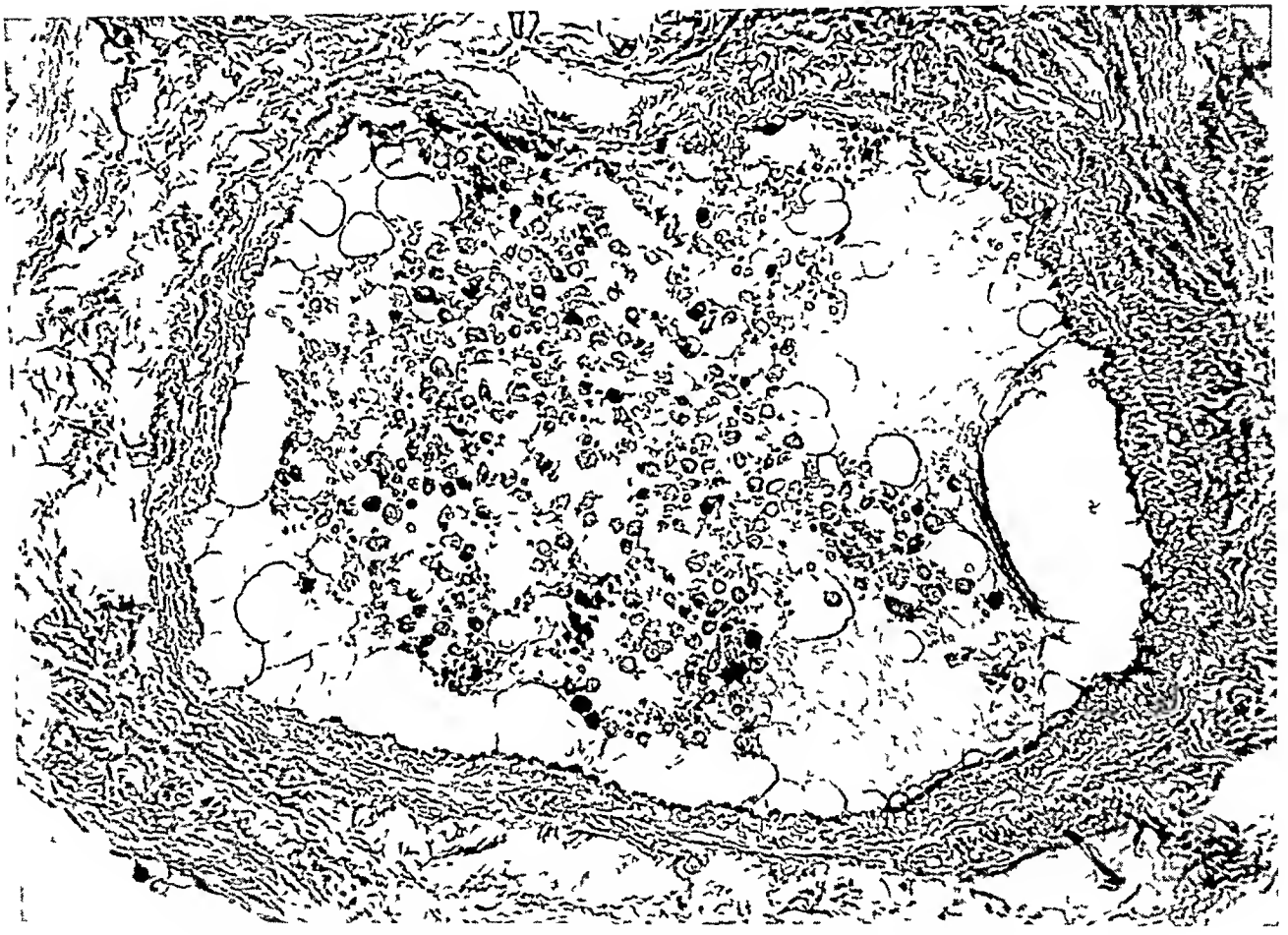

Fig 2 (case 1) —An afferent lymph vessel at the periphery of a gland, treated with potassium ferrocyanide and hydrochloric acid followed by lithium carmine All the black is iron In addition, many of the cells are stained diffusely light blue

center separated from the peripherally placed nuclei by a zone of iron-free cytoplasm There was no attempt at encapsulation of the tubercles The fat tissue around the lymph gland appeared normal, except that around the nuclei of the fat cells there were varying numbers of pigment granules which gave the iron reaction The fat tissue in other regions of the body did not show the same phenomenon

The pigmented, firm portion of the lungs was made up of dense strands of relatively acellular hyaline connective tissue, which formed an interlacing mesh-

work, in the interstices there were numerous large round cells filled with pigment, and a relatively small amount of extracellular pigment The fibrocytes and the fibroblasts contained pigment granules close to the nuclei The pigment was of three kinds (1) black pigment, much of which was extracellular and tended to occur in clumps, (2) a deep brown pigment which did not give the prussian blue reaction for iron, was principally extracellular and was found in the denser parts of the tissue, (3) a deep brown pigment which gave the prussian blue reaction, was entirely intracellular and was present in the more cellular portions In this thick tissue there were small groups of dilated and irregular alveoli, with the lining cells bulging out into the lumen, but only occasionally containing pigment Within the lumen were numerous large round and oval cells with indistinct nuclei, the cytoplasm filled with round pigment granules The largest of the cells were partially necrotic, and the pigment free in the lumen of the alveoli evidently came from the disintegration of these macrophages Within the interalveolar septums there were many large cells filled with pigment All of this pigment gave the prussian blue reaction The smaller bronchi (fig 3) were lined by tall columnar epithelium in which fine granules of brown pigment giving the reaction for iron were present between the nucleus and the free margin of the cell This portion of the cell was large, stained poorly and could be seen in places to be partially pinched off, pieces of pigment-containing necrotic material were seen in the lumen of the bronchioles

The dark nodules seen and felt in the lung had a characteristic structure In the center there was a small branch of an artery Around this, arranged in concentric fashion, were large pigment-filled cells Fibroblasts, also arranged concentrically about the vessel, gave to the nodules the appearance of whorls of tissue about the central arteriole All the pigment present gave the iron reaction, and all of it was intracellular There was no pigment in the vascular endothelium or in the walls of the vessels

The gray soft area in the lung was an area of tuberculous pneumonia with small foci of caseation, and with only occasional pigment granules

Other areas of the lung showed scattered tubercles, some of which were close together and confluent, forming nodules of macroscopic size These resembled closely the tubercles in the lymph glands central necroses containing free iron pigment a zone of macrophages loaded with pigment, many lymphocytes, few giant cells almost no fibrosis The tissue adjacent to the tubercles consisted of masses of large cells filled with iron pigment with no proliferation of connective tissue

Bone-marrow and the gastro-intestinal canal were unfortunately not taken for microscopic study

Chemical examination of the densest and blackest portion of the lung showed 8 9 per cent of the moist weight to be iron (computed as the oxide) and 12 5 per cent silicates

Case 2—*History*—A colored man, aged 38, entered the hospital on Oct 26, 1928 He had worked in a mine in Alabama How long he had worked in this or in similar mines is not known For three years he had complained of weakness, shortness of breath and heart consciousness, and had lost 48 pounds (21 8 Kg) in weight For two years he had had a dry cough Weakness was progressive In the last four months he had had swelling of the feet, which disappeared at night, also nausea, which was most pronounced in the morning and was often accompanied by vomiting Expectoration had been moderate, he had never had hemoptysis For a year the patient had been hoarse In his past there was nothing of

note, except that he had had pneumonia one year previous to entrance into the hospital, there was no history of tuberculosis in his family

Physical Examination—At the time of admission, the physical examination showed a poorly nourished colored man, who was apparently not acutely ill He had wheezing breathing and a metallic cough which became worse on exertion Examination of the chest showed prominent supraclavicular fossae with dimin-

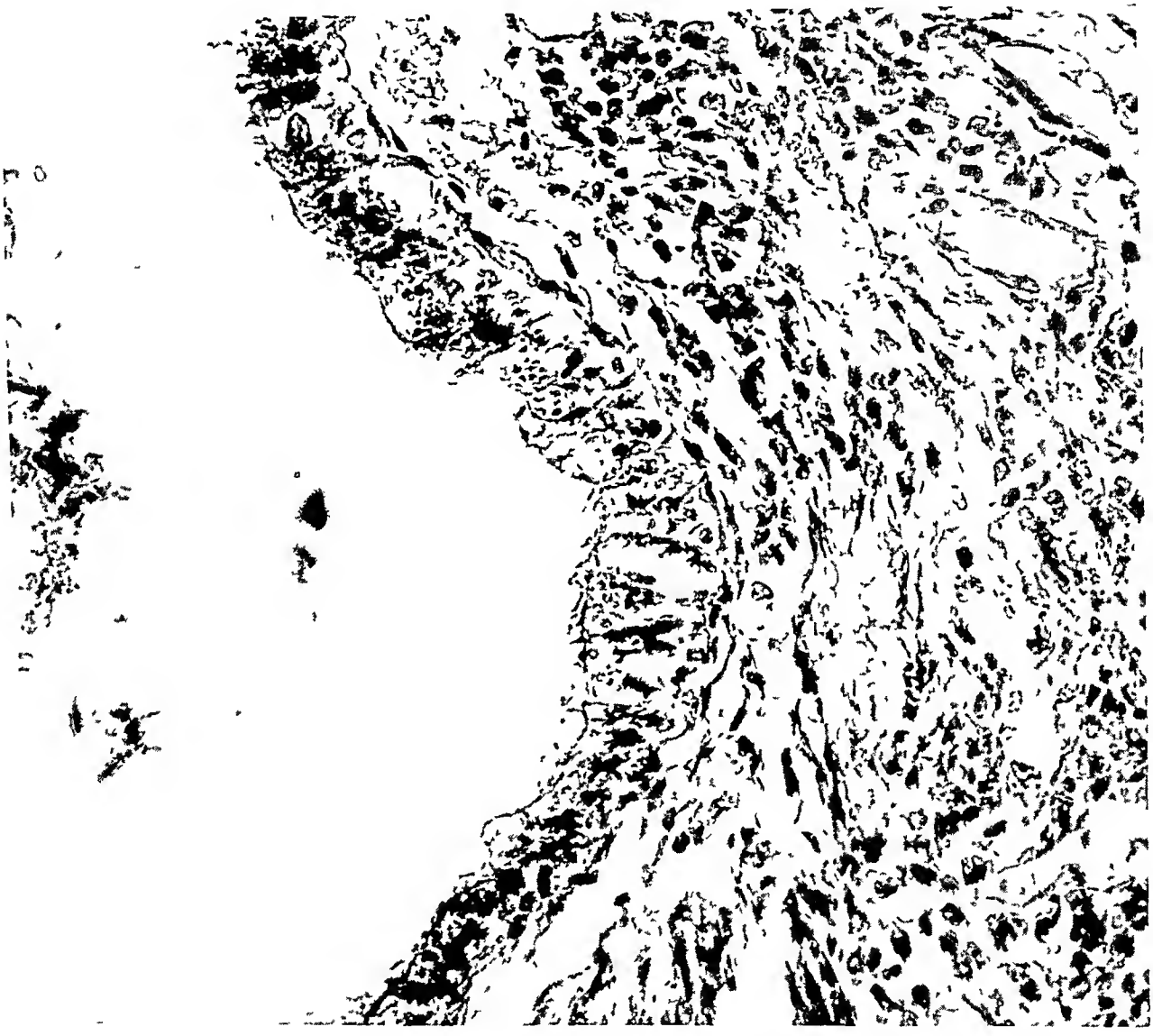

Fig 3 (case 1)—A bronchiole with granules of pigment in the lining cells At the extreme left are portions of desquamated epithelium containing pigment This pigment gives the reaction for iron Hemalum and eosin

ished tactile fremitus and dulness on the right The right apex and the entire left lung were dull on percussion The breath sounds were increased on both sides, but there were no râles The apex beat was displaced to 2 cm to the left of the mammary line and was diffuse The only abnormality in the heart sounds was a marked accentuation of the second pulmonic His hemoglobin was 55 per cent (Sahli), and the red cell count 3,800,000 A moderate amount of albumin

and many casts were present in the urine The results of the Wassermann and Kahn tests were negative The temperature of the patient remained normal during his stay in the hospital, and his pulse rate varied between 90 and 116 A definite diagnosis was not made, but pulmonary tuberculosis and an aortic aneurysm were strongly considered Roentgen examination showed increased density over the right upper lobe and almost the entire left lung, with some infiltrations in the right middle and lower lobes The mediastinal structures were drawn toward the left These observations were considered as evidences of advanced pulmonary tuberculosis

The patient's condition remained about the same until November 6, when he suddenly began coughing a great deal, became very dyspneic and after a few hours died

Necropsy—Necropsy was performed about eight hours after death The body was that of a fairly well nourished colored man, 38 years old, 68 inches (172 7 cm) long and weighing 146 pounds (66 2 Kg) The abdomen was slightly distended On removing the breastplate, one found several large, firm, very brown lymph glands in the thymic region and slightly adherent to the under surface of the sternum The left pleural cavity was nearly completely obliterated, and the lung was firmly adherent to the parietal pericardium The right lung was moderately adherent posteriorly and near the apex The pericardial sac contained about 150 cc of clear, straw-colored fluid

At the margin of the left apex there were large bullous enlargements which collapsed after puncture, with the escape of air under tension The entire upper lobe and the apex of the lower lobe were consolidated and woody A hard, deep reddish-brown mass occupied the entire upper lobe and seemed to be surrounded by a lighter capsule The only structure to be made out in this mass was a whorl-like configuration (fig 4) The upper part of the lower lobe was similarly consolidated, but there was no encapsulation, and the lower margin of the consolidated portion merged imperceptibly with the adjacent lung In the rest of the lower lobe there were numerous hard brown nodules, from pinhead size to 3 or 5 mm in diameter, more easily felt than seen Their size and number decreased from above downward The remainder of the lung tissue showed a prominent orange-brown reticulum The right lung was of similar appearance The entire upper lobe and about one third of the lower lobe were completely consolidated, but there was no definite encapsulation

The tracheobronchial lymph nodes were all enlarged, brown, firm and discrete Several of them, especially the larger ones, which measured 6 by 3 by 3 cm, showed areas of exactly the same appearance as the most consolidated parts of the lung, brown, firm masses, with a whorled gray structure faintly visible, surrounded by a definite capsule Other glands showed prominent pinhead-sized nodules diffusely scattered through their substance At the hilus of the right lung there was a single calcified lymph gland

The liver weighed 1,800 Gm , the capsule was smooth The markings were prominent reddish areas on a yellowish background

The spleen weighed 220 Gm In the capsule were small nodular areas of brownish thickening The parenchyma was soft, and contained much blood, the markings were indistinct

The pancreas was firm and had a slightly brownish hue The lobules were widely separated by fibrous tissue and fat. In the surrounding tissue were numerous brown lymph nodes, the largest 2 by 1 cm Some were a homogeneous deep brown, others contained grayish, translucent areas

Fig 4 (case 2) —Pulmonary siderosis

The kidneys, heart, brain, suprarenal glands and gastro-intestinal tract showed no pathologic changes

The anatomic diagnosis was pulmonary siderosis of the red variety, siderosis of the tracheobronchial, substernal and peripancreatic lymph glands, siderotic deposits in the capsule of the spleen, bilateral adhesive pleuritis, hydropericardium, atrophy of the pancreas

Microscopic Examination—The lobular structure of the liver was well preserved, the cords of liver cells were arranged in normal fashion, the blood spaces between them were dilated, but contained little blood Many of the liver cells contained a few brownish granules which gave the prussian blue reaction for iron The Kupffer cells were prominent, nearly all of them contained numerous golden brown granules, all of which gave the iron reaction These cells also contained fat droplets, fat in fine droplets was found also within the liver cells The portal areas were more prominent than normal, they contained accumulations of lymphocytes, but the greatest part of these areas was formed by connective tissue In the latter there was a moderate quantity of deep brown pigment, some of it within small oval or spindle-shaped cells, most of it extracellular None of this pigment gave the prussian blue reaction

The malpighian corpuscles of the spleen were few in number, but of normal appearance Among the lymphocytes there were large branched cells filled with brown pigment which gave the prussian blue reaction The sinuses were dilated and contained much blood Their endothelial lining cells were low cuboidal, they contained no pigment In the pulp cords there were large round and oval cells containing round granules of iron pigment Sometimes, instead of showing blue granules, the entire cell cytoplasm was stained blue The trabeculae were slightly thickened and contained a few cells filled with iron pigment The capsule was thickened and contained a moderate amount of pigment of two kinds an intracellular pigment which gave the iron reaction, and an extracellular pigment which did not The former was much greater in amount

The kidneys were of normal appearance and contained no pigment

Sections taken from the dense encapsulated mass in the upper lobe of the lung (fig 5) showed only enormous masses of brown pigment contained within dense fibrous connective tissue which contained few nuclei Small amounts of black pigment were also present Only occasional granules of this pigment stained by the Perls method for ferric iron or by Nishimura's modification of the Turnbull reaction for ferrous iron The capsule in this region was very thick, but much more cellular than the main mass It, too, contained much pigment, but most of it was within large macrophages and stained deep blue by the Perls method

Sections taken from the base (fig 6) showed small nodules scattered through the parenchyma, which were most numerous near the capsule Each nodule (fig 7) showed a characteristic concentric layering of connective tissue about a small blood vessel, in the meshes of the connective tissue were numerous large cells distended by granules of dark brown and golden brown pigment Nearly all of this pigment stained deep blue with potassium ferrocyanide In the alveolar septums there were similar large cells containing iron pigment In some areas, the alveoli were filled with large pigment-containing cells The lining cells of the alveoli were never found to contain pigment

The lymph glands in the tracheobronchial and anterior mesenteric regions showed two kinds of changes One group, comprising especially the smaller glands and including the peripancreatic nodes, showed the same changes described for case 1 dilatation of afferent, marginal, interfollicular and efferent channels, with iron pigment in the lining endothelium and in the numerous macrophages

filling them, and iron pigment in numerous large pale cells within the follicles and especially in the medulla The larger glands, however, had a different appearance much or, in some glands, practically all of the lymphoid tissue had been replaced by large masses of connective tissue, relatively acellular but containing clumps of dark brown and golden brown pigment Only a small portion of the pigment gave the reaction for iron In glands in which some lymphoid tissue remained there were numerous pigment-containing cells, the pigment staining deep blue with potassium ferrocyanide

Some of the glands showed tubercles, the mesenteric glands contained large areas of necrosis surrounded by tubercles, but no pigment In the tracheobronchial and peripancreatic nodes, there were many tubercles made up of caseous



Fig 5 (case 2) —The margin of the firm node in the apex of the lung The pigment in the pleura gives the reaction for iron, that in the firm masses at the right does not

centers containing pigment granules, surrounded by pigment-filled macrophages and showing one or two Langhans' giant cells Many of the latter contained several granules of pigment All of this pigment gave the reaction for iron Staining of such sections by the Ziehl-Neelsen method revealed acid-fast bacilli within the tubercles

Remnants of thymus tissue showed good differentiation of cortex and medulla Hassall's bodies were partly calcified and contained fat There was no iron pigment in the thymus

Fig 6 (case 2) —Section from the base of the lung, seen under low power Note the central arteriole in each nodule The portion outlined by the rectangle is shown in figure 7 Hemalum and eosin

Fig 7—High power magnification of portion outlined by the rectangle in figure 6

Chemical Examination—Portions of tissue from the tumor-like area in the upper lobe of the lung yielded 7 96 per cent of iron (calculated as the oxide) Only slight traces of silicates were found and no other metals Portions of the lung tissue dried in a paraffin oven were not attracted by a magnet, but putting such pieces of tissue for a moment in the Bunsen flame caused them to become so attracted Heating the tissue slowly until all organic matter was removed left a rusty red powder which was attracted by a magnet

COMMENT

These cases illustrate the reaction of the body to the presence of a large amount of iron and iron-ore introduced by inhalation In many respects, siderosis is identical with other types of pneumonoconiosis In all, the earliest lesions are small pigmented nodules which are perivascular and peribronchial accumulations of the dust The number of such nodules is greatest in the upper parts of the lungs As the nodules become larger, they acquire a firm fibrous capsule In the apex, they are close together, and may become confluent and finally form a large tumor-like mass involving an entire apex Oehmann[6] spoke of a granite hard upper lobe in one of his cases of silicosis This massive infiltration has, however, been much more common in siderosis than in other types of pneumonoconiosis If the migration of dust to the apexes is to be explained by a lymphatic spread, the greater solubility of iron may explain this greater frequency

Enlargement of the lymph glands at the hilus occurs early and is a constant observation in pneumonoconiosis Usually the glands are only moderately enlarged, only uncommonly have they been noted to approach the size found in the two cases herein reported Klehmet[11] said that they may be seen in roentgen plates and that they may cause compression of the esophagus or trachea In my second case, pressure of the glands on the recurrent laryngeal nerve caused hoarseness and a brassy cough, which led to the suspicion of an aortic aneurysm, a condition noted only once before (Klehmet[11]) Occasionally lymph glands near the spleen or pancreas have been noted to contain the foreign matter (Klehmet) In my two cases, in which the lymph glands at the hilus of the lungs were very large, the peripancreatic glands were markedly involved The peculiar retrosternal packet of brown glands, identical in these two cases, leading in the second to a diagnosis of siderosis immediately on removal of the breastplate at necropsy has, so far as I have been able to find, never been noted

The transportation of iron from its depots in the lung is interesting Probably the most important mode of excretion is by the migration of iron-laden macrophages into the alveoli and their expectoration in the

11 Klehmet M Zur Diagnose der Pneumokoniosen, Beitr z klin d Tuberk 46 153, 1921

sputum When large quantities of iron are present, the epithelium of the bronchioles may aid in the excretion (as in case 1) terminal cytoplasmic portions which contain the pigment being cast off Thus if, after a careful taking of the occupational history, siderosis is suspected, iron may be found in the sputum by acidifying the latter with hydrochloric acid and adding potassium ferrocyanide, a deep blue color (prussian blue) indicating a positive reaction In the case of a metal polisher, who, shortly after these two necropsies, entered the Research and Educational Hospital for a gastro-intestinal complaint, but who had a slight cough and expectoration the aforementioned test applied to the sputum resulted at the end of a few minutes in the appearance in it of numerous fine deep blue flakes Control tests on about fifty sputums from tuberculous patients showed no positive reactions This test has been used successfully in iron mining districts by Klehmet [11] Hoke [12] and others Hoke noted that iron may be found in the sputum even five years after cessation of exposure Hare [13] said that the sputum may be red in siderosis Hoke [12] and Klehmet [11] described it as ochre-yellow Zenker [1] found red specks in the sputum Yet such sputum is not common, and in most cases only a chemical test will result in the discovery of the iron

The iron which cannot be carried off in the sputum is in part removed from the lung by way of the lymphatic channels It is probably for this reason (Tendeloo) that so much more iron is found in the upper lobes than elsewhere Macrophages carry the pigment through the lymph vessels to the lymph glands Some of these cells become necrotic in the course of their migration and the liberated pigment is taken up by the endothelium lining the lymph channels and the intraglandular sinuses Some of the pigment is retained in the lymph glands, some passes through the gland and reaches the efferent lymph vessels The finding of iron-containing macrophages in the efferent vessels of glands far removed from the hilus of the lung (anterior mediastinal and peripancreatic) is of importance in explaining what is to follow

Black pigment supposed to be coal dust, has occasionally been found in the spleen and less often in the liver, in anthracosis this is common Riddell,[14] in a case of silicosis, found pigment in the center of miliary fibrotic areas in the liver and in fibrous nodules in the spleen Langguth [5] found iron pigment in the spleen in a case of siderosis It has

12 Hoke, E Die Eisenlunge, Med Klin **21** 766, 1925

13 Hare, H A, in Osler and McCrae Modern Medicine Philadelphia Lea & Febiger, 1907, vol 3, p 752

14 Riddell, A R A Case of Silicosis with Autopsy Canad M A J **15** 839 1925

been assumed, and the statement is to be found in most American and German textbooks of pathology, that the pigment which reaches the spleen and the liver gets there following the breaking of a disintegrating lymph gland into a blood vessel Langguth gave the same explanation in his case of siderosis Kaufmann[15] said that in severe cases of anthracosis the pigment may be transported directly from the lung to the blood In these two cases a simpler explanation seems to be justified The pigment reaches the blood stream through the lymph channels and the thoracic duct For a long time, until the gland becomes fibrotic, there is no lymphatic blockade, but a continuous passage of pigment-laden macrophages through the lymph nodes so that even in nodes far removed from the site of entrance of the dust such cells may still be found in the efferent vessels

Severe cases of siderosis become, then, excellent means of studying the fate of inorganic iron injected into the blood stream of human beings In rabbits Polson[16] has recently studied the fate of such iron in experiments lasting as long as fourteen months The earliest accumulations of iron were in the lungs The tracheal lymph glands, but not the mesenteric, also contained iron The liver at first contained only small amounts of iron in the Kupffer cells, the latter became enlarged, often forming giant cells Later, the liver cells too, contained fine granules of iron, but oftener gave a diffuse blue color with potassium ferrocyanide In the last stages, iron was found only in "giant cells" at the periphery of the lobule The spleen early contained much iron, later only small groups of iron phagocytes were found in the splenic pulp which disintegrated, liberating free granules of iron The kidneys contained no iron, except immediately after the injections, when emboli were found in the glomerular tufts The pancreas contained no iron, unless foci of inflammation were present

This corresponds closely in many respects with the observations in these two cases of siderosis The differences are to be explained by the greater length of the human experiment The ultimate fate of the pigment which cannot be excreted seems to be inclusion within dense connective tissue

In addition to transportation there is a gradual transformation of the iron pigment Some of the iron gives the prussian blue reaction; some of it does not Of course, in case 1, it may be thought and with good reason, that the nonreacting pigment is a silicate but in the second case all the pigment has been shown by chemical analysis to be iron

15 Kaufmann, E Pathology, English translation, Philadelphia, P Blakiston's Son & Company 1929, vol 1 p 421

16 Polson C J The Fate of Colloidal Iron Administered Intravenously, J Path & Bact **32** 247 1929

Yet in the dense parts of the upper lobes and the fibrotic lymph glands in even this second case most of the iron gave no typical reaction Staub-Oetiker[17] noted that in areas of fibrosis in siderosis there was no reaction for iron, while in the periphery there was a strong reaction for iron Unless the iron is included in a complex radical (as in a ferrocyanide), no inorganic form is known which will resist hydrochloric acid (as in the Perls method for iron) without dissociation to give a form which will react with a ferrocyanide or ferricyanide, no such complex inorganic iron compounds are known in the animal body The probability is, then, that the nonreacting iron is strongly combined with organic compounds, in a form as resistant to acid, as is, for instance, hemoglobin

It is to be remembered that in these two cases the pigment which gave the reaction for iron was almost entirely intracellular (except in necrotic regions), the nonreacting pigment was almost entirely extracellular To give the reaction, the pigment must be soluble It seems reasonable to conclude, therefore, that the iron which is in transport is in soluble form As soon as it becomes firmly combined with protein it remains stationary, surrounded by dense connective tissue

It is clear, too, why siderosis more than other types of pneumonoconiosis should be accompanied by a widespread distribution of the pigment In the first case in which there was much more silicon than iron in the lung only the more soluble iron was present in the liver and spleen (all the pigment in these organs gave the prussian blue reaction)

The distribution of the transportable iron is within cells of the reticulo-endothelial system, the wandering macrophages, the Kupffer cells of the liver, the reticulum cells of the spleen and lymph nodes and the lining endothelium of the lymphatic vessels and lymph sinuses The littoral cells lining the splenic sinuses contained no pigment Nowhere was pigment found in the endothelium of blood vessels The thymus, lying embedded in a mass of siderotic lymph glands, contained no iron The large cells making up the tubercles contained iron, except in the large caseous areas, in which iron was found only as free granules in the center In neither case were there many giant cells in the tubercles, but most of those present contained granules of iron in their centers

It is worthy of note that in spite of the large amounts of circulating inorganic iron there was anemia in both cases Even the hyperglobulia often accompanying chronic pulmonary fibrosis, which has been noted in other types of pneumonoconiosis (Hoke[12]), was absent in these cases It is even possible that the excess of iron may have acted as a poison to cause the anemia In the second case, the slight amount of

17 Staub-Oetiker H Die Pneumokoniose der Metallschleifer, Deutsches Arch f klin Med **119** 469, 1916

fibrotic tuberculosis of the lymph glands could not be responsible for the low red cell count It is to be recalled that Carleton[8] found early death from a toxic influence in guinea-pigs exposed to massive doses of iron dust

SUMMARY

Two cases of pulmonary siderosis are reported one in which the dust was metallic iron, produced the black variety of siderosis and ended in a florid tuberculous bronchopneumonia and one in which the dust was iron ore the siderosis of the red variety and the concomitant tuberculosis of the fibrotic type and limited to the lymph glands

In both cases there was a continuous attempt at excretion of the iron by macrophages which carried it into the alveoli and thence into the sputum, by excretion through the bronchiolar mucosa or by transference to the lymph nodes In the last event the pigment was either deposited in the gland or was carried through the gland and reached the blood stream probably by way of the thoracic duct Having reached the blood stream the iron was deposited in the cells of the reticuloendothelial system

In addition to transportation there was gradual transformation of the iron Only the soluble iron could be transported and was found intracellularly In the black variety in which more silicon than iron was present in the lung only the more soluble iron found its way into the blood stream Insoluble iron was found extracellularly in dense fibrous tissue

Where the accumulations of iron were greatest the amounts present were 8 9 and 7 9 per cent of the moist weight of the lungs

Chemical examination of the sputum for iron may be a great aid in the clinical recognition of siderosis

THE GIANT CELLS OF BENIGN GIANT CELL TUMORS OF BONE *

WILLIAM W JOHNSON, M D
SAN FRANCISCO

Many different views have been advanced in an attempt to establish the origin of the typical giant cells that are found in benign giant cell tumors of bone Between the years 1890 and 1900 this was a much discussed topic A review of the literature reveals the fact that the number of ideas on the subject nearly equalled the number of authors who wrote on the question From 1900 until the present, the literature contains no accounts of a special investigation of this subject, except for one article by Mallory [1] in 1911

Many cases of benign giant cell tumors of bone have been reported in the interim, and in each report a statement is made regarding the origin of the giant cells, but such statements can not be considered to be of any particular value because they are largely echos of statements made in preceding articles Thus King and Towne [2] in a recent report followed Mallory,[1] Goforth [3] followed Virchow,[4] etc

Kolodny [5] threw an interesting side light on the present situation when he quoted what he termed "the theory of histogenesis of the giant cell in vogue today"

Before entering on an investigation of any subject, the ideas previously advanced should be known In going back through the literature, I ran across the most varied concepts Virchow [4] and Rindfleisch began the discussion by asserting that the giant cells are hypertrophied bone cells set free by absorption of the bone matrix and are identical with osteoblasts Borst [6] agreed with this view and went further to say that since these cells are from the bone, the entire tumor is of bony origin

Ziegler [7] considered the giant cells as being formed by the process of indirect segmentation of the nuclei of osteoclasts

---

* Submitted for publication March 12 1930

From the Department of Pathology, Stanford University School of Medicine

1 Mallory, F B Giant Cell Sarcoma, J M Research **24** 463, 1911

2 King, N J, and Towne, G S Giant Cell Tumor of the Patella, Arch Surg **18** 892 (March) 1929

3 Goforth Giant Cell Tumor of Bone, S Clin North America **7** 299 1927

4 Virchow, R Die Krankhaften Geschwulste, Berlin, A Hirschwald 1864, vol 2, p 335

5 Kolodny, A Bone Sarcoma, Surg Gynec Obst (suppl 1-2) **44** 1 1927

6 Borst, N Das Verhalten des Endothelium bei der acuten und chronischen Entzundung, Verhandl d phys -med Gesellsch zu Wurzburg **31** 1, 1897

7 Ziegler E Lehrbuch der allgemeinen und speciellen pathologischen Anatomie fur Aerzte und Studirende ed 8 Jena G Fischer 1895, vol 2 p 447

Klebs[8] stated that the giant cells are large, rapidly growing osteoblasts which develop from decomposing bone cells and enlarge through mitotic division of the nuclei

Manz[9] claimed two possible modes of origin for the giant cells (1) formation by rapidly proliferating elements through multiple segmentation of nuclei and (2) in degenerating tumor tissue, from confluence of protoplasm of damaged cells

Several authors were of the opinion that they are derived from endothelium of angioblastic tissue Wegner and Malassez[10] agreed Stroebe[11] stated that "blood-vessels and giant cells stand in intimate relation Fine capillaries are seen entering and piercing the giant cells, perhaps without any genetic relation being present Sometimes the lumen of blood-vessels is seen sunken inside the giant cell body One often sees protoplasmic processes in a vessel lumen, or the latter more or less fills the body of the giant cell" He concluded therefore, that "giant cells develop from endothelium"

Lubarsch[12] noticed identical conditions and is in entire agreement with Stroebe[11] His belief was that the giant cells are "abortive vascular sprouts"

Ritter[13] made similar observations He pointed out the presence of what other authors termed "vacuoles" inside the giant cells He said "That we have to deal with vacuoles which are present in movable cells is hardly believable We can not exclude that in many cases we have to deal with a lumen which was already formed from vascular buds, because in a number of cases we have seen in such vacuoles red blood cells" He also drew an analogy by tracing the cells in Howship's lacunae to proliferating vascular endothelium

So it is seen that by 1900, various ideas had been advanced Giant cells were thought to originate from bone cells, osteoblasts, osteoclasts, decomposing bone tissue aggregate masses of stroma cells, confluence of protoplasm of decayed cells and from endothelium or angioblastic tissue

In 1911, Malloy[1] advanced the idea that these giant cells are formed at first by agglutination of the large mononuclear leukocytes of the blood, and later as a result of retrograde processes He drew attention to the fact that foreign bodies of any kind draw the large mononuclear leuko-

8 Klebs, E Die allgemeine Pathologie, Jena, G Fischer, 1889, vol 2, p 743

9 Manz Ueber Riesenzellensarkom der weiblichen Brustdrüse, Beitr z klin Chir **13** 66, 1895

10 Wegner and Malassez, L Arch de physiol norm et path, 1878

11 Stroebe, H Beitr z path Anat u z allg Path **7** 341, 1890

12 Lubarsch O Reisenzellensarkoma, Ergebn d allg Path u path Anat **1, 2** 365, 1895

13 Ritter, C Die Epulis und ihr Reisenzellen, Deutsche Ztschr f Chir **54** 1, 1899-1900

cytes from the blood to the part affected These cells then fuse forming the foreign body giant cell On boring a hole into the femur of a rabbit and leaving the bone dust, he observed the formation of these giant cells about the dust particles From this experiment he assumed that the giant cells of benign giant cell tumors of bone were similarly produced, although he made no investigations of the giant cells in such bony tumors From the experiments on rabbits he concluded that all giant cells of this type are formed in the same manner and signify only erosion and disintegration of bone substance

In a recent article on the interrelation of giant cell tumors of bone and osteitis fibrosa, Geschickter and Copeland[14] stated that the giant cells are always associated with fresh blood and new blood vessels They concluded, however, that the giant cells are accumulations of the round cells of the stroma, since they believed a histologic similarity can be seen in the nuclei

Today all these various concepts still stand, and little attempt has been made to sift the evidence, and to confirm or disprove any of them Ewing[15] in his book, "Neoplastic Diseases," sidestepped the issue by saying that "the origin of the giant cells is attributed both to bone cells and proliferating angioblastic cells"

OBSERVATIONS

In order to obtain further information at first hand, I made an examination of a series of eleven specimens of benign giant cell tumors of bone which had been collected in this department during the past twelve years Of five of these specimens paraffin blocks were found, which enabled us to prepare additional microscopic slides The remaining six are surgical specimens of which only one microscopic slide was sent to the department for the purpose of examination The evidence that I present in this paper represents the accumulated experience obtained by a careful examination of all of the eleven specimens The photomicrographic tracings that accompany the article represent pictures from eight of the specimens, the remaining three were found to be unsuitable for photographic work although the conditions found in them are similar High power photomicrographs were taken, and tracings made from them This procedure was resorted to because in this way the details could be much better shown and the essentials to be brought out could be more clearly depicted

14 Geschickter, C F and Copeland M M Osteitis Fibrosa and Giant Cell Tumor Arch Surg **19** 1 (Aug) 1929

15 Ewing, J Neoplastic Diseases, ed 2 Philadelphia, W B Saunders Company, 1922, p 280

The cells under discussion are the typical, large, multinuclear cells found in benign giant cell tumors of bone They vary greatly in shape and size and are opaque, acidophil cells containing small, oval, uniformly shaped nuclei, which are grouped in the central parts of the protoplasm They resemble the so-called "foreign body giant cell" It is found that these cells are much larger than would be suspected by observing them in a single microscopic slide By cutting serial sections it has been possible to identify the same cell in three and sometimes four consecutive sections Thus it is shown that cell processes and connections that are not apparent in one section can be found when other sections through the same cells are examined

The giant cells are found most abundantly in actively growing tumors and in areas rich in blood vessels This fact has been noted by many authors, and may be considered as definitely established This in itself suggests that there must be a connection between blood-vascular elements and the giant cells

In previous articles, the claim has been made that the accumulations of blood found in these tumors are usually due to hemorrhage This idea has been refuted many times, and my observations agree with the opinion of those who hold that this is not so I find that in most cases the blood does not lie in undefined pools, as one would expect if hemorrhage had occurred but is present in narrow preformed channels, which are close together in some areas and farther apart in others Moreover one does not always find the amount of pigment and of fibrous tissue that should result from the organization of numerous old hemorrhages The tumors are evidently extremely vascular and most of the blood lies in definite, large capillary channels

In all specimens, giant cells were found which formed part of the lining of these capillary channels in such a way that living, circulating blood elements were found in immediate contact with them It is especially important to note that there never is a layer of endothelium between the capillary lumen and the giant cells Instances of these facts are shown in tracings *A B C* and *D* in figure 1 In each of these pictures giant cells are shown forming portions of the walls of capillaries The capillary channels are all definitely outlined, and the nuclei of the endothelial lining definitely shown In every instance, the endothelium stops where the giant cell forms the wall of the vascular channel, so that the latter lies in immediate contact with the circulating blood

Having established these facts and knowing that endothelium is the normal lining of blood channels I attempted to ascertain if there actually is a connection between the endothelium and the giant cells Evidence that this is true was found in every specimen I have been able to show instances of giant cells developing in direct continuity with the blood

vessel endothelium The giant cell protoplasm extends into the endothelial wall at both sides and the cell per se thus lines directly the blood channel, and on each side of the cell the normal endothelium carries on the definite vessel outline (fig 1)

Stroebe in the article referred to earlier in this paper recounted the observation that fine capillary spaces are seen entering and piercing the

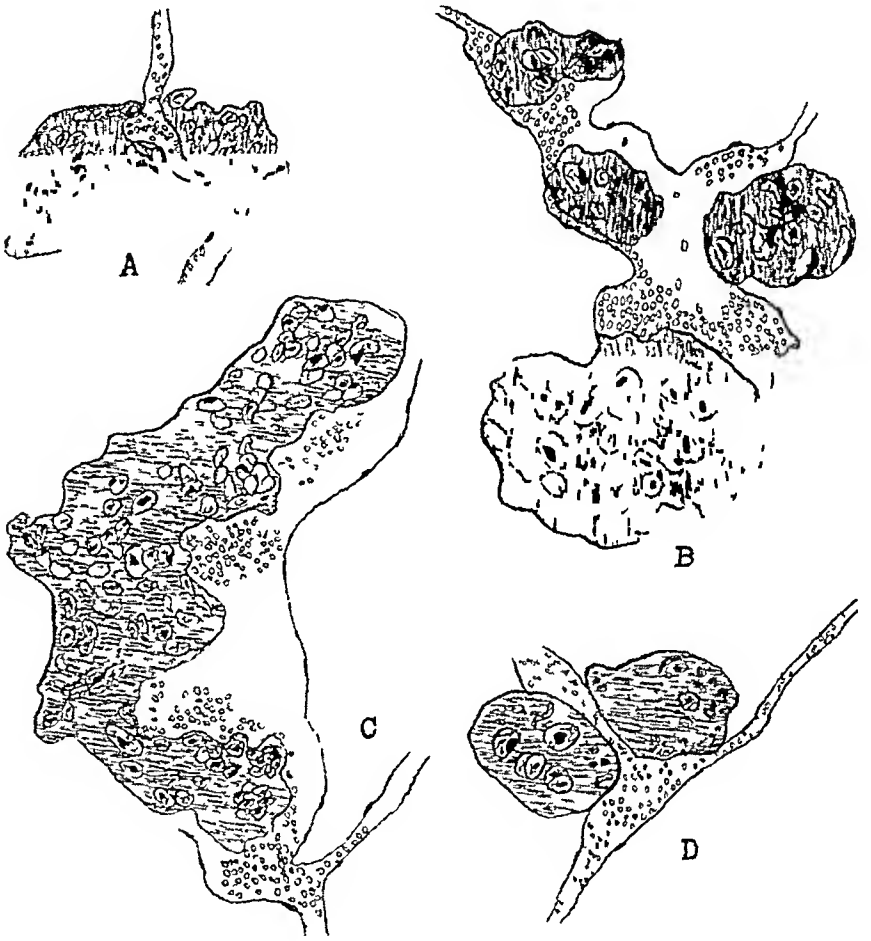

Fig 1—Blood vessels, the walls of which are partially formed by giant cells Note particularly that there is no endothelium interposed between the vessel lumen and the giant cells *A*, two giant cells forming portions of the walls of a capillary *B*, four giant cells of varied size forming a large portion of the walls of a blood channel The small cell that appears to lie within the vessel is forming part of the posterior wall of the channel, the remaining three line the walls *C*, one large giant cell forming the lining of a blood channel Blood fills the channel and lies in immediate contact with the cell *D*, a capillary dividing two giant cells The latter form the walls of the vessel

giant cells I can confirm this observation In some instances in which by chance a giant cell has been cut in exactly the plane necessary, it can be seen that the cell has been hollowed out from the vessel's side so that

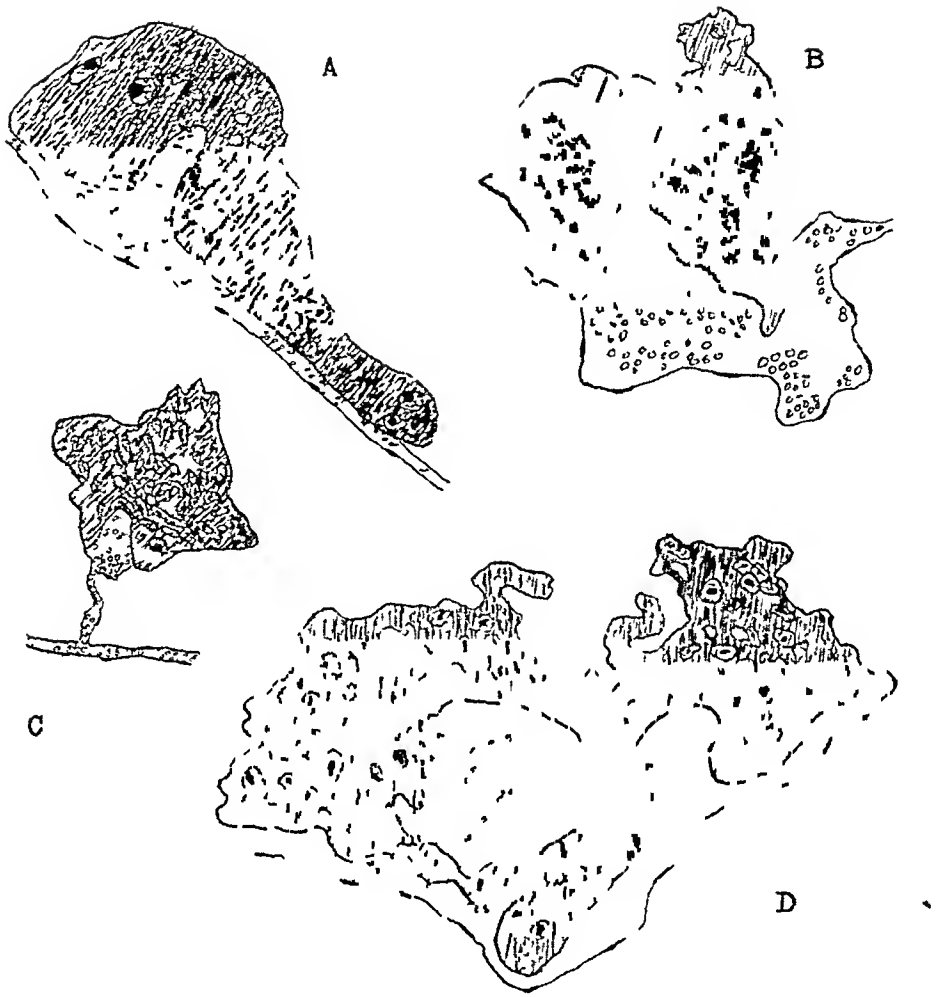

Fig 2—Giant cells lying in the walls of blood vessels, hollowing out of the giant cells has begun and blood is seen in the new channels Note particularly that no endothelium is interposed between the blood elements and the giant cells *A,* a giant cell forming a portion of the lining of the side of a vessel The hollowing out of the cell has begun from the blood vessel side, and this hollowed portion contains blood elements *B,* a giant cell is being hollowed out Blood elements are seen in the hollowed portion of the cell *C,* a giant cell formed at the end of a capillary The cell is partially hollowed out from the capillary's end Blood is seen inside the hollowed portion of the cell *D* a large giant cell forming a portion of the wall of a capillary The hollowing out process has occurred in two places Direct connection between the new vessels within the giant cell and the formed capillary can be seen Four smaller channels running in the opposite direction contain no blood and appear as "holes"

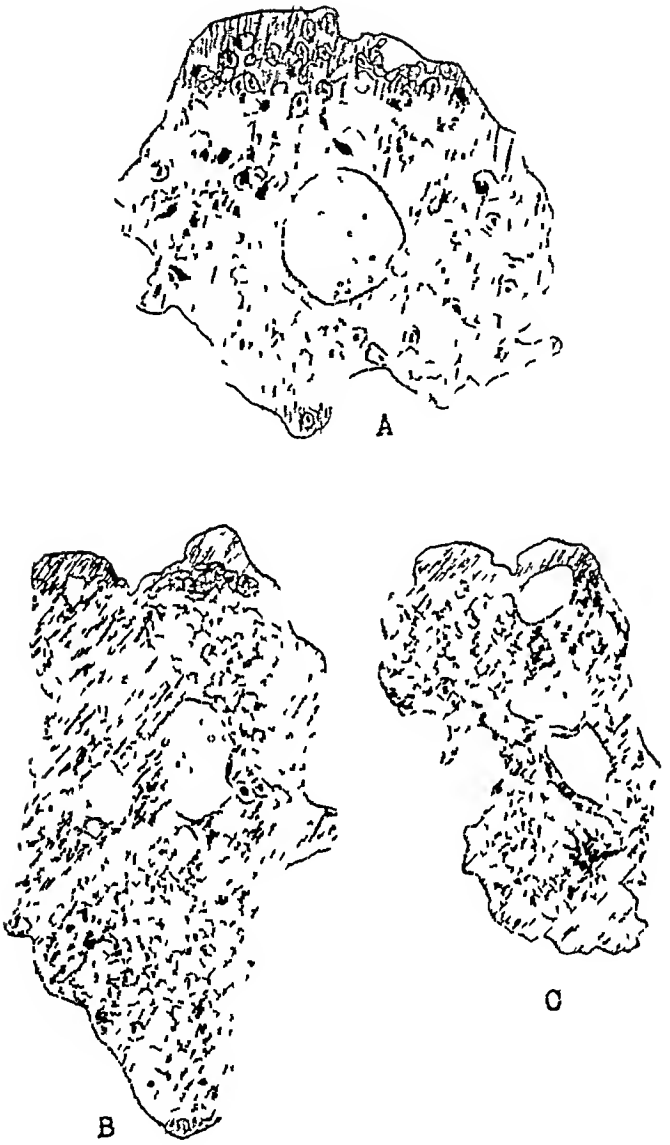

Fig 3—Giant cells in the bodies of which new blood channels are seen Some of these channels are empty and appear as "holes," the "vacuoles" or "phagocytosed fatty droplets" of some authors, others are filled with blood Note that the walls of these channels are formed directly and entirely by the giant cell *A*, a large giant cell, hollowed out and cut so as to show a cross-section of an intracellular capillary which is filled with blood *B*, a large giant cell, hollowed out and cut so as to show cross-sections of two intracellular capillaries which contain blood *C*, a large giant cell containing three large intracellular capillaries, one of which is filled with blood The remaining two are identical in structure with the former, but are empty

blood channels are formed, communicating with the vessel and running into the giant cell Thus new blood channels are formed Figure 2 tracings *A, B, C* and *D,* depicts instances in which the hollowing out process has occurred Blood is seen to be present in the capillaries and extends directly into the hollowed out portions of the giant cells Here again the intimate relation of endothelium and giant cells is shown, as well as the fact that the normal endothelial lining of the vascular channels is lacking in the portions where the giant cells form the walls of the capillaries

Should a cell that contains such a blood channel be cut in the opposite direction, a cross-section of the newly formed capillary would show within the protoplasmic body of the giant cell The picture would be that of a giant cell in the body of which there is a round opening of capillary size Practically all authors on the subject have noted this point and, since there seemed to be no other explanation of these occurrences, have labeled these holes "vacuoles,' or attributed them to phagocytosed fatty droplets Ritter was certainly correct when he stated that vacuoles in vigorous growing cells are hard to imagine as a possibility If these are bits of phagocytosed fat, they should stain readily with the differential fat stains, which is not the case There must therefore be another explanation I believe that it can be shown that these holes are new blood channels Blood has been found in them in many places In adjacent cells and sometimes in the same cell, these new blood channels, identical in every way, can be observed, some containing blood and others empty I believe that this definitely proves that these spaces are the lumen of new blood channels Figure 3 tracings *A, B* and *C,* show giant cells containing within their bodies cross-sections of these channels filled with blood Tracing *C* also shows two empty blood channels that lie parallel to and are identical with the one that contains blood These empty capillaries are the spaces that have frequently been taken for "vacuoles" or "phagocytosed fatty droplets' by some authors Here again the blood is shown to be in intimate contact with the giant cells, no endothelium being interposed

This completes the proof of the endothelial origin of the giant cells Confirmation of these observations should be readily obtained by any one who carefully examines the giant cells in these tumors microscopically in serial sections

SUMMARY

On microscopic examination of giant cells from eleven specimens of benign giant cell tumors of bone, I have found that giant cells are most numerous where the vascular tissue is most abundant, that giant cells form a portion of the lining of blood-vascular spaces, that there is no

break in continuity between early giant cells and the endothelial lining of the vascular spaces, that the giant cells lie in immediate contact with living blood elements without the interposition of an endothelial lining, that excavations or hollows in the giant cells communicate directly with the lumen of blood vessels, that the "holes" seen frequently in the body of a giant cell are in reality the lumen of newly formed blood-vessels, many of them being filled with blood

These observations show that the giant cells of benign giant cell tumors of bone arise from the endothelium of the blood capillaries

CONGENITAL ATRESIA OF THE TRICUSPID ORIFICE

PAUL J BRESLICH, M D
John Jay Borland Fellow in Medicine
CHICAGO

Congenital atresia of the tricuspid orifice of the heart is a rare cardiac anomaly Rauchfuss,[1] in 1878, thought that only five of the sixteen reports of tricuspid atresia which he found in the literature concerned true developmental defects while the others described lesions which had probably resulted from fetal endocarditis Kuhne,[2] in 1906, reported two cases in which atresia of the tricuspid orifice was not associated with other grave cardiac deformities, and she reviewed the descriptions of six similar instances already on record She classified these lesions as simple congenital atresia of the tricuspid orifice Kuhne's classification was later supported by Wieland[3] who described an instance of atresia of the tricuspid orifice in 1914 and called attention to a report made by Sieveking[4] in 1854 Huebschmann[5] reported two instances of tricuspid atresia in 1921, but only the first of these was a simple atresia belonging to Kuhne's group Additional reports were made by Monckeberg[6] in 1924 and by Rihl, Terplan and Weiss[7] in 1929

Recently a patient with congenital atresia of the tricuspid orifice was observed in the pediatric service of Dr Isaac A Abt at St Luke's Hospital

---

Submitted for publication, April 12 1930

From the Henry Baird Favill Laboratory and Pediatric Service of St Luke's Hospital

1 Rauchfuss, C Die angeborenen Entwickelungsfehler und die Fotalkrankheiten des Herzens und der grossen Gefasse, Handbuch der Kinderkrankheiten, herausgegeben von Gerhardt Tubingen, 1878 vol 4 part 1, p 99

2 Kuhne, M Ueber zwei Falle kongenitaler Atresie des Ostium venosum dextrum, Jahrb f Kinderh **63** 235 1906

3 Wieland, E Zur Klinik und Morphologie der angeborenen Tricuspidalatresie, Jahrb f Kinderh **79** 320, 1914

4 Sieveking Congenital Malformation of the Heart Absence of the Right Atrioventricular Orifice Patulous Foramen Ovale, Defective Interventricular Septum, Tr Path Soc London **5** 97 1854

5 Huebschmann P Zwei Falle von seltener Herzmissbildung, Verhandl d deutsch path Gesellsch **18** 174 1921

6 Monckeberg J G Die Missbildungen des Herzens in Henke, F, and Lubarsch, O Handbuch der speziellen pathologischen Anatomie und Histologie, Berlin, J Springer, 1924 vol 2, p 1

7 Rihl, J , Terplan K and Weiss F Ueber einen Fall von Agenesie der Trikuspidalklappe Med Klin **25** 1543 1929

A white male infant (J E) aged 8½ months, was brought to the hospital because of attacks of cyanosis noticed by the mother since the baby was 2½ months of age At first the attacks occurred only when the child was restless or feeding but later there was an almost continuous cyanosis of the hands and feet At the onset of the attacks, the child had an acute left suppurative otitis media, and the discharge from the left ear did not stop entirely The infant was undernourished His birth weight was 9 pounds and 5 ounces (595 3 Gm) and he had been breast fed for only three months There was no history of cardiac disease in the family and both parents and a brother and sister were in good health All three children had been delivered by cesarean section

During the physical examination the child became extremely cyanotic when crying or moving about, and when it was quiet the lips, hands and feet were

Fig 1 —The probe in the right ventricle of the heart is inserted into the defect of the interventricular septum

blue There were many coarse rales in the chest posteriorly, especially at the bases of the lungs A loud systolic murmur was heard over the entire precordium and in the left axilla, with a region of maximum intensity in the second and third left rib interspaces near the sternum The borders of the heart were determined with some difficulty, but were apparently within normal limits The liver was palpable about 2 cm below the costal margin

In the hospital the dietary difficulties were overcome The child was much improved, when the exudate from the left ear suddenly increased The infant became dyspneic and more cyanotic and coughed There was a moderate fever râles were heard in the entire chest and the child died three weeks after entering the hospital Clinically the cause of death was bronchopneumonia and congenital heart disease

Postmortem examination was made twenty-two hours after death The body was that of a poorly nourished, white male infant, 67 cm long and weighing 11 pounds (5 Kg) The mucous membranes of the mouth and lips were markedly cyanotic The pleura of both lungs was covered with a viscid purulent exudate, and the pericardium was moderately enlarged Within the pericardium was a small amount of clear yellow fluid, and the lining was unchanged The right auricle was huge, and the moderately enlarged ventricular portion of the heart consisted almost entirely of the left ventricle The diameter of the root of the aorta was 1 5 cm, while that of the pulmonary artery was 0 8 cm When the auricles were opened dorsally the lumen of the right was three or four times as large as that of the left The myocardium of the right auricle had a thickness of 3 mm as compared with a thickness of 1 mm on the left side The patent foramen ovale in the upper portion of the interauricular septum was 0 7 cm in

Fig 2—A pitlike depression in the base of the right auricle marks the site of the obliterated tricuspid valve to the left of the depression are defects of the lower portion of the interauricular septum

diameter In the base of the right auricle was a pitlike depression 1 mm deep, about which was a slight fibrous tissue thickening of the endocardium, but there was no trace of a tricuspid orifice A short distance to the left of the depression was a circular place in the interauricular septum 0 7 cm in diameter, partially closed by a coarsely fenestrated membrane the openings in which varied from 1 to 3 mm in diameter The mitral orifice admitted the tip of one finger The right ventricle was small and was found below the dilated right auricular appendage lying in a plane parallel to the coronary sulcus The lumen, measured from the attachment of the pulmonic leaflets to the apex, was 2 5 cm long, 0 7 cm wide, and 0 3 cm deep The lining was smooth and pale red In the septal wall, 1 5 cm from the attachment of the pulmonic leaflets, there was an opening 0 3 cm in diameter through which a small probe could be passed into the left ventricle

The endocardium at the margin of the opening was slightly thickened with fibrous tissue Above the opening the wall of the right ventricle was smooth, while below the myocardium was coarsely trabeculated There were only two leaflets of the pulmonic semilunar valve, and these leaflets were unchanged The circumference of the pulmonic ring was 1 5 cm Nowhere in the ventricle was there a vestige of the tricuspid orifice or valve leaflets The myocardium of the right ventricle was 2 mm thick The lining of the left ventricle was smooth and light red and there were no changes of the leaflets of the mitral or aortic semilunar valves The orifices of the coronary arteries were widely patent and there was no abnormality of the origin or distribution of these vessels The distance from the mitral ring to the apex of the ventricle was 4 cm and that from the attachment of the leaflets of the aortic semilunar valve to the apex was 4 cm The circumference of the aortic ring was 3 5 cm and that of the mitral ring 5 5 cm The lining of the left and right auricles and auricular appendages was smooth A probe passed into the opening of the septal wall of the right ventricle entered the left ventricle below the aortic ring beneath the commissure between the right and posterior aortic cusps There was therefore a defect in the upper portion of the interventricular septum about 3 mm in diameter The thickness of the myocardium of the left ventricle varied from 0 7 to 1 cm The ductus arteriosus permitted the passage of a fine probe

There was bilateral hypostatic bronchopneumonia, but in none of the other tissues of the chest and abdomen were there any noteworthy changes The important items in the anatomic diagnosis, therefore, were congenital atresia of the tricuspid valve, patent foramen ovale, persistent interauricular and interventricular foramina, hypoplasia of the right ventricle of the heart, marked hypertrophy of the myocardium of the right auricle and left ventricle of the heart bicuspid pulmonic semilunar valve, and acute bilateral bronchopneumonia

The heart described closely resembled those classified by Kuhne as simple or isolated atresias of the tricuspid orifice The characteristic observations in these hearts are a patent foramen ovale, an obliterated tricuspid orifice and a defect of the interventricular septum The blood passes from the right auricle through the defects in the interauricular septum to the left auricle, where it mixes with the aerated blood from the lungs and then continues through the mitral valve into the left ventricle A part of the blood is then forced through the interventricular septal defect into the right ventricle and pulmonary artery while the remainder is emptied into the aorta

COMMENT

The etiology of congenital atresia of the tricuspid valve is related so intimately to the development of the septums of the heart that a brief review of their embryology is in order Monckeberg, basing his discussion of the development of the heart on an extensive study of the literature dealing with this subject, stated that the heart of the human embryo at the end of the third week has three definite divisions the sinus venosus, the atrium and the bulboventricular loop The bilaterally dilated atrium which lies anterior to the sinus venosus, is continuous below with the left ventricular descending limb of the bulboventricular

loop while the right ascending bulbar limb gradually bends medianward and then passes upward anterior to the atrium The lateral outpouchings of the atrium extend anteriorly and partially surround the bulbus arteriosus The heart chambers at this stage of development are unpaired and consist of the lumen of the sinus venosus which opens into the right dilatation of the atrium, and the lumen of the atrium which in turn communicates through the single atrioventricular canal with the chamber of the primitive ventricle of the heart At the end of the third week a vertical fold or septum primum grows downward and forward into the lumen of the atrium from the upper posterior wall The free margin of the fold is concave and encloses an opening, the foramen primum The anterior and posterior prolongations of the septum extend to the middle of the anterior and posterior margins of the ostium of the atrioventricular canal As the septum approaches the atrioventricular orifice, there appear thickenings of the endocardium in the anterior and posterior walls of the canal These endocardial cushions fuse with each other in the midline when the free margin of the interatrial septum touches them, dividing the single atrioventricular channel into the right and left atrioventricular canals The endocardial cushions fuse with the lower margin of the septum, obliterating the interatrial foramen, but before this fusion is complete a defect occurs in the posterior upper portion of the septum primum and gradually extends forward This is the foramen ovale A second sickle-shaped septum or septum secundum, now forms in the anterior wall of the right atrium to the right of the septum primum The ends of the sickle extend posteriorly and converge to form a ring The septum secundum then fuses with the right side of the septum primum, and only that portion of the septum primum seen from the right atrium through the ring in the septum secundum remains uncovered The margins of the opening in the septum secundum are the margins of the fossa ovalis and the uncovered portion of the septum primum is the valve of the foramen ovale The interventricular septum grows from the knee of the bulboventricular loop and extends upward and anteriorly Its free margin is concave, and the anterior prolongation of the septum extends to the lower margin of the bulbus arteriosus while the posterior prolongation extends to the fused endocardial cushions of the atrioventricular canal The foramen thus left between the ventricles is closed relatively late in the embryologic development of the heart by the septum of the bulbus arteriosus and the intermediate septum of His In the second month of fetal life two spiral endocardial ridges arise in the truncus and bulbus arteriosus, which fuse across the midline from above downward, dividing the truncus and bulbus into an aortic and a pulmonic portion This septum grows toward the ventricles with its concave margin directed downward and posteriorly Its anterior process fuses

with the anterior arm of the interventricular septum, while the posterior process extends to the fused endocardial cushions As the septum enlarges, it fuses with the intermediate septum of His, posteriorly closing the interventricular foramen According to His, the intermediate septum originates in the spina vestibuli which is a connective tissue thickening in the lower posterior portion of the right atrium that projects into the atrioventricular canal below the margin of the septum primum and fuses with the endocardial cushions The spina vestibuli fuses with the free margin of the posterior prolongation of the interventricular septum, and finally unites anteriorly with the interbulbar septum At the end of the eighth week, the heart has four separate chambers

Atresia of the tricuspid valve may follow inflammation of the endocardium or may result from a true defect in development Rauchfuss stated that at least five cases of atresia that he found reported in the literature followed fetal endocarditis, for there were definite traces of inflammation Vierordt[8] suggested that endocarditis is more likely to occur in the congenitally deformed than in the normal heart and that in many cases tricuspid atresias thought to be of inflammatory origin are in reality true congenital lesions with a superimposed endocarditis

Three explanations of the cause of congenital tricuspid atresia have been advanced Rauchfuss proposed that an overgrowth and fusion of the endocardial cushions to the right of the interatrial septum produced an obliteration of the valve Since this fusion takes place before the formation of valve leaflets, the usual absence of the vestiges of the tricuspid valve is explained The position of the obliterated tricuspid orifice either cannot be determined or is marked by a slight depression in the base of the right auricle Vierordt suggested that the obliteration of the right atrioventricular orifice resulted from an unequal division of the primitive atrium by a septum deviated too far to the right As the septum fuses with the endocardial cushions, it seals over the right atrioventricular orifice and allows the development of only the left atrioventricular canal This explanation was later supported by Wieland and Monckeberg Kuhne stated that in early fetal life the septum primum is directed toward the right margin of the single atrioventricular orifice but that, as the atrioventricular canal normally shifts from left to right the free margin of the septum finally meets the lips of the orifice squarely in the middle, giving the impulse to fusion of the endocardial cushions This results in two equally large canals When the shift to the right fails to occur or is only partially complete there follows an atresia or stenosis of the tricuspid valve

The defects of the lower portion of the interauricular septum in the instance of tricuspid atresia described in this paper were probably rem-

8 Vierordt H Primare Fehler am Ostium venosum dextrum, in Nothnagel Hermann Specielle Pathologie und Therapie, Viena 1901 vol 15 part 2, p 197

nants of the foramen primum They were found just to the left of the endocardial depression thought to mark the site of the obliterated tricuspid valve Monckeberg believed that this anomaly is caused by an unequal division of the primitive atrium by a septum deviated too far to the right As the lower margin of the septum cannot fuse completely with the endocardial cushions, a persistent foramen primum remains The opening in the upper portion of the interventricular septum may also be a true developmental defect This is suggested by the associated observations of a bicuspid pulmonic semilunar valve and a moderate stenosis of the pulmonary artery Monckeberg found that defects of the membranous portion of the interventricular septum are frequently present in hearts with a bicuspid pulmonic semilunar valve An unequal division of the bulbus arteriosus by the interbulbar septum, with narrowing of the pulmonic channel, may prevent the development of the anlage of one of the pulmonic valve leaflets However as the obliteration of the tricuspid orifice occurs somewhere in the fourth week of embryonic life while the interventricular foramen is not closed until the seventh or eighth week, it is possible that the mechanical force of the blood flowing from the left to the right ventricles has prevented the interbulbar septum from uniting with the interventricular and intermediate septums

The other changes in the heart can also be explained on the basis of the disturbed circulation Thus hypertrophy of the right auricle is due to the increased amount of work necessary to force the blood through the foramen ovale into the left auricle This current of blood from the right to the left auricle also keeps the foramen ovale open The left ventricle hypertrophies because it must supply not only the systemic but the pulmonic circulation, while the right ventricle is merely an atrophic appendage of the left Kuhne believed that a deviation of the interventricular septum to the right corresponding to the right deviation of the interauricular septum explained the extreme aplasia of the right ventricle Huebschmann thought that in the hearts which he described the small right ventricular chamber was a conus pulmonalis rather than a true ventricle

SUMMARY

The postmortem examination of an infant 8½ months of age disclosed congenital atresia of the tricuspid orifice of the heart associated with defects of the interauricular septum hypoplasia of the right ventricle and a subaortic defect of the interventricular septum

The most important symptom of this lesion clinically was cyanosis increased by slight exertion with an associated loud systolic murmur of the heart heard over the entire precordium

The developmental defects of the heart were similar to those which Kuhne and Wieland described as simple tricuspid atresias, of which about thirteen cases have been recorded

THE INFECTION OF RABBITS WITH THE ANTHRAX BACILLUS BY WAY OF THE TRACHEA

STUDIES ON THE DEFENSIVE AND METABOLIC APPARATUS OF THE LUNGS*

B M FRIED, M D
BOSTON

Experiments with the intratracheal injection of vital dyes and oils[1] have shown that these substances are largely disposed of in the lungs by large mononuclear phagocytic cells that are normally present in the pulmonary septums and also alongside the wall of the air sacs If one is to judge from these "infections" with oils and dyes, which ought to be regarded as "model infections," the lungs possess a defensive mechanism of their own which in all probability also takes care of pathogenic micro-organisms that have made their way into these organs from without

The purpose of the experiments to be reported was then, to study the pulmonary reaction in animals infected with a pathogenic organism by way of the trachea

The anthrax bacillus was chosen because the disease caused in rabbits by this micro-organism is characterized by a long incubation period as compared with the rather short subsequent illness Indeed, contrary to what has been taught until recent times, this bacillus disappears almost instantaneously from the circulation even when introduced directly into the blood Apparently, the micro-organism remains "immured" for a certain length of time within the tissues, being released into the blood at the terminal period of the illness In fact, a rabbit infected with this gram-positive micro-organism remains in apparently good health until a short period preceding his death, at which time his blood appears to be flooded with the bacillus

It was accordingly presumed that this protracted "symbiosis" between the cells and the micro-organism might enable one to observe the tissue reaction to the invader accurately and in great detail It also was thought that the observation would be facilitated by the large size of the

Submitted for publication, March 15 1930

*From the Surgical Laboratory of the Peter Bent Brigham Hospital

1 Fried, B M The Origin of the Histiocytes (Macrophages) in the Lungs, Arch Path 3 751 (May) 1927, The Defensive and Metabolic Apparatus of the Lungs The Lungs and the Macrophage System ibid 6 1008 (Dec) 1928

batonet and its tinctorial properties And finally, since this organism is infallibly fatal to laboratory animals, it was believed that the obtained results would not be subject to ambiguous interpretations

MATERIAL AND TECHNIC

The experiments were performed on full grown rabbits

Two highly virulent strains of *Bacillus anthracis,* 168 and 325, secured from the State Laboratory of the City of New York, were used The bacillus was grown on plain agar slants, and a twenty-four hour growth was finely emulsified in physiologic solution of sodium chloride

Since *Bacillus anthracis,* when injected into laboratory animals, even in infinitesimal amount, is infallibly fatal, the experiments were conducted so as to introduce the organism into the pulmonary parenchyma without bringing it into contact with the extrapulmonary tissues This was done in the following way A sterile needle was inserted between the lower rings into the lumen of the exposed trachea A syringe containing the infectious material was then attached to the needle, and the material was slowly injected into the bronchial tree The syringe was then detached and the needle washed out with a newly attached syringe containing a physiologic solution of sodium chloride After withdrawal of the needle the puncture wound was cauterized

EXPERIMENTS

The experiments can be divided into two series (1) a series in which the rabbits receiving the injection of the anthrax bacillus by way of the trachea were left alive for observation, and (2) a series in which the animals were killed at intervals of from five minutes to three weeks after the intratracheal infection The experiments were invariably accompanied by "controls" infected subcutaneously with one half one third or less of the amount used in the intratracheal injections

First Series of Experiments—Twenty-one rabbits were used in this series One cubic centimeter of an emulsion containing from 1,000 000 to 500,000,000 anthrax bacilli was injected into the bronchopulmonary tree of every rabbit in the manner indicated

Three of the twenty-one animals died within two or three days as a result of a faulty technic, the characteristic gelatinous edema was present in the area of inoculation Three rabbits died because insufficient precautions were taken to avoid local contamination they were regarded therefore, as controls The remaining fifteen animals in which the described technic was strictly adhered to survived the heavy intratracheal injections

The following are protocols of two experiments that are characteristic of the whole series

Protocol 22 On Nov 20, 1928, rabbits 125 and 126, weighing each about 2 5 Kg, were inoculated via the trachea with 300,000,000 anthrax bacilli, emulsified in 1 cc of a physiologic solution of sodium chloride The animals were not anesthetized and the customary precautions were taken to avoid local contamination

The animals remained symptom-free, and when killed by an air embolus three weeks later, the examination of their lungs revealed no pathologic changes

Control Rabbit 127 of the same breed, color and weight as rabbits 125 and 126 received subcutaneously about 50,000 bacilli, the animal was found dead in its cage about seventy hours after the infection, with typical anthrax

Protocol 43 Rabbits 151 and 152, weighing each about 2 Kg, received into the lungs by way of the trachea about 500,000,000 anthrax bacilli emulsified in 1 cc of a physiologic solution of sodium chloride When killed eighteen days later, they showed no disease

Control Rabbit 153 that received simultaneously and without any local precautions an intratracheal injection of one twentieth of the amount given to rabbits 151 and 152 died fifty-two hours later with typical anthrax

The experiments showed that manifold fatal doses of the anthrax bacillus can be introduced into the lungs of the rabbit with impunity when the micro-organism is brought directly in contact with the pulmonary tissue

That the lungs represent an unfavorable pathway for infection with pathogenic micro-organisms of other kinds has been demonstrated on many occasions In animals infected by way of the trachea septicemia has failed to develop in most instances, and no local lesions have been disclosed

Of particular interest are the experiments with the production of pneumonia in animals *Pneumococcus pneumoniae* is regarded as being the organism par excellence for the infection of the lungs, yet no observer has ever been able to produce pneumonia in the rabbit, the guinea-pig or even the mouse in instances in which the trachea was chosen as a vehicle for the coccus

The harmlessness of the anthrax bacillus to small laboratory animals when the germ is introduced into the lung in the manner described has been stressed recently by Besredka,[2] who produced evidences to show that in the guinea-pig and in the rabbit the skin is the single organ that is susceptible to infection with *Bacillus anthracis*

From the experiments here reported it will be seen that the bacillus is innocuous in the rabbit when introduced by way of the uninjured respiratory tract

The mechanism of the pulmonary resistance will be analyzed in the section to follow

Second Series of Experiments—In the second series of experiments, the animals were killed by an air embolus at forty-one different intervals after the intratracheal infection the intervals ranging from three minutes to thirty days These experiments, too, were accompanied by "controls" infected subcutaneously with one twenty-fifth or one fiftieth of the amount used in the intratracheal injections The freshly removed lungs

2 Besredka, A Vaccination par voie cutanee Charbon Cuti-infection, cuti-vaccination, cuti-immunite Ann de l'Inst Pasteur **35** 421 1921

were fixed in a solution of formaldehyde and in Zenker's fluid The staining method recently described by Lillie[3] for gram-positive bacilli furnished results comparable with those of the customary Gram-Weigert stain

A resume of the histologic changes found in the lungs follows

When the lungs were examined under the microscope about five minutes after the infection took place, the micro-organism was found singly or in small groups



Fig 1—Proliferation of cells of the pulmonary septums and phagocytosis of anthrax bacilli by these cells, Gram-Weigert stain, × 600 The animal was killed about forty-five minutes after the intratracheal infection

or as long whiplike filaments lying in the lumen of the alveoli adjacent to the septums The bacillus was perfectly stained showing no apparent morphologic changes The blood vessels showed no congestion, and no migration of cellular elements from the blood could be noticed However, already at this period the pulmonary tissue was striking in that it showed marked swelling of the cells lining the alveolar wall and of those present in the septums These cells were

3 Lillie, R D The Gram Stain A Quick Method for Staining Gram-Positive Organisms in the Tissues Arch Path 5 828 (May) 1928

each the size of a large lymphocyte and had each an oval or bean-shaped eccentric nucleus with a cytoplasm that showed large and small vacuoles A large number of these cells lay free in the alveolar lumen and contained one or many agglutinated bacilli In many places, the gram-positive micro-organism was outside of but intimately close to the cell, apparently the cell had not yet succeeded in "engulfing" it (fig 1)

In the following minutes, that is ten, fifteen, twenty and up to about one hour, the cellular reaction was found to be increasing in intensity, as evidenced by multiplication and by swelling of the cells lining the septums, a great number



Fig 2—Proliferation of the cells of the pulmonary septums and phagocytosis of anthrax bacilli, which are agglutinated and fragmented In some cells, the bacillus is seen as minute black (gram-positive) "dots", Gram-Weigert stain × 600 The animal was killed about two hours after the intratracheal infection

of which, having separated from the wall, had migrated into the air sacs The phagocytosis of the bacillus by these cells had largely increased, and the micro-organism itself showed swelling with hazy outlines, and often "crumbling" into small particles The whiplike threads noted in the first few minutes had disappeared (fig 2)

The "exudate" was moderate and there was no striking outpouring of cells The bacilli apparently did not multiply in the lung On the contrary, with every added ten or fifteen minute interval, they appeared to be scantier, and those still

present showed disfiguration and fragmentation After periods of two or three hours, the elongated, "slim" anthrax bacillus could be seen mostly as intracellular minute "dots" stained with the Gram stain Within the next two or three hours, even these remnants of the pathogenic organism had entirely disappeared (fig 3) The cellular exudate by this time had largely disappeared, but the cells alongside the wall of the air sac were still swollen with large hyperchromatic nuclei and the entire lung appeared under the microscope to show a marked increase in "nuclei"



Fig 3—Lung of a rabbit infected with the anthrax bacillus via the trachea Gram-Weigert stain, × 600 The animal was killed about seven hours after the infection took place The bacillus has entirely disappeared from the lung Bacillary remnants, seen as gram-positive "dots," can still be found in the cytoplasm of the free ameboid macrophages The cellular exudate is insignificant, but the cells alongside the septums are still "swollen," and are increased in number

The anthrax bacillus had thus disappeared from the lung within a period of from six to eight hours, and the pulmonary tissue at this period showed no particular changes

The lymph nodes showed no changes The blood from every killed animal was cultivated invariably with negative results The liver, the spleen and the bone-marrow showed no histologic change and no gram-positive bacilli These viscera were not cultivated or inoculated into animals for the purpose of detecting the possible presence of the anthrax bacillus

INTERPRETATION OF EXPERIMENTS

It may be seen that (1) a micro-organism of even such high pathogenicity as the anthrax bacillus causes no disease in the animal when introduced directly into the lungs, and (2) the micro-organism is destroyed in the lungs with great rapidity by local cellular elements found within the septums and alongside the wall of the air sacs From this study it also appears that the reaction of the lung to a virtual infection with a highly pathogenic bacillus resembles closely that of the "model infection" with dyes and oils described in previous reports [1]

Following my earlier studies,[1] the defensive apparatus of the lung has been the object of new investigations by numerous workers The discussion has centered around (1) the lining of the air sacs that is, whether it represents a continuous or a discontinuous layer of cells, (2) the rôle of the cells "lining" the alveolar wall in inflammatory and congestive processes of the lung, and (3) the nature of these cells, i e, whether they are endodermal or mesodermal

These questions, which have been discussed at length in previous publications,[1] will be briefly considered here

With regard to the lining of the air sacs, there is at the present time a prevalence of opinion that the walls of the alveoli are lined, not by a syncytial row of cells, but by scattered groups of cells, which are conspicuous at the bifurcation of the capillaries, similar to the Kupffer cells in the liver The alveolar wall is therefore virtually "naked"

It is interesting that the fact of the "nakedness" of the air sacs was apparently known to some older observers Thus in studying the absorbing power of the mucous membrane of different organs Claude Bernard [4] found that toxins and poisons are absorbed by way of the alveolar surface as rapidly as by way of the blood stream He noticed that curare placed on the mucosa of the bronchi caused no harm to the animal, but that when this alkaloid was "pushed" into the alveoli it killed the animal as rapidly as if it had been injected into the circulation Claude Bernard attributed this phenomenon to the "absence d'un epithelium protecteur à la surface des vesicules pulmonaires' In a recent investigation, the French pathologist, Policard,[5] stated "The respiratory surface of the lung ought to be compared to an open wound (à une plaie vive)" This is of importance in that the pulmonary respiration is not performed through the intermediary of the "respiratory epithelium," as has been thought by physiologists, but the alveolar air apparently comes in direct contact with the mesenchyme

4 Bernard, Claude Leçons sur les effets des substances toxiques et medicamenteuses, Paris, Bailliere, Tindall & Cox, 1857

5 Policard A Les nouvelles idees sur la disposition de la surface respiratoire Presse med **37** 1243 (Oct 5) 1929

Likewise, the notion that the "readily available" alveolar phagocytes are not imported but are locally produced has come to be accepted by Aschoff (Seeman[6]) by Gardner and Smith[7] and by Policard[5] Whereas however Gardner and Smith have traced the origin of the pulmonary phagocyte to the connective tissue of the septums, entirely disregarding the activity of the "alveolar epithelium," the other authors mentioned are in complete accord with me that the "alveolar epithelium" is par excellence the progenitor of the free alveolar ameboid macrophage

There remains to be considered the nature of the "alveolar epithelium"

Seeman[6] in a series of recent observations inspired by Aschoff, found as I did that in pathologic circumstances the 'alveolar epithelium' proliferates with an amazing promptness, that it separates from the alveolar wall forming the intra-alveolar exudate, that both the fixed ('lining" the septum) and the sessile cells (exudate) are phagocytic par excellence He maintained nevertheless that the bronchiolar and the alveolar cells are endodermal because they display similar appearances when impregnated with silver nitrate He did not discuss the striking differences between the 'sedentary' bronchiolar cell and its "restless' wandering polymorphic neighbor the alveolar wall cell, except the phagocytosis Concerning this matter he said

The outstanding phagocytic activity of the alveolar epithelium' should not surprise us if we remember that occasionally the liver, kidney, adrenal and testicular cells are strongly phagocytic '

Those familiar with Aschoff's contributions to the problem of the reticulo-endothelial system will remember that this opinion expressed by Seeman is but a part of a statement previously made by his teacher Aschoff In quoting Ribbert and Rossle to the effect that the hepatic and renal epithelial cells are phagocytic Aschoff[8] added however

Das gelegentlich alle moglichen Zellen grobere Fremdkorper in sich aufnehmen, das heist als Makrophagen erscheinen konnen ist bekannt Es gibt kaum eine fixe Zelle der tierschen Organismus welche nicht imstande ware unter Umstanden andere Zellen Fremdkorper Parasiten, in sich aufzunehmen und zu verdauen Sind sie deswegen funktionell gleichwertig? Nicht in geringsten Es handelt sich hier nur um eine allen Zellen zukommende Teilfunktion, die der

6 Seeman, G Ueber den feineren Bau der Lungenalveole, Beitr z path Anat u z allg Path **81** 508 1928-1929

7 Gardner L U, and Smith D T The Origin of Alveolar Phagocytes Studied in Paraffin Sections of Tissue Stained Supravitally with Neutral Red, Am J Path **3** 445, 1927

8 Aschoff, L Das reticulo-endothelale System, in Schittenhelm, A Handbuch der Krankheiten des Blutes und der blutbildendes Organe, Berlin, Julius Springer 1925 vol 2 p 473

Verdauung Also muss man nach anderen Merkmalen suchen Die Phagocytose ist nur eine bei den uns hier beschaftigenden Zellen (reticulo-endothelial) ganz *besonders stark* ausgespragte Eigenschaft Die Intensitat, die Haufigkeit der Phagocytose ist hier das entscheidende

(It is known that occasionally every possible cell will "swallow" coarse foreign elements, i e, it will act as a macrophage There is hardly a fixed cell in the animal organism that is not in a position under certain circumstances to swallow and to digest other cells, foreign bodies and parasites Are they, thereby, functionally identical? Not to the slightest degree There is concerned here one of the functions proper to every cell, that is, of digestion One must therefore also look for other characteristics In the cells with which we are concerned (the reticulo-endothelial) phagocytosis is only one property which is *particularly marked* The intensity and the amount of phagocytosis are here the deciding factors)

This conception of phagocytosis, expressed for the first time by Metchnikoff, is at the present time the one accepted by all observers (see also Lubarsch [9]) It is true that the hepatic cell, the renal cell and other fixed cells "engulf" erythrocytes and other foreign elements However, when stimulated by these substances, these cells do not undergo morphologic changes, and do not proliferate, they do not separate from their customary seat to continue in "the space" their phagocytic activities, they do not take part in the formation of the tubercle (epithelioid cells) in tuberculosis, and do not form giant cells In brief their phagocytic properties are only casual and passive, whereas that of the "alveolar epithelium" closely approaches that of the Kupffer cells and that of the cells lining the sinuses of the spleen and the bone marrow They also apparently take part in the extrahepatic formation of bile

It is interesting that Seeman, too, although regarding the alveolar cells as epithelial, nevertheless accepted their rôle as essentially defensive Thus, he wrote [6]

Es liegt daher der Gedanke nahe, den Ausdruck "respiratorisches Epithel uberhaupt fallen zu lassen und die A-E nur als besonders differenzierte Abwehrelemente zur Beseitigung exogener und endogener Schadigungsfaktoren zu charakterisieren

(It would be more appropriate to abandon altogether the expression "respiratory epithelium" and to characterize the alveolar epithelium (A E) only as elements of defense especially differentiated for the purpose of eliminating exogenous and endogenous noxious agents)

The interest of this new conception of the pulmonary structure is evident in connection with the respiratory function of the lungs spoken of in the early part of this paper It also plausibly explains the impossibility of experimentally inducing a generalized or a pulmonary disease by pathogenic micro-organisms introduced into the normal lung by way

9 Lubarsch, O Ueber Phagocytose und Phagocyten Klin Wchnschr 4 1248 1925

of the trachea No one has been able to produce pneumonia in this way in a normal animal Only by altering the sensitiveness of the animal has it been possible to cause in the laboratory animal a specific local disease or to overpower the pulmonary barrier, producing septicemia Thus, when Besredka [10] injected into the lung of the rabbit by way of the trachea "one half a culture on agar" of the paratyphoid bacillus it was well tolerated by the animal But when the bacterial infection was preceded by the injection into the rabbit's lung of 0 5 cc of a 5 per cent solution of bile "one hundredth of the paratyphoid culture" killed the animal Bile in the insignificant amount and the weak solution that was used twenty-four hours prior to the bacterial injection causes no changes in the lungs, as revealed under the microscope The bile in all probability merely alters the normal sensitiveness of the pulmonary "defensive apparatus Parker and Pappenheimer [11] too, by infecting guinea-pigs by way of trachea with the pneumococcus, found pulmonary lesions that were mild and transitory But by "altering the reaction of the guinea-pig," they were able to produce a pneumonic process in this animal Likewise, Stillman [12] in inhalation experiments, obtained positive results in the mouse only after the rodent had been previously intoxicated with alcohol

It is most remarkable that the exquisitely thin and "naked" alveolar wall, which is highly permeable to fluids, is, as a rule, impassable to finely emulsified bacteria, which are, moreover, destroyed in the air spaces Apparently analogous to the liver and the spleen, the lungs also play a rôle in the defense of the organism, as was indeed demonstrated in the experiments herein reported As elsewhere in the body, the defensive mechanism of the lungs lies in the pulmonary mesenchyme, of which the cells "lining" the alveoli are an essential part

SUMMARY

The intratracheal introduction of anthrax bacilli causes no disease in rabbits, provided the extrapulmonary tissues are spared contamination

The micro-organisms so inoculated are retained by the lungs and are destroyed within a few hours after the infection

The destruction of the highly pathogenic bacilli is performed by macrophages by way of phagocytosis

---

10 Besredka A Infection et vaccination par voie tracheale, Ann de l'Inst Pasteur **34** 361, 1920

11 Parker Julia, and Pappenheimer, A M Experimental Pneumonia in Guinea-Pigs, J Exper Med **48** 695, 1928

12 Stillman E G Persistence of Inspired Bacteria in the Lungs of Alcoholized Mice J Exper Med **40** 353, 1924

The cells found in groups alongside the wall of the air sacs (so-called "alveolar epithelium") play the outstanding rôle in the phagocytosis of the anthrax bacilli

The experiments have likewise shown that the pulmonary reaction to this "virtual" infection is akin to the "model infections" with vital dyes and oils reported in earlier studies [1]

This work was made possible through the assistance of Professor Harvey Cushing The experiments were conducted in the laboratory of Professor Hans Zinsser

A COMPARISON OF AUTOTRANSPLANTATION, HOMOIOTRANSPLANTATION AND HETEROTRANSPLANTATION OF BLOOD CLOTS*

LEO LOEB
ST LOUIS

In a preceding paper, I analyzed the reactions of the guinea-pig host against autotransplantation and homoiotransplantation of blood clots[1] I observed that the characteristic differences that are found between the reactions of the host against autotransplanted and homoiotransplanted tissues, if living material is used for the transplantations are lacking or almost lacking in the case of the corresponding transplants of blood clots, and I concluded, therefore, that living, metabolizing tissue is necessary if one is to obtain typical homoioreactions In a few preliminary experiments, on the other hand, I found some indications that typical heteroreactions take place also after transplantation of blood coagula, provided that the latter are transplanted into animals of a different species, and I suggested, therefore that heterotoxins may be given off even by nonmetabolizing, dead tissues In the present investigations, I wished to test the correctness of the conclusions at which I arrived previously In the first place I repeated the homoiotransplantations of blood clots in the guinea-pig and then compared with these various kinds of heterotransplantation of blood coagula in the guinea-pig as well as in the rat

AUTOTRANSPLANTATION AND HOMOIOTRANSPLANTATION OF BLOOD CLOTS IN THE GUINEA-PIG

In general, in case of homoiotransplantation of blood clots the reaction on the part of the surrounding host tissue toward the clot is relatively slight and simple The host reacts essentially with the mobilization of fibroblasts which soon surround the clot in a thin layer and toward the periphery of the layer form fibrillar connective tissue in this way producing a capsule At the inner aspect of the latter the fibroblasts remain active and penetrate in various directions into the clot, either turning toward and into it at right angles or forming a network of cells in the clot In this way they may penetrate deeply into it

* Submitted for publication March 13 1930

From the Department of Pathology Washington University School of Medicine

1 Loeb, Leo J M Research **37** 353 1918 Biol Bull **40** 143 1921

The unfavorable conditions of nourishment and of oxygen supply that obtain within the clot cause many of these cells to perish here Their protoplasm becomes admixed with the coagulum, and thus a mixture of clot and fibroplasm replaces the pure blood clot It is this mixture that is gradually organized by newly ingrowing connective tissue cells The red-staining clot material, to which, as stated, in places fibroplasm is admixed, may reach directly to the connective tissue capsule, to which it is adherent During the process of organization, changes take place in the coagulum under the influence of the invading host cells, which are arranged here often in the form of parallel and concentric rows In the course of this provisional organization, the clot may thus be transformed into a homogeneous mass, which then sometimes disintegrates into granular material from which the hemoglobin is washed out As far as I can make out, the latter changes take place, at least in part, within the invading host cells, which have acted as phagocytes toward this material, and subsequently, when these cells dissolve, a hyaline material remains At a still later phase of organization, when the invading fibroblasts become more numerous, the material between the cells becomes in part dissolved, and thus vacuolar structures develop between the fibroblasts, fibrils are produced and connective tissue is formed However, in this organized material, replacing parts of the former clot some remnants of the coagulum or rather of the coagulum-fibroplasm mixture may still be found in the form of thick fibers staining red with eosin Such red often wavy fibers sometimes envelop a great part of the periphery of the clot, demarcating it from the surrounding connective tissue capsule Presumably, therefore, these red fibers represent clot material transformed into fibers under the influence of the fibroblasts In addition, there are other coarse, red-staining fibers in the connective tissue capsule which owe their origin to changes that take place in the muscle tissue on which the transplanted clot has been placed Here degenerations occur and the growing and mobile fibroblastic cells may carry necrotic and sometimes also regenerating muscle fibers, with their characteristic chains of nuclei, away from the muscle into the fibroblastic-fibrillar connective tissue and toward the margin of, or sometimes even into the clot

In the early stages of the invasion of the clot by fibroblasts, accompanied perhaps by monocytes, part of the coagulum may take on a bluish stain with hematoxylin, probably owing to the disintegration of nuclear material of the invading cells Later, from about the seventh day on central parts of the clot sometimes become converted into hard clumps of a hyaline reddish or greenish material, around which cells of the host tissue form foreign body giant and epithelioid cells Near by some fibro-

blasts enlarge, and a fibrillar capsule develops around and between some of these clumps, and together with blood pigment and a few lymphocytes, which are found in the surrounding tissue they may at a relatively late date, from about fifteen to eighteen days after transplantation, represent the last remnants of the clot, occasionally, however, there may still be seen at that time some remaining parts of typical coagulum in process of organization Within the giant cells can be observed particles of the hyaline hard material or of blood pigment which they have taken up, also within the epithelioid cells and large fibroblasts, such granules may be found Blood vessels develop in the surrounding tissue and grow toward the remnants of the clot or toward these hyaline clumps At earlier stages of the organization, branching blood vessels, likewise, may grow into the clot Rupture of these blood capillaries in certain places may occasionally give rise to hemorrhages in the periphery of the clot, and it is possible that the looser blood coagulum, which is found here and there surrounding the denser red-staining central parts of the coagulum, may owe its origin to such hemorrhages

Lymphocytes, on the whole, are insignificant in this process Small collections of these cells may now and then be found around vessels in the connective tissue capsule, or occasionally they accompany the fibroblasts during the process of organization of the coagulum On the whole they are an inconstant constituent of the organizing host connective tissue Likewise phagocytosis, although it may occur after homoiotransplantation of blood clot, is, on the whole, not a prominent feature, and I have not observed phagocytes producing a tissue-like formation here, as they do in the case of heterotransplantation Also, collections of polymorphonuclear leukocytes, while they are seen occasionally in or around the clot, are rare, and their presence is probably a sign of an accidental local infection of the blood coagulum Small accumulations of leukocytes, whenever they occur, do not, as a rule, alter the reaction of the host tissue to the transplanted clot, except that near the area of infection the number of lymphocytes may possibly be somewhat greater than elsewhere Such are the main features of the reactions of the guinea-pig toward homoiotransplanted blood clots On the whole, these reactions are indications of a simple organization of the clot mainly by fibroblasts, and the development of a relatively thin capsule of fibrillar connective tissue around the coagulum

HETEROTRANSPLANTATION OF BLOOD CLOTS

I shall now compare with the fate of blood clots after the homoiotransplantation of blood clot that after heterotransplantation For this purpose, I used clots obtained from the blood of chicken, rabbit and

guinea-pig, and transplanted the coagula into guinea-pigs and rats The blood was obtained in each case, under aseptic precautions, either from a vein or from the heart of the animals, by means of a syringe, and poured into a petri dish, where it was allowed to clot It was then kept for from one to two days on ice, after which period pieces were cut out from the coagulum and transplanted into the subcutaneous tissue of guinea-pigs and rats, likewise under aseptic precautions At various periods of time, what remained of the blood clot, together with the surrounding tissue, was removed for microscopic examination, it was embedded in paraffin and sectioned The technic used in these experiments was therefore in all essential respects the same as that used previously in the case of homoiotransplantation of blood clots in the guinea-pig

Observations on Transplantation of Chicken Blood Clot into Guinea-Pig and Rat—In this series, thirty-four transplanted pieces were recovered and examined I shall limit myself to a description of the observations at certain selected periods following transplantation

After Three Days After three days, a fibrous capsule, which is thin in the rat and, in places, thicker in the guinea-pig, surrounds the clot In both guinea-pig and rat, large mononuclear cells appear around the dense central nucleated coagulum, they act as phagocytes and take up the nucleated erythrocytes They also penetrate into the coagulum In the guinea-pig there are noticeable peripheral areas, in which hemolysis has taken place and only fibers remain, also in the rat there may be in the periphery a network of fibrin, and elsewhere the hemoglobin of peripheral erythrocytes has in part been dissolved, so that only nuclei are left However, in other places well preserved erythrocytes with hemoglobin are still seen, and while such cells may also be taken up by phagocytes, it is especially the nucleated hemolyzed corpuscles which are being phagocytosed Not only the phagocytic cells, but also some fibroblasts and polymorphonuclear leukocytes penetrate into the clot, and around the vessels outside the connective tissue capsule there may be collections of lymphocytes and some polymorphonuclear leukocytes Especially in the guinea-pig, one finds the latter kind of cells even within the connective tissue capsule

After Seven and Eight Days In the period between seven and eight days following transplantation of chicken blood clots into the rat and guinea-pig, one finds, on the whole, similar conditions in both species One can distinguish four zones in the transplants and in the surrounding host tissue In the center is a dense nucleated clot It is surrounded, at least in places, by coagulum showing an early stage of hemolysis, the nuclei are here dissolved Around this area one finds a zone in which more marked processes of solution have taken place, there are fibrin

fibers or remnants of large phagocytes that had taken up erythrocytes and thus contributed to the disintegration and solution of the clot Fibroblasts are moving into this zone, especially along the fibers There may be here also some polymorphonuclear leukocytes and lymphocytes or macrophages Surrounding this zone is the connective tissue capsule formed by the host It is more cellular and richer in fibroblasts and capillaries in the inner part, while it is more fibrillar in the outer layer, between the connective tissue fibers of this capsule, there may be seen some fibrin bands as remnants of the clot, which otherwise has been organized In some places, collections of phagocytes containing red corpuscles are found within the capsule It may then be assumed that a considerable part of the original blood clot has been replaced by connective tissue

The observations on these specimens differ from those in autotransplanted and homoiotransplanted clots, in that in the heterotranplants there is much more infiltration of the connective tissue with lymphocytes, either single ones or groups of them, also polymorphonuclear leukocytes may be here in varying numbers In places, the connective tissue surrounding the transplant has the appearance of a small cell granulation tissue growing into the clot, and where the solid clot reaches directly to the connective tissue capsule, such tissue may penetrate into it In other places, fibroblasts enter and spread into the coagulum, contributing to its organization, but especially characteristic are collections of mononuclear phagocytes which surround the dense clot and even invade it These cells take up particles of coagulum and thus help to dissolve and destroy it In the periphery, such phagocytes may be so numerous and may be arranged in such a regular fashion that a tissue-like formation results, it is, perhaps through secondary disintegration of these cells that in some cases, the peripheral cavities form, to which I referred

In other cases the hyperemic zone and the accumulations of lymphocytes may be less conspicuous or lacking altogether, and one sees merely phagocytes surrounded by a layer of fibroblastic fibrillar connective tissue concentrically arranged around the remnants of the clot into which numerous fibroblasts may grow in a radial direction Occasionally seen in the capsule are some peripheral hemorrhages, apparently due to rupture of capillaries of the host In some cases cavities are found in the central clot, caused by the activity of large numbers of polymorphonuclear leukocytes It is possible that, in such cases there is localized bacterial infection in the coagulum, in some peripheral areas it is not always certain what part is played in the processes of solution by the hemolysins developing or performed in the host, by phagocytes or by polymorphonuclear leukocytes, the latter possibly have been attracted by some bacteria contaminating the transplanted blood clot Whatever

the mechanism responsible for them, these differences between the homoiotransplanted and heteiotransplanted clot, are present notwithstanding the fact that the same technic has been used in transplanting both types of clot and one is therefore justified in attributing the essential differences, not to accidental bacterial contamination but to the difference in the reaction of the host to the different types of blood clots

After Ten and Eleven Days After ten and eleven days one finds in the rat conditions similar to those seen in earlier specimens There is a central clot surrounded by phagocytic cells, which are filled with nuclei of erythrocytes The clot may reach to the peripheral connective tissue capsule, or it may be surrounded by a zone in which the coagulum has been partly or entirely dissolved and in which there is now seen a net of fibrin fibers, with many phagocytic cells, fibroblasts, some polymorphonuclear leukocytes and lymphocytes In other places, one finds merely coagulated plasma without cells In the peripheral capsule the fibroblasts are usually arranged concentrically, while the capillaries run vertically to the clot, also cells containing blood pigment may be found in this capsule, which is thick and contains masses of lymphocytes and some polymorphonuclear leukocytes The lymphocytes seem to be especially numerous adjacent to areas in which the processes of solution have taken place As after seven and eight days, one may find, at this period mitotic proliferation in the fibroblasts surrounding the remaining parts of the coagulum The organization of the clot has made further progress, the blood vessels are penetrating into it and the lightstaining dissolved, as well as the solid, zone is being invaded and replaced by fibroblasts The phagocytes and in places also the polymorphonuclear leukocytes are helping in this work, being actively engaged in the destruction of the coagulum

In the guinea-pig, the phagocytes are prominent at this period, they may surround, in tissue-like arrangement, the clot and also fill cavities, the result of solution in the coagulum, fibers of fibrin may be visible in such areas of solution With the fibroblasts, in certain places, lymphocytes and polymorphonuclear leukocytes enter the coagulum These cells also may be taken up and digested by phagocytes although the latter usually are filled with nuclei of erythrocytes The connective tissue capsule as a rule is usually very cellular, especially in the area adjoining the coagulum The peripheral dissolved areas seem to have been organized, at least in part At the same time, the development of fibrillar connective tissue proceeds in the capsule and also in the adjoining muscle tissue, in the latter, leukocytes and lymphocytes may collect and produce injury

After from Twelve to Fourteen Days After from twelve to fourteen days, the phagocytic cells are still prominent around as well as inside the

guinea-pig clot and, in places, they may form xanthoma-like tissues The phagocytosed red corpuscles gradually become dissolved and thus only vacuoles remain in the cell bodies of the phagocytic cells In certain specimens, polymorphonuclear leukocytes are pronounced and contribute to the processes of solution in the clot There is always reason for suspecting the presence of bacteria wherever these leukocytes are numerous, especially when they occur in fissures separating parts of the clot In a few cases, I have actually seen some bacterial colonies in such places, but these were exceptional

In general, in the guinea-pig as compared with the rat, solution is more prominent, and the number of polymorphonuclear leukocytes in the clot is greater, as is also usually the number of lymphocytes which collect in the surrounding connective tissue capsule One has to consider in this connection the possibility that, in the guinea-pig, bacterial contamination may have been more frequent than in the rat The areas of solution seem to decrease in size in the later periods, they have, by this time, probably been organized to a greater or lesser extent

Observations on Transplantation of Rabbit Blood Clot into Guinea-Pig and Rat—In this series, altogether forty-three transplants were recovered and examined microscopically at periods ranging between four and sixteen days following transplantation

After Four and Five Days After four and five days mainly connective tissue, with numerous fibroblasts, and a more outer fibrillar zone surround the clot, while fibroblasts and, perhaps, other mononuclear cells invade it, at first, they perish here and subsequently cause a definite organization of the clot Blood vessels are prominent in certain cases Polymorphonuclear leukocytes, lymphocytes and larger mononuclear cells other than fibroblasts are variable in number, they may be either numerous or on the other hand, almost lacking In some specimens processes of solution have taken place in the peripheral parts of the coagulum and a network of fibrin fibers alone remains, with polymorphonuclear leukocytes, lymphocytes and fibroblasts invading this area In such cases one may find, also, in the surrounding connective tissue capsule, a larger number of lymphocytes and some polymorphonuclear leukocytes It is possible that when larger numbers of leukocytes are present, bacterial contamination has taken place, although clumps of bacteria could not be seen in my specimens In the majority of pieces, phagocytes are absent or at least are not prominent at this period, but in some cases they can be seen in larger numbers in the rat, either around a central part of the clot or in the more peripheral areas and they take up red corpuscles A part of the coagulum has already been replaced by connective tissue at this time Again one notices two phases in the organization namely the phase of provisional organization, in which the

invading cells are destroyed, and a mixture of fibroplasm and coagulum, which paves the way for the second phase of permanent organization

After Seven, Eight and Nine Days After seven, eight and nine days, changes observed are not unlike those found after transplantation of chicken clot Certain features characteristic of heterotransplantation are added to reactions that are similar to those observed after homoiotransplantation As in the case of homoiotransplantation, one finds a connective tissue capsule surrounding the coagulum The inner layer of the capsule is richer in fibroblasts which turn toward the clot, while the outer layer is more fibrillar, the fibrillae being, on the whole, arranged concentrically, in contrast with the capillaries, which often run vertically toward the coagulum Between the fibrils of connective tissue, one may find remnants of the coagulum, in the form either of fibrin fibers, staining red with eosin, or of irregular pieces of clot, which are surrounded by connective tissue, occasionally, the clot remnant has changed into a hyaline material lying between the fibrils of connective tissue More and more, these remnants of the coagulum are invaded by connective tissue and are thus organized In other places, one may find blood pigment cells lying in the connective tissue capsule and sometimes extending into the surrounding fat tissue

One may conclude that the peripheral part of the coagulum has been organized and that it has been partly replaced by the connective tissue capsule In addition to these fibrin fibers, one may again find remnants of necrotic muscle tissue or sometimes even regenerating muscle fibers carried into the connective tissue capsule by the fibroblasts developing in the surrounding muscle The fibroblasts are actively proliferating by mitosis The capsule differs from that found after homoiotransplantation in that it is often thicker, more infiltrated with small cells, especially lymphocytes, and with some polymorphonuclear leukocytes In some cases, the capsule resembles granulation tissue From this extreme, one notices all transitions to structures that one sees around homoiotransplants of blood clot There occur, therefore, variations in different places within the same specimen, as well as in specimens obtained from different animals The fibroblasts enter the coagulum and may split off parts of it and gradually organize it, lymphocytes and also some polymorphonuclear leukocytes accompany the fibroblasts in certain places Again there may be found processes of solution in the periphery of the coagulum, in some places, erythrocytes may swell, later solution occurs, leading to the formation of cavities which are traversed by fibrin bands Some lymphocytes, polymorphonuclear leukocytes and also fibroblasts, the latter often moving along the fibrin fibers, are seen in these cavities In addition, there are frequently noticed polygonal, finely or more coarsely vacuolated cells with a sharply demarcated cell membrane, evidently phagocytic elements, in appearance not unlike xanthoma cells

Similar cells occasionally may be seen also within the coagulum Such phagocytes sometimes contain remnants of cellular material which they have taken up The presence of these phagocytic cells, the greater number of lymphocytes and also of polymorphonuclear cells and, above all, the solution cavities found in the periphery of the clot, differentiate these heterotransplanted from homoiotransplanted coagula In some places, the polymorphonuclear cells may be present in larger numbers in the clot and then perish Also other cellular elements that have entered the clot are destroyed in the dense coagulum and, by means of this provisional organization, help to prepare the way for the later definite organization Again in these experiments, it is difficult to determine how far bacterial contamination may be responsible for the greater number of polymorphonuclear leukocytes which one generally finds in such heterogenic coagula Only in exceptional cases were bacteria actually seen, yet it is probable that also in other cases dense collections of leukocytes are caused by the presence of micro-organisms In some cases, these cells may possibly also be partly responsible for the formation of the peripheral cavities, but in other areas, it seems that phagocytes help to produce them The essential factor is, however, in all probability, the hemolytic effect of the foreign serum As stated previously, such cavities are not usually seen after autotransplantation and homoiotransplantation of coagulum, although in the latter type of transplantation in my experiments the same technic was used as in the case of heterotransplantation Except for the fact that, after nine days, the greatest part of the coagulum may have been already organized in the rat, one finds no essential difference between the reactions toward the clot in the latter animal and in the guinea-pig

After from Ten to Sixteen Days After from ten to sixteen days, the changes are essentially the same as in the preceding period, except that the organization of the coagulum has progressed still further Fibroblasts move into the coagulum and follow especially the direction of the fibrin fibers Again the most advanced cells frequently perish, during this process, the nuclei may still remain visible when the cytoplasm has already admixed to the coagulum With the fibroblasts, lymphocytes often invade the coagulum, the latter are especially numerous around the blood vessels in the frequently thick and densely infiltrated capsule which usually surrounds the coagulum in a concentric direction The fibroblasts here may show mitoses As in the preceding period one may find, between the connective tissue structures of the capsule remnants of the clot in the form of red-staining fibrin fibers or of hyaline material which later becomes transformed into fibrillar connective tissue through the action of fibroblasts Prominent at this time are the large mononuclear phagocytic cells, which also may penetrate

into the coagulum and take up red corpuscles or particles of coagulum and occasionally also some leukocytes After this material has been digested, finally or coarsely vacuolar large cells, forming a xanthoma-like tissue, may remain around the coagulum, which thus in the course of time, becomes very small These cells in some cases replace a considerable portion of the coagulum, and they may extend even into the surrounding connective tissue Only occasionally can giant cells be seen around remnants of the coagulum, which have become hard Blood pigment cells are found in the capsule, and they wander also into the surrounding fat tissue Furthermore, some cavities, through which strands of fibers run, are seen between the remaining parts of the coagulum and the connective tissue capsule The number of polymorphonuclear leukocytes varies in different cases, they may be rare or numerous, and it is possible that some cavities owe their origin to these leukocytes In other cases, the presence of the xanthoma-like tissue near such cavities suggests that phagocytic cells may possibly have had something to do with the formation of the cavities

Observations on Transplantation of Guinea-Pig Blood Clot into Rat —In this series, pieces were examined within a period ranging from seven to twelve days In principle, one finds here the same conditions as in the case of the other heterotransplantations of blood clots I shall note merely the principal observations

After Eight Days After eight days, one finds a connective tissue capsule around the greater part of the remaining coagulum, its thickness varies in different places On the whole, the tissue is very cellular, and its fibrillar character is therefore less prominent at this period Many lymphocytes are seen, especially near the clot and many large mononuclear cells are around the latter There are visible various intermediary stages in the transformation of the blood clot into connective tissue, and between the connective tissue cells surrounding the clot, I find red-staining fibers that represent remnants of coagulum or mixtures of coagulum and the protoplasm of degenerated fibroblasts Such red-staining fibers may envelop the coagulum and somewhat further toward the periphery a net of fibers appears, between which rounded off fibroblasts or monocytes are enclosed There are also areas that represent a mixture of coagulum and cell protoplasm, one deals here with intermediate stages in the organization process In the periphery of the capsule, where lymphocytic infiltration is noticeable, blood pigment cells appear, during the organization process, they carry particles of hemoglobin derivatives away into the surrounding tissue Near the clot, there are again pieces of yellow-stained, solid particles of coagulum with many giant cells, in some of which the nuclei have become pyknotic While

the connective tissue cells are arranged concentrically around the clot the blood vessels run as usual in a radial direction toward the coagula

After Eleven Days After eleven days, one finds again, in the fibrous tissue capsule, some remnants of clot in the form of hyaline material, as well as of hemoglobin-containing particles of coagulum Likewise there are, in places, in the connective tissue capsule, large masses of lymphocytes, as well as some polymorphonuclear leukocytes and blood pigment cells Phagocytes, epithelioid in appearance, replace parts of the clot, and again there are red-staining fibers, presumably representing a mixture of fibroplasm and coagulum, around the coagulum, and the majority of the cells between the fibers are phagocytes, containing pigment in various stages of disintegration The cells that have penetrated farthest into the coagulum are already destroyed The provisional organization is therefore still proceeding, subsequently, the organized material is transformed into connective tissue Also at this period, some red and yellow pieces of hard material, around which giant cells and connective tissue fibers are seen, develop from coagulated material In other specimens, such pieces of pigmented hard blood clot, together with foreign body giant cells, epithelioid cells and lymphocytes, are the principal remnants of the blood clot In some places there can be seen a pronounced lymphocytic infiltration, while in other places vacuolated cells surround the coagulum In the interior of the phagocytic cells, pieces of coagulum, which they have taken up, become granular, and this change represents a step in the solution of the coagulated material The whole is enclosed in a fibrillar or fibrous connective tissue capsule

COMMENT

My aim in this paper was to compare with the transplantation of living tissues, which were studied in a preceding series of papers, the transplantation of cells which have genetically the same constitution as other cells of the same organism, but which soon after transplantation cease to maintain their specific metabolism and gradually undergo disintegration and solution The problem was whether such material would call forth the same autoreactions, homoioreactions and heteroreactions as were found in the case of ordinary metabolizing tissues Do the individuality differentials function in such cells as they do in the case of normal tissues?

I therefore transplanted into the subcutaneous tissue of the guinea-pig blood clots from the same guinea-pig (autogenous blood clots), as well as from other guinea-pigs (homoiogenous blood clots) Furthermore, I carried out various kinds of heterotransplantations In the case of autotransplantation and homoiotransplantation, I found relatively simple reactions on the part of the host tissue The fibroblasts of the

host capillaries invade the coagulum, they form first a provisional organization leading to a mixture of coagulum and fibroplasm which is then definitely organized by fibroblasts growing into this material somewhat later This provisional organization leads to the formation of various structures, as, for instance, fibers staining red with eosin, representing mixtures of coagulum and of the protoplasm of fibroblasts Similar structures are also found after transplantation of heterogenous coagula, and both after homoiotransplantation and heteroiotransplantion there occur, in the fibrillar capsule surrounding the clot, remnants of the blood coagulum in the form of red-staining strands of pale hyaline material Capillaries participate in the process of organization There are occasionally some lymphocytes visible in the tissue surrounding the clot and accompanying the fibroblasts in their invasion of the clot, but on the whole, they are inconspicuous While one cannot exclude the possibility that a slight difference exists between autotransplantation and homoiotransplantation, it certainly is not comparable to such differences as one finds after transplantation of living tissues Phagocytosis occurs during the organization of the homoiogenous blood clot, but it is not a conspicuous process, however, phagocytes help occasionally in transforming the coagulum, within these cells, the particles of clot are first split into granules, which then, after the disintegration of the cells coalesce to form a hyaline material Polymorphonuclear leukocytes do not play a significant rôle, and whenever they are prominent one is justified in assuming a contamination of the coagulum with bacteria One may, therefore, conclude that the typical homoiotoxins are not in any considerable quantity given off by the nonnucleated erythrocytes of a blood clot Evidently living and metabolizing cells are necessary for this purpose

Conditions are different after transplantation of heterogenous blood clots, the reaction of the surrounding host tissue being in this case much more pronounced Admixed to the connective tissue, surrounding and invading the clot, there are generally considerable numbers of lymphocytes, and the capsule around the coagulum is usually thicker than after homoiotransplantation or autotransplantation, however, the number of lymphocytes, as well as the thickness of the connective tissue capsule, vary in different experiments, as well as at different points around the same coagulum Furthermore, there are areas with partial solution of the clot, in which various stages in the process of solution can be recognized A further distinction between the reaction of host tissue against homogenous and heterogenous clots is the greater prominence of phagocytic cells in the latter type Phagocytes take up particles of heterogenous clot containing erythrocytes and gradually dissolve them within their cell bodies Such phagocytic cells are frequently seen in great

numbers and occasionally form a tissue, in appearance not unlike xanthoma Around or invading the coagulum, there are often present polymorphonuclear leukocytes These cells are much more prominent after heterotransplantation than after homoiotransplantation While it is possible and even probable that in some cases contamination with bacteria is the cause of the increased number of these leukocytes, I do not believe that this factor is solely responsible for it, because my technic was the same after homoiotransplantation and heterotransplantation In this connection I must recall the fact that, also after heterotransplantations of ordinary tissues, polymorphonuclear leukocytes are more prominent than after homoiotransplantation As to the processes of solution which take place in the heterogenous coagula, they are probably largely due to the action of the heterogenous serum of the host, as an indication that such a process occurs one may consider the swelling of erythrocytes which I was able to observe in one specimen, and which I consider as a first step in the solution of the coagulum However, it is probable that, in other cases phagocytic cells or polymorphonuclear leukocytes contribute to the solution or cause it altogether

One sees then that heterogenous blood coagula call forth much more active reactions on the part of the host tissue than do autogenous and homoiogenous coagula Evidently heterotoxins are found also in dead cells, and may gradually be extracted from the latter and thus cause reactions on the part of the host These heterotoxins being more active than homoiotoxins exert an influence not only on the sensitive lymphocytes, which react to slight chemical alterations in the environment, but also on the polymorphonuclear leukocytes, which respond to stronger poisons

My results confirm thus my earlier conclusions as to the difference in the character of homoiotoxins and heterotoxins, and they are also in agreement with the experiments of Siebert[2] who found, in this laboratory, that typical heteroreactions can be obtained from cartilage subjected to moderate degrees of heat, sufficient to cause the death of the heterotransplant whereas after homoiotransplantation a reaction was obtained only in case the transplant remained alive Moreover the interaction which in this case takes place between substances present in the blood serum of the host and the transplanted heterogenous material, leading to processes of solution, accentuates the reactions of the host cells against the transplant

There are some quantitative differences in the effects caused by various types of heterogenous blood clots, but, in general the reactions are very similar in character One may therefore conclude that dying or

2 Siebert W J Proc Soc Exper Biol & Med **26** 238 1928

dead heterogenous transplants may still exert a specific effect on the host tissue, whereas the specific homoioreaction is no longer fully developed under these circumstances

SUMMARY

The simple processes taking place during the organization of autogenous and homoiogenous blood clots are contrasted with the much more complex processes observed during the organization of heterogenous blood clots The various types of reaction that occur in the latter case, represent reactions to heterotoxins, which remain active even in dead or degenerating tissue in contrast with homoiotoxins which are active only in case of continued life and metabolic activity of the transplant

Laboratory Methods and Technical Notes

A COMPARATIVE STUDY OF CERTAIN METHODS FOR THE ESTIMATION OF HEMOGLOBIN

C A Pons, M D, and M Schneider, B S, Long Branch, N J

Although numerous methods have been introduced and recommended for the determination of the hemoglobin content of the blood, they still possess certain inherent difficulties or faults that leave much to be desired The methods more commonly employed are subject to varying degrees of inaccuracy, so that the results obtained by the technic in one laboratory are often not comparable with those obtained in other laboratories by the same or different technics While other methods are accurate and furnish data that may be duplicated, they require more time, equipment and care than many laboratories can afford

The satisfactory technic for the estimation of hemoglobin, therefore, should include in its performance a minimum requirement of time, simplicity and facility of operation, and an accuracy such that results obtained can be duplicated A study has accordingly been made of various methods and a technic has been adopted which appears to fulfil the conditions stated

METHODS

In this report, we include only the gasometric technic of Van Slyke and Stadie,[1] the iron method of Wong,[2] the more recent colorimetric method of Newcomer[3] (the use of a colored glass plate and filter) and one modification of the Newcomer method Estimations of the red blood cells have also been made in order to supply another means of comparison

The modification that we have made of the Newcomer method consists of (1) the use of 2 5 cc of diluent (approximately tenth-normal hydrochloric acid) instead of 5 cc and (2) the use of two colored glass plates which are glued together The same amount of blood, 20 c mm, was used The details of the determination, therefore, are (1) 20 c mm of blood is added to 2 5 cc of diluent, (2) after this is mixed, it is allowed to stand thirty minutes, (3) the blood mixture is transferred to one cup of a colorimeter, while distilled water is added to the other cup, and the double glass plate is inserted under the latter The colorimeter used is the Bausch and Lomb microcolorimeter (no 3265), and light conditions are kept uniform by employing a Palo daylight colorimeter lamp

In order that the readings obtained by the colorimeter may be readily translated into grams of hemoglobin per hundred cubic centimeters of blood, a table is prepared in which are given the values of hemoglobin representative of the differ-

* Submitted for publication, March 7, 1930

* From the Laboratory of the Monmouth Memorial Hospital

1 Van Slyke, D D, and Stadie, W C J Biol Chem **49** 1, 1921

2 Wong S Y J Biol Chem **55** 421 1923

3 Newcomer, H S J Biol Chem **27** 465, 1919

ent readings These values are derived from the formula given by Newcomer[3] $3 \frac{0\ 38\ d}{t}$ in which d equals the dilution of the blood (251) and t the reading of the colorimeter in millimeters A correction for the thirty minute interval during which the diluted blood is allowed to stand before being read has been computed to be 1 5 per cent more than the value obtained directly from this formula

EXPERIMENTAL RESULTS

The results of previous experience with the original Newcomer color plate method were unsatisfactory, because the color elicited was too pale for matching the hues in more commonly encountered ranges For this reason, the double plate method, as described, was adopted

TABLE 1—*Results of Different Methods of Deriving the Hemoglobin Value of Blood*

Specimen of Blood (Different Persons)	Van Slyke's	Pons Newcomer	Wong's	Newcomer's	Erythrocyte Count	Percentage of Error
1	14 40	14 2	14 8			—1 38
2	12 62	12 7	13 0		3 820,000	+0 63
3	12 39	12 7	19 0		3,900,000	+2 50
4	12 56	12 9	13 0		4,950,000	+2 61
5	11 60	11 9	12 0		3,860,000	+2 59
6	16 53	16 4	16 6			+0 78
7	12 82	12 9	12 3	13 99	4,630,000	—0 62
8	14 54	14 72	14 5	16 55	4,540,000	+1 30
9	13 70	14 0	14 6	16 5	3,750,000	+2 19
10	13 90	14 3	14 6	17 0	4,060,000	+2 87
11	10 20	10 6	10 7	12 0	3,330,000	+3 90
12	15 90	16 1	16 4	19 0	4,850,000	+1 25
13	14 70	14 9	15 1	17 53	3,900,000	+1 35
14	12 64	12 9	12 8	14 6	4,940,000	+2 05
15	10 32	10 6	10 7	10 7	3,850,000	+2 71
16	13 48	13 6	14 0	14 0	3,620,000	+0 89
17	12 90	13 1	13 0	13 0	3,790,000	+2 39
18	10 64	11 0	11 5	11 5	3,900,000	+2 90
19	13 76	13 8	14 0	14 0	4,820,000	+0 29
20	14 96	15 1	15 4	15 41	4,320,000	+0 93

Mean average error between Van Slyke's oxygen capacity and Newcomer's +1 80 per cent

Observations have been made on specimens of blood from twenty different persons Sufficient blood was collected by venipuncture in tubes containing sodium oxalate so that hemoglobin values might be determined at the same time by the four different methods enumerated (table 1) The results reveal that the values obtained by the modified Newcomer method vary from those obtained by the Van Slyke and Stadie method, by a minimum deviation of 0 29 per cent and a maximum of 3 90 per cent The average variation for the twenty determinations, however, is only 1 80 per cent

The value obtained by the modified Newcomer method approaches more closely the Van Slyke value in sixteen instances, while the Wong method gives more nearly the accurate figures in four instances The differences in the results obtained by the Wong method and the modified Newcomer method are not sufficiently great to justify the assumption that the latter method insures more accurate results The facility of the modified Newcomer method however, renders it preferable In none

of the determinations did the newer modification of the Newcomer method give the value closest to that obtained by the Van Slyke method

The normal standard of hemoglobin as given by different authors (table 2) shows marked variations The more commonly employed value is Haldane's, which is given as 13 89 Gm per hundred cubic centimeters of blood Williamson accepted the much higher value of 16 8 Gm A study of the data in table 1 discloses that Haldane's figures are indeed too low for a normal standard We have accepted the Haden standard (15 8 Gm) as the normal

TABLE 2—*Hemoglobin Content of Blood Considered as Normal by Different Investigators Using Different Methods*

Investigator	Men Studied	Average Normal Value
Sahli, quoted by Kern, R A M Clin N Amer 5 129, 1921	Not stated	17 20
Williamson Arch Int Med 18 505 1916	36	16 80
Haden, R L J A M A 79 1496, 1922	20	15 83
Osgood, E F J Biol Chem 57 10[illegible] 192[illegible]	137	15 76
Haldane, J J Physiol 38 11[illegible], 1901	12	13 89

COMMENT

This report comprises a comparative study of the determination of hemoglobin in the blood with the Van Slyke and Stadie method as the standard This method was compared with the iron method of Wong, the Newcomer technic in its latest form (i e, the use of a colored plate and filter) and our own modification of the Newcomer method as described It has been found that the modification suggested most nearly approximates the values derived by the Van Slyke method The average deviation from the Van Slyke method in determinations in twenty persons was only 1 80 per cent In addition, it is performed with ease, and it gives similar results on repeated determinations

The values reported in this study have been given in grams of hemoglobin per hundred cubic centimeters of blood This we consider a more accurate and more appropriate manner of expressing the determinations than that more widely employed, i e, in percentage of hemoglobin The custom of stating the quantities of the chemical constituents of the blood in grams per hundred cubic centimeters of blood establishes a precedent which should include hemoglobin values also It has been our custom to report hemoglobin determination in grams rather than "per cent" in a large hospital laboratory and more recently in the present laboratory In both instances the changes were readily accepted

SUMMARY AND CONCLUSIONS

A modification of the Newcomer colorimetric method for the determination of hemoglobin in the blood is described This modified method gives values varying on an average 1 80 per cent from those derived by the Van Slyke and Stadie method It is managed with facility, it does not require expensive equipment, is not time consuming and the standard is permanent

It is suggested that hemoglobin values be expressed in grams per hundred cubic centimeters of blood

General Review

SMALLPOX AND VACCINIA

THE PATHOLOGIC HISTOLOGY *

DEDICATED TO DR W T COUNCILMAN IN HONOR OF HIS SEVENTY-SIXTH BIRTHDAY

R D LILLIE, M D
Passed Assistant Surgeon, United States Public Health Service
WASHINGTON, D C

But little of present importance in the pathologic histology of smallpox was described before the European epidemics of 1870 and 1872 The most attention has naturally enough been devoted to the lesions of the skin, but a considerable number of authors have described also focal lesions of the various internal organs Recently, these focal lesions have been strikingly paralleled by visceral lesions produced experimentally in rabbits by the use of especially virulent vaccine viruses, the effects of one of which I have had the opportunity of studying in detail in about 150 animals This study is being reported eleswhere and will be referred to only briefly in this communication

Owing to the rather considerable number of references on the subject, it was thought desirable to discuss the various organs affected individually, more especially as that plan was followed in the comprehensive review given in the great work of Councilman, Magrath and Brinckerhoff (1904) I have attempted to make this review equally comprehensive, and must here express my regret that it was necessary to derive many of the earlier references from reviews, as they were not available in their originals

SKIN

Barensprung described four stages in the evolution of the pock First were seen widening of the blood vessels of the skin, elongation of the papillae, thickening of the rete and consequent epithelial elevation to form the papule Next followed swelling of the rete cells with fluid exudate, formation of a thick wall laterally and, centrally, separation of the cells so that they floated free in the vesicle space between the stratum corneum and the papillae In pustulation, the lower part of the rete was destroyed by suppuration The fourth, inconstant

* From the Hygienic Laboratory

stage, comprised ulceration According to Auspitz and Basch, the vesicle was formed by a reticulum containing in its meshes fluid and pus cells Both these and the reticulum were considered as derived from the epithelium Umbilication was explained as due to changes in the epithelium and to evaporation from the central portion Klebs saw a reticulum formed in the middle layers of the epidermis through the separation of the epithelial cells by fluid and cellular exudate

Rindfleisch described serous exudation proceeding up from the papillae, separating the cells and forming vertical or oblique trabeculae in the thus formed vesicle The swollen cells in the lower layers of the rete next gave rise to pus cells, which filled the vesicle space, later in some cases there was suppuration with destruction of the papillae Luginbuhl called attention to the presence of multinucleate giant cells

Zuelzer and also Ponfick reported cutaneous hemorrhages in hemorrhagic smallpox, but gave no histologic details

Weigert first introduced the concept of primary coagulation necrosis with subsequent leukocyte reaction He also first studied the histologic relation of bacteria to the pock and first described the inclusion bodies later brought into such prominence by the work of Guarnieri and others following him Weigert found primarily a diphtheroid necrosis in which the cells of the lowest layer of the epidermis were necrotic, but not broken down Laterally and above these, fluid collected between the cells and caused the umbilication by the greater swelling in the periphery of the pock than in the coagulated necrotic central basal portion

Cornil saw cavities arising within the epithelial cells forming a reticulum composed of the cell peripheries The cell content of these spaces was derived partly from epithelial proliferation and partly from emigration from the corium

Leloir noted in the papular stage the formation of a clear perinuclear zone in the cells especially of the middle of the rete This space enlarged, and the contained nucleus fragmented and disappeared Next there was fusion of these intracellular spaces with invasion by pus cells from the corium Fibrin was seen in the space of the vesicle as a fine network For details of Renault's work on the development of the pock I am indebted to the reviews of Burchardt, Unna (1882) and Councilman He described edema and dilatation of the papillary lymphatics Prickle cells above the basal layer showed first perinuclear vacuolation, then swelling to large vacuoles and fusion of these to form the vesicle, the trabeculae being made up of condensed cell peripheries and cement substance Centrally, the rete cells showed granular degeneration, and later, necrosis and liquefaction of the basal cylindric cells, peripherally, there was vacuolation like that in the upper prickle cell

layer During the conversion of the vesicle into the pustule, there was capillary engorgement in the papillary bodies, with emigration of leukocytes and invasion of the vesicle by these There was breaking down of the corium under the pustule Renault described in the prevesicular stage numerous round refractile bodies, uniform in size, which on the warm stage grew into short "branches" composed of a row of similar spherules These he considered parasitic They were found in the perinuclear zone of isolated prickle cells, the latter often in the process of reticulating colliquation

Touton described several rather early pocks These were not dissimilar from the vaccine pustule described by him (q v) Hemorrhage was lacking, the necrotic cell masses described first by Weigert were less numerous, the trabeculae were thinner, the basal prickle cells were often normal or little swollen, and the round cells were more numerous Near the lateral margin of the mesh work were poorly stained foci with poorly defined nuclear and cellular outlines breaking down to vacuoles filled by granulofibrillar material This change he designated as cloudy swelling He also noted a fibrinoid degeneration of some of the epithelial cells

Guarnieri described his *Cytoryctes variolae* and *vaccinae* with several phases, which he considered as evidence of the protozoal nature of these inclusions As this subject was recently critically reviewed in the ARCHIVES by Goodpasture, I will not attempt to cover again the extensive literature which has arisen on the nature and significance of these bodies

Buri, working in Unna's laboratory, described in detail the evolution of the pock and reviewed the literature on the subject His description of the epithelial changes follows Unna's so closely that it hardly appears necessary to cite it in detail He saw much infiltration of the corium with pus cells even in very early stages These leukocytes were especially numerous in the papillae and along the blood vessels and glands Edema and dilatation of lymph and blood vessels appeared early and became more pronounced in the acme of the process Necrosis or destruction of the derma or papillae was not seen in Buri's preparations, nor did he find any diphtheroid necrosis of the epithelium In this connection, it should be noted that Buri's material comprised several pustules from one autopsy and specimens taken for biopsy, at various stages of the disease, apparently largely from discrete cases, but in at least one from a confluent case MacCallum and Moody in material taken from alastrim for biopsy, and Sweitzer and Ikeda in material taken for biopsy, from their discrete cases also saw a marked and early leukocyte reaction and lack of necrosis in dermis and epidermis

The description of the pock by the late Professor Unna (1894) is considered classic and as some of the terms used by him appear to

have been misinterpreted in more recent literature, I will attempt to summarize his account In the papular stage, "reticulating colliquation" occurs in the upper portion of the prickle cell layer of the generally edematous epithelium This begins in cytoplasmic vacuoles and is followed by fibrinoid degeneration Vertical trabeculae of epithelial cells are left In the lower portion of the prickle cell layer, "ballooning degeneration" occurs In this process, the epithelial cells separate and round up into rounded masses ("balloons") containing one or two nuclei, rarely more The vesicle extends above by a breaking down of the edematous cells Ballooning extends less The next step is fibrinoid degeneration of the trabeculae and "ballooned" masses Necrosis does not necessarily ensue In the corium, dense perivascular infiltration with large vacuolated plasma cells occurs in the papulovesicular stage On the fifth day the blood vessels of the skin dilate, emigration of leukocytes follows, these invade the vesicle and convert it into a pustule Suppuration ensues when the horny layer breaks down Otherwise, the pustule dries, and the epithelium grows in under the pock from all sides, cornifies upward and finally pushes off the crust Unna did not describe pocks in which destruction of the underlying corium occurred

Bosc found the lesion of the skin in smallpox essentially like that in vaccinia Stokes noted the frequent exudation of fibrin into the pock Councilman, Magrath and Brinckerhoff observed first nuclear swelling with chromatin clumping in the epithelial cells Cytoplasmic inclusion bodies were often present Reticular degeneration ensued, in which cell vacuoles formed, then ruptured and fused to form vesicles The trabeculae were formed by condensed cell peripheries The lowest cells in the center of the pock underwent "hyaline fibrinoid degeneration" in which they swelled and rounded up singly or in masses and then became hyaline and refractile reacting as fibrin to the Weigert method Only in the later stages did polymorphonuclear leukocytes appear in the vesicle At this time also were noted perivascular infiltrations in the corium These consisted of polymorphonuclear leukocytes and large basophil cells The latter, in part, were identified with Unna's plasma cells Judged by Councilman's excellent illustrations, the large basophil cells to which he so often refers appear to comprise both plasma cells and large lymphoid cells with nucleoli, leptochromatic nuclei and broad basophilic cytoplasm, apparently of the same type as those referred to by Pappenheim as lymphoidocytes Larger lesions showed complete destruction of the basal epithelium in the center, and necrosis of part of the corium The healing occurred essentially as described by Unna Purpuric cases showed hemorrhages in the corium, numerous streptococci in tissues and blood vessels and widespread reticulating degeneration of the epithelium Many inclusions, both

nuclear and cytoplasmic, were present Mitoses were frequent in non-reticulated areas

Ferguson described incompletely septate vesicles The septums, he believed, arose in part by proliferation of papillary epithelial buds from the malpighian layer The pustule contents he found to be about half polymorphonuclear leukocytes and half small hyaline cells In cases in which the pocks were confluent, almost continuous vesicle formation occurred over wide areas There were swelling and degeneration of the dermal collagen, infiltration by blood corpuscles and mononuclear leukocytes and frequent small intra-epidermic abscesses Healing was described essentially as by Unna

Schrumpf, in a dissertation mainly devoted to the description and discussion of Guarnieri bodies and their significance, described briefly the histogenesis of the pock There was proliferation of the malpighian layer followed by a central breaking down, exudation of fibrin and invasion by cocci Later, the margins showed varying amounts of vacuolization of the proliferated epithelium, the center, a trabeculated space filled by degenerated epithelial cells leukocytes, fibrin, cocci and débris

Heinrichsdorff studied the lesions of the skin in hemorrhagic smallpox, not including purpura variolosa One type of lesion showed first, edema in the corium, with foci of small and large round cells, small hemorrhages and emigration of leukocytes This swelling and infiltration flattened out the rete pegs of the epidermis, producing thereby a papular elevation In some of these lesions there was also exudation of fluid between the corium and epidermis, in others, small droplets of fluid appeared in the cytoplasm of the epithelial cells compressing and displacing their nuclei, but not fusing to form vesicles At the same time there was marked proliferation in all layers of the epidermis Another type of lesion showed complete coagulation necrosis of the entire epidermis In this, indistinct spaces appeared in the fused necrotic cell mass, the larger of these being filled with blood and polymorphonuclear leukocytes Marginally, such lesions showed vacuolar degeneration of the epithelium In the corium, there were hemorrhages, disruption of tissue and necrosis, capillary swelling, degeneration and thrombosis Beneath larger pocks, there were capillary lesions and edema in the corium, vacuolation of the basal layers of the epidermis, and next to these, necrotic cells surrounded by epithelial giant cells each with many small nuclei or a single giant nucleus Above these was a zone of degenerating cells breaking down to form detritus-containing spaces Elsewhere were seen epithelial syncytia with scattered pyknotic nuclei Necrosis and vesiculation occurred indiscriminately in all parts of the epithelium beneath the horny layer The hair follicles also showed necroses and epithelial giant cells Also the sebaceous

glands showed necroses These were first surrounded by exudation of fluid and polymorphonuclear leukocytes Later, either they formed and extruded a crust by downgrowth of epithelium or there occurred round cell infiltration and scarring This report of the necrosis of sebaceous glands appears to be unique in the literature of smallpox I have seen involvement of the glands of the skin in the coagulation necrosis of the corium in the local lesions of virulent vaccina in rabbits, as I believe have also Ledingham and Barratt, and Bijl and Prenkel, though they make no specific statement, and focal glandular lesions, as well, among the lesions produced by the Calmette-Guerin reaction

MacCallum and Moody studied a small number of specimens taken for biopsy from alastrim in Jamaica In the early stages, there were edema and dense perivascular infiltration of the corium The infiltrating cells were polymorphonuclear leukocytes and mononuclear cells, including definite plasma cells At the site of pocks, the epithelium was "relaxed and separated into loose cells" There appeared between the cells spaces which were "generally loaded with leukocytes" There was vacuolation which often appeared to be intranuclear, and there was often necrosis of overlying cells, but central basal coagulation necrosis was not observed The corium was usually denuded in the center of the pock Inclusions resembling those described by Guarnieri and others were seen Healing occurred as in smallpox The marked cellular inflammatory reaction in these cases is noteworthy and comparable only with that in Michelson's and Ikeda's benign case

Sorensen and Sorensen, in a case of purpura variolosa with a hemorrhagic exanthem, noted the usual picture of the early pock and streptococcal thrombi The account of Michelson and Ikeda presents few variations from those of Unna and Councilman Interepithelial perpendicular rifts were seen when much edema was present Some reticulation was noted in the deeper parts of the horny layer Destruction of elastic tissue was noted in the scars in cases in which recovery had taken place, contrary to the statement of Unna that elastic tissue did not degenerate Their benign case showed much more cellular infiltration of the corium than most of the fatal cases In purpura variolosa, Ikeda saw cutaneous hemorrhages, some perivascular mononuclear infiltration, cloudy, edematous swelling of the epithelial cells with separation of the basal layer by serous exudate, areas of ballooning and reticular degeneration and early vesicle formation

The histology of the lesions of the skin in vaccinia has been studied principally in animals, chiefly the calf and the rabbit But few publications dealing with these lesions in man have appeared

Kierle described the vaccine crust as a slough of the skin in which were distinguished histologically from above down a layer of epidermal

scales, the blood tinged cells of the rete mucosum, the likewise blood tinged papillae and interpapillary furrows, the hair follicles and elastic tissue and last a wide-meshed, coarse-threaded, branching connective tissue showing excessive cell proliferation on its trabeculae and containing sweat glands and ducts

Touton described a vaccine pustule ten days after inoculation Fairly dense small cell infiltration was noted in the cutis, with some hemorrhage in the papillary body and above this an irregular meshwork with coarse trabeculae of mostly nonnucleated, compressed epithelial cells and a finer meshwork corresponding to individual cell walls In the mesh spaces next the cutis were dense masses, granular toward the center, often with traces of a nucleus Above these, in the larger spaces, were cells with well stained nuclei, masses similar to those in the basal layer and granular and fibrillar débris, also some wandering cells Toward the roof were large cells with swollen, pale nuclei, breaking down to form further spaces, laterally, in the upper part, were swollen cells with clear vesicles containing sickle-shaped chromatic areas in the place of nuclei, lower a "compressed epithelial cord" Marginal proliferation was not noted

Gaucher observed a fatal case of generalized vaccinia in an infant 1 month of age There was a generalized pustular eruption At autopsy, the lungs were intensely congested, the spleen was enlarged and soft, and the liver was flecked with foci of fatty degeneration No histologic observations were reported Death occurred on the fifteenth day after vaccination or the sixth day of the general eruption Calf virus was used

Buri studied vaccine pustules removed on the fifth, sixth and eighth days from an infant The vesicle space was already large on the fifth day, the roof thin, the floor made up partly of naked, partly of epithelium-covered, well preserved papillae Only a few vertical or oblique trabeculae of compressed cells were present Ballooning degeneration, though seen chiefly in the lower layers, was not confined to this area and was generally much more extensive than in variola Reticulating degeneration was also seen in all layers, though again principally in the upper ones Laterally, as in smallpox, there were marked proliferation and edema of the epithelium Leukocyte infiltration both in the pock cavity and in the cutis was much less extensive than in variola Coagulation necrosis of epithelial cells was seen only along the line of the inoculation Multinucleated "balloons" as in variola showed two and three nuclei, but not more Balloons showing peripheral reticulation of their cytoplasm were seen in the eight day pustule

Unna (1894) found that ballooning colliquation played a much larger part in vaccinia than in variola Four to six rows of such rounded, ballooned epithelial cells were seen on the roof The vesicle

space lay more in the middle of the prickle cell layer The ballooned masses on the floor of the vesicle were more often multinuclear than in variola Above and lateral to the areas of ballooning was found the reticulating colliquation seen in smallpox Some of the marginal "balloons" in the roof sometimes showed the vacuolation of the reticulating type of degeneration in their outer portions The region of the inoculation wound showed a vertical strand of Weigert's coagulation necrosis, the cells comprising it having lost their nuclei and undergone fibrinous degeneration The cells of the septums were less flattened and compressed than in variola and appeared to represent remnants of the ducts of the sweat glands Suppuration was late and relatively slight, the vessels of the derma were widened only to the depth of the papillary body, the swelling of the connective tissue cells was similarly superficial, plasma cells were absent, emigration of leukocytes was slight, even at the height of the process when compared with variola The peripheral reticulating colliquation was much less than in variola Healing occurred as described in variola The comparative lack of necrosis of epithelial cells and the slight reaction in the derma contrast sharply with the much more severe injury of tissue described by Turnbull and McIntosh thirty years later

Cory vaccinated supernumerary digits of children and amputated these at varying intervals after the vaccination In this material, he saw in the papular stage an increase in the size and number of the epithelial cells and an increase of intercellular fluid, especially between the round epithelial cells of the rete malpighii As the lesion developed, this process spread peripherally while centrally the excess of intercellular fluid and the rupture of some of the large cells produced vacuoles while other cells were compressed into flattened and spindle forms to make up the trabeculae of the vesicle These changes progressed successively toward the periphery, centrally, fluid absorption occurred, and the cells became smaller Fibrinoid degeneration, necrosis, ballooning and leukocyte invasion were not mentioned An areola appeared around the vesicle about the eighth day, and about the tenth day a new stratum lucidum appeared marginally and extended beneath the vesicle, finally pushing off the scab Changes in the dermis were not described

Ewing, comparing the lesions of the skin in vaccinia and variola, concerned himself mainly with the cell inclusions, which he considered, for the most part, degeneration products

Howard and Perkins described the histology of vaccinia as based on twenty-five specimens taken for biopsy from twelve vaccinated adults In forty-eight hours, a cup-shaped vesicle traversed by an eosinophilic reticular meshwork had appeared The horny layer formed the roof the floor centrally, was bare corium, with cells laterally in hyaline

fibrinoid degeneration, and other forms of degeneration marginally The hyaline fibrinoid cells were intensely oxyphil, hyaline and often elongated, their nuclei shrunken and pyknotic The marginal basal cells were swollen, reticulated or granular, sometimes vacuolated, their nuclei swollen, with the chromatin clumping or shrunken, pyknotic or fragmented In the lateral wall were seen swelling of cells, loss of prickles, inclusion within epithelial cells of other epithelial cells and of mononuclear leukocytes Between the basal cells and in hair follicles and sweat glands there was invasion by red cells, small and large mononuclears, polymorphonuclear neutrophils and especially eosinophils Marked edema of the papillae was noted, also free red cells, mononuclear and polymorphonuclear leukocytes, hyperemia, capillary endothelial proliferation and desquamation There was marked perivascular infiltration by leukocytes, but no necrosis or abscess formation On the third day, leukocytes invaded the lower parts of the vesicle, this extended laterally by hyaline fibrinoid and reticulating degeneration, the inflammatory reaction in the corium was more marked The reticulum became more and more condensed, the invasion of the vesicle by leukocytes progressed, and necrosis of epithelium and leukocytes advanced until, by the fifth day, there was a crust of dense, homogeneous, deeply stained reticulum containing necrotic leukocytes Epithelial undergrowth appeared then and was further advanced on the seventh day

The virus used was evidently potent, as large vaccinations, extensive local edema and constitutional symptoms occurred in some cases

Turnbull and McIntosh described the lesions of the skin in their cases of postvaccinal encephalitis In these, they saw crusts, including an area of necrotic corium, demarcated by a zone of red cells and broken-down leukocytes The crusts contained vesicle spaces between the stratum corneum and the stratum lucidum in which were serum and leukocytes The underlying tissue showed perivascular infiltration with large and small lymphocytes, "hyaline cells," plasma cells, eosinophils and neutrophils In two cases there were extensive necrosis and exudation of fibrin Generally there was marked subcutaneous edema

These changes contrast with those seen by Cory and Unna much as do the lesions produced by viruses obtained by passage through rabbits in those animals with those produced by workers twenty-five years ago with calf virus of that day The contrast in each instance seems to indicate an enhanced virulence in present vaccine viruses

Pohl-Pincus inoculated a calf in from twenty to twenty-five places on one side, and from twelve to fourteen days later, on the other side He excised one or two lesions daily, hardened them in alcohol and studied serial sections stained with methyl violet and picric acid A line of necrosis appeared along the inoculation wound by the second day, enlarging on the third Cocciis masses were contained in this The

necrosis did not appear after the second inoculation The necrosis was surrounded by a zone of "cloudy swelling" with resulting marked thickening of the stratum corneum In this zone, the nuclei were well preserved or shrunken To Unna this cloudy swelling appeared to correspond to Weigert's diphtheroid degeneration Around this was a third zone of "irritation" in which were perinuclear clear zones about shrunken nuclei This appearance both Pincus and Unna considered artefact, as the latter did not find it after osmic fixation Widening of intercellular spaces with separation of the cells of the "irritation zone" was seen on the fifth day, and by the eighth day the entire pustule was converted into a necrotic crust surrounded by a zone of "cloudy swelling" and a wide "irritation zone" The period of anemia of the cutis seen by others in smallpox occurred here also

Touton described the ingrowth of new epidermal tissue under the pustule in the calf, separating it from the pus infiltrated (eitrig) corium

Kent noted fragmentation of cell nuclei and in the cytoplasm of the cells (epithelial?) the formation of rounded bodies each containing a central hematoxylin stained granule, but gave no details of the histogenesis of the vaccine vesicle

Copeman and Mann gave a detailed description of the histogenesis of the vaccine vesicle in the calf, paying much attention to the inclusion bodies of Guarnieri Necrosis and swelling of the basement membrane and profuse emigration of eosinophil leukocytes occurred in the first forty-eight hours Dilatation of the intercellular lymph channels followed on the third day, then hypertrophy and swelling of the epithelial cells Next followed reticulation or ballooning The latter process occurred principally in the lower part of the malpighian layer In this, the epidermis separated into vertical strands surrounded by lymph These ruptured, producing intra-epidermal bullae containing free groups of from one to ten cells Sometimes these isolated balloons swelled to four or five times their original size, forming perinuclear vacuoles and becoming invaded by leukocytes Karyolysis and a fibrinoid modification of the staining reaction of the cytoplasm followed Sometimes, on the other hand, the balloons condensed and reacted more like true fibrin Apparently, these "giant cells" were usually multinucleate (According to Unna, the balloons of smallpox are more often mononuclear) Inclusions interpreted as Guarnieri bodies occurred in these Designated as a third type of giant cell were numbers of vesicular nuclei lying free in cavities among the surrounding cells At the same time, a process identified with Unna's reticulating colliquation occurred in the upper layers of the rete mucosum The meshes of the cytoplasmic network became coarser, the intracellular fibers fragmented, and the perinuclear space enlarged greatly On the fourth and fifth days, necrosis appeared in the basal cells becoming more extensive and

involving higher layers on the sixth day In the dermis, edema was seen from the second to the fifth days At first scanty, later more profuse infiltration with eosinophil and neutrophil leukocytes occurred On the sixth day, much fragmentation of these leukocytes was seen in dermis and hypodermis This report of extensive participation of eosinophils in the vaccinia variola reaction I believe to be unique in the literature These authors did not follow the process beyond the sixth day

Tyzzer found that vaccination of the skin of a calf produced a picture similar to that of smallpox in man The primary change was a swelling of the epithelial cells with pallor in staining and the appearance of a reticular structure in the cytoplasm, later vacuolation appeared, and hollowing out of the cell into a clear space containing a shriveled nucleus and bounded by dense adherent cell membranes without prickles In the developed vesicle, slender trabeculae of epithelial cells passed through its cavity Multinucleated cells were numerous, containing as many as ten nuclei Free nuclei were seen in spaces in the epithelium Numerous cytoplasmic inclusion bodies were seen in epidermal and sebaceous gland cells

Gailleton first used the rabbit as a vaccinifer, according to Bard and Leclerc Bard and Leclerc produced pustules on the shaved scarified skin of the rabbit, the contents of which reproduced typical vaccinia in the calf and in a child The evolution of the pustules proceeded as in the calf Calmette and Guerin described grossly the evolution of the discrete pustules produced by rubbing vaccine into the shaved, unabraded skin, and noted also the eruption of pustules three or four days later on skin shaved twenty-four hours after intravenous inoculation ("Calmette-Guerin phenomenon")

Tyzzer first reported histologic studies of the lesions of the skin in vaccinia in the rabbit On the third day, the skin was swollen to two or three times its normal thickness, and the tissue spaces were dilated, containing many polymorphonuclear leukocytes and lymphoid cells A fibrinopurulent crust covered the surface, and the stratum corneum was swollen and hyaline In its lower layers, the epithelium showed vacuolar degeneration Centrally, the spaces were larger, distended with fluid, partly filled with leukocytes and traversed by delicate anastomosing strands, laterally, mitoses were more than usually numerous and many typical vaccine bodies were present Calf lymph was used in the production of these lesions

Camus reported the production of pustules of the lips, tongue, buccal and nasal mucosa, nares, conjunctiva, margins of the lids, and anogenital mucosae after intravenous inoculation of rabbits with raw and purified vaccine pulp These pustules underwent a normal clinical evolution with umbilication No histologic study was reported

Levaditi and Nicolau studied the eruption following epilation in a generalized vaccine infection in rabbits They described formations resembling epithelioma penetrating the derma These later became swollen and vacuolated Invasion by migratory elements and separation, vacuolation and necrosis of the epithelial cells followed, resulting in small, later confluent vesicopustules Watanabe reported a generalized cutaneous eruption in rabbits with pustules also on lips, tongue and palate Intravenous inoculations were used The focal lesions of the skin, examined apparently on the fourth day, showed small round cell infiltrations in the derma, but no epithelial changes

Ledingham and his co-workers described histologically the lesions produced in the rabbit's skin by fresh calf virus introduced by the dermal, intradermal and intravenous (Calmette-Guerin procedure) methods In six hours after intradermal inoculation, the corium showed congestion, leukocytosis and polymorphonuclear infiltration In twenty-four hours, beginning necrosis and phagocytosis by macrophages were evident, and edema appeared in the interpapillary tissue and in the malpighian layer In forty-eight hours, the corium showed a zone of necrosis containing broken down leukocytes, fibrin and necrotic fibers, walled off by a dense infiltration with polymorphonuclears and some "adventitial cells" (large mononuclears or macrophages?) On the third and fourth days cellular edema and swelling in the malpighian layer appeared, hemorrhages and necrosis of blood vessels occurred in the necrotic area in the corium, and there was proliferation of the "adventitial cells" (fibroblasts?) about the skin muscle Ballooning is mentioned, but the description does not suggest the process described by Unna under that term In seven days, the epithelial cells appeared somewhat shrunken and showed mitoses Organization of the necrotic area appeared and progressed to obliteration of the defect by the fifteenth day In this process, deeply basophil "plasma cells" formed collagen from their cytoplasm These "plasma cells" constituted an intermediate phase between the "adventitial cell" and the histiocyte and apparently are not to be identified with Unna's plasma cells When dermal inoculation was practiced, the epidermal response was more severe, fibrin appearing focally in the malpighian layer The Calmette-Guerin procedure gave similar lesions Blocking with india ink produced an enormous hyperplasia of "reticulo-endothelial" elements and an accumulation of ink phagocytes and inhibited the vaccinal reaction

Sorensen and Sorensen described the lesions of the skin produced in rabbits by calf virus The epithelium showed intercellular leukocyte infiltration generally and between the mucous and horny layers When larger quantities of more concentrated lymph were used there were hemorrhages on and in the skin, and the cellular infiltration and proliferation in the corium were greater False membranes occurred but were also seen in control material

Douglas, Smith and Price produced eruptions of the skin by intravenous inoculation of Levaditi's neurovaccine, but gave no histologic description Bijl and Frenkel described lesions of the skin produced by a neurovaccine The lesions showed a hemorrhagic tendency, widespread necrosis and marked, sometimes gelatinous, subcutaneous edema at the site of inoculation Ledingham and Bairatt, using a neurovaccine, produced purpuric foci in the skin, which showed massive hemorrhagic necrosis of all tissues down to the skin muscle, without evidence of repair

Armstrong and I described elsewhere the lesions produced by dermal inoculation and those produced in epilated skin by intravenous inoculation Armstrong's heat resistant virus was used In the lesions produced by cutaneous scarification, small vesicular spaces and marked perinuclear vacuolation appeared in the epidermis in forty-eight hours, foci of coagulation necrosis, areas of polymorphonuclear infiltration, numerous clear vesicles with cellular trabeculae and rounded epithelial cells in the cavities and considerable serous exudation in the corium by the third day, more marked polymorphonuclear infiltration in the edematous corium and vesicle spaces, areas of hemorrhage in the corium and beginning subepithelial necrosis by the fourth day, and extension of the partly hemorrhagic necrosis in the corium, in the central part of the overlying epidermis and in the subcutaneous tissue on the fifth day, reaching the cutaneous muscle by the seventh day From the seventh to the tenth days, the morphologic details in the slough became obscured, and a marginal zone of fibroblast proliferation appeared At this time, the epidermis still showed marginal, fibrin filled vesicles Nearby skin showed zones of necrosis surrounding the lymphatic channels

In the metastatic (Calmette-Guerin) pocks, several varieties of degenerative changes in the epithelium were noted Earliest was the formation of perinuclear crescentic clefts, which enlarged becoming circular and showing irregular nuclear shrinkage Then there were seen areas of intercellular edema proceeding to the formation of wide vesicular spaces with cellular trabeculae irregularly arranged, rounded normal or swollen cells or groups of cells and epithelial giant cells Other areas showed marked cytoplasmic vacuolation, often combined with the perinuclear cleft formation, proceeding to the formation of a reticulum of condensed cell borders or to transgression of these and the formation of vesicle spaces, irregularly mixed among the last two were groups of large cells with pale-staining cytoplasm gradually giving way to complete liquefaction with accompanying karyolysis, and foci of coagulation necrosis of epithelial cells, occurring in the floors of vesicles, in the upper malpighian layer, in the upper portions of the cellular trabeculae of vesicles and in foci involving the entire thickness of the epidermis The perinuclear clefts appeared in twenty-four hours, the

large clear cells, the intercellular edema and the patches of edema in the corium in forty-eight hours, small vesicle spaces and areas of coagulation necrosis in three days and invasion of some of the vesicles by large numbers of leukocytes in five days Further extension and development of these processes followed, but clear vesicles predominated over pustules even to the end of the study, which was terminated at nine days by the death of the last animal The corium showed edema and hemorrhages as early as the third day, necroses of the glands of the skin and of the connective tissues appeared in five days Cellular infiltration was at all periods moderate Polymorphonuclears appeared early, lymphocytes usually predominated, large mononuclear cells of the macrophage type were common, and late and away from the immediate vicinity of epidermal lesions large lymphoid cells of lymphoidocyte type participated to a considerable extent Unna's plasma cells were rare

The distribution of the various types of epithelial degeneration was irregular, intracellular vacuolation overlapping the intercellular edema, the clear swelling and the coagulation necrosis, involving also the free rounded cells and cellular trabeculae of the vesicles at times Usually the various types were fairly well separated and distinct

These observations appear comparable only with those of Heinrichsdorff in hemorrhagic smallpox

Summed up, the earliest changes seem to be cell injury in the epithelium, manifested by cytoplasmic and perinuclear vacuolation, cloudy swelling and, in some instances, coagulation necrosis, intercellular edema, vesicle formation, "ballooning" following later and not being seen by all observers Papillary edema and mononuclear cell infiltration in the corium are seen early Emigration of polymorphonuclear leukocytes and invasion occur late, except when coagulation necrosis is present, then leukocytes appear earlier It is notable that coagulation necrosis was seen by Weigert in the severe epidemic of 1870 and 1872, by Heinrichsdorff in hemorrhagic smallpox and by me in the hemorrhagic focal lesions of generalized experimental vaccinia, this change was lacking in the material examined by Buri and by MacCallum and Moody, their material being taken largely during life and at least in part from nonfatal cases Unna's material, too, I believe, to have been at least partly specimens taken for biopsy Buri's and Unna's material was collected in the interior of Germany during a period when the mortality from smallpox was very low Renault and Touton each described coagulation necrosis of the epithelium, there was a pronounced increase in the mortality from smallpox for Paris in the years from 1879 to 1881 (figures for France were not available) [1] Councilman's histologic

1 I am indebted to the comprehensive report of Dr R Bruce Low (1918) for the figures on the prevalence and mortality of smallpox

material all came from fatal cases, his hyaline fibrinoid degeneration includes some coagulation necrosis On the other hand, the mononuclear cellular reaction in the corium has been stressed particularly by those workers who used material taken for biopsy Sweitzer and Ikeda especially noted this contrast

From the foregoing it appears that there may be some direct relation between the virulence of the virus and the amount of coagulation necrosis induced, and possibly a reciprocal relation between these and the amount of mononuclear cellular reaction in the corium

MUCOUS MEMBRANES

Probably focal lesions of the mucous membranes are next in frequency in smallpox after those of the skin These have comprised pocks, hemorrhages and more or less widespread diphtheritic inflammatory processes

Ponfick noted in hemorrhagic smallpox hemorrhages in the mucosa of the upper part of the respiratory tract, particularly that of the nose, in the mucosa of the stomach, colon and rectum, less often in that of the ileum, tubes, uterus and vagina, and commonly in that of the bladder the pelvis of the kidney There was often also a diphtheritic inflammatory process, especially in the pharynx and larynx Zuelzer also described hemorrhages in the mucosae of the respiratory and digestive tracts and of the renal pelvis and ureters Intense diphtheritic inflammation was almost constant on the tonsils, pharynx, upper part of the respiratory tract and female genitalia in his twenty-six cases of hemorrhagic smallpox

Eppinger stressed the frequency and gravity of lesions of the mucous membranes Joffroy described a pustular eruption in the larynx and trachea infrequently extending into the primary bronchi and rarely further

Kendall saw discrete and confluent pustular laryngitides and diphtheritic inflammation, the confluent type showed submucous inflammation

Breynaert described progressively smaller pustules in the bronchi These were sometimes umbilicated like the lesions of the skin, but more often were ulcers with slightly overhanging edges

Huguenin described lesions of the nose, mouth, palate, pharynx, rectum, urethra and vagina

Roger stated that vesicopustules of the mouth and pharynx developed rapidly and ulcerated early Hemorrhagic cases showed hemorrhages in the mouth, pharynx and intestine Pustules were seen also in the larynx, trachea and bronchi, and were often the starting point of a diphtheritic inflammation He noted otitis clinically in 10 of 755 cases, but no material was examined

Stokes described dirty, yellowish, false membranes in the larynx and trachea in two of his five autopsies The epithelium showed granular necrosis without fibrin, with nuclear pyknosis and karyorrhexis The mucosa (epithelium?) was often raised off the submucosa (corium?) by a serofibrinous exudate Accumulation of plasma cells, lymphocytes and epithelioid cells was seen in the submucosa (mucosa?) Large numbers of streptococci were seen in the slough and in the vessels

Perkins and Pay described ulcers in the larynx, trachea (thirty-three cases) and esophagus (five cases) which in early cases resembled skin pocks Later there was an adherent foul green slough

Councilman, Magrath and Brinckerhoff described lesions of the soft palate, pharynx, larynx, trachea, cornea (once) stomach (once) and urethra (twice) In these there was first exudation separating the epithelial cells, then hyaline fibrinoid degeneration (cf Councilman's description of the lesions of the skin) with rounding up and separation of the basal cells, singly or in masses In this process, the degenerate cells became hyaline and refractile, reacting to Weigert's fibrin stain Superficial exfoliation followed with resulting denudation of the connective tissue and without formation of vesicles The connective tissues showed edema, fibrinous exudate and infiltration with polymorphonuclear leukocytes superficially, and deeper with large basophil cells Some vesicles were formed by total elevation of the epithelium by subepithelial exudation A variable amount of necrosis of the mucous glands was present The denuded surfaces showed great masses of streptococci and often a fibrinous false membrane Cytoplasmic inclusions were seen in the mouth, pharynx and stomach Purpuric cases showed hemorrhages in the stomach In purpura variolosa, Riedel saw hemorrhages in the mucous membranes Heinrichsdorff described the histogenesis of the tracheal lesions in hemorrhagic smallpox (not purpuric) First there appeared necroses in the middle layers of the epithelium, karyorrhexis and invasion by leukocytes ensued, then a breaking down to detritus and leukocytes, often followed by ulceration The underlying connective tissue contained many lymphoid and plasma cells and small patches of hemorrhage and necrosis in disrupted areas The capillaries showed hyaline thickening of their walls, endothelial desquamation and probable intracapillary granular thrombi Sorensen and Sorensen described pharyngeal pocks in three cases These contained the usual purulent exudate, possessed a keratinized roof, showed septums to some extent and were poorly defined below Cell inclusions were seen, part taking nuclear dyes, others staining like keratohyalin Sweitzer and Ikeda and Ikeda reported the presence of hemorrhages in the mucosa of the gastro-intestinal tract in hemorrhagic cases Edema, congestion and hemorrhagic degeneration of the epithelium occurred, leading to necrosis or exfoliation

Vaccinia on the tongue in man has been reported in about twelve cases, according to Zurhelle These have probably been secondary inoculations rather than metastatic lesions Material for histologic examination does not appear to have been available

In animals, vaccinal lesions of the mucous membranes have been studied histologically apparently only in rabbits

Calmette and Guerin produced small vesicopustules in the conjunctiva and nasal mucosa by dusting dried powdered vaccine into these spaces These evolved in from five to six days and cicatrized without crusting Immunity resulted in both instances Histologic examination was not reported In 1917, Camus described grossly typical pustules of the lips, tongue, buccal mucosa, esophagus (once), nasal mucosa, palpebral conjunctiva, margins of the lids and the anogenital mucosae, resulting from intravenous inoculation with vaccine pulp

Levaditi and Nicolau described lingual pustules at eight days after intravenous inoculation In these, the epithelial cells showed swollen vacuolated nuclei, fragmented nucleoli and sometimes total necrosis There was intercellular polymorphonuclear invasion, forming nests of pus cells Watanabe described lesions of the lips, palate and tongue in rabbits These showed intense subepithelial round cell infiltration, distinct swelling of the epithelial cells and areas of elevation of the epithelial layer and vacuole formation, vesiculation, pustulation and ulceration followed rapidly, being completed by the sixth or the seventh day Gordon, instilling calf lymph into the conjunctivae and nostrils of rabbits, produced a transient conjunctivitis and, nasally, a catarrhal, later purulent rhinitis lasting from the seventh to the tenth day Immunity was conferred by each of these routes Lesions of the lips, nose, tongue and palate were produced in rabbits by Douglas, Smith and Price using Levaditi's neurovaccine by various routes of inoculation These were not described histologically

Bijl and Frenkel saw ulcers in the esophagus and on the tongue The epithelium was replaced by "protoplasm" and a mass of nuclear débris, the underlying tissues being infiltrated with leukocytes and proliferating fibroblasts Toward the margin were seen successively epithelial cells with pyknotic nuclei and highly vacuolated cells containing inclusions stained by hemalum, apparently nuclear fragments The surface was covered by fibrin, degenerated leukocytes and bacteria The turbinates were engorged, showing necrosis and necrobiosis of the interstitial tissue and proliferation and necrosis of the epithelium, both diffusely rather than focally Ledingham and Barratt noted conjunctivitis and pocks on the lips, nose, eyelids, mouth and tongue, but gave no histologic details of these lesions They also used neurovaccine in rabbits

Armstrong and I described focal lesions of the turbinate, inner ear, tongue, small and large intestine, trachea and larynx The material resulted from Armstrong's studies on effects of the heat resistant vaccine virus developed by him The usual lesion of the turbinate was a focal necrosis showing a sharply defined area of nuclear and cellular debris without marginal reaction in the subepithelial tissue and coagulation necrosis of the epithelium over the center These necroses sometimes involved the bone and occasionally resulted in complete gangrene of the turbinate Intra-epithelial, fibrin filled vesicles occurred a few times and contained inclusion bodies in their lateral margins and roofs The lingual and laryngeal lesions showed marked thickening of the epithelium, centrally coagulation necrosis of the basal cells or even of the entire epithelium, lateral to and above the necrotic cells swollen epithelial cells with perinuclear vacuolation and later multilocular spaces containing greater or less numbers of polymorphonuclear leukocytes Some lesions of these stratified epithelial mucosae showed separation and rounding up of the basal cells, and the formation of fibrin filled spaces, which sometimes contained multinuclear epithelial giant cells lying free in the space Some areas of total coagulation necrosis of such epithelia were seen and in some instances ulcers bounded by necrotic or vacuolated cells occurred The underlying connective tissue sometimes showed infiltration with lymphocytes and plasma cells, but more often necrosis, with or without polymorphonuclear infiltration The lesion of the inner ear consisted of focal coagulation necrosis of all structures in an animal that had shown severe antemortem vestibular symptoms The tracheal lesions showed first epithelial thickening, perinuclear vacuolation in the middle layers, becoming more extensive later, then coagulation necrosis of the entire epithelium The underlying connective tissue showed fibrinous necrosis, often down to the cartilage, usually without marginal reaction Epithelial necrosis with or without vacuolation, cell inclusions and stroma necrosis was seen in the few intestinal lesions

EYE AND LACRIMAL GLAND

Adler saw early conjunctival pustules, and late in the disease a pustular keratitis He doubted the existence of true corneal pocks Hebra saw no corneal pocks Roger, on the other hand, saw frequent severe conjunctivitis and invasion of the cornea, with opacities and perforations, but gave no histologic details

Councilman and his co-workers saw a corneal pyogenic ulcer once in their fifty-four autopsies on persons who died of smallpox

The rabbit cornea has been much studied after variolation and vaccination chiefly in connection with the study of cell inclusions and

in the application of the Paul test for variola As I have excluded any extensive discussion of cell inclusions from this review because the subject has been so recently covered by Goodpasture, only those papers treating more particularly the histologic changes will be covered

According to Councilman, the gross changes in the cornea after variolation were first studied by Straus, Chambon and Menard Guarnieri and Monti, and following them numerous others used the rabbit cornea in the study of the so-called Guarnieri bodies Tyzzer described the histologic changes following corneal vaccination After scarification, a thinned layer of epithelium covered the wound in twenty-four hours Epithelial proliferation and cell swelling followed, increasing the thickness to four or five times the normal Cell vacuolation was noted on the ninth and eleventh days, but no typical vesicles were formed The inclusion bodies were seen first after sixteen hours, they became most numerous on the second and third days and thereafter decreased in numbers Paul, in his original communication on the "Paul test," found a close correspondence of the appearance of the variolated rabbit cornea with Weigert's description of the lesions of the skin in smallpox There was primary epithelial necrobiosis followed by Unna's ballooning degeneration and reticulating colliquation Later, small cell infiltration and purulent liquefaction of the pock tissue became apparent According to Ungermann and Zuelzer, similar changes occur in the variolated guinea-pig cornea These authors described in detail the changes in the rabbit following corneal variolation and vaccination In the first twenty-four hours, cellular edema, vacuolation and swelling appeared, even with separation and rounding up of the basal cells Then numerous mitoses appeared and marked thickening of the epithelium developed During the second day, necrosis and desquamation of the central swollen cells led to the formation of a crater In the process of necrosis, the cells rounded up and shrank into dense hyalinized spherules without nuclear staining Such cells were sometimes engulfed by other epithelial cells, forming the so-called "Schachtelzellen," or "box cells" Giant epithelial cells with multiple heavily stained or pyknotic nuclei in heavily stained cytoplasm appeared within a few hours after inoculation Leukocyte infiltration of the corneal lamellae appeared after the second day Marginal epithelial proliferation obliterated the epithelial defect in from six to seven days The cell inclusions were discussed at length

Scott and Simon studied the rabbit cornea about forty-eight hours after variolation They described swelling and hydropic changes of the epithelial cells, central desquamation, "Schachtelzellen" and Guarnieri bodies, but described no ballooning or reticulating colliquation Douglas Smith and Price observed conjunctival pocks twice following intravenous inoculation

Armstrong and I described metastatic corneal and conjunctival lesions seen between the seventh and fifteenth days after vaccination of the skin with his heat selected virus In the corneal lesions there were epithelial proliferation and thickening, perinuclear cleft formation and cytoplasmic vacuolation, intercellular edema and coagulation necrosis, usually of basal cells, followed by central desquamation and polymorphonuclear infiltration of the edematous superficial lamellae of the cornea, and later more extensive infiltration accompanied by an exudation of serum, fibrin and leukocytes in the anterior chamber In the conjunctival lesions, actual vesicular spaces were formed These were traversed by vertical cell cords and showed intercellular edema beneath the lesion and cellular swelling and vacuolation above and laterally Coagulation necrosis of the basal cells and trabeculae, invasion by leukocytes and superficial erosion followed by the tenth day Necrosis of connective tissue, infiltration by polymorphonuclears and swelling of capillary endothelium occurred beneath such lesions Inclusions resembling Guarnieri bodies were seen on the seventh day in both corneal and conjunctival lesions and as late as the eleventh in the corneal lesions

We also examined lacrimal glands in six animals and found no focal lesions

While in cases of smallpox corneal and conjunctival material has been but little studied, it appears probable from the extensive work on variolated and vaccinated corneas, and particularly from our account of metastatic corneal lesions that the corneal ulcerations and opacities, as well as the conjunctivitis of smallpox, have been primarily variolous in nature

LUNGS

Bronchopneumonia has been the most frequent complication of fatal pustular smallpox Joffroy saw it in about half of his sixty cases, Breynaert in about half of seventy autopsies, Chiari (1886, 1893, in thirty-one of thirty-eight cases, Auché in seventeen of forty-five cases and Perkins and Pay in seventeen of forty-five cases Councilman, Magrath and Brinckerhoff saw more or less extensive bronchopneumonia in forty-three cases and lobar pneumonia twice in fifty-four cases Sweitzer and Ikeda stated that bronchopneumonia was the immediate cause of death in their series of cases Hemorrhages in the lungs in purpuric and hemorrhagic cases have been reported by Zuelzer, Ponfick, Councilman and his co-workers and Ikeda Bronchitis of greater or less severity has been noted with great frequency (Joffroy, Breynaert, Auche, Huguenin Roger, Perkins and Pay, Councilman et al, MacCallum and Ikeda) Focal lesions have been described by Ivanowski, Bowen Bosc,

Stokes and Keysselitz and Mayer Pustules have been seen in the bronchi by Joffroy, Breynaert, Roger, Perkins and Pay and Councilman et al

Ivanowski saw in the lower parts of the lung pea-sized red or gray nodules which microscopically showed an alveolar exudate of cells resembling white corpuscles, epithelial cells with cloudy, granular cytoplasm, red corpuscles and a network of fibrous material In some of these alveoli, he saw fine refractile granules insoluble in acetic acid, caustic alkali or ether and staining light blue or dark red with iodine The granules were considered parasitic and the nodules as true foci of smallpox The latter appear to me to have been small bronchopneumonic foci

Joffroy saw pustules infrequently in the primary bronchi and rarely in smaller ones He noted bronchitis of greater or less severity in which there was poor epithelial preservation, with marked congestion, little mucus and slight swelling The pneumonia involved more often the upper posterior parts of the lower lobes and, when unilateral, the right side more frequently than the left The alveolar exudate consisted of many red corpuscles, even late in the disease, few leukocytes, and deformed desquamated epithelial cells, sometimes with a meshwork of fibrin

Breynaert (cited after M Burchardt) saw pustules progressively smaller as the bronchi decreased in caliber The pustules were sometimes umbilicated, more often appearing as small ulcers with overhanging edges Bronchitis extended to the finest bronchioles The pneumonia involved more often the middle parts of the lung, especially on the right In form there were capillary bronchitis, splenization and splenopneumonia, and confluent, discrete and subacute bronchopneumonia Histologic details were not given

Bowen (cited after Chiari) in an 18 days old child dying in the pustular stage noted pneumonia in the right lower lobe, pleurisy on the left and small, sometimes umbilicated nodules in (on?) the lungs, liver and kidneys These were described as between poppy seed and hempseed size Structurally, they showed a central network of necrotic cells surrounded successively by zones of infiltration with broken down nuclei and of "exudation" Cocci occurred in colonies in the vessels, but not in the nodules

Auche described the bronchopneumonia as bilateral, involving more often the lower lobes and the right side Splenopneumonia occurred eight times, pseudolobar pneumonia five times and nodular bronchopneumonia four times In the smaller bronchi there were epithelial swelling, proliferation and desquamation and intense infiltration with cells that Auché characterized apparently synonymously in various parts of the paper as "embryonic" and as round cells Similar cellular infil-

tration was seen in the adventitial coats of the arterioles The intimal and muscular layers of these were normal The bronchial lumen contained chiefly small round cells with small nuclei and much blackish-yellow, granular pigment In the splenopneumonia, the blood vessels were dilated, and the alveolar "endothelial" cells proliferated and desquamated to form the alveolar exudate Areas of red hepatization contained a fibrinous intra-alveolar net, "endothelial" cells, white corpuscles and some red cells In foci of gray hepatization, the alveolar walls were thickened and densely infiltrated by "embryonic cells," their endothelial lining was destroyed and the alveoli were filled by leukocytes and a few large pigment cells Such foci were often surrounded by zones of splenization and sometimes showed central phlegmonous infiltration Blood filled alveoli were seen in hemorrhagic foci The pleura was often infiltrated by leukocytes and occasionally covered by fibrinous exudate Streptococci, staphylococci and pneumococci were seen in sections and recovered culturally in all combinations, and these cocci were considered to be the cause of the pneumonic complications

Huguenin (cited after Councilman) referred the bronchitis, capillary bronchitis and telectasis to the specific action of the virus of smallpox

Roger found that pustules in the trachea and bronchi were often the point of origin of a diphtheritic inflammation

Bosc saw intense congestion, edema, foci of bronchopneumonia and sometimes ecchymosis The pneumonic foci he considered microbial in origin Firm, elastic nodules, from cherry red to dark red, were attributed to the specific action of the virus These showed proliferation of alveolar and bronchial epithelium and of peribronchial and perivascular connective tissue On this process, suppuration supervened, and the epithelial cells degenerated and broke down The nature of these nodules is not clear to me

Stokes described in one case small vesicles dotting the pleura Histologically these showed large lymph spaces filled with serous fluid Fibrinous pleurisy was seen in another case, and bronchopneumonia in three of five In two cases, he found foci of necrosis containing centrally, streptococci and cellular and nuclear debris, bordered by a peripheral zone of proliferated alveolar and endothelial cells, lymphocytes and a few leukocytes

Perkins and Pay found generally congestion and edema, bronchitis, which was purulent in later cases, bronchopneumonia in over one third of the cases and fibrinopurulent pleurisy in three of their forty-five cases Lesions resembling pocks of the skin were seen in the larynx, trachea and bronchi of earlier cases and ulcers and sloughing later

According to Councilman, Magrath and Brinckerhoff, the pneumonic exudate contained many polymorphonuclear leukocytes rare plasma cells, usually little fibrin and commonly streptococci and pneumococci These

cocci were considered the primary cause of the pneumonic reaction One of their cases showed focal necroses with cell inclusions in (the epithelium of?) the primary bronchi

Keysselitz and Mayer found in one case with generalized lesions of the viscera hyperemia of the lung and focal lesions containing free fluid and hemorrhages, but no central necrosis Guarnieri bodies were seen in both the cytoplasm and the nuclei of fixed and desquamated alveolar epithelial cells This finding of Guarnieri bodies is unique in smallpox and is paralleled only by the presence of similar inclusions in the alveolar epithelium in the rabbit in the vaccinal pneumonia described by Armstrong and myself and in the focal pulmonary lesions, as well, described by us and by Bijl and Frenkel

Sorensen and Sorensen described gelatinous pleurisy and hypostatic pneumonia in a case of purpuric smallpox

Ikeda found marked pulmonary edema and hemorrhage, exfoliation of the epithelium of the smaller bronchi and engorgement and free extravasation of blood in the peribronchial tissues

Gaucher noted intense congestion but no consolidation in an infant dying fifteen days after vaccination with calf virus and six days after the appearance of a generalized pustular eruption

Pneumonia has been noted as a complication of postvaccinal encephalitis (Bijl, Turnbull and McIntosh)

Calmette and Guerin, Levaditi and Nicolau and Gordon all practiced intratracheal or intranasal inoculation of rabbits with vaccine virus, producing immunity, but no pulmonary lesions Levaditi and Nicolau found foci of peribronchial mononuclear and especially polymorphonuclear inflammation, alveolar hemorrhages, edema and atelectasis in rabbits inoculated intravenously with their neurovaccine Six years later Douglas, Smith and Price reported almost constant production of pulmonary lesions by intravenous inoculation of rabbits with the same virus These "pocks" in the lung were punctiform hemorrhages, later glistening gray nodules with punctate hemorrhagic centers Microscopically, these foci resembled "in essentials vaccinial skin lesions"

Bijl and Frenkel produced focal lesions in the lungs of rabbits by cutaneous inoculation with a neurovaccine Microscopically, pneumonic foci were seen, in which the alveolar septums were so swollen as to obliterate their capillaries Other foci showed swelling and nuclear fragmentation and pyknosis in the septal cells, both epithelial and endothelial These cells contained inclusions staining like nuclear material Sometimes these focal nodules showed coagulation necrosis or necrobiosis There were rather general hyperemia and desquamation of alveolar epithelium In bronchi and bronchioles there was often a hyperplastic exudative process with swelling and ulceration of the

bronchial epithelium The small vessels exhibited intimal swelling, perivascular infiltration with mononuclear cells showing darkly stained nuclei and broad or narrow cytoplasm, and focal swellings of the arterial musculature in which the cells were separated apparently by inflammatory edema (This appears to be the same as the mucoid degeneration of the arterial musculature in the vaccine virus pneumonia described by us) These authors saw also minute pleural pocks showing thickening or desquamation of the pleural epithelium and subjacent connective tissue, hyalinization and necrosis

Ledingham and Barratt saw discrete and confluent areas of necrosis of alveolar tissue, with hemorrhage, following inoculation of rabbits with a neurotesticular vaccine by various routes Vascular and bronchial walls were involved in the necrotic foci Little evidence of tissue reaction was seen Subpleural hemorrhagic necroses were covered by lens-shaped areas of pleural epithelial hyperplasia Another group of animals showed marked proliferation of the "reticulo-endothelial tissue" about the bronchi and vessels and polymorphonuclear infiltration of the focal necroses

Armstrong and I (1929 and 1930) reported on serofibrinous pneumonia produced by intranasal and intratracheal inoculation of rabbits and on focal pulmonary, pleural, bronchial and vascular lesions produced by the use of other routes of inoculation We used Armstrong's heat resistant vaccine virus After intranasal or intratracheal inoculation, epithelial proliferation in the bronchi appeared as early as twenty-four hours, subepithelial necrosis and epithelial desquamation, necrosis and vesicles following on the second day Focal necroses of alveolar walls and cell inclusions resembling Guarnieri bodies in lesions and in intact bronchial and alveolar epithelia appeared also in forty-eight hours Gross and microscopic serous alveolar exudation appeared on the second or the third day, and was followed by deposition of fibrin and consolidation on the third or the fourth day At this time, arterial and venous adventitial edema and necrosis appeared, the arterial musculature became greatly swollen, and this was accompanied by intercellular and intracellular formation of large mucin-filled vacuoles (cf the "inflammatory oedema" of the muscle noted by Bijl and Frenkel) As the disease progressed, more lobes became involved, first centrally, then throughout, coagulation necrosis and diphtheritic inflammation of the bronchi became more extensive, and necrosis of alveolar walls increased Death ensued usually in from three to five days, only four of some fifty animals surviving to the sixth, seventh and eighth days Rapid passage by intratracheal inoculation with raw lung virus produced purulent bronchopneumonia superimposed on the serofibrinous type, but repurification by centrifugation and glycerinization and storage gave a virus that again produced the purely serofibrinous type About half

the animals inoculated by other routes showed various focal lesions of the lungs, such as smaller or larger foci of serofibrinous pneumonia, bronchial necroses or vesicles and focal necroses of alveolar walls Serofibrinous pleurisy with or without foci of swollen vacuolated mesothelium occurred in both the pneumonia and the focal lesions

With the experimental evidence adduced during the past year, particularly the production of a pneumonic process comparable in the lack of leukocytes to the early lesions of the skin in variola, it appears probable that the bronchopneumonia of variola is primarily due to the action of the virus of smallpox, and not primarily to the action of the invading micro-organisms It is also probable that the latter modify the character of the reaction, the participation of the polymorphonuclear leukocyte in particular being attributable to these cocci

The perivascular reactions, varying from the proliferative and mononuclear infiltrative type seen by McIntosh and Scarff in vaccinia in rabbits, and the round cell infiltration of Auché in variola, to the necrotizing serofibrinous exudation of Armstrong and myself in the vaccinal pneumonia of rabbits, all appear to constitute a lymphangitis of varying intensity

HEART AND GREAT BLOOD VESSELS

In hemorrhagic smallpox, myocardial hemorrhages have been noted by Zuelzer, subendocardial hemorrhages by Ikeda, and lesions of the serous membranes, presumably including the pericardium, by Ponfick, Perkins and Pay, Riedel, Sweitzer and Ikeda, and Ikeda Luksch noted subepicardial hemorrhages in postvaccinal encephalitis

It is not clear whether the focal lesions observed by Douglas, Smith and Price were myocardial lesions or essentially lesions of the serous membrane, probably the latter, since Armstrong and I also saw focal pericardial lesions in experimental vaccinia Vegetative endocarditis has been reported once each by Councilman, Magrath and Brinckerhoff in variola and by us in experimental vaccinia of rabbits, Interstitial myocardial infiltration with "large basophilic cells" was seen four times in the series of Councilman and his co-workers, and lymphocyte infiltration and fibroblast proliferation once in our rabbits with vaccinia Cloudy swelling of heart muscle has been generally observed in variola and also in experimental vaccinia by us More severe degenerative changes, even necrosis, were occasionally seen, but it appears that the necrosis, at least, was associated with streptococcal emboli (Councilman)

No lesions of the great vessels attributable to the action of the virus appear to have been observed either in vaccinia or variola, though these are specifically mentioned only in the studies of Councilman and his co-workers in variola and ours in vaccinia

LIVER

In smallpox, hemorrhages in the parenchyma of the liver have been noted by Wagner and Roger, subcapsular hemorrhages by Keysselitz and Mayer and Ikeda According to Councilman, Quinquaud first observed lobular foci of hepatitis and fatty degeneration of the cells Curschmann saw cloudy swelling of the liver cells and severe fatty degeneration comparable to that of phosphorus poisoning

Weigert first described what he designated as bacterial thrombi in the sinusoids of the liver Stained with hematoxylin, carmine and picric acid, these were hematoxylin staining masses of granular material The surrounding tissue cells were often normal, at other times, they showed karyolysis and complete loss of nuclear staining These microscopic focal necroses did not exceed the size of small tubercles Later, the central bacterial thrombi lost their definition, the cell bodies broke down to masses of debris, forming round, sharply defined patches without nuclei and without marginal reaction In the later stages, the margins were made up of smaller liver cells with more numerous nuclei

Barthelemy noted extensive fatty degeneration in nineteen of twenty-three cases Sireday noted lesions of the interstitial tissue and cloudy swelling of liver cells in early cases, later there was fatty degeneration of all parts of the lobule Bowen described nodules varying in size from that of a poppy seed to that of a hemp seed, partly umbilicated, on the liver, lungs and kidneys In these there was a central network of necrotic cells surrounded by a zone densely infiltrated with fragmented nuclei, and peripherally by a zone of "exudation" The foci contained no bacteria, but coccus colonies occurred in the vessels of these organs

Arnaud (1899) saw varying degrees of fatty infiltration of the liver cells, more marked toward the periportal areas Nuclei were usually preserved Less often there was granular degeneration with vitrification of the cytoplasm and disappearance of the nucleus of the liver cell, whether in isolated cells or in focal areas is not clear There was dense "embryonic" infiltration of the periportal and interlobular connective tissue with small round cells Small round cell infiltration of the walls of the larger blood vessels and endothelial proliferation and swelling in the smaller vessels were noted There were vascular stasis and marked intracapillary leukocytosis including lymphocytes, polymorphonuclears, phagocytes and lymphoid cells in mitosis Roger and Garnier (1901) and Roger described the liver in smallpox with great detail The organ was enlarged, soft, pale yellowish and greasy Periportal round cell infiltration was seen in some cases Capillaries and veins showed dilatation sometimes with endothelial swelling and desquamation In the liver cells the most frequent change was fatty degenera-

tion, usually without loss of nuclear staining, this change was more pronounced in the periportal regions Also there were foci of a few swollen cells with broad clear cytoplasm and poorly stained nuclei In some cases there were foci of necrosis and "vitreous degeneration" in which there were shrunken cells with poorly stained nuclei or none at all Such foci lay in the midst of well preserved liver tissue They were often invaded by leukocytes, and not infrequently central caseation had occurred Some cases showed complete disassociation of the liver cell cords, leaving free, rounded cells

Bosc described fatty degeneration in what appears to have been a cirrhotic liver, ascribing all the changes to smallpox Stokes saw cloudy swelling in all cases In one there were focal necroses containing, centrally, nuclear debris and homogeneous eosinophilic material, and marginally, coalescing liver cells with fragmented nuclei The focal lesions contained no streptococci, though these were numerous elsewhere in the capillaries Perkins and Pay saw central passive congestion and peripheral fatty degeneration of the lobules in twenty-three of their forty-five cases

Councilman, Magrath and Brinckerhoff found regularly a great increase in the weight of the liver, general swelling and increased granularity of the liver cells In seven cases, the liver cell cords were disassociated into separated cells lying free in the stroma In six there were foci of small eosinophilic necrotic liver cells without nuclei, with dilated capillary spaces, and in four with invasion by polymorphonuclear leukocytes In three autopsies they observed scattered, isolated necrotic liver cells In other cases there were nuclei with centrally clumped, more or less oxyphil chromatin and swollen karyolytic nuclei, with or without cytoplasmic degeneration The capillaries often contained pyogenic cocci and, late in the disease, numerous "large basophile cells" In five cases, refractile, hyaline, eosinophil bodies were seen lying in vacuoles in the liver cells, more often nearer the centers of the lobules

Keysselitz and Mayer described focal lesions of variable size in the liver in two of their three cases The larger ones involved several lobules, the smaller occurred in all parts of the lobules In them were clear fluid with or without red corpuscles, a few polymorphonuclears and rare eosinophils and mononuclears, and nonnucleate masses arising from liver cells, gradually merging into opaque coagulated masses and granular debris Peripheral to these areas of necrosis were necrobiotic liver cells with swollen clear nuclei, patches of intercellular edema and dilated capillaries Cell inclusions ranging from eight microns down in size and staining like nucleolar material occurred chiefly in the cytoplasm of liver cells, but also in their nuclei, which sometimes contained at the same time an intact nucleolus

MacCallum described marked enlargement, intense cloudy swelling and occasionally focal necroses in the liver Ikeda described slight cloudy swelling of the liver in purpura variolosa There were numerous wandering mononuclears (which are marked "lymphocytes" in his illustration) between the liver cell cords and in the periportal spaces

In fatal generalized vaccinia in an infant, Gaucher saw flecking of the liver by foci of fatty degeneration The infant died on the sixth day of a generalized pustular eruption and fifteen after vaccination with calf virus Turnbull and McIntosh saw congestion and parenchymatous degeneration of the liver in their cases of postvaccinal encephalitis In one case there were focal necroses, which were unfortunately not studied histologically

In experimental vaccinia of rabbits, small inflammatory foci containing degenerated polymorphonuclear leukocytes were observed by Levaditi and Nicolau Douglas, Smith and Price saw focal lesions of the liver in about two thirds of their animals, omitting those which had received the rapidly fatal intracerebral inoculations The lesions in the livers were examined for them by Turnbull and were said to resemble "in essentials vaccinial skin lesions" After noting the extreme pleomorphism of the cutaneous lesions produced in rabbits by a virulent vaccine virus, I find it rather difficult to imagine the appearance of such lesions within a parenchymatous organ I strongly suspect that most of the lesions attributed by these workers to the viscera were in fact lesions of the serous membrane on their surfaces

Bijl and Frenkel described diffuse endothelial proliferation and increased numbers of various leukocytes in the capillaries of the liver, reminding them of a leukopoietic process The cell types were insufficiently described or named to permit identification of the process Necrosis was present under the capsular lesions, which will be discussed under peritoneum

Ledingham and Barratt saw multiple focal necroses of liver cells, usually with initial hemorrhage These foci were rapidly replaced by bile duct proliferation in rabbits from nine to twelve days after inoculation Fibrosing granulomas were interpreted as probably coccidial in origin, an interpretation in which I concur

Armstrong and I found focal necroses in 54 of 124 rabbits inoculated by various routes with his heat selected vaccine virus The incidence of these was much higher when the rapidly fatal intracerebral and respiratory infections were eliminated The size of the lesions varied from those involving isolated cells to those involving two or three lobules There were first increased cytoplasmic oxyphilia and pyknosis or karyolysis, then swelling and vacuolation of the liver cells, disappearance or fragmentation of their nuclei, occlusion of the capillaries by the swollen

cells and fine fibrin thrombi In apparently later lesions, the liver cells were shrunken, often broken down to granular débris and free fat, and sometimes infiltrated with leukocytes Calcification was seen in some late lesions and in others marginal endothelial proliferation, gradually changing into nodules of epithelioid cells The bile duct proliferation noted by Ledingham and Barratt was seen in this material, too, and was attributed rather to the common proliferative chronic cholangeitis often seen in rabbits

The focal necroses described by Weigert, Bowen, Stokes, Councilman and his co-workers and Keysselitz and Mayer, the foci of "vitreous degeneration" of Arnaud, the vitreous degeneration and necrosis of Roger and Garner in smallpox and the focal necroses seen by Ledingham and Barratt and by us in vaccinia in rabbits appear to represent essentially the same process That the lesions seen by Turnbull and McIntosh in postvaccinal encephalitis and by Douglas and his co-workers in vaccinia in rabbits are similar seems probable The hematoxylin-staining granular masses interpreted by Weigert as bacterial thrombi lying in the centers of the focal lesions have not been seen since in either variola or experimental vaccinia I am somewhat inclined to doubt their bacterial nature

PANCREAS

This organ was specifically mentioned only by Stokes, Perkins and Pay and Councilman, Magrath and Brinckerhoff in reports on variola and by us in reports on experimental vaccinia No lesions attributable to the virus were found by any of these writers

PERITONEUM

In hemorrhagic and purpuric smallpox, peritoneal hemorrhages have been described frequently by Zuelzer, Councilman and his co-workers, Riedel, Sweitzer and Ikeda and Ikeda According to Chiari, pustules, in part umbilicated, were seen by Gosselin on the tunica vaginalis testis. This observation appears to be unique in variola Local peritonitis was seen in one of Turnbull and McIntosh's cases of postvaccinal encephalitis with ulceration of the bladder

In rabbits, Ledingham produced subperitoneal nodules with small central necroses, using intrasplenic and intraperitoneal inoculations of fresh calf virus The central necroses were surrounded by "adventitia cell" proliferation like that in the lesions of the skin Douglas, Smith and Price, using a neurovaccine, produced frequent peritoneal lesions by intraperitoneal and intratesticular inoculation, rarely by other routes There was a clear, yellow, gelatinous exudate with small white or hemorrhagic peritoneal spots on the surfaces of the organs, which microscopically resembled "pocks in the earliest stages"

Bijl and Frenkel saw in several of their vaccinated rabbits rounded, white, often umbilicated lesions on the capsules of the spleen and liver These showed capsular thickening, swelling and hyalinization of the fibers just beneath the surface and necrosis with nuclear debris beneath (or among? "unter") these

Ledingham and Barratt saw gray papules on the intestine in one rabbit These showed necrosis in the serosa and great hyperplasia and numerous mitoses in the serous endothelium Similar lesions were seen on the surfaces of the uterus and ovary Neurovaccine was used

We described two types of serosal lesions produced by the heat selected vaccine virus The first was focal necrosis of the serosal connective tissues This was sharply defined, containing cellular and nuclear débris centrally, without marginal reaction In the second type, the mesothelium was thickened, its cells separated by serofibrinous exudate, forming simple or septate vesicular spaces Coagulation necrosis of some of the mesothelial cells was seen, usually below the surface layer Necrosis and less often infiltration by leukocytes and proliferation of fibroblasts were seen in the underlying connective tissue

While a part of the peritoneal lesions seen by these workers were undoubtedly due to direct peritoneal contamination, others were just as surely metastatic Gosselin's pocks were probably of the same nature as the experimental lesions Further study of the latter is needed, as Armstrong and I who had the largest experimental material, studied only six cases with the vesicle-like lesions

SPLEEN

Wagner noted splenic infarcts in hemorrhagic smallpox Zuelzer and Ponfick did not see splenic enlargement in hemorrhagic cases, Golgi found the spleen small, dark and hard, while Birch-Hirschfeld described enlargement Roger stated that the spleen was less often enlarged than in pustular cases Arnaud (1899) noted no significant difference in splenic size between hemorrhagic and pustular smallpox He saw enlargement of the malpighian corpuscles and hemorrhages in the pulp Such hemorrhages were reported in hemorrhagic smallpox also by Perkins and Pay and by Councilman, Magrath and Brinckerhoff Riedel stated that the spleen was small

Weigert found focal necroses with central bacterial masses As the necrosis advanced to the stage of central debris without nuclei, the central masses of bacteria disappeared In pustular smallpox, Arnaud (1898b) saw frequent enlargement of the splenic corpuscles and multiplication of their cells Congestion of the pulp was common, foci of mononuclear and lobate leukocytes were seen, and there were moderate numbers of large mononuclear cells a few large swollen cells occa-

sionally containing red cells, and numerous small lymphocytes, these last filling the pulp spaces and infiltrating the splenic connective tissue and blood vessel sheaths Roger described splenic enlargement in pustular cases The pulp contained a few megakaryocytes and plasma cells, and numerous mononuclear, nongranular and neutrophil cells Stokes saw no significant changes The spleen was enlarged in about half the cases described by Perkins and Pay The splenic corpuscles were generally enlarged The pulp contained numbers of phagocytic cells including red cells and nuclear débris Three of their pustular cases showed hemorrhages in the pulp

Councilman, Magrath and Brinckerhoff stressed the paucity of polymorphonuclear leukocytes before the stage of desquamation and emphasized the prominence of proliferating large basophil cells, in both follicles and pulp The reticulum contained many large phagocytic cells including nuclear débris from lymphocytes Some of these cells showed inclusion bodies Pulp hemorrhages were frequent, and fibrin deposition in pulp spaces and sinuses occurred In late cases, pigment was present in considerable amounts Keysselitz and Mayer found focal lesions in the spleen like those described by Weigert They also described numerous intranuclear inclusion bodies in vascular endothelial nuclei, which showed peripheral chromatin condensation and clear centers

In their cases of postvaccinal encephalitis, Turnbull and McIntosh described inflammation of the spleen Four cases showed increase of polymorphonuclears and five increase of basophil mononuclears Early central necrosis of the splenic corpuscles was seen in one case

In experimental vaccinia of rabbits, no lesions were seen by Levaditi and Nicolau Douglas, Smith and Price frequently saw white spots on the surface of the spleen which were later slightly sunken and showed a grayish translucent zone Though no specific histologic description was given, these would appear to have been peritoneal or capsular lesions rather than lesions of the splenic parenchyma Bijl and Frenkel saw no parenchymatous focal lesions They described capsular lesions which I have discussed under peritoneal lesions They described hyperemia of the pulp hypertrophic changes in the follicular reticuloendothelium, sometimes with nuclear fragmentation, and much nuclear detritus and hemosiderin in the pulp Isolated focal necroses in the splenic pulp of the rabbit were first described by Ledingham and Barratt, who saw them in one case only Such lesions were found by us in 6 of 113 rabbits In these, the cells were strongly oxyphil, with karyorrhexis, pyknosis or karyolysis and later caseous debris Hemorrhage and deposition of fibrin were each sometimes seen within and in the margins of the lesions The marginal reticulum cells sometimes showed nuclear swelling and karyolysis no other marginal reaction was

evident We also noted small hyaline thrombi in the splenic pulp Leukocytosis, follicular hyperplasia, hyperemia, hemosiderosis and much nuclear débris in phagocytes were noted in many animals, but only in a minority in each instance

Summarizing, one finds that there has been much disagreement as to the size of the spleen, diffuse cellular changes and follicular hypertrophy, and it appears probable that these changes have been dependent in large measure on factors other than the virus of variola and vaccinia The cell inclusions described by Councilman and his co-workers and Keysselitz and Mayer may be specific, but this appears dubious to me The focal necroses described by Weigert and Keysselitz and Mayer in variola and by Ledingham and Bariatt and by Armstrong and me in experimental vaccinia appear to be specific and due to the virus

BONE-MARROW

Golgi first examined the bone-marrow in smallpox, noting a predominance of red corpuscles in the hemorrhagic forms and of white corpuscles in the pustular cases Osteomyelitis variolosa was first described by Chiari (1893) and further studied by Mallory (1894) while working in Chiari's laboratory In this there were yellowish focal lesions of the size of a split pea or less, with a red areola The foci were composed of large epithelium-like marrow cells with pale nuclei and fat droplets in their broad cytoplasm In the prepustular stage, central necrosis and peripheral fibrin and edema appeared Later, necrosis involved most of the "epithelioid" cells and also the bone cells of any included bone trabeculae No appreciable emigration of or infiltration with leukocytes occurred Such lesions occurred in twenty of Chiari's twenty-four cases, Mallory on more extended search found them regularly

No focal lesions were seen by Roger Nongranular, eosinophil and neutrophil cells predominated, polymorphonuclears, plasma cells and megakaryocytes were rare Infants with bronchopneumonia showed hyperplasia corresponding to the leukocytosis Muir saw almost complete absence of polymorphonuclear leukocytes, reduction in myelocytes and vascular dilatation in the rib marrow Chiari's osteomyelitis variolosa was not found

Councilman, Magrath and Brinckerhoff saw focal necroses of variable size, often hemorrhagic, and without marginal reaction Hemorrhagic and other early cases showed extensive diffuse and focal degeneration Exudation of fibrin occurred in and near areas of hemorrhage and necrosis and elsewhere Large phagocytic cells were seen including other cells and absorbing fat In general there was a great reduction in polymorphonuclear leukocytes and an increase in lymphoid and plasma

cells Keysselitz and Mayer saw, but did not specifically describe focal lesions in the bone-marrow Batzdorfft described a suppurative osteomyelitis in material removed surgically seven weeks after variola Musgrave, Sison and Crowell described histologically healed lesions in the bones of a patient who had had smallpox in childhood They also studied in living patients, bony deformities, which they attributed to past smallpox Brown and Brown found metastatic pyogenic osteomyelitis the most commonly reported variety in the literature On x-ray and clinical evidence, they believed Chiari's osteomyelitis variolosa to have been the cause of bony deformities in their two cases

MacCallum described nodules showing central necrosis of marrow cells and marginal infiltration by mononuclears Formation of polymorphonuclear leukocytes was suppressed and many degenerate leukocytes were seen

Sweitzer and Ikeda saw red marrow in the femur frequently in purpura variolosa, and Ikeda described hemorrhages with islets of normoblasts and a few myeloid cells

Soltmann reported what he designated as "osteomyelitis ichorrhamica" in a child dying thirteen days after vaccination and three days after the onset of symptoms Limited autopsy showed necrosis of the anterior surface of the femur, with edema and yellowish muscles above it The marrow cavity was not opened The etiology was considered uncertain

In experimental vaccinia in rabbits, Levaditi and Nicolau saw no lesions of the bone-marrow Bijl and Frenkel saw marked proliferation of myelocytes, hyperemia, a diffuse fibrin network and scattered small regressive changes, which were not further characterized We saw focal necroses of the bone-marrow of the femur or diploe in five of twenty-six rabbits These showed, centrally, fragmented cells and nuclei surrounded by a zone of empty reticulum, or central caseous necrosis surrounded by fat-containing, coagulated, granular myelocytes with karyolyzed or pyknotic nuclei Exudation of fibrin and hemorrhage occurred in such lesions, and fibrin was seen in patches where scattered cells showed fragmented or pyknotic nuclei Direct intramedullary inoculation produced similar, but larger areas of coagulation necrosis Bone lying in foci of necrosis showed necrotic bone cells

To date, the osteomyelitis variolosa of Chiari has been studied histologically by Chiari, Mallory, Councilman and his co-workers, Keysselitz and Mayer and MacCallum in variola and by us in experimental vaccinia Probably the report of Bijl and Frenkel could be included, but the description is not clear This osteomyelitis appears to be a specific effect of the virus The suppression of polymorphonuclear leukopoiesis seems to have been quite generally observed, though we saw

an increased number of polymorphonuclears in ten of twenty-six animals in experimental vaccinia

LYMPH GLANDS

Wagner saw hypertrophy and hyperemia of the lymph nodes Weigert described his bacterial thrombi in the follicles and peripheral sinuses of lymph nodes, and apparently included these organs in his description of focal necroses, which applied more specifically to the liver, spleen and kidney Roger described frequent enlargement of the lymph nodes in smallpox The pulp cords showed neutrophil, basophil and sometimes eosinophil myelocytes, giant cells of undescribed type and, in hemorrhagic cases, nucleated red cells as well Similar active myelopoiesis occurred in the periglandular tissue These most interesting changes Roger had not seen except in variola, and unfortunately he does not state in how many cases these changes occurred They have never been confirmed

Stokes found extensive focal necroses in the bronchial and cervical lymph nodes, usually subcapsular and often containing large masses of streptococci Councilman, Magrath and Brinckerhoff observed edema, dilatation of the peripheral sinuses, multiplication of large basophil cells by mitosis, these often taking on the characteristics of Unna's plasma cells, and evident proliferation of sinus endothelia to form large free phagocytic cells containing cells, debris and masses of fibrin There were frequent degeneration and necrosis of small cells (whether focally or diffusely is not stated) Mononuclear eosinophils were frequent, polymorphonuclear eosinophils less so In late stages, polymorphonuclear leukocytes became numerous Cocci were frequent in some cases MacCallum saw many large phagocytic cells in the lymph sinuses, also abundant smaller mononuclear cells Sweitzer and Ikeda described inconstant adenopathy, intense hyperemia and diffuse hyperplasia of the lymphoid cells

According to Turnbull and McIntosh, the axillary lymph glands draining the area of the vaccination in postvaccinal encephalitis were enlarged and congested, showing free blood in the sinuses in three, and hemorrhages in two of the seven cases There was some eosinophil infiltration

In experimental vaccinia Bijl and Frenkel saw swelling and degeneration of the sometimes phagocytic reticulo-endothelium of the peripheral and medullary sinuses and germinal centers There were scattered small necroses and hemorrhages Armstrong and I (1929 and 1930) saw in the mediastinal glands in pneumonic cases and in axillary glands after cutaneous inoculation with the heat selected vaccine virus first, edema and exudation of fibrin in the sinuses, then

coagulation necrosis, first of the peripheral sinuses, later of the entire gland Such necroses were often hemorrhagic

In general, the lymphadenitis of variola and vaccinia shows a mononuclear cell response With some strains of virus, hemorrhage and necrosis overshadow and obliterate the reaction Such strains are those which show the greatest necrotizing tendencies in the skin and other organs

THYMUS

Focal lesions of the thymus have been noted only by Armstrong and me, in a rabbit inoculated cutaneously with the heat selected vaccine virus The lesions were multiple focal hemorrhages and areas of necrosis in which the reticulum cells appeared to survive, and the lymphocytes were replaced by nuclear debris and fibrin No marginal reaction occurred

SUPRARENAL GLANDS

Oppenheim and Loeper first described the occurrence in the suprarenal gland in smallpox, of foci of infiltration with lymphocytes and fewer plasma cells, most often in the medulla, about the sheaths of the central veins and also sometimes in the capsule There was also rarely congestion, with hemorrhage and "cellular necrosis in islets" The last observation was, unfortunately, not more closely described Stokes saw no significant changes Perkins and Pay found cystic suprarenal glands in six of forty-five cases and noted frequent fatty degeneration of the medulla

Councilman, Magrath and Brinckerhoff saw foci of necrosis in some cases, and more or less degeneration in more The foci showed increasingly oxyphil, vacuolated cytoplasm with droplets of hyaline material and karyolysis, in some instances with cytoplasmic disintegration There were also small foci of infiltration with large basophil cells, chiefly in the medulla

In experimental vaccinia, Levaditi and Nicolau described the suprarenal glands of their rabbits as "en apparence non lése" Douglas, Smith and Price saw in twenty rabbits focal lesions which they described as "pocks" or as resembling small accessory suprarenal glands Possibly they referred to peritoneal lesions overlying the suprarenal glands, certainly, these were not the same as the lesions described by Bijl and Frenkel, Ledingham and Barratt and us Bijl and Frenkel described focal coagulation necroses containing, centrally, an eosinophil mass with nuclear fragments, and peripherally, necrobiotic epithelial cells and much nuclear débris, which was presumed to originate, at least in part, from leukocytes "Corpuscular elements" were seen in the cytoplasm of cells in the marginal zone Around this was a zone of capillary endothelial proliferation and probably some leukocyte infil-

tration, with some cells resembling nucleated red cells, which the authors would derive from the capillary endothelia Beginning calcification was noted in the necrotic centers Capsular lesions of the same type as seen on the liver and spleen were noted, these I have discussed under peritoneum Whether the cytoplasmic "corpuscular elements" referred to were inclusion bodies in the sense of Guarnieri bodies is not certain from the text

Ledingham and Barratt found cortical focal necroses almost constantly These were hemorrhagic in the earlier stages, and later showed a marginal "reticulo-endothelial" reaction consisting of plasmacytoid adventitial cells Polymorphonuclear invasion of the necroses was seen in one rabbit We saw frequent focal necroses, usually after the fourth day First there were swelling, increased vacuolation and loss of lipoid and cytoplasmic oxyphilia in the cortical cells Soon afterward pyknosis, karyorrhexis or karyolysis, and the intercellular deposition of a fibrin net appeared, followed by a central breaking down to caseous débris, a marginal zone of swelling of cells and vacuolation still remained in some instances Marginal or central hemorrhage was frequent In some late lesions there was central calcification, in others, moderate invasion by polymorphonuclears, in others, marginal proliferation of fibroblasts proceeding to the formation of small granulomatoid foci, in still others there was marginally active multiplication of small, otherwise typical cortical cells, sometimes mixed with lymphocytes Such lesions were found in 62 of 118 animals There were also occasional areas of small round cells in the medulla, the significance of which appeared uncertain

That the foci seen in smallpox by Oppenheim and Loeper and by Councilman and his co-workers are the same as those seen by Bijl and Frenkel, Ledingham and Barratt and Armstrong and myself appears highly probable

KIDNEY

In hemorrhagic smallpox, hemorrhages in the pelvic and ureteral mucosae have been reported by Zuelzer, Ponfick, Unruh, Roger, Perkins and Pay, and Councilman, Magrath and Brinckerhoff, parenchymatous hemorrhages by Roger, and subcapsular hemorrhages by Roger and by Ikeda

Weigert saw his bacterial thrombi in the glomeruli, cortex and medulla, but, as nearly as I can discern, the focal necroses that he described as found in the liver and spleen did not occur in the kidney Bowen described poppy seed to hemp seed sized nodules in the lungs, liver and kidneys in a case of pustular smallpox In these there was a central network of necrotic cells, a margin of nuclear fragments and a peripheral zone of "exudation" Arnaud (1898a,b) described exten-

sive interstitial infiltration with "lymphatic cells" and proliferation of "embryonic" connective tissue, swelling of glomerular capsular epithelium, more or less marked swelling and granular, fatty or reticular degeneration of the convoluted tubules, rarely hyaline degeneration and necrosis, occasionally arteriolar thrombi and in one case exudative glomerulitis Huguenin saw cloudy swelling and frequent glomerular involvements Roger noted a great similarity to the nephritis of scarlet fever Stokes also saw in one case an acute interstitial nephritis like that of scarlet fever, plasma cells and lymphocytes forming the exudate Another case showed hyaline glomerular degeneration, capsular epithelial proliferation and general granular, fibrinoid and fatty degeneration of the tubules Perkins and Pay saw one case of acute interstitial nephritis, the exudate being plasma cells, eosinophils and a few polymorphonuclears More or less extensive chronic nephritis was seen in one fourth of the remaining cases

Councilman, Magrath and Brinckerhoff saw constantly more or less acute degeneration, chiefly in the convoluted tubules, and frequent focal interstitial and intravascular accumulations of lymphoid and large basophil cells Streptococci were frequent, leukocytes were almost absent Acute glomerulonephritis was seen in five cases, and acute suppurative nephritis in two One purpuric case showed a considerable amount of necrosis in the foci of mononuclear cells Keysselitz and Mayer described focal coagulation necroses with central caseation and marginal degeneration and with Guarnieri bodies in the renal epithelium in one case Their other cases showed severe parenchymatous degeneration to the extent of necrosis in parts, but no inclusions MacCallum described degeneration of the tubular epithelium, occasional glomerulonephritis and frequent interstitial infiltration by mononuclear cells

The case reported by Russell and Oddie as postvaccinal encephalitis gave no anatomic evidence of that condition, but did show tubular degeneration with slight deposition of calcium, glomerular swelling and nuclear multiplication, which taken with the pronounced nitrogen retention recorded indicated a nephrosis the connection of which with the preceding vaccination is at least uncertain

No focal lesions of the kidneys of rabbits in experimental vaccinia were reported by Levaditi and Nicolau, Douglas, Smith and Price, Bijl and Frenkel, Ledingham and Barratt or Armstrong and myself We saw more or less severe degenerative changes in the convoluted tubules, albuminous and fibrinoid casts in some and old fibrous scars with tubular atrophy in several, often associated with areas of infiltration by lymphocytes Walthard (1927) inoculated a rabbit intrarenally, producing hyperemia, tubular swelling and patches of infiltration with leukocytes and lymphocytes at the site of inoculation

Focal necroses of the kidney have been reported apparently only in the single cases of Bowen and of Keysselitz and Mayer, hence it is not surprising that they have not been encountered in the experimental disease The most constant feature appears to have been the rather severe tubular degeneration Interstitial infiltration by mononuclear cells has been frequent While Armstrong and I have seen this in rabbits also, in this animal its significance is less clear, owing to the relative lack of familiarity with the histogenesis of the chronic focal scarring often seen in the rabbit

MUSCLES AND FASCIAE

Zuelzer noted hemorrhages in the voluntary muscles and large nerve sheaths in hemorrhagic smallpox Ponfick saw hemorrhages in the connective tissue generally Stokes saw no significant changes in the muscles In experimental vaccinia, Douglas, Smith and Price saw, but did not specifically describe, focal lesions in the voluntary muscles and in the connective tissues In experimental vaccinia of rabbits, Bijl and Frenkel saw coagulation necroses of voluntary muscle with karyorrhexis, loss of striation and calcification Aside from the coagulation necrosis of the platysma, which I have mentioned in consideration of cutaneous vaccinations, Armstrong and I saw granular, waxy and fragmentary degeneration in the voluntary muscles, but encountered no focal lesions Extensive edema and multiple focal hemorrhagic necroses in the deep fascia of the legs occurred once after intravenous inoculation

TESTIS

I am indebted to Chiari for many of the older references in regard to lesions of the testes Pustules on the tunica vaginalis testis, in part umbilicated, were seen by Gosselin Serofibrinous inflammation of the tunica vaginalis was seen frequently by Béraud and Robin Beraud first described multiple yellowish foci in the parenchyma of the testis These lesions varied from the size of a pea to that of a pinhead In these, the tubules were swollen and showed albuminous degeneration Pus cells were lacking In hemorrhagic smallpox, Wagner saw grayish-red, later yellowish, small, new formations in the testicular parenchyma These foci were generally lymphatic Zuelzer, in hemorrhagic smallpox, simply referred to hemorrhages in male and female generative organs Laboulbene noted serofibrinous periorchitis, and in both testes minute hemorrhages and small yellowish-red foci showing central nuclear and cellular albuminous degeneration, surrounded by a zone of purulent infiltration Géraud saw bilateral orchitis following revaccination of two soldiers

Chiari found, chiefly in boys but also in adults dying of smallpox, multiple grayish-yellow nodules in the testicular parenchyma These were pea-sized, sometimes bloodstained, later hard and dry In the earlier stages, these showed focal interstitial swelling, small cell infiltration and necrosis, with well preserved or degenerate but not necrotic tubules included Later, in the stage of exsiccation, the tubules also necrosed, the centers became homogeneous, the peripheral zone of small cell infiltration narrowed, and coagulated exudate appeared in the surrounding interstitial tissue Chiari, in 1886, first suggested the testicle as a source of uncontaminated smallpox virus Roger found lymphocyte and mononuclear exudate in the tunica and intense congestion and infiltration of the interstitial tissue of the testis, but no focal necroses This infiltration consisted of a fibrin net, numerous mononuclears and small hemorrhages Degeneration of the tubules varied between aspermatogenesis and necrosis Stokes saw necroses beginning in the tubular epithelium, accompanied by thickening and later necrosis of the interstitial supporting tissue, including even the arteries Perkins and Pay described focal necroses of the testes in eight of twenty-seven cases In these, the interstitial tissue was infiltrated and the tubules necrotic Bacteria were frequent in the vessels, and streptococcal thrombi were seen in arterioles

Councilman, Magrath and Brinckerhoff saw no focal necroses, but noted numerous foci of infiltration with lymphoid and large basophil cells in the interstitial tissue, often with hyperemia, hemorrhage and a little exudation of fibrin Tubular necrosis and invasion by phagocytes sometimes occurred in larger foci Polymorphonuclear leukocytes were absent More or less tubular degeneration was general MacCallum described nodules, most numerous in the subcapsular zone of the testis In these there were interstitial infiltration by wandering cells and later necrosis and mononuclear invasion of the included tubules Such opaque, yellowish foci often showed hemorrhagic haloes On healing small scars resulted Mallory (1925) saw focal necroses surrounded by a moderate to well marked inflammatory reaction Suppuration did not supervene

Tyzzer inoculated rabbits intratesticularly with calf virus, producing an acute inflammatory reaction which he regarded as nonspecific Henseval and Convent similarly produced testicular swelling and demonstrated vaccine virus in the testes Paschen (p 483) saw necrosis and cellular infiltration after intratesticular vaccination of rabbits

Von Prowazek and Miyaji produced local necrosis at the site of inoculation into the testis Noguchi saw multiple foci of interstitial polymorphonuclear infiltration appearing in twenty-four hours after intratesticular vaccination, followed by marked congestion, edema, enor-

mous interstitial infiltration by leukocytes and tubular hydropic degeneration increasing from the second to the fourth days and resulting in patches of tubular necrosis on the fourth day and breaking down of both tubules and leukocytes on the fifth day Recession began on the sixth day, edema decreased, and foci of small round cells and fibrinous masses appeared, resolution proceeding to atrophy and fibrosis thereafter

Levaditi and Nicolau first reported metastatic testicular "pustules" in the rabbit after intravenous vaccination There were focal interstitial swelling, vacuolation and necrosis, going on to central caseous débris surrounded by a zone of many polymorphonuclears and few mononuclears The included tubules were "altered," but less severely than the interstitial tissues

Douglas, Smith and Price saw focal lesions of the testes, but gave no specific description of them Bijl and Frenkel described swelling, degeneration and necrosis of the interstitial cells in the testis and degeneration of the tubules Albugineal vaccinal lesions also occurred

We saw following intratesticular inoculation severe hemorrhagic interstitial orchitis, with diffuse or focal, dense polymorphonuclear infiltration, or hemorrhagic necrosis and edema, more extensive in the interstitial tissue, but including surviving or necrotic tubules Cutaneous and intravenous inoculations produced sharply defined focal coagulation necroses of the interstitial tissue These were of varying size and contained fibrin, oxyphil débris, nuclear fragments and sometimes blood, including in the larger foci surviving or necrotic tubules and abutting marginally directly on apparently normal surviving tissue

The variation of the focal lesions reported in the literature between infiltration, usually by mononuclear cells, and secondary pressure necrosis of the tubules, on one hand, and the frank focal necroses of the interstitial tissue preceding tubular degeneration and necrosis, on the other hand, appears to be simply a further manifestation of the variation in necrotizing power of the virus of variola and vaccinia

OVARY, UTERUS AND TUBES

In hemorrhagic smallpox, Zuelzer saw hemorrhages in the female generative organs Ponfick saw hemorrhages in the mucous surfaces of uterus, vagina and tubes, in the parametrium and in the substance of the ovaries Roger noted an ovarian infarct Ikeda noted uterine hemorrhages in purpuric cases

Béraud and Robin described hyperemia and surface exudation on the ovaries In pustular smallpox Perkins and Pay saw a hemorrhage in the stroma of the ovary Councilman Magrath and Brinckerhoff described ovarian focal infiltrations by large basophil cells and phago-

cytes in two cases There were scattered single necrotic cells and some polymorphonuclear leukocytes

Though the frequency of abortion during smallpox is a matter of common knowledge, decidual lesions appear never to have been studied either grossly or histologically Consequently, experimental material bearing on this point assumes unusual interest

Swelling, vacuolation and necrosis of the interstitial cells of the ovary in generalized vaccinia were reported by Levaditi and Nicolau Polymorphonuclear invasion followed, but corpora lutea, graafian follicles and ova were not involved in their rabbits Douglas, Smith and Price reported focal vaccinal lesions of the ovaries and uterus Often the ovarian lesions could be differentiated from graafian follicles only by means of the microscope The uterine lesions were small white spots or, often, protuberant umbilicated pocks on the peritoneal surface Three pregnant animals showed necrotic débris replacing the fetuses, large, protuberant endometrial pocks and hemorrhagic peritoneal pocks Histologically, the various lesions showed "typical necrosis with the usual peripheral cellular infiltration" Bijl and Frenkel saw diffuse and focal swelling and degeneration in the interstitial tissue of the ovary, leading to necrosis Graafian follicles and their epithelium also took part in the necrosis Few polymorphonuclear leukocytes were seen Calcification appeared in later lesions Ledingham and Barratt described hemorrhagic necroses without evidence of repair in the ovarian interstitial tissue Polymorphonuclear leukocytes were lacking in early cases, but in some of the later ones they were present in vast numbers, in both ovarian and uterine focal necroses

We described focal necroses of the endometrium in seventeen of thirty-six nonpregnant rabbits The epithelial cells were oxyphil, coagulated and necrotic, their nuclei fragmented, the subjacent connective issue was filled with fibrin and fragmented cells and nuclei, often with hemorrhage, as well Margination against surviving tissue was usually direct, in one late case there was central calcification with marginal proliferation of fibroblasts Hemorrhagic necroses occurred also in the myometrium and parametrium One pregnant uterus was studied In this, the embryo was replaced by amorphous necrotic debris The necrotic and surviving tissues showed a ragged irregular margin There were masses of coagulated necrotic syncytium and Langhans cells, and in surviving decidual giant cells there were sometimes large vacuoles and small round cytoplasmic inclusion bodies about 1 micron in diameter No walling off was seen, but some broken down pseudo-eosinophil leukocytes appeared

In the ovaries, corpora lutea showed focal coagulation necroses closely resembling those in the suprarenal cortex, like them showing central débris, marginal, coarse vacuolation and late proliferation of

small lutein cells mingled with lymphocytes and small plasma cells Focal coagulation necroses of the ovarian stroma were also reported

We described a process in the follicular epithelium of the large graafian follicles, suggesting strongly that seen in other stratified epithelia First there appeared vertical intercellular rifts and intracellular vacuoles often perinuclear The latter coalesced, setting free the nucleus, which soon became oxyphil with clumps of chromatin in it The process was progressive, finally leaving many rounded, oxyphil nuclei and the necrotic ovum free within the basement membrane During the process, vesicular spaces with vertical cellular trabeculae were sometimes formed

Such endometrial lesions as those described by Douglas and his co-workers and by us, if they occur in smallpox, which seems probable, could well be the cause of the frequent abortions in this disease It is hoped that this gap in the pathologic histology of variola may be filled

MAMMARY GLANDS

Lesions of the mammary glands in smallpox have not been described, as far as I have been able to find

In experimental vaccinia of rabbits, lesions have been seen by Levaditi and Nicolau, Douglas, Smith and Price and us Douglas and his co-workers saw focal lesions in eleven animals, but published no histologic details Levaditi and Nicolau saw multiple hemorrhagic foci showing degeneration and necrosis of the acinar cells and periacinar polymorphonuclear inflammation We saw diffuse coagulation necrosis with discernible acinar outlines in one lactating gland, scattered necrotic acini in another, and in a nonlactating gland focal necroses involving acini and stroma, sharply marginated and without reaction

THYROID AND PARATHYROID GLANDS

Roger and Roger and Garnier (1903) are the only authors who have reported on the thyroid gland in variola Congestion, abundant colloid and minute hemorrhages in the parenchyma occurred in a case of confluent variola Generally, the acini were smaller than normal, the colloid was decreased, and the epithelium was desquamated and proliferated to two or three layers, the last being absent in younger patients Interacinar exudation of colloid was of regular occurrence as early as the second day (of the eruption?) No focal lesions were seen

We described colloid depletion as occurring usually in experimental vaccinia, and we saw focal necroses in eight of forty-seven animals These necrotic foci contained caseous debris and bordered on sometimes swollen but usually normal thyroid cells One or several acini and the included interacinous stroma might be involved Fibroblast proliferation appeared at the margins of the lesions at about the twelfth day

We encountered a focal coagulation necrosis in the parathyroid gland in one instance This contained coagulated oxyphil cells with karyolysis and karyorrhexis, and showed no marginal reaction

The two reports cited appear to agree on the diffuse changes in the thyroid gland Our report of focal necroses in the thyroid and parathyroid glands appears to be unique in the literature of variola and vaccinia

GENERAL REFERENCES NOT ASSIGNABLE TO INDIVIDUAL ORGANS

McIntosh described lesions of the internal organs in postvaccinal encephalitis which resembled tubercles, but showed more fibrosis Giant cells were prominent and there was a peripheral zone of fibrosis and lymphocytes From his failure to demonstrate tubercle bacilli and from the evidence of healing, McIntosh deduced that these lesions were not tubercles, and attributed them, apparently to vaccine virus His evidence against tuberculosis appears remarkably weak, as tubercles not infrequently heal, and tubercle bacilli are often difficult to demonstrate in sections

McIntosh and Scarff saw multiple lesions in the skin, mucosae and viscera of rabbits inoculated with vaccine virus The visceral lesions, without specific reference to any individual organ, were essentially in and around the smaller blood vessels There was intimal proliferation and, in arterioles, adventitial proliferation and mononuclear, lymphocyte and eosinophil infiltration followed by thrombosis of the vessel and often necrosis The necrotic foci were bordered by endothelial and giant cells and surrounded by fibroblasts, lymphocytes and plasma cells The figures showed perivascular infiltration in the lungs In my experience, perivascular infiltrations in the lungs of rodents generally and in the livers of rabbits are not uncommon, and though their significance is not clear, it does not appear probable that they are to be attributed specifically to the action of the vaccine virus The granulomatous lesions described have been ascribed to coccidiosis, in the liver at least, by Ledingham and Barratt and have also been traced by me to cysts of *Taenia pisiformis* (unpublished data) It is regretted that these lesions were not referred by the authors to the organs in which they occurred

CENTRAL NERVOUS SYSTEM

Fiedler, Roger and Southard saw no demonstrable lesions in the central nervous system in variola Southard could find none mentioned in the literature Perkins and Pay noted uniform congestion of the brain and cord, but did not report any histologic lesions Eichhorst described foci of infiltration with mononuclear round cells and hemorrhages throughout the cord in smallpox The infiltration was usually

perivascular and was either confined to, or transgressed, the lymphatic sheath The nerve cells were swollen and stained poorly by Nissl's stain Hyperemia and hemorrhages were seen in the pia

McIntosh reported a case of smallpox in which the lesions were essentially the same as those seen in postvaccinal encephalitis There was a perivascular small cell infiltration, slight in the adventitial space and diffuse in the surrounding parenchyma, where it was often accompanied by demyelination The cellular infiltration consisted of large cells with clear oval nuclei and fewer lymphocytes The pia was only slightly involved Distribution was diffuse in the upper portions of the brain, diminishing downward, the medulla containing no lesions The cord was not examined

Since the encephalitis that has recently been so much reported as a complication of vaccination has been covered by Bijl in a comprehensive review, it would be futile to again go into what appears to be a more or less collateral subject other than briefly Bijl summarizes the pathologic histology from the works of Luksch, Bastiaanse, Bijl and Terburgh, Turnbull and McIntosh, Van Hasselt, Bouman and Bok, Wiersma and lastly Peirdrau as follows

> The pia shows engorged, occasionally thrombosed vessels, occasional hemorrhages and infiltration by lymphocytes, plasma cells and cells of endothelial origin The capillaries of the brain are congested The sheaths of the blood vessels contain plasma cells, lymphocytes, polymorphonuclears and macrophages and are surrounded by a zone of cellular proliferation and demyelination Focal nodules, chiefly of microglia, also foam cells and macroglia, are seen in various parts of the brain Lesions are more pronounced and more numerous in the brain stem and basal ganglions, and fewer in the cortex

Schuimann and Turnbull each reported essentially similar observations, and material from the case of Fulgham and Beykirch, furnished me by Dr D L Harris, showed essentially the same picture The case of Russell and Oddie showed no anatomic evidence of encephalitis, and its validity as a case of postvaccinal encephalitis therefore remains, at least, dubious

In rabbits, lesions of the central nervous system have been produced almost exclusively by subdural or intracerebral introduction of vaccine virus Levaditi, Harvier and Nicolau (1921-1922) described a dural pustule at the site of inoculation, in which were numerous polymorphonuclear leukocytes and here and there "veritable giant cells" There was diffuse perivascular infiltration of the pia by mononuclears In the brain there were perivascular collars (small round cells are shown in the illustrations) and foci of polymorphonuclear infiltration Lesions of nerve cells and neuronophagia were lacking These last were first seen later in a cat (Levaditi and Nicolau) Condrea observed in the pia intense hyperemia, hemorrhages and diffuse infiltration by mono-

nuclear cells, plasma cells, rare polymorphonuclears and eosinophils, the last more intense in the gray and white substances of the brain (the text is not entirely clear, it is presumed perivascular infiltration was meant) Less frequent perivascular hemorrhages were seen in the brain Condrea also described inclusion bodies in nerve cells and in fixed and desquamated ependyma cells, which he identified as Guarnieri bodies

Luksch saw edema, hyperemia, polymorphonuclear infiltration of the pia and cortex, and round cell infiltration, especially about perforating vessels Walthard (1926) obtained no meningeal or cerebral reaction on corneal vaccination, inoculating subdurally, he produced meningeal and superficial cortical perivascular cellular infiltration Turnbull and McIntosh produced infiltration of the pia with lymphocytes, large lymphocytes, monocytes, "endothelial cells" and scattered polymorphonuclears and sleeves of round cells about perforating vessels in the brain More intense reactions showed areas of serofibrinous exudation and necrosis in the pia and superficially about perforating vessels McIntosh further noted definite areas of encephalitis in the brain and at times definite indications of perivascular softening Ledingham and Barratt found no focal lesions attributable to vaccinia in the brains of three rabbits

Levaditi, Nicolau and Sanchis-Bayarri inoculated apes and monkeys intracerebrally and saw hemorrhagic necrosis at the site of inoculation Hemorrhage, polymorphonuclears, lymphocytes and granulo-adipose cells filled the lesion and extended out from it along the sheaths of the blood vessels Degeneration of nerve cells was seen locally Other parts of the brain were free from any lesion suggesting human postvaccinal encephalitis

We described a serofibrinous, necrotizing leptomeningitis with extension inward a short distance along the sheaths of the blood vessels This lesion was not produced in animals vaccinated cutaneously five or more days preceding subdural inoculation We also saw foci of similar leptomeningitis three times among ninety-two animals inoculated by other routes The round cell infiltrations of the pia and sheaths of blood vessels reported by other workers I found just as frequently in control material, and I attribute these to the spontaneous granulomatous meningo-encephalitis of rabbits

It appears questionable to me whether postvaccinal encephalitis has been reproduced in rabbits, and on account of the great frequency of the spontaneous encephalitis, it will be difficult to obtain histologic proof of such reproduction The fact that lesions similar to those of postvaccinal encephalitis have been found in two cases of smallpox does not in my opinion establish the vaccinal nature of the encephalitis, though it is not the present intention to challenge the view that postvaccinal encephalitis is due to the vaccine virus

CONCLUSIONS

It would appear evident from the distribution of the lesions that the virus of variola and vaccinia is particulate The primary effect appears to be cell injury, manifested by various forms of degeneration and necrosis The inflammatory reaction appears to be mononuclear and proliferative, except when necrosis or secondary bacterial invasion has occurred In this instance, the polymorphonuclear leukocyte participates to a greater or less degree One of the effects of the lesser grades of cell injury is cell proliferation The lesions of variola and of experimental and human vaccinia parallel each other to such a degree as to lead inevitably to the conclusion that the virus of the two diseases is one, showing, it is true, varying grades of virulence The lesions of hemorrhagic smallpox have been reproduced in animals by some of the more virulent laboratory strains of vaccinia, as well as less severe forms The present experimental evidence indicates that the bronchopneumonia of smallpox is a true focal manifestation of the disease

BIBLIOGRAPHY

Adler H Die wahrend und nach der Variola auftretenden Augenkrankheiten, Arch f Dermat u Syph, 1874, p 175, cited after Councilman, Magrath and Brinckerhoff

Armstrong, C The Selection of a Heat Resistant Strain of Vaccine Virus (Rabbit Testicular), Pub Health Rep **44** 1183, 1929

Armstrong, C, and Lillie, R D Vaccine Virus Pneumonia in Rabbits Pub Health Rep **44** 2635, 1929

Arnaud, F Albuminurie et lesions des reins dans la variole, Rev de med **18** 392, 1898a

Lesions viscerales de la variole, Marseille med **35** 545, 577 and 709, 1898b

Le foie varioleux, ibid **36** 77, 129, 173 and 203, 1899a

La rate varioleuse, ibid **36** 289, 333, 433, 461 and 486, 1899b

La variole hemorrhagique, Rev de med **19** 469, 1899c

Auche, B Contribution a l'etude anatomo-pathologique et pathogenique de la broncho-pneumonie variolique, Arch clin de Bordeaux **2** 561, 1893, **3** 23, 1894

Auspitz, H, and Basch, S Untersuchungen zur Anatomie des Blatternprozesses, Virchows Arch f path Anat **28** 337, 1863, cited after Councilman

Bard, L, and Leclerc, A De la receptivite du lapin pour la vaccine Gaz hebd de med **28** 81, 1891

Barensprung Die Hautkrankheiten, 1854, cited after Buri

Barthelemy, M P T Recherches sur la variole, These de Paris, 1880

Batzdorff, E Ein neuer Fall von Osteomyelitis variolosa, Berl klin Wchnschr **49** 1931, 1912

Beraud, B, and Robin Recherches sur l'orchite et l'ovarite varioleuses, Arch gen de med **13** 274, 1859, cited after Chiari

Bijl, J P Die bisherigen Erfahrungen uber Encephalitis nach Schutzpockenimpfungen, Centralbl f d ges Hyg **17** 449, 1928

Bijl, J P, and Frenkel H S Experimentelle Untersuchung uber Encephalitis postvaccinatoria, Vaccinia generalisata beim Kaninchen, Centralbl f Bakteriol (pt 1, O) **112** 412, 1929

Birch-Hirschfeld Der acute Milztumor, Arch d Heilk **13** 389, 1872

Bosc, M Recherches sur les lesions specifiques de la peau, du poumon et du foie dans la variole, Compt rend Soc de biol (series 2) **4** 326, 1902

Bowen, J T Ueber das Vorkommen pockenahnlicher Gebilde in den inneren Organen, Vrtljschr f Dermat Wien **14** 947, 1887

Breynaert Des accidents bronchiques et bronchopneumoniques de la variole, These de Paris, 1881, Virchow-Hirsch Jahresb (pt 2) **16** 51, 1881

Brown, W L, and Brown, C P Osteomyelitis Variolosa, J A M A **81** 1414, 1923

Buin, T Die Anatomie der Variola- und Vaccinepustel, Monatsh f prakt Dermat **14** 20 and 49, 1892

Calmette, A, and Guerin, C Recherches sur la vaccine experimentale, Ann de l'Inst Pasteur **15** 161, 1901

Camus, L Da la vaccine generalisee consecutive aux injections intra-vasculaires de vaccin (Étude sur le lapin), J de physiol et path gen **17** 244, 1917

Chiari, H Ueber Orchitis variolosa, Ztschr f Heilk **7** 385, 1886
Weitere Beitrage zur Lehre von der Orchitis variolosa, ibid **10** 340, 1889
Ueber Osteomyelitis variolosa, Beitr z path Anat u z allg Path **13** 13, 1893

Condrea, P Contributions anatomo-pathologiques a l'etude de la vaccine cerebrale, Compt rend Soc de biol **86** 899, 1922

Copeman, S M, and Mann, G The Histology of Vaccinia, Twenty-Eighth Annual Report of the Local Government Board, 1899, Supplement Report of the Medical Officer, appendix C, p 505

Cornil Sur l'histologie des pustules de la variole hemorrhagique, Union med, (series 3) **28** 796, 1870, cited after Councilman

Cory, R Lectures on the Theory and Practice of Vaccination, New York, William Wood & Company, 1898, pp 41-46

Councilman, W T, Magrath, G B, and Brinckerhoff, W R The Pathological Anatomy and Histology of Variola, in Studies on the Pathology and Etiology of Variola and Vaccinia, Boston, Harvard Medical School, 1904, pp 12-135.

Curschmann, H Pocken, in Zeimssen Handbuch der speciellen Pathologie und Therapie, 1874, vol 2, p 364

Douglas, S R, Smith, W, and Price, L R W Generalized Vaccinia in Rabbits with Especial Reference to Lesions in the Internal Organs, J Path & Bact **32** 99, 1929

Eichhorst, H Ueber Erkrankungen des Ruckenmarkes bei Menschenpocken, Deutsches Arch f klin Med **110** 1, 1913

Eppinger, in Klebs Handbuch der pathologischen Anatomie, Berlin, A Hirschwald, 1876, vol 2, p 91

Ewing, J The Comparative Histology of Vaccinia and Variola, J M Research **12** 509, 1904

Ferguson, A R Histology of the Skin in Variola, J Path & Bact **10** 60, 1904-1905

Fiedler, A Statistische Mitteilungen und aphoristische Bemerkungen uber die Pockenepidemie zu Dresen, Jahresb d Gesellsch f Nat- u Heilk in Dresden 1871-1872, p 44

Fulgham, J H, and Beykirch, J G Postvaccinal Encephalitis, J A M A, **92** 1427, 1929

Gailleton Unpublished experiment cited by Bard and Leclerc

Gaucher, M E Observation de vaccine generalissee suivie de mort, Bull Soc franç de dermat et syph **2** 21, 1891

Geraud Rec de mem de med milit Pav **38** 180, 1882, cited after Chiari

Gins, H A Generalizierte Vakzine und Eccema vaccinatum, Med Welt **1** 713, 1927 (Review)

Golgi Sulle alterazioni del midollo ossa nel variolo, Virchow-Hirsch Jahresbericht 1873, vol 2, p 280

Goodpasture, E W Cellular Inclusions and the Etiology of Virus Diseases, Arch Path **7** 114, 1929 (General Review)

Gordon, M H Studies of the Viruses of Vaccinia and Variola, London, His Majesty's Stationery Office, 1925, pp 81-88

Gosselin Bull Soc anat de Paris, 1847, cited after Chiari

Guarnieri Recherche sulla pathogenesi ed etiologia dell'infezione vaccinica e variolosa, Arch per le sc med **26** 403, 1892

Ueber die Parasiten der Variola und der Vaccine, Centralbl f Bakteriol **16** 299, 1894

Hebra, in Hebra and Kaposi Lehrbuch der Hautkrankheiten, Stuttgart, Ferdinand Enke, 1874, p 224

Henseval, M, and Convent, A Contribution a l'etude de la vaccine experimentale l'injection de vaccine dans le testicule, Bull Acad roy de med de Belgique (series 4) **24** 635, 1910

Heinrichsdorff Zur Histogenese der hamorrhagischen Pocken, Virchows Arch f path Anat **230** 260, 1921

Howard, W T, and Perkins, R G Studies on the Etiology and Pathology of Vaccinia in the Rabbit and in Man, J M Research **14** 51, 1905

Huguenin, G Pocken, Ergebn d allg Path u path Anat **4** 246, 1897

Huon and Placidi Accidents de vaccine generalisee chez les lapins de culture, Compt rend Soc de biol **91** 308, 1924

Ikeda, K Purpuric Smallpox, J Lab & Clin Med **13** 440, 1928

Ivanowski, N Die parasitaren Knoten in den Lungen bei Variola, Virchow-Hirsch Jahresbericht, 1876, vol 11, pt 2, p 52, cited after Burchardt

Joffroy, A De la bronchite et de la bronchopneumonie dans la variole, Arch de physiol **12** 682, 1880

Kendall Acute Laryngitis During the Convalescence of Smallpox, Virchow-Hirsch Jahresbericht, 1881, vol 16, pt 2, p 49

Kent, A F S The Histology of the Vaccine Vesicle, Brit M J **2** 633, 1894

Kierle, N G Pathological Histology of the Vaccine Crust, Maryland M J **7** 167, 1880

Keysselitz, G, and Mayer, M Ueber Zellveranderungen in inneren Organen bei Variola, Arch f Schiffs- u Tropen-Hyg, 1909, vol 13, supp 2

Klebs, E Handbuch der pathiologischen Anatomie, Berlin, 1868

Laboulbene Nouveaux elements de l'anatomie pathologique, Paris, 1879, p 792

Ledingham, J C G The Reaction of the Skin to Vaccinia Virus, Brit J Exper Path **5** 332, 1924

The Role of the Reticuloendothelial System of the Cutis in Experimental Vaccinia and Other Infections, Experiments with Indian Ink, ibid **8** 12, 1927

Ledingham, J C G, and Barratt, M On the Visceral Lesions that May Accompany Experimental Vaccinia in Rabbits, Lancet **2** 515 (Sept 7) 1929

Ledingham, J C G, and McClean, D The Propagation of Vaccine Virus in the Rabbit Dermis, Brit J Exper Path **9** 216, 1928

Leloir, Henri Contributions à l'etude de la formation des pustules et des vesicules sur le peau et les muqueuses, Arch de physiol, 1880, cited after Buri

Levaditi, C, Harvier, P, and Nicolau, S Affinites neurotropes du virus de la vaccine, Compt rend Soc de biol **85** 345, 1921

Étude expérimentale de l'encephalite dite "lethargique," Ann de l'Inst Pasteur **36** 63 and 105, 1922

Levaditi, C and Nicolau, S Ectodermoses neurotropes, études sur la vaccine, Ann de l'Inst Pasteur **37** 1, 1923

Levaditi, C, Nicolau, S, and Sanchis-Bayarri, V L'etiologie de l'encephalopathie post-vaccinale, Presse med **35** 161, 1927

Lillie, R D, and Armstrong, C Generalized Vaccinia of Rabbits Pathologic Histology, Bull Hyg Lab, U S P H S, no 156, Washington, Government Printing Office, 1930

Low, R B The Incidence of Smallpox Throughout the World in Recent Years, Rep Pub Health & M Subj (n s) 117, London, His Majesty's Stationery Office, 1918

Luginbuhl Der Mikrokokkus der Variola, Arb a d Berner path Inst (Klebs) 1870-1871, cited after Buri

Luksch, F Gibt es beim Menschen eine Vakzineencephalitis? Centralbl f Bakteriol **96** 309, 1925

MacCallum, W G Textbook of Pathology, ed 3, Philadelphia, W B Saunders Company, 1924

MacCallum, W G, and Moody, L M Alastrim in Jamaica, Am J Hyg **1** 388, 1921

McIntosh, J Encephalomyelitis in Virus Infections and Exanthemata, Brit M J **2** 334, 1928

McIntosh, J, and Scarff, R W The Nature of the Lesions in Generalized Vaccinia in Rabbits, J Path & Bact **32** 551, 1929

Mallory, F B Ueber die Verbreitung der Osteomyelitis variolosa in Knochensysteme, Ztschr f Heilk **15** 235, 1894

Principles of Pathologic Histology, Philadelphia, W B Saunders Company, 1925

Michelson, H E, and Ikeda, K Microscopic Changes in Variola, Arch Dermat & Syph **15** 138, 1927

Monti Ueber die Aetiologie der Variola, Centralbl f Bacteriol **16** 300, 1894

Muir, R The Reaction of the Bone Marrow and Other Leucocyte Forming Tissues in Infections, Tr Path Soc London **53** 379, 1902

Musgrave, Sison, and Crowell The Bone Lesions of Smallpox, Philippine J Sc **8** 67, 1913

Noguchi, H Pure Cultivation in Vivo of Vaccine Virus Free from Bacteria, J Exper Med **21** 539, 1915

Oppenheim, R, and Loeper, M Lesions des capsules surrenales dans quelques maladies infectieuses aigues Arch de med exper **22** 683, 1901

Paschen, E Ueber den Erreger der Variolavaccine Immunitatsverhaltnisse bei Variolavaccine, in Kraus and Levaditi Handbuch der Technik und Methodik der Immunitatsforschung, Jena, Gustav Fischer, 1911, vol 1, Erganzungsband, p 465

Paul, G Zur Differentialdiagnose der Variola und der Varicellen Die Erscheinungen an der variolierten Hornhaut des Kaninchens und ihre fruhzeitige Erkennung, Centralbl f Bakteriol **75** 518, 1915

Perdrau, J R Histology of Postvaccinal Encephalitis, J Path & Bact **31** 17, 1928

Perkins, R G, and Pay, G O Studies on the Etiology and Pathology of Variola, J M Research **10** 163, 1903

Pohl-Pincus Untersuchungen uber die Wirkungsweise der Vaccination, Berlin, 1882, cited after Unna, 1882

Ponfick, E Ueber die anatomischen Veranderungen in den Organen bei hamorrhagischer und pustuloser Variola, Berl klin Wchnschr **9** 508, 1872

von Prowazek, S, and Miyaji, S Weitere Untersuchungen uber das Vaccinevirus, Centralbl f Bakteriol (pt 1, O) **75** 144, 1914

Quinquaud Quelques reflexions sur une epidemie de variole observee a l'hôpital de la Pitie en 1870, Arch gen de med **2** 310, 1870, cited after Councilman

Renault, J Nouvelles recherches anatomiques sur la prepustulation et la pustulation varioliques, Ann de dermat et syph **2** 1, 1881, cited after Burchardt, Max Virchow-Hirsch Jahresber **16** 51, also, Unna, 1882

Riedel, F Ueber purpura variolosa, Berl klin Wchnschr **54** 849, 1917

Rindfleisch Lehrbuch der pathologischen Gewebelehre, 1871, cited after Buri

Roger, G H, and Garnier, M Étude anatomique et chimique du foie dans la variole, Arch de med exper **13** 661, 1901

Neue Untersuchungen uber den Zustand der Schilddruse bei den Pocken, Virchows Arch f path Anat **124** 14, 1903

Roger, G H Les maladies infectieuses, Paris, Masson & Cie, 1902

Russell, A E, and Oddie, R A Fatal Case of Postvaccinal Encephalitis, Lancet **2** 547, 1928

Schrumpf, P Ueber die als Protozoen beschriebenen Zelleinschlusse bei Variola, Inaug Dissertation, Strassburg, Berlin, Georg Reimer, 1905

Schurmann, P Ueber Encephalo-Myelitis nach Kuhpockenimpfung, Beitr z path Anat u allg Path **79** 409, 1928

Scott, J M, and Simon, C E The Diagnosis of Smallpox by the Paul Method, Am J Hyg **3** 401, 1923

Sireday, A Des alterations du foie dans les maladies infectieuses, Rev de med **6** 465, 1886

Sorensen, S T, and Sorensen, E Mikroskopische Studien uber Vaccine und Variola, Virchows Arch f path Anat **258** 627, 1925

Soltmann, O Ein Fall von Osteomyelitis ichorrhamica post Vaccinationem, Jahrb f Kinderh **8** 98, 1874

Southard, E E The Central Nervous System in Variola, in Studies on the Pathology and on the Etiology of Variola and of Vaccinia, Boston, 1909, pp 298-300

Stokes, W R The Pathology of Smallpox, Bull Johns Hopkins Hosp **14** 214, 1903

Straus, Chambon, and Menard Recherches experimentales sur la vaccine chez le veau, Compt rend Soc de biol **2** 721, 1890

Sweitzer, S E, and Ikeda, K Variola A Clinical Study of the Minneapolis Epidemic of 1924-1925, Arch Dermat & Syph **15** 19 (Jan) 1927

Touton Vergleichende Untersuchungen uber die Entwicklung der Blasen in der Epidermis, Tubingen, 1882, cited after Unna, 1882

Turnbull, H M Encephalomyelitis in Virus Diseases and Exanthemata, Brit M J **2** 331, 1928

Turnbull, H M, and McIntosh Encephalo-Myelitis Following Vaccination, Brit J Exper Path **7** 181, 1926

Tyzzer, E E Etiology and Pathology of Vaccinia, in Studies on the Pathology and on the Etiology of Variola and of Vaccinia, Boston, 1909, pp 180-229

Ungermann, E, and Zuelzer, M Beitrage zur experimentellen Pockendiagnose, zur Histologie des cornealen Impfeffektes und zum Nachweis der Guarnierischen Korperchen, Arb a d Reichsgsndhtsamte **52** 41, 1920

Unna, P G Neuere Arbeiten zur Pockenhistologie, Monatsh f prakt Dermat **1** 345, 1882 (Review)

Die Histopathologie der Hautkrankheiten, Berlin, A Hirschwald, 1894, pp 639-653 and pp 445-449

Unruh, C C Ueber Blutungen in Nierenbecken und Ureteren bei Pocken, Arch d Heilk **13** 289, 1872

Wagner Die Todessfalle in der Leipziger Pockenepidemie, Arch d Heilk **13** 115, 1872

Walthard, B Ueber die Beziehungen des Vaccinevirus zum Zentralnervensystem vaccine-empfanglicher Tierspezies, Schweiz med Wchnschr **56** 854, 1926

Die Zuchtung des Vaccinevirus in nichtektodermalen Geweben, Ztschr f Hyg u Infektionskrankh **107** 221, 1927

Watanabe, N Ueber Verhaltung und Verteilung des intravenos einverleibten Vaccineerregers in Korper des normalen und immunen Kaninchens, Arch f Hyg **92** 359, 1924

Weigert, Carl Anatomische Beitrage zur Lehre von den Pocken, 1874, 1875, in Gesammelte Abhandlungen, Berlin, Julius Springer, 1906, vol 2, pp 10-89

Zuelzer, W Beitrage zur Pathologie und Therapie der Variola, Berl klin Wchnschr **9** 609, 1872

Zurhelle, E Isolierte Vaccineerkrankung der Zunge, Dermat Ztschr **45** 28, 1925

Notes and News

University News, Appointments, Promotions, Resignations, Deaths, etc—J G Doull, of the school of hygiene and public health of the Johns Hopkins University, has been appointed professor of hygiene and public health in Western Reserve University, in the place of Roger G Perkins, retired Ramon F Hanzal has been appointed instructor in pathologic chemistry in Western Reserve University

At the University of Virginia, Oscar Swineford will have charge of the department of pathology for the coming year as acting professor

At the University of Chicago, N Paul Hudson has been appointed professor in the department of hygiene and bacteriology and Clay G Huff assistant professor

At Yale University, George Valley has been appointed assistant professor of bacteriology H M Zimmerman, assistant professor of pathology, and D M Gay and C G Burn, instructors in pathology

Frank Billings, formerly professor of medicine and dean of the faculty of Rush Medical College of the University of Chicago, has given $100,000 to establish four fellowships at the college, one of which is named in honor of E R LeCount, professor of pathology

Withrow Morse, professor of physiologic chemistry and toxicology in Jefferson Medical College, Philadelphia, has retired from professional duties in order to devote himself to investigative work

Samuel H Gray has resigned as associate professor of pathology in the school of medicine of the University of Colorado to become pathologist to the Jewish Hospital, St Louis

Frederick E Becker has been promoted to assistant professor of pathology in the school of medicine of the University of Colorado

Benjamin White has been appointed assistant professor of preventive medicine and hygiene in Harvard Medical School

George B Magrath, medical examiner in Boston, has been appointed instructor in legal medicine at Harvard Medical School

George Neil Stewart, professor of experimental medicine, Western Reserve University, has died at the age of 70

Max Pinner, at present director of the laboratory, Maybury Sanatorium, Northville, Mich has accepted an appointment in the Desert Sanatorium, Tucson, Ariz, and will begin his work there on October 1

The board of scientific directors of the Rockefeller Institute announces the following promotions associate member to member, Peter K Olitsky, assistant to associate Mortimer L Anson, Robert B Corey, Rene J Dubos, Rebecca C Lancefield, Dr Currier McEwen, Alfred E Mirsky, Albert L Raymond, Julius Sendroy, Jr, and Richard E Shope

W W Brandes, instructor in pathology in the Northwestern University, Chicago, and pathologist to the Evanston Hospital, has accepted the appointment of assistant professor of pathology in Baylor University, Dallas, Texas

Ralph Waldo Webster, clinical professor of medicine at Rush Medical College, University of Chicago, founder and director of the Chicago Laboratory and chemist to the coroner's office of Cook County (Chicago), died on July 2, 1930, at the age of 57 He graduated from Rush Medical College in 1898 and received

the degree of Ph D in chemistry from the University of Chicago He was a member of the American Association of Pathologists and Bacteriologists and of the Society of American Bacteriologists He served during the World War, wrote books on clinical diagnostic methods, edited the last edition of Peterson and Haines' Legal Medicine and Toxicology, and was widely known as an expert in toxicology

Seventh International Congress of Medical History—The seventh Congress will be held in September, 1930

Archivio italiano di anatomica e histologica patologica—This is a new bimonthly publication issued by professors of pathology A Dionisi in Rome, A Pepere in Milan and F Vanzetti in Turin The editors are N Orlandi and R Reitano, Ospedale Maggiore, Milan The summaries of the articles are given in four languages Italian, French, German and English The contents are divided into original articles, reviews and brief reports The subscription price per year is 150 lires outside Italy

Research on Psittacosis—The U S Public Health Service has established a laboratory for research on psittacosis at the quarantine station at Curtis Bay (Baltimore) Charles Armstrong will be in charge of the laboratory, and only persons who have had psittacosis are to engage in work there

Obituary

KATSUSABURO YAMAGIWA, M D

1863-1930

Katsusaburo Yamagiwa died on March 2, 1930, from pneumonia He was born on Feb 23, 1863, in Ueda, Nagamo Prefecture, Japan, and graduated in medicine from Tokyo Imperial University in 1888 In 1891, he became assistant professor in Tokyo Imperial University He was sent to Germany for study, returning in 1894, when he was appointed professor of pathology, in which post he continued until he retired as emeritus in 1923

Yamagiwa early became an active contributor to pathologic literature, his first papers dealt with inflammation and regeneration of tendons In 1900, he published a paper on beriberi in which rice was suggested as a cause In 1905, he published a monograph on cancer of the stomach and in 1911, a study of primary cancer of the liver The work that made him famous was the demonstration in 1915, with Itchikawa, that cancer can be produced in the ear of the rabbit by the prolonged local application of coal tar This epochal work was the outcome of an earnest and determined effort to settle by experiment whether chronic irritation and repeated minor traumas of various kinds may cause cancer It is of interest to recall that Fibiger's demonstration in 1913 that cancer could be produced in the stomach of rats by feeding them with a certain parasite was hailed by Yamagiwa "as a glorious and stimulating achievement" Yamagiwa also produced cancer of the mamma in rabbits by the injection of tar His experimental production of cancer has proved to be a most important advance, because his method offers a chance to search for the actual substance or substances at work and the precise way in which cancer is produced under such circumstances Work of this kind is now being done and is yielding valuable results (see W H Woglom's review on Experimental Tar Cancer, ARCH PATH 2 533, 1926)

In 1906, Yamagiwa founded *Gann,* a journal devoted exclusively to the publication of results of research in the field of cancer, and now the official organ of the Japanese Society of Cancer Research Yamagiwa became a member of the Imperial Japanese Academy in 1919, and in the same year he was awarded the Academy Prize in recognition of his experimental work on cancer In 1929, he received the Sophie Prize from Germany

Yamagiwa's name will live in the annals of pathology because he introduced a new and fruitful method in cancer research, based on sound experiments Twenty years ago the possibility of inducing cancer at will seemed remote indeed "The realization of that possibility, one

KATSUSABURO YAMAGIWA, M D

of the most significant victories of modern medicine, encourages the hope that even the problem of controlling cancer will be ultimately solved" In view of the achievements of Yamagiwa and others there is no room for the sterile, unwarranted pessimism of the notion that the problem cannot be solved

Abstracts from Current Literature

Experimental Pathology and Pathologic Physiology

THE EFFECT OF PARATHYROID EXTRACT AND CALCIUM UPON CALCIFICATION AND HEALING IN PULMONARY TUBERCULOSIS BURGESS GORDON AND A CANTAROW, Am Rev Tuberc **20** 901, 1929

A roentgenographic study of sixty tuberculous patients to whom parathyroid extract was given (10 units twice daily), from one to four months, showed no specific change in the course of the disease except as obtained through the relief of signs and symptoms, notably hemoptysis, pleurisy, cough and expectoration There was no evidence of decalcification or increased calcium deposition in the lungs Parathyroid extract (20 units every forty-eight hours) and calcium lactate (30 grains three times daily) were given to fourteen patients with pulmonary tuberculosis for a period of from one to six months The results were the same as in the foregoing group and there was no change in calcification of the lung fields or bones of the hands and no visualization of the blood vessels It appears that diseased or potentially diseased tissue is not influenced directly by hypercalcemia and that parathyroid hormone and calcium should not be administered with the expectation of inducing calcification The influence of these agents on certain phenomena arising during the course of the disease may be considered of value in treatment

H J CORPER

THE EFFECT OF RACHITIC DIETS ON EXPERIMENTAL TUBERCULOSIS AGNES H GRANT, Am Rev Tuberc **21** 102, 1930

The addition of cod liver oil to diets which have been deficient in vitamin D decreases the resistance to tuberculosis that is already below normal The addition of calcium to diet which had been deficient in both calcium and vitamin D does not seem to retard, in rats, the development of tuberculosis in the lungs

H J CORPER

THE EFFECT OF RACHITIC DIETS ON EXPERIMENTAL TUBERCULOSIS AGNES H GRANT, Am Rev Tuberc **21** 115, 1930

Resistance to tuberculosis can be decreased from a natural immunity to moderate susceptibility, without destroying the growth impulse, by prolonged disturbance in the optimal balance that should exist between the calcium, vitamin C and vitamin D of the diet A prolonged excess of vitamin D in the diet, either with a deficiency of calcium or with a normal amount, hastens the spread of tuberculosis through the lungs The substitution of vitamin C for vitamin D at the time of inoculation or the addition of vitamin C to a diet which is deficient in vitamin D tends to increase the amount of tuberculosis in the lung, rather than decrease it The addition of vitamin C to a diet containing vitamin D tends to correct the diet, and to increase the resistance to tuberculosis The degree to which diets corrected after inoculation can retard the spread of tuberculosis in white rats depends on the type of deficiencies and excesses in the diet before inoculation, and on how long the deficient diets have been given

H J CORPER

SICKLEMIA JOSEPH LEVY, Ann Int Med **3** 47, 1929

In a routine study of fresh blood specimens of 213 negroes, the blood of twelve patients showed the sickling phenomenon In only three of these cases was there

clinical evidence of the disease Liver therapy produced marked improvement in these patients and apparently tends to inhibit the formation of sickle cells

WALTER M SIMPSON

EXPERIMENTAL EDEMA IN DOGS IN RELATION TO HUMAN EDEMA OF RENAL ORIGIN M HERBERT BARKER and E J KIRK, Arch Int Med **45** 319, 1930

Edema in dogs, varying from a slight to a marked degree, can be produced by decreasing their serum protein The amount of edema both in patients and in dogs seems more closely associated with the level of the serum albumin fraction than with the total protein The basal metabolism of the dogs fell with the depletion of the blood serum The blood volume in dogs was unchanged in the edematous period, but the cardiac output was greatly increased Renal pathologic changes in dogs were produced by a low proteinemia, as shown by the appearance in the urine of albumin, granular casts, fat droplets and products of renal cell degeneration in the urine and by definite degeneration of the renal tubules, destruction of the glomeruli and scar tissue formation

AUTHORS' SUMMARY

THE ETIOLOGY OF EMPHYSEMA L M LOEB, Arch Int Med **45** 464, 1930

Long continued high grade obstruction of the air passages of dogs was insufficient to produce a pathologic picture simulating vesicular emphysema in man If obstruction is a factor, an additional factor or factors, as an associated infection of the finer respiratory passages is an essential concomitant It is possible, but improbable that an expiratory obstruction much greater than inspiratory might be adequate

AUTHOR'S SUMMARY

THE PATHOGENESIS OF MULTIPLE SCLEROSIS RICHARD M BRICKNER, Arch Neurol & Psychiat **23** 715, 1930

While it is agreed that myelinolysis precedes gliosis in multiple sclerosis, it is not known what causes the destruction of the myelin To solve this problem Brickner immersed pieces of fresh spinal cords from rats in oxalated plasma of patients suffering from multiple sclerosis The dishes containing the plasma and cord were sealed with sterile petrolatum and placed at 37 C for from twenty-four to forty-eight hours Control plasma from healthy persons was used with the same method The segments of the cord, after fixation in formaldehyde, were stained with hematoxylin and eosin, by the Marchi or Weigert-Pal methods Brickner found changes in the cords treated by both pathologic and healthy plasma, but they were less marked in cords treated with plasma from healthy persons

In general, the cord changes were mostly in the form of tumefaction of the myelin which took the stain well, the lacunae were more numerous and some sheaths showed fragmentation The areas most suitable for study proved to be the anterior and the anterolateral columns As the multiple sclerosis plasma invariably brought about changes in the white fibers, it is, according to Brickner, but fair to assume that it contains a myelinolytic factor Such must be present also in normal blood, but in small quantities The nature of the myelinolytic element is to be studied In a limited number of cases of amyotrophic lateral sclerosis, post-encephalitic states and subacute combined cord degeneration no alterations were found which resembled those in multiple sclerosis

GEORGE B HASSIN

LONG TIME FEEDING EXPERIMENTS WITH ACTIVATED ERGOSTEROL C A BILLS and A M WIRICK, J Biol Chem **86** 117, 1930

The prolonged feeding of activated ergosterol to rats, in concentrations 100 times in excess of those necessary for the maintenance of a minimum antirachitic level, has no apparent effect on appearance, growth, reproduction or resistance to

respiratory infection Toxic effects are manifest at overdosages of a thousand-fold, and strongly evident at dosages in excess of forty thousand fold The toxic action is augmented by calcium and diminished by phosphate The administration of large overdoses of the vitamin to nursing rats does not result in the passage of more than a small amount into the milk No significant quantity can be transmitted to rats in utero

ARTHUR LOCKE

THE SPECIFIC OXYGEN CAPACITY OF THE BLOOD COLORING MATTER IN PATHOLOGICAL CONDITIONS H ENGELKES, Quart J Med **72** 507, 1929

In determinations of the specific oxygen capacity of the blood of five normal persons, the author obtained values similar to those obtained by other investigators In several cases of intraglobular sulphemoglobinemia, the specific oxygen capacity was found to be less than normal It was, however, unchanged in secondary anemia In a hemolytic process such as pernicious anemia or malaria, the specific oxygen capacity drops Sulphemoglobinemia was also observed in animals, and the specific oxygen capacity was found to be somewhat lowered

N ENZER

LACTIC ACID CONTENT OF MUSCLE AFTER DEATH CAUSED BY EXPERIMENTS WITH INSULIN H BAUER, Beitr z path Anat u z allg Path **83** 1, 1929

If the normal rabbit is suddenly killed by a blow on the back of the neck, rigor of the musculature occurs in from four to eight hours As has been long known, the chemical changes that occur in muscle and manifest themselves in rigor consist in a progressive decrease of the dextrose and glycogen of the muscle and a corresponding increase of the lactic acid In previous work, it had been found that postmortem rigor of muscle occurs much more quickly in rabbits dying from an overdose of insulin than in normal animals The usual postmortem increase of lactic acid did not occur in the muscles after death caused by insulin The failure of the lactic acid to increase was associated with a low sugar and glycogen content of the muscle at the time of death Since death due to insulin is preceded by muscular contractions like those caused by strychnine, the question that presented itself was whether the rapid onset of rigor, with a low lactic acid content, was not the result of the muscular contractions rather than of the insulin itself Experiments designed to answer this question are presented in the present communication Transection of the thoracic cord prevented the occurrence of contractions of the hind limbs following administration of insulin, but had no effect on the contractions of the fore limbs Rigor of the fore limbs set in rapidly, as in control rabbits killed by insulin, whereas rigor was greatly delayed in the hind limbs The chemical changes in the muscle of the hind limbs were similar to those of the muscle of a normal rabbit killed by a sudden blow, namely, a progressive decrease in glycogen and a corresponding increase in the acid-alkali index, as determined by the method of Wacker The postmortem electric and mechanical irritability of the muscle of the hind limbs, after transection of the cord and administration of insulin, was found to be greatly increased as compared with that of the fore limbs The increased irritability manifested itself by muscular twitchings that sometimes persisted for an hour after death The heaping up in the muscle of carbohydrate split products, such as methylglyoxyl, is put forward as a possible explanation of the greater irritability of muscles in which convulsive contractions are prevented This article is one of twenty that make up a number of the *Beitrage zur pathologischen Anatomie und zur allgemeinen Pathologie* issued as a "festschrift" in honor of the sixtieth birthday of Prof Max Borst

O T SCHULTZ

EFFECT OF EXPERIMENTAL HYPERTHYROIDISM ON SEXUAL FUNCTION G DODERLEIN, Beitr z path Anat u z allg Path **83** 92, 1929

For the experimental study of the interrelationships of the organs of the endocrine system, Doderlein considers the thyroid gland the most logical point of

attack Its hormone has been isolated, and its specific effects can be determined The measure of the end-result of a state of experimental hyperthyroidism was the sexual function His report relates to experiments carried on for two and a half years Young, sexually mature guinea-pigs were fed desiccated thyroid substance, the material being administered into the esophagus in daily doses of 0 05 to 0 1 Gm The specific effect of the administered substance was determined and controlled by daily weighing of the experimental animals and biweekly determination of the basal metabolic rate

Larger doses affect both males and females, the males apparently more than the females Sexual desire and copulation are not influenced, but the male is rendered incapable of fecundating the female Hyperthyroid females may become pregnant, but the pregnancy frequently ends in death and abortion of the young When smaller doses are used, effects are noted in the first filial generation, again more marked in the male than in the female The young of a hyperthyroid parent may exhibit evidences of hyperthyroidism at birth, but these rapidly disappear with the growth of the animal An effect of longer duration manifests itself in the males when they become sexually mature, their sexual capacity is normal, but they usually fail to impregnate the female Microscopic examination reveals no changes in the testis or ovary of animals in an experimental hyperthyroid state or of the offspring of such animals, although such animals are not functionally normal The other endocrine organs, other than the suprarenal, reveal no changes The suprarenal cortex is increased in thickness, the increase being chiefly of the zona fasciculata, which contains an increased amount of lipoid material

The simplest explanation of the results obtained would be to suppose that thyroid hyperfunction directly affects sexual function Since there is no morphologic support for such a view, the author believes that the effect is a more indirect one through the blood stream and an intermediate portion of the endocrine system, the latter, in the case of sexual function, probably being the suprarenal glands

O T SCHULTZ

HEMOLYTIC SPLENOMEGALY WITH PAROXYSMAL HEMOGLOBINURIA IMRE BARTA and DENES GOROG, Virchows Arch f path Anat **273** 266, 1929

The patient, a man, aged 34, knew nothing about jaundice in his family The disease became manifest with anorexia, cramplike pains under the right costal arch and darkening of the urine The patient was pale, not jaundiced, the spleen was slightly enlarged, the blood picture was normal and the resistance of red cells was from 0 45 to 0 34 per cent to sodium chloride One year later the patient came to the hospital with abdominal pain, weakness, subicteric color, more enlarged spleen, urobilin in the urine, anemia, microcytosis and absence of reticulocytes Resistance of red cells was from 0 42 to 0 30 per cent The blood serum was reddish, the urine was the color of meat juice There were no red cells in the sediment of the urine, but many granules of hemoglobin were present Increasing anemia with microcytosis was noted, but there were no nucleated red cells Splenectomy was performed, and during the two weeks following the blood picture improved rapidly, normoblasts and reticulocytes appeared The patient died of thrombosis of the splenic, portal and mesenteric veins The spleen (18 by 11 by 5 cm) showed little histologic change, the blood was mostly in the pulp, the sinuses appeared compressed Much blood was found in the loose tissue around the medium-sized arteries, the elastic layers of which were split Iron pigment could be found only in the epithelium of the convoluted tubules of the kidney The bone-marrow was aplastic

In the discussion the authors stress the point that the resistance against sodium chloride is no true indicator of the real vitality of red cells The disease could be called anhemopoietic hemolytic splenomegaly or aplastic hemolytic icterus Autolysins and hemolysins were absent even during hemoglobinuria

ALFRED PLAUT

ENDOCRINE GLANDS IN LEAD POISONING I M PEISSAKHOVITCH, Virchows Arch f path Anat **273** 276, 1929

In dogs and cats poisoned by lead, the chromaffine substance in the suprarenal glands was found decreased The total fat was increased, with changes in the mass relation between the different kinds of lipoid There was some atrophy of the thyroid gland

ALFRED PLAUT

LIPOIDOSIS OF THE SKIN AND MUCOUS MEMBRANES E URBACH and C WIETHE, Virchows Arch f path Anat **273** 285, 1929

This detailed report deals with a new disease The authors have made observations on nine patients belonging to four families Shortly after birth, up to the second year of life, hoarseness was noted Some of the patients suffered from recurrent stomatitis and tonsillitis during childhood After vaccination, skin eruptions occurred which may have been eczema vaccinatum or variolois All the patients had smallpox-like scars (the childhood symptoms otherwise are known from history only, the patients observed were adults) The skin lesions appeared later than the lesions of the mucous membranes in the mouth and larynx, which were responsible for the symptoms during childhood In the adult, the skin of the face had a peculiar, sepia brown and greenish tint, there were many nodules the size of a pinpoint Another lesion was represented by waxy, pale, yellow, miliary hard nodules, some the size of a lentil, which were located in the scalp chiefly The hair was sparse Some patients had similar lesions over the lips and the nose In one the introitus vaginae was studded with yellow nodules In the patients from one family one type prevailed, in the second family, another one Yellow and brownish masses bulged from the mucosa of the lips, tongue and pharynx The frenulum of the tongue was stiff and interfered with the forward movement of that organ The sense of taste was impaired The papillae of the tongue were atrophic The epiglottis was much thickened, as were the vocal chords

Histologically (many biopsies were taken), all superficial blood vessels of the skin and mucosa exhibited marked diffuse thickening of their walls, and there were enormous lipoid deposits In sections from the older stages of the yellow nodules, large, homogeneous, partly round, more or less well outlined masses were seen, with few nuclei In the small, wartlike lesions the deposits were more diffuse, and there was much overgrowth of blood vessels It was similar with the mucosal lesions

According to histochemical examinations, the deposits consisted of some lipoid which was physically combined with a protein It was insoluble in alcohol, ether and chloroform, but was soluble in hot absolute alcohol and in boiling acetone It became dark orange with sudan III

The carbohydrate metabolism was disturbed in all nine patients Either the blood sugar was high or the tolerance test gave a pathologic curve Alimentary glycosuria was found three times The differential diagnosis is discussed, notably from xanthomatosis and from hyperkeratotic lesions Treatment may be necessary to prevent narrowing of the glottis by the deposits Tracheotomy was performed in six instances Cosmetically, electric removal of the lesions on the face is done Radium treatments proved unsuccessful Fat-free diet together with insulin treatment was of no avail Treatment of the faulty sugar metabolism should be tried In one patient considerable improvement followed the first pregnancy, the infant was normal

ALFRED PLAUT

LIPOMATOSIS OF THE PANCREAS AND ITS RELATION TO GENERAL OBESITY J BALO, Virchows Arch f path Anat **273** 320, 1929

With Soxhlet's method of ether extraction, ten normal and ten lipomatous pancreases were analyzed for fat By subtracting the figure for fat from that for the total dry substance, a parenchyma index was arrived at This index was

much lower (5 to 12 Gm) in the lipomatous than in the normal pancreas (11 to 20 Gm) The atrophy of the glandular tissue is difficult or impossible to find by microscopic examination The islands generally were well preserved, occasionally situated in fat tissue It is unknown whether the atrophy is primary or secondary to the lipomatosis Probably the islands as well as the exocrine part of the pancreas have to do with obesity

ALFRED PLAUT

Pathologic Anatomy

LYMPHATIC LEUKEMIA WITHOUT LEUKOCYTOSIS C M HYLAND, Am J Dis Child **39** 59, 1930

Three cases of lymphatic leukemia without leukocytosis are reported Two of these cases came to autopsy and presented the pathologic picture of leukemia The other patient died at home and no permission for postmortem examination was obtained In all cases the white blood count was low (8,600 being the highest), but in all there was a high percentage of lymphocytes No immature cells were found save for a single myelocyte noted in one of the cases in which autopsy was done All cases were characterized by glandular enlargement, severe anemia and fever

J N PATTERSON

CIRRHOSIS OF THE LIVER IN CHILDHOOD T LEONARD SUTTON, Am J Dis Child **39** 141, 1930

The nature and occurrence of cirrhosis in childhood are discussed The thirteenth American case of nonalcoholic primary atrophic cirrhosis of the liver in a child is reported A warning is given concerning the easy confusion of primary cirrhosis with Banti's disease in relation to the question of splenectomy The onset of the disease with a disturbance like catarrhal jaundice, and the occurrence of large spider angiomas of the skin in association with cirrhosis are again emphasized

AUTHOR'S SUMMARY

ALTERATIONS IN THE VOLUME OF THE NORMAL SPLEEN AND THEIR SIGNIFICANCE JOSEPH BARCROFT, Am J M Sc **179** 1, 1930

The volume of the normal spleen of the dog was studied by two methods (1) estimating of the size of the organ by means of x-ray photographs, taken in horizontal and vertical planes, following a preliminary operation in which small metal clips were placed along the edge of the spleen, (2) observing the size, following an operation in which the spleen was exteriorized without injury to the vascular and nervous attachments Pregnancy produced prolonged contraction of the spleen A similar contraction is seen after intestinal operations The spleen buffers mechanically the vascular system against sudden emergencies, but the explanation of the shrinkage in intestinal operations in pregnancy and in heat remains in the dark It is thought that a large increase in the vascular bed of the generative organs accounts for the shrinkage during pregnancy and heat

JOHN PHAIR

THE AGRANULOCYTIC BLOOD PICTURE IN CONDITIONS OTHER THAN ANGINA GEORGE BLUMER, Am J M Sc **179** 11, 1930

There are cases of local and general sepsis with an agranulocytic blood picture, aside from the well-recognized group of agranulocytic anginas It is not yet clear whether the sepsis or the loss of power of the bone-marrow to form granulocytes is the primary lesion Such cases cannot be differentiated clinically from acute aleukemic lymphatic leukemia with terminal infectious processes In some instances it may be difficult to differentiate them from aplastic anemia with terminal infection

AUTHOR'S SUMMARY

THE INVOLVEMENT OF THE CORONARY ARTERIES IN RHEUMATIC FEVER SOLOMON R SLATLR, Am J M Sc **179** 22, 1930

A case of thrombosis of the coronary artery due to rheumatic disease with characteristic electrocardiographic observations is reported The symptomatology and pathogenesis of rheumatic coronary arteritis are discussed

AUTHOR'S SUMMARY

EOSINOPHILIA IN LIVER DIET E MEULENGRACHT AND SIGRID HOLM, Am J M Sc **179** 199, 1930

Eosinophilia in liver treatment of pernicious anemia has appeared in a marked and persistent form when the treatment is carried out with raw liver (calf) in large doses As a rule, the eosinophilia has appeared rather suddenly after about four weeks of treatment, and it has reached high degrees—20, 40, even 74 per cent In seems to persist as long as the administration of raw liver is kept up On treatment with fried liver (calf) or liver extract, the phenomenon has usually been absent, and when present in single instances, it was in a faint and transitory form Persons studied as control who were suffering from various other diseases have responded to the treatment in the same manner as have patients with pernicious anemia, as they constantly showed eosinophilia on ingestion of raw liver but not after intake of fried liver or liver extract This eosinophilia is to be considered a by-product in the treatment for pernicious anemia with raw liver that has nothing to do with the curative effect of the treatment As far as directly observable, the eosinophilia represents a harmless phenomenon

AUTHORS' SUMMARY

EOSINOPHILIA WITH SPLENOMEGALY FRANCIS F HARRISON, Am J M Sc **179** 208, 1930

A case is reported with marked eosinophilia and an enlarged spleen No parasites were found Autopsy revealed a hyperplastic bone-marrow filled with eosinophils and in the spleen and lymph nodes very many eosinophils and occasional eosinophilic myelocytes Similar cases are reported from the literature The belief is expressed that these cases constitute a clinical entity

AUTHOR'S SUMMARY

INTESTINAL POLYPOSIS WITH AN INSTANCE OF MULTIPLE FIBROMATOUS POLYPS J GOTTESMAN AND DAVID PERLA, Am J M Sc **179** 370, 1930

Two cases of multiple polyposis of the intestine are reported The first is an instance of multiple fibromas of the small and large intestine associated with chronic tuberculous enteritis A relation between the chronic irritation and the development of the polyps is suggested The second instance is one of multiple adenomatous polyps of the intestine complicated by intussusception and malignant degeneration These two instances again emphasize the etiologic rôle of chronic irritation in the formation of new growths

AUTHORS' SUMMARY

THE CLINICAL AND ANATOMIC DESCRIPTION OF A NEGRESS PELVIS J WHITRIDGE WILLIAMS, Am J Obst & Gynec **18** 504, 1929

Williams describes a pelvic deformity in a negress who had six uneventful and spontaneous deliveries The outstanding feature of the pelvic menstruation was an asymmetry in which the right oblique diameter was 2 cm shorter than the left, and the distance from the spine of the last lumbar vertebra was 2 25 cm greater to the right than to the left anterior superior spines In the seventh

delivery the progress was slow and version extraction was made Manual removal of the placenta was likewise necessary Some hours later a traumatic rupture of the uterus necessitated a supravaginal hysterectomy Death occurred on the twenty-fifth day from a tuberculous pneumonia The pelvis and the last two lumbar vertebrae were removed, and examined carefully It was a typical Naegele pelvis or obliquely ovate pelvis, in which the left sacro-iliac joint had been obliterated, a considerable part of the left ala of the sacrum disappeared, and what remained of it had become firmly synostosed with the left innominate bone The diameter of the right posterior superior spine to the left anterior superior spine was 15 75 as compared with 19 75 cm of the corresponding opposite diameter This indicated that in the right oblique diameter delivery was almost impossible and in the other diameter a small fetus could be delivered There was no atrophy of the left innominate bone Roentgenograms of the left sacro-iliac joint showed that the bony fibers extended continuously and pursued a regular course which did not favor an ankylosis secondary to an inflammatory process There was nothing in the history to indicate a previous inflammatory process This is offered as a case which does not support the contentions of Breus and Kolisko that a previous inflammatory process is the basis of this type of pelvic deformity

A J Kobak

The Pacchionian System N W Winkelman and Temple Fay, Arch Neurol & Psychiat **23** 44, 1930

Winkelman and Temple Fay studied the condition of the pacchionian granulations in a series of more than 200 cases, from a great variety of clinical and pathologic conditions In fourteen cases they found aplasia of these bodies, that is, their absence, even their immature forms, arachnoid villi, were scarce Such a type—evidently a developmental anomaly—occurred in eight cases of idiopathic epilepsy and several cases of hydrocephalus of unknown etiology

In the second group (twenty-eight cases), hypoplasia was the prominent feature Here the pacchionian bodies are present but not fully developed and show no evidence of functional activity They are usually represented by groups of mesothelial cells within the meshes of the dura In the third group, hyperplastic conditions, the pacchionian granulations are enormously dilated and their contents (myxomatous material) are stained homogeneously with the acid dyes With some stains a fibrillary network can be demonstrated containing vacuoles filled with granular material This form was observed in acute uremia, acute alcoholism and other "hydropic" conditions The fourth group comprised "fibrosis" (forty-two cases) Here the pacchionian granulations are fibrosed, shrunk and atrophied, the fibrils are very dense This type occurs in conditions in which the soft membranes of the brain are fibrosed (in dementia paralytica, arteriosclerotic conditions and chronic alcoholism) and clinically in cases associated with frequent convulsions In group five (fifty-three cases) are included infiltrative conditions Here the pacchionian granulations contain the same abnormal elements that are found in the subarachnoid space (inflammatory cells as seen in acute forms of meningitis, tuberculosis and syphilis, they also contain blood or blood pigment) The changed pacchionian bodies, whatever the type, cause insufficient escape of the cerebrospinal fluid This accumulates around the bodies and causes their atrophy from pressure Certain cases of hydration and a tendency toward convulsive seizures are also considered by Winkelman and Fay as the result of the pathologic state of the pacchionian structures These, they think, not only possess a definite physiologic function but also present a definite pathologic condition The significance and effect of the latter, however, they admit must be determined by subsequent studies

George B Hassin

THE NATURE OF VON RECKLINGHAUSEN'S DISEASE AND THE TUMORS ASSOCIATED WITH IT WILDER PENFIELD AND ARTHUR W YOUNG, Arch Neurol & Psychiat **23** *320, 1930*

The clinical symptoms in Penfield and Young's patient, a girl, aged 21, were difficulty in walking, deafness, impaired vision, headache and dizziness The earliest complaint was headaches at the age of 14, followed by disturbances of gait, dizziness, deafness, first in the left and later in the right ear, blurred vision and speech troubles A diagnosis of tumor of the brain was made The patient's condition allowed only a suboccipital craniotomy after which total blindness set in and the deafness became worse The patient died of respiratory paralysis

At necropsy, multiple subcutaneous nodules were found over the surface of the body, in the mesentery of the ileum, the lesser curvature of the wall of the stomach, without involving its mucosa, in the sympathetic ganglions (one of which displaced the right suprarenal gland forward), in the left auditory nerve (size 5 5 by 3 5 cm) which distorted the pons, medulla and cerebellum, and a smaller tumor (the size of a split pea and well encapsulated) in the right auditory and facial nerves Small tumors were attached to the left oculomotor, right trigeminal nerves, and pea-sized tumors were seen along the glossopharyngeal, the vagus, the spinal accessory and the hypoglossal nerves, the first, second and fourth cranial nerves escaped In the spinal cord, the tumors were numerous in all the roots of the cauda equina, they were scarce on the anterior roots, scattered throughout the dura, in both dorsal and ventral portions of the brain and the spinal cord, were many small nodules (4 by 4 mm) In the brain (white matter, optic thalamus) many soft areas were present In short, the meninges and the central and peripheral nervous systems were involved Histologically, the tumors of the spinal nerve roots and the peripheral nerves presented a mixture of connective tissue, nerve fibers and cells of Schwann, often also nerve fibers were present, the nuclei of the tumor were elongated and arranged in a palisade form, they stained poorly for reticulin with Hortega and Perdrau's methods with van Gieson's they assumed a yellowish-brown tone, the fibroglia fibers stained blue with Mallory's phosphotungstic acid stain The authors consider the widely accepted designation of such tumors as neurinoma "unfortunate" and use instead Mallory's definition "fibroblastoma" The numerous connective tissue fibers found in such tumors (designated by Antoni as type B) are just the result of a reaction The tumors of the cranial nerves were typical neurofibromas with superimposed areas of fibroblastomas which were also found in the tumors of the roots and peripheral nerves The tumors of the meninges (mainly dura) were made up of fibroblasts which differed from such of the perineural type and "possessed the characteristics peculiar to the cells of the meninges" The neoplastic growth was associated with a nonneoplastic reaction of the same cells in the warty eruptions of the dura In the spinal cord one section showed an ependymoma (in the center), near by (near the ventral surface of the cord) was an astrocytoma, a definite neuroglia reaction was present at another level of the cord and in the same section, overlying the cord, was an area of typical meningeal fibroblastoma in the pia-arachnoid In the cerebrum, one area showed a conglomeration of blood vessels which justified the diagnosis of hemangioma, another area in the brain contained an astrocytoma and something similar was present also in the cerebellum As a reaction to the astrocytes, areas of gliosis were present In all the tissues (connective tissue sheaths of the nerves, the meninges and the central nervous system) in which multiple tumors were present in this case there were definite signs of hyperplastic reaction of the cells peculiar to those tissues The authors assume that in von Recklinghausen's disease various tissues are under the influence of some irritant which results in their hyperplasia The neoplastic growth of the tissue cells is merely a superimposed phenomenon being thus the result of an irritation rather than that of some embryologic factors

GEORGE B HASSIN

CORTICAL ANOMALIES, VENTRICULAR HETEROTOPIAS AND OCCLUSION OF THE AQUEDUCT OF SYLVIUS JAMES W KERNOHAN, Arch Neurol & Psychiat **23** 460, 1930

Heterotopias of the brain tissues are usually multiple In Kernohan's case they were associated with congenital occlusion of the aqueduct of Sylvius, a rare occurrence The patient, a girl, aged 3 years, had hydrocephalus and epilepsy She was normal at birth, but at the age of 4 months was undernourished, and when she was 1 year old epileptic convulsions developed The child was an idiot, she never talked or walked and had disturbed sensations, but could hear a little The head was large and was not influenced by lumbar punctures Death occurred during status epilepticus There were dilated lateral and third ventricles, thin walls and numerous reddish-brown nodules (from 1 mm to 1 cm in diameter) scattered over the lateral and superior walls of the lateral ventricles, the aqueduct of Sylvius was partly closed, the tissue around it was gray and gelatinous The fourth ventricle was normal Histologic studies revealed absence of the ependyma from the walls of the lateral and third ventricles and a widened subependymal glia layer which became in some areas continuous with the heterotopic nodules The latter contained many irregularly arranged ganglion cells, which varied in size, axis cylinders were absent, glia cells were excessive but no glial fibrils were present Basal ganglions, cerebellum, pons and medulla oblongata contained no nodules The lamination of the cortex was, with some exceptions, fairly well retained In some areas the cortex had a mottled appearance because of loss of cells, many ganglion cells appeared immature, some as Betz cells were greatly diminished in numbers, often they were collected in groups and showed signs of degeneration, the optic thalamus was practically devoid of ganglion cells Signs of inflammation were absent throughout The cause of the occlusion of the aqueduct was most likely congenital

GEORGE B HASSIN

HYPEROSTOSIS AND TUMOR INFILTRATION OF BASE OF SKULL ASSOCIATED WITH OVERLYING MENINGEAL FIBROBLASTOMA N W WINKELMAN, Arch Neurol & Psychiat **23** 494, 1930

The tumor occupied the left anterior part of the brain, extending to the lateral surface of the temporal, motor and posterior parts of the undersurface of the temporal lobe and the posterior part of the orbital surface of the frontal lobe, it was associated with marked thickening of the left orbital roof which was four or five times the size of the opposite side and was closely adherent to the dura The tumor was a fibroblastoma with a collection of few tumor cells in two small narrow spaces of the thickened orbital bone While thickening of the bones of the skull may be associated with meningeal tumors, their invasion by the latter has not been described

GEORGE B HASSIN

FUNCTIONAL CIRCULATORY DISTURBANCES AND ORGANIC OBSTRUCTION OF THE CEREBRAL BLOOD VESSELS FRIEDRICH HILLER and ROY R GRINKER, Arch Neurol & Psychiat **23** 634, 1930

Hiller and Grinker assume with others that actual changes in the brain may be caused by functional vascular disturbances, such as stasis, prestasis and ischemia, just as they may be caused by organic changes in the blood vessels As an example of the former, they describe the histologic changes in a case of pertussis eclampsia A child, aged 3 years, while recovering from whooping cough, had several convulsions within six weeks and in one day before admission to the hospital had as many as seven Clinically, the child showed constant twitchings of the muscles of the anterior part of the left thigh loss of power of the left arm, absence of abdominal reflexes and "normal Babinski reflex" Ten days before death a paresis developed on the right Necropsy showed bronchopneumonia,

areas of softenings in the cortex at the level of the rostrum of the corpus callosum and some foci irregularly scattered throughout the frontoparietal lobes The blood vessels were hyperemic, but not thrombosed and the meninges appeared normal Brain changes were in the right hemisphere (mostly in the third and fourth lamina) in the form of ganglion cell degeneration, proliferation of astrocytes and microglia cells which were filled with fat (stage of astrocytic proliferation) The next stage was termed incomplete softening—the degeneration of the ganglion cell progressed further and the microglia cells developed into gitter cells, while the astrocytes showed regressive changes The third stage was that of complete softening—the field consisted of fat laden gitter cells which were gathered also around the blood vessels In areas of severe softening, the latter showed proliferation of endothelial cells and perivascular infiltrations with lymphocytes and plasma cells, but no endarteritis or proliferation of blood vessels was present Quite affected was Ammon's horn, especially Sommer's sector, and the gray matter of the basal ganglions The white matter showed mucinoid degeneration but no areas of softening

The second case was an example of changes in the brain caused by thrombosis or possibly embolism of the middle left cerebral artery in a woman who died from an ulcerative endocarditis The main change in the brain was an extensive softening of the left superior and middle temporal gyri, extending from the prerolandic area back to the gyrus, including the insula The parenchyma was edematous and the cortex in the region affected was necrotic, but the white matter was preserved Microglia showed no reactive phenomena which were present in the bordering areas In general, the destruction was much more advanced

GEORGE B HASSIN

ON UTERINE CASTS J PRESTON MAXWELL, J Obst & Gynec Brit Emp **36** 544, 1929

Casts of the uterus are classified by the author as (a) those from early abortion, (b) those from ectopic pregnancy, (c) those associated with menstruation, and (d) those of doubtful origin Examples are given of each type and illustrated Those from intra-uterine pregnancies are diagnosed by the demonstration of villi, but those in the other groups are difficult to classify since the presence of decidual-like cells is not a positive indication of pregnancy

A J KOBAK

ECTOPIC ENDOMETRIUM IN A MACACCUS RHESUS A D FRASER, J Obst & Gynec Brit Emp **36** 590, 1929

This case is offered as the first nonexperimental evidence of ectopic endometrial growth in a lower animal The animal in question was killed "for reasons which had no concern with its state of health," and no clinical data are included in the report The umbilical region was swollen by a firm encapsulated tumor the size of a walnut In the mesentery of the ilium there were twenty-three firm nodules varying in size, the largest about 1 inch in diameter, and a brownish pedunculated pea-sized growth was seen attached to the right sacro-uterine fold Endometrial tissue was found in all these growths They varied in appearance, some appeared to be in the resting stage, some in the premenstrual, and others were cystic and lined with flattened epithelium There was no endometrial tissue found in connection with the ovaries, and the tubes were patent

A J KOBAK

SALPINGITIS ISTHMICA NODOSA AND TUBAL ADENOMYOSIS OSCAR FRANKL, Arch f Gynak **135** 556, 1929

The nodular thickening of the isthmic portion of the tube originates, in the majority of cases, on inflammatory basis Deep growths of the tubal epithelium with tubal formation with simultaneous muscle hypertrophy are results of an inflammation with or without abscess formation The old term of "salpingitis

isthmica nodosa" is therefore correct In rare cases there is another genesis for nodular thickening of the isthmic and interstitial portions of the tube Either it consists in an adenomyosis from the uterus, or a heteroplasia of the tubal epithelium in the tubal musculature In such cases as in uterine adenomyosis there is no inflammatory basis Therefore in these rare cases the designation of tubal adenomyosis is adequate A true case of adenomyosis may be associated with a secondary inflammatory process, making it difficult to determine its origin Cases of this sort are not suitable for studying the cause of the tubal swelling

A J Kobak

Congenital Stenosis of Posterior Urethra M Beck, Beitr z path Anat u z allg Path **83** 13, 1929

Beck reports two cases of congenital infracollicular stenosis of the urethra In one case in a boy aged 3½, the stenosis was situated at the junction of the prostatic and membranous urethra The corpus spongiosum of the penis, with the urethra, lay dorsal to the corpora cavernosa, which were not separated from each other by the usual median longitudinal septum The meatus of the glans penis was dorsal, the coronary sulcus ventral The bladder was small and contracted The ureters were greatly dilated and convoluted The wall of the lower segment of the left ureter contained a rudimentary accessory ureter The renal pelves were dilated In the second case, in a new-born male infant, the stenosis was situated in the membranous portion of the urethra There were no anomalies of the penis except phimosis The left testis was retained in the inguinal canal, the right in the abdomen The bladder was distended and reached to the level of the umbilicus The ureters were tortuous and moderately dilated An accessory ureter situated in the anterior and mesial wall of the main ureter of each side opened into the bladder laterally to the normal ureteral opening The accessory ureters ended blindly above The renal pelves were dilated The kidneys were small and polycystic The pelvis of the left kidney was situated anterior to the lower pole of the kidney

O T Schultz

Intraperitoneal Hemorrhage Associated with Myoma of the Uterus O Brakemann, Beitr z path Anat u z allg Path **83** 63, 1929

In the three cases presented by Brakemann, intraperitoneal hemorrhage occurred suddenly at the time of menstruation In the first case, a clinical diagnosis of myoma of the uterus had been made some months before the sudden onset of hemorrhage The tumor had previously caused no symptoms At operation, a large amount of free blood was found in the peritoneal cavity The surface of a large, degenerated fibroid of the uterus was covered by a network of greatly dilated veins Hemorrhage had occurred from erosion of one of the varicosed veins Increased filling of the enlarged veins at the time of menstruation and rubbing against the bony pelvis were considered factors in the erosion In the second case, the hemorrhage resulted in death before surgical intervention could be undertaken At necropsy, there was found a large fibromyoma of the uterus This was adherent to the sigmoid in a region in which there were two ulcer-like depressions of the mucosa The mucosa itself was, however, intact The wall of the sigmoid in this region and the adhesions contained misplaced endometrial tissue, from which the fatal intraperitoneal hemorrhage had occurred The latter was held to have been due to erosion of a blood vessel by the cytogenous stroma of the misplaced endometrial tissue rather than to menstruation of the latter In the third case, laparotomy revealed intraperitoneal hemorrhage and a ruptured tubal pregnancy The uterus contained many fibroid nodules, and the wall of the uterus was the seat of diffuse endometriosis Although the hemorrhage in this case was due to the most frequent cause of intra-abdominal bleeding, namely, rupture of a tubal pregnancy, the myomatous condition is held to have been a contributing factor, in that it prevented uterine implantation of the ovum

O T Schultz

CLASSIFICATION OF CHRONIC ENLARGEMENTS OF THE SPLEEN W HUECK, Beitr z path Anat u z allg Path **83** 152, 1929

Looking on the spleen as a purely mesenchymal organ which has deviated less from the embryonic mesenchymal state than has any other organ, Hueck presents an analysis and classification of chronic enlargements of the spleen He leaves out of consideration enlargements due to specific inflammations or to tumor formation The remaining enlargements of longer duration, as opposed to the acute swellings of infectious diseases, he divides into three groups (1) those due to swelling, (2) those due to infiltration, deposition or storage and (3) those due to growth or hyperplasia Swelling may be due to edema, of the occurrence of which in pure form in the spleen little is known, or to hyperemia The later may be arterial or venous Arterial hyperemia begins in the subcapsular or perifollicular zones, but may lead to filling of all the blood spaces of the spleen, in which case it is not to be distinguished from venous hyperemia Transmission of the pulse wave causes rupture and hemorrhage, which may lead to iron and calcium incrustation Arterial hyperemia may regress without causing permanent changes, or it may lead to hyperplastic changes Venous hyperemia begins in the peritrabecular sinuses It may regress without causing permanent alterations If of sufficient duration, it causes changes the nature of which depends on the site of the hindrance to venous outflow If the obstruction is central or beyond the liver, most of the tissue is in a state of venous engorgement with sluggish circulation, the spleen being large, firm and dark red Peristence of such engorgement leads to cyanotic atrophy and sclerosis of the spleen, the organ become small, tough and pale Portal stasis also causes venous engorgement, but this leads to hyperplasia, especially of the reticulum about the sinuses Hemorrhage and iron and calcium incrustation are frequent Enlargement due to infiltration, deposition or storage may involve either the cells or the ground substance or both The greater degrees of such enlargement are usually associated with hyperplasia, as in Gaucher's disease The reticulum may undergo softening, because of edematous infiltration, or hardening, due to amyloid or hyaline deposition Growth or hyperplasia may be cellular or reticular in origin Most of the splenic enlargements detected clinically belong to this group The cellular hyperplasia may involve the so-called germinal centers of the follicles, a process noted chiefly in the young Or it may involve the perifollicular zone, when it may be either myelopoietic or lymphopoietic Hyperplasia of the reticulum leads to diffuse growth of the spleen The reticulum that undergoes hyperplasia may be that of the follicles, to which process the author applies the term lymphadenosis It may be the pulp reticulum, which bears no direct relation to the follicles or the sinuses, this process is seen in the chronic splenic enlargements of chronic sepsis, anemia or hemolytic icterus It may be the reticulum about the sinuses, such being the case in venous hyperemia due to portal stasis If the growth processes are associated with marked variations in the degree of vascular engorgement, there results a peculiar condition that the author terms fibro-adenia By this, the author understands a progressive stiffening and condensation of the ground substance, which becomes difficult of differentiation from the reticulum The author's use of this term seems to differ somewhat from that of Eppinger

O T SCHULTZ

OSTEITIS OF THE JAW OF DENTAL ORIGIN H SIEGMUND, Beitr z path Anat u z allg Path **83** 289, 1929

Siegmund presents a general discussion of changes in the alveolar processes of the jaws of dental origin Students of general pathology have paid little attention to such alterations The older view that the peridental membrane acts as a periosteum to the root of the tooth is no longer tenable It, together with the tooth, and the alveolar process form a unit structure or tooth organ Inflammatory changes that reach the apex of the tooth root through the root canal quickly involve the membrane and the surrounding bone Acute purulent inflammation, which is

rare, leads to destruction of the spongy bone of the alveolar process in a manner that does not differ from a similar involvement of any other spongy bone Chronic inflammatory reactions may follow an acute stage, but more frequently develop gradually as the result of less severe infection by way of the root canal Such chronic inflammations do not remain limited to the peridental membrane, but cause changes in the bone for a considerable distance about the root of the tooth The bone becomes rarefied by the resorptive action of the inflammatory tissue that is formed The so-called granuloma which is often seen attached to the root of an extracted infected tooth consists only of the inflammatory tissue formed at the apex of the tooth The bone is involved for some distance about the site of the granuloma Chronic osteitis about a root need not be the result of infection It may be an aseptic process, brought about by the chemical used in root canal fillings In accepting this possibility, Siegmund accepts also Stricker's theory of the role of circulatory disturbance as a primary factor in setting up inflammation If, after extraction of the tooth, epithelium becomes embedded in the healing tissues of the socket, a cyst may be formed Complete healing cannot occur if a cyst has been formed If no cyst is formed, healing may occur by the new formation of bone If the involved root is situated near the surface of the bone, as may be the case with some of the molar teeth, the chronic inflammatory process may spread to the cortical bone and periosteum of the mandible or to the antrum of the maxilla Siegmund's discussion is based in part on the microscopic study of human material, and in part on the study of lesions produced experimentally in dogs

O T SCHULTZ

PERIARTERITIS NODOSA DIAGNOSED DURING LIFE W STEPP, Deutsche med Wchnschr **56** 437, 1930

A man, aged 31, had symptoms of marked polyneuritis after a drinking spree and complained of violent pain in the abdomen resembling gallstone colic He had a moderate septic fever and a slight leukocytosis The blood pressure was increased and the urine contained casts, albumin and a few leukocytes The neurologic symptoms were the only physical changes The occurrence of polyneuritis with abdominal colic, nephritis and a septic fever suggested the diagnosis of periarteritis nodosa Postmortem examination demonstrated a perforated gastric ulcer and generalized peritonitis There were infarcts and abscesses of the kidneys The microscopic examination disclosed a periarteritis nodosa

PAUL J BRESLICH

THROMBI AND TUMORS OF THE HEART FRANZ WINDHOLZ, Virchows Arch f path Anat **273** 331, 1929

The presence of myxomatous tissue in a pedunculated mass attached to the endocardium of antrium cordis does not prove the neoplastic character of the lesion The author gives a description of different portions and the different layers of such a large mass He interprets it as an organized thrombus The thrombus was surrounded by endocardium The thin pedicle contained no blood vessels In three of nine parietal thrombi of the left auricle, homogeneous material was found in spots which, however, was not mucin In a cherry-sized mass which also was attached to the edge of the fossa ovalis, the myxomatous change could be seen with the naked eye, but the thrombotic origin of the whole formation could be proved nevertheless On the other hand, the endocardial metastases of a bronchial carcinoma and a sarcoma of femur contained myxomatous structures without any thrombosis being present The formative power of the ever-moving heart blood acts in the same way on tumors and thrombi This throws some light on the much involved discussion about neoplastic or nonneoplastic origin of intracardial thrombi or myxoma

ALFRED PLAUT

Pathologic Chemistry and Physics

THE DIFFUSIBILITY OF CALCIUM IN BRONCHIAL ASTHMA AND ALLIED DISORDERS, AND IN PULMONARY TUBERCULOSIS A CANTAROW, Am J M Sc **179** 497, 1930

The present study appears to indicate that in bronchial asthma and allied disorders there is a definite and constant disturbance of calcium balance in the form of an increase in the ratio of diffusible to nondiffusible calcium It is conceivable that this observation is related in some way to the increased capillary and cellular permeability which is believed to exist in these conditions In chronic pulmonary tuberculosis there is considerable variation in the diffusibility calcium It seems that an increased diffusibility ratio is associated with an exudative type of lesion with a high degree of clinical activity, while a decreased diffusibility ratio is associated with a productive process, relatively benign clinically Whether or not these findings bear any relation to the problem of allergy in tuberculosis cannot be stated definitely but the implication is obvious

AUTHOR'S SUMMARY

THE BLOOD-CALCIUM CONTENT IN PULMONARY TUBERCULOSIS VERA B DOLGOPOL, Am Rev Tuberc **20** 931, 1929

In moderately advanced pulmonary tuberculosis the blood-calcium content is increased In the advanced stage only the far advanced C (National Tuberculosis Association classification) shows an average calcium content below the average normal and a decreased incidence of cases with a high calcium content The other far advanced groups (A and B) do not show any evidence of decalcification The decalcification in the far advanced C group is the result of malnutrition In moderately advanced pulmonary tuberculosis the highest calcium content is observed in the age group from 21 to 40 years, and the lowest above the age of 40 In far advanced pulmonary tuberculosis the patients over 40 years of age show the highest calcium content A drop of the calcium content to below 9 2 mg per hundred cubic centimeters of serum is a sign of imminent death

H J CORPER

THE ACID-BASE COMPOSITION OF GASTRIC JUICE DURING THE SECRETORY CYCLE THEODORE L BLISS, Ann Int Med **3** 838, 1930

Bliss determined the acid-base composition of the gastric juice during the secretory cycle of three human beings and one dog with a Pavlov pouch The concentration of chloride was increased after stimulation except in the achlorhydric state, but in amounts that were less than the increase in the concentration of free hydrochloric acid During the secretory cycle the concentration of base varied inversely to the concentration of acid Sodium was found to be the most significant of the individual bases, both in amount and in its relationship to the variation in the total base during the secretory cycle The concentration of the determined ions was found to be less in the stomach than in the blood serum, with the exception of potassium The concentration of potassium was from three to five times greater in the gastric juice than in the blood serum

WALTER M SIMPSON

THE SIGNIFICANCE OF CHANGES OF VISCOSITY IN PATHOLOGICAL SERUM E H FISHBERG, J Biol Chem **85** 465, 1930

An attempt has been made to analyze the factors contributing toward an abnormal viscosity of the blood serum in cyanosis, nephrosis, uremia, pernicious anemia and obstructive jaundice

ARTHUR LOCKE

FORMATION OF A COLORLESS FORM OF HEMOGLOBIN AFTER SPLENECTOMY G B RAY and L A ISAAC, J Biol Chem **85** 549, 1930

Spectrophotometric examinations have been made of the blood of dogs, following splenectomy The results have been interpreted to indicate the presence, in such blood, of a colorless derivative of hemoglobin which may become transformed into hemoglobin on reduction, and into methemoglobin on oxidation

ARTHUR LOCKE

CYSTINURIA E BRAND, M M HARRIS AND S BILOON, J Biol Chem **86** 315, 1930

The compound which passes through the kidney in cystinuria is not necessarily free cystine A more complex precursor, similar in structure to glutathione, may be concerned Evidence is presented that the cystine content of the urine, as estimated by the Sullivan method, may be only minimal at the moment of excretion, and may later increase at a rate suggestive of the completion of an intermediate decomposition process

ARTHUR LOCKE

UROROBIN, A NEW PIGMENT OF THE URINE M WEISS, Klin Wchnschr **9** 248, 1930

Under the name urorubin, a new urinary pigment is described, which arises from a chromogen by exposure to sunlight The pigment, which is demonstrable spectroscopically, has some relation to diabetes, to cardiac and vascular diseases and to certain infectious diseases, especially tuberculosis and convalescence following catarrhal jaundice

AUTHOR'S SUMMARY

Microbiology and Parasitology

A SURVEY TO DETERMINE THE PREVALENCE OF TUBERCULOUS INFECTION IN SCHOOL CHILDREN H W HETHERINGTON, F MAURICE MCPHEDRAN, H R M LANDIS and EUGENE L OPIE, Am Rev Tuberc **20** 413 and 421, 1929

Tuberculin tests of school children of Philadelphia show that 37 7 per cent are infected with tuberculosis at the age of 5 years and 90 2 per cent at the age of 18 years These figures indicate that there has been no significant diminution of the incidence of tuberculous infection during childhood to correspond with the diminution of mortality from tuberculosis in recent years The intracutaneous tuberculin test is the only accurate method of determining the incidence of tuberculous infection in apparently healthy children American born children of Italian parentage have shown a low incidence of tuberculous infection In Jewish children attending school, being more frequent in highschool children than in other children Pulmonary tuberculosis recognized by roentgenologic examination in association with symptoms and physical signs is found in 0 5 per cent of children attending school, being more frequent in highschool children that in children of elementary schools Latent apical tuberculosis recognizable in roentgenologic films is often the precursor of the adult type of pulmonary tuberculosis It is found in 1 per cent of adolescent children (of highschool age) and is more frequent in girls than in boys Latent tuberculous infiltration of the lung of childhood type was found in more than 1 per cent of the children These lesions may be the precursor of grave disease Latent tuberculous foci in lungs and tracheobronchial lymph nodes are found in more than 10 per cent of school children It may be the precursor of pulmonary tuberculosis It varies from massive caseous lesions of serious import to firmly calcified foci, which are evidently healed Its significance is determined by the size of the lesion, the activity of the tuberculin reaction, continued exposure to open tuberculosis, associated changes in the lung substance and the age of the child Pulmonary tuber-

culosis recognized by roentgenologic examination together with symptoms and physical signs was found more than twice as often in adolescent girls as in boys of the same age It is approximately four times as frequent in colored as in white children of highschool age The evidence suggests that tuberculous infection may spread within schools but under the existing system of medical school inspection this seldom occurs

H J CORPER

EXPERIMENTAL PNEUMONOKONIOSIS (REACTIVATION OF HEALING PRIMARY TUBERCLE IN THE LUNG BY THE INHALATION OF QUARTZ, GRANITE AND CARBORUNDUM DUSTS) LEROY U GARDNER, Am Rev Tuberc **20** 833, 1929

Guinea-pigs were primarily infected by the inhalation of tubercle bacilli of low virulence In normal animals such infection produces isolated subpleural pulmonary tubercles which caseate, then retrogress and finally heal by resolution As a part of the picture of primary infection, the tracheobronchial lymph nodes are also involved, and the lesions in this location undergo a similar series of changes At intervals of from fifty-four to 206 days after such infection animals were removed to dust chambers where they were exposed to the inhalation of quartz, carborundum and granite dust until they died or were killed The inhalation of these dusts stimulated a renewed multiplication of bacilli in the healing tubercles, and this was followed by widespread chronic ulcerative tuberculosis At least two months' exposure to the dust is necessary to affect the primary foci of infection Marble and soft coal exhibited no stimulating effect The reaction appears to be a specific result of the inhalation of certain types of dust and factors like overcrowding, lack of proper ventilation and light, endemic pneumonia and nonspecific inflammations have not influenced this type of tuberculous infection In partial explanation of the results it was shown that a renewed multiplication of bacilli took place only in those tubercles containing ample amounts of dust, in which the dust particles had been carried into the nodules by phagocytes Relatively few quartz particles were ingested by any one phagocyte, and the activity of these cells was not affected, perhaps it was even accelerated So many carborundum and granite particles were taken up by the majority of the cells that their power of locomotion was lost and very little dust was carried into the tubercles Various theories are discussed and it is believed that the data can be applied to pneumonokoniosis in human beings It is believed that in a certain proportion of cases in man in which dust of the proper type is inhaled, this may stimulate preexisting quiescent foci of infection

H J CORPER

THE SUSCEPTIBILITY OF THE HAMSTER (CHINESE FIELD MOUSE) TO THE TUBERCLE BACILLUS GEORGE Y C LU, Am Rev Tuberc **20** 938, 1929

Hamsters are susceptible to minute amounts of tubercle bacilli As high as 85 per cent were successfully infected with approximately ten to fifteen bacilli About 50 per cent showed tuberculous lesions ten weeks after inoculation with probably not more than one or two living bacilli The first evidence of tuberculous infection after the inoculation of a few tubercle bacilli appeared about four weeks after inoculation Exposure of hamsters to the roentgen rays before the inoculation of tubercle bacilli had no effect on shortening the time elapsing before tuberculous lesions appeared

H J CORPER

THE INFLUENZA EPIDEMIC OF 1928 EUGENE F TRAUT and RUSSELL D HERROLD, Arch Int Med **45** 412, 1930

The flora in the sputum of patients acutely ill with influenza were identical in containing two predominating types of bacteria green-producing streptococci

and gram-negative diplococci The streptococci of these patients were pathogenic for animals These streptococci produced a toxin Skin tests with this toxin suggested a means of determining susceptible persons Vaccines from these streptococci seemed to have the power of immunizing against the influenza infection The green-producing streptococci for the most part reacted similarly in fermentation tests and bile-solubility tests These streptococci showed relationship in cross-agglutination experiments

AUTHORS' SUMMARY

THE RELATIONSHIP OF YELLOW FEVER OF THE WESTERN HEMISPHERE TO THAT OF AFRICA AND TO LEPTOSPIRAL JAUNDICE W A SAWYER, S F KITCHEN, MARTIN FROBISHER, JR, AND WRAY LLOYD, J Exper Med **51** 493, 1930

The yellow fever now occurring in South America, the present yellow fever of Africa and the historic yellow fever of Panama and other American countries are the same disease This conclusion is based on cross-immunity tests in monkeys with strains of yellow fever virus from Africa and Brazil and on tests of serums from twenty-five persons, who had recovered from yellow fever in various places and at various times, for the power to protect monkeys against African or Brazilian virus strains Cases of leptospiral jaundice (Weil's disease) were present among those diagnosed as yellow fever in the recent epidemic in Rio de Janeiro This is shown by the isolation of cultures of *Leptospirae* from the blood of two patients by H R Muller and E B Tilden of the Rockefeller Institute, and by the demonstration by us of protective power against *Leptospirae* and absence of protective power against yellow fever virus in the serums from two persons after recovery The isolation of *Leptospirae* by Noguchi and other investigators from the blood of occasional patients in past epidemics of yellow fever in a number of American countries indicates that leptospiral jaundice was present then as well and was diagnosed clinically as yellow fever The absence of protective power against *Leptospirae* shown by the Brazilian serums which protected against yellow fever virus and the absence of protective power against yellow fever virus in the serums that protected against *Leptospirae* point to the probability that American yellow fever is not the combined effect of *Leptospirae* and yellow fever virus The position of *L icteroides,* isolated by Noguchi during epidemics of yellow fever, now appears to be not that of a secondary invading micro-organism in cases of virus yellow fever, but that of the incitant of a form of infectious jaundice, sometimes fatal, often coincident in its appearance with typical yellow fever and apparently indistinguishable from it clinically This leptospiral disease has not hitherto been separated from true yellow fever Noguchi's discoveries become, therefore, of the greatest significance in respect to the epidemiology and causation of yellow fever and of infectious jaundice, previously confused one with the other In all outbreaks of supposed yellow fever hereafter the existence of the two kinds of jaundice, one due to yellow fever virus and the other to *Leptospirae* will have to be taken into account Only the former probably is spread by mosquitoes and requires antimosquito measures for its control The only difference observed between the American and African strains of yellow fever virus was a pronounced difference in virulence for monkeys The virulence of the two African strains studied was high, while that of the one American strain was highly variable and usually low

AUTHORS' SUMMARY

THE SKIN AS A PORTAL OF ENTRY IN BR MELITENSIS INFECTIONS ALBERT V HARDY, MARGARET G HUDSON and CARL F JORDAN, J Infect Dis **45** 271, 1929

It seems clear that there is more than one possible portal of entry in *Br melitensis* infections Our object was to determine the relative importance of

the different sites of entrance That undulant fever may be acquired by ingesting organisms is universally accepted That the infection might gain entrance through the skin has also been recognized, but this has heretofore been given too little consideration Our experiments show that the normal skin of guinea-pigs is more vulnerable as a portal of entry than is the digestive tract, and the epidemiologic evidence indicates that the same is true of humans Since the organisms gain entrance without causing any local lesions, the probable portal can be determined only by considering carefully the types of exposure, the dosage and the resistance to invasion at the different portals On a consideration of these points it seems probable that *Br melitensis* frequently gains entrance through the skin to produce undulant fever in man Furthermore, judging from experimental data, ingestion is not a satisfactory explanation for the natural and ready transmission of contagious abortion among animals, and we believe that, for animal infection also, more consideration should be given to the skin as a portal of entry for *Br melitensis*

AUTHORS' SUMMARY

THE PATHOGENICITY OF THE SPECIES OF THE GENUS BRUCELLA FOR MONKEYS I FOREST HUDDLESON and E T HALLMAN, J Infect Dis **45** 293, 1929

Our data indicate quite clearly that *Br abortus* (Bang) is pathogenic for the monkey, in which it produces a disease resembling undulant fever Infection, however, is not readily produced and in many cases does not occur at all Monkeys are very susceptible to infection from a small dose of the *suis (porcine)* species of *Brucella* regardless of its source In fact the data indicate that this species is more virulent for the monkey than is the *Br melitensis* species

AUTHORS' SUMMARY

THE RESISTANCE OF SCARLET FEVER STREPTOCOCCI TO THE ACTION OF BACTERIOPHAGE JOHN E WALKER, J Infect Dis **45** 304, 1929

Streptococci from erysipelas are in general susceptible to lysis by the streptococcus bacteriophage described by Shwartzman Scarlet fever streptococci so far tested are resistant It also appears that epidemic sore throat strains are susceptible to lysis when freshly isolated Streptococci may lose their susceptibility to lysis on cultivation on artificial mediums Other strains may retain their susceptibility even after ten years' cultivation All nonhemolytic streptococci tested were resistant to the bacteriophage

AUTHOR'S SUMMARY

THE GROWTH OF PASTEURELLA AVICIDA IN THE FOWL L D BUSHNELL and V D FOLTZ, J Infect Dis **45** 308, 1929

The results obtained indicate that there is a marked difference in individual cells of the same bacterial culture Some cells are capable of surviving in the body of the bird while others are not In artificial mediums practically all the cells present seem to be able to survive and grow There is a difference in the vegetative function and aggressive function of bacterial cells This difference is probably the basis of virulence in these organisms *P avicida* appears to have an organ virulence for blood and is able to grow irrespective of the manner in which introduction is made The organisms possess so little toxicity that they do not call forth any marked response on the part of the host However, the exudation into the lungs may be due to serotoxins or some product due to the interaction of the bacteria and serum or tissue cells which does not appear in artificial culture

AUTHORS' SUMMARY

A STUDY OF CERTAIN HEMOLYTIC STREPTOCOCCI OF THE BETA TYPE IN CERTIFIED MILK EDITH HAYNES, J Infect Dis **45** 316, 1929

The majority of hemolytic streptococci of beta type in certified milk which either do not hemolyze at all in fluid mediums, or do so only slightly, are members of

group 7 according to the classification of Brown, Frost and Shaw This group closely resembles *Str mastitidis* (group 2) in cultural and biologic characteristics Some of the strains found in certified milk which do not hemolyze in the test tube are members of group 9 This group is very similar to group 4 which does hemolyze in fluid mediums Groups 7 and 9 differ in their fermentation of salicin and in their appearance on blood agar plates Many of the strains of group 9 produce double or triple zones of hemolysis around the colonies Strains belonging to group 8 are found infrequently Strains of groups 7 and 9 usually do not hemolyze in fluid mediums, but this test is not constantly negative The age of the inoculum and the age of the culture tested affect the hemolytic titer in the standard test only slightly, but an inherent quality in the culture probably is more often the source of variation This test is, however, considered sufficiently reliable to use as a basis of classification The slight tendency for the weakly hemolytic strains to show hemolysis in the tube indicates a close relationship between them and the strongly hemolytic strains None of our cultures which had been kept on artificial mediums for some months proved pathogenic for mice A narrow capsule may be present on young cultures of group 7 This is not so distinct or obvious as the capsule of *Str epidemicus* (Davis) and does not persist so long All the strains studied hydrolyze sodium hippurate Growth of these strains in litmus milk is very similar to that of other streptococci which ferment lactose, and this test is of no differential value A temperature of 58 C for twenty minutes is sufficient to kill these strains in a lightly inoculated medium They probably would not survive pasteurization unless present in milk in large numbers Agglutination tests show a close serological relationship between groups 2 and 7 Groups 3 and 4 do not seem to be so closely related to group 7 Group 7, to which most of our strains belong, seems from both a cultural and serologic standpoint to be a very homogeneous group This group is distinguished from group 2 only by a weak hemolytic titer

AUTHOR'S SUMMARY

PATHOGENICITY OF TWO STRAINS OF HERPETIC VIRUS FOR MICE H B ANDERVONT, J Infect Dis **45** 366, 1929

Two well known strains of herpetic virus of different pathogenicity for the rabbit, namely, the JB and Levaditi strains, were used for studying the activity of the virus in mice The conclusions attending these studies are as follows Mice react to both strains when inoculated intracranially, in fact, mouse-brain constitutes a delicate test object for each Seventy-five mouse-brain passages of the JB virus and 21 mouse-brain passages of the Levaditi virus failed to produce any marked change in their pathogenicity for the rabbit Dilution tests in mice show that the JB virus is more virulent than the Levaditi virus Mice are susceptible to pad, corneal, intracutaneous, intraperitoneal and intravenous injection with JB virus Mice are highly susceptible to traumatized skin inoculation with either virus No marked difference in pathogenicity between the two strains is detected with this test The virus tends to become more generalized in mice after skin inoculation than after brain inoculation Intraperitoneal injection of active virus produces immune mice Mice immune to the JB strain are also immune to the Levaditi strain and vice versa Serum of herpes-immune rabbits neutralizes the mouse-passage virus in vitro and confers passive immunity on mice New-born of actively immunized mice are immune to skin inoculations with either strain for approximately two weeks

AUTHOR'S SUMMARY

PATHOGENIC SPORE-BEARING ANAEROBES IN THE CARCASSES OF SHEEP I E NEWSOM, FLOYD CROSS and HERTA S DOBBINS, J Infect Dis **45** 386, 1929

Pathogenic spore-bearing anaerobes may be isolated from the spleens of a considerable proportion of sheep dead of a variety of diseases In the case of *Cl oedematis* the longer the animal has been dead the greater is the likelihood

of its presence in the spleen *Cl oedematis* is not the cause of the disease described by the authors as overeating Caution should be exercised in attributing etiologic significance to the presence of *Cl oedematis* in the tissues of sheep

AUTHORS' SUMMARY

UNUSUAL TYPES OF NONLACTOSE-FERMENTING GRAM-NEGATIVE BACILLI FROM ACUTE DIARRHEA IN INFANTS LEROY D FOTHERGILL, J Infect Dis **45** 393, 1929

A group of organisms called, although incorrectly, "atypical paratyphoid" bacilli have been found in the stools of a high percentage of patients suffering from "summer diarrhea" This group of organisms, although called here "atypical paratyphoid" bacilli, do not belong in the paratyphoid genus nor to any of the known genera of gram-negative intestinal bacilli This group of organisms has in common the following characteristics they are nonmotile, they do not liquefy gelatin, they do not ferment lactose or else ferment it with a latent reaction, and all sugars fermented are fermented with acid and gas production Within this group, agglutination shows that they are not an homologous group like the typhoid bacillus Of these organisms, a sucrose-fermenting subgroup occurred in about one third of the carefully studied cases, and the serum from a few patients with this organism in the stools showed agglutination, but in one case agglutination was negative With other types of organisms in the main group, the patients' serums in the very few cases studied showed no agglutination The study of this group of organisms as related to infantile diarrhea is far from complete and much remains to be done before one would be justified in drawing any definite conclusions concerning the etiology

AUTHOR'S SUMMARY

AN OUTBREAK OF FOOD POISONING CAUSED BY SALMONELLA ENTERITIDIS RIGNEY D'AUNOY, J Infect Dis **45** 404, 1929

An outbreak of food poisoning following the ingestion of cream puffs infected with *Salmonella enteritidis,* which affected ninety persons, is reported All patients recovered Agglutinins for a recovered strain of *S enteritidis* and for old laboratory cultures were noted in two cases, in one of which an acute endocardial involvement developed during the course of illness None of the food handlers showed agglutinins for this or closely related micro-organisms, nor could any significant forms be isolated from their feces *S enteritidis* was isolated from rodent excreta found in the bakery, as well as from the intestinal contents of mice trapped therein Intraperitoneal injection of the recovered organism in mice and guinea-pigs caused death, but feeding live and killed cultures to a limited number of rabbits and guinea-pigs produced no observable symptoms

AUTHOR'S SUMMARY

THE LEUKOCYTOSIS IN SCARLET FEVER IN RELATIONSHIP TO SERUM TREATMENT AND COMPLICATIONS MARGARET E WYLIE, J Infect Dis **45** 408, 1929

The leukocyte count is a less reliable index of the severity of scarlet fever than is the general clinical picture and can seldom be used as an index of the severity or of the progress of a case of scarlet fever with respect to the probable onset of complications In uncomplicated and complicated cases of scarlet fever a pronounced fall in the white cell count, between the first and third day, is a constant finding There is no evidence to indicate that the administration of antitoxin in cases of scarlet fever has any effect on the leukocyte count from admission to the seventh day of illness In cases of scarlet fever a polymorphonuclear leukocytosis is the rule, but the excess of polymorphonuclear cells is slight, and their proportion

does not undergo much variation throughout the course of the disease nor does it differ characteristically in the complicated and uncomplicated cases The behavior of these cells does not distinguish the simple from the complicated cases From the first day onward the small lymphocytes undergo a steady and constant increase The large lymphocytes increase from first to third day but decrease thereafter until by the seventh day their original level is virtually regained This constant curve is independent of the occurrence or nonoccurrence of complications and of the giving or withholding of serum

AUTHOR'S SUMMARY

THE HERPES-ENCEPHALITIS PROBLEM FREDERICK P GAY and MARGARET HOLDEN, J Infect Dis **45** 415, 1929

From a critical survey of the literature on experimental herpes and on epidemic encephalitis it is pointed out that the only well maintained hypothesis as to the causation of the latter disease is the one sponsored primarily by Levaditi Epidemic encephalitis may well be caused by a neurotropic strain of the virus of herpes simplex, acting under a combination of favoring conditions Evidence in favor of this hypothesis would seem to be accumulating and apparent disproof of this explanation has become less persuasive At all events the continued experimental study of the nature and mode of action of the herpes virus offers the best present method of approach to the encephalitis problem, be it only in nature of analogy In addition, information obtained from the study of herpes enlightens the complex problem of the nature of virus diseases in general Our studies are based largely on the examination of a strong neurotropic herpes virus (Le Fevre) without demonstrable dermotropic properties, compared with a less neurotropic virus ("Frank" by Flexner) which readily produces a characteristic herpetic eruption The Le Fevre virus is adsorbed and neutralized by carmine powder and partially adsorbed without neutralization by charcoal It is readily precipitated in large part with the globulins of carbon dioxide whence it can be extracted integrally by 5 per cent sodium chloride solution Desiccation and conservation of the virus were possible but only at a low temperature Direct freezing of the brain with or without carbon dioxide gas yields a preparation that can be ground and dried to a homogeneous powder for an as yet undetermined period retains its original properties of disease production The Le Fevre virus when inoculated in or on the skin disappears within a few hours (± 24) and without producing any well defined lesion Rapid passage through the skin at shorter intervals apparently does not render the virus any more dermotropic Repeated injections of the virus in various parts of the body frequently produce a very irritative form of dermatitis often at a distance from the point of inoculation This lesion varies distinctly from the characteristic herpetic lesion produced by the Frank virus Rabbits withstand relatively large doses of the Le Fevre virus in the pleural cavity, when administered in a single dose When an easily tolerated dose is divided over a period of days or weeks it is always fatal This greater susceptibility is not, however, due to a process of specific sensitization but apparently to structural changes that may be induced by indifferent substances in the granulating pleura Immunization by the actively neurotropic Le Fevre virus is very difficult and dangerous by intraperitoneal, subcutaneous and intravenous routes Intradermal inoculation though relatively harmless does not readily lead to protection The ideal method of producing active immunity both in rabbits and guinea-pigs lies in provoking an herpetic eruption by scarification or intradermal inoculation by means of the Frank virus This is quite harmless and leads rapidly on recovery to a strong generalized immunity not only against the Frank but also the Le Fevre and H F strains Active immunity is characterized by the presence of virucidal properties in the serum No alexin-fixing or precipitating antibodies were found even in hyperimmunized rabbits The virucidal antibody is easily demonstrable by allowing the serum to act on the herpes-producing virus (Frank) and injecting the mixture intradermally

in rabbits or guinea-pigs Continued inoculation of a horse with the Le Fevre virus produced no virus-neutralizing property in the serum of this animal

AUTHORS' SUMMARY

THE PRODUCTION OF STAPHYLOCOCCAL TOXIN F M BURNET, J Path & Bact **33** 1, 1930

Under the experimental conditions used, strains of *Staphylococcus aureus* incubated in broth for from three to five days do not produce appreciable quantities of hemolysin unless a considerable proportion of albus variants appear or the cultures are incubated in an atmosphere containing added carbon dioxide The albus variants give rise to moderately stable cultures that produce large amounts of hemolysin in broth or on agar without the necessity for more than traces of carbon dioxide In broth, the albus type produces hemolysin only while the medium is on the acid side of neutrality Large yields of toxin can be obtained by extracting the agar beneath a twenty to twenty-four hour growth of a staphylococcus grown under suitable conditions The carbon dioxide requirements for the two types to produce toxin are the same for agar as for broth cultures Equivalent amounts of albus and aureus types from the same strain differ in their buffering capacity, the albus strain being more effective The results are discussed from the standpoint that the function of carbon dioxide in bacterial physiology depends on its power to pass freely into the organisms and alter the intracellular p_H independently of that of the environment

AUTHOR'S SUMMARY

THE PATHOGENESIS OF, AND PROPAGATION OF THE VIRUS IN, EXPERIMENTAL POLIOMYELITIS R W FAIRBROTHER AND E WESTON HURST, J Path & Bact **33** 17, 1930

After intranasal and intracerebral inoculation in monkeys, poliomyelitis spreads histologically from above downward, the various levels of the cord becoming involved more or less simultaneously Owing to the greater individual susceptibility of the anterior horn cells, and particularly those of the lumbar region, paralysis usually appears, and later becomes complete, first in the legs, the clinical signs are thus no guide to the path of entry or manner of spread and development of the disease Spread of the infection to the brain stem and cord occurs by way of the axis cylinders and this appears to be the route usually taken to other parts of the central nervous system, meningeal spread is, however, possible and probably always plays some part in the local dissemination of the infection around the site of inoculation Meningitis is therefore not the primary lesion of the disease, which begins as a primary degeneration of nerve cells accompanied by inflammation in the interstitial tissues Virus is present in greatest amount in those regions in which nerve cell degeneration is particularly severe, that is to say, in the spinal cord and brain stem, where nerve cell degeneration is slight, as in the cerebral cortex, in spite of the existence of numerous foci of inflammation, the virus is found inconstantly The cerebral cortex is not a favorable site for survival of the virus which tends within a few days to disappear altogether from the site of inoculation If the virus travels chiefly by way of the axis cylinders, its appearance in the cerebrospinal fluid would not be expected, nor, in fact, is it found there except on rare occasions

AUTHOR'S SUMMARY

SPONTANEOUS TUBERCULOSIS IN THE GUINEA-PIG A STANLEY GRIFFITH, J Path & Bact **33** 153, 1930

Spontaneous tuberculosis in the guinea-pig may be the result of infection with bovine, human or avian tubercle bacilli

AUTHOR'S SUMMARY

THE THERMAL DEATH-RATE OF THE BACTERIOPHAGE SCHRAB H NANAVUTTY, J Path & Bact **33** 203, 1930

The mode of destruction of the bacteriophage at different temperatures has been observed and represented graphically in the form of curves The shape of these curves is consistent and suggests that the bacteriophage is composed of living units having varying susceptibilities to heat The heat susceptibility of the bacteriophage has been found to be dependent in a large measure on the substrate in which it is suspended, perhaps owing to an alteration in its physical state

AUTHOR'S SUMMARY

VACCINATION ENCEPHALITIS A ECKSTEIN, H HERZBERG-KREMMER and K HERZBERG, Deutsche med Wschnschr **56** 264, 1930

Smallpox virus was found in the blood of eight children between the third and tenth days after vaccination with reaction, and absent from the blood of nine others None of the spinal fluids obtained from children contained virus, even when the virus could be demonstrated in the blood The spinal fluid of one of three infants with symptoms of encephalitis produced by the vaccine contained virus on the twelfth day

PAUL J BRESLICH

PRIMARY ACTINOMYCOSIS OF THE STOMACH HELMUTH NATHAN, Virchows Arch f path Anat **273** 480, 1929

A man, aged 46, died of heart failure after an atypical severe stomach disease of a few months' duration He had hematemesis and lost weight rapidly Roentgen examination suggested ulcer of the stomach with perforation into the liver Total acidity was 30, free hydrochloric acid, 15 The diagnosis was carcinomatosis, but the clinicians expected something unusual Autopsy revealed a large perforated ulcus callosum covered by the liver, duodenum and pancreas There were abscesses in the liver, pylephlebitic, and there was thrombophlebitis of the hepatic vein with abscesses in the lower lobe of the right lung The latter observation indicated something unusual, since ordinary infections are stopped by the liver Smears from the aforementioned foci contained filaments with true dichotomies, anaerobic culture yielded a pure streptothrix Fungus filaments and sulphur grains were found in the tissues and in the lumen of the blood vessels There was no typical actinomycotic granulation tissue, only abscesses, but many Russel bodies were found which are considered characteristic for actinomycosis Probably the existing ulcer was secondarily invaded by the actinomyces Few certain cases of actinomycosis of the stomach are reported in the literature

ALFRED PLAUT

Immunology

THE SEROLOGIC AND ETIOLOGIC SPECIFICITY OF THE ALPHA STREPTOCOCCUS OF GASTRIC ULCER EDWARD WATTS SAUNDERS, Arch Int Med **45** 347, 1930

The following facts have been established which demonstrate clearly the specificity of the alpha streptococcus obtained from gastric ulcer the proof obtained by experiment that a nonhemolytic streptococcus of the alpha type, isolated from nine resected gastric, duodenal and gastrojejunal ulcers, was an agglutinogenic and antigenic homolog, its agglutinogenic and antigenic unlikeness with all alpha strains from foci of infection such as the teeth, its agglutinogenic and antigenic identity with four alpha strains obtained from four cases of an acute specific disease, characterized by small ulcers of the lip, tongue, buccal membrane and tonsils, their relation to alpha prime strains producing ulcers of the skin, their specific agglutination with serums from patients with proved gastric, duodenal

or gastrojejunal ulcers controlled against serums from patients with other types of streptococcus infection, the organisms' apparent presence in the lesion in immediately prepared Levaditi tissue sections, the ability to produce ulcer and its relation to an alpha-prime strain definitely producing ulcer The possibility of their source being cow's milk has been suggested If in a large series of cases specific agglutination of the gastric alpha strain continues, as it gives every indication of doing, this department's efforts will be aimed primarily toward determining its source and prevention, and secondarily toward a real vaccine therapy

AUTHOR'S SUMMARY

CUTANEOUS REACTIONS WITH CULTURE FILTRATES OF THE COLON TYPHOID TYPE E E ECKER and H WELCH, J Exper Med **51** 409, 1930

The observations of Ecker and Rimington on the production of skin reactions with synthetic medium culture filtrates (concentrated and dialyzed) of organisms belonging to the colon-typhoid group have been confirmed and extended The filtrates show a marked degree of thermostability and marked resistance to ultraviolet radiation Intravenous injections of the filtrates stimulate the production of precipitins No precipitins are produced in the serums of rabbits that receive intracutaneous injections only At no time during the course of immunization was the skin reaction obliterated An indurative process was noted at the site of injection (skin) during the course of immunization Mixtures of the filtrates with their homologous antiserums, obtained from animals immunized by the intravenous route, and injected into skin, also failed to obliterate the erythema and edema The observations of Shwartzman have been confirmed, the Shwartzman phenomenon appears to be group or species specific Filtrates from enterococci failed to produce the phenomenon Filtrates of other unrelated organisms have not been studied The products of Shwartzman and of Ecker and Rimington appear to be the same

AUTHORS' SUMMARY

CHANGES IN HUMORAL IMMUNITY OCCURRING DURING THE EARLY STAGES OF EXPERIMENTAL PNEUMOCOCCUS INFECTION EDWARD E TERRELL, J Exper Med **51** 425, 1930

A study was made of the changes in humoral immunity occurring during the early phases of experimental pneumococcus infection in the dog and cat The methods devised by Robertson and Sia were employed to demonstrate the presence of antipneumococcus properties in the serum of animals naturally resistant to this micro-organism It was found that with a generalized and overwhelming infection accompanied by early invasion of the blood, there was a prompt and rapid decrease in the concentration of natural humoral immune bodies which frequently disappeared entirely by the time of death This same early diminution of humoral immune substances, opsonins, agglutinins and pneumococcidal-promoting bodies was observed in animals that survived a moderately severe generalized infection, but the concentration of immune bodies rose again with the onset of recovery The decrease in concentration of humoral immune substances during a severe generalized infection appeared to be due to the combination of "S" substance with the normal immune bodies When the pneumococcus infection was more localized as in the case of true lobar pneumonia, a different sequence of events was observed to occur Several animals, in which extensive lobar pneumonia was produced, showed the presence in quantity of humoral immune bodies in the blood throughout the course of an infection terminating fatally These observations suggest that after the inception of pneumococcus infection in the dog and cat, the chief function of natural antipneumococcus substances in the blood is to limit or prevent invasion of the blood When pneumococcic infection is located, these circulating antibodies appear to have little effect either in preventing the spread of the process or in determining the outcome of the disease

AUTHOR'S SUMMARY

REACTIONS OF RABBITS TO INTRACUTANEOUS INJECTIONS OF PNEUMOCOCCI AND THEIR PRODUCTS LOUIS A JULIANELLE, J Exper Med **51** 441, 449, 463, 1930

Sixty rabbits were immunized by repeated injections into the skin of small doses of suspensions of heat-killed type I pneumococci In fifty-three of the rabbits no type-specific antibodies appeared in the serum, and in those remaining the titer of these antibodies in the serum was low In all cases, however, the serums possessed a high titer of species-specific antibodies Forty-five rabbits similarly immunized by injections of heat-killed type III pneumococci also failed to form type-specific antibodies but did form species-specific antibodies Suspensions of heat-killed R pneumococci and solutions of bacterial substances when injected into the skin stimulated the production of species-specific antibodies, although they failed to stimulate the production of any type-specific antibodies Animals which had been immunized by intracutaneous injections still possessed the ability to form type-specific antibodies when they were subsequently given intravenous inoculations of type-specific pneumococci Injection of suspensions of heat-killed pneumococci into the skin of rabbits is followed by an active immunity which is effective against intravenous infection by homologous and heterologous types of pneumococcus This form of active immunity may be induced by the injection of S or R strains of pneumococcus Intracutaneous immunization with soluble derivatives of pneumococcus does not induce active immunity to infection The serums of 79 per cent of the rabbits immunized to type I pneumococcus by intracutaneous injections afforded no protection to mice against infection with pneumococci None of the serums of rabbits intracutaneously immunized to the type-specific type III (S) pneumococci, to R cells or to soluble derivatives of pneumococcus protected white mice against infection The serums of rabbits immunized first intracutaneously and subsequently intravenously possess a high titer of protective antibodies It may be concluded that when type-specific pneumococci are injected into the skin, they lose the property of stimulating an active immunity of a specific type and of stimulating the production of type-specific antibodies, but they act just as do the degraded or R forms, causing the animals to become resistant to infection with pneumococci of all types without the development of any type-specific antibodies in the serum Following repeated intracutaneous injections of heat-killed pneumococci, rabbits acquire an increased skin reactivity The increased skin reactivity reaches a maximum after from four to six injections have been made, after which it becomes greatly diminished The relationship of increased skin reactivity to active resistance to infection by pneumococcus, and to the presence of species-specific antibodies in the blood, is still obscure The increased skin reactivity is not transferable by serum from a highly reactive to a normal rabbit After regression of the reaction to the first injection of pneumococcus into the skin, there frequently follows a recrudescence, or exacerbation, of the reaction The increased skin reactivity and secondary reactions are incited alike by all types and all forms of pneumococcus

AUTHOR'S SUMMARY

ON THE INHERITANCE AND RACIAL DISTRIBUTION OF AGGLUTINABLE PROPERTIES OF HUMAN BLOOD K LANDSTEINER and PHILIP LEVINE, J Immunol **18** 87, 1930

The studies reported substantiate the view that an agglutinable property of human blood detected by an agglutinin present in certain exceptional human serums ("extra agglutinin I") is inherited and that its frequency shows a racial difference in the two populations examined Consequently, it must be considered as a constitutional property The same conclusion seems to hold for other properties of red cells demonstrable by atypical human serums Evidence is presented

to show that the qualities characterizing the two subgroups of group A are inherited The experiments reported were made with the use of some atypical serums containing agglutinins of marked activity

AUTHORS' SUMMARY

THE RATE OF DISAPPEARANCE OF INJECTED HORSE SERUM FROM THE BLOOD OF THE RABBIT H R DEAN, N E GOLDSWORTHY and C TEN BROECK, J Immunol **18** 95, 1930

A series of rabbits have received intravenous injections of horse serum, usually 10 cc Samples of blood have been taken from these rabbits at intervals from a few minutes to twelve days after the injection The volume of horse serum present in the rabbit serum obtained from these samples has been determined by the optimal proportions method The blood volume of each rabbit has been calculated by a formula put forward by G Drever and W Ray (1912), and the serum volume has been taken as 60 per cent of the blood volume The results obtained by the titration of each sample together with the calculated serum volume of the rabbit provide data for the estimation of the volume of horse serum present in the blood of the rabbit at various intervals after the injection In a considerable proportion of the experiments the results obtained during the first hour after the injection have yielded ridiculously high figures, results indeed which appeared to show that the rabbit's blood contained more horse serum than had in fact been injected In other experiments the results obtained from the titration of the earlier samples were more reasonable A satisfactory explanation of the more surprising results has not been found In all experiments the rate of disappearance of horse serum from the blood of the rabbit was rapid during the first six hours, after which on an average about 50 per cent of the horse serum that had been injected had disappeared After the sixth hour the rate of disappearance was much more gradual Quantitative determinations of the volume of the horse serum which remained in the rabbit's blood could be made until about the eighth day, when rather less than 10 per cent of the injected volume of horse serum remained

AUTHORS' SUMMARY

SKIN REACTIONS PRODUCED BY ANTIHUMAN SERUM WILLIAM W REDFERN, J Immunol **18** 109, 1930

A pronounced twenty-four hour local reaction follows injection of rabbit antihuman serum into human skin This reaction is almost identical with that produced by a second injection of antigen into a previously sensitized local area Microscopically, both are seen to be inflammatory, showing edema and perivascular round cell infiltration Fractionation of immune serum with ammonium sulphate shows that the skin reactive substances are closely associated with the globulins as are also the precipitins Removal of the precipitins, however, fails to destroy the skin reacting properties The albumin fraction of rabbit serum fails to incite an immediate urticarial reaction in human skin as does the globulin Persons who show clinical manifestations of hypersensitiveness do not show stronger skin reactions than nonsensitive persons Five patients from the series of sixty-eight given injections showed a local delayed reaction comparable to that of serum sickness

AUTHOR'S SUMMARY

ALLERGIC TESTIS REACTIONS IN GUINEA-PIGS WITH COCCIDIOIDAL GRANULOMA EDWIN F HIRSCH and DOROTHY D'ANDREA, J Immunol **18** 121, 1930

The testes of guinea-pigs with coccidioidal granuloma respond to injections of broth culture filtrates of *Coccidioides immitis,* as do other allergic tissues in the presence of antigen, by the appearance of an acute inflammatory exudate far

in excess of that in the tissues of uninfected hosts similarly injected These results are further evidence that the tissue reactions of hosts with coccidioidal granuloma, when culture filtrates of *Coccidioides immitis* are injected, are allergic

AUTHORS' SUMMARY

THE RELATIONSHIP OF TWO HEMOTOXIC ANTIGENS IN B WELCHII GROWTH PRODUCTS A F SCHNAYERSON and S L SAMUELS, J Immunol **18** 141, 1930

In the sterile filtrates of *B welchii* broth cultures, two hemotoxins have been demonstrated One of these designated as A is active in vitro and probably to some extent in vivo, the other, B, causes no hemolysis in vitro but marked blood destruction in vivo These two principles were not completely separated The hemotoxin A (hemolysin) was produced in such strength that 0 0075 cc completely lysed 1 cc of 5 per cent washed red blood sheep cells in eighteen hours Hemotoxin B was generally found to be much more toxic for pigeons than A Immune serums were produced with these two hemotoxins It was found that antihemotoxin A serum in high dilution would neutralize its homologous antigen whereas antihemotoxin B had no effect on it On intravenous inoculation into rabbits it has been found that hemotoxin B alone caused approximately as marked an anemia as a mixture of A and B Although A apparently gave rise to a more rapid initial hemolysis in vitro than B, the continuing anemia and morphologic blood changes were evidently due to the action of hemotoxin B

AUTHORS' SUMMARY

THE NATURE OF THE SO-CALLED CONGLUTINATION REACTION (BORDET-STRENG) HARRY EAGLE, J Immunol **18** 169, 1930

The adsorption (fixation) of complement midpiece by antigen-antibody suspensions (sensitized red cells or bacteria, specific precipitate) causes a change in their surface properties, evidenced by an increased tendency to cohesion and flocculation So-called conglutination is a specific instance of this general property of complement-midpiece, involving sensitized cells and the slight quantities of midpiece present in heated serums Since the terms conglutinin and conglutination do not define a distinctive substance or reaction, it is suggested that they be dropped from immunologic nomenclature

AUTHOR'S SUMMARY

EFFECT OF SODIUM CITRATE ON ANTIPNEUMOCOCCUS POWERS OF BLOOD SHEO NAN CHEER, J Immunol **18** 187, 1930

The concentrations of sodium citrate which were found to be without detectable deleterious action on the pneumococcidal properties of the blood elements are considerably less than those customarily employed in citrated blood transfusions

AUTHOR'S SUMMARY

A SKIN TEST FOR SUSCEPTIBILITY TO SMALLPOX SANFORD B HOOKER, J Infect Dis **45** 255, 1929

Endermal injections of heat-killed vaccine virus produce definite and easily interpretable reactions which are rather highly dependable as indexes of immunity to smallpox, correlating well with the various grades of response to living virus The few discrepant reactions have been on the "false" positive side and are probably ascribable to other proteins which contaminate crude virus, the negative reaction as a criterion of susceptibility has so far been wholly reliable

AUTHOR'S SUMMARY

BIOLOGIC RELATIONSHIPS OF MORGAN'S BACILLUS AS SHOWN BY COMPLEMENT FIXATION LEON C HAVENS and CATHERINE RIDGWAY, J Infect Dis **45** 263, 1929

Complement-fixation reactions between ten strains of *Bacillus morgani* revealed close antigenic identity The serologic unity demonstrated by this method permitted a study of the antigenic relationship of *B morgani* to members of the typhoid-dysentery group Close relationship to the paratyphoid and paradysentery strains studied was indicated The paratyphoid and paradysentery serums reacted with *B morgani* antigens in the same manner and degree as did the Morgan serums The same relationship held true for the Morgan serums and the paratyphoid and paradysentery antigens

AUTHORS' SUMMARY

AMMONIUM SULPHATE PRECIPITATION OF TOXIC SUBSTANCES OF BACILLUS TYPHOSUS GREGORY SHWARTZMAN, J Infect Dis **45** 283, 1929

In this work, filtrates of washings of a twenty to a twenty-two-hour-old growth of *Bacillus typhosus* on plain agar were fully saturated with ammonium sulphate The precipitates and precipitate-free filtrates were tseted in rabbits There were no skin preparatory or reacting factors detected in precipitate-free filtrates even in amounts representing several multiples of the minimal doses necessary to elicit the phenomenon with the untreated "mother" filtrates The precipitate-free filtrates showed no general toxicity for rabbits The precipitates, on the other hand, contained both powerful skin preparatory and reacting factors A yield of 9 1 Gm of dry powder was obtained from 4,000 cc of the "agar-washings" filtrates after precipitation and dialysis When both the skin and intravenous injections of the precipitate were made into the same rabbits, 0 1 mg was sufficient to prepare the skin of some rabbits which subsequently received 8 mg per kilogram of the precipitate intravenously When, however, the intravenous dose was reduced to 2 mg of precipitate per kilogram, it was necessary to use 1 0 mg intradermally in order to prepare for the reaction Doses of the precipitates larger than 2 mg per kilogram injected intravenously often produced general toxicity The potency of the precipitate, preserved over phosphorus pentoxide in a desiccator at room temperature, remained unchanged for four and seven months after its preparation was completed

AUTHOR'S SUMMARY

SEROLOGIC SPECIFICITY OF STREPTOCOCCI HAVING EFFECTIVE LOCALIZING POWER AS ISOLATED IN VARIOUS DISEASES OF MAN EDWARD C ROSENOW, J Infect Dis **45** 331, 1929

A large number of strains of green-producing streptococci have been studied serologically with hyperimmune serums prepared with the respective freshly isolated strains of streptococci These streptococci had been isolated directly from patients having various diseases, or more often from the tissues showing specific lesions in animals following injection of freshly isolated cultures of streptococci having elective localizing power Both the precipitin and agglutinin reactions were used and gave comparable results In these serologic experiments, it was found that although the streptococci isolated in widely different diseases are much alike culturally and morphologically, they react differently serologically All or most of the different strains isolated in each of the following diseases reacted specifically with the corresponding antiserums those of poliomyelitis, encephalitis, chorea, influenza epidemic parotitis, ulcer of the stomach or duodenum, ulcerative colitis, cholecystitis, chronic arthritis, pyelonephritis and endocervicitis The strains isolated in a study of similar diseases were found more closely related serologically than those isolated in a study of more widely different diseases Thus, from poliomyelitis and encephalitis the strains were the most nearly alike of any that were studied These and the chorea strains were next most closely related The

arthritic and spasmodic torticollis strains were more like the chorea strains than like the encephalitis, poliomyelitis and other strains Arthritis is common in spontaneous chorea, and chorea strains often produce arthritis in animals on intravenous injection, the symptoms in animals following intracerebral injection of spasmodic torticollis and chorea strains are strikingly similar The strains from respiratory arhythimia, a disease always associated with symptoms of encephalitis, were found more closely related to encephalitis strains than to the poliomyelitis and chorea strains Hemolytic streptococcus antiserums, from septic infections and scarlet fever, reacted specifically with the respective strains but not with the hemolytic streptococci isolated in epidemic influenza This indicates that the hemolytic streptococci so often encountered in epidemic influenza are not merely invaders of *Streptococcus pyogenes* from the upper respiratory tract Serologic specificity (just as elective localizing power) is usually lost rather soon after artificial cultivation but not in a parallel manner Both serologic specificity and elective localizing power usually can be maintained for many culture generations if transfers (0 2 cc) are made often (from four to eight times a day) in previously warmed dextrose-brain broth (15 cc amounts in tall 12 cm columns) Specific antigenic properties were best maintained by keeping cultures in latent life in meat infusion, on blood agar slants sealed with paraffin corks, and in dense suspension in glycerol and sodium chloride solution Marked changes occurred in some strains regardless of the various methods employed to maintain specificity These will be considered in a separate paper The secret of being able to prepare these highly specific antiserums rests, aside from proper dosage and so forth, largely on the use as antigens, during the prolonged period of immunization, of the respective strains which, at the time when they had been freshly isolated, had been placed for preservation in dense suspension in glycerol and sodium chloride solution Positive precipitin and agglutinin reactions were obtained more often with heterologous strains of green-producing streptococci and the different green-producing streptococci antiserums than with strains of type pneumococci and hemolytic streptococci This fact indicates that the different green-producing streptococci isolated in a study of the different diseases, while they seem highly specific when tested under selected laboratory conditions, yet are much alike basically The close relationship, basically, between the different groups of green-producing streptococci was further shown by the fact that the serum of horses that reacted highly specifically after a short period of immunization acquired increasing precipitating and agglutinating power over nonspecific strains after prolonged immunization This occurred when the precipitating or agglutinating power over the specific strains was no higher or even when it was lower than during the earlier part of the period of immunization This observation suggests that perhaps antiserums might be prepared from a single strain or group of strains of green-producing streptococci which would have beneficial therapeutic effects in widely different diseases due to green-producing streptococci The results from the serologic study support those obtained from studies of elective localization, and the conclusion that the various strains isolated in a study of the different diseases are of etiologic importance seems warranted Since most of the strains from each of the different diseases are serologically much alike, or identical, and since all possess well marked antigenic power, it may be hoped that attempts at the preparation and use of specific antiserums in treatment, now under way, will prove of value in all of the diseases studied, as have those in poliomyelitis, encephalitis and ulcerative colitis

AUTHOR'S SUMMARY

ON THE CONCENTRATION OF ANTISTREPTOCOCCUS SERUM GEORGE F FASTING, J Infect Dis **45** 360, 1929

A modification of the Felton method for precipitating antibody-euglobulin in antistreptococcus serums has been described The use of ether in the diluent, for lowering surface tension, appears to have technical advantages and does not destroy the therapeutic merits of the antibody-euglobulin The antibody fraction has been

administered intramuscularly and subcutaneously in a large number of cases, over a long period of time, without the observation of the complications and undesirable features of whole serum or of that concentrated by the salting method Prolonged immunization of horses with green-producing streptococci produces a change in the euglobulin This change is manifested by the appearance and increase of a fraction with an iso-electric point near that of normal blood, which carries down the bulk of the agglutinin and other antibodies, and which is of definite therapeutic value

AUTHOR'S SUMMARY

ANAPHYLACTIC SENSITIZATION OF GUINEA-PIGS TO STREPTOCOCCAL FILTRATES AND TO UNINOCULATED BROTH JEAN V COOKE, J Infect Dis **45** 435, 1929

Under certain circumstances the injection of nutrient broth into guinea-pigs produces specific anaphylactic hypersensitivity which may be shown by the Schultz-Dale method Broth filtrates of bacteria, therefore, cannot be used to demonstrate the presence of specific bacterial antigen by this method for testing for allergic hypersensitivity

AUTHOR'S SUMMARY

THE COMPARATIVE POTENCY OF CONCENTRATED AND UNCONCENTRATED ANTIPNEUMOCOCCUS SERUM GRACE M SICKLES, J Infect Dis **45** 490, 1929

Previous experience with the testing of various concentrated and unconcentrated antipneumococcus serums is summed up, and results are recorded with two samples of the more recent preparations of concentrated antipneumococcus antibody solution which were tested against a virulent strain of pneumococcus type I by the Felton method With the strain of pneumococcus used, the estimated titer of both samples was lower than that with which they were labeled The estimated titer of an unconcentrated serum of high potency, tested by this method, was not materially lower than that of the concentrated products In tests in which large amounts of culture and serum were used the unconcentrated serum, because of the so-called zone phenomenon, appeared to be superior to the concentrated product

AUTHOR'S SUMMARY

THE CONTENT OF ANTIBODIES IN BLOOD PLASMA AND IN SERUM R S TSCHERIKOWER and F T GRUNBAUM, Zentralbl f Bakteriol **112** 108, 1929

The authors tested the content of antibodies in the same animal as to concentration in the plasma, serum from clotting and serum from defibrinated blood They did this because of observations by Kritschewski and Tscherikower (*Ztschr f Immunitatsforsch u exper Therap*, 1925, vol 42) that thrombocytobarines are in less concentration in serum from clotted blood than in defibrinated serum from the same blood The concentration of thrombocytobarine and bacterial agglutinin was greater in defibrinated blood than in plasma or in serum from clotting, and was greater in plasma than in serum from clotting in the case of thrombocytobarine Similar results were obtained with bacteriolysin and hemolysin The hemagglutinins and precipitins, however, were in higher concentration in the plasma In the latter case, however, when the fluids were diluted and tested with a constant quantity of antigen, the plasma showed the highest titer, whereas when the antigen was diluted, the highest titer was found in the serum from clotting

PAUL R CANNON

THE FLUCTUATION OF THE NORMAL AGGLUTININS AND PRECIPITINS IN THE BLOOD OF GRAVID AND PUERPERAL WOMEN T SATO and Y KATSU, Jap J Obst & Gynec **12** 152, 1929

The patients selected for this study were free from any puerperal morbidity and never had had typhoid infection The serum was titrated with strains of

typhoid bacilli In general, it was found that in early pregnancies there was a variable range with a more or less decrease in agglutinins, which then gradually increased and by the eighth month approximated that found in the nongravid woman This increase progressed, being greatest shortly after labor, though the difference of agglutinin titer before and after the birth of the child was not marked During puerperium there was a gradual decrease to the level of that in the nongravid state The precipitins did not appear to vary in any peculiar way during pregnancy

A J Kobak

Tumors

Sarcoma of the Vagina S E Tracy, Am J Obst & Gynec **19** 279, 1930

This is a rare form of tumor that occurs most frequently in the first four decades of life The author quotes McFarland's 1911 collection of 102 cases, who found that thirty-four of forty-four cases that occurred in the first five years were sarcoma botryoides Tracy adds four of his own cases, all in adults, three of which were in the third and one in the fifth decade These tumors arose from the rectovaginal and vesicovaginal septums of the vagina Two were of the round cell, one of the spindle cell and a fourth of a mixed cell type Sarcoma of the vagina is a rapid and hopelessly recurring type of tumor The spindle cell sarcoma, however, has survived for six years after the use of 2,400 milligram hours of radium, following surgical enucleation

A J Kobak

Primary Carcinoma of the Lung James Alexander Miller and Oswald R Jones, Am Rev Tuberc **21** 1, 1930

The authors report thirty-two cases of primary carcinoma of the lung observed during the past six years, the diagnosis in each being substantiated by either bronchoscopic or postmortem sections In addition, the clinical diagnosis of primary bronchial carcinoma was made in more than 100 other cases in which the authors were unable to obtain a section of tissue This experience is testimony to the relative frequency of the condition

H J Corper

Neoplasms of the Lung William C von Glahn, Am Rev Tuberc **21** 57, 1930

Seven cases with autopsy are reported The cases of carcinoma are divided into those arising in primary bronchi, in tuberculous foci, in alveolar epithelium and in bronchiectatic cavity The author doubts that there has been an actual increase in carcinoma of the lung

H J Corper

A Statistical Study of the Coincidence of Malignancy and Tuberculosis Carl H Fortune, Ann Int Med **3** 495, 1929

Fortune carried out a controlled statistical analysis of the coincidence of malignancy and tuberculosis based on the autopsy records of the department of pathology of the University of Michigan This study revealed that active tuberculosis occurs neither more nor less frequency combined with malignancy that it does combined with any other major disease capable of producing death Healed tuberculosis was found to occur with approximately equal frequency in cancerous and noncancerous persons

Walter M Simpson

Gelatinous Carcinoma of the Breast G L Cheatle and M Cutler, Arch Surg **20** 569, 1930

Gelatinous carcinoma is comparatively rare Forty-nine instances were found in 2,944 cases of carcinoma of the breast The amount of gelatinous material may

vary Sometimes the tumor reaches enormous size The gross features are striking The tumor may be easily recognized by the light gray, jelly-like substance Microscopically, these tumors have the usual appearance of carcinoma, usually of the scirrhous type, with, in addition, a large amount of gelatinous material and degenerating islets of tumor tissue Two points of view are held as to the origin of the gelatinous substance Some believe that it takes origin in the stroma and others from the epithelial cells Various authors have reported comparatively slow growth of these tumors Recurrences appear late, and the results of operation are generally better Nevertheless, these tumors may be quite malignant The amount of colloid substance may be so extensive as to make it difficult to find the tumor-bearing areas From the examples described, there seems to be no doubt that the gelatinous material takes origin in the neoplastic epithelium Gelatinous degeneration is more common than is generally supposed, and may often be overlooked, particularly if only a few sections are taken of the specimen The process begins and ends in the epithelium Gelatinous deposits may also be found in the metastases

N Enzer

Recurrent So-Called Giant Cell Tumor C F Geschickter and M M Copeland, Arch Surg **20** 713, 1930

The authors present a review of a series of giant cell tumors which have been reported to have recurred or to have become malignant In the groups examined clinically there were twenty-six that recurred after primary curettement Studies of those groups indicate that the recurrence was not due to any inherent quality in the tumor, but rather to a poor selection of the type of treatment, or else to incomplete operation The microscopic lesions in this series did not show any peculiarities which would account for their recurrence Thus, they contained large numbers of multinucleated giant cells in the primary tumor, and there was no structural change which could be considered sarcomatous in the recurrent tumor The recurrent lesion is usually characterized by an increase in fibrous tissue and in fibroblasts Occasional large xanthoma cells are found, and these are considered the result of perforation of the bony capsule and extension of the tumor into the soft tissue, which would furnish the lipoids characteristic of these cells In 105 cases in which the patient submitted to primary curettement, the ages of those in whom curettement was successfully done were as follows 21 per cent were over 30 and 41 per cent were under 21 In the recurrent tumors, 42 per cent were over 30 and only 16 per cent under 21

The lower end of the radius appears to be a favorable location for the return of the lesion after currettement The upper part of the tibia showed relatively few recurrences and the lower part of the femur a moderate number Recurrence may be due to the destruction of the bone shell in the nonweight-bearing bone before attention is drawn to the lesion Recurrence occurred more often after currettement than after resection In this series giant cell tumor did not recur after a primary radical operation

The second group of cases included those that were reported to have malignant variants and certain differential points in the microscopic pictures Infection is often the cause of a change in the structure, which may be mistaken for a sarcomatous change Often, also, the healing process is mistaken for a malignant variant The apparent malignant modification in the microscopic structure of giant cell tumor is usually the result and not the cause of the recurrence When the malignant variant is present in the primary tumor and recurrence results, metastasis is apt to follow, and this tumor must be considered as an osteogenic sarcoma and not a giant cell tumor In the reported cases of metastatic giant cell tumor, the authors find that the metastatic nodule did not have the structure of giant cell tumor and that the metastases are always definitely sarcomatous They have analyzed these cases, and have shown that the primary lesion is really a sarcoma with giant cells and not essentially a giant cell tumor

N Enzer

GAS SECRETION IN GASTRIC CANCER W S POLLAND and A L BLOOMFIELD, Bull Johns Hopkins Hosp **46** 307, 1930

Most cases of cancer of the stomach show a deficient gastric juice as evidenced especially by abnormally small volumes of secretion with a low acidity or with an absence of acid In a small proportion of the cases there are secretory observations within normal limits Cancer appears to arise almost always on the basis of an already existing lesion, usually a chronic gastritis, less frequently a peptic ulcer

AUTHORS' SUMMARY

RELATIVE POTENCY OF CARCINOGENIC TARS AND OILS C C TWORT and J M TWORT, J Hyg **29** 373, 1930

A method has been devised whereby the potency of any given carcinogenic agent can be compared with that of a standard agent This is called the standard carcinogenic potency of the agent (P) The relative potency of the agent (R P), calculated from P, permits one to estimate the effect on the agent of different chemical treatments and dilutions, the percentage increase or decrease in activity of the agent being at once shown A unit of carcinogenicity (U C) has been established, and a concentration of 500 carcinogenic units per cubic centimeter is considered to induce the maximum relative response in animals when the agent is applied twice a week

PRIMARY CARCINOMA OF THE LUNG S L SIMPSON, Quart J Med **22** 413, 1929

This article is based on a study of 139 patients with carcinoma of the lung admitted to the London Hospital between 1907 and 1925 The author devotes considerable space to the consideration of so-called "oat-cell sarcoma," a rather unfortunate term He believes that these tumors are really carcinomas, and that practically all of them arise from the bronchi These tumors differ somewhat in their gross appearance from the more characteristic carcinomas of the lung They tend to invade the mediastinum more extensively and are subject to more necrosis However, microscopically, these tumors show considerable pleomorphism, the reverse is also true, namely, areas of oat cells may be found in large celled carcinoma The metastases occurred most frequently to the regional glands, liver, vertebrae, ribs and brain Pleural effusion occurred in thirty-nine cases, and various types of inflammatory reaction were found within the lung The pericardium was invaded in sixty-two instances, twenty-one of which were associated with pericardial effusion Thrombosis was common, and direct invasion of the superior vena cava occurred in sixteen cases The errors of diagnosis are rather interesting Of the 108 cases, sixty-six were incorrectly diagnosed These were divided into (1) the pulmonary group, in which there were twenty-four cases in which such diagnoses as pleural effusion, bronchopneumonia, bronchiectasis, etc were made, (2) the cerebral group consisting of thirteen cases, in which such diagnoses as cerebral neoplasm, abscess, encephalitis, etc, were made, and (3) the spinal group of five cases, in which the diagnoses made were transverse myelitis, paraplegia and caries of the spine In five instances the diagnosis was aneurysm, and in nineteen there was a multiplicity of wrong diagnoses such as gastric ulcer, carcinoma of the esophagus, generalized carcinoma, etc These diagnoses are analyzed in detail, the source of error being indicated There were nine cases incorrectly diagnosed during the life of the patient as carcinoma of the lung, which on postmortem examination proved to be lymphogranuloma, carcinoma of the thyroid, carcinoma of the thymus, lymphogranuloma of the thymus, fibrosarcoma of the mediastinum and carcinoma of the nasopharynx

The author discusses the alleged increase in the incidence of primary carcinoma of the lung and reviews the literature From his own investigations he concludes that there is a real increase in the incidence of pulmonary carcinoma, and this

increase is beyond the increase in carcinoma in general With regard to the etiology, he is inclined to believe that there is some irritative factor There seems to have been an increase following the influenza epidemic of 1918, and there is a high incidence of pulmonary infection preceding the onset of the tumor Increase in carcinoma of the lung in Saxony is reviewed, and he points to the possible sources of inhaled irritants such as tar, bismuth, arsenic and cobalt There seems to be less evidence in favor of tuberculosis being an etiologic factor than was previously supposed Likewise, syphilis does not seem to bear any direct relationship

N Enzer

Suprarenal Virulism A D Fordyce, Quart J Med **22** 557, 1929

The author reports two cases of hypernephroma in the cortex of the suprarenal with virulism, one in a boy and one in a girl The case histories and pathologic descriptions are complete No chromatin tissue could be recognized in either specimen

N Enzer

Reaction of the Stroma to Carcinoma R Bohmig, Beitr z path Anat u z allg Path **83** 333, 1929

Ribbert, who considered chronic inflammation an important factor in the genesis of carcinoma, looked on the reactions manifested by the stroma, in and about the tumor, and especially the round cell infiltration, as primary changes leading to the formation of the neoplasm Borst held these reactions to be the expression of local disturbances of metabolism Many pathologists have believed them to be inflammatory and secondary to the presence of the tumor Experimental tumor transplantation has ascribed an important protective and immunologic rôle to the stroma reaction Bohmig made a systematic study of 115 carcinomas from human beings, paying especial attention to the stroma within the tumor and at its periphery and to the stroma of the organ at a distance from the tumor The material utilized, lesions with ulceration being excluded, included thirty-four epitheliomas of the skin and eleven of the cervix uteri, twelve glandular carcinomas of the breast, twenty-three of the stomach and intestine and six of the uterus, fifteen scirrhous carcinomas of the breast, fourteen metastatic carcinomas of the liver and thirty-nine metastases of the lymph nodes In the microscopic examination, especial attention was paid to the blood vessels of the stroma, to the density, hyalinization and elastic changes of the stroma and to the degree and character of the round cell infiltration of the stroma The author concludes that the reaction of the stroma cannot be interpreted as either a local or a general immunologic reaction, and that no prognostic deductions may be made from the character of the reaction The latter is inflammatory and is secondary in origin Its character depends on the morphologic type of the tumor, and on the preexisting structure of the stroma of the organ

O T Schultz

Energy Metabolism of Granulation Tissue C Neuhaus, Beitr z path Anat u z allg Path **83** 383, 1929

Determination of the glycolytic activity and oxygen consumption of tissue under aerobic and anaerobic conditions, by the method of Warburg, has shown that embryonic tissue and tumor tissue, both of which are rapidly growing, differ from each other in that the former has slight or no glycolytic activity under aerobic conditions, whereas tumor tissue readily splits carbohydrates under aerobic conditions In its growth characteristics, Neuhaus conceives granulation tissue to be intermediate between embryonic and tumor tissue The growth of embryonic tissue is orderly and is regulated by the needs of the organism as a whole The growth of tumor tissue is disorderly and autonomic or unregulated The growth of granulation tissue is a disorderly process, and in this respect granulation tissue

and tumor tissue are alike, but the growth is regulated or controlled by the needs of the organism, and in this respect granulation tissue is like embryonic tissue To test the correctness of this conception, Neuhaus made a study of the glycolytic activity and respiration of granulation tissue by the method of Warburg The tissues used were tuberculous granulation tissue of the guinea-pig, foreign body granulation tissue of the guinea-pig and white rat caused by the subcutaneous injection of purified siliceous earth and aseptic callus of the rabbit and dog caused by fracture of the humerus or femur In its glycolytic activity under aerobic conditions granulation tissue was found to be intermediate between embryonic and tumor tissue The degree of aerobic glycolysis varied, however, in the different species of animals and to a lesser degree in individuals of the same species The degree of activity was progressively greater according to species in the following order dog, guinea-pig, rabbit, rat The activity of granulation tissue from the rabbit is comparable to that of benign tumor tissue, that of granulation tissue from the rat to malignant tumor tissue These differences are not due to differences in the disorderly character of the granulation tissue, but to species-specific differences of tissue The greater the metabolic activity of the granulation tissue of a species, the more prone is the tissue of that species to the formation of tumor

O T SCHULTZ

CARCINOMA OF THE FOOT AFTER ATROPHY OF THE SKIN W KRESSIN, Deutsche med Wchnschr **56** 12, 1930

A white man, aged 68, was treated for years because of ulcers in the atrophic skin of the legs and feet The ulcers recurred from time to time, but one over the left external malleolus finally failed to heal Histologically, this ulcer proved to be a squamous cell carcinoma After high amputation of the leg, metastases were found in the femoral lymph nodes

PAUL J BRESLICH

SEROLOGIC SPECIFICNESS OF CANCER TISSUE E WITEBSKY, Klin Wchnschr **9** 58, 1930

Organ suspensions, with the exception of suspension of the lens, usually yield antibodies that are species rather than organ specific In this respect, there is a difference in the behavior of different organs, brain suspensions, for example, give rise to lipoid antibodies that are organ specific, while mesodermal or endodermal organs usually yield only species specific antibodies Alcoholic extracts of tumors also are specific for the blood groups, which complicates matters The injection of alcoholic extracts of carcinoma leads to the formation of antiserums with varied properties In one series of experiments, extract from ovarian carcinoma yielded an antiserum that reacted specifically with the homologous antigen and gave no reactions with extracts from rectal carcinoma or normal organs In this case, the antiserum was specific not only for the new tissue but also for the organ in which it formed In another series, the antiserum was species specific, giving cancer specificity only when the test solutions were first treated with a little lecithin In still other experiments, the antiserums gave a cancer rather than an organ or a species specificity Boiled globulins extracted from mediastinal and rectal cancers and from normal liver yielded antiserums that were specific for the homologous antigen In the case of metastases, the boiled globulins show two kinds of specificity, one for the organ containing the primary carcinoma and the other for the organ in which the metastasis occurred In some cases, reactions were obtained also by treating the globulin antiserums with suspensions of the homologous carcinoma Specific antiserums may be obtained by injection of either the alcoholic extracts or the globulins from cancer tissues, the specificity being for the organ in which the cancer resides The formation of cancer tissue thus results in a new cancer specificity which is different for each organ The significance of these results for biology and for the serologic treatment for cancer is discussed

ARTHUR G COLE

HISTOCHEMICAL CHANGES IN CARCINOMA FROM RADIUM L SCHOENHOLZ and H HIRSCH, Strahlentherapie **34** 273, 1929

The study was made on carcinoma of the cervix There was found a marked increase in calcium in ashed sections of the tissue two days after irradiation, while the structure as revealed in ordinary tissue seemed to be unchanged The increase in calcium in the carcinoma cells is regarded as due to irradiation and as independent of changes in the connective tissue

PRIMITIVE HEMANGIOMA OF THE STRIATED MUSCLES T ANARDI, Tumori **16** 159, 1930

The author describes two cases of primary hemangioma of striated muscles (triceps and sternocleidomastoideus), both with phleboliths The anatomopathologic study of the removed masses is followed by a chemical and histopathologic study of the phleboliths In the second patient these were found in diverse stages of evolution which made it possible to arrive at any conclusion concerning the development of these formations

AUTHOR'S SUMMARY

PRIMARY EPITHELIAL BLOOD-FORMING LIVER TUMORS IN SHEEP AND CATTLE (ADENOMA AND ADENOCARCINOMA HEPATOCELLULARE HEMATOPLASTICUM) H S FRENKEL, Virchows Arch f path Anat **273** 611, 1929

Epithelial tumors of the livers from six sheep were examined They were all situated in the right lobe, varying in size from that of a hen's egg to that of a child's head They were mostly soft and medullary and were well separated from the surrounding liver tissue, metastases were present in some, in the liver tissue itself and in the lymph nodes Some of the tumors had a more trabecular structure, others were more tubular The outstanding feature was the presence of hematopoietic foci which were conspicuous by the intense staining of the nuclei The blood formation could be studied in these tumors much better than in the embryonic liver Hemogones ("Haemogonien"), single and in groups, develop from the endothelium of capillaries Hemoglobin-containing cells are seen among them The nuclei of the red cells disappear by lysis or rhexis, never by expulsion Giant cells seem to spring from the hemogones by amitosis In spite of the presence of all stages of blood formation no connection between blood-forming cells and epithelium could be found In some specimens the epithelium and blood-forming tissue seem to be situated very closely together, but reticulum stain indicates that they are separate The reticulum is similar to that described by Mollier in the embryonic liver

The blood formation in these tumors is similar to that in the liver of the sheep embryo The endothelial cell is the common mother cell The blood formation in these tumors, as well as in the embryonic liver, is autochthonous, the mother cells are furnished by the capillaries of the liver Extramedullary hematopoiesis in the adult generally takes place within the capillaries The described extracapillary blood formation is characteristic of these obviously embryonic tumors of sheep and cattle Five of the six sheep were young

ALFRED PLAUT

THE NUMBER OF CHROMOSOMES IN HUMAN CANCER CELLS K A HEIBERG and TAGE KEMP, Virchows Arch f path Anat **273** 693, 1929

A rapidly growing, not horrifying squamous cell carcinoma in the cheek of an elderly man contained an unusually large number of well preserved mitotic figures In some of them the chromosomes could be counted Many were tetraploid (between 90 and 100 chromosomes) and in some there was a still higher number of chromosomes There were some diploid mitoses, and a few of them were similar to the mitotic figures in normal tissue In the majority, however, there was an irregular arrangement of chromosomes Haploid mitoses (twenty-three

chromosomes) could be seen only occasionally The authors do not want to draw conclusions from the examination of this single tumor The difficulties lie in the fact that most mitotic figures are too large for complete examination in a single section and that examination of single sections does not give full guarantee of not losing single chromosomes Furthermore, change in size and shape and possible disintegration of chromosomes may lead to error Corresponding investigations on tissue cultures will be made

ALFRED PLAUT

PRIMARY CARCINOMA OF THE THYMUS A PARABUTSCHEW, Ztschr f Krebsforsch **30** 380, 1929

Four cases of primary carcinoma of the thymus are reported To warrant such a diagnosis, the author submits the following criteria absolute exclusion of other possible primary sites, proper location of the tumor, with regard to its relationships to surrounding structures, and histologic character According to Parabutschew, all forms of these tumors are derived from reticular tissue Hassall corpuscles, which he regards as degenerative metamorphoses of reticular cells, are not pathognomonic He regards as an important predisposing factor restricted involution of the organ as a result of inadequate function of the sex glands, which may be accentuated by the pathologic involution of these in advanced age It may be mentioned incidentally that his cases did not show a high age factor, his patients were aged 42, 54, 49 and 38 years, respectively He considers these so-called thymomas as representing transitional forms between benign and malignant tumor

H E EGGERS

THE PRODUCTION OF A GENERAL PREDISPOSITION TO TUMOR K AKIMOTO, Ztschr f Krebsforsch **30** 428, 1929

While the author was unsuccessful in influencing the susceptibility of rabbits resistant to coal tar by the injection of the serum of sensitive animals, he was more successful in obtaining evidence of increased general predisposition by the use of tar itself He applied it, in rabbits and mice, to skin areas rarely the site of cancer, and traumatized the more usually cancerous areas by burning With the rabbits, the results were merely suggestive, and took the form of limited epithelial hyperplasia at the sites of the burns But with the mice, skin tumors developed in the burned areas in those tarred in a percentage of 48, as compared with 20 per cent in untarred controls Although 64 5 per cent of the tarred animals showed skin tumors at the site of tarring, it was rather evident that the burn cancers were not metastases from these tumors, in many the two tumors developed simultaneously, in some they were of different histologic character, and in some they occurred only at the burned site

H E EGGERS

VITAMIN DEFICIENCY IN THE CAUSATION OF CANCER O L E DE RAADT, Ztschr f Krebsforsch **30** 449, 1929

Since vitamin deficiency, which has been shown to be of etiologic significance in the causation of experimental cancer, cannot be regarded as playing any important part in that disease in man, de Raadt believes that the explanation of its action is to be sought farther, in the alkalosis which results from vitamin A deficiency In support of this view he cites the frequency of cancer of the liver in the Orient, with its largely vegetarian diet, the low incidence of cancer in tuberculous patients, with their intentionally high protein intake, the rare occurrence of cancer in lepers, the fact that in Italy the distribution of cancer seems to correspond to the dietetic habits of the inhabitants, with a high rate corresponding to the regions of diets low in protein, and the relatively vegetarian diet of the aged

H E EGGERS

HISTOGENESIS, STRUCTURE AND CHARACTER OF SO-CALLED PLANT CANCER H HAMDI, Ztschr f Krebsforsch **30** 547, 1930

From a careful study of the growth characteristics of the plant tumors resulting from infection with *Bacillus tumefaciens,* the author concludes that these are not akin to the malignant tumors of animals, but are more like the malformations that may be caused by prolonged irritation Unlike cancers, they do not represent autonomously growing tissues, the new growth is dependent on the presence of the bacilli, even to the formation of metastases, they show the physiologic functions and changes of the normal tissues from which they are derived, even to the extent of occasionally putting out normal twigs

H E EGGERS

CANCER MORTALITY IN THE UNMARRIED S PELLER, Ztschr f Krebsforsch **30** 581, 1930

This statistical study is based on mortality data from Vienna, in large part for the year 1928 It was found that death from cancers were considerably more frequent among married than among unmarried men of corresponding age, although this difference became less in the later years of life Differences of the same sort, but less in degree, were found for women as well However, cancer of the breast was almost twice as common in unmarried as in married women, while cancer of the bile tracts, which was much more common in women than in men, was relatively rare in the unmarried women, and in the married women showed an evident relationship to the number of pregnancies Cancer of the colon, more frequent in men than in women, was somewhat more frequent in unmarried than in married women In regard to economic status, cancer was more common in the women of the poorer classes than among the more prosperous, but this difference was not shown by men In general, there was a lower mortality rate for Jews than for gentiles, in spite of the fact that there was a higher rate for intestinal cancer among the former, particularly pancreatic cancer and in the women, mammary cancer

H E EGGERS

THE TERM PRECANCER H STAHR, Ztschr f Krebsforsch **31** 67, 1930

Stahr takes exception strongly to the current tendency to regard precancerous lesions as constituting definite entities, capable of subdivision into successive stages of progress He points out that the term covers several dissimilar conceptions Some of the so-called precancerous changes are really more in the nature of concomitants of cancer, while others are merely indications of the presence of an irritation, which in circumstances that are not yet understood is capable eventually of producing cancer

H E EGGERS

Medicolegal Pathology

BLOOD GROUPS IN CRIMINAL INVESTIGATIONS L S DYKE, Lancet **1** 1029, 1930

The determination of blood groups may be of value in cases of disputed paternity, but it has other medicolegal applications as well In cases of murder or injury it may prove of great importance to determine, if possible, the group of blood on clothing or other objects Fancy the significance of finding that the blood staining the clothing of the suspect not only does not belong to the blood group of the suspect but does in fact fall in the same group as the blood of the victim On account of such possibilities it has been urged that the blood groups of all persons involved in crimes associated with bloodshed be determine as promptly as possible This is said to be customary in Russia

WOUNDS PRODUCED BY THE PARING-KNIFE (SHOEMAKER'S KNIFE) A DALLA VOLTA, Arch di antropol crim **49** 56, 1929

This study supplements the statistical work of Canuto, who two years ago described twenty-five cases (*Arch di antropol crim* **48** 88, 1928) Wounds inflicted by the paring-knife can, under certain circumstances, be differentiated from stab-wounds and cut-wounds produced by other sharp instruments Peculiarities of these otherwise uncommonly observed wounds are presented by the author in every detail and must be read in the original paper

E L MILOSLAVICH

Technical

NEW METHOD FOR THE DETERMINATION OF THE BASAL METABOLISM OF BABIES AND OF SMALL CHILDREN HAROLD L HIGGINS and VELMA BATES, Am J Dis Child **39** 71, 1930

A chamber method for the determination of basal metabolism in babies and small children is described The advantages claimed for this method are that the periods of observation are much shorter and the results more accurate

J N PATTERSON

THE MODIFIED ARNETH AND THE SCHILLING BLOOD DIFFERENTIAL COUNTS IN TUBERCULOSIS H I SPECTOR, Am Rev Tuberc **21** 265, 1930

In comparing the Arneth and the Schilling methods it is apparent that both methods have certain advantages and disadvantages The Arneth method gives a better understanding of the shifting to the left in progressive infections, and to the right in retrogressive diseases The Schilling method would fail to detect such an infection, especially in conditions characterized by lymphocytosis Lymphocytes are an index of resistance while monocytes are an index of the extent of the anatomic lesion and in this respect the Schilling count is superior to the modified Arneth test and is of great prognostic significance since it mirrors the battle field and reflects the intensity of the fight

H J CORPER

STUDIES ON VITAL STAINING H P SMITH, J Exper Med **51** 369, 1930

A spectrophotometric method is discussed which permits quantitative analysis of colored substances present in mixtures Special attention is given to the analysis of mixtures of two dyes which are being used in a series of studies on vital staining It is shown that the method can be applied to quantitative analysis of mixtures of naturally occurring animal pigments or to mixtures of these with various other colored substances Certain limitations of the method and certain necessary precautions are discussed

AUTHOR'S SUMMARY

PRESERVATION OF RED BLOOD CELLS FOR HEMOLYTIC REACTIONS GUILFORD B REED, J Infect Dis **45** 247, 1929

Placing whole sheep's blood in Rous and Turner's mixture of isotonic dextrose and sodium citrate results in the red cells remaining intact for from eight to twelve weeks The preservation of the cells is accompanied by gradual increase in resistance to hypotonic sodium chloride and by a decrease in resistance to the hematoxin of *B welchii* and to complement-amboceptor hemolysis Attention has been directed to the use of these preserved cells in complement fixation reactions and hematoxin titrations and for the general enrichment of culture mediums The advantage, for these purposes, is purely one of convenience

AUTHOR'S SUMMARY

Society Transactions

CHICAGO PATHOLOGICAL SOCIETY

Regular Meeting, April 14, 1930

HENRY C SWEANY, *President, in the Chair*

THE INHIBITION OF DIPHTHERIA AND TETANUS TOXINS BY CYSTEINE ARTHUR LOCKE and E R MAIN

The addition of cysteine to cultures of the diphtheria and the tetanus bacillus is followed by increase in the rate of growth and decrease in the rate of toxin production Cultures that ordinarily produce 600 and 3,000 minimal lethal doses, respectively, may produce, in the presence of 0 8 per cent cysteine, less than 50 and 100 minimal lethal doses, respectively The action of the cysteine appears to be directed toward the removal from the culture medium of an essential metallic ion Evidence is presented that this ion may be Cu^{++} The copper and iron contents of a highly concentrated preparation of diphtheria toxin are described, together with those of typical aerobic and anaerobic bacteria The suggestion is made that the bacterial neurotoxins may owe their poisonous character to contents of copper-carrying respiratory substance, well adapted to further the peculiarly aerobic or anaerobic respiratory processes of the bacterial cells in which they have their origin, but intolerable to the cells of the more highly organized, less aerobic or anaerobic tissues into which they may diffuse

LYMPHANGIOMA OF THE ILEUM GEORGE MILLES

The rare occurrence of the so-called lymphangiomas or chylangiomas of the intestine has been emphasized by all authors who have considered the subject These lesions, usually found incidentally in postmortem examinations, have been discussed by Henke and Lubarsch They are described as single or multiple, discrete, pea-sized, polypoid excrescences in the mucosa of the upper half of the intestine, occurring in elderly subjects There are reports of cystic lymphangiomas that have necessitated surgical intervention Such lesions have occurred in young persons Reports of occurrence in the bowel have been made by Naumann, Michaelson and Reinecke, in the mesentery, by Rayster and by Abadie and Arguad, and in the omentum, by Graussman and Jaffe and Fischer

Naumann, in the analysis of his account mentioned that, except for the rare observation of the type described by Henke and Lubarsch, his was the first cystic lymphangioma seen in twelve years at the St George Hospital, Leipsic The patient, 23 years old, had pain in the region of the left kidney, increased by lying supine Obstipation and later symptoms resembling salpingitis were noted There was a tumor the size of a pigeon's egg in the left fornix Later, this tumor proved to be a cyst arising from the ileum and adjoining mesentery The involved loop of intestine and mesentery were resected The cyst was filled with a chylous fluid containing cholesterol and fats Microscopically, the tissues were identical with those described in my report, except for the cyst that had penetrated the muscularis

These tissues were found incidentally during the postmortem examination of a white railroad clerk aged 30 who died from extensive fibrocaseous pulmonary tuberculosis Meckel's diverticulum, distinct from the tumor under discussion, also was found A segment of the middle third of the ileum extending 6 cm in the axis of the intestine was marked off from the remainder of the bowel by its darker and more transparent appearance Scattered in it beneath the peritoneal surface were irregular white regions as large as 2 mm in diameter and resembling flecks of cottage cheese The involved portion on the lumen surface was raised

above the normal mucosa and consisted of closely arranged, soft sessible polypoid structures 5 to 10 mm in diameter They were light gray-yellow with occasional darker yellow places at the summit of some of the excrescences Scattered in these tissues were milky white flecks like those on the peritoneal surface

The polypoid growths had little normal bowel mucosa The villi, mucosa and submucosa were chiefly spaces as large as 1 mm in diameter Nowhere was the muscularis involved The spaces were lined by flat endothelial cells in a single layer In the lumina were macrophages filled with fat droplets, and surrounding these cells or occurring alone was a homogeneous lipoid material The stroma was chiefly loose fibrous tissue, with few cells and some disarranged smooth muscle fibers, the remnants of the muscularis mucosa

In the classification of this lesion I am uncertain whether it is lymphangioma or lymphangiectasis Henke and Lubarsch, in discussing the senile variety preferred to consider them lymphangiectasias rather than true tumors Histologically, they are like those described in the report by Naumann and the one that I have described Naumann, from the evidence of progressive growth preferred to consider the lesion true lymphangioma The diffuse growth with some evidence of increase in size of the lesion that I have described support Naumann's contention that these are tumors

Coal Pigmentation of the Liver with Cirrhosis S H Robertson

The liver to be described was removed by Dr Apfelbach from the body of a coal miner, aged 35 who died at the Presbyterian Hospital, Chicago from an abscess of the mediastinum communicating with the thoracic portion of the aorta and the esophagus The lungs and the tracheobronchial lymph glands contained much coal pigment

The liver weighed 1,230 Gm and was firm, and the capsule was everywhere smooth, shiny and transparent The liver lobules seen through the capsule were irregular in size and shape, from gray-white to gray-red-brown and surrounded by light gray-black regions These darker regions were associated with about one half of the lobules The liver cut with slightly increased resistance and the surfaces made by cutting were moist and glassy and did not bulge The lobules were distinct, depressed and irregular in size and shape, 3 to 6 mm in diameter and nearly uniformly surrounded by light gray-black regions in minute white-gray backgrounds The central veins were distended, and the adjacent liver cells were a darker red-purple than those more peripheral

The black pigment in sections of the liver remained unchanged when the tissues were placed in concentrated sulphuric acid, in boiling glacial acetic acid hydrochloric acid nitric acid, ammonium sulphide and concentrated potassium hydroxide

Microscopically some of the black pigment was in small deposits between unchanged liver cells and the capillary walls, and a little was contained in the Kupffer cells The usual distribution of the pigment was within bands and nodules of fibrous tissue These fibrous regions were sharply circumscribed and never completely surrounded a lobule They were chiefly in the interlobular tissues, but occurred also around central veins and at any place in a lobule The pigment and fibrous regions varied in size, many were no longer than six or seven liver cells The shape of the fibrous patches varied, but there was a general tendency to assume a long narrow shape following the course of the interlobular vessels or rows of liver cells These same regions were composed of dense hyaline fibrous tissue with few cells the cells were chiefly elongated connective tissue cells closely applied to the fibers, and many of them contained black pigment Fibrous tissue did not occur except in association with the deposits of pigment

In about one fourth of the lobules the central veins were dilated and there were indistinct liver cells surrounding the veins

This pigmentation of the liver was associated with a mild interlobular cirrhosis The chemical tests indicated that the pigment was coal pigment

William H Welch (*Bull Johns Hopkins Hosp* **1** 32, 1891), described a similar liver He stated that the character of the fibrous regions and the relationship between them and the coal pigment were the unusual features of the tissues

Alburger (*Proc Path Soc Philadelphia,* 1905) described the liver of a woman who died from pulmonary tuberculosis, in which there was coal pigmentation but only a slight increase of the interlobular connective tissue

Small amounts of coal pigment in the liver are not rare Welch stated that such deposits were reported by Arnold, Soyka, Weigert and others Weigert demonstrated that adhesions and destructive inflammations may favor the passage of this pigment from the lymph glands directly into adjacent blood vessels and probably similar alterations in the lungs do the same

Arnold mentioned the frequent association of emphysema of the lungs and coal pigment in the spleen, liver and elsewhere

DISCUSSION

E R Long Were deposits of pigment found in the spleen and mesenteric lymph nodes? Deposits in the spleen would suggest dissemination by the blood stream, whereas deposits in the mesenteric lymph nodes could indicate absorption of pigment from the bowel

S H Robertson There were large deposits of pigment in the spleen, but none in the mesenteric lymph nodes

MULTIPLE TUMORS OF THE BRAIN IN A CASE OF SYRINGOMYELIA AND SYRINGOBULBIA F D GUNN

A case of syringomyelia with syringobulbia was presented Besides cysts lined with endothelial-like cells, multiple tumor formations were found Adjacent to the cysts, a dense glia meshwork with scanty astrocytes prevailed This was gradually replaced by glioma formations composed of different types of spongioblasts, astrocytes and astroblasts Furthermore, papilloma-like protrusions of the wall of the inferior part of the fourth ventricle were found, and a proliferation of ependymal cells with invasion of the nervous tissues Finally, multiple neurinomas were found at the nerve roots arising from the medulla oblongata

DISCUSSION

A Knapp Syringomyelia occurs in geographic foci among the working class more often in men than women The cord changes may be caused by distention of the canal (hydromyelia), traumatic hemorrhage (hematomyelia) and growth of the glia (neoplastic) Were there sensory disturbances in Dr Gunn's patient, a thoracic kyphosis or disturbances in swallowing? The changes of cord and brain with syringomyelia sometimes are inconspicuous in the unfixed tissues and are demonstrated only by microscopic examinations

F D Gunn The clinical record gives no details of sensory disturbances or postural peculiarities

P C Bucy Syringomyelia is associated with tumors and hyperplasia of the ependyma A considerable part of Dr Gunn's tumor seems to consist of ependymal cells The origin of the endothelial lining of the cysts is difficult to explain There are wide variations in the cells of tumors of the brain, and sometimes such differences make the classification of a certain tumor difficult There is never a pure cell tumor but invariably a mixture, although a certain type of cell may predominate

STANDARDIZATION OF CHOLESTEROLIZED ALCOHOLIC BEEF HEART ANTIGEN FOR USE IN COMPLEMENT-FIXATION PROCEDURES EMPLOYING WARM PRELIMINARY INCUBATION B S LEVINE

Only fresh beef heart freshly ground and rapidly dried should be used in the preparation of antigen extracts The cholesterol content of the antigenic dose

should always be the same for any particular complement-fixation procedure The antigenic titer for any particular complement-fixation method should be of a fixed value An antigen used in any particular modification of a complement-fixation method is to be regarded with reasonable assurrance as of the same standard as the one in prior use only after it has yielded 100 positive and 100 negative concordant results It is evident that standardization of antigens can be done satisfactorily only in laboratories testing a large number of serums routinely

AN ELECTRICAL DEVICE FOR GRINDING TISSUE UNDER ASEPTIC CONDITIONS H O MARYAN

There are various devices for grinding tissue under sterile conditions (1) the mortar, pestle and sand, (2) Latipie's hand tissue-grinder, (3) Hirschfelder Rosenow and Nickel's tissue-crushers, and (4) Rosenow's sterile air chamber containing a mortar, pestle, sand and small meat-grinder Dr Maryan found that by these methods there were unavoidable sources of contamination through handling and the great difficulty of finely crushing the fibrous tissues Therefore, a mortar driven tissue-grinder was devised, enclosed in a vertical tubular brass air chamber The details of construction may be obtained from E V Muller & Company, Chicago

---

Regular Monthly Meeting, May 12, 1930

HENRY C SWEANY, *President in the Chair*

INTRACRANIAL NEOPLASMS IN LOWER ANIMALS MAUD SLYE, HARRIET F HOLMES and H GIDEON WELLS

A review of the literature indicates that intracranial tumors are rarely observed in lower animals of any species Especially noteworthy is the fact that but one seemingly conclusive report of a cerebral glioma in an animal could be found In 11,188 brains of mice of the Slye stock, only three primary intracranial neoplasms were found, namely, an endothelioma of a cerebral peduncle, a papillomatous growth in the ependyma of the lateral ventricle, and an infiltrating adenoma of the hypophysis Although about half the mice examined suffered from some sort of malignant tumor, in no case was an intracranial metastasis found, although in two cases of osteosarcoma, metastases were found in the skull A case of adenoma in the hypophysis of a parrakeet (*Agatornis pullaria*) is also described

MALIGNANT MIXED TUMOR OF THE THYROID GLAND WITH SKELETAL MUSCLE FIBERS EDWIN F HIRSCH

Spindle cells with the cross-striations of skeletal muscle fibers in malignant mixed tumors of the thyroid gland seem not to have been reported A primary malignant tumor of the thyroid producing metastases into many tissues of the neck trunk and bones occurred in a young man, aged 21, and in all of the growths there were mixtures of three varieties of cells, namely, small undifferentiated cells, large spindle cells with cross-striations of skeletal muscle fibers, and huge fused-cell aggregates suggesting abortive thyroid gland acini

DISCUSSION

H G WELLS In the metastases of these malignant mixed tumors there is often a separation of the two germ layer components

MULTIPLE PULMONARY ABSCESSES SIMULATING TUBERCULOSIS CAUSED BY FRIEDLANDER BACILLUS H C SWEANY, ASYA STADNICHENKO and KARL J HENRICHSEN

The clinical course, pathologic and bacteriologic observations in a fatal Friedlander bacillus infection were described The micro-organism differed from the usual type in that it grew as well or better anaerobically than aerobically, poorly on potato medium, fermented dextrose with acid and gas, and produced coagulation

The process was subacute or chronic bronchopneumonia with progressive necrosis and abscess formation with a varied type of cell reaction from lymphocytes, monocytes and plasma cells to polymorphonuclear leukocytes

The clinical aspects and roentgen appearances closely simulated chronic pulmonary tuberculosis, differing only in the general appearance of the patient and in the irregular type of temperature

CYSTADENOMA OF THE GALLBLADDER RALPH A KORDENAT

Cystadenomas of the gallbladder are usually found in women, of the average age of 40 years, complaining of symptoms of cholecystitis and cholelithiasis The tumors are rare, usually occurring in the fundus of the gallbladder They are small (1 5 cm in diameter in the instance here reported) They appear grossly as a rounded, oval elevation of a limited area of the fundus Microscopically, there are glandular acini lined with adult type of columnar epithelium without degenerative changes or evidence of reversion to the embryonic type The etiology of these tumors is not clear

DISCUSSION

E F HIRSCH These tissues are probably inflammatory hyperplasias and not true tumors

---

PATHOLOGICAL SOCIETY OF PHILADELPHIA

Regular Meeting, May 9, 1930

BALDWIN LUCKE, *President, in the Chair*

SIX CARD SPECIMENS OF COMPARATIVE SIGNIFICANCE HERBERT RATCLIFFE

The following specimens were presented an inguinal hernia in a pig-tailed *macaque*, spondylitis deformans in a leche antelope, ulcerative cholecystitis with cholelithiasis in an orang-utan, the spleen and kidneys of a cheetah showing unusual infiltrations in myeloid leukemia, and arteriosclerosis in a greater bird of paradise and in a California hair seal These specimens were taken from routine autopsy material at the Philadelphia Zoological Garden and illustrate a not widely recognized fact, namely, that wild animals in captivity regularly show disease changes similar to those of man

A CASE OF ACUTE LEUKEMIA WITH AUTOPSY B L CRAWFORD

History—On Feb 6, 1930, a white boy, aged 14, was admitted to Jefferson Hospital (service of Dr Gibbon, later transferred to that of Dr McCrae), with swelling of the neck, more marked on the left side The family history was negative The patient had enjoyed good health prior to July, 1929 In this month he had an attack of sore throat, lasting about one week Shortly afterward, on one side, the neck, face and eye became swollen over night The swelling in the neck did not disappear, and when, shortly afterward, incision was made approximately two teaspoonfuls of pus were obtained The swelling practically disappeared, but the father noted that the boy was not as vigorous or active as he had been previously, tiring easily on exertion In November, marked swelling of the face, neck and gums followed extraction of a tooth and the patient gradually grew worse, with loss of weight and strength

Physical Examination—The results of physical examination were negative, except for marked gingivitis, swelling of the gums and of both sides of the neck The temperature ranged from 99 F to 105 F The blood count on admission was hemoglobin (Dare) 42 per cent, erythrocytes, 2,700,000, leukocytes, 22,600 color index, 0 77 plus The differential count was polymorphonuclears, 6 per cent, small lymphocytes, 16 per cent, and large mononuclear, immature cells 78 per cent These large mononuclear cells had large, irregularly shaped nuclei, some of which contained nucleoli, and the cytoplasm of many of cells was finely granular Practically all these mononuclear cells contained oxydase-positive granules There was also marked change in the red blood cells, with presence of a few normoblasts and an occasional megaloblast A short time before death, the leukocyte count decreased to 11,800 The results of the Wassermann and Kahn test, of the blood were negative

Bacteriologic Studies—Two blood cultures remained sterile Smears from the mouth contained many organisms, including many spirochetes and fusiform bacilli Cultures from the lesion in the neck on one occasion contained *Staphylococcus albus* and *Staph aureus*, and on one occasion when the lesion was incised, a mixed growth of *Staph albus* and nonhemolytic *Streptococcus* was obtained

Autopsy—Autopsy was performed seven hours post mortem The gums were swollen, soft and spongy, and the teeth were in bad condition, but there was no definite ulceration of the mouth The subcutaneous tissue of the neck was swollen, nodular and edematous The pericardium and pleura contained numerous small petechial hemorrhages The lungs contained numerous, firm, circumscribed, consolidated areas throughout all the lobes The spleen weighed 300 Gm, and was uniform in color and consistency The cut surface was red, smooth and resilient Follicles were not observed A few enlarged, rather soft lymph nodes were present at the base of the neck, in the mediastinum and in the upper part of the abdomen No nodules were observed in either the spleen or the liver The bone-marrow of the lower end of the femur was markedly hyperplastic, friable and red

Histologic Examination—Sections from the lymph nodes, spleen, lungs and liver revealed a diffuse infiltration of these organs by large mononuclear cells with large, irregularly shaped nuclei In sections from the bone-marrow, the leukoblastic hyperplasia seemed to overshadow the erythroblastic element

Summary—From the presence of the immature type of cell (granulocyte) in the blood the rapidly fatal course of the illness and the infiltration of the internal organs by the large immature type of cell the diagnosis of acute myeloid leukemia was considered justified

THE RELATIVE PHAGOCYTIC ABILITY OF MONOCYTES AND POLYMORPHONUCLEARS M STRUMIA, B LUCKE, S MUDD and M MCCUTCHEON

Results of experiments in which various antigens were employed (*Bacillus tuberculosis, B coli*, sheep erythrocytes, collodion particles coated with various proteins, etc) show that serums and their fractions, immune or not, promote phagocytosis by both monocytes and polymorphonuclears in vitro There is a close parallelism in the phagocytosis-promoting effect of serums on the two kinds of cells The dilution of immune serum causing the greatest degree of phagocytosis in one kind of cell also causes the greatest degree of phagocytosis in the other Conversely, when a given dilution of serum does not induce phagocytosis in one kind of cell, it also fails to cause phagocytosis in the other The degree of spontaneous phagocytosis is different with the various particles

SURVEY OF THE HISTORY OF THE LABORATORY OF COMPARATIVE PATHOLOGY OF THE PHILADELPHIA ZOOLOGICAL GARDEN COMPARABLE DISEASES OF MAN AND WILD ANIMALS HERBERT FOX

The survey included remarks in response to the request of the president about the origin and history of the Laboratory of Comparative Pathology of the

Zoological Society of Philadelphia descriptions of the main events that have occurred in the twenty-five years of the laboratory's existence, and a special reference to the experience of eradicating tuberculosis in monkeys by the use of the tuberculin test Details of these parts have been published

Since the eradication of tuberculosis, the total death rate of monkeys falls almost uninterruptedly and falls disproportionately faster than the death rate of tuberculosis The expectation of life of all animals has increased 130 per cent The expectation of life of nontuberculous animals has increased 100 per cent This would indicate that the removal of tuberculosis, not only eliminates this cause of death, but seems to be parallel with the improvement of life expectancy of all animals Morbidity and mortality from other causes remain about the same with a slight increase in certain varieties of enteritis and degenerative bone disease

Figures indicate again the susceptibility of old world monkeys to tuberculosis, a definitely lower susceptibility of South American monkeys and marked resistance of marmosets

The subcutaneous injection of tuberculin remains the best method of making the tuberculin test Cutaneous, intracutaneous and conjunctival tests are difficult to perform and the results are unreliable

A proper cage, an experienced handler and a knowledge of the normal temperature of monkeys are essential to the success of the test

Contrastive Diseases—It is interesting to note that captive wild animals do not show clinical and pathologic evidence of rheumatic infection Microscopic structures comparable to the Aschoff body have been seen in a variety of mammals in the absence of arthritis, valvulitis and cutaneous lesions

The pathology of hypertension is not unequivocal, but if the condition can be described as chronic myocardial and valvular disease, arteriosclerosis or arteriolitis, chronic nephritis, uremia and lesions of the central nervous system, it is noteworthy that this combination is exceedingly rare, and it is therefore probable that hypertension, essential at least, does not occur in wild animals

There are few criteria on which to judge the existence of hypersensitivity If emphysema and asthenia are major indications, hypersensitivity must be exceedingly rare So, too, skin eruptions of the sensitivity type are exceedingly rare

Bronchiectasis is another rarity among wild animals Chronic bronchitis and peribronchitis are reasonably common, especially among the carnivores and rodents It is probable that lower animals do not have bronchiectasis because they do not indulge in fits of coughing with the marked inspiratory increase of pulmonary pressure and the distension of the lungs by forceful expiration

Degenerative disease of the nervous system of the tabes type and apoplexy are practically unknown Degenerative myelitis on the basis of malnutrition has been observed in the ungulates

Diet in Relation to the Degenerative Bone Diseases in Monkeys E P Corson-White

In the course of a study of the degenerative bone diseases, an analysis of the diets fed in the Gardens to the various groups of monkeys was made, especial note being made of the amount of protein, calcium and phosphorus This analysis, when reduced to the amount per kilogram of body weight per day for each variety, divided the monkeys into several groups (1) those in which the protein, phosphorus and calcium were equal to or above the amount of these substances (per kilogram of body weight per day) necessary to keep man in equilibrium, (2) those in which the protein fell below, but in which the calcium and phosphorus were above man's requirement for maintenance, (3) those in which both protein and calcium were below but in which phosphorus was above, and (4) those in which the protein and the calcium were still below, and the phosphorus was either just at or below, man's requirements for maintenance

In these groups, the degenerative bone diseases were definitely distributed In class 1 osteomalacia and hypertrophic osteitis rarely if ever occurred At times young were born and developed on mother's milk without the occurrence of rickets, even when confined to the house In class 2 osteomalacia and osteitis were rare, and when present, were slight in extent The young that were born, if fed on mother's milk, developed more or less severe rickets Class 3 showed some osteomalacia, which was never severe Young were born, but generally died early, and almost always, if they lived for any time, showed severe rickets Class 4 was apparently unable to maintain inorganic equilibrium They showed a high incidence of osteomalacia of a severe progressive type Hypertrophic osteitis also was present Young were never born, and the animals made no attempt at breeding

From this study it was concluded that diet, if not a cause of degenerative bone diseases, was at least a potent factor in their development, that the amount of protein, calcium or phosphorus per kilogram of body weight per day necessary to maintain man in equilibrium was the amount necessary to keep the other primates in equilibrium, and that the standard requirement of calcium, protein and phosphorus for maintenance of balance was probably the same in all primates

Book Reviews

A CLASSIFICATION OF BRIGHT'S DISEASE By DOROTHY S RUSSELL Price, 8 shillings, 6 pence Pp 248, with 16 plates, 2 in color Special Report Series, No 142, Medical Research Council of Great Britain London His Majesty s Stationery Office, 1929

The soundness of Richard Bright's views on the gross pathologic anatomy of the kidney and on the relation of renal pathology to the clinical state of the individual during life is attested by the fact that they still form the basis of text-book discussions of renal disease and that the classifications of nephritis attempted since the appearance of Bright's studies in 1836 have had to justify themselves in the light of his work New terms, like nephrosis and nephropathy, have been introduced and have been widely accepted They are sometimes used in such a way as to suggest that the writer does not have in mind a clear conception of the underlying renal pathology Their use has led to renewed philosophic discussion of the nature of inflammation as a general pathologic process In this discussion there is evident as wide a divergence of opinion in the interpretation of parenchymatous alterations as inflammatory reactions as in the identity or nonidentity of nephrosis and nephritis Other classifications have sought to introduce greater precision into renal pathology by the use of microscopic data that were not available to Bright

The present study is an attempt at classification based primarily on microscopic data It is, as the title indicates, a classification of Bright's disease Since the present concept of renal pathology may not include under Bright's disease all of the conditions originally described by Bright, it is necessary and proper that the author define the Bright's disease that she proposes to discuss This she does in the following words "In this paper Bright's disease is defined provisionally as an idiopathic, non-suppurative inflammation of the kidneys Those forms of nephritis that are clearly symptomatic are treated separately" As thus defined and used, Bright's disease is therefore not synonomous with nephritis, a fact that makes for difficulty in reading, since the reader may have in mind his own broader conception of nephritis, whereas the author has limited herself to a portion of the field that she terms Bright's disease The liability to confusion is increased by the fact that forms of nephritis, other than those falling within the restricted definition of Bright's disease, are discussed in a comparative manner On this point the author says "Inasmuch as all non-purulent inflammations of the kidney met with in this investigation have been described as examples either of Bright's disease or of symptomatic nephritis, and the histological changes in both groups have been compared, readers can modify our definition of Bright's disease as they wish"

A brief introductory chapter is followed by one of thirty-seven pages which is virtually a microscopic microdissection of the kidney The various alterations encountered in the glomeruli, the tubules, the interstitial tissue and the vessels are described with great minuteness Especial attention is given to the glomerulus, which is dissected into the endothelium and stroma of the tuft, the visceral and parietal epithelium and basement membrane of the capsule, the periglomerular tissue and the cavity In the discussion of "progressive changes leading to partial or complete obliteration of the capsular space and destruction of the tuft," a sharp distinction is made between "ischaemic glomerular atrophy" and "toxic glomerular atrophy," this distinction being a fundamental one in all the discussion that follows and in the final classification adopted

There next follows a chapter in which the various minute lesions described in the preceding chapter are put together, correlated and described in relation to each other as they occur in the kidney as a whole The elements of the

classification ultimately adopted begin to make their appearance in the division of the kidneys of Bright's disease into histologic types dependent on whether the inflammatory reaction is early, intermediate or late In each group there is further subdivision according to whether the reaction is mild or intense In the group with late inflammatory changes, alterations of toxic origin are distinguished from those of ischemic origin, the two kinds of lesion often being combined The gross appearances are correlated with the histologic alterations in the various types of kidneys

In chapter IV, entitled "Histological Types of Kidneys in Symptomatic Nephritis," "forms of nephritis which are found in association with various pathological conditions and are apparently symptomatic of them are described and compared with the different types in Bright's disease" It is difficult to understand the rationale of differentiating between the nephritis of a long list of diseases, infectious and otherwise, and the nephritis of Bright's disease, especially that form which the author terms toxic The reasons for such a differentiation are set forth in chapter V, "The Nature of Ischaemic and of Toxic Nephritis in Bright's Disease" In order not to be led too far afield in the realm of argumentation, one may grant the validity of terming ischemic the type of renal change that is associated with degenerative arterial changes, concerning which form "there can be little doubt that it is due to interference with the blood supply" But the following summarizing statement on toxic nephritis does not leave one much the wiser as to the essential differences between toxic nephritis of Bright's disease and symptomatic nephritis of a host of other diseases "It is clear that varieties of nephritis resembling the varieties of the toxic nephritis of Bright's disease can be caused by endogenous and bacterial poisons The term 'toxic' appears, therefore, to be amply justified for this an-ischaemic form of Bright's disease"

The two succeeding chapters discuss respectively, the clinical manifestations of the nephritis of Bright's disease classified by the histologic criteria adopted by the author and an evaluation of the histologic classification on the basis of clinical evidence The classification proposed is homologized with a clinical terminology as follows (the clinical terminology has been placed in parentheses to prevent confusion) I, Primary ischaemic nephritis (primary arteriosclerotic nephritis) II, Toxic nephritis 1, nephritis mitis (subacute hydropigenous nephritis), 2, nephritis acris in (*a*) early stage (acute nephritis), (*b*) intermediate stage (subacute azotemic nephritis), (*c*) chronic stage (chronic azotemic nephritis), 3, nephritis repens (insidious chronic azotemic nephritis)

A brief summarizing chapter that restates the author's views concludes the body of the monograph In one appendix are given the results of the renal efficiency tests, the cases being grouped according to the author's classification In another appendix are presented concise summaries of the clinical and anatomic observations of the 123 necropsies that formed the basis of the work There is a bibliography of fifty-one titles A synopsis at the head of each chapter and subtitles in the body of the chapter facilitate reading A large number of cross references in the text to other parts of the work make for ease of reference but also for difficulty in reading

The monograph presents in great detail the results of a careful histologic study of the kidney in certain forms of nephritis and attempts to correlate the clinical manifestations of such forms of nephritis with the histologic changes that form the basis of the classification adopted That the classification and terminology proposed will soon replace other recent classifications or terms introduced by Bright and in use ever since appears doubtful

THE AUTONOMIC NERVOUS SYSTEM By ALBERT KUNTZ, PH D, M D, Professor of Anatomy, St Louis University School of Medicine Price, $7 net Pp 576, with 70 engravings Philadelphia Lea & Febiger, 1929

The great significance of the autonomic nervous system both in health and in disease is becoming more and more apparent, however, a number of difficulties

confront the physician who wishes to orient himself with respect to the available scientific data on the subject From the clinical as well as the experimental aspects there is an enormous literature which is to a large extent uncorrelated The discovery of new facts has repeatedly made it necessary to give up wide generalizations previously accepted, such, for example, as the original formulations of vagotonia and of sympathicotonia Even in terminology the various authors are not in complete agreement, so that a certain confusion of terms results Of course, a considerable part of the difficulty encountered by the clinician or the experimental investigator in any attempt to survey the field of the functions and the disorders of the autonomic nervous system is due to the still imperfect knowledge of that subject But it cannot be denied that there has been a needed for a comprehensive treatise on the vegetative nervous system Such a need is now answered by Kuntz in his book on the autonomic nervous system

The author follows with only minor deviations the terminology of Langley, using the terms autonomic, sympathetic and parasympathetic The introduction contains a brief presentation of the historical development of general views concerning the autonomic nervous system, as they are so well reflected in the terminology itself the involuntary nerves, the great, medium and small sympathetics of Winslow (1732), the ganglionic nervous system of Johnstone (1764), the vegetative system of Bichat, who made a distinction between animal life and organic or vegetative life in the organism, and accordingly assumed the existence of animal and vegetative nerves (1800), Gaskell's classification of the visceral nervous system, Langley's "autonomic nervous system" a term introduced on the basis of physiologic and pharmacologic research

The first part of the book deals with the anatomy and physiology of the autonomic nervous system the macroscopic structure, the histology of the autonomic ganglion cells, the "fiber anatomy" of the autonomic system—autonomic centers and conduction pathways, the general physiology of the autonomic system with special treatment of the relationships to endocrine glands and of pharmacologic influences on the sympathetic and parasympathetic nerves, the development of the autonomic nervous system

The second part considers the relationships of vegetative innervation to the special systems of the organism the circulatory system, the respiratory system, the digestive system, the glands (including glands of internal secretion), the genitourinary organs and the involuntary innervation of the eye A special chapter is devoted to the difficult problems of the autonomic innervation of the skeletal muscles

In the third part the pathology of the autonomic system is treated First, the pathologic anatomy, especially the microscopic changes, is discussed, including neoplasms of the vegetative system There follows a survey of the whole subject of visceral sensitivity and the clinically important topic of referred pain The conception of vagotonia-sympathicotonia is outlined in a special chapter In the last two chapters the pathologic aspects of the subject are considered from a more nosologic point of view, and a survey of the surgery of the autonomic system is made

It is apparent that the author writes with a full knowledge of his subject This is especially evident in those sections which he has enriched by his own researches, notably the problem of autonomic innervation of skeletal muscles and the outline of the ontogenetic and phylogenetic development of the autonomic system There is an excellent, comprehensive bibliography In a book dealing with one of the most problematic divisions of neurology, one may see a number of points in a different light from the author Such controversial subjects can be settled only by further factual investigations As a guide to just such further research, this book should be of great use It is not only the best book available in English on the subject, but it is a useful and important addition to such standard works as those by L R Muller Schilf and Laignel-Lavastine

FILTRABLE VIRUSES AND RICKETTSIA DISEASES By EARL BALDWIN MCKINLEY Price, $4 Pp 442, with 70 plates and 7 text figures Manila Bureau of Science 1929

This book is monograph 27 of the Bureau of Science, Manila, and is reprinted from the *Philippine Journal of Science,* volume 38, 1929 It gives a review of the knowledge of the large group of diseases of man, animals of all kinds or plants that are either accepted or tentatively regarded as caused by ultramicroscopic or filtrable viruses In this group the diseases of man receive particular attention As indicated by the title, the diseases known or thought to be caused by *Rickettsia* are included in the review Since the book was published, psittacosis has been shown fairly conclusively to be caused by a filtrable virus McKinley's review is intentionally descriptive rather than analytic or critical, and shows the present state of knowledge on a given topic, e g, bacteriophage, or at least the general trend of the developments in active investigation Chapter 18, the final chapter, discusses more critically certain general phases of the virus diseases

The book is illustrated extensively by the reproduction of seventy plates from original articles, which is a highly helpful feature Each chapter is provided with a selected bibliography The author's intention to revise and expand the review, as developments may indicate, merits encouragement

Books Received

FILTERABLE VIRUS AND RICKETTSIA DISEASES By Earl Baldwin McKinley Price, $4 00 bound, $2 50 unbound Pp 442, with 70 plates and 7 text figures Manila Bureau of Science, 1929

TRAUMA, DISEASE, COMPENSATION A HANDBOOK OF THEIR MEDICO-LEGAL RELATIONS By A J Fraser, M D, Chief Medical Officer, Workmen's Compensation Board, Winnipeg Price, $6 50 Pp 524 Philadelphia F A Davis Company, 1930

HUMAN BIOLOGY AND RACIAL WELFARE Edited by Edmund V Cowdry, Professor of Cytology, Washington University, St Louis Price, $6 Pp 612, with illustrations New York Paul B Hoeber, Inc, 1930

CHILD LIFE INVESTIGATIONS THE CAUSES OF NEO-NATAL DEATH By J N Cruickshank, Medical Research Council Special Report Series, no 145 Price, 1 shilling, 6 pence, net Pp 87 London His Majesty's Stationery Office, 1930

THE ROAD TO HEALTH By C-E A WINSLOW, D P H, Professor of Public Health, Yale School of Medicine Price, $2 Pp 151 New York The Macmillan Company, 1929

THE BACTERIOPHAGE AND ITS CLINICAL APPLICATIONS By F D'Herelle, Professor of Bacteriology, Yale University School of Medicine Translated by George H Smith, Professor of Immunology, Yale University School of Medicine Price, $4 Pp 258 Springfield, Ill Charles C Thomas, 1930

COLLECTED REPRINTS FROM THE LABORATORIES OF THE MOUNT SINAI HOSPITAL, NEW YORK, 1929

BACTERIAL METABOLISM By Marjory Stephenson, M A, Associate of Newnham College, Cambridge, Member, Scientific Staff, Medical Research Council Price, $7 Pp 320, with diagrams New York Longmans, Green & Company, 1930

REVIEW OF CARBON MONOXIDE POISONING By R R Sayers, Surgeon United States Public Health Service, and Sara J Davenport, Principal Translator, United States Bureau of Mines Prepared by direction of the Surgeon General United States Treasury Department, Public Health Service Public Health Bulletin, no 195 Paper Price, 20 cents Pp 97 Washington, D C Government Printing Office, 1930

THE PROBLEMS, METHODS AND AIMS OF PATHOLOGY IN THEIR PAST, PRESENT AND FUTURE ASPECTS The Two Introductory Lectures to the Course in General Pathology at McGill University, October, 1929 By Horst Oertel Pp 28 Montreal, Canada Renouf Publishing Company

COLLECTED PUBLICATIONS FROM THE ROBERT DAWSON EVANS MEMORIAL FOR CLINICAL RESEARCH AND PREVENTIVE MEDICINE No 1 Endocrine Studies Boston, 1929

DIE BIOLOGIE DER PERSON Ein Handbuch der allgemeinen und speziellen Konstitutionslehre unter Mitarbeit zahlreicher Fachmanner Von Prof Dr T Brugsch und Prof Dr F H Lewy Lieferungen 15 and 16 Band 3 Pp 311 Berlin Urban & Schwarzenberg, 1930

THE FORTY-FIFTH ANNUAL MEDICAL REPORT OF THE TRUDEAU SANATORIUM AND THE TWENTY-FIFTH MEDICAL SUPPLEMENT FOR THE YEAR ENDING SEPT 30, 1929, TOGETHER WITH THE THIRTEENTH COLLECTION OF THE STUDIES OF THE EDWARD L TRUDEAU FOUNDATION FOR RESEARCH AND TEACHING IN TUBERCULOSIS, Trudeau, New York, 1929

ARCHIVES OF PATHOLOGY

VOLUME 10 SEPTEMBER, 1930 NUMBER 3

THE LESIONS IN EXPERIMENTAL AMEBIC DYSENTERY*

DALE L MARTIN, M D
TACOMA, WASH

In the development of knowledge of the pathologic changes in amebic dysentery as it occurs in the human being as well as in the experimental animal, few differences of opinion have arisen concerning the character of the lesions produced, particularly the advanced lesions of the bowel, which are recognized and described as ulcerations The earliest careful description of this more advanced lesion varies but little from that by the most recent investigators True, the early investigators were largely interested in the ulcerative processes of a disease that had just been recognized as having a new and specific etiology, and they studied and described largely the lesions that are now looked on as typical of amebic dysentery, namely, the sharply punched-out ulcer with elevated edges and undermined base, the "shirt-button" ulcer of the French Concerning this lesion as it appears macroscopically and microscopically, there has been little controversy

The same agreement does not prevail, however, in the attempts to explain the ability of *Endameba histolytica* to produce ulceration of the intestine Here, speculation and opinion based on controversial evidence have had to be substituted for exact knowledge Is *Endameba histolytica* always pathogenic? Does it act by the secretion of a cytolytic or proteolytic toxin or ferment, and thus loosen or destroy the cells that stand in the way of its entrance into the tissue, as thought by Dopter,[1] or does it gain entrance into the wall of the bowel by virtue of its ability to force its way between and among the cells in its path, as taught by Schaudinn?[2] Is the primary attack on the submucosa of the bowel, as believed by Councilman and Lafleur,[3] and if so, how is this tissue reached without injury to the overlying mucosa? Or is the first lesion

* Submitted for publication, March 12, 1930

1 Dopter, C Sur quelques points relatifs a l'action pathogene de l'amibe dysenterique, Ann de l'Inst Pasteur **19** 417, 1905

2 Schaudinn, Fritz Untersuchungen uber die Fortpflanzung einiger Rhizopoden, Arb a d k Gsndhtsamte **19** 547 1903

3 Councilman, W T, and Lafleur H A Amoebic Dysentery, *Johns Hopkins Hosp Rep* **2** 395, 1891

that of the mucosa,[4] and if so, does it first invade the mucosal crypts (Wenyon,[5] Kofoid[6]), or does it attack the surface of the mucosa, destroying epithelial and interstitial cells with equal facility (Dopter,[4] Christoffersen, and James[7])?

It is evident that answers to these questions cannot be found by study of the fully developed intestinal lesions, and more recent descriptions have included smaller and presumably earlier lesions, in the interpretation of which there is, again, difference of opinion It also seems unlikely that the nature and exact site of the primary attack on the part of the ameba could be determined from the evidence presented by human material alone Intestinal postmortem changes occur with great rapidity, especially in the colon, and the motility of the ameba is such that a delay of not more than an hour in obtaining the material for study might permit the occurrence of such alterations that the lesions present would fail to represent the conditions prevailing during life

Difficulties in procuring earlier and unchanged intestinal ulcers of man led to study of the lesions in the more readily controlled experimental animals Artificial production of amebic dysentery can be effected more or less at will, the time of onset can be readily determined, and the lesions for study can be procured before postmortem changes have essentially modified their appearance

Unfortunately, artificially induced amebiasis, and a study of the lesions produced in the intestinal tract of the cat, the animal most frequently used in experiments, although they contributed to knowledge of the disease, had failed, up to the time the study reported in this paper was made, to answer definitely the questions concerning the nature and the earliest point of attack of *Endameba histolytica,* even so far as the cat is concerned The intestinal ulcers of the cat suffering from amebic dysentery are similar to those of man ill with the same disease This similarity has given rise to a tendency to interpret the lesions of man in the light of those of the experimentally infected animal Difference in the disease as found in man clinically and in the

4 Dopter, C Anatomie pathologique de la dysenterie amibienne, Arch de med exper et d'anat path **19** 505, 1907 Christoffersen, D R Zur pathologischen Anatomie der Amobendysenterie, Virchows Arch f path Anat **223** 350, 1917 Kaufmann, Eduard Lehrbuch der speziellen pathologischen Anatomie fur Studierende und Aerzte, Berlin, W de Gruyter & Company, 1922, vol 1, p 608

5 Wenyon, C M Experimental Amoebic Dysentery and Liver Abscess in Cats, London School of Tropical Medicine **2** 27, 1912-1913

6 Kofoid, C A Amoeba and Man, Univ Calif Chronicle 1923, pp 149 and 291

7 James, quoted by Harris, H F Virchows Arch f path Anat **166** 67, 1901

experimental animal, as well as in the lesions presented by both, makes hazardous the unreserved application to one of them of conclusions obtained from a study of the other

Knowing that the amebic lesions of the bowel of the experimentally infected cat closely resemble those found in man ill with the same disease, but recognizing at the same time, certain significant differences that distinguish the lesions in one from those in the other, I believed that carefully conducted work with the artificially infected cat might throw light on the nature of the initial attack of *Endameba histolytica* on the intestine To this end, a series of experiments was undertaken, the nature and results of which are here presented All kinds of experimental lesions were examined, but special attention was devoted to the early lesion If the answer to this query is to be found experimentally, it should come out of the earliest lesion that still may be recognized as amebic

In the beginning of this experimental work, the first material suitable for inoculation into animals came at a time when no animal adapted to the needs of the experiment was available The attempt to maintain this material for later use led to the artificial cultivation of *Endameba histolytica,* with which study 1 of this paper is concerned Study 2 deals with the production of amebic dysentery in kittens, both by amebas artificially maintained and by amebas obtained from the stools of persons infected with *Endameba histolytica* and of kittens ill with amebic dysentery Study 3 is concerned with the intestinal lesions thus produced

1 CULTURAL METHODS

DATA FROM THE LITERATURE

In view of later developments in the cultivation of the parasitic amebas of man, it now seems probable that Cutler [8] succeeded in growing *Endameba histolytica* as early as 1918, although his work was not confirmed by others at the time, and Dobell [9] apparently did not consider his work successful His medium was such that it might have succeeded, and Boeck and Drbohlav [10] were able to grow *Endameba histolytica* on it, although poorly (see appendix to study 1) It is probable that Yoshida [11] kept the ameba of dysentery alive in his medium (see appen-

8 Cutler, D W A Method for the Cultivation of Entamoeba Histolytica, J Path & Bact **22** *22,* 1918

9 Dobell, Clifford The Amoebae Living in Man A Zoological Monograph, London, John Bale Sons & Danielsson, Ltd, 1919, pp 34 and 58

10 Boeck, W C, and Drbohlav, J The Cultivation of Endamoeba Histolytica, Am J Hyg **5** 371, 1925

11 Yoshida, Kazuyoshi The Encystment of Dysentery Amebae in Vitro, J Exper Med **28** 387, 1918

dix), although it is hard to explain the temperature at which they survived for from thirty-six to seventy-two hours No attempts were made by him to make subcultures from the strains that he used

Of the numerous attempts to cultivate the amebas parasitic in animals and man, the first to be generally accepted as a success was the cultivation of an endameba from the turtle by Barret and Smith [12] in 1924 The medium was composed of human blood serum, 1 part, and 0 5 per cent solution of sodium chloride, 9 parts The growth of the endameba was successful at both room and icebox temperature, although some strains were lost through the early overgrowth of bacteria and *Blastocystis* When the strains were established, transfers were required every two or three days at room temperature and once a week at icebox temperature Five strains were thus grown, ranging in age from several weeks to nineteen months at the time of the first report A later report by the same authors [13] told of the successful cultivation of *Endameba ranarum* for more than eight months Taliaferro and Holmes [14] compared the amebas from Barret and Smith's cultures with those of the turtle from which they were grown and succeeded in cultivating them on Loeffler's dehydrated blood serum, 1 part, and 0 5 per cent solution of sodium chloride, 10 parts

Previous to this time, many workers besides Cutler and Yoshida had attempted cultivation of the intestinal amebas parasitic in man Many mediums had been used, some with apparent success, even to the extent that amebas grown on them produced dysentery in experimental animals In spite of apparently confirmatory inoculation in animals, it is now generally believed that no one, with the possible exception of one or two observers, succeeded in growing parasitic amebas Rather it is thought that the organisms so readily grown were contaminants from the locality in which the experiments were made or were free-living amebas accidentally ingested by the patient and on their way through the intestinal tract

In 1924, the same year of Barret and Smith's work with the ameba of the turtle Boeck and Drbohlav [15] read a paper before the meeting of the American Society of Tropical Medicine The following year this

12 Barret, H P, and Smith, N M The Cultivation of an Entamoeba from the Turtle Chelydra Serpentina, Am J Hyg **4** 155, 1924

13 Barret, H P, and Smith, N M The Cultivation of Endamoeba Ranarum, Ann Trop Med **20** 85, 1926

14 Taliaferro, W H, and Holmes, F O Endamoeba Barreti, N Sp, from the Turtle, Chelydra Serpentina, a Description of the Amoeba from the Vertebrate Host and from Barret and Smith's Cultures, Am J Hyg **4** 160, 1924

15 Boeck, W C, and Drbohlav, J The Cultivation of a Pathogenic Amoeba (Entamoeba Histolytica) from a Case of Relapsed Amoebic Dysentery, Am J Trop Med **4** 440, 1924

work was published in full[10] Two mediums were used by them with apparently equal success Locke's egg-serum (L E S) medium, and Locke's egg-albumin (L E A) medium (see appendix) Each consisted of a Dorsett egg-slant overlaid with inactivated human serum and Locke's solution in the proportion of 1 8, or with 1 per cent crystallized egg albumin in Locke's solution On these mediums, they grew two strains of *Endamoeba histolytica* that showed, culturally, the essential characteristics of the pathogenic parasite and that, on inoculation into kittens, produced clinical dysentery with the amebas in the stools and also the typical ulceration of amebic dysentery with the amebas in the lesions This work was further confirmed within the same year by Andrews,[16] Kofoid and Wagener[17] Drbohlav,[18] Das Gupta,[19] Guérin and Pons,[20] Thomson and Robertson,[21] and later by many other workers

Because mediums of Boeck and Drbohlav have been found successful in the cultivation of the parasitic amebas of man, most of the subsequent work has been done with one medium, or with modifications of mediums that seemed to promise superior cultural properties As originally prepared, the hydrogen ion concentration of the mediums varied from 7 2 to 7 8, but this was quickly reduced as a result of the rapid multiplication of intestinal bacteria that are invariable contaminants of every protozoal culture made directly from the stool This necessitated the making of frequent subcultures A buffer was added by Boeck and Drbohlav[10] without result, and later, a buffer and starch were added by Drbohlav[22] working alone He substituted Ringer's solution for Locke's solution and replaced the egg-slant with a slanted N N N medium as the underlying solid portion He found that the medium, thus modified, kept the organisms alive for from ten to twenty-four days Kofoid and

16 Andrews, J M The Cultivation of Endamoeba Histolytica by Boeck's Method, Am J Hyg **5** 556, 1925

17 Kofoid, C A, and Wagener, Edna H The Behavior of Endamoeba Dysenteriae in Mixed Cultures with Bacteria and Studies of the Effects of Certain Drugs upon Endamoeba Dysenteriae in Vitro, Univ Calif Pub Zool **28**.127, 1925

18 Drbohlav, Jaroslav Presentation d'amebes dysenteriques et cultures, Bull Soc path exot **18** 121, 1925, Une nouvelle prevue de la possibilite de cultiver Entamoeba dysenteriae type histolytica, Ann de parasitol **3** 349 1925, Culture d'Entamoeba dysenteriae type tetragena minuta, ibid **3** 358, 1925 Cultures d'Entamoeba coli Loesch, 1875, Emend Schaudinn 1903, ibid **3** 364, 1925

19 Das Gupta, B M A Note on the Cultivation of an Entamoeba from a Monkey (Macacus Rhesus), Indian M Gaz **60** 323, 1925

20 Guerin, F H, and Pons, R Culture d'Entamoeba dysenteriae par le procede de W C Boeck et Jaroslav Drbohlav, Bull Soc path exot **18** 517, 1925

21 Thomson, J G, and Robertson, Andrew Notes on the Cultivation of Certain Amoebae and Flagellates of Man, Using the Technique of Boeck and Drbohlav, J Trop Med **28** 345, 1925

22 Drbohlav (footnote 18, second reference)

Wagener[17] found that a reduction of the dextrose in Locke's solution from 2 5 Gm, as used by Boeck and Drbohlav,[10] to 0 25 Gm gave a more prolonged growth As a cover fluid, they used the whites of two eggs to 1,000 cc of the modified Locke s solution and adjusted the mixture with dilute hydrochloric acid to a hydrogen ion concentration of 7 6 or 7 8 In an attempt to inhibit bacterial growth, various substances including acriflavine, were added to the medium without result In three cases of active amebic dysentery in which cultures were made by them, growth was positive in all and was carried to the fifty-fifth, the sixty-second and the eightieth transplants, respectively Subcultures were made every forty-eight hours, but by renewing the cover fluid every day, survival of amebas in one tube, for as long as nine days, occurred With but one exception, the cultures of motile forms from six cases of chronic dysentery failed to show any amebas at the end of twenty-four hours One attempt to cultivate cysts failed

Although Drbohlav[22] substituted an unnamed starch for sugar in the cover fluid, it remained for Dobell and Laidlaw[23] to work out the relative values of the various starches for this purpose Of these, the best was rice starch, which they found to be readily ingested by the amebas, and the mediums thus modified gave the most luxurious and prolonged growth observed by them up to that time (see appendix) They found, also, that the addition of acriflavine in the proportion of 1 20 000 for several generations inhibited bacterial growth and promoted richness of the amebic cultures Organisms were grown on this medium as follows four strains of *Endameba histolytica,* two from men and two from monkeys, one strain of *Endameba gingivalis*, two strains of *Endameba coli*, one from man and one from monkey, and one strain of *Endameba nana* from man and monkeys Kofoid and Wagener[24] announced that the addition of defibrinated blood to Locke's solution as the overlying fluid gave good results, and that bacteria grew less rapidly in this than in the preparations that contained human serum Of the various bloods thus used, the best was that from the rabbit, used in 0 5 per cent concentration St John[25] made use of the cultural method in the diagnosis of dysentery and found it more favorable than examination of the direct smear In his work the solid egg base was used, whereas the overlying fluid consisted of human serum or horse serum 1 part to Locke's solution, 7 parts In the latter, the sugar was

23 Dobell, Clifford and Laidlaw, P P On the Cultivation of Entamoeba Histolytica and Some Other Entozoic Amoebae, Parasitology **18** 283, 1926

24 Kofoid, C A, and Wagener, Edna H A Simplified Medium for the Cultivation of Endameba Dysenteriae, J Lab & Clin Med **11** 683, 1926

25 St John J H Practical Value of Examination for Endameba Histolytica by Culture J A M A **86** 1272, 1926

reduced to 0 1 per cent only In three cases, cysts from stools sent by mail gave positive cultural results

Craig[26] reported the successful cultivation of *Endameba histolytica* in a medium consisting only of Locke's solution, 7 parts, and inactivated human serum, horse serum or rabbit serum, 1 part The best of these was inactivated human serum In this medium, *Endameba histolytica* remained alive and mobile for eleven days, and successful transfers were made at the end of eight days Transfers made every twenty-four to forty-eight hours continued the culture for three months Later, Craig[27] announced the successful cultivation of *Endameba histolytica* in a medium consisting of inactivated human serum, 1 part, and Ringer's solution, 7 parts, and in inactivated human serum and physiologic solution of sodium chloride in the same proportions In the latter, he kept one strain alive for six weeks, with forty transfers in this time He found that Ringer's solution and solution of sodium chloride both inhibited bacterial growth, and that the amebas grown on these mediums were larger and more active than those grown on the egg mediums Craig and St John,[28] using these simplified mediums in the diagnosis of amebic dysentery by cultural methods, found that Locke's solution and serum, Ringer's solution and serum, and physiologic solution of sodium chloride and serum were equally good, and that all were better than Locke's egg serum of Boeck and Drbohlav for this purpose

Laidlaw, Dobell and Bishop[29] left the egg base out of their medium and kept the fluid portion of the original composition horse serum, 1 part, and Ringer's solution, 8 parts, with the addition of a small amount of sterile rice starch (see appendix) As a buffer, there was later added to Ringer's solution 0 2 Gm of disodium hydrogen phosphate for each 100 cc In the latter medium, amebic growth lasted for from ten days to two weeks, although transfers were made every week Four strains of *Endameba histolytica* were successfully grown on this culture medium one from man isolated three years before by Drbohlav and three from monkeys, one of the strains from monkeys being eighteen months old, one seven months old and one recently isolated

---

26 Craig, C F A Simplified Method for the Cultivation of Endamoeba Histolytica, Am J Trop Med **6** 333, 1926

27 Craig, C F Observations upon the Cultivation of Endamoeba Histolytica, Am J Trop Med **6** 461, 1926

28 Craig, C F, and St John, J H The Value of Cultural Methods in Surveys for Parasitic Amebae of Man, Am J Trop Med **7** 39 1927

29 Laidlaw, P P , Dobell, Clifford, and Bishop, A Further Experiments on the Action of Emetine in Cultures of Entamoeba Histolytica, Parasitology **20** 207, 1928

In the literature on the cultivation of parasitic amebas of man up to 1928, the impression obtained is that the artificial cultivation of parasitic amebas is comparatively simple, and that this may be accomplished on a rather wide variety of mediums This view is particularly strengthened by the work of Craig and St John,[25] who used the simplest mediums successfully in the diagnosis of dysentery by cultural methods With the exception of Kofoid and Wagener,[17] who failed to grow the ameba from six cases of chronic dysentery, and of Cutler, whose work is not generally accepted, there are only a few communications dealing with the difficulties of growing parasitic amebas The first is that of Miller,[30] who reported in 1928 that the use of Boeck and Drbohlav's medium in nineteen cases of amebic dysentery had given survival of amebas for longer than one day in two cases only He felt that there was some promise in the medium as modified by Dobell by the addition of starch, as with this preparation he had one strain of *Endameba histolytica* surviving in four successive subcultures Johns [31] said that the original Boeck's medium, modified by the addition of rice starch and acriflavine, 1 30,000, was the only medium that cultural survival of amebas for any length of time In a study of the value of cultural methods in the examination of stools for protozoal parasites, as compared with direct examination of stools, Magath and Ward [32] found agreement in the case of *Endameba histolytica* in only 47 per cent of cases and 42 per cent of stools examined They mentioned an "almost universal failure encountered in an attempt to transfer any of these cultures"

METHODS AND RESULTS

That *Endameba histolytica* might at all times be available for experiments on animals, it seemed wiser to attempt their cultivation than to depend for material on the uncertain and irregular appearance of patients who have the organism in their stools This attempt resulted in a series of experiments and observations concerning the growth characteristics of *Endameba histolytica* that appears to be of interest and value

The material used in the attempted cultivation of *Endameba histolytica* was obtained from eight patients who presented themselves at the Mayo Clinic for examination and treatment during the year 1928 (table 1) Cultivation of positive stools was not attempted as a routine,

30 Miller, M W Difficulty in Cultivation of Endamoeba Histolytica, Proc Soc Exper Biol & Med **25** 762, 1928

31 Johns, F M In a personal communication to T B Magath, in 1928

32 Magath, T B, and Ward, C B Laboratory Methods of Diagnosing Amoebiasis, Am J Hyg **8** 840, 1928

neither was there a selection of only those cases in which there was evidence of active amebic dysentery with pronounced evidence from an examination of the stools Of the eight patients from whose stools cultures were made, only five had moderately active symptoms, with stools varying from an early morning looseness to as many as fourteen stools a day On inspection of the gross specimens, some of these stools contained mucus and blood Three patients were free from intestinal symptoms at the time of examination, and one who was in the hospital with an amebic abscess of the liver did not give a history of previous dysentery or diarrhea In one patient who did not have

TABLE 1—*Data Concerning Cases Which Furnished the Material for Experiments in the Cultivation of Amebas, Results of Cultivation*

Case	Age, Yr	Sex	Where Contracted	Duration of Symptoms	Stools According to History	Cultural Strain	Growth	Comment
1	27	M	Venezuela	1 year	3 to 6 a day, with mucus and blood	A	+	
2	23	M	Indiana	3 months	Formed, no history of dysentery	D	—	Amebic abscess of liver
3	36	M	Texas	7 months	Formed	E F	+	Three months later, abscess of liver
4	48	F	India	2 years	Formed	G	+	
5	48	F	China	24 years	5 to 12 each day, watery	H	+	
6	22	F	Minnesota	2 years	Early morning looseness	I	+	
7	44	M	Indiana	2 years	3 to 4 each day, mixed with urine	J	+	
8	27	M	Illinois	2 years	5 to 14, with mucus and blood no salts previous to examination	K L	— +	

intestinal symptoms, an amebic abscess of the liver developed later From the stools of these eight patients, ten cultures were made, and growth occurred for one day or more in eight, an incidence of 80 per cent Of the eight positive growths, only three survived culturally longer than six days, or four generations, whereas one grew one day only and did not appear in the first subculture Of the three that grew the longer time, it seems reasonable to suppose that all might, with care, have been continued indefinitely, as one was lost through accident after having grown seventy-two days, and two were abandoned at the end of one hundred one and sixteen days, respectively, the purpose for which they were grown having been accomplished

The culture showing the poorest growth (strain J) which might, in fact, have been a survival only, was made from a stool that was mixed with urine (table 2)

Of the two cultural attempts that failed, one culture (strain D) was made from cysts from the solid stool of a patient (case 2) ill at the time with an amebic abscess of the liver The other culture (strain K) was the first of two attempts to grow *Endameba histolytica* from the stool of a patient (case 8) who was having from five to fourteen typical dysenteric stools a day In this instance, there was some delay in preparing the culture, and the stool, which was small, not more than 30 cc, became cold before being used The next day, from the same patient a stool that was cultivated at once gave a positive growth (strain L) that was continued for sixteen days

Of factors influencing the successful cultivation of *Endameba histolytica* from stools, it is possible that the taking of Epsom salts may be an inhibiting factor, as suggested by Craig[33] In the examination

TABLE 2—*The Artificial Cultivation of Endameba Histolytica from Man*

Strain	Source Case	Material	Growth	Generations	Days of Growth	Results of Inoculation of Animals	Comment
A	1	Motile forms	+	30	72		
D	2	Cysts	—	—	—		
E	3	Motile forms	+	1	2		
F	3	Motile forms	+	4	6		
G	4	Motile forms	+	1	2		
H	5	Motile forms	+	44	101	+	Abandoned
I	6	Motile forms	+	2	4	—	
J	7	Motile forms	—	1	1		
K	8	Motile forms	—	—	—		
L	8	Motile forms	+	8	16	+	Abandoned

of stools for parasites, the routine procedure at the Mayo Clinic calls for a preliminary dose of salts, that the material to be examined may be fluid and may contain the motile forms on which the diagnosis is made, rather than the cysts This rule may be departed from at times in the case of a patient giving a history of diarrhea Only one of the patients (case 8) whose stools were used for cultural purposes did not receive salts Consequently, the effect of a preliminary dose of salts in the inhibition or prevention of amebic growth, culturally, cannot be determined from this series

In handling my cultures, no attempt was made to determine the thermal death point of the amebas or their resistance to deleterious influences, rather, every effort was made to protect them from factors that might jeopardize their continued survival To this end, cultures were first planted as early as possible, while the stools from which the cultures were made were still fresh and warm The tubes of mediums to be inoculated, both those for the first cultures and those for all subsequent transplants, were warmed to approximately 37 C

33 Craig, C F In a personal communication to T B Magath

before the inoculations were made As soon as possible after inoculation, the tubes were placed in the incubator, which was kept at 37 C, and each time one of them was removed for any purpose it was kept out a limited length of time and was stood, during that interval, in a container of warm water

For the removal of culture material for examination or for subinoculation, a capillary pipet was used In the observations of Boeck, Kofoid and others, the amebas were found in the egg slant cultures at the lower point of juncture between the slant and the glass of the tube Dobell said that in his modified mediums the amebas were found in the starch that had gravitated to the lower part of the tube or in the groove between the solid portion of the medium and the wall of the tube As here determined, unless the starch was added only in minute quantities, the amebas were found on the surface of this collection and not in its interior This fact may help to explain a negative reading one day, followed later by a positive reading in the same tube

Subcultures from growing cultures were made at the height of growth, and this varied somewhat with each culture strain The average interval was forty-eight hours, although this was sometimes exceeded and but rarely reduced With every strain grown, most careful selection was made of the tube or tubes from which all subcultures were made, in all cases, the tube that showed the most prolific growth was selected Nor were the old tubes discarded until they were found negative Several times it was possible to prolong the growth only by going back to an older generation for cultural material, the younger having given negative results

In the cultivation of strain A, the first attempted, eighteen tubes of medium were inoculated four contained inactivated human serum and Locke's solution, 1 8, two of these with rice starch added and two without, six tubes contained inspissated horse serum (Loeffler's) with a cover fluid of serum and Locke's solution as described, three with rice starch and three without, and eight tubes contained Boeck's medium with inactivated human serum in the cover fluid, four of these with rice starch added and four without To one starch-free tube of each kind of medium used was added 0 3 cc of sterile potato extract This had no appreciable effect on the amebic growth and was used in growing one subculture only

The first reading of cultures, forty-eight hours later, showed growth graded 1 and 2 on a basis of 1 to 4 (1 indicating slight growth and 4, large growth) in the first and simplest medium, without starch There was no growth in the second group, in which the medium contained inspissated horse serum as a base Growth graded 2 and 3 occurred in all of the eight tubes containing the egg slant as a base From four of the best of the tubes showing positive growth sixteen subcultures were

made at the end of the first forty-eight hours Two days later, every one of these was negative Examination of the original tubes, however, showed that three of those containing Boeck's medium with rice starch added, and, at that time, ninety-six hours old, still showed a growth graded 2 It was from these that the strain was continued, with the use, throughout, of the same medium as a standard, with an occasional modification of it for experimental purposes

During the life of this strain, serums from the human being, the horse and the dog were used, both fresh and inactivated, without noticeable effect on the growth On several early attempts to grow the ameba in a medium free from starch, it was found that the culture soon ran out and disappeared It finally became possible to grow the ameba

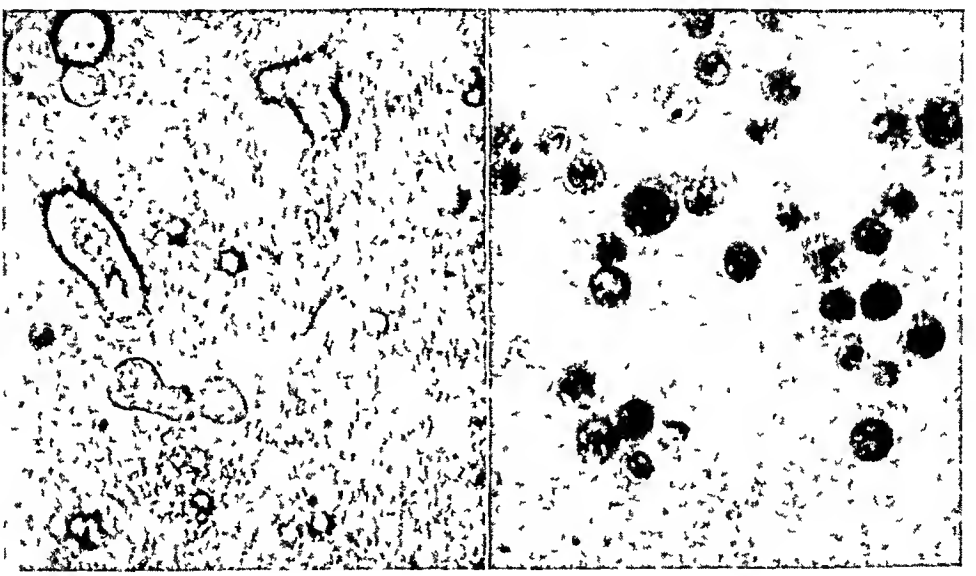

A B

Fig 1—*A* living, motile Endameba histolytica from culture (strain A) showing elongated shapes assumed by the organisms when moving across the field *B*, motile forms of Endameba histolytica from culture (strain A) fixed and stained with iron-hematoxylin, × 300

on a starch-free medium to which had been added 0 5 per cent defibrinated rabbit blood, according to the observations of Kofoid and Wagener[24] The growth here, however, was far less than in the medium that contained starch One attempt to grow *Endameba histolytica* on the simplified medium of Craig, that without the egg slant base did not result in survival in any tube at the end of twenty-four hours

Strain *A* grew luxuriantly on the Boeck and Drbohlav medium with the addition of rice starch (fig 1) Growths in many of the tubes were graded as high as 3 and 4, particularly when the strain became older It could be safely carried by inoculating only two or

three tubes each time a subculture was made It seems reasonable to suppose that this particular strain might have been continued indefinitely It was lost, however, at the end of seventy-two days, by accident, after it had passed through thirty generations or twenty-nine subcultures

Strains D, E, F and G were inoculated into the medium previously used, the medium of Boeck and Drbohlav and starch, with no growth of D and poor growth and growth of short duration of the remainder

In the cultivation of strain H, the modified medium of Boeck was used as described, except that to the overlying fluid in a portion of the tubes acriflavine was added in the proportion of 1 30,000 Later readings of these cultures showed growth graded 1 and 2 in the tubes without acriflavine, while in those with acriflavine the growth was graded 2 and 3 Subcultures from these, in the corresponding medium, continued to show growth in favor of the medium containing acriflavine, the growth was graded 4, 3, 3 and 2, respectively, in four tubes Subcultures from these four tubes, without acriflavine, showed no growth in one tube and growth graded 1 in three tubes The poorer cultures were dropped, and the strain was continued for a time with cultures in Boeck's medium and starch, to which acriflavine was added Later attempts to continue the culture in mediums free from acriflavine showed that the importance of the latter is not great after a culture is established Later, parallel cultures in mediums differing only in the content of acriflavine gave practically parallel growths

Three attempts were made to grow *Endameba histolytica* of strain H on the simplified medium of Craig one in the thirteenth generation of the strain, one in the twenty-seventh and one in the twenty-ninth On the first attempt, Locke's solution and horse serum were used in the proportion of 7 1, in the second, Locke's solution and human serum, 7 1, and in the third, 0 85 per cent solution of sodium chloride and human serum in the same proportion Readings of the first culture after twenty-four hours gave four amebas to a slide from one tube and none to a slide from a second Twenty-four hours later, growth in both tubes was negative The second attempt with Craig's medium gave grades of 1, 3 and 3 at the end of twenty-four hours, and of 2, 2 and 2 at the end of forty-eight hours Growth in these tubes and in the tubes containing subcultures from them was negative twenty-four hours later In this cultural attempt, it was found that a certain amount of the rice starch from the standard medium from the growth on which the cultures were made had been carried across to the Craig medium along with the transplanted amebas This starch was seen microscopically at the time of the first examination, both within and outside the amebas In the first subculture that was negative, starch was not visible The third cultural attempt with the Craig medium gave but two amebas in a whole slide from one tube, one ameba in each

preparation from a second tube and negative results in preparations from the third tube These cultures, as well as the subcultures from them, were negative twenty-four hours later

In the twenty-fifth generation of strain H, one of the simplified mediums of Dobell was inoculated This medium consisted of Ringer's solution, 8 parts, human serum, 1 part, and rice starch This substrain grew well for three generations, or seven days, the growths at this time were graded 3 and 4 Surprisingly, on the next day, there were no organisms in any of the tubes A second attempt, with the same simple medium in the thirtieth generation of this strain, did not show growth in twenty-four hours A third attempt, in the thirty-second generation of strain H, gave a poor growth at the end of twenty-four hours, but twenty-four hours later there was no growth in these same tubes or in those containing the subcultures from them With the use of the same medium, with the disodium hydrogen phosphate buffer added, inoculation in the thirty-eighth generation gave an amebic growth from fair to good for fifteen days, or six generations, then the strain was abandoned

Strain H grew one hundred one days, or for forty-four generations, and was dropped when the need for it was passed It never grew as profusely as strain A and was maintained with greater difficulty It seems, however, that it might with care, have been maintained indefinitely

Strain I grew poorly and for a short time only on Boeck's medium with starch added On the same medium, to which was added acriflavine, strain J, from the stool contaminated with urine, gave a poor growth in the first generation only In the same medium, strain K gave no growth As has been indicated, this stool was cold at the time the inoculation was made

Strain L was planted in three sets of mediums, one set containing Boeck's medium, with starch and acriflavine added, one containing the same, without acriflavine, and one containing inactivated human serum and Ringer's solution, without the underlying egg slant as recommended by Craig [26] In all tubes growth was present at the end of the first forty-eight hours In Craig's medium, however, growth was graded 2 as against that graded 2, 3 and 4 in the modified Boeck's medium Twenty-four hours later, Craig's medium was negative for growth, both in the original tubes and in the tubes containing subcultures from them Parallel subcultures on the egg base mediums with acriflavine modifying one set gave continuously from good to fair results for sixteen days, or eight generations, then the strain was abandoned An attempt in the sixth generation to grow the established strain on the mixture of physiologic solution of sodium chloride and serum, the

medium of Craig, showed amebas at the end of forty-eight hours, but twenty-four hours later showed no growth in these tubes or in the tubes containing the first subcultures from them

Although subcultures were made every forty-eight hours, on an average, survival in the same tube lasted as long as one hundred forty-four hours twice in strain A and once in strain H Survival for one hundred twenty hours was reasonably frequent in all strains, and several times strains were saved by inoculation from tubes containing cultures of amebas ninety-six hours old This is far from the experience of others in the field, whose cultures were maintained in the same tube for as long as twenty-four or more days, and who found it necessary to make subcultures at weekly intervals only With my cultures, survival for the longer time could never be predicated, and for the sake of safety, an interval well within the maximum was chosen

Early in the life of strain A, cysts were so common that many tubes contained a preponderance of these forms As the strain grew older, cysts became less frequent and finally disappeared, to reappear in small numbers at later and irregular intervals This is in conformity with the observations of Dobell and Laidlaw [23] on the effect of starch in the culture medium on production of cysts None of my other strains produced more than a moderate number of cysts at any time, and all fell far short of the number of cysts produced by the first strain grown Excystation was not observed, either in the fresh, living preparations or in the stained slides, but this particular activity of the culture cysts was not especially studied and might well have been overlooked although present (Dobell [34] and Yoshida [35])

In unstained preparations of the cultivated amebas, the sudden cooling produced in preparing the slide caused temporary cessation of active motility This was soon restored and lasted for half an hour or more in the same preparation, in spite of the concentration of the material due to the drying at the edges of the coverslip and of the temperature (that of the room) to which the amebas were exposed Movement was usually typically progressive, with the amebas elongated in the direction of movement (fig 1) Certain organisms, particularly the larger forms, remained in one situation and threw out clear pseudopodia in one or several directions An occasional giant form was found to stretch out until the two resulting portions were united by a thread (fig 2) In these cases, the widely separated halves were usually drawn together again It happened, however, that this fine connecting thread

34 Dobell, Clifford Further Observations and Experiments on the Cultivation of Endamoeba Histolytica from Cysts, Parasitology **19** 288, 1927

35 Yoshida, Kazuyoshi Reproduction in Vitro of Entamoeba Tetragena and Entamoeba Coli from Their Cysts, J Exper Med **32** 357, 1920

snapped while under observation, and the two resulting amebas went on their separate ways This was observed three times In one instance, the larger portion resulting from an unequal division of an ameba grown by culture, again divided in a similar manner There thus took place the division of one large ameba into three amebas of about the average size Dobell, in his extensive experience with cultivated amebas, never saw a living form divide, although he referred to York as having observed the process

Especially conspicuous in the culture preparations was that form of debris-carrying ameba originally described as *Endameba sinensis* by Faust [36] That portion of the ameba opposite the direction of movement had attached to it masses of bacteria that clung tenaciously and were not loosened by the relatively large and heavy starch granules among which

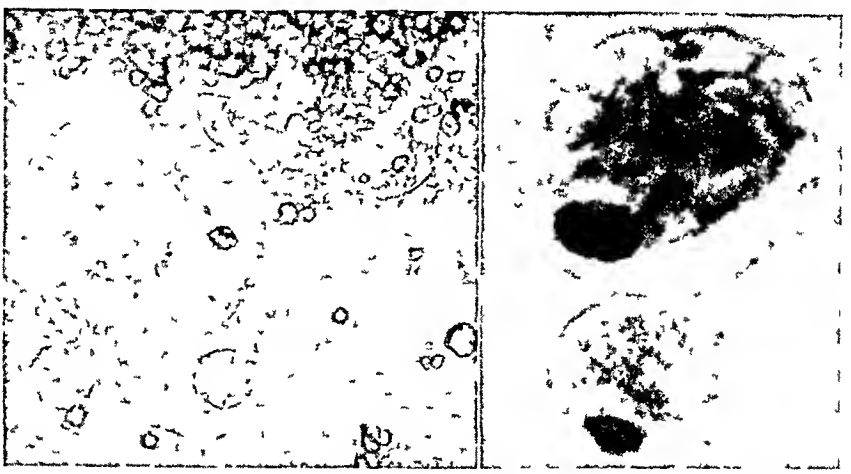

2 3

Fig 2—Living, motile Endameba histolytica from culture (strain A) showing one large, elongated ameba at the edge of a mass of starch granules This ameba was later observed to divide In the same field are two rounded, motile amebas of about average size

Fig 3—Motile forms of Endameba histolytica from culture (strain A) stained with iron-hematoxylin Differences in size are shown, whereas one only, the larger, shows an ectoplasmic margin, coarse nuclear rings and karyosomes, × 1250

it flowed Morphologically, the unstained amebas were similar to the forms described as occurring in the stools in cases of amebic dysentery The nucleus was usually visible, but inconspicuously so The size of organisms observed, however, was most variable, large and small forms were found side by side (fig 3) The ectoplasm, too, varied in a similar manner, some amebas showed a relatively large amount and

36 Faust, E C A New Type of Amoeba Parasitic in Man Observed in North China J Parasitol **9** 221, 1923

some showed little if any (fig 3) In preparations from mediums containing starch, the presence of starch granules within the amebas was conspicuous In fact, some were so loaded with starch that it appeared to be with great difficulty that they dragged themselves around At times, only careful observation made it possible to recognize that a large clump of starch granules was within an ameba In the absence of starch from the medium from which the preparation was taken, bacteria were visible within the amebas, and under this condition the amebas presented the vacuolated, granular appearance usually ascribed to *Endameba coli* These appearances in the fresh unstained preparations of amebas obtained in culture correspond to those previously observed by Boeck, Dobell, St John and others



Fig 4—Endameba histolytica from an intestinal lesion of the kitten, stained with iron-hematoxylin, showing the lightly staining cytoplasm and the delicate nuclear rim, with its small, central karyosome These are characteristics of the organism as found in lesions in tissue, × 1250

When amebas obtained in culture were stained by the iron-hematoxylin method, the starch and bacteria ingested were accentuated in the fresh preparation, and the great variation in the size of the organisms was brought out more clearly, as well as the marked differences in the amount of ectoplasm The most conspicuous disclosures of the stain, however, lay in the condition of the nucleus Here was found a heavier, more granular nuclear ring of chromatin than usually is ascribed to *Endameba histolytica* (figs 3 and 4) By this change, the nuclear ring in the cultivated organisms approached closely the appearance of the nuclear ring of *Endameba coli* In the cultivated *Endameba histolytica* this condition of the nucleus was not constant, however, and seemed to depend in part on the depth of staining Although the karyosome

showed a similar unusual heaviness, it continued to be centrally placed The occasional partial dispersion of the karyosome did not give me the impression that I was dealing with more than one species of ameba (Kofoid[37]) In the many stained preparations from all the strains grown, the giant form of York and Adams[38] was seen two or three times, although it fell far short of containing the thirty or forty nuclei described by them

The table showing the complete protocol of these strains is omitted, owing to its voluminous nature

CONCLUSIONS FROM STUDY I

In regard to culture mediums, conclusions are as follows

The original medium of Boeck and Drbohlav is best for the cultivation of *Endameba histolytica* The substitution of a sugar-free cover fluid for Locke's solution, as suggested by Drbohlav,[21] and the addition of rice starch, as recommended by Dobell and Laidlaw,[29] constitute the most valuable modifications of these basic mediums Although the effect is not striking, the addition of acriflavine to the supernatant fluid portion of the medium for the first one or two transplants may help to establish the continuous growth of cultivated amebas

Dobell's simplified medium, without solid constituents, gives variable results, indicating that older strains, modified by prolonged culture, might grow in it indefinitely

The simple mediums of Craig do not give continued growth Readings of cultures in the mediums suggest that the positive results might have been due to survival only

In regard to the cultivation of *Endameba histolytica,* conclusions are as follows

Cultivated *Endameba histolytica* usually retains its motility unimpaired Amebas artificially grown show conspicuous variations in size Under the cultural conditions of these experiments, formation of cysts is irregular and tends to appear early in the life of strains grown on mediums containing starch Ingestion of bacteria and starch granules results in the appearance of increased vacuolation in the amebic cytoplasm Variations in the amount of ectoplasm make its presence or absence of little value in the diagnosis of cultivated *Endameba histolytica* Artificially grown *Endameba histolytica* shows increased coarseness of the chromatic material of the nucleus, which causes it to

37 Kofoid, C A Councilmania Tenuis and C Dissimilis, Intestinal Amebas of Man Arch Int Med **41** 558 1928

38 York, Warrington, and Adams, A R D Observations on Entamoeba Histolytica I Development of Cysts, Excystation, and Development of Excysted Amoeba in Vitro, Ann Trop Med **20** 279, 1926

approach, in appearance, the chromatin-rich nucleus of *Endameba coli* The karyosome of the cultivated organism, however, continues to be centrally placed

APPENDIX TO STUDY I

Cutler's Medium—Cutler's mediums were prepared as follows

1 One egg was shaken and to this 300 cc of distilled water was added, the mixture was slowly brought to the boiling point on a water bath and boiled half an hour, with violent shaking throughout The material was then placed in tubes, 5 cc in each, and autoclaved To each tube was added a few drops of blood just before inoculation

2 Human blood clot to the amount of 500 cc was boiled with 1,000 cc of water for one hour To the filtrate was added 0 5 per cent sodium chloride and 1 per cent peptone This mixture was tubed and steamed for twenty minutes on three successive days A few drops of blood were added just before use

Yoshida's Medium—Yoshida[11] tried several mediums, but only one giving "good" results was described Ringer's solution, 4 parts, was added to horse serum, 1 part, and a few erythrocytes The inoculated tubes were incubated at 22 and 27 C

Boeck and Drbohlav's Mediums—Boeck and Drbohlav's mediums were prepared as follows

1 Locke's egg-serum (L E S) was prepared as follows Four eggs were washed, brushed with alcohol, then broken and added to 50 cc of Locke's solution The material was then tubed, slanted in an inspissator at 70 C until solid, then autoclaved at 15 pounds (6 8 Kg) pressure for twenty minutes To the prepared slants was added a mixture of inactivated human blood serum and Locke's solution in the proportion of 1 8 This was added in an amount sufficient to cover the slant to a depth of about 1 cm above the highest part

2 Locke's egg-albumin (L E A) was the same medium as Locke s egg-serum (L E S), except that the cover fluid was a 1 per cent crystallized egg albumin in Locke's solution Locke's solution, as used by Boeck and Drbohlav, was made as follows Distilled water, 1,000 cc , sodium chloride, 9 Gm , calcium chloride, 0 2 Gm , potassium chloride, 0 4 Gm , sodium bicarbonate, 0 2 Gm , and dextrose, 2 5 Gm The medium had a p_H of from 7 2 to 7 8 and served best when incubated at 37 C

Drbohlav's Medium—In Drbohlav's medium, "ovomucoid" solution composed of modified Ringer's solution was used as a cover fluid, to which was added a buffer, and the whole was adjusted by the addition of sodium hydroxide or potassium hydroxide to a p_H of 7 4 The buffered Ringer's solution was made as follows Distilled water, 1,000 cc , sodium chloride, 6 Gm , potassium chloride, 0 1 Gm , calcium chloride, 0 1 Gm , sodium bicarbonate, 0 1 Gm , and monopotassium phosphate, 5 Gm To this was added the white of one egg so carefully handled that the resulting mixture was used without filtering to sterilize For the solid portion, one of the following three mediums was used, the best being the one containing starch (1) Ringer's solution buffered as described (p_H 7 4), 1,000 cc , and agar, 14 Gm , autoclaved for thirty minutes, tubed and slanted, (2) same as 1, except that blood of any animal was added, and the mixture tubed, slanted and steamed at 100 C for thirty minutes, and (3) same as 1, except that starch, 14 Gm to the liter, was added This was autoclaved thirty minutes, tubed and slanted To each solid medium was added "ovomucoid" solution to cover the slant

Dobell and Laidlaw's Medium—In Dobell and Laidlaw's medium, for the solid medium already in use, inspissated horse serum slant (Loeffler's) was substituted and found satisfactory For cover fluid, ovomucoid solution containing the whites of four eggs to 1,000 cc of Ringer's solution (modified) was used, horse serum and Ringer's solution (modified) were used in the proportion of 8 1 Just before inoculation, a small amount of sterilized rice starch was added to all mediums used The modified Ringer's solution was made as follows Distilled water, 1,000 cc , sodium chloride, 9 Gm , potassium chloride, 0 2 Gm , and calcium chloride, 0 2 Gm To sterilize the rice starch, a small amount of loose, dry starch (from 2 to 2 5 Gm) was added to each of several test tubes These were corked and heated to 180 C dry heat for one hour

Laidlaw, Dobell and Bishop's Medium—The modified Ringer's solution of Dobell and Laidlaw was used, and a small amount of sterilized rice starch Later, this was modified by adding, to the Ringer's solution for a buffer, 2 Gm of disodium hydrogen phosphate

Craig's and Craig and St John's Mediums—The mediums of Craig and of Craig and St John are given in the body of the text

Technic—For the purpose of fixing amebic stools and amebic culture slides for staining, Schaudinn's fluid was used at room temperature only

In experiments with Heidenhein's technic for staining with iron-hematoxylin, it was found that immersion of the slide in 0 5 per cent aqueous solution of hematoxylin for half an hour was adequate, when the slide had been mordanted for half an hour in an aqueous solution of iron-alum

2 INOCULATION OF ANIMALS

DATA FROM THE LITERATURE

The first recorded successful attempt to infect an animal with amebic dysentery by inoculating it with ameba-containing material was made by Losch[39] (1875) At first, he fed three dogs and gave them rectal injections of the freshly passed stool of a patient who had active amebic dysentery Infection did not result In an attempt to prepare the bowel for the ready invasion of the injected amebas, he gave a fourth dog a preliminary dose of croton oil When the immediate effects of this had subsided, he introduced into the colon of this animal, by rectal injection, on each of three successive days, a freshly passed ameba-containing dysenteric stool Although the dog remained clinically well, on the eighth day, examination of the stool disclosed the presence of motile amebas resembling those injected Eighteen days after the last injection, the dog was killed, and motile amebas indistinguishable from those contained in the injected human stool were found in the ulcerative lesions of the colon

Uplavici[40] obtained only two positive results in inoculations of seventeen dogs The use of cats, however, gave four infections in the

39 Losch, F Massenhafte Entwickelung von Amoben in Dickdarm, Virchows Arch f path Anat **65** 196, 1875

40 Uplavici, O (Hlava, O), quoted by Kartulis (footnote 41)

six animals used Negative results were reported from the inoculation of eight young dogs, two chickens and six guinea-pigs The methods used by Uplavici were not detailed, but the results with the cat indicated that it is rather highly susceptible to infection with *Endameba histolytica*

Kartulis[41] reported on the results in three cats of rectal injection of human dysenteric stool containing large numbers of motile amebas One of the three cats had an infected stool in two days and died of dysentery in fourteen days Postmortem examination of the cat did not disclose definite ulceration, but widespread erosion of the colon, with punctate hemorrhages The other two cats remained normal Some doubt is cast on the validity of the observations because of the results obtained by the same author with cultures of these amebas He inoculated the amebas of dysentery into a simple straw infusion, and claimed to have found them, later, growing among the numerous bacteria on the surface of this fluid in a weblike pellicle That the organisms obtained here were free-living forms is evidenced by the nature of the culture medium, their situation on the surface of it and their ability to excyst after a lapse of time as great as four months With this material for injection, Kartulis reported the production of amebic dysentery in cats He further reported positive intestinal lesions in one of three cats each of which was given a rectal injection of a pure (bacteria-free?) culture of the amebas of dysentery in the third cultural generation Feeding experiments with cultivated cysts gave negative results In spite of the great probability that Kartulis did not produce amebic dysentery in animals by the injection of his cultivated amebas, he introduced into his experiments the control element of first examining the stool of the animal to be used, in order that native parasitic amebas found in it should not add an element of confusion to the result He gave each animal a preliminary dose of morphine, and in two instances sewed the anus of the inoculated animal with catgut to prevent the early expulsion of the injected material These sutures were removed at the end of two and three days

Kovacs[42] continued the use of cats in the experimental production of amebic dysentery He introduced material from the dysenteric stool of two patients into the bowels of cats, both by enema and by injection of the infectious material directly into the small bowel by means of a needle In some instances, the anus of the animal was closed by suture for twenty-four hours following the inoculation He found the ameba-containing stool of patients to be infectious for cats only during the

41 Kartulis, S Einiges uber die Pathogenese der Dysenterieamoben, Centralbl f Bakteriol **9** 365, 1891

42 Kovacs, F Beobachtungen und Versuche uber die sogenannte Amoebendysenterie, Ztschr f Heilk **13** 509, 1892

period of active dysenteric symptoms For diagnosis, fecal material of the suspected animal was obtained by the introduction of a glass rod into the rectum

This work was later extended and continued by a long line of investigators (Quincke and Roos,[43] Kruse and Pasquale,[44] Marchoux,[45] Craig,[46] Werner,[47] Dale and Dobell,[48] Sellards and Leiva [49] and others), all confirming, in part, the previous work of pioneers in the field, amplifying and modifying it

Kruse and Pasquale [44] reported on the rectal injection into forty kittens of stools from clinical cases of amebic dysentery They were the first to inoculate kittens successfully by rectal injection of pus from an amebic abscess of the liver Marchoux,[45] and Strong and Musgrave [50] also succeeded in producing dysentery by rectal inoculation of cats with material obtained from tropical abscess of the liver The latter produced intestinal lesions in both of two cats used, one showing definite lesions of the colon in two days, the other presenting more advanced lesions in five days The pus from the amebic abscess of the liver used was found to be free from bacteria, both on direct examination and on culture Later attempts (Werner,[47] Wenyon [51]) to inoculate cats by the rectal injection of ameba-containing pus from amebic abscesses of the liver failed

Quincke and Roos [43] mentioned the kitten rather than the cat as their experimental animal, and were the first to recognize and describe

43 Quincke, H, and Roos, E Ueber Amoben-Enteritis, Berl klin Wchnschr **30** 1089, 1893

44 Kruse, Walther, and Pasquale, Alessandro Eine Expedition nach Egypten zum Studium der Dysenterie und des Leberabscesses, Deutsche med Wchnschr **354** 378, 1893, Untersuchungen uber Dysenterie und Leberabscess, Ztschr f Hyg u Infectionskrankh **16** 1, 1894

45 Marchoux, M Note sur la dysenterie des pays chauds, Compt rend Soc de biol **51** 870, 1899

46 Craig, C F Observations Upon Amebas Infecting the Human Intestine, with a Description of Two Species, Entamoeba Coli and Entamoeba Dysenteriae, Am Med **9** 854, 897 and 936, 1905

47 Werner, Heinrich Studien uber pathogene Amoben, Arch f Schiffs-u Tropen-Hyg **12** 1, 1908

48 Dale, H H, and Dobell, Clifford Experiments on the Therapeutics of Amoebic Dysentery, J Pharmacol & Exper Therap **10** 399, 1917

49 Sellards, A W, and Leiva, L Investigation Concerning the Treatment of Amoebic Dysentery, Philippine J Sc **22** 1, 1923 The Effect of Stasis in the Development of Amoebic Dysentery in the Cat, ibid **22** 39 1923

50 Strong, R P, and Musgrave, W E Preliminary Note Regarding the Etiology of the Dysenteries of Manila, Annual Report of the Surgeon General, U S Army, 1900, p 251

51 Wenyon, C M Protozoology, New York, William Wood & Company, 1926, pp 225-234

the encysted form of *Endameba histolytica* After feeding the cyst-containing stool from human beings to four kittens from two to nine days after the stool was passed, they demonstrated the development of amebic intestinal ulceration in two animals They found the feeding of stools containing only the motile forms of *Endameba histolytica* to be without effect Schaudinn[2] fed two cats the dried stools of a patient who had amebic dysentery One became infested in three days and showed at death, lesions of amebic dysentery The second likewise became ill, but recovered in four weeks A third cat was fed the infected stool of an infected animal without effect Four weeks later, this cat was fed a dried stool from a dysenteric patient, and intestinal amebiasis developed Schaudinn first clearly recognized and described two species of parasitic amebas in man, the harmless *Endameba coli* and the pathogenic *Endomeba histolytica* He recognized the cysts of the former, but believed that *Endameba histolytica* produced only a resistant spore

In marked contrast with the observations of Quincke and Roos and Schaudinn, Craig[46] reported that when half-grown kittens were fed with stools from dysenteric patients, 65 per cent of the animals showed amebic dysentery as compared with 50 per cent of animals that were given rectal injections of the same material The results of his feeding experiments are unexplained, unless the cysts of *Endameba histolytica* were actually present but unrecognized, since, at that time, following the teaching of Schaudinn, he doubted that *Endameba histolytica* encysts He recognized the cysts of *Endameba coli,* however, and feeding experiments conducted with them gave negative results Werner,[47] on the other hand, was unable to infect animals by feeding them with the motile forms of *Endameba histolytica* or of *Endameba tetragena* (organisms which he felt to be identical) either from human beings or from cats recently dead of amebic dysentery Huber[52] found the feeding of trophozoites to be innocuous Schimura[53] who recognized the cystic forms of *Endameba histolytica,* found the incidence of infections resulting from feeding experiments conducted with them to be 50 per cent as contrasted with an incidence of 90 per cent in cases in which the motile forms were injected rectally

In the feeding experiments for the production of infection with endamebas, the classic work of Walker and Sellards[54] should occupy

52 Huber Untersuchungen uber Amobendysenterie, Ztschr f klin Med **67** 262, 1909

53 Schimura, Sohei A New Non-Pathogenic Tetragenous Ameba, J Exper Med **28** 415, 1918

54 Walker, E L, and Sellards, A W Experimental Entamoebic Dysentery, Philippine J Sc **8** 253, 1913

first place in importance if not in point of time, because of the significance of the results obtained Their work, instead of being done on the usual experimental animal, was done on men, volunteers from among the native prisoners of a Philippine prison Of the sixty men used, twenty were fed free-living amebas and the cysts of free-living amebas, without result Twenty were fed cysts and motile forms of *Endameba coli,* and the organism appeared in the stools of seventeen in from two to eleven days Neither of these groups presented any intestinal symptoms of infection Finally, twenty men were fed the cysts and motile forms of *Endameba histolytica* Of these, seventeen had stools containing *Endameba histolytica* after the first feeding, whereas one required three feedings to establish parasitization and two remained uninfected In four of the group in whose stools *Endameba histolytica* was found, amebic dysentery developed, but they recovered from it It was clearly shown that *Endameba coli* and *Endameba histolytica* may become established as parasites in the colon of man, through his ingestion of the cyst forms Feedings of the motile forms of these organisms did not show conclusively, however, that they might not also be infectious following ingestion Strangely enough, attempts to inoculate animals with *Endameba histolytica,* both by feeding of cysts and by rectal injection of motile forms, did not result in infection in seven monkeys, two cats, six kittens and one pig

Marchoux [45] was the first to carry amebic dysentery from animal to animal by inoculating one animal with the infected stool of another He spoke of the ease with which the cat is thus infected, and succeeded in carrying one strain of *Endameba histolytica* through nineteen animal passages Wenyon,[45] using stools of human beings containing cysts and motile forms of *Endameba histolytica* to infect the first animal, carried one strain through four subinoculations in cats Similar propagation of animal dysentery, by inoculation from animal to animal, was carried out by Darling,[55] Dale and Dobell, Mayer,[56] Sellers and Leiva [57] Werner, Wagener [58] and others Attempting to insure the survival of animal strains of *Endameba histolytica,* Sellards and Baetjer [59] introduced the motile forms of this organism into the cecum by means of

55 Darling, S T The Identification of the Pathogenic Entamoeba of Panama, Ann Trop Med **7** 321, 1913

56 Mayer, Martin Klinische, morphologische und experimentelle Beobachtungen bei Amobenerkrankungen, Arch f Schiffs-u Tropen-Hyg **23** 172, 1919

57 Sellards and Leiva (footnote 49, first reference)

58 Wagener, Edna H A Precipitin Test in Experimental Amoebic Dysentery in Cats, Univ Calif Pub Zool **26** 15, 1924

59 Sellards, A W, and Baetjer, W A The Propagation of Amoebic Dysentery in Animals and the Recognition and Reproduction in Animals of Atypical Forms of the Disease, Am J Trop Dis **2** 231, 1914

a needle In this way, they carried one strain through eleven generations of cats with positive infections resulting in about 100 per cent as contrasted with positive infections in 65 per cent of animals that received injections by rectum Sellards and Leiva [60] went a step further in the operative inoculation of animals In addition to the injection of the infective material into the cecum by means of a syringe and needle, they ligated the bowel at various levels below this point and reported the production of dysenteric lesions above the ligature in all of three kittens used They emphasized the value of stasis for the production of infection in the animals that were given injections Sellards and Theiler [61] carried out the same operative procedure with the introduction of the cysts of *Endameba histolytica,* and demonstrated the ability of the parasite to excyst within the colon of the experimental animal

Early experimental work tending to show that *Endameba histolytica* and *Endameba tetragena* are probably environmental modifications of the same organism was that of Werner [17] In the attempted propagation of animal strains by inoculating one animal with the positive stool of another, he succeeded in carrying three strains of *Endameba tetragena* through five, three and one animal passages and carried one strain of *Endameba histolytica* through six

Cutler [8] was the first to succeed with cultures of *Endameba histolytica* for inoculation into animals Although some have doubted that Cutler was able to grow *Endameba histolytica,* it is now known that he may have grown them and probably did (see study 1) His cysts in cultures given by mouth infected five of the six kittens used, whereas rectal injection of the motile forms, from culture, infected the only kittens used The cultivated organisms of Boeck and Dirbohlav [10] and of Drbohlav [62] were found to be infectious With them, the rectal injection of motile forms of *Endameba histolytica* from culture produced amebic dysentery in 65 per cent of the sixteen kittens used It was their observation that length of life under cultivation did not modify infectivity The recent work of Kessel [63] confirmed the observations of previous workers with reference to the infectiousness of cultures of *Endameba histolytica*

Dobell and Laidlaw [23] reported that the addition of rice starch to the culture medium in which *Endameba histolytica* is grown apparently destroyed their infectivity for cats They gave seven cats rectal injec-

60 Sellards and Leiva (footnote 49, second reference)

61 Sellards, A W, and Theiler, M Investigations Concerning Amoebic Dysentery, Am J Trop Med **4** 309, 1924

62 Drbohlav (footnote 18, third reference)

63 Kessel, J F Amoebiasis in Kittens Infected with the Dysentery Amoeba from Acute and Carrier Human Cases and with the Tetranucleate Amoeba of the Monkey and the Pig, Am J Hyg **8** 311, 1928

tions of the thirteenth subculture of *Endameba histolytica* grown in a starch-containing medium, with negative results in all It was their belief, based on the results obtained with one inoculated animal, that this infectivity, once lost, could not be restored by cultivation on mediums free from starch That the conclusions of Dobell and Laidlaw are not strictly justifiable was shown by Rees,[64] who introduced the motile forms of *Endameba histolytica* grown on starch-containing medium into the bowels of experimental animals in which the colon had been occluded by ligature near the rectum In this way, he produced infection with *Endameba histolytica* in about 50 per cent of the animals used

Abscess of the Liver in Experimental Animals—The development of abscess of the liver in artificially infected animals was first described by Marchoux[45] in the case of a cat that died of amebic dysentery Similar observations were reported later by Craig,[46] Werner, Huber, Wenyon,[5] Dale and Dobell, Mayer and others Harris[65] observed abscesses of the liver in two of three very young dogs inoculated rectally with stool from a dysenteric patient

Special Methods—Special methods of handling the experimental animals have included the administration of a preliminary cathartic (Losch, Rees[66]), preliminary starvation (Rees[66]) and the administration of an anesthetic for the injection of infectious material, both for operative introduction and for simple injection through a catheter by rectum (Sellards and Leiva,[49] Sellards and Theiler, Rees,[67] Sanders[68]) Attempts to produce stasis after inoculation have varied from the simple expedient of holding the cat head down for a few minutes after the injection (Dale and Dobell), through temporary plugging of the anus (Boeck and Drbohlav[10]), suture of the anus (Kartulis,[41] Kovacs[42]) and ligation of the bowel below the site of operative injection (Sellards and Leiva,[60] Sellards and Theiler,[61] Rees[69]) In only one case was stool from a dysenteric patient injected directly into the liver of an animal (Werner[47]) This was done in a guinea-pig, with negative results

---

64 Rees, C W Experimental Amoebiasis in Kittens, J Parasitol **14** 125, 1927, The Infectivity and Pathogenicity of a Starch-Fed Strain of Endamoeba Histolytica, ibid **15** 131, 1928

65 Harris, H F Experimentell bei Hunden erzeugte Dysenterie, Virchows Arch f path Anat **166** 67, 1901

66 Rees (footnote 64, first reference)

67 Rees, C W Pathogenesis of Intestinal Amebiasis in Kittens, Arch Path **7** 1, 1929

68 Sanders, E P Changes in the Blood Cells of Kittens Resulting from Infections with Endamoeba Histolytica, Am J Hyg **8** 963, 1928

69 Rees (footnote 64, second reference, footnote 67)

Animal to Animal Inoculation—Infection carried from animal to animal by rectal inoculation with the stool of the infected cat resulted in the widest possible variations both in the incidence of "takes" and in the number of animals through which the different strains of *Endameba histolytica* were carried Werner maintained 3 strains of *Endameba tetragena* for 5, 3 and 1 passage, respectively, and 1 strain of *Endameba histolytica* for 6 passages Wenyon[5] carried a strain obtained from the stool of a human being through 4 passages By operative inoculations, Baetjer and Sellards[70] carried 2 strains of *Endameba histolytica* from men for 11 generations Wagener and Thomson[71] carried *Endameba histolytica* from the stool of the human being through 6 passages by the use of 23 cats In marked contrast with these modest results are the reports of Marchoux, who carried 1 strain through 19 passages, of Mayer, who carried 3 strains through 32, 39 and 49 passages, respectively, with positive results in 86 5 per cent of 126 kittens used, and of Dale and Dobell, who carried 1 strain of *Endameba histolytica* through 43 animal passages in 120 kittens In the work of the latter, amebic infection failed to develop in only 12 of 139 kittens The high proportion of infections obtained by Dale and Dobell may be due, in part, to the fact that their material for inoculation was obtained by washing the opened bowel of a recently killed dysenteric animal with 0 9 per cent solution of sodium chloride and adding the scraping of the mucosa to obtain a rich suspension of *Endameba histolytica*

Incubation—The period of incubation, as determined for the commonly used cat, varied from one day (Dale and Dobell, Wagener and Thomson) to twenty (Baetjer and Sellards[70]) This varied definitely with the age of the animal (Sellards and Leiva[57]), and was shorter in those which were younger It varied, also, with the nature of the inoculation, being longer in animals inoculated by the feeding of cysts (Dale and Dobell) In the attempt to fix more accurately the time of onset of amebic infection in the experimental animal, Sellards and Leiva[57] did not rest the diagnosis on the examination of stools passed spontaneously, but determined the onset of infection by the examination of stools obtained by means of an enema Kovacs accomplished the same end by the use of a glass rod inserted into the rectum of the animal that had been given the injection

Modification of Virulence of Endameba Histolytica—Widely varying opinions are held concerning the effects of passage through animals

70 Baetjer, W A, and Sellards, A W Continuous Propagation of Amoebic Dysentery in Animals, Bull Johns Hopkins Hosp **25** 165, 1914

71 Wagener, Edna H, and Thomson, Margaret D Experimental Amoebiasis in Cats from Acute and Chronic Human Cases, Univ Calif Pub Zool **26** 267, 1924

and of artificial cultivation on the virulence of *Endameba histolytica* Respecting the effects of passage through animals, it is believed, on the one hand, that this increases the infectivity of the protozoon (Baetjer and Sellards,[70] Meyer, Sellards and Leiva [57]), and on the other hand, that passage decreases its infectivity (Werner, Darling [55]) Darling ascribed the loss of virulence to the gradual reduction in size of *Endameba histolytica* by passage through animals, until it finally reaches a uninucleated cyst stage in the fourth or fifth subpassage, after which it ceases to be infectious Wagener expressed the belief that virulence is unaffected Cultural modification of *Endameba histolytica* was seen by Sanders, who observed loss in the infectivity of *Endameba histolytica* grown artificially Boeck and Drbohlav [10] did not find a change after prolonged cultivation, whereas Dobell and Laidlaw found complete, unrestorable loss of virulence in *Endameba histolytica* grown on starch-containing mediums

Wagener and Thomson alone found the resistance of the experimental animal to infection with *Endameba histolytica* to be increased by previous attempts at inoculation

Choice of Experimental Animal—In attempted inoculations of animals with *Endameba histolytica,* the dog and the cat usually have been used Darling [72] described spontaneous dysentery in the dog due to *Endameba histolytica,* but usually the dog has been somewhat refractory to infection with this organism (Losch, Uplavici) The cat, and particularly the young kitten, became the animal of choice This animal is easy to procure and is highly susceptible to infection with *Endameba histolytica* and presents, when infected, ulcerative intestinal lesions closely resembling those of man The guinea-pig, although frequently used (Uplavici, Werner, Baetjer and Sellards,[73] Chatton,[74] Wagener and Thomson), has proved refractory, when infected, this animal does not present symptoms of dysentery, and shows a peculiar tumor-like lesion of the involved bowel rather than the usual ulceration (Baetjer and Sellards,[73] Chatton [74]) Only two have reported the development of amebic lesions in the inoculated rabbit (Huber, Thomson [75]) This animal remained free from intestinal symptoms and the intestinal lesions

72 Darling, S T Entamoebic Dysentery in the Dog, Proc M A Isthmian Canal Zone **6** 60, 1913

73 Baetjer, W A, and Sellards, A W The Behavior of Amoebic Dysentery in Lower Animals and Its Bearing upon the Interpretation of the Clinical Symptoms of the Disease in Man, Bull Johns Hopkins Hosp **25** 237, 1914

74 Chatton, E Realisation experimentale chez le cobaye de l'amebiase intestinale a'Entamoeba dysenteriae, Bull Soc Path exot **10** 794, 1917, L'amebiase intestinale experimentale du cobaye a Entamoeba dysenteriae, Arch Inst Pasteur de Tunis **10** 138, 1918

75 Thomson, Margaret D Experimental Amoebiasis in the Rabbit, Univ Calif Pub Zool **29** 9, 1926

that developed were far from comparable with those of the human being The monkey has been used occasionally (Walker and Sellards, Dale and Dobell, Kessel[63]), but is subject to the development of spontaneous dysentery and has within its intestinal tract parasitic amebas that are indistinguishable from those of man and that are believed (Dobell and Laidlaw) to be identical with them The rat has been used in the experimental production of amebic dysentery by many (Werner[47] Wagener and Thomson, Brug,[76] Lynch,[77] Kessel,[78] Chiang[79]) The work of Lynch[77] and of Chiang tended to show that the monkey may be a carrier of *Endameba histolytica*, at least, with the mouse (Kessel[80]), it frequently harbors confusing parasitic intestinal amebas Less frequently used animals are the chicken (Uplavici) and the pig (Walker and Sellards, Wagener and Thomson, Kessel[63])

In the literature dealing with animals for experimental production of amebic dysentery, the terms "cat" and "kitten" have been loosely used, the general term "cat" often including the kitten even when this is not expressly indicated.

The domestic cat, as found throughout the world, varies widely in appearance and actions and may present enough differences in resistance to infection with *Endameba histolytica* to explain, in part, the varying results obtained by investigators working with the native cats of widely separated countries So far, no investigator has named the species of cat used by him in his experimental work Chatton[81] alone remarked on the special resistance of the native cats of south Tunis to infection with *Endameba histolytica* Until it is shown that the domestic cat, wherever found, offers approximately the same resistance to experimental amebic dysentery, the results of experiments in inoculation conducted with *Felis chaus* of China or of *Felis manual* of Egypt should not be compared uncritically with those obtained with the domestic cat of America (*Felis domestica*)

In my selection of the animal best suited for the experimental work to be undertaken, everything pointed toward the kitten Although for all the commoner laboratory animals native parasitic intestinal amebas

76 Brug, S L, quoted by Wenyon (footnote 5)

77 Lynch, K M The Rat a Carrier of a Dysenteric Amoeba, J A M A **65** 2232, 1915

78 Kessel, J F Methods of Obtaining Amoeba-Free Rats for Experimental Infection with Intestinal Amoeba, Univ Calif Pub Zool **20** 401, 1923, Experimental Infection of Rats and Mice with the Common Intestinal Amoebae of Man, ibid **20** 409, 1923, The Distinguishing Characteristics of the Parasitic Amoebae of Culture of Rats and Mice, ibid **20** 490, 1924, footnote 63

79 Chiang, S F Study of Parasitic Amoebae by Experimental Cross Infection of Laboratory Animals, Nat M J China **11** 440, 1924-1925

80 Kessel (footnote 78, second and third references)

81 Chatton (footnote 74, first reference)

have been described (Hegner and Taliaferro,[82] Craig,[83] Wenyon,[51] Knowles [84]), certain authors excluded the cat from the list of animals enumerated (Craig,[83] Hegner and Taliaferro, Wenyon [51]) Among 150 kittens obtained from the streets of Peiping, Kessel [63] found 3 ill with amebic dysentery Wenyon [51] was of the opinion that the only ameba of the cat is the true *Endameba histolytica* This comparative freedom of the cat from native amebiasis, the availability of the animal, the ease with which it is handled, its susceptibility to infection with *Endameba histolytica* and, finally, the character of the intestinal amebic lesions, determined my choice

TABLE 3—*Data Concerning Cases Which Furnished Material for Inoculation of Animals, Results of Inoculations*

Case	Age, Yr	Sex	Where Contracted	Duration of Symptoms	Stool According to History	Forms Used	Animals Used	Amebiasis in Kittens
9	38	F	Texas	No definite number of days	Formed	Motile forms and cysts	4	Absent
10	25	M	Mexico	3 months	Formed	Cysts	2	Absent
11	33	M	Texas	2 or 3 years	Formed	Motile forms	3	Absent
12	55	M	Porto Rico	No history of dysentery	Formed	Motile forms	2	Absent
13	22	M	Illinois	1 year	8 to 9 each day, with blood	Motile forms	4	Absent
14	30	M	Texas	1 year	8 to 20 each day, occasional blood	Motile forms	4	Present in one
6	22	F	Minnesota	2 years	Early morning looseness	Motile forms	1	Absent
15	48	F	India	2 years	Formed	Motile forms	3	Absent
5	48	F	China	24 years	5 to 12 watery stools each day	Motile forms	2	Present in one
8	27	M	Illinois	2 years	5 to 14 each day, with mucus and blood, no salts	Motile forms	4	Present in four

MATERIAL INOCULATED AND METHODS USED

The cultivated amebas used for inoculation in animals were the vigorous strain A and the longer-lived but less vigorous strain H, previously described Both were grown on Locke's egg-serum medium of Boeck and Drbohlav, to which was added rice starch as recommended by Dobell Acriflavine in the proportion of 1 30,000 was added to the medium of strain H for a portion of its life

Stools containing *Endameba histolytica* were obtained from ten patients who during the course of this experimental work (table 3) presented themselves at the Mayo Clinic for diagnosis and treatment Of these patients, only four had at

82 Hegner, R W, and Taliaferro, W H Human Protozoology (Monograph), New York, The Macmillan Company, 1924, pp 47-90

83 Craig, C F A Manual of the Parasitic Protozoa of Man, Philadelphia, J B Lippincott Company, 1926, p 37

84 Knowles, Robert An Introduction to Medical Protozoology, with Chapters on the Spirochaetes and on Laboratory Methods, Calcutta, Thacker, Spink & Company, 1928, pp 39-78

the time active intestinal symptoms Of the remaining six, two did not give a history of previous dysentery, while all but the four mentioned did not have, or had only very mild, intestinal symptoms

The infected stools of kittens that had been given injections were also used

For the purpose of introducing the infective material from either a culture or a stool, a 5 cc glass Luer syringe was fitted with a rubber catheter tip so cut as to give a usable length of about 10 cm (Wenyon) [5] This tip was flexible enough to follow the anatomic course of the bowel and yet stiff enough to overcome the ordinary resistance to its introduction This catheter-tipped syringe was also used for the introduction of material into the stomach by way of the mouth in the "feeding" experiments

Cultural material was always fluid enough to require no dilution for use with the syringe Usually, typical dysenteric stool, free from particles of feces, could also be used undiluted If the character of the stool was such that it could not be introduced by means of the syringe, it was diluted with warm physiologic solution of sodium chloride or tap water, was greatly broken up and was filtered through one layer of coarse gauze When possible, feces were injected undiluted and immediately after being obtained

In the selection of cultivated amebas for inoculation in animals, only those in tubes that showed good growth of live amebas were used They were kept at incubator temperature throughout Immediately before the amebas were to be used, the upper two thirds of the fluid portion of the medium in the selected tubes was siphoned away, the remaining fluid was agitated to stir up the ameba-containing starch sediment, and a heavy mixture of amebas and starch granules was thus obtained with a small amount of fluid Of this mixture, from 3 to 4 cc was used for each animal and never more than 5 cc

It was necessary to transport the material from patients' stools some distance before it could be used experimentally There was thus an appreciable lapse of time between the reception of the stool and its use During this time, an effort was made to protect it against cooling In one instance, a stool containing the motile form of *Endameba histolytica*, that had been kept in the incubator for three hours before use, produced amebic dysentery in all four inoculated half-grown kittens

Special care was not used to protect cyst-containing material from culture or man against cooling

For the simple injection of material by bowel or stomach, no preparation of the animal was attempted For rectal injection, the catheter was inserted as far as it could be easily and safely passed, the material was slowly injected, and the animal was held head down for a variable time, up to as long as ten minutes, as suggested by Dale and Dobell Occasionally, moderate attempts were made to produce early postinjection stasis by the simple expedient of Boeck and Drbohlav [10] of plugging the anus with cotton and sealing it over with collodion This was hard to apply, remained a most uncertain length of time, and fell far short of producing the degree of stasis that resulted from the use of a ligature or suture Because it was difficult to determine the value of this procedure, it was used only with some of the earlier inoculations

Animals were prepared for operative inoculation by the withholding of food for twenty-four hours The abdomen was opened under anesthesia, the injection was made into the cecum by means of a small needle, and in some instances the colon was ligated in its lower portion by means of nonabsorbable material In all operative inoculations, cultural material only was used, this necessitated only a small needle and no particular care of the puncture wound in the bowel Fol-

lowing the operation, the animals were offered water and milk, but forced feeding was not attempted Early postoperative recovery was remarkable, and it was impossible to distinguish, by the actions of the animals, between those with ligated colons and those without

For the diagnosis of dysentery in the inoculated kittens, the appearance of diarrhea alone could not be relied on It was necessary to find *Endameba histolytica* in the stool of the cat For this purpose, the suspected animal was given a rectal injection of a small amount of warm physiologic solution of sodium chloride by means of a syringe and catheter arrangement similar to that used for inoculation (Sellards and Leiva [57]) Without removal of the tip of the catheter from the bowel, manipulation resulted in drawing into the syringe some of the injected fluid stained with feces, blood and mucus, in some part of which the motile forms of *Endameba histolytica* were found, if the cat was infected The estimation of the period of incubation was, in all cases, based on the time of the appearance of *Endameba histolytica* in the stools and not on the time of onset of intestinal symptoms Occasionally, the time of incubation might have been found to be shorter by an earlier examination of the stool Finally, all positive infections here reported were later confirmed by postmortem examinations

Since the study of the lesions in the intestine of the infected dysenteric animal was the primary object of the experimental work, no animal was killed to procure material for animal to animal inoculation Infected stool was obtained by means of the syringe and catheter in a manner similar to that exercised in obtaining stool for examination This resulted often in a smaller quantity of material than was desired, and may explain, in part, my inability to carry the infections of the animals through a long series It made possible, on the other hand, the use of the same animal as a source of supply over a period of one or more days, and so far as can be determined, left the intestinal lesions of the donor cat unmodified for later study

From an examination of tables 4 to 7 inclusive, in which the details of the inoculations are given, it will be seen that some of the animals were used as many as four and five times, that an animal marked "negative" in one may appear as "positive" in another, that in some instances the same animal was used repeatedly at such short intervals that the estimate of the incubation period indicated is of no value, since the infection may have resulted from an injection other than the last A study of the dates indicating the order of inoculation will show that the animal that showed negative results one or more times later showed positive results Concerning the infecting injection, it can be said only that the so-called negative animal was considered to be negative if it seemed well and if examination of its stool gave negative results The object throughout was the production of lesions of amebic dysentery, and not a critical study of the susceptibility of the cat to infection with *Endameba histolytica*

RESULTS

Inoculation of Animals with Cultures of Endameba Histolytica — Although Dobell and Laidlaw stated that the artificial cultivation of *Endameba histolytica* in mediums containing rice starch apparently destroyed their infectivity for animals, the first of my experiments in inoculation was undertaken with a rich culture of *Endameba histolytica,* strain A, previously described, grown in the medium of Boeck and Drbohlav, Locke's egg-albumin, to which rice starch had been added

The first kittens available for this work were young, some as young as fourteen days, and the mortality among them was high owing to causes other than the experimental manipulations With cultures of strain A, thirteen inoculations were made in five animals, kitten 2 was used three

TABLE 4—*Data Concerning Inoculation of Animals with Cultures of Endameba Histolytica*

Kitten	Strain	Cysts Given by Mouth	Trophozoites Given by Rectum	Amebic Lesions	Length of Life After Last Inoculation, Days	Manner of Death	Comment
1	A		+	—			
1	A		+	—	7	Died	
2	A		+	—			
2	A		—	—			
2	A		+	—	7	Died	
3	A		+	—			
3	A		+	—			
3	A		+	—			
3	A		+	—			
3	A		+	—	141	Died	
4	A	+		—			
4	A		+	—	1	Died	
5	A	+		—	1	Died	
6	H		+	—			
6	H		+	—			
6	H		+	—			
6	H		+	—			
6	H		+	—	4	Killed	Stool positive for amebas
7	H		+	—			Operative inoculation, rectum tied
7	H		+	—			
7	H		+	—			
7	H		+	—			
7	H		+	+	3	Killed	Operative inoculation rectum tied
8	H		+	+	3	Killed	Operative inoculation rectum tied
9	H		+	—	4	Killed	Operative inoculation, rectum tied
10	H		+	—	5	Died	Operative inoculation, rectum tied
11	H		+	—	5	Died	Operative inoculation rectum tied
12	H		+	—	2	Died	Operative inoculation
13	H		+	—	4	Died	Operative inoculation
14	H		+	+	4	Killed	Operative inoculation
15	H		+	—	(few hours)	Died	Operative inoculation
16	H		+	—	6	Killed	Operative inoculation
17*				—	3	Killed	Operative inoculation rectum tied
18*				—	3	Killed	Operative inoculation rectum tied

Summary

Nonoperative inoculations with culture	21
Kittens	7
Infected	0
Operative inoculations with culture	11
Kittens	11
Infected	3
Total number inoculated with cultures	32
Total number of kittens	16
Total number infected	3

* Received injection of culture of ameba free intestinal contents

times and kitten 3 five times Twice, cysts obtained on cultivations were given by mouth With these exceptions, inoculations were made with motile forms by rectum In spite of their youth, amebic dysentery did not develop in any cat of this group

In the work with cultures of strain H, only trophozoites were used These introduced into the colon by rectal injection gave negative results When cultures of this strain were introduced directly into the cecum by means of a needle, amebic lesions developed in three of eleven kittens operated on In one of the three the result was positive in spite of the absence of stasis, for the bowel of this kitten had not been occluded by ligature (table 4) Kitten 6 was given a rectal injection of the same strain, four times, with negative results, whereas, following operation, its intestinal content contained motile amebas, but intestinal lesions were not found (see study 3) Kitten 7 remained uninfected following four rectal injections of strain H, but became infected after the fifth, or operative, inoculation Two kittens which served as controls for those operated on, and which had been given injections of cultures made from stools that were free from amebas, gave negative results

Besides the control kittens, inoculation from culture was attempted thirty-two times in sixteen animals, with infection resulting in only three Those in which infection resulted all fell in the operative group of eleven kittens The incidence of infection was 27 per cent In twenty-one nonoperative inoculations in seven kittens, infection did not occur

In view of the lack of knowledge concerning the possibility of modifying the virulence of *Endameba histolytica,* and of the fact that injections into animals were not made with the stools from which the cultures of strains A and H were grown, it is impossible to conclude from the results of the experiments here described, that the addition of rice starch to the medium in which the amebas were grown had reduced their infectivity It is evident from the operative results with strain H that it is still infectious for cats In spite of the lack of conclusive evidence, the impression remains that rice starch does reduce the infectivity of artificially grown *Endameba histolytica,* at least as far as the effect on cats is concerned

Inoculation of Animals with Material Derived from Human Beings (Table 5) —In preparation for the examination of stools of patients with parasites, as practiced at the Mayo Clinic (see study 1), magnesium sulphate is taken before breakfast on the day that the test is to be made This may not be carried out in the case of a patient who at the time of examination has active diarrhea Since the resulting stools for examination usually are fluid, only the history of the cases can indicate whether the fluid stool was usual for the time or was the result of the physic In the light of the histories subsequently studied, it was found that only four of the ten patients whose stools were used for inoculation were having dysenteric symptoms at the time of examination and may not have taken a preliminary dose of magnesium sulphate (table 2)

Of the four stools from cases of active dysentery, only one failed to produce amebic dysentery in kittens Of the three stools that produced amebic lesions, one infected one of three kittens, one infected one of two and one infected all of four The patient (case 8) from whom the last stool was obtained is known to have taken no preliminary magnesium sulphate, the animals that were given injections of this

TABLE 5—*Data Concerning Inoculation of Animals with Endameba Histolytica from Human Beings*

Animal Given Injection	Source of Material, Case	Cysts	Trophozoites	Amebic Lesions	Manner of Death	Length of Life After Last Inoculation, Days
19	6		+	—		
20	11		+	—		
20	15		+	—		
21	11		+	—		
21	15		+	—		
22	11		+	—		
22	15		+	—		
23	9	+		—	Died	16
24	9	+		—		
25	9		+	—		
25	12		+	—		
25	13		—	—		
26	9		+	—		
27	5		+	—	Killed	3
28	5		+	+	Killed	4
29	10		+	—		
18	10	+		—		
30	12		+	—		
30	13		+	—		
7	13		+	—		
6	13		+	—		
31	14		+	—	Died	2
32	14		—	—		
33	14		—	—		
34	14		+	+	Killed	9
35	8		+	+	Killed	13
36	8		+	+	Killed	17
37	8		+	+	Killed	18
38	8		+	+	Killed	18

Summary

Inoculations from positive stools of human beings	29
Kittens inoculated	23
Kittens infected	6

patient's stool were larger than normal, being about one-half grown Two were returned to their cages as soon as the injection was made, whereas two were held head down for ten minutes following the injection The period of incubation was long because of the size and presumable age of the kittens, and holding the kittens head down failed to modify the results

Cysts from the stools of two human beings were used for the inoculation of kittens by feeding, two for each stool, with negative results in all

Both cysts and motile forms from the stools of human beings were used for injection into twenty-three kittens The injections were given by mouth and by bowel, a total of twenty-nine times, with infection resulting six times This is an incidence of 26 per cent of kittens used and of 20 7 per cent of injections

Inoculation of Animals with Stools of Infected Kittens—Infected stools of nine kittens were used as material for injection into ten kittens a total of fourteen times, with positive results in three (table 6) Kitten 32 was given injections four times, once of material from kitten 7 and three times of material from kitten 34 In this case, the period of

TABLE 6—*Data Concerning Inoculation of Animals with Positive Stools from Kittens*

Kitten Given Injection	Source of Material, Kitten	Amebic Lesions	Manner of Death	Length of Life After Last Inoculation, Days
39	28	+	Killed	3
40	28	—	Killed	6
41	26	+	Died	2
9	26	—		
38	25	—		
42	7	—		
32	7	—		
32	34	—		
32	34	—		
32	34	+	Killed	5
43	36	—		
43	38	—		
44	37	—		
25*	27	—		
25*	40	—		
25*	40	—		

Summary

Inoculations with positive stools of kittens	14
Kittens inoculated	10
Kittens infected	3

* Given injections of fecal material from kittens which had been inoculated with Endamoeba histolytica and in which diarrhea had developed but lesions had not

incubation must be indefinite, for any one of the last three injections may have produced the disease The infection from kitten to kitten was not carried beyond the third subpassage in any case These data are in marked contrast with those of Sellards and Baetjer,[59] who carried a strain from animal to animal for eleven generations, of Dale and Dobell, who carried a strain for forty-three passages, and of Mayer, who carried strains through animals for thirty-two, thirty-nine and fifty-nine passages, respectively In my work however, as already explained, no animal was killed for the sake of the infective intestinal material

In the ten infected kittens, the stools of which could be examined during life for diagnosis, the period of incubation varied from one day to nine days with an average of five days (table 7) The period of incubation was shorter in the younger cats

SUMMARY OF STUDY 2

Cultures of strains of *Endameba histolytica,* not previously tested for virulence, failed to infect kittens, except in those instances in which the infective material was introduced operatively directly into the cecum of the experimental animal The proportion of animals infected by this last means was 27 per cent

No animal was infected by the use of stools from patients free from symptoms of dysentery The stools of all but one of the patients who presented symptoms of active dysentery caused infection, the results in six of fourteen experiments were positive, an incidence of 42 8 per cent

Thirty per cent of animals that received injections of the infected stools of cats that were ill with amebic dysentery became infected Survival of the infection beyond the third subinoculation did not occur

TABLE 7—*Incubation Period in Animals Infected with Endameba Histolytica*

Kitten	Source of Material	Incubation, Days
14	Culture strain H	3
28	Stool of human being	3
35	Stool of human being	7
36	Stool of human being	6
38	Stool of human being	9
37	Stool of human being	9
41	Stool of kitten	1
42	Stool of human being	6
32	Stool of kitten	3
39	Stool of kitten	3

* Of the animals represented in this table, kitten 14 was infected by operation, all others by rectal injection Kittens in which inoculation was by operative methods, and in which the rectum was tied, are not included in this table

The use of cysts for inoculation, both those from culture and those from the stools of human beings, gave negative results

The effect of passage through animals on the virulence of *Endameba histolytica* could not be determined

Evidence is not presented to show that the resistance of the experimental animal to *Endameba histolytica* is increased by previous attempts to infect it with this organism

(To be Concluded)

BASAL CELL CARCINOMA

A STUDY OF EIGHT HUNDRED AND THIRTY-SIX CASES *

MAY OWEN, M D
FORT WORTH, TEXAS

The term basal cell carcinoma is used to designate carcinoma arising from the basal cell layer of the epidermis and retaining to a large extent the characteristics of basal cells Reports in the literature indicate that primary basal cell carcinoma of the mucous membrane is not common

The work presented was undertaken for the purpose of determining, if possible, whether or not basal cell carcinoma, with its low grade of malignancy, occurs primarily on the mucous membranes, and to study the relation of the basal cell carcinoma having its origin on the skin to the so-called basal cell carcinoma having its origin on the mucous membrane A recent report of two cases of basal cell carcinoma of the cervix suggested the possibility of a highly malignant squamous cell carcinoma being confused with a basal cell carcinoma I had opportunity to study the tissues from these cases, and I believe that the report in question concerns active squamous cell carcinomas In both cases, the history was that commonly noted in cases of highly malignant squamous cell carcinoma In one case there was extensive pelvic metastasis, and the patient lived less than nine months after the onset of symptoms, in the other case, the patient lived less than twenty-two months after the diagnosis had been made

REVIEW OF THE LITERATURE

Basal cell carcinoma, or rodent or jacobean ulcer, was first described by Jacob [1] in 1827 His description has not been essentially modified slow growth, peculiar condition of the edges and the surface of the ulcer, absence of contamination of the neighboring lymph nodes and distribution in the region of the eyes Following this report, Hutchinson,[2] in 1860, reported a clinical case in which the lesion occurred on the skin of the groin Until this time basal cell carcinoma had been considered peculiar to the face

Krompecher,[3] in 1900 reported his histologic observations on basal cell carcinoma He concluded that the origin is in the basal cell layer

* Submitted for publication, April 22, 1930

* Work done in the Section on Surgical Pathology, the Mayo Clinic, Rochester, Minn

1 Jacob Arthur, quoted by Little Brit J Dermat **27** 145, 1915

2 Hutchinson, J Rodent Ulcer of the Forearm, Tr Path Soc, London **48** 220, 1860

3 Krompecher E Der drusenartige Oberflachenepithelkrebs, Beitr z path Anat u z allg Path **28** 1, 1900

of the epidermis, and he suggested the classification of cutaneous carcinomas into basal cell and spinal cell carcinomas This has been widely accepted Following the work of Krompecher, the growths became known as basal cell carcinoma, or epithelioma Borrman [4] opposed this theory that basal cell carcinoma has its origin in the basal cell layer of the epidermis, and maintained that it originates in cell rests and becomes united to the epidermis only secondarily

Cohnheim [5] was of the opinion that in the early stage of embryonic development more cells are produced than are required for building up the part concerned, so that there remains unappropriated a quantity of cells that because of their embryonic character are endowed with a capacity for proliferation Furthermore, the early slow growth is due to the poor blood supply, and as soon as the lesion penetrates the deeper tissues and receives a better blood supply, growth is more rapid

Walker,[6] Mallory,[7] Paul,[8] Johnson [9] and others believed that basal cell carcinoma has its origin from hair follicles, sebaceous glands, sweat glands or a combination of these Blasdell [10] believed that it has its origin in seborrheic patches or senile patches of the skin, and Ewing,[11] that it arises perhaps exclusively from the basal cells, often from misplaced and embryonal group of such cells, but the normal transformation into squamous cell entirely fails

Cleveland and Paul,[12] in 1920, stated that the type of epiblastic development depends on the situation of the cells They gave as an example the epiblast covering the chorionic villi, which forms a syncytium and Langhans' layer of cells, while other cells similarly derived form the epidermis on the surface of the body That is, in spite of the uniformity of origin and presumed equality of potentialities, the highest development of the cells depends on the structures among which they find themselves situated in regard to the whole body

---

4 Borrman, Robert Die Entstehung und das Wachstum des Hautcarcinoms, Ztschr f Krebsforsch **2** 1, 1904

5 Cohnheim, J F Lectures on General Pathology (Translation), London, The New Sydenham Society, 1889-1890, vol 2, p 760

6 Walker, Norman The Pathology of Rodent Ulcers, Tr Path Soc London **45** 172, 1894

7 Mallory, F B The Principles of Pathologic Histology, Philadelphia, W B Saunders Company, 1914, pp 371-373

8 Paul, Norman Observations on the Origin, Causation and Treatment of Rodent Ulcer, M J Australia **1** 85, 1923

9 Johnson, F H The Treatment of Rodent Ulcers (Basal Cell Epithelioma), with Especial Reference to Recurrence, Lancet **1** 389, 1926

10 Blasdell, H E Basal Cell Carcinoma, J Kansas M Soc **23** 338, 1923

11 Ewing, J Neoplastic Diseases, Philadelphia, W B Saunders Company, 1919, p 457

12 Cleveland, J B, and Paul, Norman Rodent Ulcers and Allied Growths An Analysis of Sixty Australian Cases, M J Australia **1** 407, 1920

Kyrle[13] explained the failure of the cells of basal cell carcinoma to differentiate and become keratinized as normal basal cells do on the basis that the basal cell layer of the skin has two tasks to fulfil to differentiate into pavement epithelium and to act as the matrix for the postfetal sebaceous glands without formation of squamous cells It follows that when tumors arising from the basal cell layers differentiate into pavement epithelium, squamous cell carcinoma is formed When the tumor arises from the cells acting as the matrix for postfetal sebaceous glands basal cell carcinoma is formed

Lunford and Taussig[14] reported 230 cases of superficial carcinoma, 89 of which were basal cell and 141 squamous cell They made separate analyses of the basal cell and squamous cell types of carcinoma and further divided them into those occurring on the skin and those occurring on the mucous membrane Of 109 carcinomas of the skin, 89 (81 65 per cent) were basal cell and 20 (18 25 per cent) were squamous cell The 121 carcinomas of the mucous membrane were of the squamous cell type

In 194 cases of carcinoma of the tongue that I recently reported,[15] I did not observe a basal cell carcinoma

Martzloff[16] studied 387 cases of carcinoma of the cervix and concluded that basal cell carcinoma with its low grade of malignancy does not occur in the cervix He divided carcinomas of the cervix into three groups, basing the classification on cell differentiation (1) spinal type of cancer cell, (2) transitional type of cancer cell and (3) the fat spindle type of cancer cell Martzloff believed that the last type corresponds to Krompecher's[17] basal cell carcinoma, but in his series it proved to be the most malignant

There is a striking similarity between the observations of Broders[18] and those of Martzloff in carcinoma of the cervix In Martzloff's series, 47 per cent of the patients with spinal cell carcinoma, 24 2 per cent with the transitional type of carcinoma, and 9 5 per cent with fat spindle cell type of carcinoma remained well for five years after operation These

13 Kyrle J Beitrag zur Frage der Basalzellengeschwulste der Haut, Arch f Dermat u Syph **121** 246, 1916

14 Lunford, C J and Taussig, Laurence Superficial Epitheliomata California & West Med **25** 740, 1926

15 Owen May Lesions of the Tongue with Special Reference to Their Location Texas State J Med **22** 693, 1927

16 Martzloff K H Cancer of Cervix Uteri, Variations in Malignancy of Different Varieties, Northwest Med **25** 127, 1926

17 Krompecher E Zur vergleichenden Histologie der Basaliome, Ztschr f Krebsforsch **19** 1, 1922-1923

18 Broders A C The Grading of Cancer and Its Practical Application, Arch Path **2** 376, 1926

correspond, respectively, to Broders' cases graded 2 with good results in 53 33 per cent, those graded 3 with good results in 21 56 per cent and those graded 4 with good results in 9 52 per cent None of these types conformed to the basal cell carcinoma of the skin as regards lack of malignancy

Vinson,[19] in a series of 159 cases of carcinoma of the esophagus, did not see a basal cell carcinoma In all except two cases the malignancy was graded high In the two cases of low grade malignancy the neoplasm occurred on old strictures which had been caused by lye and which had been repeatedly dilated They corresponded more or less to carcinoma experimentally produced by tar, which is often of a low grade of malignancy So far as I am aware, basal cell carcinoma has not been produced experimentally

Contrary to most other authorities, Krompecher[20] reported that in his observation basal cell carcinoma originates on the mucous membrane of the uterus, esophagus, larynx, nose and sinuses He described the neoplasm in these situations as forming long, narrow, concave bands with indefinite borders This he considered as being a separate type of basal cell carcinoma He also believed that the tumors described by a number of pathologists as endotheliomas, cylindromas and mixed tumors of the salivary glands are forms of basal cell carcinoma According to his observations, about half of the malignant tumors of the nose and a third of those of the larynx correspond to the basal cell type, the nose is the most common site (twenty-nine of sixty) and the larynx is the next most common (fifteen of fifty) However, taking them as a whole, he has found the occurrence of basal cell carcinoma much more rare on the mucous membrane than on the skin

New[21] and Figi[22] never observed that a basal cell carcinoma originated on the mucous membrane of the trachea, larynx, mouth nose or sinuses

Broders,[23] in his report of 362 cases of carcinoma of the cavities and internal organs of the head and neck, did not mention a basal cell carcinoma He studied the clinical and pathologic aspects of carcinoma thoroughly and divided the lesions into groups according to their degree of cell differentiation[24] In the microscopic study of thousands of

19 Vinson, P P Personal communication to the author

20 Krompecher, E Zur Kenntnis der Basalsellenkrebse der Nase, der Nebenhohlen, des Kehlkopfes und der Trachea, Arch f Laryngol u Rhinol **31** 443, 1918

21 New, G B Personal communication to the author

22 Figi, F A Personal communication to the author

23 Broders, A C Epithelioma of Cavities and Internal Organs of the Head and Neck, Arch Surg **11** 43, 1925

24 Broders, A C Squamous-Cell Epithelioma of the Lip A Study of Five Hundred and Thirty-Seven Cases, J A M A **74** 656, 1920

carcinomas, he never observed a true basal cell carcinoma of the jacobean type having its origin on the mucous membrane

DATA IN EIGHT HUNDRED AND THIRTY-SIX CASES

The work reported here is based on the microscopic study of 836 cases diagnosed basal cell carcinoma, which were observed in the Mayo Clinic from August, 1915, to January, 1927 In every case, the diagnosis was made on the basis of a microscopic examination of excised portions or the whole lesion Special effort was made to ascertain the site of the original growth and to obtain tissue for study Those cases in which tissue was not available and those in which there was any doubt as to the site of the original growth were discarded I also made a careful microscopic examination of more than 500 specimens removed at biopsy from the cavities and internal organs of the head and from the neck, esophagus, bronchi, cervix uteri, bladder and rectum, in no case did I observe a carcinoma that conformed to the characteristics of basal cell carcinoma or rodent ulcer of the skin The cases will not be reviewed in detail, a summary of some of the more general observations follows

The average age of the patients was a little more than 56 years, the youngest patient was aged 18 and the oldest 81 The condition was preponderantly one of the fourth, fifth and sixth decades In this series, basal cell carcinoma was slightly more than twice as common in men as in women In 774 cases (92 58 per cent), the lesion occurred on the face and head, in 226 cases (27 03 per cent), on the nose Seven hundred and eighteen of the lesions were simple basal cell, 111 were basal cell and squamous cell mixed, the squamous cell being graded 1 and 2 (fig 1), and 7 were pigmented basal cell carcinomas It may be this pigmented type that has led a few observers to consider the nevus as the origin of the basal cell carcinoma

The material for the study of these 836 cases included only specimens removed at operation Three of these neoplasms, although resembling basal cell carcinoma, proved, on careful microscopic study, to be highly malignant squamous cell carcinoma, 1 was from the mucous membrane of the nose and 2 from the cervix As stated, on cursory microscopic examination, these three cases closely resembled basal cell carcinoma, but on more careful study they were found to be squamous cell carcinoma graded 3 or 4 (fig 2) The tumors were almost wholly of undifferentiated cells containing many irregular mitotic figures and varying greatly in size, shape and number of nuclei The patient in each case gave a history of a tumor of short duration and extensive metastasis which corroborated the microscopic data

I was impressed with the frequency with which the tumors graded 3 and 4 grew in the form of solid branching strands of closely packed

cells, and how readily the neoplasm could be mistaken for basal cell carcinoma The cells were rather less regular in form and character of nuclei than is usual in carcinoma of the skin The clinical course of the highly malignant squamous cell carcinoma is more rapid than that of

Fig 1—Mixed basal cell and squamous cell carcinoma (×60), *a*, basal cell carcinoma, *b*, squamous cell carcinoma, of malignancy graded 1

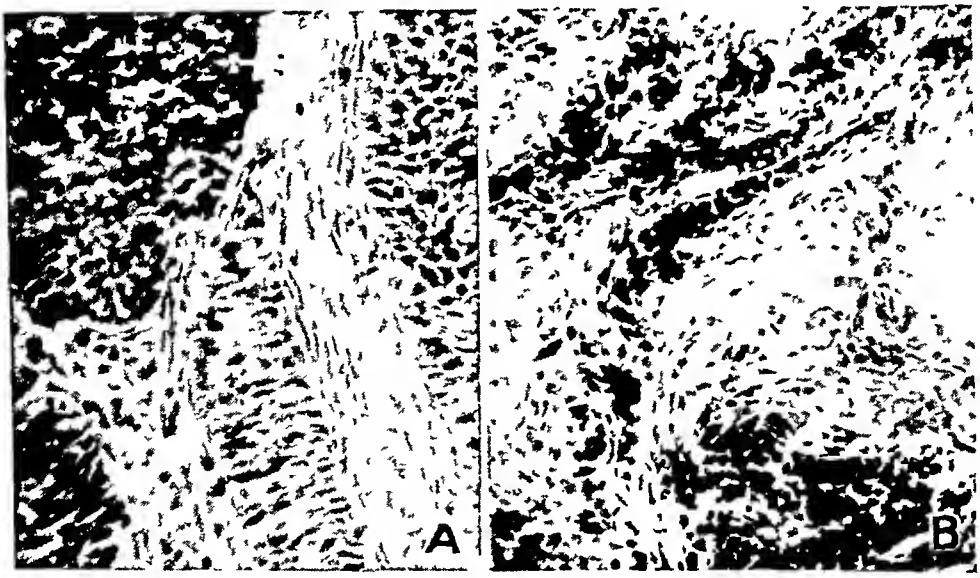

Fig 2—*A*, squamous cell carcinoma of the cervix, originally diagnosed basal cell carcinoma (×100), malignancy graded 4 *B*, squamous cell carcinoma from the mucous membrane of the nose, originally diagnosed basal cell carcinoma (×100), malignancy graded 4 The patient had extensive metastasis

the basal cell carcinoma, there is often metastasis, and the cells are only slightly differentiated

The basal cell carcinomas studied, besides the familiar rodent ulcer, comprised many flattened, irregular patches and smooth, elevated,

rounded masses Most of them were characterized by slow growth, smooth pearly borders and granular bases often covered by a dirty-brown crust In none of the cases were the lymph nodes involved As a rule, the lesions occurred singly, but they were sometimes multiple Although the lesion was carcinomatous in structure, the cells did not penetrate far into the deeper tissues

The structure of these growths varied greatly The stroma was either abundant or scanty The relatively bulky compact masses of cells, connected by narrow strands of similar cells, lay in artificial spaces, from which they readily shrank on hardening There was a tendency to concentric arrangement of the cells which formed the masses, the greater percentage of which showed a marginal palisade or a layer of columnar-like cells The large masses often contained clear areas in which were small amounts of degenerating mucus In another type, the growth assumed more the appearance of finger-like processes, often separated into lacunae that suggested in general glandular carcinoma or adenocarcinoma

The tumor cells resembled the basal cells of the epidermis, and were small and polyhedral or spindle-shaped, and one, two or more layers thick These cells were characterized by a cylindric or spindle shape, a small amount of cytoplasm, a large amount of nuclear material, which took the shape of the cell and stained much more intensely than the average squamous cell, and by the intimate relation of the cells to each other

It has been generally believed that basal cells do not possess prickles or bridges Broders,[25] however, was convinced that they do Mallory stated that rarely is there a hint of the formation of the intercellular bridges or prickles I studied a number of specially prepared sections and am able to corroborate Broders' observations In order to demonstrate satisfactorily the intercellular bridges or prickles in basal cell carcinoma, it is necessary to cut the sections from 2 to 3 microns thick and stain them carefully With the usual technic, the cells are too closely packed to permit the finest cytologic studies Because of the presence of prickles in some cases in both basal cell and squamous cell carcinoma, it is sometimes difficult to differentiate these two types

Mitosis is often found in basal cell, as well as in squamous cell, carcinoma However, there is a question as to its relative significance in basal cell carcinoma

COMMENT

The division of carcinomas into squamous cell and basal cell forms, as well as into carcinoma of the mixed tumor type and adenocarcinoma

25 Broders, A C Personal communication to the author

is of more than academic interest The distinguishing features are determined by the amount of cell differentiation Another feature of this cellular classification is that a particular growth may not be entirely of one type but may be mixed Particularly is this true of the basal cell and squamous cell carcinoma It is only natural that this should be so, since the normal cells from which carcinomas spring are not widely separated, nor do they differ widely in their nature Montgomery [26] recently called attention to the mixed basal cell and squamous cell or transitional carcinoma and applied to this the term basal-squamous cell carcinoma He reported fifteen cases in which he showed that in the transitional forms the prognosis is serious as compared with that in the basal cell carcinoma

Since a high percentage of carcinomas described by some writers as basal cell arising from the mucous membrane of various organs, such as the cervix, esophagus, mouth and sinuses, metastasize, if the grade of malignancy is not too low, and since they grow more rapidly than basal cell carcinoma of the skin, the generalization seems justifiable that if epithelial tumors can be definitely identified as forming pearls or if they grow rapidly and destructively and metastasize, and consist to a large extent of undifferentiated cells, they may not be considered basal cell carcinoma It is well known that in basal cell carcinoma, if the cells once gain access to mucous surfaces, they rapidly involve most, or all, of the exposed surfaces, and a relatively large tumor results without metastasis

Early, as well as recent, writers have been unanimous in their belief that the basal cell carcinoma arises from the basal cell layer of the epidermis or its appendages, and almost all have considered the logical necessity of selecting some point of origin Few have contended that the basal cell carcinoma also develops from the basal cell layer of the mucous membrane My own studies induce me to attribute its origin to the basal cell layer of the skin In this series of 836 cases, I was unable to find a true basal cell carcinoma having its origin on the mucous membrane However, a number of growths had extended from the skin to the mucous membrane, particularly those near the eyes and nose In some cases there was even extensive destruction of the orbit and its contents

SUMMARY

Since Jacob, in 1827, first described basal cell carcinoma, or rodent ulcer, reports and studies of these tumors have appeared with comparative frequency Basal cell carcinomas have been confused microscopic-

26 Montgomery, Hamilton Basal-Squamous-Cell Epithelioma, Arch Dermat & Syph **18** 50, 1928

ally with nevi, endotheliomas, sarcomas, carcinomas (mixed tumor type) and highly malignant squamous cell carcinomas Certain of the more recent writers have been unable to confirm the observations of Krompecher and others with regard to the occurrence on the mucous membrane of basal cell carcinoma with its low grade of malignancy

My observations have been similar in many respects to the observations of others, but a recent report of two cases of basal cell carcinoma of the cervix suggested a review of the entire subject However, my study of 836 cases of basal cell carcinoma seems to show that carcinomas having their origin on the mucous membrane lack the benign characteristics of basal cell carcinomas, or rodent ulcers of the skin I have emphasized the contrasting characteristics of the basal cell carcinoma, or rodent ulcer of the skin, and the so-called basal cell carcinoma with its origin on the mucous membrane

CONCLUSIONS

My observations do not indicate that true basal cell carcinoma may occur on the mucous membrane

The review of cases in this paper lends weight to the contention that carcinomas having their origin on the mucous membrane lack that low grade of malignancy which the basal cell carcinomas that are situated on the skin possess

It would seem rather hazardous to diagnose as basal cell carcinoma a tumor having its origin from the basal cell layer of the mucous membrane when there are present metastasis and rapid extensive growth consisting chiefly of undifferentiated cells or cells showing squamous characteristics This tumor seems to be a squamous cell carcinoma

NEUROMUSCULAR CHANGES IN AMYELIA AND THEIR RELATION TO THOSE OF CONGENITAL CLUBFOOT*

R J DITTRICH, M D
WICHITA, KAN

Although there is a wide gap between anatomic conditions in amyelia and those in congenital clubfoot, there is nevertheless a remote relationship between the two which indicates that the difference in their construction is merely one of degree of involvement Congenital clubfoot has at various times been considered a deformity brought about by a neuromuscular imbalance of the foot, manifested by a predominance of certain muscle groups over their antagonists This conception has been largely the result of clinical observation, although a considerable amount of evidence of structural changes in the neuromuscular mechanism has been contributed by anatomic investigation In a recent article,[1] I presented evidence to show that congenital clubfoot may be produced by an abnormal development of the peroneal nerve This structure has certain embryologic peculiarities by which during intrauterine development it may be exposed to harmful influences that are instrumental in preventing the normal outgrowth of a portion or all of its constituent nerve fibers as they proceed from the spinal cord As a direct consequence of a loss of nerve substance to the muscles supplied by these nerves, a deficiency occurs in the synergy of opposing muscle groups controlling the position of the foot

In his discussion of amyelia, Ernst[2] stated that practically all malformations of the central nervous system are the results of varying degrees of the same disturbance in development, namely, a deficient anlage of the medullary plate or an incomplete closure of the medullary groove With complete absence of the cord, the musculature of the trunk and the extremities may be present and even supplied with nerves The muscles can develop completely without the influence of the medullary canal, and only in extra-uterine life do they become dependent on the motor nervous system That the musculature can develop normally without the motor nerves has also been shown experimentally in frogs by removing the anlage of the brain and cord

* Submitted for publication, May 24, 1930

† From the Pathological Laboratory of St Francis Hospital

1 Dittrich, R J Pathogenesis of Congenital Club-Foot (Pes Equinovarus) An Anatomical Study, J Bone & Joint Surg **12** 373, 1930

2 Ernst, P Storungen der Entwicklung, in Aschoff, L Pathologische Anatomie, ed 2, Jena, Gustav Fischer, 1911, vol 2

The object of this study was to investigate the condition of the muscles and nerves of the lower extremities in amyelia and to determine in what respects they differ from those found in congenital clubfoot

DESCRIPTION OF SPECIMEN

The specimen studied was a new-born girl with multiple malformations The child was born of a first pregnancy The date of the mother's last menstrual period was May 9, 1929 Fetal heart sounds were last heard on Dec 24, 1929, and delivery occurred on Dec 26, 1929 The history stated that no roentgen or radium treatments had been given to the mother

The skin of the specimen was dark and somewhat macerated In some areas, the discoloration of the skin indicated hemorrhage This was most marked on the dorsum of the right foot The head showed a marked defect of the posterior portion (anencephaly) The upper extremities appeared normal There was an eventration of the anterior abdominal wall allowing the contents to protrude The spine showed marked kyphosis in the dorsal region, and the skin over this area was absent, the result evidently of pressure necrosis The muscles of this region were small and poorly developed The right foot was in a position of equinovarus, and the left foot in a position of calcaneovalgus The left leg was larger than the right

Examination of the muscles of the legs showed that the anterior muscles of the left leg were larger and better developed than those of the right leg This was most noticeable in the tibialis anterior, less so in the extensor hallucis and the extensor longus digitorum The peronei on each side were not clearly differentiated and appeared to be fused The posterior muscles were about equal in development and volume on the two sides The right tibialis anterior, in addition to being smaller than the left, was distinctly pale and consisted of fine fasciculi, which were easily separated

In the thighs, both portions of the sciatic nerve were present and no difference between the nerves on the two sides was shown They were grayish brown The peroneal nerve on the right side was followed down into the leg and was seen to give off branches to the muscles The branches to the muscles were fine filaments and were more numerous than ordinarily

On both sides, the cutaneous portions of the superficial peroneal nerves were present and had a normal glistening appearance

The spinal column consisted of the vertebral bodies with small rudimentary pedicles projecting only a few millimeters from the bodies There was no trace of a spinal cord from the upper dorsal to the midsacral segments Several of the vertebral bodies were found to have well formed centers of spongy bone

Microscopic Observations—The controls used in this investigation were the same as those used in the determination of the anatomic condition of the muscles in a case of clubfoot[1] This was necessitated by the impossibility of finding a suitable control in a case of amyelia The muscle from which control sections were made was the extensor carpi ulnaris

The appearance of certain muscles of the legs was studied by means of the hematoxylin-eosin staining method

The right peroneus longus showed a general narrowing of the muscle fibers and an increase in the number of nuclei All fibers showed a moderate loss of sarcoplasm and occasionally fragmentation Cross-striations were present in all fibers Many small hemorrhages were found in the muscle tissues Numerous dilated blood vessels were noted throughout the section

A section of the right gastrocnemius showed an increase in the number of nuclei, a general narrowing of the fibers and a moderate loss of sarcoplasm Cross-striations were present in all the fibers, although in some they were indistinct Fragmentation was noted in some fibers, and numerous small hemorrhages were seen There was an increase in the number of blood vessels These also were dilated

The right tibialis anterior showed a slight increase in the number of nuclei Considerable variability was noted in the size of the fibers, some being normal but most of them being narrowed Cross-striations were present in all fibers, but loss of sarcoplasm was not as marked as in the other muscles of the right leg A few small areas were present in which there was complete loss of muscle substance and replacement by fibrous tissue Several small hemorrhages were noted The blood vessels were dilated but were not increased in number

The left peroneus longus showed a marked increase in the number of nuclei and a distinct loss of sarcoplasm Cross-striations could be seen in all fibers, although in some they were not clear Individual fibers showed fragmentation Numerous small hemorrhages were present Blood vessels were increased in number and dilated

The left gastrocnemius disclosed wide variation in the appearance of the fibers Most fibers were narrowed, at times to one third or one fourth of their normal width, and showed an increase in the number of nuclei, together with loss of sarcoplasm Cross-striations were present in all fibers, but indistinct in some There were numerous small areas of hemorrhage and many individual red blood cells scattered throughout the muscle Among the atrophied fibers were some which were more normal in appearance These showed a more intense staining reaction, clear cross-striations and no increase in the number of nuclei, and were approximately normal in size (fig 1)

In the left tibialis anterior, most of the fibers were slightly narrower than normal No increase in the number of nuclei and only a mild loss of sarcoplasm were noted Cross-striations were normal There was no increase in the number or dilatation of blood vessels

Microscopic examination of the nerves was limited to a study of cross-sections of the sciatic nerves, the specimens being obtained at the level of the distal portions of the thighs The nerve tissues were embedded in gelatin, sectioned and stained with hematoxylin and eosin and by the Spielmeyer methods

The left sciatic nerve was larger than the right

The most striking feature of the nerve tissues was the large number of blood vessels These were dilated, frequently having a thin wall, and were well filled Hemorrhages of variable extent were found in both sections, mostly in the epineurium and the perineurium (fig 2)

By means of the hematoxylin-eosin staining method, numerous sheath cells were seen, which had a normal appearance No fibrosis, sclerosis or degenerative changes were noted With the Spielmeyer staining method, the nerves showed a rather uniform distribution of myelin, although myelinization was incomplete

ANALYSIS OF ANATOMIC CHANGES

The alterations in the muscles were mostly such as would be expected in beginning simple atrophy They consisted almost entirely of narrowing of the fibers, an increase in the number of nuclei and loss of sarcoplasm The specific fiber structure was retained, and cross-striations

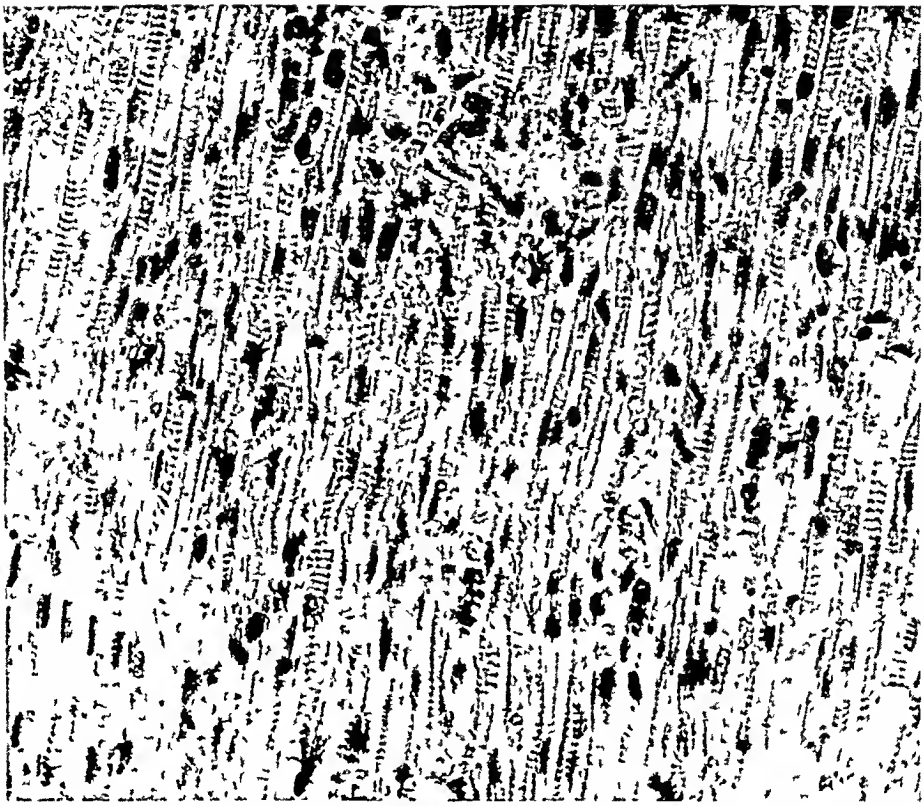

Fig 1—High power photomicrograph of the left gastrocnemius, showing variation in size of fibers and loss of sarcoplasm

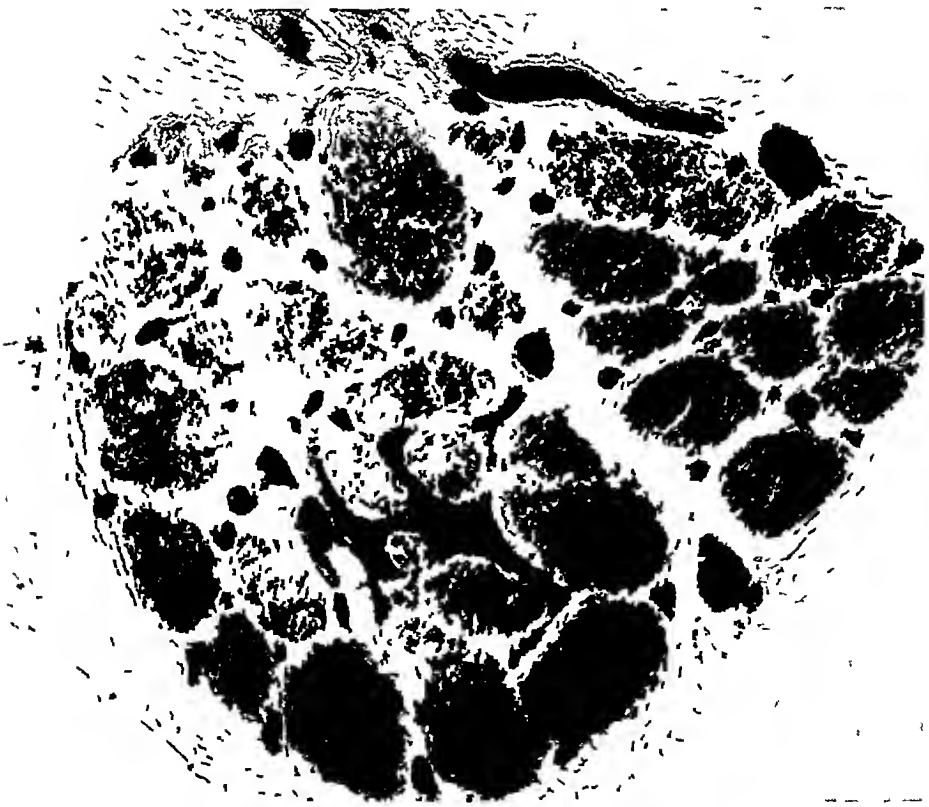

Fig 2—Low power photomicrograph of left tibial and peroneal nerves, showing degree of myelinization hyperemia and hemorrhage

were seldom lost The only evidence of degenerative atrophy consisted of a few small areas in which the muscle structure had entirely disappeared and was replaced by fibrous tissue

From a study of the condition of nerves and muscles, there is no reason to believe that the position of the feet was in any way dependent on the functional activity of the different groups of muscles of the leg On the right side, with the foot in a position of equinovarus, the atrophic process was approximately equal in the three muscles examined It may be significant that on the left side, with the foot in a position of calcaneovalgus, the tibialis anterior was grossly proportionately larger than the other muscles, and that microscopically it had a more normal appearance However, in the absence of connections with the central nervous system, it is not likely that the position of either foot was produced by muscular activity The position of the feet is interpreted as the result of mechanical influences, such as pressure conditions in utero or whatever effect may have been produced by the pull of the inactive muscles

A simple atrophy of the muscles as seen in this case is in distinct contrast with the degree of atrophy found in congenital clubfoot, in which, even at the same stage of development, the atrophic process is more pronounced, at times proceeding to a complete disappearance of muscle structure and to fibrous degeneration The difference in the degree of atrophy may be attributed to the fact that, in one case, there is no muscular activity whatever, whereas, in the other, certain muscles are under normal nervous control As a result of the action of the normal muscles, the denervated muscles are more or less continually subjected to strains, which would accelerate the atrophic process

The pathologic changes in the nerves were clearly not extensive With the exception of vascular changes—hemorrhage and hyperemia—the nerves presented a normal appearance, if it is borne in mind that the incomplete myelinization was normal for this stage of development of the fetus

The occurrence of hemorrhage in association with congenital abnormalities was repeatedly emphasized by Bagg[3] in his investigations of the effects of roentgen rays on descendents of irradiated white mice He described the formation of localized blood clots in the portions of the extremity which subsequently showed various types of deformity, such as clubbing, syndactylia, polydactylia or amputation Bean,[4] who made an analysis of the anatomic conditions of such deformities in white mice, concluded that the underlying disturbance was a deficiency

3 Bagg, H J Hereditary Abnormalities of the Limbs, Their Origin and Transmission, Am J Anat **43** 167, 1929

4 Bean, A M A Morphological Analysis of Foot Abnormalities Occurring in Descendents of X-Rayed Mice, Am J Anat **43** 212, 1929

in the blood vessel and nerve supply to these regions The influence of muscle action was considered as a factor in the production of the deformity, although it was evident that this could not explain all the features

Hyperemia as seen here in the nerves and muscles was described by Kiyono [5] as a common observation in the endocrine glands in cases of anencephaly As it has not been found in the muscles and nerves in congenital clubfoot, it seems that it is closely related to extensive defects of the central nervous system

With reference to changes in muscles and nerves as seen in congenital clubfoot, it will be recalled that certain muscles frequently show alterations consisting of varying degrees of atrophy The nerves, on the other hand, when subjected to anatomic examination in practically all instances, have failed to reveal any distinct abnormality, although there is a decided diminution in electrical excitability In order to ascribe deformities of the feet, such as clubfoot, hollow foot, etc, to remote disturbances, such as malformations in the lower part of the spine, it is necessary to consider the medium by which such long-range effects may be brought about An association of deformities of the foot with defects in the lower part of the spine would require only one factor to be considered—an interference with the normal development or function of the nerves in the lumbar and sacral regions As a rule, pathologic changes are lacking in the nerves supplying the muscles that are definitely atrophic—a factor which has led to the conclusion that there is merely a physiologic interruption of continuity The absence of anatomic abnormalities in the nerves may rightly militate against any conception that deformities of the foot are the results of developmental defects in the lumbosacral spine However, in view of the fact that a similar appearance of the nerves may accompany complete amyelia as seen in this case, it would be difficult to contradict the possibility of this mode of development solely on the ground of negative changes in the nerves The observations indicate that although visible structural changes are not present in the nerves, they may be functionally deficient Also the question is raised as to why there should not be more extensive degenerative changes in the peripheral nerves since following section of a nerve wallerian degeneration begins in a few days

Another important question suggested by this case is that of myelodysplasia a congenital aplasia or hypoplasia of a portion of the spinal cord a condition frequently used as an explanation for the occurrence of motor, sensory vascular and trophic disturbances of the lower

5 Kiyono H Die pathologische Anatomie der endokrinen Organe bei Anencephalie Virchows Arch f path Anat **257** 441 1925

extremities While a case of amyelia at first sight may appear to be an example of myelodysplasia in its more severe form, it is necessary to distinguish between primary congenital defects due to intrinsic disturbances and secondary degenerative processes due to extrinsic influences It will be recalled that in the case under investigation the peripheral nerves were fully developed even to the point of myelinization This, according to the outgrowth theory of His, indicates that the spinal cord was present in the early embryonic stages for a period of time sufficient to allow the nerves to develop Also in this specimen there was a complete absence of the laminar arches and of the pedicles of the vertebrae, which ordinarily serve as a protective covering for the spinal cord Under these conditions, it is apparent that the absence of the spinal cord was due to a pressure necrosis as a result of lack of protection This leads to the conclusion that the primary defect of development was that of the osseous portions of the spinal canal This seems to harmonize with the idea that in cases of congenital clubfoot resulting from interference with the development of certain nerves in the lumbosacral area, the primary influence is a defect in the bony structures

SUMMARY

A study of the muscles of the lower extremities in a case of amyelia indicates that the muscular alterations are similar to those found in congenital clubfoot, with the exception that the changes are not so far advanced The appearance of the sciatic nerves in amyelia is similar to that of the nerves in congenital clubfoot, with the addition, in the former, of a marked degree of hyperemia The relationship of the spinal canal in amyelia to the spinal cord indicates that the primary defect of development is that of the bony portions of the spine

THE CHANGES OF THE SPLEEN IN SUBACUTE BACTERIAL ENDOCARDITIS *

HERBERT FOX, M D

PHILADELPHIA

The copious literature on subacute bacterial endocarditis of the *Streptococcus viridans* type contains few references to the morbid anatomy of the spleen It is the purpose in the following pages to put on record the results of observations on five cases at the University Hospital and the examination of twenty histologic preparations afforded me by others Preparations have been received from the following Dr McCordoch of St Louis, six, Dr Paul of Yale, four, Dr Bauer of the Pennsylvania Hospital, three, Dr Black at the Philadelphia General Hospital, three, Dr Case at the Graduate Hospital, three, and Dr Reimann at the Lankenau Hospital, one The records of the cases in Philadelphia were personally reviewed, while those in St Louis and New Haven were examined and approved as true *viridans* endocarditis by those who sent the material Only cases in which autopsy had been performed and in which during life or at postmortem examination or both *Streptococcus viridans* was isolated from the blood were accepted In addition, the cases were reviewed with Horder's criteria in mind They all showed fever, endocarditis, bacteria at some location and some evidence of embolic dissemination of the organism—petechiae, infarcts or glomerulonephritis

The principal information concerning the spleen in this disease can be obtained from Clawson's articles [1] The organ is always enlarged and is greater in size in malignant and in subacute endocarditis than in any other form or phase of this disease Infarcts form the most conspicuous morbid change, being found in 62 per cent of cases According to the present studies, these occur most often near the upper pole of the organ and somewhat more frequently on the posterolateral surface Suppuration is not common, but was noted in five of the twenty-five records included here The infarcts may participate in the enlargement

* Submitted for publication, April 3, 1930

* From the William Pepper Laboratory of Clinical Medicine, University of Pennsylvania

* Read before the American Association of Pathologists and Bacteriologists, New York, April 18, 1930

1 Clawson, B J An Analysis of Two Hundred and Twenty Cases of Endocarditis, with Special Reference to the Subacute Bacterial Type, Arch Int Med **33** 157, 1924, A Comparison of Acute Rheumatic and Subacute Bacterial Endocarditis, ibid **37** 66, 1926

of the organ, and this is apparently confirmed by the figures in the present series of cases The average recorded weight of all the spleens is 414 Gm The three without infarcts average 200+ Gm Nevertheless, as will be seen later in this paper, considerable general hyperplasia and increase of blood can contribute to the enlargement The cases of this series have been divided, as well as possible from the description, into acute and subacute typical cases of *viridans* endocarditis and acute and subacute cases that are not perfectly typical It is interesting to note that in the more acute forms the spleen ranges in weight from 250 to 320 Gm, while in the more protracted or more subacute cases the average weights range from 500 to 570 Gm

Arnett and Clawson have separately shown that phenomena of infection are more potent in enlarging the spleen than is passive congestion The foregoing statements and those that are to follow agree with their observations

Concerning the more specific changes in the organ, it may be mentioned that Libman and Aschoff called attention to the prominence of large mononuclears in all tissues, an observation that agrees with the presence of similar cells, especially of the so-called clasmatocyte type, in the blood, probably first noted by Hess [2] This is also consistent with the studies by Gay on the relation of these large mononuclears in streptococcal disease They do not, however, loom so large in the microanatomy of the spleen as one might expect from the investigations referred to

The brief reports of the anatomy of two spleens removed by operation during life in cases of subacute bacterial endocarditis may well be quoted here

Reimann described the spleen from a case reported by Riesman [3] as follows "There is endothelial hyperplasia, diffuse around the blood sinuses, just as in acute splenic tumor, e g typhoid The inference is that the patient had a long standing infection of very low virulence or a long standing toxemia"

Escudero and Merlo [4] also reported a splenectomy in a case of this disease The spleen was large and reddish purple, with various infarcts and an acute perisplenitis at various sites Cultures were positive for *viridans* organisms

External to the spleen, but associated with it, have been noted thrombophlebitis and periarterial hemorrhage in the gastric wall It has been stated repeatedly that pus does not form in *viridans* cases, at least in a manner suggesting it to be the sole effect of the related streptococci

2 Hess, F O Deutsches Arch f klin Med **138** 330, 1922

3 Riesman, David Chronic Septicemic Endocarditis The Splenomegaly Treatment by Splenectomy, J A M A **71** 10, 1918

4 Escudero and Merlo Rev Soc d med int **1** 361, 1925

While this may be true the presence of polymorphonuclears in clumps of various sizes is a frequent observation

With this brief survey of the pertinent literature, the analysis of the changes found in the series of spleens that I have had may be undertaken The individuality of the changes peculiar to this disease lies less with the gross than with the minute anatomy, and the latter affords some idea of the character of the lesions that take place in the organ

GROSS ANATOMIC CHANGES

The spleen in the acute stages or rapidly progressing cases assumed the appearance of an acute tumor of the congestive type—a moderately enlarged, purplish, soft organ, with a smooth, thin capsule, in which there was no capsular inflammation However, it was the exception to see the spleen at any stage without some perisplenitis, and as the chronicity advanced adhesions became more and more evident The pulp was usually soft and of a homogeneous purple until late in the disease, then it was firm and dull red Follicles and trabeculae never seemed overprominent, not even in the two cases that were known to have existed five months Nor did the larger blood vessels show to the naked eye any definite change The matters of weight and infarcts have already been discussed

MICROSCOPIC CHANGES

The twenty-five cases of the present series are divisible into thirteen that seem to fulfil all the requirements of subacute bacterial endocarditis, while the remaining twelve are almost certainly acceptable, yet not so convincing in their history and description The first group includes those that ran a rapid course and are called acute typical (three), and those in which the history ran to five months and in which the clinicopathologic manifestations were less acute (ten) The spleens do not fall into perfectly corresponding groups, however In the acute cases and the more acute of the prolonged cases, there was a definite reduction of follicular size, and the lymphocytic pulp was loose and poor in small round cells The blood content was low, and the blood sinuses and vessels were not conspicuously distended Reticulo-endothelial cells were not prominent Pigment was normal in quantity

In the more advanced cases, there was a striking change in that follicular size increased and germ centers became more evident, reticulo-endothelial cells were vastly increased and much pigment was present

The first group, then, suggests atrophy or at least, depressed activity of the tissue, whereas the second group reveals a pronounced activity of all the elements making up the organ

The twelve cases comprising the acceptable, but not perfect, examples of *vividans* endocarditis are not readily classified with the two

aforementioned groups, but resemble fairly well the second division The more acute cases of this group are like those of the typical subacute division, but in three of the five in the category there was a complicating mixed infection or unrelated concomitant change The atypical subacute group did not show splenic changes in discord with any other group, but the description given is not perfectly applicable

Special Features—The arterial spindles were not prominent features in the typical case, either acute or subacute, whereas in the aberrant case they might be traced with ease This does not mean that in the typical case they were eradicated, for they could be found clearly, but there was no prominence of them

The condition of the germ center commanded attention in five cases by the presence of a coarse coagulum that filled the spaces between a mixture of large mononuclears, adventitial cells and a few polymorphonuclears

Clasmatocytes (this cellular determination being judged by the irregularity of size with laterally placed nucleus), vacuoles and phagocytic debris were found in any number only in two typical cases The location was perivascular and perifollicular Phagocytosis by large nondescript cells was observed in seven instances In one case, I was inclined to consider the consumed material as red blood cells, but I could not be assured of the correctness of this

Granulomatoid Collections—In four cases, cellular accumulations were encountered that challenged attention They were sometimes perivascular or lateral to a vessel, or they were found without association, except, perhaps, that of being near a follicular border as if near a blood vessel They consisted of elongated nuclei of connective tissue type, with a few large, round mononuclears and an irregular scattering of polymorphonuclears The groups were not encapsulated, but around some there was a compression of adjacent cells and fibers that suggested a limitation The whole area suggested a Bracht-Wachter body of experimental endocarditis and differed from the Aschoff nodule in the absence of large vacuolated cells and the more orderly arrangement of that structure

A formation possibly akin to this was seen in one case, a case of atypical endocarditis on a background of previous malaria Scars of a shape and position suggesting removed follicles were found The center was occupied by fibroblasts and granular debris

Polymorphonuclear neutrophils were conspicuous in the spleen in subacute bacterial endocarditis in this series In all stages, typical and slightly atypical, these cells were scattered through the tissue singly and in small groups Nor were they near infarcts The position of most of the polymorphonuclears was along cellular groups that corresponded to lymphatic cords, adjacent to blood vessels, near infarcts and in

follicular centers It cannot be stated that any one of these localities represented a characteristic localization, unless the frequency with which they were formed in germinal centers is worthy of emphasis

Eosinophils were more numerous in this series of spleens than they were in another series from cases of splenic anemia Their distribution was not characteristic, but they were perhaps most easily found where the neutrophilic polymorphonuclears occurred

Disease of the blood vessels of the follicular centers and interlobular septums was not a prominent change In supposedly normal spleens, hyaline change of media and occasional obliterative endo-angiitis of small vessels are well known There was no conspicuous increase of these lesions in the spleens in the cases of subacute endocarditis Only two of this series showed thrombo-angiitis of large veins and in both cases this was in proximity to infarcts Curiously enough, the blood vessels in this series of twenty-five were recorded as markedly altered in only nine instances

The capsular lesions consisted of fibrinocellular exudate that entered the layers of the capsule as well as accumulated on its exterior The process seemed most active near trabeculae, but the material does not permit this to be stated as an absolute observation The cells were chiefly large and small mononuclears, but occasionally a few neutrophils were mixed with them

SUMMARY

The outstanding features of the spleen in subacute bacterial endocarditis of the *viridans* type are as follows

The most important gross lesion is the infarct Practically every case shows perisplenitis whether an infarct exists or not

In early stages, the organ is not greatly enlarged but suggests a soft splenic tumor of the congestive type In the later stages, the organ is definitely enlarged as the result of hyperplasia of its constituent tissue and the inflammatory and hyperplastic changes incident to infarctions

Hyperplasia of lymphatic elements proper is not a feature of this disease, on the contrary, those tissues are inactive Hyperplasia of cells of the reticulo-endothelial series is not seen early, but appears more evident in the cases of longer duration

Marked changes of the linings of blood vessels is not an outstanding peculiarity of this disease Evidences of destruction of blood are missing in early, but present in older cases Degenerations and coagulation within germ centers are frequently observed

Structures suggesting Bracht-Wachter bodies have been seen several times Clasmatocytes are occasionally seen, but rarely in any numbers Polymorphonuclear neutrophils are prominent as revealed in spleens of this series of cases of bacterial endocarditis Eosinophils are also frequently seen

THE EFFECT OF CERTAIN TOXIC SUBSTANCES IN BACTERIAL CULTURES ON THE MOVEMENT OF THE INTESTINES

IV THE PRODUCTION AND ACTION OF THE TOXIC SUBSTANCES OF BACILLUS DYSENTERIAE (SHIGA-KRUSE) *

E E ECKER, PH D
AND
B J WOLPAW, M D
CLEVELAND

It has long been known that toxic substances occur in broth cultures of the Shiga-Kruse type of organisms A short review of the literature is found in the work of Olitsky and Kligler [1] and an extensive study of the "toxinaemia and bacteriaemia dysenterica" was published by Posselt [2]

In most of the published experiments, signs of intoxication were observed in the rabbit and described at the end of twenty-four hours following the injection of the toxic materials At this time, general weakness, paralysis of the extremities and diarrhea were fairly well established However, knowledge is limited concerning phenomena occurring soon after the injection of the toxic filtrates and the effect of the latter on the movement of the intestines in the intact animal

REVIEW OF THE LITERATURE

Lucchini [3] studied the action of the toxic products on an isolated strip of intestine and found that small and moderate doses of the toxic substances produced an increase of tone and of rhythmic longitudinal movements, while larger doses arrested all movements Similar results were obtained when the products were heated at 75 C for one hour Tadokoro and Suga [4] perfused isolated rabbit intestines with a potent filtrate and observed increased peristalsis with small doses and paralysis with larger doses As this action was exhibited after heating of the filtrate at 85 C for one hour, the authors concluded that it was due to other factors than

* Submitted for publication, May 12, 1930

* From the Institute of Pathology, Western Reserve University

* Aided by a grant from the Therapeutic Research Committee of the American Medical Association

1 Olitsky, P K, and Kligler, T J J Exper Med **31** 19, 1920

2 Posselt, A Ergebn d allg Path u path Anat **22** 360, 1922

3 Lucchini Igiene mod **6** 301, 1923, quoted by Posselt

4 Tadokoro, R, and Suga, K Keio Igaku, 1925, vol 5, no 17, abstr, Japan M World **6** 67, 1926

to the toxin itself This conclusion applies also to the work of Lucchini [3] Creazzo [5] pointed out that the toxic effect may be on the plexus of Auerbach The clinical symptoms in dysentery, it is suggested by Tadakoro and Suga, may be due to the stimulation of the accessory sympathetic nerves of the larger intestine instead of to a nonspecific reaction arising from a pathologic change in the mucous membrane

Loeper [6] recorded degenerative changes of nerve fibers and of cells of the plexuses in dysentery of man, and these changes occurred particularly in the region of Peyer's patches Lorentzen [7] found early in the disease changes in the ganglion cells of the intestine (Meissner's plexus) in the form of vacuolization, poor staining and necrosis The process may extend to the cells of Auerbach's plexus These changes one must take into consideration when dealing with intestinal motility in this disease

EXPERIMENTS

The present report concerns a systematic study of the effect of the filtrates of stock and newly isolated cultures of various ages on the movement of the small intestine in the intact rabbit and in the laparotomized rabbit, by the use of both the "pouch technic," as described by Ecker and Rademaekers,[8] and the new method of Ecker and Biskind,[9] which eliminates ethyl carbamate (urethane) anesthesia

Method—Strains 51, 52, 858, 859, 860 and 861 employed in these experiments were obtained through Dr G H Weaver from the American collection of culture types and were all recently isolated when employed One strain was secured through Dr W B Wherry and one strain (Delh) through Prof E P Snyders Strain 731 (A-2440) was supplied by Dr C TenBroeck, of Peiping, China The mediums employed were a 2 per cent Witte peptone veal infusion broth, with a p_H of from 7 2 to 7 4, and the egg albumin broth of Olitsky and Kligler The organisms were grown at 37 C for various periods of time, and the cultures were passed through Berkefeld N candles and the filtrates tested for sterility From 1 5 to 4 cc of the filtrates was injected into the marginal ear vein of the rabbit While the effect of a filtrate on the motility of the laparotomized rabbit's intestine was being studied, an intact control rabbit was given the same dose in order to determine the potency of the filtrate Additional animals, intact and laparotomized, received the sterile noninoculated broth, with no other effects than those described by us elsewhere (Ecker and Rademaekers [8]) The filtrates were heated at 60 C for thirty minutes and at 100 C for five minutes to determine the effect of heat on their potency

5 Creazzo Arch per le sc med **35** 361, 1911

6 Loeper, M Bull et mem Soc med d hop de Paris **43** 196, 1919, Progres med **34** 129, 1919

7 Lorentzen, W Virchows Arch f path Anat **240** 184, 1922

8 Ecker, E E, and Rademaekers, A J Exper Med **43** 785, 1926

9 Ecker E E, and Biskind, M S The Effect of Certain Toxic Substances in Bacterial Cultures on the Intestinal Movement, II, Arch Path **7** 204, 1929

The pouch method of Sollmann for the study of the rhythmic longitudinal muscle movements, as here employed, has been described elsewhere[8] The operations were all performed under anesthesia produced by ethylcarbonate (2 Gm per kilogram), which was administered through a stomach tube Additional studies were made by the new method of Ecker and Biskind[9] Prior to the experiment, all food was withheld for twenty-four hours

The Production of Toxic Filtrates and Their Effect on the Rabbit—Table 1 summarizes the observations on the toxicity of filtrates of cultures of various ages The Wherry strain was grown in 2 per cent Witte peptone veal infusion broth for from twenty-four to one hundred

TABLE 1—*Yield of Toxic Substances in Plain Broth Cultures of Various Ages (Strain Wherry)*

Rabbit's Weight, Gm	Age of Culture When Filtered, Hours	Amount of Filtrate Injected, Cc	Hour of Injection	Results
1,700	24	1 5	10 15	At 11 12, respiration rate is variable, at 11 16, rabbit urinates and flattens, at 11 16, hind legs are weak, at 11 40, rabbit recovers
1,970	24	3	1 15	At 1 50, respiration rate is irregular, at 2 10, rabbit urinates, and hind legs are weak, at 2 15, rabbit flattens, at 2 20, it recovers
1,450	48	1 5	9 50	At 10 48, rabbit urinates and defecates, at 10 55, there is marked defecation, at 11, mild paresis of hind legs is present and respiration is irregular, at 11 15, rabbit recovers, next day, in afternoon, it shows paresis of legs, is very weak, but recovers later
1,508	72	1 5	9 35	At 10 15, rabbit urinates and has paresis of hind legs, at 10 20, it flattens and passes soft stool, at 10 35, it passes more soft stool, at 10 45, it has paresis of front legs, prostration and spasms, at 10 50, it has convulsions at 10 55, it is dead
1,850	120	1 5	10 53	At 11 30, rabbit shows incoordination, at 11 45, its respiration is labored and it is nervous, at 11 50 it flattens, at 11 55, respiration is extremely labored and irregular, rabbit recovers
2,300		Sterile broth filtrate 3, control	10 48	No reaction

and twenty hours, and the cultures were then filtered through a Berkefeld N candle and tested for sterility

From table 1 it is seen that a definite reaction occurred within one hour following the intravenous injection of the filtrate of the culture grown for twenty-four hours The animal inoculated with a filtrate of a three day old culture died in one hour and twenty minutes, thus demonstrating the occurrence of an early acute reaction This is comparable to the more pronounced reaction that we have reported as obtained by the use of young cultures of the paratyphoid group

The majority of the animals survived the immediate reaction Rabbit 6, inoculated with the filtrate of a forty-eight hour old culture, showed typical reactions of the nervous system on the day following the injection, but no diarrhea In the case of this particular strain, then, a minimum of forty-eight hours of incubation in this broth was necessary to

obtain a markedly toxic filtrate Since diarrhea was not common in these animals, we decided to use the egg albumin broth of Olitsky and Kligler and also other strains of the Shiga-Kruse organisms

Table 2 gives a resumé of these observations It is evident from this table that the organisms grown in egg albumin broth produced potent filtrates Early and marked reactions occurred in all the animals receiving injections Intestinal reactions (diarrhea) were present in eight of the eleven rabbits receiving the injections These occurred in from forty-five to eighty minutes following the injections of the toxin Nervous symptoms were noted both early and late in all but one of the animals Two of the rabbits receiving injections survived, and seven died within twenty-four hours Two others died on the third day following the administration of the filtrate Two died within four hours after the injection of the filtrate Of the six strains of *B dysenteriae* (Shiga-Kruse) employed, not one failed to produce a potent filtrate Severe diarrhea and paralysis were also produced in animals that received saline washings of the Wherry strain grown for twenty-four hours at 37 C in Kolle flasks on plain agar The washings thus secured were incubated at 37 C for three days prior to filtration

Resistance of the Toxic Filtrates to Heat—In a series of experiments (table 3), we determined the effect of heat on the potency of the filtrates of three and five day old growths of two strains in plain broth and in egg albumin broth

Heating of the filtrates of three and five day old growths of the Wherry strain at 60 C for thirty minutes and at 100 C for five minutes left the filtrates practically unaltered in potency The early reactions were similar to the reactions obtained following the injection of the nonheated filtrates Filtrates of the Deli strain grown for three and for five days in veal infusion broth and heated at 100 C for thirty and for sixty minutes showed a definite decrease in potency On injection of a filtrate of a three day old culture of this strain heated at 100 C for one hour, the rabbits appeared weak and discharged a moderate amount of soft feces One of the two animals showed a moderate paresis of the hind legs Heating of this filtrate at 100 C for thirty minutes was insufficient to weaken the filtrate to the extent of the one heated at 100 C for one hour The reactions were marked, and one rabbit was found paralyzed, with a marked fecal discharge on the day following the injection The reactions noted following the injection of filtrates of this strain were of the nervous type The filtrate of a five day old culture of this strain was greatly weakened following heating at 100 C for one hour The control animal died in three days with all the typical symptoms

TABLE 2.—Yield of Toxic Substances in Egg Albumin Broth by Several Strains of B. Dysenteriae (Shiga-Kruse)

Rabbit's Weight, Gm	Number or Name of Culture	Age, Hours	Amount of Filtrate Injected, Cc	Hour of Injection	Results
2,190	Cinci	120	1.5	3.00	At 4, rabbit is very excitable, at 4.15, it has convulsions, at 4.25, it has more convulsions and dies
1,950	Cinci	120 (new culture)	1.5	1.45	At 2.27, rabbit urinates, at 2.30, it flattens, has diarrhea and is nervous, at 2.45, shows marked diarrhea and at 3.10, tremors, at 5.30, it shows paresis of hind legs and lies on side, at 5.40, it has convulsions, at 5.45, it is dead
1,420	731	120	1.5	11.30	At 12, rabbit has marked diarrhea and at 12.20, still more diarrhea at 12.24, it urinates, at 12.30, it has paresis of hind legs, it remains sick all afternoon and evening, next day it is very sick, lies on side and is paralyzed, it survives
2,130	731	120	2.0	11.00	At 12, rabbit has diarrhea with urination and cramps, at 12.10, it passes liquid feces, at 12.12, more liquid feces and at 12.27, a mucous discharge, it dies during the night
1,605	731	72	1.5	10.25	At 10.45, rabbit defecates, at 10.47, it urinates, is prostrated, swings from side to side, at 11.15, it passes soft fecal balls, at 11.35, there is marked defecation of soft stool, two days later, rabbit shows complete paralysis of front and hind legs and diarrhea and dies on the third day following injection
1,700	51	120	1.5	1.55	At 2.40, rabbit urinates, at 3, it defecates, at 3.05, it has cramps with defecation at 3.15, it flattens, at 3.20, the hind legs are weak, 48 hours later, it has paralysis of front legs, soft feces, marked diarrhea and beginning paralysis of hind legs, on third day after injection, rabbit dies
1,900	51	120	1.5	10.50	At 11.45, rabbit urinates, at 11.46, it passes soft feces, at 11.52, it has diarrhea, at 12, it has a mucous discharge and is weak, next day it is very weak and dies
1,550	860	120	1.5	11.45	At 12.15, rabbit defecates and urinates, at 12.30, it flattens, and respiration is rapid at 12.35, it passes soft feces, at 12.37, it has diarrhea and paresis of hind legs, at 12.45 and 12.55, there is more diarrhea. Rabbit appeared recovered in the afternoon
1,550	860	120	1.5	11.05	At 11.55, rabbit urinates, at 12.10, it is nervous and at 12.12, hyperpnea, at 12.20, it defecates, at 12.30, it is very excitable, showing twitchings of muscles, and it remains so all afternoon, at night, rabbit dies
1,500	859	120	1.5	11.00	At 11.48, rabbit defecates, respiration is labored, at 12, rabbit flattens and is nervous, at 12.35, it is weak in the hind legs and excitable, at night, it dies
1,900	861	120	1.5	11.20	At 11.40, rabbit urinates, at 12, it appears spastic with cramps, at 12.07, respiration is labored, at 12.08, rabbit is restless, at 12.13, it shows air hunger, at 12.15, it is extremely excitable, at 12.30 it urinates and at 2, defecates, during night, it has diarrhea and is dead the next morning

Effect of the Filtrates on Intestinal Movements—Eleven experiments were made with the Sollmann pouch technic in order to observe directly the reactions of the small intestines to the filtrates The dosages used varied from 1 5 to 4 cc of filtrates of three to six day old cultures of

TABLE 3—*Effect of Temperature on Potency of Toxic Filtrates of the Wheary Strain*

Rabbit's Weight, Gm	Age of Culture When Filtered, Hours	Exposure to Heat, Degrees C	Time of Exposure, Minutes	Amount of Filtrate Injected, Cc	Hour of Injection	Results
				Plain Broth Cultures		
1,508	72	0	0	1 5	9 35	At 10 15, rabbit urinates and has paresis of hind legs at 10 20, it flattens and passes soft stool, at 10 45, it it passes more soft stool, at 10 45, it has paresis of front legs, prostration, spasms, and at 10 50 convulsions, at 10 55, it dies
1 550	72	60	30	1 5	3 05	At 3 45, respiration deepens, at 3 55, animal urinates, at 4, it has marked diarrhea at 4 45, it is very weak and lies on side at 5 20 it is slightly recovered, next day, it is very weak and at night has considerable diarrhea, and dies
1,850	72	100	5	1 5	3 03	At 4 03, respiration is increased from 120 to 200+, at 4 45, animal is prostrated and has paresis of hind legs at 5 15, it dies in convulsions
				Egg Albumin Broth		
1,950	120			1 5	1 45	At 2 27, rabbit urinates at 2 30, it flattens, has diarrhea and is nervous at 2 45, it has marked diarrhea at 3 10, tremors at 5 30, paresis of hind legs, lying on side, at 5 40, convulsions at 5 45, rabbit is dead
2,300	120			1 5	10 00	At 10 10, rabbit urinates at 10 35, respiration is labored, at 10 40, rabbit urinates, at 10 45, respiration is irregular, at 11 05, there is marked defecation (soft feces), rabbit presents no further symptoms and recovers
1,720	120	60	30	1 5	2 20	At 2 50 respiration is irregular, at 3 05, rabbit is extremely nervous and has slight convulsions, at 3 30, it is prostrated, at 3 33, it shows air hunger and convulsions at 3 35, it is dead
1 900	120	60	30	1 5	10 15	At 10 25, rabbit urinates, at 10 40, respiration is labored at 10 45, animal is extremely nervous and dyspneic, and defecates at 10 55, there is more defecation, and at 1 15, intermittent convulsions at 1 45, it is dead
2,150	120	100	5	1 5	10 27	At 11 25, rabbit flattens at 11 30, it urinates and shows copious discharge of fecal balls, at 11 32, it has diarrhea and is very nervous In ten days it is dead It remained weak and sick throughout the ten days

strains 731, 941, 858, 860, 861 and Wheary All these filtrates were highly toxic for the control rabbits Three types of reactions were noted In four of the eleven experiments recorded here in composite form, an increase of tone of the longitudinal muscles with an increase of the amplitude of contractions was observed (graph *A*), and in five experiments similarly recorded, an increase of tone with a decrease in the amplitude of contractions (graph *B*) In two experiments a rise

in amplitude with no change in tone was found (graph *C*) The graphs demonstrate the type of reactions observed

A control series of intact rabbits received the same filtrates at the same time as the laparotomized rabbits When the reactions of the intact and of the laparotomized animals were compared, it was found that filtrates which caused diarrhea in the normal rabbits usually caused a rise of tone of the intestines in the laparotomized animals Filtrates that caused severe reactions of the nervous system caused the most marked rises of tone, accompanied, however, by a decrease of amplitude of contractions Usually the diarrhea observed in the intact animal preceded the changes noted in the laparotomized animals This may be accounted for by the inhibiting influence of the urethane anesthesia.

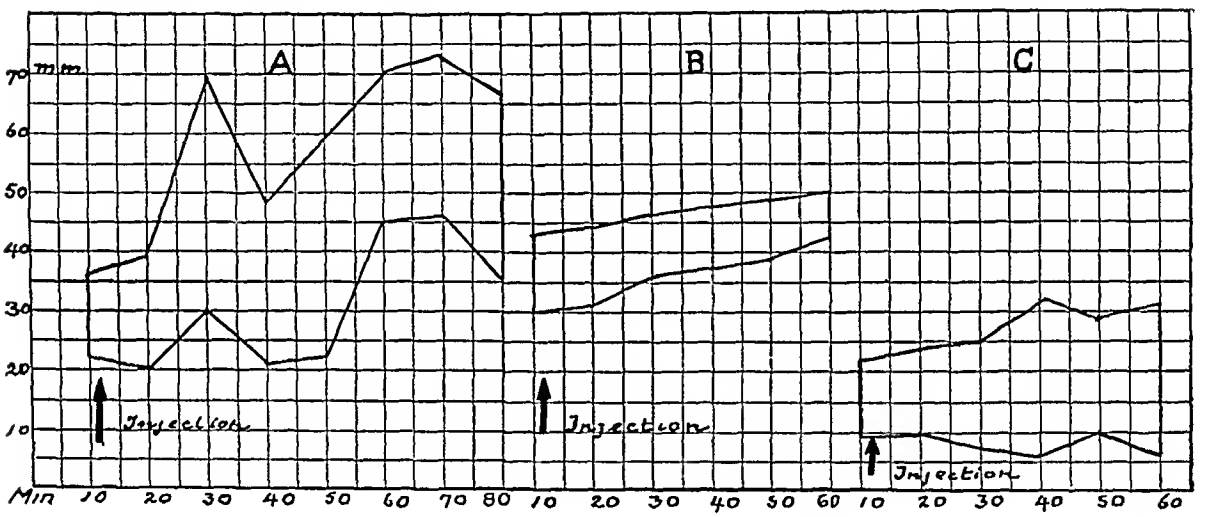

Graphs showing changes of tone and of the amplitude of contraction of the longitudinal muscles following injection of filtrates of cultures of B dysenteriae (Shiga-Kruse) *A*, an increase of tone with an increase of the amplitude of contractions, *B*, an increase of tone with a decrease of the amplitude of contractions, and *C*, an increase of the amplitude of contractions with no change in tone

In four experiments, an increase of tone and of amplitude of contractions in the laparotomized animals was observed, while the control animals had severe diarrhea

Strain 731 produced a rise of tone of the longitudinal musculature, with a variable effect on the amplitude of contractions The Wheiry strain caused a rise of tone, accompanied by a decrease of amplitude of contractions These facts demonstrate the variability of the reactions that may be obtained with filtrates of different strains of this organism Animals also differ in susceptibility Certain strains (861 and Deli) produced severe neurotoxic effects

Variation in Susceptibility of Animals—To meet the question of individual variability of the animals, 4 cc of a filtrate of a one hundred

and forty-four hour culture of strain 731 was injected into each of four animals The resulting reactions were strikingly similar, namely, a transitory increase in the rate of respiration of the animal, then a slowing with increased depth, urination at the end of one hour, diarrhea and death within from twenty-four to forty-eight hours The animals did not show symptoms of involvement of the nervous system

Relation of Age of Culture Filtrates to Type of Reactions Produced —Repeated tests showed that the age of the culture was of some importance with regard to both symptoms and ultimate prognosis Filtrates of twenty-four hour old cultures usually produced mild nervous symptoms with no diarrhea Filtrates of forty-eight hour old cultures caused increased nervous symptoms with defecation, but not diarrhea No deaths followed injections of filtrates of cultures from twenty-four to forty-eight hours old Filtrates of seventy-two hour old cultures produced the most consistent symptoms of dysentery, namely urination, paresis and paralysis of the hind and front legs, diarrhea, local spasms and general convulsions and death The reactions began uniformly one hour after the injections of the filtrates

A filtrate of a fourteen day old culture produced marked nervous symptoms, namely dyspnea, prostration, paresis, paralysis and death in less than twenty-four hours Here no diarrhea was noted

Observations on Intestines under Oil According to the Method of Ecker and Biskind —In a series of four experiments performed by the method of Ecker and Biskind,[9] the filtrates of three strains, nos 986, 731 and 52, were employed The ages of the cultures were 4, 5, 6 and 30 days The normal control animals showed prostration, defecation and neurotoxic reactions The laparotomized animals showed an increase of contractions in the longitudinal muscles of the upper intestines and an increased activity of the lower colon, with marked propulsion The lower colon appeared to be more active than usual The most marked effect was obtained when the filtrate of a month old culture of strain 731 was injected In this case, the tone of the cecum was markedly increased, and rolling movements of the haustra of the colon were noted In general, the reactions were mild, and the results compared favorably with those obtained by the older method

SUMMARY

Although toxic manifestations were noted in rabbits that received filtrates of twenty-four to forty-eight hour old cultures by vein, the most marked reactions occurred in those animals that received filtrates of seventy-two to one hundred and twenty hour cultures This was true of both the filtrates of cultures grown on 2 per cent Witte peptone veal infusion broth and those of cultures grown on the egg albumin

medium of Olitsky and Kligler Diarrhea was more common in these animals than in the animals inoculated with the filtrates of younger cultures

Sardjito [10] also noted that the formation of these toxic substances did not begin until after the third day of incubation Okell and Blake [11] observed that viable cells appear in their greatest number in twelve hours, and that filtrates usually attain a maximum toxicity when a p_H of from 8 6 to 8 8 has been reached During the period of increasing toxicity, autolytic changes (as gaged by microscopic observations of the bacilli) become more and more marked They described two stages in the production of these toxic substances "(1) a growth (or endotoxic) phase lasting 12 to 18 hours when all the toxin is produced as endotoxin within the bodies" and "(2) an autolytic (or exotoxic) phase during which autolytic processes gradually disintegrate the bacilli and release the endotoxin into the circumambient medium (filtrate) "

As stated before, powerful toxic substances did not occur in our very young cultures We agree with Kanai,[12] Przesmycki [13] and Robertson [14] that it is at present difficult to split an exotoxin and an endotoxin in the sense of Pfeiffer However, Olitsky and Kligler stated that such a differentiation can be made It is also possible that the type of toxic elements produced in vivo may greatly differ from that produced in vitro (Ludke [15]), and that different products are elaborated during the growth of the organism

Of thirty-eight animals into which the filtrates of various strains of the organism were injected, twenty-eight died Thirty-two animals showed involvement of the central nervous system (medulla and cord), and twenty-nine showed diarrhea of varying degrees of severity Kanai [12] showed that the toxin of this organism affects principally the central nervous system and at the same time acts on the capillary circulation generally, with the production of hyperemia and hemorrhages in the various viscera Olitsky and Kligler [1] believed that the so-called exotoxin operates on the central nervous system and that the endotoxin affects the gastro-intestinal tract At present, it is doubtful that divisions into distinct fractions can be accomplished, in view of the complexity of the mediums employed for the production of these substances, etc The reactions observed in the laparotomized animals were not marked They appeared variable, a rise of tone with an increase of amplitude of contractions and also with a decrease of amplitude

10 Sardjito, M Geneesk tijdschr v Ned Indie **66** 337, 1926
11 Okell, C C, and Blake, A V J Path & Bact **33** 57, 1930
12 Kanai, S Brit J Exper Path **3** 158, 1922
13 Przesmycki, F Med dosw i spol **5** 18, 1925
14 Robertson, R C Brit M J **2** 729, 1922
15 Ludke, H Deutsche med Wchnschr **50** 1569 1924

of contractions of the longitudinal musculature being seen Furthermore, a simple increase of the amplitude of contractions without a rise of tone was also recorded Direct observations under oil gave the impression of an increased activity of the lower colon following the injection of the filtrates At no time, however, was a peristaltic rush observed It seems justifiable to assume that the filtrates, owing to their variable neurotoxic qualities, affect the vagus in a greater or less degree, or that the preexisting tone of the intestines accounts for the reactions seen Robertson [14] believed that the neurotoxin has a secondary action on the intestine, through the initial inhibition of peristalsis prior to the passing of mucous or desquamated epithelial debris Additional studies are required to elucidate further the mechanism in question

General Review

JUVENILE ARTERIOSCLEROSIS *

PEARL ZEEK, M D
CINCINNATI

Arteriosclerosis occurs in children much more frequently than is commonly believed Even in infancy may be found not only the early manifestations of the disease, but occasionally stages so far advanced as to present extensive calcification A careful study of the disease in the early years of life is especially valuable from an etiologic standpoint, since in such cases many of the complicating factors of adult life are absent (Dickinson)

The term "arteriosclerosis" was first used by Lobstein in 1834 (cited by Collins) Later, Jores limited its use to those conditions in which there was definite fatty degeneration in the intima Marchand used the term in a much broader sense, including all changes in the coats of arteries that lead to a thickening of the wall Klotz, in 1915, employed the term in a generic sense, not to define any particular disease, but to denote a process induced by a variety of factors the end-result of which is a hardening of the arteries Later modifications of the definition may be found in the writings of Osler (1918) and Evans (1923)

In the present study, an attempt has been made to include all cases in which there was definite thickening, hardening or scarring of the arterial walls resulting from degenerative and nonspecific inflammatory processes, thus excluding all cases in which the disease was frankly syphilitic, rheumatic or immediately pyogenic in origin, and also omitting those in which the lesions were the results of operative procedures or traumatic accidents Furthermore, this study does not include periarteritis nodosa or the lesions known as the thrombo-angiitis obliterans of Leo Buerger

The lesion of particular interest in this review is the so-called simple arteriosclerosis, of undetermined etiology, commonly believed to begin in the intima with lipoid degeneration (Saltykow, 1926), often followed by calcification The process may or may not be accompanied by a definite inflammatory cellular reaction, it may be focal or diffuse, it may be limited to the intima or may involve all coats Sometimes it involves

* Submitted for publication, May 14, 1930

* From the Department of Pathology of the University of Cincinnati and the Cincinnati General Hospital

only the aorta and large branches, at other times, it affects the visceral arterioles, and again it may be most manifest in the media of peripheral arteries

Although the term "juvenile" has been used by certain authors to refer to a particular type of arteriosclerosis occurring at any age, and by others to include any type occurring before the third or fourth decade, this review will be concerned only with cases occurring before the twentieth year of life

EARLY PERIOD OF INVESTIGATION, BEFORE 1872

The first mention of this condition in children was by Hodgson in 1815 (cited by Fremont-Smith), who described the temporal artery of a 15 months old infant as being "converted into a complete tube of calcareous matter" In 1826, Martin stated that he had observed changes in the aorta after the first year, but had never seen disease of the middle-sized branches before the twentieth year (cited by Fremont-Smith) Three years later, Andral noted calcified plaques in the aorta of an 8 year old girl, but thought that they occurred in the media He said, however, that the internal coat was often "detached from its connections by the calcium concretions" and later stated "the bony material is simply deposited between the internal and middle coats" He even suggested that "the bony matter may originate in the atheromatous material," which he frankly recognized as being located in the intima He further said, "All we know of the formation of these ossifications is that they are the result of a derangement in the natural processes of secretion and nutrition It is a general and constitutional derangement associated with too free use of animal diet" A hundred years have passed since this was written, but the etiology of arteriosclerosis is still obscure

During the twenty-five years following Andral's publications, little is found in the literature concerning this condition in children In 1855, Rokitansky's "Pathological Anatomy" was published, in which is the suggestion that the atheromatous plaques may be derived from the blood The author observed that the "deposition is generally thickest directly over the division of a trunk, or at the bifurcation of a vessel" He strictly differentiated this process, which he considered degenerative, from a true inflammation In regard to age, he recognized the occasional absence of the disease in old persons, as well as its occurrence in childhood and believed that when it occurs prior to the age of 20 years it is usually a local disease, depending on congenital or early acquired anomalies of the blood vessels or heart He considered the disease to be caused by a peculiar condition of the arterial blood, apparently antagonistic to tuberculosis and associated with an excess of fat and cholesterol He

was one of the first to direct attention to the rarity and peculiarities of this condition in the veins

During the following decade so little was heard of this condition in children that Lebert in 1867 wrote "In youth atheroma is very rare, it begins usually after the 40th year of life" A similar opinion was expressed three years later by Steiner and Neuretter, and during the same year Holmes wrote, "The gouty, the aged, the rheumatic, the persons whose tissues are embued with fat, and those whose excretory organs fail to purify the circulating blood, are more prone to this disease than the phthisical, the cancerous, or the young" In 1872, De Mussey, in a thorough review of all phases of hardening of the arteries, stated that he had seen the condition in persons "as young as 17 years"

MIDDLE PERIOD, 1872 1900

The year 1872 marked a milestone in the study of arteriosclerosis, for it was in that year that Sir William Gull and Henry G Sutton published their often-to-be-quoted paper, "Chronic Bright's Disease" Besides stressing the importance of arteriolar changes in this condition, they reviewed 336 cases that had come to autopsy, one of these being that of a 9 year old child Not only did this article and others by the same authors arouse widespread discussion and dissension, but workers everywhere began to note more carefully changes in the vascular system in all kinds of cases and at all ages Chronic nephritis became of especial interest and was studied not only in adults but also in children So, in 1874, Barlow reported the case of a young child with vascular changes associated with contracted kidney The following year a case of aortic disease unassociated with renal lesions was observed in France (Moutard-Martin)

In 1881, the results of a decade of careful observation and study began to appear in the literature Tyson recognized an association between chronic nephritis and diabetes and also noted changes in the vascular system in both diseases Phanomenow reported a case of abdominal aneurysm in a newly born baby, probably atherosclerotic in origin But of most importance to this study was the appearance in that year of Dickinson's masterly "Treatise on Albuminuria," in which he cited many cases of undoubted arteriosclerosis associated with renal disease in children He also recognized an increased arterial tension in such cases and described muscular hypertrophy in heart and blood vessels as following an "overexertion of the heart and arteries" attempting to drive blood through "vessels which seem to be overfull" But he did not believe, as did some of his successors, that this muscular hypertrophy constituted the sum and substance of arteriosclerosis, but stated, "The

arteries, besides mere muscular thickening, undergo degenerative and pseudo-inflammatory changes, palpable atheroma, nuclear and muscular degeneration and marked thickening of the fibroid sheath" He also appreciated the tendency for hemorrhages to occur in the type of arteriosclerosis associated with renal disease He said, "In granular degeneration of the kidney in children the vascular change is extreme and characteristic, the hypertrophy of the left ventricle great, and cerebral hemorrhage an occasional termination" He believed that the "cardiovascular thickening is a direct consequence of simple renal inflammation and is directly produced by it"

In 1883, the influence of Gull and Sutton was manifested in Germany in Filatoff's diagnosis of "arteriolar capillary fibrosis" with contracted kidneys and atheromatous arterial degeneration in a 12 year old boy The following year, Thoma expressed his views on the influence of mechanical factors in causing the closure of arteries in amputation stumps These observations were followed by years of the most painstaking experimentation on his part to prove the mechanical origin of sclerotic plaques in blood vessels Thoma (1886, 1911 and 1922) believed that thickening of the intima by connective tissue followed slowing of the blood stream Although other workers (Ophuls, 1906) repeated his experiments, with different results, causing much of his work to stand discredited today, nevertheless Thoma helped to emphasize the need for careful experimentation in the field of arteriosclerosis and thus made a valuable contribution to this subject

During the next five years, reports of seven more cases appeared in the literature (table 1) In 1887, Sanne published a review of the subject, "Aneurysm in Children" He concluded, "The pathology is the same as in adults To ascertain the underlying cause one must study the heredity and past history of the patient"

In Keating's "Encyclopedia of Diseases of Children," one again finds emphasis placed on the rarity of atheroma in youth The author stated that when it does occur it is found usually in the blood vessels of the brain and in the aorta During the same year, Grode reported two cases of marked arteriosclerosis in young boys addicted to alcohol

In 1893, Basch published a series of articles on latent arteriosclerosis, but was more interested in the changes occurring during the third and fourth decades of life than in those of childhood Other writers, however, have recognized similar latent changes in young persons

Dohle's article in 1895 on syphilitic disease of the aorta, followed in 1897 by Dmitrijeff's description of the changes in elastic tissue in arteriosclerosis, emphasized the growing opinion that syphilis produces a definite pathologic picture that can usually be differentiated from other

types of arterial disease Henceforth, fewer authors gave syphilis as the probable cause of atheromatous lesions (Allbutt, 1899)

Seitz (1896) expressed the opinion that arterial changes in the young were not so rare as had commonly been believed to that time Besides collecting a considerable number of cases from the literature, he reviewed in detail 3 of his own cases, and also stated that among 148 cadavers examined in the Munich Pathological Institute he found characteristic changes in the blood vessels of 17 persons that were between 10 and 29 years of age Also, he had encountered numerous cases clinically He believed that in his cases he could fairly well rule out presenile changes, alcoholism, muscle strain, syphilis and intestinal intoxication, but thought heredity might be an important etiologic factor This factor was again emphasized in 1899 by Brill, especially in cases associated with chronic nephritis During the same year, Durante described a case of aortic disease developing in utero The hereditary factor was emphasized as recently as 1925 (Mortensen) and 1926 (Leopold)

In spite of all these cases in the literature, Baginsky in 1899 wrote "Aneurysm and chronic endarteritis are very rare in childhood"

RECENT PERIOD, 1900 1930

During the first five years of the period from 1900 to 1930 reports of cases and observations appeared in the literature from many sources Probably there were two chief reasons for this first, the developing interest in infection as an etiologic factor in arterial disease, inducing more careful examinations of the vascular system in deaths from the infectious diseases of childhood (Stengel, Simnitzky, Seitz, 1901, Buchta, Jordan, Gilbert and Lion, Torhorst, and Thayer), second, the reopening of the subject of chronic nephritis in children (Guthrie, cited by Greene, Barnes, Milligan, cited by Greene, Hirsh, Anderson, Democh) It was also at this time that Bryant and White described their interesting case of extensive vascular sclerosis with calcification in a 6 months old baby in whom the only obvious etiologic factor was extreme phimosis, with urinary obstruction

Parallel with the study of arteriosclerosis in children, intensive work was done during this period on the general subject of vascular disease, much of which was in the experimental field (Jores, Matusewicz and others)

During 1904, a comprehensive series of reports appeared presenting the data for and against the various agents suspected of causing arteriosclerosis (Cabot, Stengel, Thayer, Billings, Dock) During the same year, a similar discussion was carried forward in the Congress fur innere Medizin in Germany Here Romberg mentioned the frequency with which he had observed arteriosclerotic changes in young persons, many

of whom did not have chronic nephritis Schott had frequently seen the condition in youth, and believed that in such cases the disease might remain stationary for a long time, or was capable of flaring up and progressing rapidly

The following decade (1905 to 1914) added many articles summarizing, commenting on, and occasionally contributing more data to, the accumulated evidence that infection plays an important etiologic rôle in arteriosclerosis Wiesner and Wiesel found changes in the coronary arteries in young persons with verrucous endocarditis, osteomyelitis and other acute infections Saltykow (1908) and Manouelian produced atherosclerosis in animals by repeated injections of staphylococci Lubarsch found atherosclerosis in young dogs dying of acute infections

Frothingham studied the relationship between infectious diseases and arterial lesions in man He found vascular lesions in fifty-six persons under 25 years of age, and in nearly all persons over that age who suffered from infectious diseases In all of his patients over 1½ years old dying of tuberculosis, typhoid fever, glanders or pneumonia there were intimal changes in the aorta Frothingham believed that in patients who recover from acute infections, the vascular changes may also disappear, except those in which actual necrosis has occurred In such cases, healing is by the formation of connective tissue and the scar is permanent The lesions that heal without scarring consist of fatty droplets in the tissue cells In 1915, Klotz expressed a similar opinion In a later article (1913), Frothingham discussed all the various factors believed to be of etiologic importance in arteriosclerosis and concluded "It is certain, therefore, that infections may cause localized arterial lesions but the evidence in regard to their causing diffuse arterial disease is lacking As to the most likely causative agents in production of arteriosclerosis, the most evidence at present is in favor of retained metabolic products through faulty elimination, and acute infections"

During 1913, Hirsch in Berlin emphasized the hereditary factor, especially in juvenile cases He also differentiated arteriosclerosis from "angio spasm" and "nervous heart," which often present similar symptoms

During this period, the effect of epinephrine and high blood pressure on the cardiovascular system was studied extensively (Josue, Harvey) By injecting epinephrine hydrochloride, Fischer produced aneurysms, and Ziegler, necrosis and calcification of the media with compensatory intimal thickening By the use of amyl nitrite, Braun counteracted the effect of epinephrine in raising blood pressure, and found the same type of pathologic lesions as when epinephrine was used alone, Boveri modified the severity of the lesions following the administration of epineph-

rine by the use of iodized sesame oil 40 per cent Rickett obtained lesions in the media by using mechanical means of raising blood pressure In 1909, Harvey pointed out that the lesions of experimental arteriosclerosis were a medial degeneration of the Monkeburg type, while Sumikawa showed that sclerosis of the human aorta and large vessels begins in the intima

The trend of thought in relation to juvenile arteriosclerosis was decidedly affected by the experimental work of this period Ferenczi looked on vascular lesions in childhood as a sign of exhaustion, which, under ordinary conditions, occurs only in old age, but occasionally, as a result of hard physical labor, toxins, high blood pressure, etc, the "resistance capacity" of the vascular system may be exhausted early in life A similar opinion was expressed by Romberg, who called it a "wearing-out process" and recognized its frequent occurrence in young persons

In 1912, Klotz wrote, "If we wish to gain a true insight into the complex question of arteriosclerosis we must attempt to follow the lesion from its earliest beginning" He mentioned grossly visible superficial fatty streaks in the blood vessels of persons from 1 to 73 years old (the majority being between the ages of 20 and 30 years) Changes were found in the aorta more frequently than in any other vessel The fatty streaks were rarely seen before the tenth year of life, he mentioned only four cases all of which followed scarlet fever Furthermore, Klotz differentiated fatty intimal streaking from the nodular pearly thickening seen at orifices of blood vessels and in the walls of peripheral arteries Fatty streaks were particularly associated with infectious diseases, such as typhoid fever, pneumonia and acute osteomyelitis In only two of thirty-five cases of typhoid fever in which blood vessels were examined for yellow streaking, was it absent Jores was the first to show that these yellow streaks in the aorta in young persons were the beginnings of arteriosclerosis Torhorst did not see much relationship between the two conditions Zinserling studied the polarizing effect of these fatty particles in the young and found it to be the same as in older people They occurred with great frequency in young persons (from 16 to 17 years old) dying of typhoid fever, also in children from 6 to 10 years old who suffered from various infectious diseases They were even found in a 3½ year old child with measles followed by scarlet fever

In 1909, Foster studied sections of aorta and arteries from persons varying in age from 6 months to 80 years and concluded that there is progressive development of elastic tissue up to 35 years of age, causing an increase in thickness of the wall of the blood vessel and a relative decrease in muscle tissue Therefore, in the early decades, a moderate

increase in thickness of the walls of blood vessels due to physiologic processes is to be expected

By this time, the term arteriosclerosis had come to include such a wide variety of lesions that different writers attempted to define and classify the various lesions But opinions varied so widely concerning etiology, site of origin (in intima, media or adventitia) and the steps in development that no definition or classification met with unanimous approval (Klotz, 1906, Brooks, Poynton, Aschoff, 1908, Halbey, Nascher) These, however, were not the first attempts made to define the term Every few years since Lobstein in 1834 used the name "arteriosclerosis" to designate a pathologic process, some one has attempted to bring order out of chaos by means of a definition or a classification, but only the broadest use of the term has stood the test of time

Collins, in 1906, wrote a review of the various theories concerning arteriosclerosis, including experimental data, but he said little about the disease in children The following year, Vollbrecht attempted to collect all the available material—"clinical, pathological and literary"—on juvenile arteriosclerosis for an inaugural dissertation Including only cases in which the patients were of ages up to 36 years, he collected twenty-eight from the literature and twenty-one from the Leipziger Medical Clinic All of those in which the patients were under 20 years of age, on which the original report verified the diagnosis of arteriosclerosis, are included in the present study

In 1908, another review of cases from the literature was written by Fremont-Smith He concluded "In the previously detailed cases there appears a remarkable uniformity in pathological changes in a great variety of conditions The findings of Flexner in typhoid fever and of Wiesel in many infections are practically identical and point to a uniform primary medial degeneration in these diseases, and in certain other intoxications not of bacterial origin"

Many other writers of this period mentioned juvenile arteriosclerosis Aschoff (1908) saw a typical lesion involving the mitral valve in a 1 year old child Schlayer looked for it in 100 persons between 14 and 23 years of age and found it in 37 Frederich and Romberg saw it in young persons subjected to hard physical labor

During these years there were also further studies made concerning the relationship between renal disease and arteriosclerosis Miller and Miller and Parsons and Barber (1913) reported cases of chronic nephritis in children in which the vascular changes were slight or absent, while reports on other cases showed marked vascular involvement (Barber 1913, Miller and Parsons) Gaskell classified nephritis

according to the type and extent of the vascular lesions Ernberg made follow-up observations on a large number of cases of nephritis in childhood, ascertaining, among other things, that a considerable proportion of such cases reveal cardiovascular symptoms during the third decade of life Most of his patients did not return for follow-up until after they were 20 years of age, but the extent of the disease in some of them would indicate that the cardiovascular involvement had begun years earlier

In 1914, Stumpf studied the aortas of eighty-five children and found degenerative changes frequently after the first year of life He wrote, "I have shown that the degenerative changes in the aorta of the child are in part due to mechanical factors As I believe, it comes about in certain places by pressure and pull of developing disturbances in the circulation of lymph in the vessel wall, from which a degeneration of tissue, injured in this way, takes place As one studies many groups of children of different ages one must conclude that the mechanical factor is not the only one which may injure the aortic wall in youth" He believed chronic infections might also produce such changes

During the same year, Holt said, "In early life chronic disease of the blood vessels is exceedingly rare But even young children are not exempt" He found reports of seven cases of atheroma in the literature and believed that probably the most important etiologic factor was syphilis, but he mentioned several other possible contributory factors

During the years from 1915 to 1930, interest in the problem of arteriosclerosis continued to grow, as is shown by the great mass of material in the literature on all phases of the subject Reports of nineteen cases in persons under 20 years of age were published, and several studies are on record that lay special emphasis on the disease in children Saltykow in 1915 sought to differentiate normal developmental changes in the aorta from degenerative ones, but was convinced that "the so-called fatty changes in the arteries of childhood and youth, especially in the aorta, are nothing else but the beginning of atherosclerosis" McMeans studied the changes in elastic tissue following acute infections in children as young as 5 years He interpreted the changes as "a tissue response to an irritant," and described them as (1) granulation and splitting of the elastic fibers, (2) diffusion of the elastic-staining material and (3) difference in tingeability of the fibers He believed that they pointed to a chemical rather than a mechanical change and were found in cases in which age or wear and tear could be factors The elastic tissue gradually acquires a special affinity for fatty substances, which in turn, predispose to calcification Any cellular exudate present arises by a direct migration of wandering cells from the surface of the artery

Klotz (1926) examined the arteries of young people (from 10 to 18 years of age) who had died of acute infections He decided that the mechanical theory could not adequately explain the button-like thickenings in the intima

In 1920, Evans reviewed arteriosclerosis as related to renal disease and found extensive evidence to support his theory that arteriosclerosis is of inflammatory origin In the examination of 1,800 fixed sections he found sclerosis of small blood vessels more common in the kidney than in any other organ, and never found it elsewhere unless present also in the kidneys and spleen Two years later, he said that in younger persons the response to injury is apt to be more active, therefore the endothelial proliferation in the walls of small blood vessels is more marked in juvenile than in adult arteriosclerosis "This," he said, "is further evidence of the inflammatory origin of arteriosclerosis" Evans considered the changes in the vessels and in the glomeruli as probably being simultaneous results of a single pathogenic agent The same opinion has since been expressed by Dyke and others Evans concluded that arteriosclerosis is not uncommon in children and is essentially identical with the process in adults, as is confirmed by (1) the nature of the lesion in the arterial wall, (2) its distribution in the vascular tree, (3) its incidence in the various organs and (4) its association with increased blood pressure and left ventricular hypertrophy

During this period, experimental work followed many paths Bailey produced extensive degeneration of the aorta and large vessels, as well as pronounced renal changes by injecting large doses of diphtheria toxin Schmidtman produced a rise in blood pressure accompanied by arterial changes in animals by feeding pulverized liver Anitschkow and others fed animals high cholesterol diets and found fatty deposition in the deep layer of the intima Newbergh and Clarkson found that a high protein diet would produce atherosclerosis in rabbits even when the cholesterol content was low Alter used high protein diets and virulent bacterial capsules, obtaining intimal lesions in twenty weeks Nuzum and his co-workers thought the acid-base equilibrium in the body was an important etiologic factor in their experiments Ophuls (1921a), however, believed that none of these experimental lesions exactly duplicated human arteriosclerosis

During the last ten years, several more reviews have been published, covering the subject of arteriosclerosis (Evans, 1923, MacCallum, Oertel, Aschoff, 1924, Clifford, Allbutt, 1925, Klotz, 1926) MacCallum remarked, in 1922, that "we are quite as ignorant of the underlying cause of arteriosclerosis as were our forefathers in the days of Morgagni" He also said, "Arteriosclerosis may be found in a highly

developed form in children" As factors in arteriosclerosis, Klotz mentioned diseases of childhood and adolescence, chronic intoxications, minor infections, overwork and fatigue, bacterial infections and certain exogenous poisons

In 1927, Fishberg studied the arteriolar lesions in glomerulonephritis He thought the probable sequence of events was Chronic glomerulonephritis caused endarteritic obliteration in the vessels to the diseased glomerular tufts, followed by hypertension and generalized arteriolar lesions, which in turn caused widespread destruction of glomeruli, uremia and death

Moschowitz and Cheney studied arteriosclerosis in the pulmonary circuit, but said little of its occurrence in childhood The former mentioned congenital lesions of the heart as a possible factor in etiology

In 1927, Moulonguet and Pavie differentiated "presenile arteriosclerosis" from syphilis, the former being a degenerative lesion, noninflammatory, with characteristic changes in the limiting elastica According to Jeans and Cooke, syphilis is an uncommon factor in the causation of cardiovascular disease in children Syphilitic lesions of the heart and large vessels are so rare, according to these authors, as to be pathologic curiosities, but lesions of smaller vessels are somewhat more common, especially in the central nervous system

Joslin has written several articles in recent years on the association of diabetes and arteriosclerosis In 1927, he reported arteriosclerosis in 20 per cent of patients between 10 and 19 years of age in whom diabetes developed In 1929, he wrote, "The presence of arteriosclerosis was demonstrated by the roentgen ray in five of 29 diabetic children The duration of the latter disease was five or more years"

During 1927, the association of arteriosclerosis with renal infantilism was discussed by Hunt He reviewed fifty-four cases of the latter disease and reported arteriosclerosis in 10 per cent of cases that had come to autopsy The sclerosis was limited to the larger vessels He concluded, "In general, the vascular changes are much less pronounced than those found in adults with a similar degree of renal involvement"

In 1930, following the report of a case (table 1), Murphy remarked, "The development of a profound arteriosclerosis in these young patients who have diseases characterized by hypercholesteremia leads one to suspect that a high fat diet, one rich in cholesterol fat, may be more injurious than is commonly supposed"

Table 1 consists of ninety-eight cases of juvenile arteriosclerosis collected from the literature An attempt was made to include all cases in persons under 20 years of age having the type of lesions described in the definition of arteriosclerosis given In each case, the author's

TABLE 1.—*Summary of Data on Arteriosclerosis in Young Persons in Cases Reviewed*

Patient, Age Sex	Family and Personal History	Final Status	Blood Pressure	Observations in Heart	Blood Vessels	Kidneys	Other Observations	Source of Data
1 5 yr I					Calcified temporal artery			Cited by Fremont Smith *
2 9 yr M					Atheroma of aorta			Cited by Seitz (1896) *
3 8 yr I					Calcified plaques in aorta			Andral (1829) *
4 10 yr I	Shortness of breath for 5 yr, no other illnesses	Extreme dyspnea, pallor, cyanosis			Aneurysm of aorta			Roger
5 9 yr I				Hypertrophy of left ventricle	Thickening of adventitia of arterioles of pia mater and kidneys	Small, granular 2 and 1½ oz (56.4 and 42.4 Gm.)	Small, tough spleen	Gull and Sutton *
6 6 yr I	Grandmother had chronic arthritis, patient had no childhood diseases, but always weak and delicate, treated for enuresis when 2 yr old, convulsion 1 yr before	Frequent headaches and earaches, albuminuria, recurrent convulsions		Hypertrophy of left ventricle	Renal arteriosclerosis	Small, granular	Pulmonary emphysema	Barlow *
7 2 yr M		Loud murmur over base of heart transmitted over thorax, exaggerated impulse, convulsions, smallpox		Marked hypertrophy, chronic pericarditis, aortic stenosis and insufficiency	Yellowish white plaques, 2.5 mm. in diameter, in aorta			Moutard Martin *
8 Still born I				Dilatation of left ventricle	Aneurysm of aorta, 10 by 11 cm., arising below renal arteries and filled with blood clot, wall of sac contained coats of aorta with hyperplastic intima, fatty infiltration of muscle cells and mild inflammatory hyperplasia			Phanomenow *
9 12 yr I	Scarlatina	Headache, coma		Enormous hypertrophy of left ventricle	Stiff cerebral arteries, marked thickening of muscular and fibrous coats	Chronic nephritis	Large hemorrhage in posterior lobe of left cerebral hemisphere	Dickinson *

10 14 yr M	Renal stone at 3 yr	"Wizened face and parchment complexion," headache diminished vision, vomiting, polyuria, polydipsia albuminuria, convulsions	Weight of heart 8 oz (0 2 Kg), left ventricle 1 in (2 5 cm) thick, mitral valve atheromatous	Atheroma of descending aorta and of coronary and cerebral vessels	Granular degeneration	Marked anemia of brain, ulcerative enteritis and peritonitis	Dickinson *
11 11 yr M	Scarlatina 3 yr before	Sick since scarlet fever 3 yr before, headache, vomiting, drowsiness, edema, polyuria, diminished vision, pallor, wasting, epistaxis	Hypertrophy of left ventricle	Thickening of renal arteries	Granular with many petechial hemorrhages	Albuminuric retinitis with detached retina	Dickinson *
12 6 yr F	Repeated colds	Dropsy for 2 yr, albuminuria with blood and fat in urine	Hypertrophy of left ventricle, few atheromatous spots on mitral and aortic valves	Thickening of renal arteries	"Mottled tubal nephritis"		Dickinson *
13 13 yr F		Uremia	Hypertrophy of left ventricle, weight of heart 9 oz (0 28 Kg)	Thickening of pial arteries	"Tubal nephritis"		Dickinson *
14 10 yr F		Renal dropsy for 3 mo	Hypertrophy of left ventricle	Hypertrophy of muscle of cerebral arteries	"Tubal nephritis"		Dickinson *
15 7 yr M		Sick 10 wk	Marked hypertrophy of left ventricle	Marked fatty degeneration of pial arteries	"Tubal nephritis"		Dickinson *
16 7 yr M		Severe scarlatinal dropsy, general edema, smoky urine, pneumonia	Hypertrophy of left ventricle	Hyaline thickening of pial arteries	Scarlatinal nephritis		Dickinson *
17 12 yr M	Weakly from birth	Palpitation, polyuria, apoplexy with left hemiplegia 1 yr before, with headache, vomiting, loss of vision, oliguria, edema, nosebleeds, coma	Hypertrophy of left ventricle	Chronic endarteritis with medial hypertrophy of vessels of brain stem, aorta and brachials, arteriosclerosis (of Gull and Sutton)	Granular atrophy	Hemorrhage of brain, albuminuric retinitis	Filatoff *
18 5½ yr M	Tuberculous peritonitis of long duration	Ascites pallor, emaciation, diarrhea		Fibrosis of splenic vessels	Interstitial nephritis	Atrophic cirrhosis of liver, spleen, kidney, tuberculous peritonitis (?) fibrous pleurisy, hypostatic pneumonia	Morell Lavelce *
19 12 yr M	Scarlet fever and dropsy at 8 yr, rheumatism later	Dyspnea for 2 yr, headache, vomiting, drowsiness, fits, coma	Mitral insufficiency	Aneurysm of midcerebral artery, wall of vessel atheromatous and brittle		Hemorrhage into subarachnoid space and ventricles, adherent pericarditis, vegetative mitral endocarditis	Keating (1887) *

* Author indicates that a postmortem examination was obtained in this case

TABLE 1.—*Summary of Data on Arteriosclerosis in Young Persons in Cases Reviewed—Continued*

Patient Age, Sex	Family and Personal History	Final Status	Blood Pressure	Observations in Heart	Blood Vessels	Kidneys	Other Observations	Source of Data
20 13 yr F		Sick 6 mo., dyspnea, epistaxis, cyanosis		Marked hypertrophy of left ventricle, atheromatous deposits on aortic valve with aortic stenosis and insufficiency	Atheromatous aorta with dilatation of arch and small pouched aneurysm, the orifice of which was calcified			Sanne *
21 13 yr F	Father syphilitic, patient had scarlet fever and psoriasis	Shortness of breath for 2 yr., pain in back, albuminuria, cyanosis, enlarged liver		"Colossal" heart, hypertrophy of left ventricle, grayish white flecks in endocardium, normal valves	Narrowing of aorta for almost entire extent, inflammatory changes and thrombosis in abdominal portion, also narrowing of hypogastric, innominate, carotid and pulmonary arteries		Amyloid in spleen and lungs (no evidence of syphilis)	Wallis *
22 8 yr M	Improper feeding and excessive alcohol, family alcoholics	Sick 1 day (?), headache, dizziness, colic, convulsions coma, cyanosis, diarrhea		Hypertrophy of left ventricle (2 cm.), "mother of pearl" spots on endocardium, also ecchymoses, early myocardial fibrosis	Atheromatous plaques and streaks in ascending aorta, renal arteriosclerosis, and arteriolosclerosis, coronary periarteritis and sclerosis	Albumin in urine 4 plus (post mortem)	Subpleural hemorrhage, acute emphysema	Girode *
23 15 yr M	Mother neuropathic, patient had enlarged glands in neck and conjunctivitis, assisted alcohol vendor for 3 yr., and drank per day ⅔ glasses absinthe, 3 glasses whiskey, ⅔ liters wine and several glasses liqueur	Chronic alcoholism, loss of appetite, thirst, violent gastric pain, tremor, nightmares, repeated loss of consciousness, loss of breath on exertion, frequent epistaxis		Enlargement, accentuation of A2 and roughness at base	Hard cylindric cordlike radials, distinctly felt ulnars large, sinuous, hard temporals		Extremities cold and blue	Girode *
24 5 mo F	Deserted when 2-3 wk. old	Emaciation, marasmus "looked like old dried up woman"			Irregular thickening of coronary artery, involving the lining of the vessel with some extension to media			Meigs *
25 ? M		Partial left hemiplegia, mental involvement, uniocular diplopia 2 yr. before, abscess in neck			Thickening of cerebral arteries, with small aneurysm which had ruptured		Large clot, right hemisphere with organization	Councilman *

26 4 yr M		Polyuria, headaches, decrease in weight, nausea, vomiting, diarrhea, thirst diminished vision, uremia		Thickening of renal arteries, especially of adventitia	Granular atrophy	Pulmonary congestion	Greene *
27 11 yr F	Measles at 6 yr, 2 attacks of influenza, no history of syphilis	Acute nephritis 3 wk, uremia (?)	Slight hypertrophy and dilatation of left ventricle, plaques in endocardium (like those in artery)	Involvement of all arteries of body, raised gray, translucent spots and patches, narrowed lumen especially in aorta, which hardly admits bullet probe at bifurcation	No scarring	No gummas, chronic perisplenitis, chronic perihepatitis, pneumonia, renal and pulmonary infarcts, hemorrhage into cerebellum	Hawkins *
28 14 yr M	Chilblains of feet in winter	"Shingles," chest and back, prickly sensations left arm		Absence of radial pulse on left, cordlike radials and brachials		Slight cyanosis of fingers	Bond
29 12 yr M		Uremia		Sclerosis of aortic arch, innominate artery and carotids	Contracted		Simnitzky *
30 13 yr F	Mother died at 36 yr of phthisis, father living, aged 38, has catarrh and arteriosclerosis, patient's history showed measles, whooping cough and diphtheria, without nephritis	Following diphtheria, less than 1 yr before, palpitation and dyspnea developed, followed for 5 mo during which no change except occasional albuminuria	Enlargment, loud ringing, A2	Rigid radials and crurals, with decreased elasticity	Occasional albuminuria		Seitz (1896)
31 14 yr M	Father living, aged 44, has heart trouble, mother and sibs healthy, patient, measles, rheumatism in arms and legs	Palpitation and dyspnea on exertion, systolic murmur at apex	Enlargement to right, systolic murmur at apex, accentuation of A2	Rigid radials, also crurals and tibials, with decreased elasticity	No albumin		Seitz (1896)
32 12 yr M	Father died at 45 yr, had heart trouble, mother died at 39 yr, with marked arteriosclerosis, five healthy sibs, patient, severe scarlet fever and pneumonia at 5 yr	Dyspnea on exertion since scarlet fever, also headaches and dizziness	Slight enlargement to left, ringing, clear A2	Very hard radials, visible pulsation in carotids and temporals, decreased elasticity	Slight albuminuria		Seitz (1896)
33 9 yr M	Repeated rheumatism	Heart trouble	Slight enlargement, hypertrophy of left ventricle, slight thickening of mitral valve, thickening of aortic valve with vegetations	Two patches of atheroma with outward bulging in aortic arch, small aneurysm in abdominal aorta at bifurcation, probably embolic in origin			Aitken *

* Author indicates that a postmortem examination was obtained in this case

TABLE 1.—*Summary of Data on Arteriosclerosis in Young Persons in Cases Reviewed—Continued*

Patient Age, Sex	Family and Personal History	Final Status	Blood Pressure	Observations in Heart	Blood Vessels	Kidneys	Other Observations	Source of Data
34 13 yr M		Abdominal typhus		Heart pale and flabby, congenital anomaly in right atrium (reticulum), no hypertrophy, atheroma of aortic valve	Arteriosclerosis in ascending aorta, slight changes in all parts of aorta, yellowish white streaks and plaques with thickened intima		Typhoid fever, suppurating bronchitis, lobular pneumonia	Chiari *
35 11 yr M	Measles and whooping cough	Bright's disease, vomiting, cough, pain in side, loss of weight, diarrhea with blood, edema of legs, albuminuria		Apex in 6th interspace, hypertrophy of left ventricle	Early atheroma at root of aorta	Weight 3 oz (84 9 Gm) together, granular, firm	Ascites bronchitis	Russel *
36 14 yr F	3 sibs have chronic nephritis, patient weak, undersized, had gastroenteritis at 6 mo	Shortness of breath on exertion, paralysis of left side following fright, with fever and hemoptysis		Marked enlargement of left ventricle, systolic murmur at apex and in the aortic area, accentuation and reduplication of A2, fibrinous pericarditis, moderate atheroma of aortic valve, slight thickening of mitral valve	Generalized chronic arteritis, patches of atheroma in aorta, especially around coronary orifices, marked atheroma of coronary artery with calcification	Chronic nephritis	Staph albus septicemia, pulmonary edema, hemorrhage in lungs, spleen and mesentery, pneumonia, congestion of liver with calcification, acute splenitis, gastroenteritis	Brill *
37 2 wk ?	7 mo gestation, poorly nourished	Generalized edema		No abnormality	Atheromatous plaques in pulmonary artery, as in a senile aorta, and brittle, calcified walls, rigid aorta with no gross lesions, microscopically, typical atheromatous plaques with calcification, more marked in pulmonary artery, with calcification		Fibrinous peritonitis	Durante *
38 7 yr F	Weak infant, diarrhea, measles	Frontal headaches for 2 mo , vomiting, development of hemiparesis, convulsions, uremia		Enlargement of heart, hypertrophy of left ventricle	Palpable brachials, arteriosclerosis, renal arteriolosclerosis	Albuminuria, diffuse interstitial nephritis	Cerebral hemorrhage	Greene *
39 10 yr M	No evidence of syphilis, mother and father and 5 sibs living and well, patient—measles at 7 yr , chorea for 2 yr , nocturnal enuresis, thirst	Headache 1 wk , convulsions and vomiting, glandular swelling in right side of neck, bleeding into mouth stomatitis ulcerosa albuminuria, repeated epistaxis development of systolic murmur at apex with signs of decompensation, constipation		Weight 8½ oz (0 21 Kg), granular patches in endocardium and at bases of great vessels, hypertrophy of left ventricle	Sclerosis of all vessels in the body, except cerebrals, all coats involved, general and coronary circuits (pulmonary ?) included	Chronic nephritis with acute nephritis	Edema of ankles	Baines *

40 6 mo M	Breast fed only 2 mo, no childhood diseases, no syphilis in history, but first child was stillborn	Loss of weight weakness, constipation, development of diarrhea and vomiting, right foot became cold, then gangrenous		Slight hypertrophy of right ventricle, normal left ventricle, endocardium of left auricle hard, nodular, gritty, also that of left ventricle	Thick, cordlike femoral artery, normal cerebral artery, thick, rigid, nodular thyroid artery, tortuous, hard, thick coronaries, few atheromatous patches in pulmonary artery, sclerosis and grittiness of 1st part of aorta and bifurcation, rest not remarkable, sclerotic, obliterated iliac artery, sclerosis of femorals and branches, brachials, mesenteric, hepatics thyroidal, renal splenic, etc	Extreme phimosis with marked dilatation of urinary tract and renal atrophy	No sign of congenital syphilis, gangrene of toes, caseous bronchial glands	Bryant and White *
41 7 yr M	Weakly since birth	Patient underdeveloped, anemic, with diminished vision, polyuria, nocturia, headaches, edema		Hypertrophy	Marked thickening of blood vessels in kidneys	Advanced interstitial nephritis	Albuminuric retinitis	Greene *
42 17 yr M	No evidence of syphilis, has had measles, tuberculosis	Patient not well enough to go to school for past 2 yr	120	Slight hypertrophy	Thickening of radials and crurals	Normal	Apical tuberculous thickening (x ray) with calcification of hilic lymph node, slight edema of extremities, congested liver	Hofbauer
43 8 yr M		Scarlet fever		Slight enlargement, pale muscles plaques on mitral valve	"Chronic deforming endarteritis of the aorta" whitish yellow plaques in intima of aorta, microscopically, thick intima with fatty cells in deep intima, also intercellular fat droplets, increase in connective tissue		Obsolete apical and bronchial lymph node tuberculosis	Simnitzky *
44 12 yr M	Inflammation of lung, trauma of leg	Suppurative osteomyelitis of femur, hemorrhagic infarcts in the lungs, seropurulent pleuritis, pyemia		Normal	Hard, raised plaques in aorta			Simnitzky *
45 17 yr F	No history of previous illness	Cerebrospinal meningitis, fibrinopurulent rhinitis, suppurative bronchopneumonia		Normal size, anemic	Disseminated yellowish white small patches in aorta	Chronic Bright's disease	Hydrocephalus, pulmonary edema	Simnitzky *
46 17 yr M	No history of previous illness	Incarcerated herniotomy lobular pneumonia, scoliosis		Normal	Hard yellow streaks in aortic intima			Simnitzky *

* Author indicates that a postmortem examination was obtained in this case

TABLE 1—*Summary of Data on Arteriosclerosis in Young Persons in Cases Reviewed—Continued*

Patient Age, Sex	Family and Personal History	Final Status	Blood Pressure	Observations in Heart	Blood Vessels	Kidneys	Other Observations	Source of Data
47 5 yr M	Healthy	Pneumonia vegetative endocarditis		Globular vegetations in right auricle (thrombosis)	Few hard white streaks in sinus of Valsalva and aorta			Simnitzky *
48 4 yr M	Scarlet fever one month ago	Scarlatinal nephritis		Hypertrophy thickening of mitral valve	Sparse grayish yellow patches and streaks	Nephritis following scarlet fever		Simnitzky *
49 10 yr M	Healthy	Typhoid fever		Normal	Fine streaks in aorta		Enlarged spleen, peptic ulcer	Simnitzky *
50 12 yr M	Scarlet fever 2 yr ago	Mitral and aortic insufficiency chronic endocarditis		Hypertrophy of left ventricle chronic endocarditis of mitral and aortic valves	Yellowish white plaques in ascending aorta, arch and abdominal portion		Congestion and edema	Simnitzky *
51 19 yr M	Tuberculosis for 15 yr, typhoid fever	Pulmonary tuberculosis with tuberculous enteritis		Streaking of aortic valve	Numerous longitudinal elevations of intima of aorta		Tuberculosis	Simnitzky *
52 16 yr M	Epilepsy	Epilepsy, pneumonia		Patches on aortic valve	Sparse elevated patches and streaks in intima of aorta			Simnitzky *
53 2½ yr F	Pertussis 1 mo before	Suppurative broncho pneumonia		Enlarged, pale flecks on aortic valve	White, thickened flecks in intima of aorta		Edema of brain	Simnitzky *
54 14 yr F	Epilepsy	Epilepsy, arrested tuberculosis of left node		Normal	Hard patches of thickening in intima of ascending aorta			Simnitzky *
55 18 yr M	Articular rheumatism 6 yr before, alcoholism	Heart disease		Chronic endocarditis of mitral and aortic valves with insufficiency and stenosis, thick pericardium, dilatation, hypertrophy	Numerous small grayish white patches and streaks in intima of aorta and large vessels		Congestion and edema	Simnitzky *
56 9 yr F	Scarlet fever, tuberculosis	Tuberculosis		Normal	Hard raised patches in aorta		Lymph node tuberculosis	Simnitzky *
57 18 yr ?	Healthy	Abdominal typhoid, lobular pneumonia		Normal	Sparse patches and streaks in ascending aorta and arch			Simnitzky *

58 2 yr M	Laryngeal diphtheria	Lobular pneumonia	Yellow plaques on aortic valve	Several small yellow plaques in aorta			Simnitzky *
59 17 yr F	Tuberculosis	Tuberculosis	Normal	Raised yellowish white flecks in entire aorta and branches		Tuberculous laryngitis tracheitis and lymph node tuberculosis	Simnitzky *
60 10 yr F	Articular rheumatism 1 yr before		Chronic endocarditis of mitral valve, cardiac hypertrophy	Numerous small patches and streaks in aorta and large branches	Chronic Bright's disease	Arrested pulmonary tuberculosis	Simnitzky *
61 10 yr M	Diphtheria 3 yr before followed by otitis media	Sinus thrombosis following otitis media with operation, suppurative meningitis	Normal	Small disseminated yellowish white streaks and elevations in aorta and large branches		Pulmonary abscesses, seropurulent pleuritis, pyemia tuberculosis of bronchial lymph nodes	Simnitzky *
62 14 yr M	Measles 6 yr before	Suppurative periostitis and arthritis	Slight enlargement	Elevations around orifices and bifurcation of aorta and large branches		Pulmonary abscesses and pyemia	Simnitzky *
63 13 yr F	Scrofula	Chronic tuberculosis of lymph nodes, amyloidosis, anasarca, vegetative endocarditis	Hypertrophy of left side, globular vegetations in both ventricles	Raised patches and streaks in intima (aorta?)	Chronic Bright's disease	Amyloidosis, anemic infarcts in spleens	Simnitzky *
64 13 yr F	Scarlet fever 8 yr before	Abdominal typhoid fever, lobular pneumonia		Small grayish white patches in intima of aorta and large branches		Decubitus	Simnitzky *
65 17 yr M	Measles 8 yr before	Posthemiotomy peritonitis	Slight enlargement, pale muscle, few plaques on valves	Few plaques and streaks in intima of arch of aorta			Simnitzky
66 15 yr M	Measles at 6 yr, chickenpox at 8 yr, polyuria for 1 yr, recent headaches	Hemorrhage from gums following extraction, weakness, dyspnea, slight edema of ankles	Left ventricle 20 mm, right ventricle 9 mm, soft systolic murmur at apex, accentuation of A2, weight of heart, 300 Gm	Decidedly atheromatous aorta with several calcified plaques in descending portion, spots of fatty degeneration in entire extent, fibrosis of renal vessels	Left, 68 Gm, right, 80 Gm, advanced stage of contracted kidney	Bilateral hydrothorax, congestion of lungs	Hirsch *
67 18 yr F	Cancer of breast on mother's side, measles, pertussis, diphtheria, always weak, menstruated at 10 yr, fall at 14 yr and in bed 1 yr, kidney trouble for 2 yr	Development of about 14 yr anemia, signs of nephritis, development of anasarca, patient died in coma	Left ventricle 15 mm, right ventricle 7 mm, accentuation of A2	Abnormally small aorta, no atheroma in aorta marked thickening of renal artery	Chronic nephritis	Pulmonary congestion, old tuberculous lesion of spine with calcification	Hirsch *
68 11 yr M	Scarlet fever, no other illness, no history of syphilis	Advanced arteriosclerosis		Far advanced widely distributed generalized arteriosclerosis	Chronic nephritis		Anderson *

* Author indicates that a postmortem examination was obtained in this case

TABLE 1.—*Summary of Data on Arteriosclerosis in Young Persons in Cases Reviewed—Continued*

Patient Age, Sex	Family and Personal History	Final Status	Blood Pressure	Observations in Heart	Blood Vessels	Kidneys	Other Observations	Source of Data
69 9 yr F	Healthy	Headache, exhaustion pain in cardiac region, dyspnea, patient died suddenly		Pericardium filled with blood clot	Infiltration of aortic sheaths with blood dissecting aneurysm in intima with media, sclerosis only in two thickened areas, not at site of aneurysm, with microscopic evidence of proliferation of intima			Oppenheimer *
70 10 yr M		Patient died following resection of tuberculous joint			Arteriosclerotic plaques in first portion of aorta			Oppenheimer *
71 4 yr M	Father had gonorrhea before marriage, and syphilis (?), has been epileptic since age of 21, patient's birth weight 12 lb (5.4 Kg), required artificial respiration at birth severe bronchitis at 6 wk followed by whooping cough, fainting spell at 2 yr	Systolic murmur since whooping cough, febrile attack like malaria but no improvement with quinine, increasing anemia, loss of weight edema, sudden death		Blood filled pericardiac sac, small, pale heart, aortic stenosis	Diminished radial pulse, aneurysm of arch and ascending aorta, ruptured into pericardial sac, extensive layers and patches of atheroma in aorta, very thick wall	Fatty deposits	Generalized glandular enlargement, large, hard liver and spleen, submucosal hemorrhage in stomach	Willson and Marcy *
72 11 yr F	Measles at 2 yr, headache and weakness 2 yr before, with polydipsia, cystitis (?) enuresis	Enuresis, cystitis (?), dyspnea, headache, severe nosebleed, death	160	Aortic insufficiency, hypertrophy of left ventricle	Rigid radials and carotids, yellow marks in aorta and carotids generalized (?) arteriosclerosis	Right, 120 Gm, with parenchymatous nephritis, left, 15 Gm., contracted	Hemorrhage in left cerebral hemisphere and into ventricles of brain, follicular cystitis, adherent pleuritis	Rich *
73 13 yr M		Patient somewhat small for age, had shortness of breath	120/75		Rigidity of radials and other vessels (a constricted, diffuse rigidity)			Bahrdt
74 12 yr M	Father, obliterating endarteritis with gangrene, also syphilis	Pinched, haggard, looked like "old man"		Normal	Diffuse sclerosis of all palpable arteries with calcification and beading	Normal	Mentally bright	Tremont Smith
75 6½ yr F	Small baby, retarded growth and development and polyuria since birth	Development of child of 3 yr, edema of face and legs		Great enlargement, petechial hemorrhages left ventricle ¼ to ⅜ in (0.6 to 0.96 cm) fibrosis of myocardium	Markedly thickened renal vessels, lumina narrowed, granular	Less than 1 oz (28.3 Gm) together	Bronchopneumonia	Miller and Parsons *

76 15 yr I	Rheumatism on mother's side several attacks of loss of speech and paralysis of legs lasting about 15 min, bronchitis 2 yr before	Cough, orthopnea on exertion and on exposure to cold, child small for age		Enlargement	Subclavian pulsations, sclerosis of brachials and radials, no pulsation in these	Trace of albumin	Congested fingertips, negative Wassermann reaction	Chapman
77 16 yr M	Rheumatism, no history of syphilis	Patient dropped dead on street		Myocarditis, vegetation on aortic valve obstructing coronary orifice when valves were closed obliterative pericarditis	Near occlusion of coronary arteries by sclerosis			*
78 15½ yr M	Mother sick and overworked during pregnancy, no syphilis, polyuria for years	Stunted growth		Slight hypertrophy of left ventricle	Obvious arteriolosclerosis in the kidneys, no abnormality of aorta and arteries	Interstitial nephritis		Barber *
79 13 yr F	Lobar pneumonia several times in infancy	Postoperative intussusception, gangrenous appendix, patient died 6th day after operation			Renal arteriolosclerosis with chronic periarteritis only in right kidney	Right, 9 6 Gm, slight acute nephritis increased interstitial tissue, degeneration, left, 56 Gm	Early generalized peritonitis	Simpson *
80 10 yr ?	Chronic nephritis for 5 yr	Chronic nephritis		Slight enlargement, grayish white flecks on right side of heart	Yellow atheromatous changes in ascending arch and thoracic aorta with thick intima, also in carotids and innominate arteries, absent in other vessels	Chronic parenchymatous nephritis (no vascular changes)		Hattori *
81 10 yr F	Aunt an idiot, mother died in childbirth, had chronic nephritis, sister dead at 2½ yr of renal disease, chronic nephritis diagnosed in patient at 1¼ yr, retarded development	Idiocy, polyuria, albuminuria, patient died of diphtheria, with evidence of impending uremia	100	Enlargement, hypertrophy of left ventricle, two white plaques on mitral valve	Palpable arteries, renal arteriosclerosis and arteriolosclerosis	Chronic nephritis	Albuminuric retinitis	Glaser *
82 1¾ yr M		Renal dwarf with multiple fractures			Great thickening of arteries	Fibrosis	General osteoporosis	Patterson *
83 14 yr F	Weak and backward from infancy, severe headaches for years, measles in infancy, scarlet fever 2 yr before, healthy family	Development of a child of from 5 to 6 yr	240 190	Moderate hypertrophy of left ventricle, accentuation of A2	Small and wiry radial arteries, sclerosis of retinal vessels	Approaching uremia	Slight genu valgum, albuminuric retinitis, Wassermann reaction negative	Fletcher

* Author indicates that a postmortem examination was obtained in this case

TABLE 1—*Summary of Data on Arteriosclerosis in Young Persons in Cases Reviewed—Continued*

Patient, Age, Sex	Family and Personal History	Final Status	Blood Pressure	Observations in Heart	Blood Vessels	Kidneys	Other Observations	Source of Data
84 12 yr M	Measles and scarlet fever at 3 yr, hematuria at 9 yr, enteritis 4 mo before, frequent colds	Uremia, pulmonary edema	140/110	Moderate hypertrophy and dilatation of left ventricle	Slight arteriosclerosis	Late subacute nephritis (large kidneys mottled with hemorrhage)	Chronic suppurative tonsilitis	Ophuls *
85 14 yr F	Weak since birth, scarlet fever 2 yr before	Frontal headaches, enuresis, uremia (?), pain and deafness in right ear, coma, death	250/170	Hypertrophy	Sclerosis of peripheral vessels, retinal sclerosis with hemorrhage, marked sclerosis of aorta and large vessels of brain stem, obliterative endarteritis of renal arteries	Advanced chronic nephritis	Negative Wassermann reaction, renal dwarf, hypertrophy of suprarenal glands	Evans (1922) *
86 14 yr M	Epilepsy 7 yr before, following operation, mother had 4 miscarriages and 4 living children, measles at 4 yr, bronchopneumonia at 5 yr, tuberculous adenitis at 8 yr, bronchitis annually	Defective vision, cerebral hemorrhage	195/170; 260/200	Hypertrophy	Sclerosis of peripheral vessels, dilated aorta arteriosclerosis with calcified plaques arteriosclerosis in kidneys	Chronic nephritis with tubular degeneration	Rickets, negative Wassermann reaction albuminuric retinitis, cerebral hemorrhage	Evans (1922) *
87 14 yr F	Scarlet fever 10 mo before admission	Defective vision, headache, vomiting (1 wk), uremia, stomatitis and terminal pericarditis	165/123	Hypertrophy of left ventricle thickening of aortic and mitral valves	Thickening of renal arteries, other vessels not sclerotic	Extreme chronic nephritis	Albuminuric retinitis, pericarditis, hypertrophied suprarenal glands	Evans (1922) *
88 11 yr M	Well until 2 wk before	Septic sore on finger development of uremia	190/120	Hypertrophy of left ventricle	Intimal atheroma of aorta, marked fatty changes in renal vessels with sclerosis of larger ones	Granular scarred kidneys with punctate hemorrhages		Dyke *
89 4 yr F	Mother had 4 miscarriages, difficult feeding 1st yr, frequent bronchitis, no other infectious disease	Drowsiness and vomiting following an eruption called "measles," development of crossed eyes, convulsion of left side, coma		Hypertrophy of left ventricle, atheromatous patches on mitral valve, thickening of aortic valve	Definite atherosclerosis in sinuses of Valsalva and ascending aorta	Chronic nephritis in scarred, granular shrunken kidneys	Rickets	Greene *
90 10 yr F	Always delicate, scarlet fever at 2 yr, headaches since 6 yr, treated for fits at 8 yr, large healthy family	Nephritis, dyspnea, coma convulsions	240	Marked hypertrophy of left ventricle primary sclerosis of aortic cusps	Small, wiry pulse, carotid pulsations tortuous retinal arteries with few hemorrhages, arteriosclerosis of aorta and coronary arteries, marked atheroma of abdominal aorta renal arteriosclerosis (arteriolar)	Arteriosclerotic scars	Emaciation, purpuric spots on abdomen negative Wassermann reaction obliterative pleuritis acute bronchitis multiple small hemorrhages	Henderson *

91 3½ yr M	Father's and mother's Wassermann reactions positive but after birth of patient, patient had had measles parotitis, diphtheria, scarlet fever and tonsillectomy	Epigastric pain after meals marked constipation, polydipsia, polyphagia polyuria, enuresis, clotted blood in stools death from hemorrhage	250 — 195		Plainly visible temporal arteries, pipe stem radials, narrow, cork screw retinal arteries, with fresh and old hemorrhages and degeneration	1 200 cc of urine in 24 hr heavy trace of albumin few red and white blood cells	Old skin wrinkled brown dry, liver 2 fingerbreadths below costal margin, negative Wassermann reaction (blood and spinal fluid), albuminuric retinitis	Schwartz
92 11½ yr F	Measles and pertussis at 3½ yr	Polyuria, marked emaciation acute intussusception and gangrene of ileum	240 — 180	Apex in 6th interspace, weight of heart 240 Gm enormous left ventricle, probable arteriosclerosis of mitral valve, atheroma of aortic valve	Atheroma of aorta and iliac artery (nodular) uniform thickening of systemic vessels renal and splenic arteriolosclerosis	Congenital hyperplasia, subacute nephritis	Edema of lung with petechial hemorrhages, chronic passive congestion of liver and spleen	Schwartz *
93 2 dy F	Normal delivery				Circumscribed thickening of intima in axillary artery (fatty degeneration)		Cause of death unknown	Hesse *
94 17 yr M			184 — 122	Weight of heart, 550 Gm	Arteriolosclerosis of kidney, spleen, pancreas, liver, lung	Diffuse glomerular fibrosis		Branch *
95 6 mo ?				Large septal defects	Isolated sclerosis of pulmonary artery (transposition of large vessels), lipoid degeneration most marked in smaller branches		Negative Wassermann reaction	Watjen *
96 7½ yr F	Father's Wassermann reaction positive, fracture of femur at 2¾ yr	Genu valgum lordosis, tetany, cardiac decompensation albuminuria, death, patient a renal dwarf	140 — 80	Dilatation, adherent aortic cusps, atheroma of endocardium	Atheroma of aorta	Chronic nephritis (contracted) kidney	Rickets marked by beading, bosselation caries, stunted growth dry skin, large fibrous spleen, fatty liver	Karsner *
97 4 yr F		Convulsions alternating with semistupor, sexual precocity, death following exploratory laparotomy	160 — 100		Vascular sclerosis in pia		Small thymus and thyroid gland tumor nodules in lung, malignant hypernephroma, focal encephalomalacia	Dieterle *
98 16 yr M	Tonsillitis and tonsillectomy at 7 yr, cervical adenitis at 13 yr, mastoiditis at 14 yr, pneumonia at 15 yr, epidemic meningitis at 15 yr	Patient followed for 4 yr, chronic nephritis with lipoid changes, hypercholesterolemia, convulsive uremia	160 — 110 250 — 130	Atheroma plaques on mitral valve	Atherosclerosis of aorta with thickening of vasa vasorum, renal arteriosclerosis and arteriolosclerosis	Chronic glomerular nephritis, lipoid degeneration	Albuminuric retinitis, anemia	Murphy *

* Author indicates that a postmortem examination was obtained in this case

description of the lesion, when given, rather than his diagnosis, was taken as the criterion for including the case There were several reasons for this procedure In the early literature, lesions of syphilis and atherosclerosis were not clearly differentiated, and many lesions were described as lipoid degeneration in the intima, even with calcification, and then were called "syphilis" A few cases are included in which a history of parental syphilis was found, but the patients' lesions, as described, were those of atherosclerosis rather than syphilitic aortitis On the other hand, many cases called "atherosclerosis" were rejected because the descriptions did not conform to the definition employed Many of these rejected cases have been listed in studies of juvenile arteriosclerosis by other authors, and have been so frequently quoted and misquoted that it was deemed advisable to include them in a supplementary bibliography at the end of this paper

Although an attempt was made to review all the literature on juvenile arteriosclerosis, it was found to be a well-nigh impossible task, since only a few cases are listed in the medical indexes under arteriosclerosis or even under vascular disease A careful search through many reports of cases of chronic nephritis revealed a high incidence of arteriosclerosis A similar review of certain other conditions might be just as fruitful

Therefore, since this review is of necessity incomplete, the time is not ripe for final conclusions A few comments, however, may be in order

TABLE 2—*Arteriosclerosis with Relation to Age*

Age of patients	Under 1 yr	1 4	5 9	10 14	15 19
Cases	6	10	19	45	17
Percentage	6	10	19 5	46	17 5

Age—Arteriosclerosis may occur at any age The patients here represented ranged from the newly born to those 20 years of age It is interesting to note that nearly half the total number of cases occurred during the age period of from 10 to 14 years, while a decidedly smaller number occurred in the succeeding age period of from 15 to 19 years However, it may be that fewer cases in persons of the latter ages gain entrance to the literature, since the disease in the prepubescent person is so much more striking than it is in a person approaching adult life

Sex—There were forty-one females and fifty-three males, a difference too small to be considered significant in this review

Family History—No one factor appeared with sufficient frequency to be of value In many cases, family history was not mentioned

Past History—Only seven patients were stated to have been healthy to the time of the final illness In one or the other of the remaining ninety-one was found almost every illness of childhood No one condi-

tion stood out prominently enough to signify etiologic value The infectious diseases were of most frequent occurrence, but such is also the case in children without arteriosclerosis

Blood Pressure—When recorded, it was high In most of these cases, however, chronic nephritis was present In cases without renal involvement, blood pressure was usually not mentioned

Heart—There was cardiac involvement in sixty-eight cases In twelve, the heart was stated to be normal and in eighteen it was not mentioned The most common departure form normal was hypertrophy of the left ventricle Atheroma or fibrosis of the endocardium was described in thirty-two cases Most of these were fairly definite atherosclerotic lesions, although a few may have been scars of previous bacterial endocarditis

Incidence of Vascular Lesions—The incidence of vascular lesions in the cases was as follows hypertrophy, 55, endocardial involvement, 32, normal heart, 11, heart not mentioned, 18, involvement of aorta and large branches, 59, of peripheral vessels, 25, and of visceral arterioles, 44

In a few of the cases, the peripheral vessels were the only ones mentioned, in those coming to autopsy, the visceral and peripheral vessels were often neglected

COMMENT

Perhaps more important than any conclusions to be drawn from this review are the unanswered questions that it has raised, a few of which are listed

1 What is the real incidence of arteriosclerotic lesions in children dying from any cause? This question can be answered only by a careful review of autopsy material, both gross and microscopic, from a large series of cases

2 Under what conditions, if any, do chronic renal lesions occur in children without lesions in the vascular system? What is the real incidence of renal lesions in juvenile arteriosclerosis?

3 Congenital malformations causing partial obstruction in some portion of the urinary tract are not rare In what proportion of these cases are vascular changes found? Or does the case of Bryant and White represent a coincidence?

4 Does congenital or acquired syphilis ever produce typical atherosclerotic lesions with calcification?

5 Are vascular lesions any more numerous in children with poor heritage, many childhood diseases and faulty environment than in those showing an absence of these factors?

6 Is there a real peak in the incidence of arteriosclerosis around the onset of puberty? If so, why?

7 Would careful studies of metabolism reveal retention phenomena that would help explain the apparent frequency of association between renal lesions and arteriosclerosis, also between diabetes and vascular lesions?

8 Does hypertension without renal changes ever occur in childhood?

BIBLIOGRAPHY

Aitken, R Y Brit M J **1** 1655, 1898

Allbutt, T C System of Medicine, New York, The Macmillan Company, 1899, vol 7, p 307, ibid, 1900, vol 6, p 307

Arteriosclerosis A Summary View, 1925, New York, The Macmillan Company, reviewed, Brit M J **2** 65, 1925

Alter, N M Colorado Med **22** 199, 1925

Anderson, H B Am Med **7** 426, 1904

Andral, G Precis d' anat **2** 350, 1829

Clinique medicale, 1836, trans by D Spillan

Andrews, C R New York M J **79** 1091, 1904

Anitschkow, N Beitr z path Anat u z allg Path **70** 265, 1922

Virchows Arch f path Anat **249** 73, 1924

Aschoff, L Beihefte z med Klin **4** 1, 1908

Munchen med Wchnschr **56** 2341, 1909

Lectures on Pathology, New York, Paul B Hoeber, 1924, p 131

Baginsky, A Lehrbuch der Kinderkrankheiten, Braunschweig, F Wreden, 1899, p 735

Bahrdt, H Berl klin Wchnschr **45** 1424, 1908

Bailey, C H J Exper Med **25** 109, 1917

Baines, Allen Tr Am Pediat Soc **13** 58, 1901

Ballantyne, J W Manual of Antenatal Pathology and Hygiene, The Foetus, Edinburgh, W Green and Son, 1902, pp 374 and 235

Barber, Hugh Brit M J **2** 1204, 1913

Lancet **1** 142, 1918, ibid **1** 18, 1920a

Quart J Med **14** 205, 1920b

Barlow, W H Lancet **2** 151, 1874

Basch Wien med Presse **34** 761, 1893

Beale, L S Brit M J **1** 33, 1873

Biedert, P Lehrbuch der Kinderkrankheiten Stuttgart, Ferdinand Enke, 1902, p 471

Billings, F S Arteriosclerosis Due to Lead, J A M A **43** 772 (Sept 17) 1904

Bond, B W Lancet **1** 150, 1895

Boveri, Piero Deutsche med Wchnschr **32** 877, 1906

Branch, Arnold J Clin Investigation **3** 299, 1926

Braun, Ludwig Munchen med Wchnschr **52** 533, 1905

Brill, N E J Exper Med **4** 541, 1899

Brooks, Harlow Am J M Sc **131** 778, 1906

Bryant, J H, and White Guy's Hosp Rep **55** 17, 1901

Buchta Wien klin Wchnschr **15** 926, 1902

Cabot, R C Relation of Alcohol to Arteriosclerosis, J A M A **43** 774 (Sept 17) 1904
Chapman, C W Proc Roy Soc Med **6** 109, 1912
Chiari Prag med Wchnschr **23** 9, 1898
Clarkson, S J Exper Med **43** 595, 1926
Clifford, Sir Thomas Arterio Sclerosis, New York, The Macmillan Company, 1925, p 157
Collins, Joseph New York M J **83** 1167, 1227 and 1282, 1906
Cooley, T B, and Lee, P Sickle Cell Anemia in a Greek Family, Am J Dis Child **38** 103 (July) 1929
Councilman, W T Tr A Am Phys **6** 179, 1891
Democh, Ida Arch f Kinderh **33** 284, 1902
De Mussey, Greeneau Arch de med **20** 128 and 292, 1872
Dickinson, W H A Treatise on Albuminuria, 1881
Dieterle, R R J Nerv & Ment Dis **65** 42, 1927
Dmitrijeff Beitr z path Anat u z allg Path **22** 207, 1897
Dock, George Arteriosclerosis of Nephritic Origin, J A M A **43** 730 (Sept 10) 1904
Dohle Deutsches Arch f klin Med **55** 190, 1895
Dominguez, R J Exper Med **46** 463, 1927
Effect on the Blood Pressure of the Rabbit of Arteriosclerosis and Nephritis Caused by Uranium Influence of Other Heavy Metals, Arch Path **5** 577 (April) 1928
Durante, G Bull Soc anat de Paris **74** 97, 1899
Dyke, S C Quart J Med **16** 1, 1922
Ernberg, Harold Nord med Ark **2** 1, 1911
Evans, Geoffrey Quart J Med **14** 215, 1920, ibid **16** 33, 1922
Brit M J **1** 454, 502 and 548, 1923, ibid **2** 1168, 1925
Faber, Arne Lancet **2** 125, 1913
Ferenczi, A Ungar med Presse **10** 412, 1905
Filatoff, N Jahrb f Kinderh **20** 209, 1883
Fischer, Bernhard Deutsche med Wchnschr **31** 1713, 1905
Fishberg, A M Arteriolar Lesions of Glomerulonephritis, Arch Int Med **40** 80 (July) 1927
Fletcher, H M Proc Roy Soc Med **13** 118, 1920
Flexner, S Am J M Sc **127** 747, 1904
Foster, L S J M Research **21** 297, 1909
Frederich, W Cong internat de med **16** 355, 1909
Fremont-Smith Am J M Sc **135** 199, 1908
Frothingham, Channing Relation Between Acute Infectious Diseases and Arterial Lesions, Arch Int Med **8** 153 (Aug) 1911
Bull Johns Hopkins Hosp **24** 323, 1913
Gaskell, M B J Path & Bact **16** 287, 1912
Gilbert A and Lion Arch de med exper et d'anat path **16** 73, 1904
Girode, J Rev mens d mal de l'enf **7** 241, 1889
Glaser, F Jahrb f Kinderh **87** 95, 1918
Greene, C H Chronic Diffuse Nephritis in Childhood, Am J Dis Child **23** 183 (March) 1922
Guillaume, A C Ann d'anat path **4** 772, 1927
Gull Sir W W and Sutton, H G Med Chir Tr **55** 273 1872
Halbey, Hunt Med Klin **11** 1135, 1915
Harvey, W H J Exper Med **8** 388, 1906
Virchows Arch f path Anat **196** 303, 1909

Hasenfeld, A Deutsches Arch f klin Med **59** 193, 1897
Ungar med Presse **2** 3, 1906
Hattori, Sadakichi Verhandl d jap path Gesellsch **5** 122, 1915
Hawkins, H P Tr Path Soc London **43** 46, 1892
Henderson, John Glasgow M J **99** 370, 1923
Hesse, M Virchows Arch f path Anat **258** 249, 1925
Heubner, J O L Ueber chronische Nephritis und Albuminurie im Kindesalter, Berlin, A Hirshwald, 1897
Hirsch, Max Med Klin **9** 1119, 1913
Hirsh, J L Am J M Sc **127** 1056, 1904
Hofbauer Wien klin Wchnschr **16** 983, 1903
Holmes, T A System of Surgery, 1870, vol 3, p 396
Holt, L E Diseases of Infancy and Childhood, New York, D Appleton & Company, 1914, p 595
Hopkinson, Daniel Wisconsin M J **10** 37, 1930
Hunt, F C Renal Infantilism Report of Case and Review of Literature, Am J Dis Child **34** 234 (Aug) 1927
Jeans and Cooke Clin pediat **17** 37, 1930
Johnson, George Brit M J **1** 59, 1873
Jordan, A C Lancet **1** 515, 1903
Jores, L Beitr z path Anat u z allg Path **32** 146, 1902
Virchows Arch f path Anat **178** 367, 1904
Joslin, E P Ann Clin Med **5** 1061, 1927
Joslin, E P, and White, P Diabetic Children, J A M A **92** 143 (Jan 12) 1929
Josue, O Am J M Sc **131** 186, 1906
Karsner, R G Am J Roentgenol **18** 442, 1927
Keating, J M Arch Pediat **4** 656, 1887
Encyclopedia of Diseases of Children, 1889, vol 2, p 868
Klimoff, J A Folia urolog **1** 222, 1907
Klotz, Oskar Brit M J **2** 1767, 1906
J Path & Bact **16** 212, 1912
J M Research **32** 27, 1915, **31** 409, 1915
Canad M A J **16** 11, 1926a
Ann Clin Med **4** 814, 1926b
Kolbert, V Wien klin Wchnschr **39** 790, 1926
Lebert, Herman, in Virchow, Rudolph Handbuch der speciellen Pathologie und Therapie, 1867, vol 5, p 335
Leopold, Simon Atlantic M J **29** 681, 1926
Lewkowitsch Jahrb f Kinderh **12** 189, 1878
Libman, E Mt Sinai Hosp Rep **5** 488, 1905
Longcope, W T Bull Johns Hopkins Hosp **21** 270, 1910, ibid **45** 335, 1929
Lowenthal, K Experimental Arteriosclerosis, Med Klin **22** 770, 1926 abstr, J A M A **87** 210 (July 17) 1926
Lubarsch Munchen med Wchnschr **56** 1909, 1909
MacCallum, W G Physiol Rev **2** 70, 1922
McMeans, J W J M Research **32** 377, 1915
Manouelian, Y Ann de l'Inst Pasteur **27** 12, 1913
Marchand Cong f inn Med **21** 23, 1904
Martin Bull Soc anat de Paris **2** 17, 1827
Matusewicz, J Beitr z path Anat u z allg Path **31** 217, 1902

Meade, H Lancet **2** 816, 1870
Meigs, A V Am J M Sc **95** 589, 1888, Tr Coll Phys Phila **11** 159, 1889
Miller, Reginald Proc Roy Soc Med **5** 38, 1912
Miller, Reginald, and Parsons, L Brit J Dis Child **9** 289, 1912
Morell-Lavelee Rev mens d mal de l'enf **3** 166, 1885
Mortensen, M A Is Arteriosclerosis a Hereditary Constitutional Disease? J A M A **85** 1696 (Nov 28) 1925
Moschowitz, Eli Am J M Sc **174** 388, 1927
Moulonguet, P Ann d'anat path **4** 685, 1927
Moutard-Martin, M Bull Soc anat de Paris **10** 775, 1875
Murphy, F D Chronic Glomerulonephritis with Lipoid Changes, Arch Int Med **45** 23 (Jan) 1930
Nascher, I L New York M J **106** 927, 1917
Newbergh, L H, and Clarkson, Sarah The Production of Atherosclerosis in Rabbits by Feeding Diets Rich in Meat, Arch Int Med **31** 653 (May) 1923a
Newbergh, L H Proc Inst Med, Chicago **5** 101, 1925b
Nuzum, F R California & West Med **25** 737, 1926b
Nuzum, F R, Seegal, Beatrice, Garland, Ruth, and Osborne, Margaret Arteriosclerosis and Increased Blood Pressure Experimental Production, Arch Int Med **37** 733 (June) 1926a
Oertel, Horst Northwest Med **23** 339, 1924
Ophuls, W Am J M Sc **131** 978, 1906
Arteriosclerosis and Cardiovascular Disease Their Relation to Infectious Diseases, J A M A **76** 700 (March 12) 1921a
Stanford Univ Publ **1** 1, 1921b
Oppenheimer, Rudolf Virchows Arch f path Anat **181** 382, 1905
Patterson, D H Proc Roy Soc Med **13** 107, 1920
Poynton, F J Heart Disease and Thoracic Aneurysms, London, Frowde, 1907
Phanomenow Arch f Gynak **17** 133, 1881
Rach, Ezon Jahrb f Kinderh **65** 221, 1907
Rickett, G R J Path & Bact **12** 15, 1908
Riva, A Med ital **3** 81, 1905
Roger, M H Bull et mem Soc med d hôp de Paris **5** 499, 1863
Rokitansky Pathologische Anatomie, 1855, vol 4, p 191
Romberg, E Cong f inn Med **21** 60, 1904
Lehrbuch der Krankheiten des Herzens und der Blutgefasse, Stuttgart, Ferdinand Enke, 1906
Ruhl, Arthur Deutsches Arch f klin Med **156** 129, 1927
Russel, A E St Thomas Hosp Rep **18** 63, 1899
Saltykow, S Beitr z path Anat u z allg Path **43** 147, 1908
Cor -Bl f schweiz Aerzte **45** 1057, 1089 and 1377, 1915a
Beitr z path Anat u z allg Path **60** 321, 1915b
Centralbl f allg Path u path Anat **37** 553, 1926
Sanne Rev mens d mal de l'enf **5** 56, 1887, Jahrb f Kinderh **27** 221, 1888
Scarff, R W J Path & Bact **30** 647, 1927
Schlayer Munchen med Wchnschr **55** 50, 1908
Schmidtman, M Virchows Arch f path Anat **237** 1, 1922, ibid **267** 601, 1928
Schott Cong f inn Med **21** 154, 1904
Schwarz, Herman Kidney Disease in Infants and Children Malignant Hypertension Nephritis, Primary Sclerotic Kidney, Am J Dis Child **27** 233 (March) 1924

Seitz Carl Verhandl d Gesellsch f Kinderh **13** 177, 1896
Kurzgefasstes Lehrbuch der Kinderheilkunde, Berlin, S Karger, 1901, p 400
Senftleben Virchows Arch f path Anat **72** 542, 1878
Simnitzky, S Ztschr f Heilk **24** 177, 1903
Simpson, E D J M Research **31** 301, 1914
Steiner and Neuretter Vrtljschr f prakt Heilk **105** 79 1870
Stengel, Alfred Discussion on papers by Drs Thayer and Brush, Drennan, Dock, Billings Cabot, Osler and Anders, J A M A **43** 780 (Sept 17) 1904
Stewart, T G Brit M J **2** 277 and 565, 1873
Stumpf Beitr z path Anat u z allg Path **59** 390, 1914
Sumikawa, T Virchows Arch f path Anat **196** 232, 1909
Thayer, W S, and Brush, C E Relation of Acute Infections to Arteriosclerosis, J A M A **43** 726 (Sept 10) 1904a
Thayer, W S Am J M Sc **127** 391, 1904b
Thoma, R Virchows Arch f path Anat **95** 294, 1884, **104** 209 and 401, 1886, **105** 1 and 197, 1886, **106** 421, 1886, **204** 1, 1911, **236** 243, 1922
Torhorst, H Beitr z path Anat u z allg Path **36** 210, 1904
Tyson, James Bright's Disease and Diabetes, Philadelphia, Lindsay & Blakiston, 1881, p 109
Virchow, Rudolf Virchows Arch f path Anat **77** 380, 1879
Vollbrecht, Richard Ueber jugendliche Arteriosklerose bis zum 36, Lebensjahre, 1907
Wallis, C Jahrb f Kinderh **27** 251, 1888
Watjen Sclerosis of Pulmonary Artery in an Infant with Transposition of Large Vessels, Verhandl d deutsch path Gesellsch **21** 259, 1926, abstr, Arch Path **4** 274 (Aug) 1927
Wiesel, Josef Wien klin Wchnschr **19** 723, 1906
Wiesner, Richard Wien klin Wchnschr **19** 725, 1906
Willson R W, and Marcy, Alexander Rupture of an Aortic Aneurism in a Child of Four Years, J A M A **49** 15 (July 6) 1907
Ziegler, Kurt Beitr z path Anat u z allg Path **38** 229, 1905
Zinserling, W D Centralbl f allg Path u path Anat **24** 627, 1913

SUPPLEMENTARY BIBLIOGRAPHY *

Alexejeff Arch f Kinderh **26** 109, 1899
Baginsky, Adolf Berl klin Wchnschr **45** 144, 1908
Henning, Carl Jahrb f Kinderh **30** 106, 1889
Marfan Semaine med **21** 97, 1901
Oppe, Wilibald Jahrb f Kinderh **37** 427, 1894
Also cases of Buchta, Libman, Klimoff, Meade, Moulonguet and Ruhl

* Cases quoted or reported as arteriosclerosis, but not conforming to definition of arteriosclerosis as used in this review

Laboratory Methods and Technical Notes

NEW METHOD OF DECALCIFICATION

NEWTON EVANS, M D, AND ARAM KRAJIAN, LOS ANGELES

The following simple method has been developed for the preparation of bony and other calcified tissues for section

The decalcifying solution consists of equal parts of (1) 85 per cent aqueous solution of formic acid and (2) 20 per cent aqueous solution of sodium citrate This is used following the usual fixation of appropriately sized blocks of tissue in a diluted solution of formaldehyde U S P (1 10) or other standard fixative The decalcification requires from a few hours to three or four days, depending on the character of the tissue and the size of the blocks

After decalcification is complete, the tissue must be washed in running water for from sixteen to twenty-four hours Thorough washing in water is essential, otherwise the subsequent embedding or freezing preparatory to sectioning cannot be accomplished The tissue is then cut by the freezing or by the paraffin method and stained in the usual manner

The use of this method for a number of months in comparison with decalcification by nitric acid, makes evident that it has marked features of superiority over the latter method The most prominent point is that the cellular elements are practically unaffected and take the usual stains apparently as perfectly as tissues that are not subjected to any decalcifying process It is our observation that after tissues have been subjected to nitric acid, the nuclear elements do not take stains well, and the longer the time during which they have been exposed to the acid the less satisfactory are the results

In a recent review of methods of preparing bony tissue, Jaffé [1] stated that formic acid is not a satisfactory agent because of its tendency to produce swelling of the fibers Our observations fail to detect this defect It is possible that the combination of the citrate with the formic acid counteracts such a tendency

* Submitted for publication, July 16, 1930

From the Pathology Laboratory of the Los Angeles County General Hospital

1 Jaffe, H L Methods for the Histologic Study of Normal and Diseased Bone Arch Path 8 817, 1929

Notes and News

Society for Experimental Biology and Medicine, New York—The Society recently elected Peyton Rous president, D J Edwards vice president and S J Goldfarb secretary-treasurer

Institute for Advanced Study—The initial endowment of this institute, which is founded by Louis Bamberger and his sister, Mrs Felix Field, Newark, N J, is $5,000,000 The aim is to provide facilities for research and training of advanced students by "eminent men of learning" The trustees for the first year have been selected, Abraham Flexner is the director of the medical division, and the further organization is in progress

Gift to National Institute of Health—The National Institute of Health (formerly the Hygienic Laboratory, Washington, D C) has been given $100,000 by the Chemical Foundation, Inc, it is reported, to be used for fellowships and studies in basic chemistry

Cancer Institute Organized—Under the direction of John G William Greeff, commissioner of the department of hospitals, the Brooklyn Cancer-Radium Research Institute is being organized for special cancer work John E Jennings is chairman of the organizing committee, which will be a holding corporation for the distribution of scholarship and research funds and of funds where needed for cancer prevention

Stokes Memorial Tablet—The foyer of the municipal building in Baltimore has been selected for a memorial bronze bas-relief in honor of William Royal Stokes, chief of the bureau of bacteriology of the city health department for more than thirty years, who died Feb 10, 1930, from psittacosis contracted while working on infected parrots

Schaudinn Medal—On March 23, 1930, the twenty-fifth anniversary of Schaudinn's discovery of the cause of syphilis, the Schaudinn Medal was awarded to F d'Herelle, microbiologist, Yale University, Max Hartmann, protozoologist, Berlin, and Eduard Reichenow, protozoologist, Hamburg

Abstracts from Current Literature

Experimental Pathology and Pathologic Physiology

DEPRESSED BONE MARROW FUNCTION FROM THE ARSPHENAMINES DAVID L. FARLEY, Am J M Sc **179** 214, 1930

Reports of seven cases of depressed function of bone marrow following treatment with arsphenamine are detailed The clinical pictures presented by these patients varied according to the degree of the depression of bone marrow and according to the particular element or elements of the marrow most affected The cases reported belong to the group of symptomatic blood dyscrasias It seems likely that the direct cause is disintegration in vivo of the arsphenamines, so that a benzene-like action takes place This, however, is a matter of opinion and not of proved fact The rarity of occurrence suggests a preceding weakness of the hemopoietic apparatus in the persons affected Careful examinations of the blood of patients showing unusual reactions to arsphenamine should be made Blood transfusions should be vigorously repeated in the treatment of depression of bone marrow, keeping constantly in mind that a physiologic paralysis rather than an actual aplasia may be present in the particular case, and that the patient may be tided over this phase to recovery

AUTHOR'S SUMMARY

INTESTINAL PERMEABILITY IN OBSTRUCTION OF THE COLON SIEGFRIED F HERRMANN AND GEORGE M HIGGINS, Am J M Sc **179** 365, 1930

The general permeability of the wall of the colon to particulate graphite is not increased in obstruction under the condition of the experiments here reported In the presence of injury to the mucosa and obstruction, however, particulate graphite may enter directly into the circulation and may be distributed by the portal blood stream

AUTHORS' SUMMARY

THE EFFECT OF INSULIN ON PATHOLOGIC GLYCOGEN DEPOSITS IN DIABETES MELLITUS SHIELDS WARREN, Am J M Sc **179** 482, 1930

Pathologic deposits of glycogen tend to disappear in cases of diabetes in which the patients are treated with insulin The normal storage of glycogen is increased in diabetic patients by treatment with insulin Sepsis decreases the effect of insulin so far as maintaining a normal distribution of glycogen is concerned The distribution of glycogen may be a valuable aid in the postmortem diagnosis of active diabetes Glycogen in the renal epithelium may represent an attempt at salvage of the carbohydrate being lost in the urine Variations in deposits of glycogen in the skin of diabetic subjects may be related to their susceptibility to cutaneous infection

AUTHOR'S SUMMARY

EARLY CHANGES IN DOGS FROM STERILE EXTRACT OF ANTERIOR LOBE OF HYPOPHYSIS EDWARD B BENEDICT, TRACY J PUTNAM AND HAROLD M TEEL, Am J M Sc **179** 489, 1930

The experiments reported here confirm our earlier observations on experimental hyperpituitarism and show particularly the early changes resulting from daily injection of a sterile active anterior lobe extract After only three months of injection definite changes are noted in the thyroid gland and in the genital tract The changes in the thyroid consist in hypertrophy of the gland epithelium with invasion of the lumen and almost complete absence of colloid As to the genital tract, both male and female were sexually inactive In the female there

is an hypertrophy of the uterus, ovaries and vagina In the male there is no hypertrophy, the testicles being small and showing only the earliest stages of spermatogenesis Skeletal overgrowth and splanchnomegaly were noticeable in the case of the foxhounds after three months of injection Sluggishness, inalertness and plantigrade stance were all noted after two months of injection A comparison was made between hypophysectomized and normal animals Cessation of growth after hypophysectomy was confirmed A marked slowing in the rate of growth of hair was noted Normal alertness was not interfered with by hypophysectomy

AUTHORS' SUMMARY

THE OUTCOME OF 625 PREGNANCIES AFTER IRRADIATION DOUGLAS P MURPHY, Am J Obst & Gynec **18** 179, 1929

The analysis is based on answers to questionnaires from all parts of the country Only therapeutic irradiation was considered The most striking outcome is the high frequency of gross deformities in the child after pelvic irradiation The central nervous system was affected most often The frequency and uniformity of the defects observed (microcephally most frequent) leave no doubt that irradiation of the internal genitalia of pregnant women is likely to be followed by seriously defective offspring

A J KOBAK

THE EFFECT OF PARATHORMONE ON NORMAL AND VITAMIN B-DEFICIENT RATS W B ROSE AND C J STUCKY, Am J Physiol **91** 513, 1930

Because of a number of similarities in behavior in dogs suffering from parathyroid tetany and from deficiency in vitamin B, the hormone was tested for possible content of the vitamin complex Using rats in which to a diet deficient in vitamin B was added a parathormone-dextrose, preparation prepared in such a way as to preserve any vitamin B that may have been originally present, or with some animals, supplementing the deficiency by daily subcutaneous injection of parathormone, it was found that the hormone was without effect in overcoming the vitamin deficiency Old rats succumbed after the third injection of 25 units of the hormone Young rats, on the other hand, survived four successive injections of a proportional dosage The injections resulted in a rise of blood calcium by approximately 40 per cent

H E EGGERS

THE EFFECTS OF ETHYLENE ON THE RATE OF GROWTH AND FERMENT ACTION IN ANIMALS A D HIRSCHFELDER AND E T CEDER, Am J Physiol **91** 624, 1930

In view of the fact that ethylene induces the rapid maturation of green fruits, the work here reported was undertaken to determine if it exerted a similar effect on animal growth, or on animal ferment activity No stimulating effect on growth was observed in rats on the saturation of their drinking water with ethylene, nor by the addition to their air of ethylene in various concentrations Its effect on various ferments was to cause an increased activity of amylase, but no effect was noted on pepsin, trypsin or liver lipase

H E EGGERS

EFFECTS OF PARATHYROID INSUFFICIENCY J N ESAU AND O O STOLAND, Am J Physiol **92** 1, 25 and 35, 1930

In three articles dealing with the subject of parathyroid insufficiency, the writers report, in dogs, the following observations An increase of inorganic phosphorus in the blood, with an increase of the total acid-soluble phosphorus which accompanied in amount the severity of the symptoms However, in cases with mild symptoms of parathyroid deficiency with delayed onset, the blood phosphorus usually fell below normal Low inorganic phosphorus in the blood, and

particularly a low content of acid-soluble phosphorus, were highly favorable to recovery Magnesium lactate and morphine sulphate were found to have beneficial effects despite a secondary progressive rise in inorganic and acid-soluble phosphorus, presumably through depressant action on the respiratory center and other nervous mechanisms No relationship could be established between the rate of fall of blood calcium and the type and severity of symptoms, although there was evidence of a relation to the time of onset The behavior of the calcium and acid-soluble phosphorus compounds in the blood of parathyroidectomized dogs is attributed to a disturbance of phosphocreatine metabolism chiefly within the muscle fibers, which affects the calcium-potassium ratio, with an effect on the permeability and irritability of the tissues whereby there is an accumulation of otherwise nontoxic metabolites with access of these to the cellular protoplasm, this producing the various clinical manifestations of parathyroid insufficiency Administration of parathormone was found to reduce the inorganic and acid-soluble phosphorus until the calcium rose much above the normal Then there was a rapid rise of inorganic phosphorus followed by a marked increase in acid-soluble phosphorus usually until death ensued The injection of liver extract into dogs with parathyroid insufficiency was found to produce marked visceral symptoms, which were accompanied by increased severity of the tetany, or by the induction of a brief period of tetany in dogs during the depression state Following the visceral reactions there was a recovery from the tetany, when these failed to develop, there was no improvement after treatment with extract While in the unbenefited animals there was a rise of blood calcium following the injection of the liver extract, in animals suffering from tetany, and in normal animals, the injection was followed by a slight lowering of blood calcium Synchronously, with the visceral reactions there was a marked fall in blood pressure, and during the period of low pressure there was distinct reduction of coagulation time The administration of the liver extract did not markedly prolong the recovery period of thyroparathyroid ectomized animals In general, liver extract was not found to be as effective an agent in counteracting the toxemia of parathyroid tetany as were calcium and other substances

H E Eggers

THE EFFECT OF REMOVAL OF THE LIVER ON THE FORMATION OF AMMONIA J L Bollman and F C Mann Am J Physiol **92** 92, 1930

Following the removal of the liver in dogs there was a complete cessation of the formation of urea, and administration of ammonia was followed by its appearance as ammonium salts in the urine and tissues So that removal of the liver is usually found to be followed by a considerable increase of blood and tissue ammonia Much of this appears to come from the gastro-intestinal tract, and to be independent of the urinary ammonia, which, following hepatectomy, depends on acid-base equilibrium to about the same extent as in normal animals After hepatectomy there is a progressive loss of the preformed urea, until, with minimal amounts in the urine, there is an accompanying decrease of urinary ammonia, along with the appearance of large amounts of amino-acids, uric acid and creatinine If these substances are administered, they are without effect on urinary ammonia, but if urea is given, the urinary ammonia is markedly increased—evidence of the origin of ammonia in the urine from urea

H E Eggers

THE PLACENTAL TRANSMISSION OF INSULIN FROM FETUS TO MOTHER G T Pack and D Barber, Am J Physiol **92** 271, 1930

Anesthetized pregnant goats were subjected to laparotomy, and insulin was carefully injected into the palpated feti, care being taken to avoid loss in the peritoneal cavity While the procedure was invariably followed by abortion, death of the feti being presumably due to hypoglycemic shock, such death did

not occur during the period of the experiment, as was determined by palpation and abdominal auscultation Determinations of blood sugar in the mother established the fact that there was transplacental transmission of the insulin

H E Eggers

The Experimental Production of Xerophthalmia in Mice E Pomerene and H H Beard, Am J Physiol **92** 282, 1930

In mice fed on adequate diets containing casein, extracted (A and B free) casein, and edestin as the protein factor, and commercial crisco, or this aerated for sixteen hours at 140 F, it was found that commercial edestin contained no vitamin A, and while crisco contained enough of this vitamin to prevent xerophthalmia in mice, it was inadequate to protect rats in similar circumstances The latter evidently require more of the antixerophthalmic factor than do mice

H E Eggers

The Physiologic Action of Rattlesnake Venom H E Essex and J Markowitz, Am J Physiol **92** 317-345, 695-705, 1930

In this series of eight articles the authors report the results of the observation of the effects of crotalin on living animal tissues Its administration was followed by a sharp and profound drop in blood pressure, which by a series of eliminations was found to be of peripheral character The fall in pressure is strikingly similar to that following injection of antigen into a sensitized animal Injected into skeletal muscle, it greatly weakens the fatigue curve, in uterine muscle it causes a maximal contraction which differs from that of anaphylaxis in that it has a long latent interval, and desensitization is slight, requiring repeated doses of venom In this condition, histamine is still capable of evoking a maximal reaction Perfused lung becomes tremendously edematous The addition of venom to blood, provided plasma unmodified by oxalate is present, causes swelling of the red cells to spherical form with later hemolysis, both of these changes being absent after removal of the plasma or its modification by the addition of oxalate From tests of the action of the venom on protozoa, it appeared to be a nonspecific protoplasmic poison As an indication of immunity to the venom its effect on blood pressure served as a satisfactory criterion, as did also its effect on corpuscular swelling Both of these criteria would indicate that in dogs the acquired immunity is of rather short duration Certain similarities are pointed out between crotalin intoxication and anaphylactic shock—the sharp fall in blood pressure, with initial splanchnic constriction followed by congestion, frequently lost coagulibility of the blood, a wheal reaction following intradermal injection of the crotalin, identical with that observed after the injection of histamine or of suitable antigen, evidence of bronchial constriction after the injection of the venom, maximal contraction of perfused uterine muscle, precipitation in dog serum incubated with small quantities of crotalin, constant rise of urinary bladder pressure after its injection in the dog In view of the fact that most of the outstanding effects of histamine may be obtained with crotalin, the writers suggest that the effect of tissue extracts or allied substances may depend for their depressor activity on a principle that is neither histamine nor cholin Crotalin contains no histamine, and yet it causes reduction of blood pressure, reddening and whealing of the skin, and contraction of perfused virgin guinea-pig uterus—the usually accepted criteria of histamine

H E Eggers

Effect of Isolation of Tail of Pancreas on Carbohydrate Metabolism G de Takats, F Hannett, D Henderson and I J Seitz, Arch Surg **20** 866, 1930

Sugar tolerance tests were made on dogs whose pancreatic glands were divided with an electrocautery and then wrapped in omentum The tests repeated at

intervals of from two to four weeks for several months showed a definite fall in blood sugar and an increase in hypoglycemia Intravenous doses of dextrose showed that a larger than normal amount of dextrose per kilogram of body weight had to be given intravenously in order to produce glycosuria These observations would suggest the possibility that mild pancreatitis set up by the stimulus of the operation results in a hypertrophy of islet tissue

N ENZER

THE METABOLISM OF AMINO-ACIDS IN HEALTH AND DISEASE LESLIE WITTS, Quart J Med **22** 477, 1929

The amino-acid glycine was administered orally in amounts of from 25 to 50 Gm in from 10 to 15 per cent aqueous solution Amino-acid nitrogen, non-protein nitrogen, uric acid, urea and sugar of the whole blood were determined at intervals after the ingestion of glycine and compared with the fasting levels In a normal person, after the ingestion of 50 Gm of glycine, the amino-nitrogen of the blood increases from the fasting level of 7 mg per cent to about 12, reaching its peak in from one to four hours and returning to the fasting level in from six to eight hours In thirty-one miscellaneous conditions without involvement of the liver, the average fasting level of amino-nitrogen was 6 3 mg per cent Lower values were found in myxedema and in one nervous patient The values were slightly higher in uremia and in a case of leukemia In twelve cases of disease of the liver, the average fasting level was 6 8 mg per cent, and in ten of these the amino-nitrogen was between 5 7 and 8 mg per cent A low value of 5 mg per cent was found in a case of Hanot's cirrhosis, and a high value of 8 6 mg per cent in a comatose patient with cirrhosis of the liver Following the ingestion of glycine, the curves were essentially similar to those obtained in controls In diseases of the liver, with the exception of acute yellow atrophy, both the fasting and postabsorptive values of amino-nitrogen were normal However, in acute yellow atrophy there is an increase in the amino-nitrogen of the blood, and a higher curve is obtained after the ingestion of glycine This is probably due to the necrosis and autolysis of the liver cells Following the ingestion of 25 Gm of glycine by normal subjects, the blood urea increases from 30 per cent upward as high as 113 per cent The same type of variation occurred in normal persons as well as in those with diseases of the liver The blood sugar was found to rise after the ingestion of glycine, but no distinction could be made in diseases of the liver and in diabetes different from other diseases In passive congestion of the liver, the protein metabolism appeared to be normal In hypertension the amino-nitrogen was high and urea formation was deficient In two diabetic patients, urea formation was defective, but in other cases of diabetes, in exophthalmic goiter, myxedema and gout it was within normal limits The author concludes that tests based on changes in the blood amino-nitrogen or urea after the ingestion of proteins or amino-acids have no value in the diagnosis of hepatic disease

N ENZER

THE FATE OF THYROXIN IN THE TREATMENT OF NEPHROSIS R PLATT, Quart J Med **23** 129, 1929

Clinical observations are to the effect that patients with nephrosis have a very high tolerance to thyroxin A low metabolic rate does not seem to account for this unusual tolerance Experiments were made to determine whether or not the nephrotic kidney allows rapid excretion of thyroxin Groups of tadpoles were taken, and to the vessel containing one group was added the urine of a case of nephrosis receiving from 7 to 10 mg of thyroxin per day To group B the same amount of normal urine was added, in which had been dissolved thyroxin in the calculated concentration which the urine of the patient would have contained had the drug been excreted Two control groups receiving thyroxin only and one receiving normal urine only were used The results seemed to show

that nothing approaching the amount of thyroxin administered is being excreted by the patient in an unchanged condition The author suggests that the thyroxin is rapidly distributed in nephrosis, or its action is inhibited The inhibition does not seem to depend on the increased level of blood cholesterol N ENZER

SOME FORMS OF PERNICIOUS ANEMIA WITH KNOWN ETIOLOGY ALFRED FONTANA AND KARL LAGEDER, Virchows Arch f path Anat **273** 553, 1929

The material of this extensive paper (50 pages) is furnished by five cases of anemia Syphilis, tuberculosis, pregnancy, enteritis, hepatitis are considered the cause of the pernicious anemia in these cases The morbus Biermer is only one manifestation of the much wider concept, "pernicious anemia" Pernicious anemia is a complex of symptoms which may be produced by different causes

ALFRED PLAUT

CONGENITAL ANOMALIES OF LIPOID METABOLISM A ABRIKOSSOFF AND H HERZENBERG, Virchows Arch f path Anat **274** 146, 1929

The so-called Christian type is not a disease by itself but a skeletal form of Niemann-Pick's disease All congenital anomalies of lipoid metabolism (xanthoses) form one group The anomaly may be more marked in the cholesterol metabolism in the neutral fats, the phosphatides or the kerasin There may be ectodermal, visceral or skeletal forms These anomalies obviously are mutations They represent an inherited genotypically fixed disease of the mesenchyme The factors are recessive and become manifest only after inbreeding The hypercholesterinemia is not primary

ALFRED PLAUT

REMARKS ON ARTICLE BY ABRIKOSSOFF AND HERZENBERG L PICK, Virchows Arch f path Anat **274** 152, 1929

The three types, Gaucher's disease, Niemann-Pick's disease, and the disease described by Christian, are different manifestations of a primary disturbance of lipoid metabolism Nevertheless, each of the three is a definite clinical and anatomic entity The clinical course of Niemann-Pick's disease generally is too fast for the development of a skeletal form Intermediate forms must be expected So far, about fifty cases of Gaucher's disease are on record and about fifteen of morbus Niemann-Pick and Christian's syndrome In comparison with these figures, the number of intermediate forms is negligible ALFRED PLAUT

THE INCREASED FREQUENCY OF THROMBOSIS AND EMBOLISM H AXHAUSEN, Virchows Arch f path Anat **274** 188, 1929

Statistical survey of 11,266 autopsies between 1912 and 1928 showed a decrease in thrombosis and embolism up to 1921, then increase beginning in 1923 Since circulatory diseases in this study give figures not dissimilar to those of other disease, one cannot attribute the increased frequency to intravenous therapy Surgical and medical cases show no difference Obviously, we are facing a problem of changing frequency as it exists in many other diseases ALFRED PLAUT

Pathologic Anatomy

THE LOCAL EFFECT OF THE INJECTION OF GASES INTO THE SUBCUTANEOUS TISSUES A W WRIGHT, Am J Path **6** 87, 1930

By the subcutaneous injections of oxygen, nitrogen and carbon dioxide, there have been produced large numbers of monocytes modified monocytes, epithelioid cells and epithelioid giant cells which resemble those of tuberculosis as seen in

supravital preparations The causes for this reaction are nonspecific Monocytes are considered to arise locally, originating from some type of fixed connective tissue cell Epithelioid cells and epithelioid giant cells appear in these experiments to arise almost entirely from monocytes, the cause of the transformation being evidently due to some chemical change in the medium about the cell Histologic structures resembling true tubercles have been found in considerable numbers Fibrin is present in the gas spaces, often forming a thin membranous lining The new formation of elastic tissue is suggested about gas spaces where tissue cells are under tension Spaces lined with flat, mesothelial-like cells and containing both gas and fluid are found after six or eight days The lining cells are thought to originate from connective tissue cells, although endothelium cannot be ruled out as a source

AUTHOR'S SUMMARY

MIXED TUMORS OF THE PALATE R D'AUNOY, Am J Path 6 137, 1930

The term mixed tumor as applied to the neoplasms occurring in the general oral-facial region is distinctive and descriptive and should be retained The origin of these tumors can be most satisfactorily explained by the theory of embryonal enclavement Microscopically complex but clinically benign, it is doubtful if typical mixed tumors ever undergo so-called malignant changes Certainly such transformations, if occurring, are difficult of proof Palatal mixed tumors show the same general histologic complexity and clinical characteristics as those occurring in other regions Two mixed tumors of the palate are reported

AUTHOR'S SUMMARY

PRIMARY MYOCARDIAL AMYLOIDOSIS R M LARSEN, Am J Path 6 147, 1930

The distribution of amyloid within the myocardium in primary myocardial amyloidosis may be diffuse as well as focal Its deposition within the heart may occur in the presence of hypertrophy as well as atrophy It is deposited only in those tissues that have a known vascular bed Its presence in avascular tissue is only accomplished by continuity with deposits in vascular tissue The deposition of amyloid occurs primarily about venocapillary endothelium from which it extends to surround the normal tissues, ultimately cutting off the vascular supply to the part Then only the tissues atrophy and are replaced by amyloid This constitutes the primary mode of amyloid infiltration Amyloid gains entrance to occasional cardiac muscle cells by a process of invagination and ultimate penetration of the cell wall This is a direct method by which myocardial cells may be replaced by amyloid There is no evidence that amyloid deposit is dependent on localized metabolic changes, nor is there evidence of primary pericellular deposition of amyloid, from which it freely invades living cell substance The deposit of amyloid apparently is dependent on changes in endothelium, especially of venocapillaries, which may possibly become impermeable to some substance in the tissue lymph that may normally be present in tissue lymph and capable of permeating venocapillary endothelium

AUTHOR'S SUMMARY

GENERALIZED AMYLOIDOSIS OF THE MUSCULAR SYSTEMS SHIELDS WARREN, Am J Path 6 161, 1930

A case of generalized amyloidosis of the muscular systems is reported The evidence indicates a widespread perversion of fibroblastic function The parenchymatous organs are not involved

AUTHOR'S SUMMARY

AGE OF AMPHOPHILE LEUCOCYTES IN RABBITS EMILY HUNT AND H G WEISKOTTEN, Am J Path 6 175 and 183, 1930

The Arneth count made from smears from the blood of the rabbit is of definite value in determining the relative age of the amphophils, and that a "shift to the

left" in the count (increase in per cent of the simpler formed nuclei) actually indicates a relative increase in the number of young or more immature amphophils in the circulating blood Cessation of the supply of amphophils from the marrow results in practically complete disappearance of amphophils from the circulating blood in a period of between three and four days The average duration of the life of amphophils in the rabbit's blood is between three and four days

AUTHORS' SUMMARY

COMPLETE SITUS INVERSUS OF THE VENA CAVA SUPERIOR B HALPERT AND F D COMAN, Am J Path **6** 191, 1930

A rare vascular anomaly in a negro infant 2 weeks of age is described The arrangement and the course of the dural sinuses, the large venous trunks of the neck, the vena cava superior and the vena azygos presented a mirror image of the normal There was no trace of a right vena cava superior Previous reports of this anomaly are reviewed

AUTHORS' SUMMARY

THE TOTAL NUMBER OF GLOMERULI IN THE CONGENITALLY ASYMMETRICAL KIDNEY R A MOORE, Am J Path **6** 199, 1930

The enlarged kidney associated with hypoplasia or agenesia of the opposite kidney contains the usual number of glomeruli characteristic for one kidney of that species

AUTHOR'S SUMMARY

THE VASCULARIZATION OF THE EPICARDIAL AND PERIAORTIC FAT PADS H F ROBERTSON, Am J Path **6** 209, 1930

The arteriae telae adiposae of the heart and ascending aorta proliferate in response to disease, augmenting the myocardial blood supply or tending to compensate any deficiency in it The periadventitial vessels of the ascending aorta, joining the coronary vessels with those of the thorax, may greatly assist in this compensation The fat bodies develop about the proliferating vessels and their size depends primarily on the extent of vascularization present, secondarily on such factors as atrophic and sclerotic myocardial changes, and individual peculiarities in local and general metabolism

AUTHOR'S SUMMARY

CHANGES IN THE FINGER NAILS IN PULMONARY TUBERCULOSIS ALBERT G HAHN, Am Rev Tuberc **20** 876, 1929

Pittings or depressions in the finger-nails were observed in 100 per cent of a group of patients suffering from active pulmonary tuberculosis as compared to 6 per cent of a group of patients in whom the tuberculosis had been inactive for a relatively short period, and a third group of patients without symptoms of activity for from one to twenty-five years in whom this change was absent in 100 per cent These characteristic pittings in a known case of pulmonary tuberculosis are considered indicative of recently active tuberculous disease provided no other disease is present Hippocratic incurvation was found in 76 per cent of the active tuberculous group, 50 per cent of the inactive tuberculous group, and 30 per cent of the ex-patient workers at the sanatorium This change did not occur in any of the nontuberculous controls (presumably normal persons) Cyanosis of the finger-nails was noted in 66 per cent of the active group as against only 2 per cent of the inactive or chronic group This change was well marked in all cases in which the disease was rapidly advancing, as evidenced by clinical symptoms and roentgenographic studies Cyanosis may be of value in prognosis Ridging seems to be of less importance than the other changes described

H J CORPER

COMPARATIVE RADIOGRAPHIC AND ANATOMICAL STUDIES OF INTESTINAL TUBERCULOSIS M MAXIM STEINBACH, Am Rev Tuberc **21** 77, 1930

On the basis of sixty-seven cases of far advanced pulmonary tuberculosis, studied clinically, roentgenologically and at autopsy in relation to tuberculous ulceration of the intestines, it was found that the roentgenologic signs usually considered diagnostic of this condition were highly unreliable in over 52 per cent of the cases Microscopic as well as gross anatomic examination of the intestines should be done in all cases Examination without incising the intestine is not to be relied on, since many of the early ulcerations involve only the mucosa and submucosa, and are to be detected only after opening and washing the intestines A large number of ulcerations not visible macroscopically are seen only after careful microscopic search

H J CORPER

CHRONIC GLOMERULONEPHRITIS WITH LIPOID CHANGES FRANCIS D MURPHY, Arch Int Med **45** 23, 1930

The clinical features of a patient, aged 12 years, with chronic glomerulonephritis and lipoid changes in the various organs, are described from the onset of the disease until death five years later During the course of the disease it is seen that the symptoms were evanescent and varied so much from time to time that the proper interpretation of the clinical picture was difficult in some stages of the disease Lipoid deposits in the various parenchymatous organs are described, and their relationship to hypercholesterolemia is discussed The atherosclerosis of the aorta and mitral valve is described and its dependence on hypercholesterolemia is pointed out A description is given of the changes found in the arteries and arterioles of the kidney and other parenchymatous organs as well as those found in the skeletal muscles The damage found in the renal arterioles is especially dwelt on

AUTHOR'S SUMMARY

HEMOCHROMATOSIS ELMER H FUNK AND HUSTON ST CLAIR, Arch Int Med **45** 37, 1930

A case of hemorchromatosis without diabetes is reported The copper content of the liver was found to be 140 mg per kilogram of fresh tissue, or 331 8 mg for the entire organ The copper content of the spleen was found to be less than 1 mg for the entire organ The estimated quantity of iron in the liver is probably inaccurate but was found to be at least 6 2 Gm per kilogram of tissue, or 14 7 Gm for the entire organ No analyses were made for zinc, manganese, nickel or other heavy metals It is unlikely that increased hemolysis is the cause of the iron pigmentation It is likely that the role played by copper is secondary to an unknown etiologic agent

AUTHORS' SUMMARY

ATELECTASIS IN THE PATHOGENESIS OF ABSCESS OF THE LUNG THEODORE S MOISE AND ARTHUR H SMITH, Arch Int Med **45** 92, 1930

Obstructive atelectasis is a common observation in otherwise healthy albino rats The obstruction is frequently the result of the accumulation of mucus in the form of a plug completely occluding the bronchial lumen Micro-organisms may be frequently obtained from the lungs of healthy animals On the basis of these observations, it is probable that the sequence of events in the pathogenesis of pulmonary disease in the white rat is the entrance of organisms into the lung, an obstructive atelectasis followed by the growth of organisms distal to the point of occlusion and the development of pulmonary suppuration The established suppurative process may extend to other parts of the lung by a repetition of these changes or by direct extension to adjacent structures

AUTHORS' SUMMARY

THE RELATION OF THE DISTRIBUTION AND STRUCTURE OF THE CORONARY ARTERIES TO MYOCARDIAL INFARCTION MERRITT B WHITTEN, Arch Int Med **45** 383, 1930

The deep branches of the arteries of the left ventricle leave at right angles and pass directly through the myocardium The branches of the arteries of the right ventricle spread out in practically the same plane as the larger artery from which they arise Three distinct types of lesions are produced by infarction involving the left ventricle The nature of the infarction depends on the site of the occlusion The fact that the injury in infarction is almost always to the left ventricle, whereas the right ventricle rarely is involved, seems to depend on the differences in the anatomic structure of the arteries of the two ventricles Infarction in the posterior surface of the left ventricle is much more common than has been heretofore recognized Infarction at the apex may be due occasionally to occlusion of the right coronary artery It is suggested that the position of the first part of the circumflex branch of the left coronary artery, while it is in the coronary sulcus and above the ventricle, is a factor in making it less liable to occlusion than the anterior descending artery Infarction in the right ventricle was found only in connection with massive infarction of the left ventricle and usually was minimal in amount The right ventricle, although it appears to be less vascular than the left, is not believed to be especially predisposed to failure with age In fact, the left ventricle is found to be the one to fail most frequently from arterial insufficiency

AUTHOR'S SUMMARY

ACUTE TOXIC (NONSUPPURATIVE) ENCEPHALITIS IN CHILDREN A A LOW, Arch Neurol & Psychiat **23** 696 1930

Low studied in detail the structural changes in the brains of children who died after a short course with manifestations of severe lesion of the brain, such as convulsions, coma, delirium, general spasticity, ocular nerve palsies and similar signs The duration of the illness was two four, ten, fourteen and thirty-nine days Some structural changes in all of the five cases, in spite of the varied time element, were common Here Low includes the absence of mesodermal elements (infiltrations) in the perivascular spaces and of hemorrhagic foci, extensive damage to the cortical ganglion cells (mostly as peracute or acute liquefaction), progressive glial and vascular reaction, the presence of so-called glial reticulum and a moderate meningeal reaction In the five cases the changes varied somewhat In the case, for instance, that lasted only two days, the ganglion cells showed so-called peracute liquefaction with disintegration, while the glia cells also showed regressive changes which in the corpus striatum were of the so-called ameboid type, in the cases that lasted two or more weeks, the glial changes were proliferative in the form of rich cytoplasmic glia, glia rosets, neuronophagia and satellitosis, the ganglion cell destruction was milder, the blood vessels were engorged and new capillaries were numerous Low contrasted his observations with those of Lothmar and Rosenthal, who by injecting dysentery toxin and guanidin into rabbits obtained changes like those described by Low The changes in the animals differed according to the virulence and the amounts of the toxins injected

GEORGE B HASSIN

TUMOR OF THE BRAIN WITH SUDDEN ONSET OF SYMPTOMS C W IRISH, Arch Neurol & Psychiat **23** 727, 1930

Tumors of the brain often give a clinical picture of an acute onset and rapid course much resembling a vascular or an inflammatory condition of the brain Structurally such tumors, in the greatest number of cases, were spongioblastomas, a type of glioma especially well studied by Globus and Strauss They are malignant gliomas because of the rapid growth, as evidenced by the presence of numerous mitotic phenomena in the tumor cells and the presence of well defined

spongioblasts Irish gives clinical histories of ten cases, nine of which proved to be definite spongioblastoma multiforme, one case was classified as medulloblastoma The clinical picture varies, depending on the localization which in the series of Irish involved the frontal lobes (twice), frontotemporal (twice), temporal and occipital lobes (once in each), and once the vermis of the cerebellum In three cases the lesions were multiple involving among other structures also the basal ganglions The termination is practically always fatal, the entire duration of illness averaging fifty-eight days (from seven days to four months)

GEORGE B HASSIN

ELEPHANTIASIS AND EDEMA F L REICHERT, Arch Surg **20** 543, 1930

Emphasis is placed on the importance of appreciating that obstruction of the lymphatic and venous drainage does not cause elephantiasis unless there is a concomitant inflammatory process in the subcutaneous tissue In a previous report by the author (*Arch Surg* **13** 871, 1926), there was reported the technic of complete severance of the tissue of the thigh, with the exception of the femoral artery and vein Invariably edema developed in the extremity and an anastomosis could be demonstrated by opaque material injected into the arterial and venous system Similarly, lymphatic regeneration could be demonstrated Subsidence of the edema occurs with the regeneration of the lymphatic system, and edema persists if the lymphatics are blocked The author attempted to superimpose an infection on such an edema, but all attempts by injecting various strains of streptococci failed, except for one instance The author believes that so-called elephantoid conditions differ from true elephantiasis only in their extent In contrast with simple edema elephantiasis and elephantoid states present an entirely different picture in roentgenograms of the soft tissue Not only do they show great thickening of the dermis and marked enlargement of the subcutaneous tissues down to the muscle, with a thickened muscular aponeurosis, but there is an extensive network of fibrous trabeculations in the hypodermal layer The article is extensively illustrated by case histories and photographs of roentgenograms No edema, even of long duration, will lead to proliferative change and deposition of fibrous connective tissue unless it is associated with inflammation Lymphedema and lymphaticovenous stasis occurred in replanted limbs and in venous and perivenous blockade The factor of lymphangitis in elephantiasis could not be reproduced experimentally The elephantoid state is a sequel to varicose veins, phlegmasia alba dolens and to chronic bacterial fungoid and malignant ulcerations

N ENZER

AMYLOIDOSIS OF THE THYROID GLAND W C HUNTER and D B SEABROOK, Arch Surg **20** 762, 1930

The authors report an instance of enlargement of the thyroid due to amyloidosis The patient had advanced tuberculosis in both upper lobes The thyroid was causing pressure on the trachea Grossly, the gland was yellowish white, and somewhat soft and avascular, the colloid was scanty and vacuolated, there was a strongly positive test for amyloid, and there was a marked reduction in the number of acini, the epithelium was flat or cuboidal There was a large amount of homogeneous hyaline substance between the acini A review shows that the lesion is rather rare, although the author does not report the total number of cases on record to date

N ENZER

ANNULAR PANCREAS N J HOWARD, Surg Gynec Obst **50** 533, 1930

After dense adhesions between the gallbladder, omentum and the duodenum were separated it was found that the head of the pancreas completely encircled the midpart of the second portion of the duodenum The pancreatic tissue was narrowed to an isthmus about 3 cm broad at the lateral anterior wall of the

duodenum Proximal to the constricting ring, the duodenum was dilated to a diameter of 6 cm and distally constricted to 4 cm The cutting of a good sized duct in the pancreatic tissue anterior to the duodenum led to the formation of a pseudocyst which on incision resulted in a pancreatic fistula At least 1,100 cc of fluid was discharged a day, but there was no intense ulceration of the skin which was attributed to the absence of duodenal secretions, which activates the pancreatic enzymes The literature and the embryologic explanations of this anomaly are given

RICHARD A LIFVENDAHL

PSEUDOTUBERCULOUS SALPINGITIS J DENTON and G DALLDORF, Surg Gynec Obst **50** 663, 1930

It is believed that a foreign body type of reaction in the oviducts is frequently diagnosed as tuberculosis In seventy-eight cases previously diagnosed as tuberculous salpingitis, there were thirty-four in which this confusing type of reaction had occurred The foreign substance consisted of calcium refractive crystalloid clusters in the centers of basophilic masses and in the bodies of giant cells and endothelial nodules These chemical substances are absent in true tuberculous lesions and the tubes are larger, cannot be easily separated from the surrounding granulation tissue and extensive caseation is present through the muscularis, and the tubercles on the serosal surface are confluent and caseous

RICHARD A LIFVENDAHL

SOLITARY CYSTS OF THE KIDNEY A B HEPLER, Surg Gynec Obst **50** 668, 1930

On a basis of four serous and three hemorrhagic solitary cysts studied by the author, a review of the literature and experimental work, the conclusions are reached that tubular block alone cannot produce such cysts, but if the same condition which produced tubular obstruction also interfered with the blood supply to the same segment of the kidney, thus resulting in parenchymal anemia and degeneration, then tissue relaxation, rapid dilatation and cyst formation might occur

RICHARD A LIFVENDAHL

THE CAUSES OF NEONATAL DEATH J N CRUICKSHANK, M Res Council, Special Rep Series, no 145, 1930

In 800 autopsies in cases of neonatal death the cause of death was considered to be due to birth asphyxia, birth injury or prematurity in 540 instances, to infected conditions in 238, and to gross developmental defects in 22

ACUTE EOSINOPHILIC LEUKEMIA AND EOSINOPHILIC ERYTHRO-LEUKEMIA J HAY and W H EVANS, Quart J Med **22** 167, 1929

The authors report two cases, the first of which was clinically identical with acute myelogenous leukemia, splenomegaly and general glandular enlargement and leukocytosis being present The internal organs showed intense infiltration with eosinophilic cells The white blood count in this case was 72,187, with 83 7 per cent eosinophils

The second case was more chronic and showed the combination of polycythemia with leukocytosis and also a high eosinophilic count Details are given of the clinical and the postmortem observations, and fairly complete records of similar cases selected from the literature All of the cases are identical in that they closely resemble a myelogenous leukemia, with the exception that the cellular infiltrations are polymorphonuclear or adult eosinophilic cells

The authors hold that there is no justification for the establishment of a new clinical entity, as favored by some authors, under the caption "hyperleucocytosis with splenomegaly" They urge, rather, that these are examples of myelogenous leukemia, differing only in the type of cell predominant With reference to the

polycythemia and leukocytosis, they point out that in other cases of this type myelogenous forms appear in the circulation, and in one case (Blumenthal's) there was a frank combination of leukemia and polycythemia Hence they favor the term "erythro-leukemia"

N ENZER

STEREOSCOPIC RADIOGRAPHY OF THE CORONARY SYSTEM J S CAMPBELL, Quart J Med **22** 247, 1929

This is an instructive article on the blood supply of the heart An opaque medium "Roentyum" was injected into the vessels, through each coronary artery Stereoscopic x-ray pictures were then taken of the specimens The results bear out the previous work of Gross The author points out the inconstancy of the blood supply His studies, based on 100 specimens, disclosed numerous variations in the distribution of the coronary vessels In the auricles particularly he found nothing constant in the distribution of the vessels, with the exception of one branch of the ramus ostei cava superiosus While this vessel has no constant origin, it has a constant termination It helps to form the anastomosis at the junction of the superior vena cava with the right atrium The ventricular blood supply is fairly constant on the anterior surface, but not so on the posterior surface With regard to the blood supply of the neuromuscular tissue, it was found that the supply came in 81 per cent from the right coronary and in 19 per cent from the left coronary There are, however, many alternative channels of blood supply, as demonstrated in two of his cases in which lesion of the specific artery of the node and bundle failed to give any electrocardiographic evidence of a lesion The article is well illustrated

N ENZER

STORAGE OF IRON FOLLOWING ITS ORAL AND SUBCUTANEOUS ADMINISTRATION C J POLSON, Quart J Med **23** 77, 1929

Ten cubic centimeters of undiluted dialyzed iron containing 0 5 Gm of iron was administered orally and subcutaneously in daily doses to rabbits The experiments lasted from one hundred and seventy-two to four hundred and fifty days The rabbits receiving the iron orally showed a maximum storage in the liver There was no increase of iron in the lungs The kidneys in some cases showed excessive iron The chemical analysis of the subcutaneous series also showed high concentration in the liver, none in the lungs, an excess in both the kidney and spleen, and also a considerable amount in the dried subcutaneous tissue The liver lobules contained iron diffusely Coarse granules could be seen in the liver cells around the nuclei, generally at the outer third of the hepatic lobule A few Kupffer cells contained iron Iron could be stained in the spleen There was an excess in the cecum and kidney, no excess in the bone-marrow and none in the lungs In the subcutaneous series, the liver contained numerous giant cells, and the concentration of iron was much greater than in the oral series, although it appeared later There were no giant cells noted in the oral series There was more iron in the spleen after oral administration than after intravenous administration The high concentration of iron in the cecum and kidney is due to excretion

N ENZER

THE REACTION OF TISSUES TO THE ASBESTOS FIBER, WITH REFERENCE TO PULMONARY ASBESTOSIS S ROODHOUSE GLOYNE, Tubercle **11** 151, 1930

Asbestos fibers, when injected into the body, act as a benign irritant producing granulation tissue with many asbestosis giant cells, presumably an attempt to destroy the asbestos fibers by phagocytosis Connective tissue is formed in due course, but the giant cells persist The asbestosis giant cell is readily distinguished from the tuberculosis giant cell Asbestosis bodies are not found Asbestos injected repeatedly intravenously appeared to have no toxic effects on distant tissues

H J CORPER

PULMONARY ASBESTOSIS DEATH FROM TUBERCULOSIS TWO YEARS AFTER FIRST EXPOSURE TO THE DUST W BURTON WOOD and D S PAGE, Tubercle **11** 157, 1930

The rapid evolution of the tuberculous process in a patient who had been exposed to asbestos dust was a feature of a case here reported A large number of asbestosis bodies was present in the lungs two years after the first exposure to the dust

H J CORPER

BLOOD CONTENT OF THE HUMAN SPLEEN H HARTWIG, Beitr z path Anat u z allg Path **83** 431, 1929

To determine the blood content of the spleen, the organ, carefully isolated at necropsy, was perfused with water until the perfusate was colorless The hemoglobin content of the blood of the right side of the heart and of the perfusate having been determined, it was possible to calculate the quantity of blood represented by the hemoglobin of the perfusate A pressure of from 170 to 180 mm of mercury was used for the perfusion, the time required varying from one and one-half to six hours The quantity of perfusing fluid varied from 6 5 to 70 5 liters, the average being 20 5 liters One hundred and fifty-two spleens, obtained in the course of 194 necropsies on persons ranging in age from 5 to 86 years, were found satisfactory for perfusion Of the perfused spleens, only those in which microscopic examination after perfusion revealed no red corpuscles in the tissue were used for the final calculation of results Hartwig s figures are therefore based on sixty-seven spleens The normal spleen with an average postmortem weight of 169 Gm was found to have a blood content of 56 cc Blood constituted 33 per cent of the postmortem weight of the normal spleen The lowest figures were obtained for the spleens from cases of generalized anemia, for which group the average weight was 115 Gm, of which blood constituted 22 per cent It may be noted that the printed tabulation contains a misprint of this figure, which is given as 59 The highest figures were obtained for passively congested spleens The average weight of the spleens from this group was 249 Gm, the blood content being 116 cc, or 49 per cent of the total weight The blood content of the spleen is estimated at 1 3 per cent of the total blood for the normal spleen, 0 7 per cent for the spleen from cases of generalized anemia, and 2 6 per cent for the spleen passively congested These values are much lower than those obtained by other methods for the spleens of living animals, in which the spleen is held to act as an important reservoir of the splanchnic blood The human spleen is probably smaller after death than at any time during life Hartwig estimates the decrease at from one-fifth to one-third To determine the maximum fluid capacity of the spleen, the organ, after completion of the perfusion, was filled with water to its maximum capacity at a pressure of 180 mm of mercury By this method the average maximum fluid capacity of the normal spleen was found to be 202 cc, as compared with an average postmortem blood content of 56 cc For the spleen from cases of generalized anemia, the average maximum capacity was 104 cc and for the passively congested spleen, 230 cc The determinations of the maximum capacities gave considerable deviations from the average for each group Hartwig estimates the blood content of the normal spleen during life at from 50 to 200 cc and believes that the figure lies in the upper half of this range

O T SCHULTZ

ACQUIRED PATHOLOGIC FISSURES OF THE BRAIN MARIA MITTELBACH, Beitr z path Anat u z allg Path **83** 445, 1929

The author presents a description of five examples of a lesion of the brain that she believes has not been previously described, except for a brief report of one of the cases of her series made by Spatz The lesion is a characteristic fissuring of the convolutions of the brain The fissures are narrow, slitlike and long,

and are situated in the middle of the convolutions, following the windings of the latter Short lateral branches are given off from some of the main fissures The pia may run smoothly over the fissures, so that the latter would be overlooked if the pia is not removed A loose network of connective tissue dips down into some of the fissures from the undersurface of the pia The convolutions of the convex surface of the frontal and anterior third of the parietal lobes were involved, the distribution being symmetrical in the two hemispheres Macroscopically, on cross-section the fissure appears as a narrow funnel-shaped defect that does not extend entirely through the cortex Microscopically, the cell layers of the cortex extend in regular order to the margins of the defect At the bottom of the latter is a narrow glial scar in which both glia cells and fibers are increased In this area the regular arrangement of cells and fibers is disturbed In preparations stained for myelin sheaths, the scar reveals a dense network of irregularly entwined myelin sheaths in which neurofibrils can be demonstrated This histologic picture is identical with that of the plaques fibromyeliniques described by C and O Vogt No remains of the lost cerebral substance were present in any of the lesions, which leads to the conclusion that the lesion is an end-stage of a process, the earlier stages of which have not been seen The fissures can be readily distinguished from congenital microgyria, from the cortical defects due to arteriosclerosis of the pial vessels, and from the granular atrophy due to sclerosis of the finer vessels of the cerebral cortex The lesion bears a close resemblance to the defects seen in the base of the brain as the result of concussion Although there was no history of trauma in the cases reported, the author believes trauma to be the most plausible explanation of the pathogenesis of the fissures In none of the cases were there symptoms that could be ascribed to the lesion described

O T SCHULTZ

BACTERIAL LOCALIZATION IN AREAS OF CEREBRAL SOFTENING F QUEDNAU, Beitr z path Anat u z allg Path **83** 471, 1929

In two cases, what appeared to be multiple abscesses of the brain proved on closer examination to be areas of cerebral softening in which secondary localization of bacteria and suppuration had occurred In one case the cerebral infarction was due to arteriosclerosis, and in the other to syphilitic arteritis Each patient had suffered shortly before death with a pneumococcic infection of the lung Pneumococci were cultivated from the blood stream and were seen in sections of the cerebral lesions In one case streptococci were also present in the lesions of the brain In experiments on animals, aseptic injury of the brain was produced by puncturing the skull of rats with a scalpel On the second or third day after the trauma, bacteria were injected intravenously In three animals that received staphylococci and in three that received hemolytic streptococci, no infection of the traumatized brain tissue occurred In one rat that received pneumococci, suppuration of the injured tissue combined with purulent meningitis led to the death of the animal Quednau believes that brain tissue that has undergone softening, either as the result of injury or of infarction, is a focus of lessened resistance and a site of election for the localization of any bacteria which may be present in the blood stream, especially pneumococci He thinks that some of the idiopathic abscesses of the brain and abscesses following trauma to the head but in which no connection between the abscess and injury of the skull can be detected may be due to secondary infection of injured brain tissue

O T SCHULTZ

HEALING OF THE INJURED ARTERIAL WALL A SSOLOWJEW, Beitr z path Anat u z allg Path **83** 485, 1929

Much of the literature on the reparative phenomena of the arterial wall relate to the changes that follow section and suture of arteries, or ligation or crushing In the author's experiments, a procedure was used that did not destroy the elastic tissue, namely, cauterization of the outer surface of the vessel by means of a

red-hot wire The rabbit was used, and the common carotid arteries and the abdominal aorta above the bifurcation were selected for study The vessels were removed for microscopic examination at varying intervals ranging from two to ninety days after the cauterization In the early stages, there is slight polymorphonuclear infiltration of the inner and middle zones of the media and a few polyblasts may be present The author thinks that these cells wander into the tissue from the vessel lumen If the elastic tissue is not destroyed, the reparative phenomena occur chiefly in the media The muscle cells of the media at the margin of the injured area proliferate, and the young cells grow along the surface of the layer of elastic fibers The latter form a compressed and compact layer as the result of the disappearance of original tissue elements from between the fibers The regeneration of the media may be so complete that the site of the injury is difficult to detect If the elastic fibers form such a compact layer that the regenerating muscle cells cannot penetrate between the fibers, a latter replacement of mucle cells by connective tissue occurs If the injury was great enough to cause destruction of the elastic tissue, regeneration of the media does not occur, but the injury is repaired by an ingrowth of fibroblastic tissue from the adventitia The intima may be thickened in the injured area In early stages, proliferation of endothelium is seen, the endothelial cells forming a layer several cells thick Although the author grants the formation of muscle and connective tissue of the intima from the proliferated endothelium, he saw no evidence of such transformation in his material If the elastic layer was not too compact, young muscle cells could be seen to make their way between the fibers to take part in the regeneration of the intima A new formation of elastic fibrils could not be detected in the media, but was seen in the adventitia The process of healing of the injured arterial wall is a very slow one and requires a long time for its completion

O T SCHULTZ

THE CELL REACTION IN LUPUS K. A HEIBERG, Virchows Arch f path Anat **272** 375, 1929

Only in 41 of 100 specimens of lupus were giant cells found and in some of these only few A large number of plasma cells were found in 2, a considerable number in 5 The absence of central necrosis may be due to rapid absorption as well as to lack of its formation The relative amount of epithelioid cells, lymphoid cells and plasma cells and their distribution mainly depends on the age of the lesion and on treatment

ALFRED PLAUT

SYSTEMIC RETICULOSIS O BYKOWA, Virchows Arch f path Anat **273** 255, 1929

An acute infectious disease probably influenza, together with signs of decompensation, brought an obese woman 69 years of age to the hospital She looked anemic and cyanotic Enlarged lymph nodes varying in size up to that of a walnut and even a plum were felt in the axilla and groin They were hard, isolated from each other, but not tender There were 4 per cent eosinophils, 65 per cent lymphocytes and 14 5 per cent monocytes The number of neutrophils decreased, and the monocytes increased to 25 per cent, they were the only form, the absolute figure of which was never below the normal

At autopsy, an enlargement of spleen and lymph nodes was found The lymph nodes were soft, the marrow in the long bones was red and the liver was not enlarged In the lymph nodes many clear cells prevailed which had phagocytic properties In addition, there were round basophil cells with large, round nucleus and many nucleoli The architecture of the lymph node was destroyed, the cells closely enmeshed in a system of fibrils The spleen gave a corresponding picture In the bone-marrow many of these cells contained erythrocytes and pyknotic nuclei Very few granulocytes were left In the tonsils also the lymphatic tissue was atrophic Reticulum cells and basophil cells occupied the whole organ and were found in the neighboring muscle also Smaller accumulations of such cells

were found in other organs The oxidase reaction was negative These results indicated a systemic overgrowth of reticulum cells with atrophy of lymphatic parenchyma In the bone-marrow the erythroblastic system was less damaged than the remainder The disease is regarded as an aleukemic reticulosis The cause is unknown, as it is in the other forms of reticulo-endotheliosis

ALFRED PLAUT

THE HILUS CELLS OF THE OVARY H O NEUMANN, Virchows Arch f path Anat **273** 511, 1929

Negative chrome reaction does not preclude the sympathetic nature of the hilus cells When one kills mice with ether and chloroform, even serial sections do not lead to the detection of any chromaffin cells In decapitated animals, with the same technic, the chrome reaction was negative Guinea-pigs were killed with chloroform during labor after one of the young was born In the young that was born before the administration of chloroform to the mother, the chrome reaction was positive, in the others it was negative

Cells similar to the hilus cells of the ovary are found in the hilus of intestine All these cells are special sympathetic elements which sometimes exhibit more of a paraganglionic character, sometimes more of the character of cells with internal secretion

ALFRED PLAUT

AGGREGATION OF A SPECIAL CELL IN THE MALE GENITALS OF ANIMALS ZENICHI SHIOSAWA, Virchows Arch f path Anat **273** 531, 1929

The cellular mass was found in four of five rabbit testicles when serial sections were made In representative sections they were found in 80 of 287 specimens They were absent in dogs The location was either the septum or the neighborhood of the rete or the connective tissue of the coni vasculosi They occurred with equal frequency in healthy and in diseased rabbits The size varied from 45 to 1,100 microns, their number in one testicle from one to ten The organ is surrounded and occasionally subdivided by connective tissue The cells are polyhedral, round or ovoid, with much cytoplasm which may be granular or vacuolized The cells measure from 7 to 10 microns the nuclei from 4 to 7 microns, they are vesicular, clear, with one or two nucleoli Oxydase, chromaffin substance, epinephrine, Altmann granules, glycogen and fat are absent The cells change rapidly after death They store neither carmine nor india ink The organ can be damaged by feeding the animals hydrous wool fat, by exposing the scrotum to sunlight, and by deficient diet It seems to be more resistant than the testicle In spite of the relatively rare occurrence (28 per cent), it is considered a normal organ Its function is unknown

ALFRED PLAUT

EPENDYMAL EMBRYONIC NEUROGLIOMA OF PINEAL GLAND G L DERMAN and M A KOPILOWITSCH, Virchows Arch f path Anat **273** 657, 1929

The tumor (2 75 by 2 by 2 cm) springs from the commissura habenularum A groove separates a small posterior portion which is the pineal gland Characteristic rosets are found in the tumor The clinical symptoms appeared during pregnancy, receded after delivery, and reappeared with increased intensity in the second month of the following pregnancy About eighty cases of primary tumor of the pineal gland are reported in the literature

ALFRED PLAUT

SOLID TERATOMA AND MEDULLARY OSTEOCHONDROMA OF CORPUS UTERI W MANN, Virchows Arch f path Anat **273** 663, 1929

The literature contains no well established report of intra-uterine teratoma A healthy woman, aged 31 had a prolonged menstruation and, two months later, pain at the onset of menstruation The uterus was enlarged, and in the distended cervix a firm, strawberry-like tumor was felt which was diagnosed as a submucous

myoma but proved to be a teratoid tumor Two months after its removal, bleeding and pain led to hysterectomy

The left tubal angle was the seat of a tumor the size of a small apple It was partly nodular and partly polypoid, the consistency varied There were cysts with different contents The outline against the myometrium was indistinct Microscopically, skin, hairs, glands, bone and cartilage, etc, were found All three germinal layers were represented, most tissues had embryonic character Mesoderm and entoderm prevailed This tumor could not possibly have originated from an ovum of the patient The ovulogenous theory of teratomas probably is erroneous One must, for this uterine teratoma, refer to one form of the blastomeric theory It is unknown why in this instance a solid teratoma had formed and not a dermoid cyst

The second tumor described in this paper was found in a tripara 38 years of age, who had had one breast amputated twelve years before She had a squamous cell carcinoma of the cervix and was pregnant After an unexpected premature labor she had fever for many weeks She received radiation treatment The cervical tumor was a squamous cell carcinoma without hornification

In the right tubal angle an osteochondroma the size of a walnut was situated within the myometrium It was surrounded by a thin layer of firm connective tissue The cartilage was hyalin The ossification partly looked similar to an epiphyseal line The marrow contained few cells, there was no blood formation Germinal misplacement seemed the best explanation

ALFRED PLAUT

PHYSIOLOGY OF CELLULAR RESPIRATION IN ITS RELATION TO NEW HISTOLOGIC OBSERVATIONS ON LEUKOCYTES AND HEART MUSCLE E SEHRT, Virchows Arch f path Anat **273** 701, 1929

Histologic methods that can demonstrate single phases only, not processes, on the other hand, are not subjected to many of the sources of error that may interfere with physiologic work The granules that form a permanent part in the structure of the living cell obviously must be centers of cellular respiration They are the seat of the oxydase reaction, stabile and labile The functional iron of the cell so far has escaped histochemical demonstration except for Katsunuma's observations in the vaginal muscle The lipoid nature of the oxydase granules often has been suggested but never has been proved These granules are identical with the fine granules that one can see under oil immersion in unstained sections of unfixed material Since the beginning of histology (Koelliker), the lipoid character of these granules has been suspected, but never has been proved By means of a modified double sudan stain, Sehrt has succeeded in staining granules of the myeloic cells red with sudan In the polymorphonuclear leukocytes, the protoplasm is full of dark red granules, which, in distribution, shape and size, are identical with the common neutrophil granulation The eosinophil granulations are very distinct The majority of the transitional cells contain red granules which, in size, shape and color, are similar to those of the polymorphonuclear cells They are mainly located at the indentation of the nucleus Thirty-nine per cent of the transitional cells are free of granules Basophil cells show their coarse granules in dark red color, but in addition there are smaller granules, as in the neutrophil leukocyte In normal people, all large mononuclear cells contain many red granules, just as the neutrophil cells do The lymphocytes are entirely free of sudan stained granulations The granules are insoluble in cold alcohol, cold acetone, boiling acetone, cold ether, cold benzine, cold chloroform, they are easily soluble in xylol, in hot absolute alcohol, they slightly dissolve in acetone when left there for a long time

Thus, oxydase granules and these sudanophil granules are identical They are morphologically alike Number and distribution of both kinds of granules in the neutrophil leukocytes are identical The four groups into which Naegeli divides the neutrophil cells, according to their oxydase granulations, can be established for the sudanophil granulations as well

The labile oxydase granules contain lipoid also For their demonstration the author used the following method Frozen sections of unfixed material are spread on the slide and allowed to dry These sections practically never come off the slide and can be used for nearly all staining methods They are not torn, and they do not shrink They do not contain traces of water, they have all the advantages of the paraffin or the frozen section Another modified sudan method is used for the labile oxydase granulation The whole heart muscle appears studded with the fine red granules, which follow not only the lengthwise striation, but the cross-striation also Connective tissue, blood vessels, etc, are entirely free of granules After exposure to fat solvents, the sudan stain is negative

These granules adsorb fatty acids If one puts the dry frozen section into liquid animal fat at a temperature of 40 C and removes the fat mechanically, the granules will stain with any sudan method This experiment becomes negative when dry paraffin section has been in a fat solvent for a few days These observations are in accord with Warburg's physiologic experiments These granules are soluble in absolute alcohol, xylol, ether, chloroform, acetone and benzine They obviously consist of mono-amino-phosphatids The same substances have been found by Meyerhof in ether-alcoholic extracts of heart muscle The granules of the myeloic cells, on the other hand, consist of saturated phosphatids and cerebrosids

Cellular respiration and oxydase reaction are dependent on lipoids The functional iron in the cell must be located on the granules Every granule is an oxidation center with active surface

ALFRED PLAUT

CIRCUMSCRIBED LIPOID DEPOSITS IN THE MUCOSA OF THE STOMACH AND INTESTINE FRIEDRICH FEYRTER, Virchows Arch f path Anat **273** 736, 1929

In 1,300 autopsies, circumscribed lipoid deposits were found twenty-five times in the mucosa of the stomach They are found in between 3 and 10 per cent of persons over 45, depending on the occurrence of atheroselerosis, cholelithiasis and obesity The season seems to play a role also Generally only one island of lipoid cells was found They are easily overlooked in the routine slide It is impossible to say why the lipoid deposits are circumscribed and isolated In the intestine, the lipoid deposits are a little different Only twice in the 1,300 autopsies could they be seen with the naked eye, and in both instances in the duodenum In the intestine, overgrowth of the lipoid cells is found It is absent in the stomach There is no indication of a congenital anomaly at the point of these deposits

ALFRED PLAUT

FOUR CASES OF CONGENITAL OCCLUSION OF INTESTINE HANS NAHRATH, Virchows Arch f path Anat **273** 747, 1929

The fact that between multiple stenoses of small intestine, meconium and lanugo could be found, leads to the conclusion that in this one instance the cause of the occlusion must have come from within the intestine The outer layers and mesenteric vessels were found completely intact, without any angulation or torsion The time when the liver begins to secrete bile is much later than the time when parts of the intestine pass through a solid stage Thus, fetal enteritis is given as a cause for this case of congenital multiple stenoses of small intestine In the three other cases described, disorders in the obliteration and separation of the omphalomesenteric duct had been leading to meconium peritonitis

ALFRED PLAUT

HYPOPLASIA OF CORPUS CALLOSUM IN NEW-BORN INFANTS HEINRICH V HAYEK, Virchows Arch f path Anat **273** 767, 1929

The corpus callosum was half the normal size The brain had been fixed in situ The gyrus cinguli was interrupted and thin, corresponding to the absence of corpus callosum fibers There were no other important anomalies

ALFRED PLAUT

THE LACUNAR RESORPTION OF UNCALCIFIED DENTINE W BAUER, Virchows Arch f path Anat **273** 780, 1929

In the teeth as well as in the bone, the hard substances are entirely passive in the processes of bone formation and of bone destruction Both processes depend entirely on the condition of the surrounding soft parts, notably the blood circulation

ALFRED PLAUT

TRAUMATIC INFLAMMATION INFLUENCED BY X-RAYS SHUICHI FUKASE, Virchows Arch f path Anat **273** 794, 1929

Radiation of an incision in the abdominal skin of a rabbit immediately after making the incision leads to rapid healing Exudation and infiltration are less in the radiated part of the wound In the radiated part, round and spindle-shaped cells with oxyphil granulation are found, cells which are not present in the circulation of the rabbit The author believes that these cells originated in loco He thinks that oxyphil cells which are formed from connective tissue cells generally develop segmentation of the nucleus at the same time, while in his experiment the radiation prevented the segmentation of the nucleus

ALFRED PLAUT

THE ACTION OF LIVER DIET ON PERNICIOUS ANEMIA T FAHR, Virchows Arch f path Anat **273** 864, 1929

Fahr starts from the question why the liver of the patient with pernicious anemia should be unable to furnish the substance which is active in the liver extract or other liver preparation administered by mouth In the livers of fifty patients who died of pernicious anemia, the tissue changes were unimportant, irregular, and showed no relation to the degree of the anemia Great liver destruction, such as occurs in acute yellow atrophy, does not lead to anemia, the red cell count generally is high, and it is doubtful how far the high figures in liver atrophy are due to inspissation of the blood Dogs were fed with raw liver alone, spleen alone, or portal lymph nodes alone The results were quite ambiguous, and the experiments therefore were discontinued These experiments with dogs do not prove much concerning anemia in man, since the iron metabolism in dog and man is quite different Dogs normally show much erythrophagia in the portal lymph nodes In the human portal lymph nodes there is little erythrophagia It becomes much more marked in anemia, never as marked as it is normally in the dog In this connection, Fahr quotes the fact that the blood from patients with anemia inhibits the development of plant germs and that dog blood does that normally Liver therapy in two normal young physicians resulted in a slight increase of red cells and hemoglobin When there is severe damage done to the bone-marrow, as in osteoplastic anemia, the liver diet is ineffectual No relation could be found between the paucity of iron in the spleen and the degree of anemia For the question, how the clinical picture of anemia can be explained by some toxic agent, the funicular myelitis is of great importance There are patients with marked funicular myelitis and relatively little anemia In rare instances a patient dies of the myelitis, and the blood picture, and the autopsy findings are hardly sufficient for a diagnosis of pernicious anemia The anemia itself cannot be due to a toxic factor, and the liver diet probably acts as a substitution therapy in a similar way as vitamin feeding works in scurvy

ALFRED PLAUT

OSTEITIS DEFORMANS (PAGET) ERNST FREUND, Virchows Arch f path Anat **274** 1, 1929

Several problems were studied in sections from the femur of a 71 year old woman who had been in bed for eight years after fracture of the neck of femur The femur partly was normal, and the beginning phases of Paget's disease could be studied In the process of destruction of the old tela ossea, fibrillar marrow

hollows out the old trabeculae, between which, however, the old fatty marrow remains Under the periosteum, a layer with thin, mostly noncalcified trabeculae of reticular bone is situated, the author calls it the parosteal layer The Paget bone becomes thicker by a kind of parosteal callous formed in the parosteal layer No osteoblasts participate in this process There were changes in the joint cartilage which did not completely correspond to the picture of deforming arthritis

ALFRED PLAUT

OSTEOGENESIS IMPERFECTA AND ENDOCRINE SYSTEM ERIK JOHANNES KRAUS, Virchows Arch f path Anat **274** 37, 1929

In two instances of osteogenesis imperfecta no signs of premature development of the endocrine glands could be found

ALFRED PLAUT

SYSTEMIC ANGIOPLASTIC SARCOMA IN SPLEEN, LIVER, AND BONE-MARROW WALTHER SCHLOPSNIES, Virchows Arch f path Anat **274** 85, 1929

The tumor in its main features corresponds to the hemangio-endothelioma as described by B Fischer-Wasels The patient was a woman 38 years old, her previous history was irrelevant After her second delivery about three months before admission she felt tired, had no appetite, and complained of swelling of the legs She became progressively weaker, was pale, but had no pain An area of massive dulness occupied the left lower part of the thorax, the whole left side of the abdomen was occupied by the enlarged spleen The long bones and the sternum were tender on percussion The blood contained many normoblasts, among the 7,000 leukocytes, 5 per cent were myelocytes, 5 per cent young forms

The enlarged spleen (2,600 Gm) was fixed by adhesions, it was firm, the cut surface was irregularly gray and red, with many hemorrhages and some reddish gray, wedgeshaped foci under the capsule The bone-marrow was red throughout Many round, cyanotic foci were found in the bone-marrow The liver also contained countless, mostly round, well outlined nodules, the smallest ones hardly visible, the largest ones the size of a walnut

Microscopically, the tumors consisted of spindle-shaped elements with very dark, large nuclei These cells formed blood vessel-like spaces and in other areas accumulated into sarcoma-like masses All gradations, from the normal endothelial cell to the tumor cell, could be seen Single large tumor cells were found in otherwise normal capillaries In the spleen, most of the normal structure was destroyed There were large areas of necroses, the tumor was mostly sarcoma-like Mitotic figures were not very frequent Large blood spaces were formed by the tumor cells, their walls were free from elastic fibers Occasionally, small foci of blood formation were seen

In the bone-marrow, the picture was different Very little normal bone-marrow was found The tumor, which had replaced the bone-marrow, mainly consisted of thinner spindle cells, partly with wider blood spaces

This tumor cannot be explained by metastasis from a single primary focus There was a diffuse, tumorous change of the endothelium in liver, spleen and bone-marrow The other organs were free There are cases in the literature in which other organs, like the thyroid, for instance, show the same tumor The cause of the tumor is unknown, one has to assume a disturbance in the embryonic "Anlage" of the endothelial system This is a disease of the endothelial cells alone The reticulum cells are not involved

ALFRED PLAUT

AMYLOIDOSIS OF KIDNEY IN CATTLE T PRIMGAARD, Virchows Arch f path Anat **274** 111, 1929

The so-called parenchymatous chronic nephritis in cattle is primarily an amyloidosis of kidney complicated by interstitial and parenchymatous inflammation

In a few instances, amyloidosis could be produced in mice and rats by injection with bacteria cultivated from the cattle, but one animal only showed amyloidosis of the kidneys

ALFRED PLAUT

ISOLATED AMYLOIDOSIS OF SEMINAL VESICLES O LUBARSCH, Virchows Arch f path Anat **274** 139, 1929

General amyloidosis seldom reveals amyloid deposits in the seminal vesicles The amyloid then is found mostly in the walls of blood vessels In the few instances of isolated amyloidosis of seminal vesicles, the deposits were situated between epithelium and propria, as found in a man 49 years old who died of lymphatic leukemia No explanation of this isolated amyloidosis can be given

ALFRED PLAUT

CALCIFICATION OF THE MYOCARDIUM IN DOMESTIC ANIMALS W S TSCHERNIAK and S VORONZOV, Virchows Arch f path Anat **274** 154, 1929

Calcification of myocardium, mostly in the papillary muscles of the left side of the heart, is not rare in horses and dogs The inflammatory reaction obviously is secondary to the calcification It is interesting that in four dogs which died of distemper, such calcification was found

ALFRED PLAUT

NUTRIENT VESSELS OF AORTA H SMETANA, Virchows Arch f path Anat **274** 170, 1929

The distribution of nutrient vessels of aorta was studied by injection of the whole thorax Tandler's cold gelatin solution with prussian blue was used A detailed description of the vessels is given, illustrated with thirteen drawings Anastomoses of larger arterial branches are rare One generally can distinguish three portions of the thoracic aorta first, the lower half of the aorta ascendens, which receives its blood from the coronary arteries, second, the portion up to the origin of the left subclavian artery, and third, the descending portion The distribution of the syphilitic aortitis cannot be sufficiently explained by the distribution of the vasa vasorum The fact that a disease which has such a different cause as, for instance, the filaria aortitis of the dog, has the same distribution, speaks against any important role of the vasa vasorum, especially since the distribution of the vessels in the dog is quite different from that in man

ALFRED PLAUT

Pathologic Chemistry and Physics

THE RELATION OF PARTICLE SIZE TO MECHANISM OF DYE EXCRETION BY THE KIDNEY J OLIVER and E SHEVKY, Am J Physiol **93** 363, 1930

There is a correlation between the degree of filtrability of a series of dyes and the mechanism of their elimination as studied in the perfused kidney of the frog Easily filtrable dyes, of small particulate size, pass readily through the glomerular membrane, those of moderate size are discharged by tubular activity, and those of large size cannot be eliminated

H E EGGERS

IS IT POSSIBLE TO PRODUCE PERMANENT CHANGE IN THE ACID BASE BALANCE? M MECKLENBURG, Beitr z Klin d Tuberk **73** 232, 1929

No clinical or experimental method is known at the present time by which a permanent change in the acid base balance can be produced without endangering the life of the organism

MAX PINNER

THE DIFFERENTIATION OF THYROXIN IODINE FROM INORGANIC IODINE BY THE MEMBRANES OF THE LIVING ORGANISM W LIPSCHITZ, Klin Wchnschr **9** 642, 1930

Dogs endured large single doses (20 mg per kilogram of weight) of thyroxin intravenously, most of it was found in the plasma The initial concentration (from 5 to 6 per cent I) decreased within one or two days to less than one-tenth without appreciable amounts passing into the urine Little, if any, of the circulating thyroxin is secreted by the stomach and the parotid Small amounts are split into iodides, which then appear in gastric and parotid secretions The gland membranes of the living organism fractionate the various iodine compounds in the blood so that a determination of the iodine content of the gastric juice or the parotid secretion enables the approximation of the circulating iodide of the blood It approaches about one-tenth and may be more closely determined by testing in each individual the concentrating power of the glands, following the intravenous injection of small amounts of iodide

EDWIN F HIRSCH

CHEMOTAXIS OF LEUKOCYTES C HABLER and C WEBER, Klin Wchnschr **9** 760, 1930

Experiments by the Pfeiffer method demonstrated that chemotaxis parallels the surface tension activity of the test solution and that changes of the actual reactions and of the osmotic tension have no effect No specific action of the cations of the alkali and earth metals was demonstrated The differences in chemotaxis of various organic acids disappears when their solutions are brought to the same surface tension

EDWIN F HIRSCH

PHENOL IN THE BLOOD IN CIRRHOSIS OF THE LIVER E BECHER, Munchen med Wchnschr **77** 751, 1930

Moderate increase of phenol in the blood and especially the presence of free phenol in the blood occur in many cases of cirrhosis of the liver These results suggest a disturbance in the detoxication of intestinal products in cirrhosis of the liver

AUTHOR'S SUMMARY

CHOLESTEROL CONTENT OF BLOOD AND BLOOD SERUM IN PULMONARY TUBERCULOSIS F WARNECKE, Ztschr f Tuberk **56** 137, 1930

In minimal and moderately advanced tuberculosis, the cholesterol content of the blood is found within normal limits In far advanced and toxic conditions, the cholesterol is decreased The decrease in cholesterol is not specific for tuberculosis, but occurs in all infectious diseases that produce cachexia

MAX PINNER

Microbiology and Parasitology

INTRANUCLEAR INCLUSIONS IN YELLOW FEVER E V COWDRY and S F KITCHEN, Am J Hyg **11** 227, 1930

Cytologic studies on the intranuclear inclusions in experimental yellow fever in monkeys and in human beings would seem to show that the nuclear response in yellow fever is of the same general type, though different in detail, as that which occurs in many other virus diseases, especially chickenpox, herpes, virus III disease and submaxillary disease

JOHN PHAIR

THE LOCATION OF YELLOW FEVER VIRUS IN INFECTED MOSQUITOES AND THE POSSIBILITY OF HEREDITARY TRANSMISSION NELSON C DAVIS and RAYMOND C SHANNON, Am J Hyg **11** 335, 1930

Yellow fever virus has been demonstrated in the head, thorax and abdomen of mosquitoes before the bites are infective Transmission has been secured by the inoculation of legs, ovaries, salivary glands, midguts and hindguts of infected

Aedes aegypti No transmission has been obtained from the inoculation of hemocelic fluid or of mouth parts of infected mosquitoes Virus is occasionally present in the dejecta from infected mosquitoes No definite transmission has been secured from the inoculation of eggs laid by infected mosquitoes No evidence has been obtained that virus ever passes from one generation of mosquitoes to the next through the eggs (hereditary transmission) No transmission has been accomplished by adults bred from larvae which had consumed large numbers of infected mosquitoes

AUTHORS' SUMMARY

AN EPIDEMIC OF INFLUENZA IN AN ISOLATED COMMUNITY—NORTHWEST RIVER, LABRADOR W G SMILLIE, Am J Hyg **11** 392, 1930

An epidemic of influenza occurred in Northwest River, an isolated community in Labrador, in 1928 The date of introduction of the disease into the community was known and it was possible to trace the epidemic throughout its course It seems probable that the virulence of the infective agent remained fixed, and the dosage was uniform There occurred, however, a marked variation in resistance of various individuals to infection It seems probable that this resistance was nonspecific The infective agent disappeared completely from the community in a short time, for a presumably highly susceptible group of Indians entered the community one month after the last case had occurred and none of them was affected

AUTHOR'S SUMMARY

PARATYPHOID—ENTERITIDIS MENINGITIS FRANK B LYNCH, JR, and SAMUEL A SHELBURNE, Am J M Sc **179** 411, 1930

A review of the literature reveals fifteen previous cases of meningitis from which bacilli of the *paratyphoid-enteritidis* group were isolated, and a sixteenth case is here reported Most of the cases occurred in children All the patients aged a year or less died, including the author's patient In most of the cases the fluid was purulent, or showed a predominance of polymorphonuclear neutrophils In all the previously reported cases in which blood culture was made, it was positive In our case postmortem blood culture was negative

AUTHORS' SUMMARY

TRICHOMONAS VAGINALIS C H DAVIS, Am J Obst & Gynec **18** 575, 1929

Davis finds that these organisms may be killed when exposed in a water bath to 46 C for ten minutes They likewise are destroyed by exposure to cold (9 C) for twelve hours

A J KOBAK

LESIONS OF FOWL-POX AND VACCINIA C EUGENE WOODRUFF, Am J Path **6** 169, 1930

The histology of lesions obtained in chick epithelium following inoculation with vaccinia virus alone, fowl-pox alone and the two viruses mixed is described The characteristic virus bodies of fowl-pox, whether occurring in the skin or the cornea of the chick, give a positive reaction for fat The Guarnieri bodies of vaccinia do not stain for fat Ludford's statement regarding the identity of the virus bodies of vaccinia and fowl-pox in the chick is refuted His observations are due, it is believed, to the utilization of tissue from a mixed lesion of fowl-pox and vaccinia

AUTHOR'S SUMMARY

TRANSMISSION OF DENGUE VIRUS FROM INFECTED TO NORMAL AEDES AEGYPTI JOE H ST JOHN, JAMES STEVENS SIMMONS and FRANCOIS H K REYNOLDS, Am J Trop Med **10** 23, 1930

It is possible to infect normal *A aegypti* with dengue by feeding them through a guinea-pig's skin on a mixture of blood and macerated dengue-infected mos-

quitoes Mosquitoes fed on this mixture later produced dengue fever in two human volunteers This method should prove helpful in the study not only of dengue, but also of other virus diseases transmitted by insects

AUTHORS' SUMMARY

PARASITES IN THE BLOOD OF WILD MONKEYS OF PANAMA HERBERT C CLARK, Am J Trop Med **10** 25, 1930

Ten varieties of monkeys are found in the Republic of Panama Four of these are included in this survey, *Ateles geoffroyi, Cebus capucinus-imitator, Saimiri oerstedii-oerstedii* and *Alouatta palliata-inconsonans* Tertian-like and quartan-like malarial parasites, microfilaria and trypanosomes were found in the blood of these monkeys Autopsy of these monkeys revealed adult *Filaria* in the abdominal cavities of the red spider and white throated species, but no adults were found in the cavities of the Titi monkeys An adult female monkey *(Macacus rhesus)* was inoculated with defibrinated blood of sixty monkeys, twenty-four of which showed signs of malarial infection This female, however, presented no signs of illness, no elevation of temperature and no parasites in the blood for a period of six weeks following inoculations No trypanosomes have been seen although she was inoculated with positive blood from three species Guinea-pigs also failed to show trypanosome infection The monkey should be a better animal than the bird for research work in malaria since it supplies a larger volume of blood, a type of red blood cell more closely resembling man's and species of *Plasmodii* that are difficult to distinguish from the benign species found in man Some attempts at transfer of monkey malaria to man have failed in the Eastern hemisphere, yet it would seem proper to repeat this work in Panama if an infant monkey with an acute initial infection can be taken alive Similar efforts with the trypanosome should be made with the horse

JOHN PHAIR

TUBERCULOUS INFECTION IN SCHOOL CHILDREN E FINGER, P M MATTILL and E PHELAN, Am Rev Tuberc **21** 183, 1930

The incidence of tuberculous infection in school children in rural Hennepin County, Minnesota, is much lower than that usually reported The "questionable positive" group may represent an infection that is of such low grade that it gives no appreciable reaction or it may represent a once active infection that is dying out The markedly positive group represents those cases having received recent or repeated infections The high incidence of tuberculous infection in contact cases is again shown Malnutrition does not seem to predispose to infection nor does it necessarily follow after infection has taken place X-ray plates are essential in determining pulmonary involvement in infected cases, there is not a complete correlation between the positive reactors and the x-ray film, nevertheless, the x-ray film gives much valuable information and should be taken in at least all of the positive reactors

H J CORPER

THE DISAPPEARANCE OF SCROFULA H R M LANDIS, Am Rev Tuberc **21** 195, 1930

The author compares his observations of the incidence of scrofula at the end of the last century and at the present time and notes particularly that in the Episcopal Hospital in Philadelphia there were 136 cases of scrofula in 1900, while in 1928 there were 27 and only 8 of these occurred in children In the Jefferson Medical College Hospital in 1900 there were fifty-four cases, while in 1928 only twenty were recorded and seven of these occurred in children He cites numerous other statistics to indicate that both scrofula and tuberculous adenitis showed a decided decline

H J CORPER

FORTY STRAINS OF YEAST-LIKE FUNGI FROM SPUTUM W D STOVALL and ANNA A BUBOLZ, J Infect Dis **45** 463, 1929

Forty strains of yeastlike fungi isolated from sputum are reported in this study They fall into four genera giving characteristic differences on culture mediums *Monilia, Oidia, Endomyces* and *Saccharomyces* *Monilias* comprise the largest group—thirty-seven strains Of the others only one strain of each kind was encountered All the organisms showed constant cultural reactions over a period of two years On the basis of these observations, viz —sugar fermentation and colony formation on malt agar in forty-eight hours at 37 C incubation, we have been able to recognize three distinct types of *Monilia* The results of animal inoculations were variable

AUTHORS' SUMMARY

EPIZOOTIC LYMPHADENITIS IN GUINEA-PIGS DUE TO AN ENCAPSULATED MUCOID HEMOLYTIC STREPTOCOCCUS JOHN SUMTER CUNNINGHAM, J Infect Dis **45** 474, 1929

An epizootic of lymphadenitis affecting a small number of guinea-pigs has been described The disease frequently terminated as a septicemia following superimposed experimental laboratory infections The inciting organism in each case was an encapsulated hemolytic streptococcus of the B type, having large mucoid, mucilaginous colonies on blood agar All strains of this streptococcus were culturally and serologically identical In transfers from broth cultures and from cultures treated with a bacteriophage the colony changed to a small granular rough type This dissociation of the strain occurred spontaneously and was apparently aided by the presence of bacteriophage Serial lysis was not produced Agglutinins for this streptococcus were found in high titer in a guinea-pig affected with typical "lumps," having large abscesses of the cervical nodes Similar agglutinins were commonly present, though in lower titer, in the serum of normal rabbits Rabbits given intravenous injections with washed (in salt solution), killed streptococci produced specific agglutinins in high titer The titer was partially sustained for two months after the last injection The lymphadenitis, although in a somewhat more acute form, was reproduced experimentally in guinea-pigs by subcutaneous injections of this streptococcus The organism was highly virulent for rabbits and mice, killing these animals in from two to four days

AUTHOR'S SUMMARY

METABOLISM OF THE ABORTUS-MELITENSIS GROUP JAMES G MCALPHINE, WAYNE N PLASTRIDGE and GEORGE D BRIGHAM, J Infect Dis **45** 485, 1929

When grown on plain Fairchild peptone agar for several generations *Bacterium melitensis* and the porcine and human strains of *Bacterium abortus* tend to lose their ability to utilize dextrose Growth on liver infusion agar, plain agar, nutrient broth or dextrose broth fails to restore completely this lost characteristic Three transfers in liver infusion broth with continued incubation at 37 C for two weeks caused these strains to develop a new form (mucoid) in which the dextrose-utilizing power was restored The mucoid forms of the bovine strains tested did not utilize dextrose

AUTHORS' SUMMARY

VIBRIOTHRIX TONSILLARIS N SP THE ORGANISM OF ACTINOMYCES-LIKE TONSILLAR GRANULES RUTH TUNNICLIFF and LEILA JACKSON, J Infect Dis **46** 12, 1930

From an actinomyces-like tonsillar granule a second strain of *Vibriothrix tonsillaris* has been isolated in pure culture, which produces roset and test tube brushlike forms similar to those seen in the original material This strain is characterized by the production of masses of ovoid and irregular bodies and

filaments, which stain pink with Giemsa, from which bacilli and filaments appear to originate, and around which the stars and test tube brush forms seem to develop This *Vibriothrix* produces lesions in the lung, bone and skin of rabbits and from the latter the organism was isolated in pure culture AUTHORS SUMMARY

THE TWO VIRUSES IN ENDEMIC TYPHUS (MEXICAN TABARDILLO) JOSE ZOZAYA, J Infect Dis **46** 18, 1930

The scrotal lesion produced in the guinea-pig, by the injection of endemic North American typhus, is not of typhus origin The Rickettsia-like organisms found in the epithelial cells of the scrotal lesions in the guinea-pig have nothing to do with the production of typhus in the human being or in the animal There are often two different viruses in the blood of patients with endemic typhus (typhus not transmitted by the louse), one the specific virus of typhus, and the other a virus pathogenic for the guinea-pig, producing in this animal scrotal lesions The scrotal lesion-producing virus is transmissible, nonpathogenic for man, and has a short incubation period (two to four days) after being adapted to animal passage

AUTHOR'S SUMMARY

THE ACTION OF PANCREATIC JUICE ON BACTERIA ALEXANDER A DAY and WILLIAM M GIBBS, J Infect Dis **46** 26, 1930

Pancreatic secretion obtained directly from the pancreatic duct by the aid of secretin was consistently sterile while that collected in a balloon usually contained a few bacteria These contaminants are not normal inhabitants of the pancreatic duct and may be regarded as opportunists The fresh juice, that secured by the secretin method, killed the bacteria tested, with the exception of *Staphylococcus aureus*, within forty-eight hours and was more effective than that gathered by the balloon method In only one instance was digestion of the organisms noted While *B tuberculosis* was killed by the pancreatic juice no evidence of dissolution of the cells or loss of acid-fast property was observed Pancreatic secretion activated with enterokinase was no more bactericidal than the normal juice Pancreatic juice diluted with salt solution or bile, or made acid, was ineffective against bacteria The foregoing experiments indicate that the pancreatic juice of the dog has bactericidal properties which may not be great yet may play a part in the normal defense of the pancreas against infection

AUTHORS' SUMMARY

ACUTE ANTERIOR POLIOMYELITIS AT VEGA BAJA, PORTO RICO E GARRIDO MORALES, J Infect Dis **46** 31, 1930

Reports of epidemic poliomyelitis in the tropics are rare Poliomyelitis has probably existed in endemic form in Porto Rico for some time, it has not been recognized or, at least, the cases and deaths have not been reported as such No epidemic of the disease has ever been reported in Porto Rico before 1928 Poliomyelitis appeared in epidemic form (ten cases, one death) in the town of Vega Baja during April, May and June, 1928 The evidence strongly suggests that indirect personal contact played a major part in the spread of the disease Apparently, the virus responsible for the present outbreak was not introduced from outside, but from a local source, presumably represented by cases which had occurred two years before in Vega Baja

AUTHOR'S SUMMARY

ATTEMPTS TO PRODUCE ACUTE GLOMERULONEPHRITIS IN RABBITS WITH THE PERITONEAL LYSATE OF STREPTOCOCCUS SCARLATINAE ALLAN F REITH, LOUIS M WARFILLD and NORBERT ENZEK, J Infect Dis **46** 42, 1930

In an attempt to repeat the work of Duval and Hibbard on experimental production of acute glomerulonephritis in rabbits we were unable to produce in the peritoneal cavity of immune rabbits a sterile bacteriolysate containing the alleged

endotoxic principle of scarlatinal streptococci Rabbits given intravenous injection of the filtered or centrifugalized peritoneal fluid of previously immunized rabbits which were given an intraperitoneal mass dose of homologous scarlatinal streptococci from two to three hours before the peritoneal fluid was drawn, did not show symptoms of toxemia At necropsy the kidneys of some of these rabbits had lesions resembling some of the lesions described by Duval and Hibbard and which they claimed to be the result of acute glomerulonephritis of the scarlet fever type However, similar lesions were observed by us in the kidneys of normal healthy rabbits and rabbits given injection with bacterial suspension other than scarlatinal streptococci None of our rabbits showed lesions typical of scarlet fever nephritis

AUTHORS' SUMMARY

THE INCIDENCE OF MIDDLE EAR INFECTION AND PNEUMONIA IN ALBINO RATS AT DIFFERENT AGES JOHN B NELSON and JOHN W GOWEN, J Infect Dis **46** 53, 1930

Data are presented on the incidence of middle ear disease and pneumonia in a colony of albino rats originally established from pneumonia-free breeders and maintained on a balanced diet The rates of both infections were high in adult rats (1 year and over) In young rats (3 to 4 months) there was a significant but unsymmetrical decrease in the incidence of the two conditions The respective rats for middle ear infection were 69 and 32 per cent, for pneumonia 81 and 2 per cent A group of wild rats (approximately 6 months to 1 year) showed 1 per cent middle ear infection and 10 per cent pneumonia Fifty per cent of the adult rats with middle ear disease had a concurrent inflammation of the nasopharynx while less than 1 per cent of the young rats were similarly affected The relation between middle ear infection, pneumonia and inflammation of the upper respiratory tract is discussed

AUTHORS' SUMMARY

THE BACTERIA OF THE INFECTED MIDDLE EAR IN ADULT AND YOUNG ALBINO RATS JOHN B NELSON, J Infect Dis **46** 64, 1930

The bacterial flora of the middle ear in natural infection in a group of adult albino rats on a balanced diet was found to embrace a wide variety of microorganisms in pure or mixed culture *B actinoides,* streptococci and a diphtheroid were most often encountered in the order named In a group of infected young rats from the same colony there was a greater incidence of sterile cultures There was likewise a varied bacterial flora which included a diphtheroid, streptococci and *B actinoides,* in the order of their isolation Aside from *B actinoides* and two species of low incidence, all of the bacteria from the middle ear were either observed in direct films or isolated in culture from the nasopharynx of normal young rats The bacteriologic results are discussed in relation to the etiology of middle ear disease

AUTHOR'S SUMMARY

HEAT RESISTANCE OF THE SPORES OF CLOSTRIDIUM BOTULINUM E W SOMMER, J Infect Dis **46** 85, 1930

Spores of *Cl botulinum* have been prepared in different mediums under various conditions and heated in phosphate solution of p_H 7 at 100 C for time intervals of from one-half to five hours The survivals were determined by subculturing in beef heart medium Spores grown in 4 per cent peptone showed a resistance of from one and one-half to two and one-half hours The addition of phosphate raised the heat tolerance to four hours, the effect, however, was not constant The addition of dextrose and the increase in concentration of peptone raised the number of organisms but not the resistance After testing numerous substrates a standard casein-digest medium supplemented with Liebig's meat extract was selected as most favorable for the routine production of *Cl botulinum* spores A

yield of from 200,000,000 to 500,000,000 spores per cubic centimeter was obtained with a uniformly higher resistance than in any other medium tested Different lots of casein medium prepared under similar conditions vary in their ability to produce heat resistant organisms The same lot of medium has consistently yielded identical results Supplementing with different electrolytes, sand, dextrose, olive oil, protein or vegetable extracts did not improve the basic substrate Of the fifteen strains tested sixty-two and nineteen type A, gave the most resistant spores Attempts to increase the resistance by selection failed Incubation temperatures of 28, 37 and 41 C showed little influence on the heat resistance of the organism The most resistant organisms have been found in four to eight day cultures The degree of anaerobiosis had no evident effect on the heat resistance of the spores The apparent heat resistance of a spore suspension increases with its density up to approximately 1 billion per cubic centimeter, beyond this limit it may be considered constant Spores preserved in their own liquor in the icebox and in a dry state usually deteriorate on standing Numerous products, however, have remained constant over periods of four months From the distribution curves plotted from forty-six resistance experiments on small spore samples an average heat tolerance of from four to four and one-half hours is shown When the results from forty-four pools prepared by the Sharples centrifuge are considered two maxima, at three and one-half and five hours, are evident

AUTHOR'S SUMMARY

A CULTURAL STUDY OF CERTAIN ANAEROBIC BUTYRIC-ACID-FORMING BACTERIA ELIZABETH MCCOY, E B FRED, W H PETERSON and E G HASTINGS, J Infect Dis **46** 118, 1930

The butyric anaerobes of fermentation form a subgroup of the genus *Clostridium*, they are characterized by their production of acids or of characteristic neutral products in addition All are granulose-positive, catalase-negative and nonpathogenic Two general types have been recognized Group 1 produces acid end-products, chiefly acetic and butyric acids Of these so-called "true butyric" anaerobes three subtypes have been studied *Cl pasteurianum* type, *B saccharobutyricus* type, and five special *plectridia* (cultures 29 to 33 inclusive) Group 2 produces butyric and acetic acids and the neutral products, butyl and ethyl alcohols and acetone These are the butyl organisms of industry, *Cl acetobutylicum* Weizmann There are certain facultative organisms related to the true anaerobes In general they produce acetic acid, ethyl alcohol and sometimes acetone, but no butyric acid *Aerobacillus polymyxa* Prazmowski from Donker is the only representative studied here The general morphologic and cultural characteristics of butyric, butyl and related facultative organisms have been studied Some important differences have been noted Because adequate quantitative studies of the fermentation products have not been attempted, the authors prefer to leave the final classification of the organisms till a future time At this time three physiologic types of the butyric anaerobes are distinguished *Cl pasteurianum* type, *B saccharobutyricus* type and a *plectridial* type in some respects like the butyl organism, *Cl acetobutylicum* Weizmann

AUTHORS' SUMMARY

RESULTS OF BLOOD CULTURE IN ACUTE POLYARTHRITIS EDWIN P JORDAN and JOHN P BOLAND, J Infect Dis **46** 148, 1930

Minute bacilli much like those described in this paper have been obtained from the blood and other tissues in many different conditions (Sellards and Bigelow, Mellon, and others) It is also well known that organisms probably wholly unrelated to a disease may be present from time to time in the blood stream Hence the relationship between organisms found in the blood stream and the disease process in question is only presumptive Nevertheless, an association which occurs frequently enough in a certain disease, and which does not occur in other diseases, is sufficiently suggestive to warrant consideration The classifica-

tion of rheumatic conditions is in a state of chaos and it seems possible that further studies may reveal several etiologically distinct groups at present undifferentiated The unusual frequency with which we have obtained minute bacilli from the blood of patients with acute polyarthritis is worth noting

AUTHORS' SUMMARY

RELATION OF PELLICLE FORMATION AND TOXICOGENICITY IN DIPHTHERIA CULTURES RALPH H HEEREN, J Infect Dis **46** 161, 1930

That a definite correlation exists between pellicle and toxicogenicity is shown by the fact that eighty-nine of the 100 toxicogenic colony cultures produced a definite and characteristic pellicle on Wadsworth's medium to which they had become habituated by means of a series of transfers carried over a forty-five day interval That the pellicle is not necessary for formation of a strong toxin is shown by the fact that the remaining eleven of the 100 toxicogenic colony cultures, carried through the same growth and test conditions, were consistently apellicular That the increase in toxicogenicity was due to habituation of the cultures to the medium rather than to increased degrees of pellicle formation is shown by the fact that the apellicular forms demonstrated increases similar to those of the pellicular forms On the other hand it has been shown that pellicle formation in diphtheria cultures does not determine toxicity, since six of fifteen cultures (proved atoxicogenic by two methods) showed pellicles regularly

AUTHOR'S SUMMARY

EXPERIMENTAL TRANSMISSION OF ENDEMIC TYPHUS OF THE SOUTHEASTERN ATLANTIC STATES BY THE BODY LOUSE H MOOSER and CLYDE DUMMER, J Infect Dis **46** 170, 1930

The virus of typhus from the southeastern Atlantic States is able to survive and multiply in the body louse The louse, therefore, must be considered as a possible factor in the epidemiology of typhus in southern United States

AUTHORS' SUMMARY

FILTRABILITY OF VIRUS OF PSITTACOSIS IN BIRDS CHARLES ARMSTRONG G W McCOY and SARA E BRANHAM, Pub Health Rep **45** 725, 1930

Experiments are reported the results of which indicate that the causative agent of psittacosis in birds is filtrable

RICKETTSIA-LIKE INCLUSIONS IN PSITTACOSIS LESIONS R D LILLIE, Pub Health Rep **45** 773, 1930

The lesions seen in three parrots associated directly or indirectly with human cases of psittacosis are described and briefly compared with those in a human case Minute intracellular inclusions are described in human lesions and in the lesions in the parrots, and the name *Rickettsia psittaci* is proposed for them The evidence of a laboratory outbreak of the disease indicates that the virus (sensu lato) of psittacosis was present in some of the birds under investigation

AUTHOR'S SUMMARY

ACCIDENTAL PSITTACOSIS INFECTION AMONG THE PERSONNEL OF THE HYGIENIC LABORATORY G W McCOY, Pub Health Rep **45** 843, 1930

Of eleven cases (between January 25 and March 15, 1930) two occurred in persons handling infected birds, one in a person who worked only with cultures from infected birds, but none of the eight remaining cases could be traced to any recognizable source of infection All of these persons, however, worked in the building in which the work on psittacosis was carried on in certain rooms to

which only those engaged in the work had access The usual precautions employed in studies of dangerous infections were carried out These examples of infection through the medium of contaminated environment without contact with infected birds suggest "that the infectiveness of the virus of psittacosis for man is of a very high order"

A New Meningococcus-Like Organism from Epidemic Meningitis Sara E Branham, Pub Health Rep **45** 845, 1930

During an epidemic of cerebrospinal meningitis in which all four of the usual types of meningococci were involved, an apparently new form was isolated from the spinal fluid of fourteen cases In morphology this micro-organism is indistinguishable from the other members of the genus *Neisseria* It differs from the meningococcus in pigment production, lack of fermentative action and antigenic relationship These fourteen strains form a homogeneous group culturally, biochemically and serologically The name *Neisseria flavescens* n sp is proposed for this new form Since 30 per cent of the spinal fluid strains received from this locality belong to this group (comprising 9 per cent of the total number of strains received at the Hygienic Laboratory during 1928-1929), since it is not represented in any of the therapeutic polyvalent serums now manufactured and since the mortality in these cases was at least 30 per cent, the occurrence of *N flavescens* in epidemic meningitis warrants special attention

A Bacteriological and Experimental Study of Cholecystitis A C Nickel and E S Judd, Surg Gynec Obst **50** 655, 1930

Green-producing streptococci, gram-negative bacilli and staphylococci were isolated from the majority of acutely or subacutely inflamed surgically removed gallbladders Cultures from the "strawberry" and chronically infected bladders were found to be sterile in most instances, unless there was a complicating factor The streptococci obtained were capable of producing the disease in rabbits when injected intravenously

Richard A Lifvendahl

Treatment of Experimental Tuberculosis by Calcium Administration J C Hoyle, Quart J Med **22** 451, 1929

The experiments give no support to the view that the oral administration of calcium has any beneficial effect on tuberculosis Likewise, the intravenous administration of calcium had no beneficial effect Rabbits were inoculated with a virulent bovine strain and were then given intravenous injections of calcium chloride As many as forty-eight injections were given The average length of survival after inoculation in control rabbits was fifty days, in treated ones, forty-six days At postmortem examination no differences were noted in either the extent or the character of the disease in the two series

N Enzer

After-Results of Gassing and Gunshot Wounds of the Chest in Relation to Tuberculosis G Basil Price, Tubercle **11** 97, 1929

While "gassing" appears to bear a relatively unimportant part on the incidence of tubercle, in gunshot wound injuries of the chest (all types, surface and penetrating) the incidence of pulmonary tuberculosis forms a small but appreciable percentage of not less than 0 5 This is more than double that occurring among the civil population If the relative incidence of pulmonary tuberculosis could be applied to men suffering from only penetrating injuries of the chest, this percentage of 0 5 would in all probability be considerably exceeded When the pulmonary tissue has been definitely injured, and especially when a foreign body is retained in or near the damaged area, activation of tubercle may occur in the organ affected, even at an indefinite period later

H J Corper

IS THE VIRUS OF TRACHOMA FILTRABLE? M C TRAPESONTZEWA, Ann d'ocul **167** 160, 1930

Trapesontzewa obtained trachomatous material in large quantities and filtered it with the least possible addition of salt solution Blind human subjects were used for a part of the experiments From material procured by scraping, excision and expression and by trituration with but a few drops of physiologic solution of sodium chloride, she obtained a filtrate, using tiny filters specially made in Germany Inoculations were made by subconjunctival injections or instillations into the scarified conjunctiva Not a trace of a follicle was found In one experiment the author herself was the subject The material was taken from twelve florid cases and inoculated by two ophthalmologists Within about thirty-six hours the edema of the upper lid, as well as the conjunctival injection, disappeared Two weeks later the other eye was inoculated, after scarification of the conjunctiva, and a portion of the filtrate was inoculated, subconjunctivally, into the first eye Within a few days the mild inflammation was gone A month later a filtrate was made from the material obtained from twenty-four trachomatous lids that had never been treated Subconjunctival injection and instillation into the scarified conjunctiva were made, and the conjunctiva was examined every day The last examination, made six months later, revealed neither granulations nor follicles The author concludes that the virus of trachoma is nonfiltrable

CHARLES WEISS

CONDITIONS REQUISITE FOR THE PRODUCTION OF LOCAL IMMUNIZATION IN INFECTIONS OF THE EYE L POLEFF, Arch f Augenh **102** 722, 1930

It has been demonstrated that certain tissues of the eye, especially the bulbar conjunctiva, the cornea and the anterior chamber, can produce local specific antibodies, and this function is of special significance in those infections that stand out because of their strong ophthalmotropism, e g, the virus of trachoma, diplobacillus infections and possibly gonorrheal ophthalmia The other organisms (staphylococcus, gonococcus and streptococcus) are known to induce only a local immunity, even in other organs of the body, which is not accompanied by antibodies in the blood Poleff discusses the use of Besredka's bouillon filtrates in producing local immunity and points out the basis for such investigations

Broth culture filtrates have a species-specific, growth-arresting character for homologous organisms in vitro

In experimental animals they produce a local, sharply limited and specific immunity which protects them against repeated lethal doses of the organism

This immunity, produced only by the use of specialized technic, occurs when the filtrate comes into direct and sufficiently prolonged contact with the tissue that is to be immunized Finally, a virulent strain pathogenic for the eye should be selected (For the present, staphylococcus or streptococcus filtrates only may be used in the eye)

The best results are obtained by injecting the "antivirus" subconjunctivally, or by applying it as a salve After repeated injections the immunity advances to the limbus and protects it against phlyctenulae which are so easily formed in tuberculous animals that are subjected to staphylococci Immunizing the cornea is more difficult because of its retarded metabolism Only after repeated subconjunctival injections of 1 per cent sodium chloride solution was the instillation of the filtrate followed by a positive result The author recommends the addition of atropine to the antivirus in order to prevent absorption of the immunizing factor The vitreous is immunized only by deep peribulbar and retrobulbar injections of the filtrate

In all these cases the immunity obtained is neither absolute nor permanent Antivirus has been successfully used in many hundreds of cases of ulcerative blepharitis, dacryocystitis, corneal ulcer, recurrent hordeolum, postoperative infection, etc

CHARLES WEISS

THE TUBERCULOTOXIC NATURE OF PHLYCTENA AND OTHER SCROFULOUS MANIFESTATIONS H GUILLERY, Virchows Arch f path Anat **273** 806, 1929

Typical phlyctenae can be produced in the rabbit's eye without working on the eye itself, if one tuberculinizes the rabbit and injects bacterial ferments which make hyperemia of the eye At autopsy the animals were found free from tuberculous lesions, the phlyctenae contained no tubercle bacilli and no necroses A small, permeable bag was inserted behind the one eye, and a phlyctena resulted in the other eye, abdominal insertion also led to phlyctena Microscopically, one finds many small phlyctenae, besides the few large ones, and much perivascular infiltration in the bulbar conjunctiva Similar cell masses were found in sclera, ocular muscles and orbital fat Corresponding examinations have not been made on eyes of scrofulous children In some rabbits, corneal phlyctenae were found In all animals into which a bag of tubercle bacilli was inserted, the tuberculin reaction became positive Inflammatory processes in the surroundings of the bag indicate the way the tuberculotoxins are taking

ALFRED PLAUT

MUCOR MYCOSIS IN SWINE M CHRISTIANSEN, Virchows Arch f path Anat **273** 829, 1929

Mold diseases in domestic animals are even more rare than in man In nine hogs that were about 6 months old, tumor-like masses and abscesses were present in the abdomen, mostly coming from the mesenteric lymph nodes There were smaller nodes in the liver and the lungs, some animals had intestinal ulcers with thick margins, occasionally, nodules in other organs and extra-abdominal, mostly cervical, lymph nodes were found The intestinal lesions sprang from the plaques of Peyer Seven of the nine animals came from one slaughter house Single animals had the disease, while others from the same litter were free The hyphens of the fungi were easily found in fresh specimens Pure cultures were obtained from all the animals The cultures were highly pathogenic for rabbits, guinea-pigs, rats and mice, but were not pathogenic for sparrows and pigeons Rabbits, after intravenous injection, developed labyrinthine symptoms as described in *Aspergillus* infection Inoculation of young pigs and of a pregnant sow did not lead to development of the disease Some of the young animals died after intravenous injection, and subcutaneous injection occasionally led to a localized abscess

ALFRED PLAUT

EXPERIMENTAL INVESTIGATIONS OF POSTVACCINAL ENCEPHALITIS J P BIJL AND H S FRENKEL, Zentralbl f Bakteriol (Abt 1) **112** 412, 1929

The authors injected the neurovaccine of Gallardo into rabbits cutaneously and studied the effects A large proportion of the animals died about the tenth day after inoculation In these rabbits miliary foci of inflammation were found in various organs of ectodermal, mesodermal and entodermal origin In the same organs the vaccine virus was recovered The foci, especially in the lungs, are characterized by a marked proliferative reaction with a perivascular infiltration of mesenchymal cells and, in the opinion of the authors, are specific for the neurovaccine of Gallardo The suggestion is made that the similar foci of inflammation in the brain in cases of encephalitis are caused by the vaccine virus or its toxins

PAUL R CANNON

THE ETIOLOGY OF GRIP D A PAVLOVIC, Zentralbl f Bakteriol (Abt 1) **112** 429, 1929

Secretions from the throats of patients with grip were injected intratracheally into rabbits and produced fever, inflammation and punctate hemorrhages in the lungs The results were the same with both unfiltered secretions and with those

passed through a Chamberland filter L_2 The secretions were usually taken during the first twenty-four hours of the illness The pathologic observations were similar to those observed by Olitsky and Gates, viz, hyperemia of the tracheal and laryngeal mucosa with punctate hemorrhages in the pleural surfaces and deep in the lungs Passage of the virus from animal to animal was unsuccessful Animals once infected, however, were immune to a second injection of the virus Using the technic employed by Olitsky and Gates, unsuccessful attempts were made to isolate *Bacterium pneumosintes* Another organism, however, was isolated which is called by the author *Bacterium granuliformans* This organism is a facultative anaerobe and is named *granuliformans* because of the presence of small granules after from ten to fifteen days of cultivation in broth While Pavlovic does not claim that this bacterium is the cause of grip, he believes that it and *B pneumosintes,* which it resembles, are related to grip in some manner

PAUL R CANNON

THE NATURE OF ANTIVIRUS B G MATWEJEWSKY, Zentralbl f Bakteriol (Abt 1) **112** 464, 1929

The author studied the problem of the nature of the growth inhibition in vitro of Besredka's so-called antivirus, using staphylococcic and streptococcic filtrates The addition of sources of energy such as carbohydrate or broth to the filtrate led to growth of the organisms, whereas the addition of peptone or ascitic fluid did not Adjustments of the p_H did not favor growth of the bacteria The growth-inhibiting effect was nonspecific and seemed to be due to the exhaustion of the mediums, especially of sources of energy such as are present in broth and carbohydrates

PAUL R CANNON

ATTEMPTS AT INFECTION BY RUBBING INFECTIOUS AGENTS INTO THE INTACT AND THE SUPERFICIALLY TRAUMATIZED SKIN Y S SHOUKRI, Ztschr f Hyg u Infektionskr **110** 697, 1929

Infection by way of the scarified skin occurs less readily than parenteral infection by way of the subcutaneous tissue or the peritoneum, but much more easily than infection by way of the intact skin A complete severance of the skin does not increase the chances of infection but seems to lessen them to some extent Infection from the scarified skin was rarely due to a few single organisms As a rule, it required from 100 to 1,000 times more than the smallest infectious dose in subcutaneous or intraperitoneal infection Smaller quantities were either ineffective or resulted in a more protracted course which seemed to favor the development of metastatic foci in the pericardium, the pleura or the lungs

W OPHULS

THE SCARLATINOTOXIC PROPERTIES OF HEMOLYTIC STREPTOCOCCI FROM CASES OF ANGINA W GRUNKE and E BARTH, Ztschr f Hyg u Infektionskr **110** 738, 1929

Filtrates were made of cultures of hemolytic streptococci obtained from the throats of twenty-one patients with angina lacunaris or angina phlegmonosa These were compared with standard Dick toxin by skin reaction in thirty-seven persons In 50 per cent of the cases the skin reaction was identical

W OPHULS

ENCEPHALITIS IN RABBITS WITH COCCIDIOSIS B GALLI-VALERIO Ztschr f Immunitatsforsch u exper Therap **65** 325, 1930

Meningo-encephalomyelitis may develop in rabbits with intestinal coccidiosis The lesions in the central nervous system are due probably to toxic products of *Coccidia*

Immunology

BIOLOGICAL TESTS FOR HYDATID DISEASE R H GOODALE AND H KRISCHNER, Am J Trop Med **10** 71, 1930

In a series of 106 cows, both the intradermal and complement fixation tests for hydatid disease were performed to compare their relative values These tests were checked by examination of the organs after slaughtering Of forty-four cows in which hydatid cysts were found, thirty-eight, or 86 3 per cent, gave a positive skin test, and twenty-six, or 59 per cent, a positive complement-fixation test There were eleven false positive skin tests and ten false positive complement-fixation tests In the rest of the series the observations substantiated those in the organs One of the two tests was positive in all of the cows in which hydatid cysts were found

AUTHORS' SUMMARY

ON THE HEREDITY OF THE LANDSTEINER BLOOD GROUPS ALEXANDER S WIENER, MAX LEDERER and S H POLAYES, J Immunol **18** 201, 1930

The bloods of 1,334 mothers and their 1,462 children were typed Although 485 group 0 mothers with 516 children and 94 group AB mothers with 142 children were examined, not once did the combinations AB mother—0 child or 0 mother—AB child appear The authors' data, together with Schiff's and Thomsen's, therefore completely support the Bernstein theory A survey of the literature shows that many apparent exceptions were found On careful analysis of these cases, not a single completely proved exception to Bernstein's theory could be found It may therefore be concluded that although the existence of bona fide exceptions to the Bernstein theory cannot be disproved entirely, it is certainly true that of all the theories of heredity of blood groups, Bernstein's theory agrees best with the facts Any true exceptions to this theory may be due to other factors complicating the mechanism of heredity

AUTHORS' SUMMARY

SPECIFICNESS OF SENSITIVENESS (TUBERCULIN TYPE) TO EGG PROTEINS L DIENES, J Immunol **18** 279, 1930

According to the observations described in this paper, the sensitiveness of the tuberculin type produced in guinea-pigs with egg globulin, crystalline egg albumin, and ovomucoid is specific to the preparation with which the animals were treated The specificity of this type of sensitiveness, like that of the anaphylactic sensitiveness, corresponds to the antigen specificity

AUTHOR'S SUMMARY

ANTIGENS IN SYNTHETIC MEDIUM FOR TUBERCLE BACILLUS L DIENES and E W SCHOENHEIT, J Immunol **18** 285, 1930

In the filtrates of cultures grown on the synthetic medium of Long, beside the carbohydrate precipitable substance we can demonstrate the presence of two antigenic substances They are separated from each other by acid precipitation By both the serologic reactions and the antibody production these antigens are well differentiated from each other and from the other antigens of the tubercle bacillus The difference between these two fractions can be observed also concerning the tuberculin reaction in guinea-pigs treated with one or the other of these preparations The acid-precipitable antigen readily forms antibodies in tuberculous animals which are specific toward this antigen The acid nonprecipitable fractions did not form antibodies reacting with the same preparations or with the acid precipitate and concentrated culture medium, but the serums of the majority of the guinea-pigs treated with these preparations gave strong reactions with the bacillary emulsion From the observations that neither of the two antigens separated by acid precipitation or their mixture gave a positive reaction with several serums produced with the concentrated culture medium and that the latter did not react

with the serums produced with the acid precipitate we draw the conclusion that in the culture medium the antigens that are separated by acid precipitation are united in a higher complex which has a specifically markedly different from that of the isolated antigens, and in the reactions of which the effect of the isolated antigens does not appear The differences that we found concerning the serologic reactions between the culture filtrate of different tubercle bacillus strains are probably caused not by the absence or presence of a certain antigen, but by the differences in the way in which the acid-precipitable part is united to the higher complex Probably the aforementioned complex antigen is responsible for the production of antibodies by the concentrated culture medium and the acid filtrate, although this complex often gives no reaction or only a slight one with these serums

AUTHORS' SUMMARY

INFLUENCE OF AGE UPON ANTIBODY FORMATION JULES FREUND, J Immunol **18** 315, 1930

In rabbits less than 20 days of age, the formation of agglutinins against typhoid bacilli, of hemolysins against sheep cells, and of precipitins against horse serum and egg white is strikingly less intense than in adult rabbits immunized in the same way A definite Arthus' phenomenon cannot be produced in young rabbits immunized with horse serum or egg white

AUTHOR'S SUMMARY

THE ANTIBODY CONTENT OF THE BILE OF IMMUNIZED RABBITS JULES FREUND and HOWARD J HENDERSON, J Immunol **18** 325, 1930

Antibodies are eliminated from the liver in the bile of rabbits actively or passively immunized against typhoid bacilli The following numerical relation exists between the agglutinin titers of the serum, liver extract, lymph of the liver and bile, expressed in percentages serum 100 per cent, liver extract 10 per cent, lymph of liver 80 per cent and bile 0 8 pr cent In the bile of passively immunized rabbits the maximum titer is reached within two hours after the immune serum has been injected The loss of antibodies by elimination with the bile explains at least in part why antibodies disappear from the blood of animals after active or passive immunization

AUTHORS' SUMMARY

PREPARATION AND ANTIGENIC PROPERTIES OF CARBONMONOXIDE HEMOGLOBIN ALDEN KINNEY BOOR and LUDVIG HEKTOEN, J Infect Dis **46** 1, 1930

Pure carbonmonoxide hemoglobin was prepared by treating oxyhemoglobin, made by the method of Marshall and Welker, with pure carbonmonoxide, and in all species used, except man, the carbonmonoxide hemoglobin was recrystallized from alcohol three or four times at O C The watery solutions or dried crystals were preserved at O C and at room temperature under an atmosphere of carbonmonoxide The report of previous investigators that oxyhemoglobin is antigenic and mainly species-specific was confirmed by the precipitin test, and likewise carbonmonoxide hemoglobin was found to be antigenic and mainly species-specific Cross reactions appeared in the case of closely related species, such as duck, chicken and turkey, beef and sheep Cross reactions of one dog antiserum and one sheep antiserum with other species were observed These antiserums became species-specific when diluted 1 3, which suggests a common radical in the antigen having weaker antigenic powers than the species-specific portion of the molecule This point requires further work

AUTHORS' SUMMARY

ON THE PURIFICATION AND CONCENTRATION OF SCARLET FEVER TOXIN LAWRANCE E SHINN, J Infect Dis **46** 76, 1930

The experiments reported here indicate that a lethal dose of scarlet fever toxin for rabbits has not been established Although rabbits were given intravenous

injections with more than seven times the dosage of scarlet fever toxin designated by Hartley as the lethal dose for rabbits, no specific lethal action of the toxin was demonstrated It was possible to concentrate scarlet fever toxin by precipitation with sodium sulphate and acetic acid Attempts to obtain further purification by fractional precipitation with sodium sulphate were unsuccessful Attempts to concentrate scarlet fever toxin by precipitation with acetic acid alone were not successful Precipitation with acidified alcohol gave the most uniform and the best results Rabbits are not suitable for standardization of scarlet fever products Concentration of scarlet fever toxin may be obtained by several methods Of those used in these experiments, precipitation with alcohol acidified with acetic acid gave the best results

AUTHOR'S SUMMARY

THE COMPOSITION OF CRYSTALLINE PROTEINS FROM HUMAN BLOOD SERUM AND URINE HILDA H KROEGER and LUDVIG HEKTOEN, J Infect Dis **46** 115, 1930

On successive crystallization in filtrates of ammonium sulphate precipitations of proteins in human blood serum, albumin tends to become the chief constituent of the globular crystals as determined by their precipitin reactions Crystallization consequently may be a means of separating albumin from the globins in blood serum In nephritic proteinuria a large part of the protein proved to be albumin

AUTHORS' SUMMARY

THE ZONE PHENOMENON IN AGGLUTINATION TESTS R R SPENCER, J Infect Dis **46** 138, 1930

Studies were made of a serum which agglutinated *Brucella abortus* in high dilutions and showed an unusual middle zone of inhibition The middle zone of inhibition could be transferred to other positive *abortus* serums but not to antityphoid serums, suggesting that the zone phenomenon is a specific reaction However, a later specimen of serum from the same patient gave a wide prezone which could not be transferred to other anti-*abortus* serums The presence or absence of the zone was controlled by the temperature at which the agglutination test was incubated This was found to be true also for an antimeningococcus serum exhibiting a zone The optimum temperature for obtaining the zone, however, was not the same for both serums Inactivation at 56 C of the serum showing the zone tends to increase its range A prezone may be induced in some positive serums, but not in all, by inactivating them at 56 C These tests serve to emphasize the great difficulty in making trustworthy generalizations covering even a single antigen-antibody reaction (agglutination) since the knowledge concerning the nature of such immune reactions is still so incomplete Therefore it is preferred for the present to report the results without further comment

AUTHOR'S SUMMARY

ON ISOHEMAGGLUTINATION, THE HEMOLYTIC INDEX AND HETEROHEMAGGLUTINATION LELAND W PARR, J Infect Dis **46** 173, 1930

Data for 1,685 serologically syphilitic serums tested for blood groups fail to support the contention that there is any relation between any one blood group and susceptibility to or resistance against syphilic infection Furthermore, the small amount of dementia paralytica in the Near East where 10 per cent of the people are of the blood group AB speaks against any marked increase of late syphilis in persons belonging to that blood group Similarly, negative observations are reported as regards the relationship of malarial infection to any one of the four blood groups, based on a study of 279 cases of malaria While my data on the blood groups and sex, based on a series of 7,074 cases, indicate a slight preponderance of females in blood group AB, yet there is probably no significance to this observation in view of the contradictory nature of other observations on the subject and the absence of any theoretical reason for such an increase Racial

blood group data for the French of the poorer classes of Paris show the unsatisfactory nature of such data for racial studies in view of the wide variations encountered by different workers dealing with the same group of pople Fresh blood serum of more than 93 per cent of Near Easterners has hemolytic activity against sheep red blood cells The average hemolytic index is 4 12, based on 788 determinations There is no significant racial difference, but blood group 0 persons average greater hemolytic power than others whereas AB people have least of this power The blood of new-born infants has no hemolytic activity, this is acquired after birth, whereas the content of complement and isohemoagglutinin is partially present at birth Attention is called to the high percentage of pregnant women who at term give a hemolytic index of zero The almost universal occurrence of heterohemagglutination between certain animal serums and heterologous red blood cells was confirmed Positive reactions occurred in 99 6 per cent of 1,485 tests made on cattle, pig and rabbit serums in contact with rabbit cells and especially with human cells of all four groups

AUTHOR'S SUMMARY

BRUCELLA AGGLUTININS IN THE BLOOD AND MILK OF COWS ROBERT GRAHAM and FRANK THORP, J Infect Dis **46** 260, 1930

It is apparent that a negative agglutination test with milk serum is not a reliable indication of the *Brucella* agglutinin content of the blood of the same animal Agglutination with the milk serum detected from 47 to 68 per cent of the cows in two *Brucella*-infected herds, the blood serum of which reacted These observations tend to confirm the generally accepted limitations of the milk serum test for *Brucella* agglutinins in the diagnosis of this infection in cattle

AUTHORS' SUMMARY

NEW BLOOD GEN (A') AND RESULTING BLOOD GROUPS A' AND A'B O THOMSEN, V FRIEDENREICH and E WORSAAE, Klin Wchnschr **9** 67, 1930

The authors believe that another blood gene A' has been demonstrated, and that instead of only four groups there are six, namely, O, A, A', B, AB, and A'B The two new groups are not subgroups, but rather, independent and as important as the other four A technic for the demonstration of these two new groups is described

AUTHORS' SUMMARY

Tumors

ON THE CHANGES IN THE MAMMARY GLAND PRECEDING CARCINOMA ALEXANDER A CHARTERIS, J Path & Bact **33** 101, 1930

A histologic study of forty-eight breasts removed by operation for carcinoma has been carried out Of these, forty-one were in addition the seat of so-called chronic cystic mastitis, and this lesion is described in detail, except in two cases the diagnosis was possible only on slicing up the organ or on microscopic examination All grades of epithelial hyperplasia may be found in the ducts and acini of the organ, and the earlier stages are usually to be seen in association with the "chronic mastitis" The process may result in the formation of papillomatous growths wth a variable amount of stroma or in more cellular and diffuse growth without stroma The more purely cellular hyperplasias may be traced through a series of progressive developments in which changes in the character of the cells are at last apparent No line of demarcation between the various stages can be made out, they merge insensibly with each other until at last the ducts and acini are filled with cells indistinguishable histologically from cancer cells—intraduct carcinoma These finally break through the duct wall and invade the tissues, forming a cancerous tumor This is the common sequence of events Cancer, however, occasionally arises in connection with papillomas, and those of the filiform variety with a minimal amount of stroma seem especially prone to undergo malignant transformation, giving rise to the cancer in two cases of this series The

malignant growth is believed to have arisen from the ducts in thirty-one of the forty-eight cases Paget's disease of the nipple is referred to, and one case in particular provides some interesting facts bearing on the relationship between this lesion and intraduct carcinoma The occurrence of desquamative changes and of epithelium of sweat gland type is briefly discussed From these observations it would appear that the onset of cancer in the breast is frequently the result of a long series of proliferative changes, mainly in the duct epithelium, and that these begin as relatively simple lesions the study of which might give information of value as regards prophylaxis More work of an experimental nature is necessary

AUTHOR'S SUMMARY

FURTHER EXPERIMENTS ON THE CARCINOGENICITY OF SYNTHETIC TARS AND THEIR FRACTIONS C C TWORT and J D FULTON, J Path & Bact **33** 119, 1930

The carcinogenic activity of synthetic tars varies according to the chemical compound utilized for their manufacture A synthetic tar made from pinene at 850 C was a more powerful carcinogenic agent than one made from turpentine under similar conditions The relative carcinogenic potencies were 100 and 21, respectively The carcinogenic activity of a synthetic tar varies according to the temperature of the combustion tube Pinene tars made at 500, 600, 750, 850 and 950 C had relative potencies of 0, 12, 24, 100 and 64 A synthetic tar was concentrated as far as its carcinogenic activity was concerned by means of distillation and differential solubility in alcohol A 5 per cent solution of our most concentrated fraction was about five times as powerful as the ordinary crude gas tars tested by us The active constituents in the synthetic tar formed crystalline picrates, the extract proved to be almost devoid of carcinogenic activity The trinitrophenol extract proved to be extremely potent as a cancer-producing agent Oxygenation of a synthetic tar at 100 C reduced the potency of the tar from 100 to 63, and when the same tar was oxygenated at from 150 to 160 C the potency fell to 1 Oxidation with an acetone solution of permanganate reduced the potency to 24, with pyridine as a solvent the figure fell in one case almost to 0 Reduction of the tar by means of sodium in boiling amyl alcohol reduced the potency of the tar to 0 5, and when this tar was treated with sulphur its potency was raised to 5 Dilution of the tar with oleic acid instead of with the inert liquid paraffin reduced the potency by about 20 per cent Similarly, oleic acid reduced the potency of coal gas tar from 90 to 66 Applications of oleic acid have given rise to benign tumors With lactic or butyric acid, no tumors were observed A mixture of hydrocarbons soluble in chloroform failed to induce the development of tumors, while a mixture of insoluble hydrocarbons, suspended in liquid paraffin, gave rise to two epitheliomas Among several insoluble hydrocarbons tested in the pure state, suspended in liquid paraffin or oleic acid, chrysene (if our specimens have been completely purified) appears definitely to be carcinogenic although its potency is extremely low Among liquid hydrocarbons tested American turpentine and pinene have both induced the development of a benign tumor

AUTHORS' SUMMARY

TAR LESIONS BY THE INTRAVENOUS ROUTE CESARE TEDESCHI, Tumori **4** 101, 1930

The author has subjected rabbits to repeated intravenous injections of tar in oil and has made a histologic examination of their viscera He emphasizes especially regressive processes in the heart, the lungs and the liver and the frequent formation of sclerotic foci, he has encountered more rarely the signs of an inflammatory process In fibrous spots of the pulmonary parenchyma hyperplastic changes of the alveolar epithelium are observed, hyperplasia with a somewhat atypical character is also seen in the epithelium of the small bronchi The observations show a general toxic action of tar

AUTHOR'S SUMMARY

STUDY ON THE BASAL METABOLISM IN PATIENTS WITH TUMOR DINO DONATI, Tumori **4** 126, 1930

In studying the basal metabolism in cases of tumor, a diminution was found in patients with cancer, sensibly diminished values in two persons with benign tumors and an increase in cases of sarcoma and lymphosarcoma An increase was also found in a case of myelocytic leukemia Radium therapy produced an increase of from 15 to 20 per cent, roentgen therapy, an increase of from 6 to 10 per cent In both cases the increase was noted only on the day following the application

AUTHOR'S SUMMARY

GANGLIONEUROMA OF THE PINEAL BODY A SCHMINCKE, Beitr z path Anat u z allg Path **83** 279, 1929

One-half year before his death, a man, aged 50, began to complain of headache, dizziness, diplopia and sleepiness Three months before death, his gait became unsteady A decompression operation resulted in death On his admission to the hospital, there was slight paresis of the left facial and abducens nerves, spontaneous nystagmus to the right, absence of the cremasteric reflex, increased patellar reflexes and a positive left Babinski sign Ventriculography revealed compression of the posterior horn of the right lateral cerebral ventricle At necropsy, the pineal body was the size of a small cherry Attached to and a part of the pineal body was a rounded tumor mass, which rested on the corpora quadrigemina and which had caused obstruction of the ventricular system Histologic examination showed the tumor to be composed of glia cells, many of them of giant size, glia fibers, ganglion cells in various stages of differentiation, and nonmedullated axis cylinders The only change noted in the genital system was a moderate increase in the size of the testes, in which spermatogenesis was active

O T SCHULTZ

PRECANCEROUS CHANGES IN BLOOD VESSELS LEIV KREYBERG, Virchows Arch f path Anat **273** 367, 1929

After reviewing some pertinent questions of the present knowledge of experimental carcinoma, Kreyberg formulates his problems as follows What are the local anatomic and functional changes in the cutaneous blood vessels of the white mouse after painting with tar? What rôle may these changes play in epithelial proliferation and cancer formation? Nonpregnant white mice were used The tar used had been found potent in previous experiments The vessels were studied in the living mouse, partly under a binocular microscope A 1 3 per cent aqueous solution of sodium sulphide keeps the skin hair free and makes it translucent The mild hyperemia caused by the sulphide does not interfere with the vascular changes Preparations of skin were examined in balsam, they mostly were taken from mice into which carmine had been injected There was always transudation in the tar-painted skin area, the small vessels were much distended The hyperemia began immediately after the first painting It lasted for about forty-eight hours After repeated paintings the hypermia lasts longer, its duration corresponding to the duration of painting It occurred also in areas that were cut off from their nerve supply The tar obviously damages the contractile apparatus of small vessels When the tar painting is not continued for more than one month, the blood vessels recover Otherwise permanent dilatation is established, accompanied by transudation Painting with spiritus sinapis did not lead to permanent vascular changes, neither did regular application of hot water The local action of the tar was characterized by intense hyperemia and relatively slight toxic action In rabbits and rats there was no vascular reaction after painting with tar, and no hyperplasia of epidermis The hyperemia appears earlier than the small warts It may, together with other factors, lead to local increase of growth In addition, there is the local and general toxic action of the tar The possibility of a connection between tar hyperemia and tar hyperplasia is stressed

ALFRED PLAUT

A RARE TUMOR OF THE CECUM IN AN INOCULATED MOUSE L HEIDENHAIN, Virchows Arch f path Anat **273** 541, 1929

Ten mice were treated intramuscularly with fresh suspension of a congenital myelogenous giant cell sarcoma In six of the ten mice malignant tumors developed One of the mice had the following tumors squamous cell carcinoma of the colon, carcinoma of the ileum, uterus and pylorus, double carcinoma in the cecum, and sarcomatous lymph nodes in the region of the pancreas ALFRED PLAUT

TOBACCO AND TOBACCO SMOKE AS ETIOLOGIC FACTORS IN CANCER F LICKINT, Zschr f Krebsforsch **30** 349, 1929

The author gives a careful and excellent survey of the literature on the relationship of tobacco to cancer He summarizes the knowledge of the subject as follows Experimentally, cancer has not as yet been induced by the application of tobacco tar, although this has been found to cause epithelial hyperplasia From clinical observation, tobacco may be regarded as a cause of cancer of the lip, tongue, oral mucosa, gums, pharynx, esophagus and stomach, as well as of the larynx, bronchi and lungs in the respiratory tract He inclines to the view that it may occasionally be responsible for primary cancer of the liver and urinary bladder

H E EGGERS

Medicolegal Pathology

PURIFIED MINERAL OILS NOT CARCINOGENIC F C WOOD, J A M A **94** 1641, 1930

Extensive appropriate experiments on white mice and rats with purified mineral oils (Squibb's Liquid Petrolatum and with Nujol) failed to produce carcinoma of the gastro-intestinal tract These negative results favor the assumption that purified mineral oils do not produce carcinoma in man

METHYL SALICYLATE POISONING IN INFANCY IRWIN S MEYERHOFF, J A M A **94** 1751, 1930

A boy, aged 22 months, swallowed about 24 cc of synthetic methyl salicylate Vomiting was an early symptom, the breath smelled of wintergreen, the abdomen was distended After death, the lungs were congested, the liver large, smooth, pale and yellow, the lining of the stomach was edematous, and the contents of the ileum and cecum had the odor of methyl salicylate Microscopically, early glomerular nephritis, degeneration of the liver, and hyperplasia of lymphatic structures in the ileum and of mesenteric lymph nodes were noted

REVIEW OF CARBON MONOXIDE POISONING By R R SAYERS, Surgeon United States Public Health Service, and SARA J DAVENPORT, Principal Translator, United States Bureau of Mines Prepared by direction of the Surgeon General United States Treasury Department, Public Health Service Public Health Bulletin, no 195 Paper Price, 20 cents Pp 97 Washington, D C Superintendent of Documents, Government Printing Office, 1930

The various aspects of carbon monoxide are considered — occurrence, symptoms, diagnosis, pathology, prevention and treatment The bibliography at the end contains 195 references, which are not arranged alphabetically There are many interesting reminders of the historical side of this ancient form of poisoning The medicolegal problems of monoxide poisoning are not discussed systematically Under the heading of pathology are considered mainly the various opinions in

regard to the genesis of the symptoms of the poisoning and of the lesions in the brain, which are now regarded as the result of anoxemia and secondary vascular changes Pathologic anatomy is not described minutely and systematically The percentage of carbon monoxide that is dangerous to breathe is considered fully, as are also the methods for determining its presence in the blood and in the air The medicolegal pathologist will be interested in the method for determining carbon monoxide in the blood, devised by Sayers and his collaborators This method is based on the fact "that a light gray brown suspension is formed after a few minutes when normal blood diluted with water is treated with a solution of tannic and pyrogallic acids, whereas with blood having carbon monoxide in combination with the hemoglobin a light carmine suspension is formed, but in any mixture of normal blood and blood containing carbon monoxide the suspension will be a corresponding mixture of the two extremes of color The apparatus consists of a set of standards to represent the different colors of varying but known amounts of carbon monoxide in combination with hemoglobin, to which unknown specimens can be matched and the amount of carbon monoxide hemoglobin evaluated The percentage of saturation of carbon monoxide in the blood can easily be determined by this method to a degree of accuracy involving only 5 per cent error" The apparatus designed for this purpose is simple enough to be used without special training and it is durable and compact so that it can be carried in the pocket The apparatus may be obtained from the Mine Safety Appliance Company, Pittsburgh

AIR EMBOLISM FROM FILLING URINARY BLADDER WITH AIR C P MATHE, J d'urol **28** 163, 1929

Preliminary to operative removal of a vesical papilloma in a man, 56 years old, the bladder was being filled with air, a hissing sound was heard, and the patient died in collapse After death, air bubbles were found in the iliac and mesenteric veins, in the abdominal part of the vena cava and in the renal vein The air appears to have entered the circulation through ulceration in the neighborhood of the vesical tumor

THE SEROLOGIC IDENTITY OF CARCINOMA L HIRSZFELD and W HALBER, Klin Wchnschr **9** 918, 1930

The authors sought by serologic studies to determine whether in carcinoma there are many antigens or only one carcinoma substance They conclude that there is a definite serologic substance common to all, or at least there are many tumors, which probably is significant biologically and may be demonstrated in the serums of patients with carcinoma

EDWIN F HIRSCH

LESIONS IN THE NERVOUS SYSTEM IN EXPERIMENTAL THALLIUM POISONING R GREVING and O GAGEL, Zentralb f d ges Neurol u Psychiat **120** 805, 1929

Following an attempt at suicide by means of a rat poison containing thallium, a severe motor polyneuritis developed in a woman Experiments were made and weakness and ataxia in hind extremities developed in dogs and cats The nerves of the extremities presented marked degenerative changes

ASCARIASIS THE CAUSE OF SUDDEN DEATH W LEWINSKI (Warsaw), Czas lek **6** 223, 1929

Headache and vomiting suddenly developed in a girl, aged 9, She became unconscious and died in six hours Autopsy revealed a mass of thirty-eight worms in the jejunum, 80 cm from the pylorus The jejunal mucous membrane was congested and swollen The cause of death is ascribed to intoxication with ascaris poison

Technical

THE CONTROLLED FLOCCULATION TEST IN THE DIAGNOSIS OF SYPHILIS ALEXANDER MICHAILOFF, Am J Hyg **11** 202, 1930

The controlled flocculation test using the mastic-brain-muscle antigen has proved more accurate, more sensitive, more easily interpreted and more time-saving than the Wassermann or other flocculation tests The brain-muscle antigen gives more sensitive and less false reactions when used in the regular Wassermann technic than do the antigens of Bordet-Ruelens and Bering-Werke (cholesterinized) In an accurate Wassermann test it is necessary to use at least three different antigens Without the addition of complement our mastic-brain-muscle antigen gives a sensitive flocculation test To avoid anticomplementary reactions, serums, after separation, should be shaken five minutes and then centrifugated and inactivated

AUTHOR'S SUMMARY

LEUCOCYTE COUNTS IN RABBITS S C CHENG, Am J Hyg **11** 449, 1930

In the light of the observations recorded the following points especially must be taken into consideration in order to obtain consistent leukocyte counts in rabbits (*a*) the age of the rabbit, (*b*) the time of day at which counts are made, (*c*) the manner of feeding, (*d*) pregnancy and the postparturient period, (*e*) the position of the animal and (*f*) the conditions of sensitization, infection or the carrier state, with *Bacillus bronchi-septicus* or *Bacterium lepisepticum* With these factors eliminated or controlled, and with quiet animals, consistent counts can be obtained on successive days

JOHN PHAIR

THE EARLY DIAGNOSIS OF PREGNANCY, CHORIOEPITHELIOMA AND HYDATIDIFORM MOLE BY THE ASCHHEIM-ZONDEK TEST S ASCHHEIM, Am J Obst & Gynec **19** 335, 1930

This test is based on the hormone from the anterior lobe of the hypophysis, which is increased in pregnant women and is found in abundance in the urine The hormone activates the ovaries of the infantile mouse (aged 3 weeks and weighing 6 Gm) to the production of mature follicles and corpora lutea, which in turn by the hormone they elaborate bring about estrus-like changes The technic, briefly, consists in using six mice as specified which receive six hypodermic injections, three each, on the first and second days of the morning urine of the suspected pregnant woman The single doses are 0 2 and 0 25 cc for the first two mice, 0 3 cc for the third and fourth and 0 4 cc for the fifth mouse The sixth mouse acts as a control One hundred hours after the first dose the mice are killed and the ovaries studied The ovaries of control mice are pale grayish pink and hardly pinhead in size, while those of test mice are much larger and distinctly red and have submiliary yellowish protrusions corresponding to the corpora lutea The microscopic test may verify this, and changes found as in estrus are seen in the uterus and vagina This test has been found to be accurate in 98 6 per cent of 880 cases The urine of women having hydatid moles or chorio-epitheliomas is strongly positive

A J KOBAK

A NEW TEST OF RENAL FUNCTION R T BRAIN and H D KAY, Quart J Med **22** 203, 1929

The authors describe a glycerophosphate test in which 550 mg of sodium glycerophosphate is given intravenously in a 50 per cent sterile solution, 10 cc being given at one time One hour after the test the bladder is emptied The proteins are precipitated and phosphorus determinations are made Before the test is given, a control specimen is obtained which gives the normal phosphorus excretion

The difference between the control and the test specimen gives the excess phosphorus excretion In normal persons 150 mg of extra phosphorus is usually excreted In renal impairment much lower values are obtained In forty-four cases of renal disease this test has been compared with the urea concentration and the phenolsulphonphthalein test, and was found to be at least as valuable as these two tests, and in some instances more closely approached the clinical observations The test is based on the enzymic activity of the kidney The presence of phosphates in the kidney tissue has been held responsible for the inorganic phosphates of the urine The authors had previously observed that in chronic nephritis and in experimental nephritis the phosphate content of the kidney was diminished, and the reduction in the enzymic activity seemed to be parallel with the degree of structural damage in the kidney

N Enzer

THE DEMONSTRATION OF TUBERCLE BACILLI IN SURGICAL TUBERCULOSIS M Knorr and H Friedrich, Munchen med Wchnschr **77** 173, 1930

The diagnosis of surgical tuberculosis by means of animal inoculations was in error, at most, in 5 per cent With intraglandular inoculation, the length of the test in 95 per cent was shortened to from ten to twenty-eight days without modifying the certainty of the result Cultures made according to Hohn were negative in ten cases in which the animal tests were positive Cultures were never positive when the animal inoculations were negative Tubercle bacilli in material treated with sulphuric acid were demonstrated with greater ease by animal inoculation than by culture Certain infections seemed to be caused by strains nonpathogenic for guinea-pigs In these cases, attempts to grow the organisms were unsuccessful

Authors' Summary

THE PHOSPHATIDE AND CEREBROSIDE CONTENTS OF THE SPLEEN AND LIVER IN GAUCHER'S DISEASE OF CHILDREN, IN NIEMANN-PICK'S DISEASE, AND NORMALLY Emil Epstein, Virchows Arch f path Anat **274** 294, 1929

The figures for lecithin as given in the literature are far too high If one extracts normal spleens with ether, working with fresh material and with formaldehyde-fixed material, the residue after evaporation of the ether is three times as heavy in the fresh material as in the fixed It is different after extraction with alcohol, generally the fresh spleen leaves a residue which is only one-tenth heavier Therefore, organs for lipoid extraction must be kept unfixed on ice, and, if possible, given to the chemist the same day One can keep the organs for some time by slicing them and rubbing chemically pure sodium chloride into the slices

Alfred Plaut

Society Transactions

PATHOLOGICAL SOCIETY OF PHILADELPHIA

Annual Conversational Lecture April 10, 1930

The Etiologic Grounds for Separating the Different Forms of Hypersensitiveness, with Special Reference to Anaphylaxis, Atopy (Hay-Fever—Asthma Group) and the Tuberculin Type Arthur F Coca

One of the important contributions of the science of immunology is the paradoxic discovery that antibodies are sometimes the actual cause of disease

The first instance of this discovery was in the demonstration by Landsteiner with Donath that paroxysmal hemoglobinuria is due to the presence of an antibody in the blood of these subjects, the autohemolysin, which causes the destruction of the red blood corpuscles if the blood has been chilled in the surface vessels to a temperature of 16 C or lower

Showing the Outstanding Differences Between Anaphylaxis and Atopy

	Anaphylaxis	Atopy
Antibodies	1 Produced by normal human being or animal	1 Produced against usual atopens under normal conditions of contact only under atopic hereditary influence
	2 Neutralize the antigen	2 Usually incapable of neutralizing the antigen
	3 Sensitize unstriped muscle of guinea pig	3 Do not sensitize unstriped muscle of guinea pig
	4 Do not sensitize human skin	4 Sensitize human skin
Shock tissue	Normally susceptible to antibody antigen reaction	Normally insusceptible to antibody—antigen reaction
Transmission to offspring	From female only, by passage of antibodies from mother s blood through the placenta	From father or mother, by mendelian inheritance
Desensitization	Complete in guinea pig difficult in rabbit	Impossible

The second category of immunologic diseases is that of specific sensitiveness, comprising, in the human being, the hereditary conditions of asthma, hay-fever and eczema and also specific dermatitis (of that type known as dermatitis venenata) and serum disease, neither of which is subject to the special hereditary influence to which reference has been made

In the accompanying table, the atopic (hereditary) hypersensitiveness of man is contrasted, as to its chief features, with the experimental form (anaphylaxis) in lower animals

Since it has been found that under continuous contact with the excitant the age of the onset of symptoms of atopic sensitiveness is determined by heredity, the influence of contact in establishing this clinical condition must be entirely subordinate even among atopic persons This is further emphasized by the fact that intensive natural or artificial contact, on the part of an atopic person, with an antigen to which he is not naturally sensitive does not render him atopically sensitive to that antigen

The studies of Anderson and Schloss, of M Walzer and of Ecker and of Cohen and Breitbart have shown that at least 90 per cent of normal human beings are constantly absorbing unaltered proteins through their mucous membranes, yet only those of atopic ancestry become clinically hypersensitive, and these usually to only a limited number of the absorbed proteins

Furthermore, atopic hypersensitiveness is much less commonly exhibited to the "good" antigens, such as egg, milk and meat proteins, than to the "poor" antigens, such as the pollens

All of these well established facts show the relative unimportance of contact in the etiology of the atopic form of hypersensitiveness, they refute the indirect attempts to identify atopy and anaphylaxis

Book Reviews

REFLEX ACTION A STUDY IN THE HISTORY OF PHYSIOLOGICAL PSYCHOLOGY By FRANKLIN FEARING, Ph D Price, $6 50 Pp 350, with illustrations Baltimore Williams & Wilkins Company, 1930

This summary of the growth and present status of the concept of the reflex arc is timely, for it gives the historical perspective necessary for evaluating those recent movements in physiology and psychology that derive all human behavior from simple and conditioned reflexes, and for an appreciation of the reasons for a searching criticism of these movements The history of the emergence from scholastic mysticism of the idea of the reflex as the natural operation of bodily mechanisms is outlined in the first seven chapters These early efforts to find scientific formulation of the problem reached their logical fulfilment in la Mettrie's "Man a Machine," published in 1748, but at that time the factual knowledge of bodily organization was inadequate to support so sweeping a generalization

At the close of the eighteenth century, the concept of reflex action as a type of neuromuscular response with certain specific objective characteristics was clearly formulated, despite the lack of adequate anatomic knowledge of the nervous structures involved In the nineteenth century, this anatomic knowledge was so rapidly accumulated that there seemed to be reasonable hope of a satisfactory mechanistic account of all human behavior Numberless specific reflexes were accurately investigated physiologically and their nervous pathways and centers were demonstrated

Before the dawn of the twentieth century, the focus of interest shifted from the particular reflexes as units of behavior to the problem of their organization, their integration and their modifiability The Russian school studied intensively the conditioning of reflexes (which is learning), and in Germany an "objective psychology" rapidly developed The last mentioned movement culminated in the excesses of the American school of radical behaviorism Meanwhile Sherrington, in 1906, published his "Integrative Action of the Nervous System," a work which, as one looks back on it, one recognizes as marking the turning point from an analytic toward a genuine and well founded synthetic treatment of the reflexes in their organic setting—not as isolated units of function, but as parts of the machinery of integration

Today it is generally recognized that the "simple reflex" is a pure fiction, and there is a healthy skepticism regarding all of the traditional dogmas that have for so long been associated with the terms "reflex," "automatic," "involuntary" and "voluntary" It is concluded that reflexes can no longer "be regarded as isolated units of function in the intact nervous system," and it is equally clear, though not mentioned by our author, that in pathologic processes the local reflexes, though valuable diagnostic signs, must be interpreted critically in their relation to the organization as a whole Their disorders may be far more instructive as indicators of systemic disturbances than merely as aids in the localization of lesions

The swing at the present time is strongly away from regarding the reflex as a practicable unit of behavior In psychology, this is most evident in the so-called Gestalt movement "From the point of view of physiological psychology, we are concerned with the reflex act as part of the total response pattern of the functioning organism, rather than with the analysis of the functional components of the isolated reflex arc" This is as true in physiology as in psychology, and the author has missed an instructive exemplification of it, for he has overlooked the work of Coghill ("Anatomy and the Problem of Behavior," Cambridge University Press, 1929, and earlier works there cited), who has shown that local reflexes, so far from being primary elements of behavior, are secondary to total patterns

of behavior and are derived from these They are partial patterns which in ontogeny are slowly emancipated from mass movements of the whole bodily musculature Adult behavior patterns are not fabricated from an assemblage of separate reflexes, but all bodily activities are perfectly integrated from the beginning of embryonic development and the local reflexes come at the close of the developmental process, not at its beginning This reversal of our traditional reflexology is well authenticated by observation and experiment It may have important applications in medical practice, but this field awaits exploration

REPORT OF THE MEDICAL RESEARCH COUNCIL FOR THE YEAR 1928-1929 Price, 3 shillings Pp 153 London His Majesty's Stationery Office, 1930

The work of the Medical Research Council is supported by public and by private funds and is conducted by its own full-time staff in the National Institute for Medical Research at Hampstead, by so-called clinical units in various hospitals in London and elsewhere, and by grants-in-aid to workers in various centers for research on a great variety of problems In the introduction to the detailed report certain major topics are discussed and special attention may be called to the section dealing with clinical research and experimental medicine Here is discussed again the questions whether there is a science of experimental medicine of which the actual material for study is the human patient or is scientific work by the physician or surgeon limited to the application in his art of scientific results worked out elsewhere in the laboratory and delivered to him for use? The Council makes it clear that all in its power will be done to encourage further the direct scientific study of disease in man by recruiting "young workers of ability who are prepared to test themselves in this branch of medical research with the view to its becoming their life work" This section bears directly on our problem of full-time clinical teachers Without going into greater detail, let it be said that the report conveys an excellent and instructive view of the scope and nature of the activities of the Medical Research Council, which is the most important factor by way of organized effort in medical research in Great Britain The report is a model of its kind, it should be copied by similar agencies elsewhere, and it should be studied by all who are concerned in the promotion of medical research and the practical application of results

PRAKTIKUM DER GEWEBEPFLEGE ODER EXPLANTATION BESONDERS DER GEWEBEZUCHTUNG By RHODA ERDMANN Second edition Price, 14 80 marks Pp 148, with 99 illustrations Berlin Julius Springer, 1930

Although the author considers this merely a handbook for a practical course for students, it must also be ranked as an excellent guide for investigators in the field of tissue culture The author defines her terms carefully and calls timely attention to the errors of nomenclature and misuse of terms that are gradually creeping into the subject A good example is the expression "generations" of cultures when what is really meant is a series of "transfers" of part of a tissue grown "in vitro" Full details of the technic for the explanation and care of various tissues of animals and man are given A feature of the book is the detailed description of the best methods for staining whole explants or sections of them and for the differentiation of the various types of tissue and cell The illustrations are well chosen and of good quality There are practically no errors of printing, and such a discrepancy as "Typhusbakterien" in the legend of figure 93, page 128, and "Tuberkelbacillen" in the text referring to this illustration was the only one noted by the reviewer The book is not merely a technical manual, for it contains a discussion of the value and limitations of this type of investigation, brief but good descriptions of the historical background of every phase of the subject, summaries of the established facts, and, what is more important, suggestions for future investigations

BACTERIAL METABOLISM By MARJORY STEPHENSON, M A , Associate of Newnham College, Cambridge, Member of the Scientific Staff of the Medical Research Council Price, $7 00 Pp 320, with diagrams New York Longmans, Green & Company, 1930

This volume of two hundred and seventy text pages is intended, according to the preface, to "choose from the mass of data on the chemical activities of bacteria facts — to appraise our knowledge of bacteria as living organisms apart from their role as disease germs or the bearers of commercially important catalysts" The point of view is mathematic rather than biologic Emphasis appears to be placed on isolated, unrelated details rather than on coordination and unification of the material considered The first seven chapters, comprising an introduction and sections on energy relations and fermentation, respiration, growth and nutrition, carbohydrate breakdown, "viscous fermentation" and protein breakdown, are chiefly compilations, gleaned from many sources, illustrative of the versatility of bacteria and related forms under various conditions rather than informative concerning their biology The last two chapters, however, which make up one fifth of the book, on nitrogen fixation and autotrophic bacteria, are well organized, constructive in their scope and more in harmony with the title

Books Received

DIE GASBEHANDLUNG BOSARTIGER GESCHWULSTE Von Dr Bernhard Fischer-Wasels O O Professor der allgemeinen Pathologie und pathologischen Anatomie an der Universitat, Direktor des Senckenbergischen Pathologischen Instituts zu Frankfurt am Main Unter mitwirkung von Privatdozent Dr W Bungeler, Dr J Heeren, Dr S Heinsheimer, Dr G Joos Mit 82 zum teilfarbigen Abbildungen im Text und zahlreichen Tabellen Price, 65 marks Pp 472, with 82 illustrations Munich J F Bergmann, 1930

PRAKTIKUM DER GEWEBEPFLEGE ODER EXPLANTATION BESONDERS DER GEWEBEZUCHTUNG Von Rhoda Erdmann Zweite Auflage Price, 14 80 marks Pp 148, with 99 illustrations Berlin Julius Springer, 1930

REPORT OF THE LABORATORY AND MUSEUM OF COMPARATIVE PATHOLOGY OF THE ZOOLOGICAL SOCIETY OF PHILADELPHIA By Herbert Fox, M D, Pathologist Pp 60 Philadelphia, 1930

CLINICAL ATLAS OF BLOOD DISEASES By A Piney, M D, M R C P, Research Pathologist, Cancer Hospital, London, and Consulting Pathologist, Chelmsford Hospital and Stanley Wyard, M D, M R C P, Physician, Bolingbroke Hospital, and Assistant Physician, Cancer Hospital, London Price, $4 Pp 98, with 36 illustrations Philadelphia P Blakiston's Son & Company, 1930

TEXT BOOK OF PATHOLOGY INCLUDING BACTERIOLOGY, ANIMAL PARASITOLOGY, LABORATORY METHODS AND LABORATORY DIAGNOSIS OF DISEASES By Dhirendra Nath Banerjee M B (Cal), M D (Berlin), Demonstrator of Pathology, Carmichael Medical College, Radiologist, Chittaranjan Hospital, Radiologist, Calcutta Polyclinic, Ltd, Author of "Cholera and Its Modern Treatment" Second edition, revised and enlarged Price, $4 Pp 646, with 314 illustrations Calcutta The Medical Bureau, 1929

REPORT OF THE MEDICAL RESEARCH COUNCIL FOR THE YEAR 1928-1929 Price, 3 shillings, net Pp 153 London His Majesty's Stationery Office, 1930

OM OPRINNELSEN TIL OG UTVIKLINGEN AV DE TUBERKULOSE SYKDOMMER TUBERKULOSENS ETIOLOGI, PATOGENESE OG PATOLOGISKE ANATOMI [On the Origin and Development of the Tuberculous Diseases The Etiology, Genesis and Pathologic Anatomy of Tuberculosis] En oversikt for laeger og studerende Av Francis Harbitz, Professor, dr med Pp 170, with 33 illustrations Oslo H Aschehoug & Company, 1930

ARCHIVES OF PATHOLOGY

VOLUME 10 OCTOBER, 1930 NUMBER 4

ADDISON'S DISEASE WITH SELECTIVE DESTRUCTION OF THE SUPRARENAL CORTEX

("SUPRARENAL CORTEX ATROPHY")*

H GIDEON WELLS, M D
CHICAGO

Most cases of Addison's disease are associated with nearly complete destruction of the suprarenal glands, usually by tuberculosis, rarely by secondary neoplasms and amyloidosis In such cases, no information is offered as to what part of the clinical picture depends on loss of cortical function and what part depends on destruction of the medulla More instructive are the relatively infrequent cases in which there is found a selective destruction of the cortical elements alone This condition, often inadequately called "atrophy" of the suprarenal glands, is apparently responsible for about one tenth of the cases of Addison's disease Thus, among twenty-eight cases observed in the Mayo Clinic and reported by Barker [1] twenty-five presented bilateral tuberculosis and three "advanced bilateral atrophy" Harbitz [2] stated that among twenty-two cases of Addison's disease examined by him, twenty showed tuberculosis and two atrophy of the suprarenal glands Brenner [3] collected the records of sixty-eight cases of Addison's disease, in thirteen, or 19 per cent, of which "atrophy" of the suprarenal glands was responsible But many series of cases of Addison's disease have been reported that included no example of this atrophic condition, so that the estimate of 10 per cent is probably not far from the actual proportion

My own experience is peculiar and difficult to explain Until a few years ago, I had seen only two cases of Addison's disease unassociated with tuberculosis of the suprarenal glands, one of these was a case with severe amyloid infiltration of the suprarenals, the other was one in which both suprarenals were destroyed by metastatic melanomatous deposits and in which it was difficult to determine whether the clinical picture observed was Addison's disease or merely neoplastic melanosis In this period, according to my records and my memory, there were approximately twelve cases of Addison's disease Of the

Submitted for publication, June 9, 1930

From the Department of Pathology, University of Chicago, and the Otho S A Sprague Memorial Institute

1 Barker, N W The Pathologic Anatomy in Twenty-Eight Cases of Addison's Disease, Arch Path 8 432, 1929

2 Harbitz Norsk Mag f laegevidensk 87 371, 1926

3 Brenner Quart J Med 22 121, 1928

last nine cases of the disease examined in this laboratory, no less than six have been of the atrophic type, the other three being associated with suprarenal tuberculosis

The literature of the subject was so recently and so well reviewed by Brenner that it is unnecessary to do more than discuss his presentation, in which are analyzed forty-two of the more recently reported cases of the type under consideration He found that they could be divided into four groups In the first group, including eighteen cases, there was marked destruction of the cortex with a relatively intact medulla In these the greater part of the cortex was destroyed, and "that which remained consisted of islands of very large cells undergoing destruction," associated with varying degrees of fibrosis and round cell infiltration A second group of eight cases also exhibited a practically normal medulla with entire absence of the cortex In the third group, of eight cases, there was much damage to both medulla and cortex with considerable round cell infiltration and varying degrees of fibrosis sometimes with hypertrophy of the remaining cortical cells In the fourth group, also of eight cases, one or both suprarenal glands were missing or were replaced by a mass of fat or fibrous tissue, with marked damage in whatever surviving suprarenal tissue was found It is to be noted that in no case did Addison's disease depend on destruction of the medulla with the cortex left approximately intact, and no such case has been convincingly described, as far as I can learn [4]

The occurrence of a condition in which the cortex of the suprarenal gland is selectively damaged, leaving an abundance of medullary tissue, furnishes a valuable natural experiment demonstrating the vital importance of the cortex and proving beyond doubt that clinically recognizable Addison's disease appears whenever the cortex is destroyed, often despite the preservation of the medulla in a condition in which, as far as morphologic evidence permits one to judge, it should be able to function adequately These natural experiments on the suprarenal gland offer an unequaled opportunity for securing information on the functions of both cortex and medulla in man, and as such experiments are comparatively rare, each should be considered as carefully as possible Therefore I present such pertinent information as I have been able to collect concerning the five cases that have come under my observation

4 I agree with Brenner that the case reported by Bannwart (Frankfurt Ztschr f Path **26** 307, 1922) as Addison's disease from bilateral destruction of the suprarenal medulla by metastatic tumors with intact cortex is far from convincingly diagnosed as Addison's disease Malignant tumors of the abdominal cavity may produce cutaneous pigmentation without any involvement of the suprarenal glands

REPORT OF CASES

The first case of this series occurred in the practice of Dr Albert H Baugher, to whom I am indebted both for the clinical study of the case and for the opportunity to secure an examination of the body at the Illinois Central Hospital, where the death of the patient occurred Dr Baugher's clinical report is as follows

CASE 1—An unmarried white woman, aged 28, entered the hospital on June 3, 1923, with severe abdominal pain, nausea, vomiting, a temperature of 100 F, a pulse rate of 98, marked bronzed pigmentation of the skin and apparent cardiac insufficiency The pigmentation was especially pronounced on the face, forearms, backs of the hands, axillae, sides of the hips, knees, outer surfaces of the legs, shoulders and buttocks There was also slight pigmentation of the mucous membrane of the roof of the mouth The patient was extremely restless in bed and had alternate fits of laughing and crying The cardiac insufficiency was not observed at first, but was soon noticed The blood pressure was 110 systolic until the day of death Repeated urinalyses showed pale straw-colored urine with a low specific gravity (1 007), positive acetone and diacetic acid, and no albumin or sugar The abdomen was flat, with apparently no surgical condition present The condition persisted in gradually increasing severity, and palliative treatment did not amend it to any degree A tentative diagnosis of acute suprarenal insufficiency secondary to hemorrhage, necrosis or tuberculosis was made Epinephrine hydrochloride was given intramuscularly, 10 minims (0 6 cc) every three hours, together with dextrose and solution of sodium bicarbonate twice daily by rectum An extract of fresh suprarenal gland in salt solution was given intravenously six hours before death, with considerable improvement in the blood pressure On June 5, forty-eight hours after admission to the hospital, the patient died from progressively increasing cardiac insufficiency

Past History—In 1919, the patient had influenza and an attack of appendicitis She recovered from the latter without operation, and had several attacks later, but they were much less severe In 1922, she had her tonsils removed but noticed no change in health On April 20, 1923, she again sought medical aid on account of general lassitude, dysmenorrhea, menorrhagia and anoxemia Beginning six months prior to this date, she gradually lost vigor, feeling greatly exhausted at the end of the day, but lost no time from work During the two weeks previous to admission to the hospital she had what she termed an "epidemic cold" (These 'colds" were prevalent at this date) Her tongue was thickly furred, the temperature, blood pressure and pulse rate were normal The hemoglobin was 80 The color of the skin was that of marked anemia, but pigmentation as an index of disease was not observed at this time, although she stated that it was necessary for her to use cosmetics so that her skin would appear normal On May 1, the patient entered the hospital complaining of severe abdominal pain at McBurney's point, with nausea and vomiting She was poorly nourished, the temperature was 100 F, the pulse rate 110, and the respiration rate 24 Severe symptoms had begun at 3 p m on the previous day Immediate operation revealed an acute gangrenous condition of the appendix, which was distended with foul pus A plastic exudate was found about the appendix, and its mucosa was hemorrhagic and necrotic The patient s pulse rate while she was in the hospital recovering from the appendectomy remained for the most part between 90 and 100, but before the time of discharge it became stabilized at about 80 Aside from the pulse rate, nothing unusual was noticed in regard to the recovery of the patient,

and she was discharged on May 16 At this time the blood pressure was 110 systolic and 85 diastolic

Family History—The patient's father, mother, one brother and two sisters were healthy, except that one sister had an extremely toxic goiter, with marked mental and nervous disturbances, and was considerably improved by a bilateral superior polar ligation and by a later subtotal resection

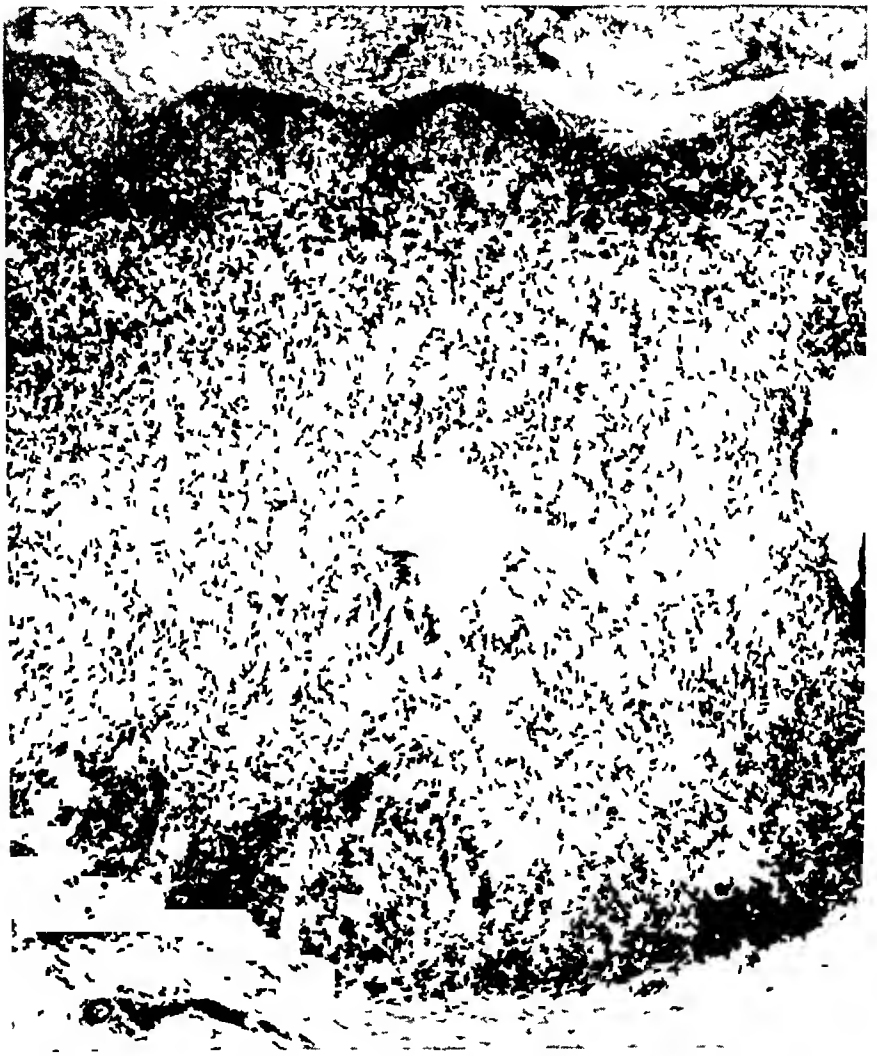

Fig 1—Selective necrosis of the suprarenal cortex with preservation of the medulla (case 1) The medulla, seen about a central vein, shows no noticeable change from normal The cortex is completely disorganized It is indicated only by the dark outer zone, which exhibits no recognizable cortical structures, their place being taken by dilated blood spaces giving the dark color, × 60

Necropsy—The body was examined by Dr E R Long Unfortunately, the opening of the body was limited to a small abdominal incision, and there were other restrictions that prevented a complete examination The general nourishment was fair, and there were no external abnormalities beyond the scar of a recent appendectomy and a brownish pigmentation, most marked on the face,

forearms, backs of the hands, axillae, sides of the hips and knees and outer surfaces of the lower extremities, shoulders and buttocks There was but slight pigmentation of the oral mucosa

The abdominal viscera were normal, except for the absence of the appendix and the presence of a few small cysts in the ovaries Only the suprarenal glands showed marked changes They were greatly and equally reduced in size, each weighing 1 1 Gm They were dark, and the cortex could not be distinguished, except for a few small nodules of the color of cortical substance, each about 1 mm in diameter The right suprarenal gland measured 44 mm long, 8 mm wide and from 1 to 2 mm thick The left was of about the same size

Microscopically, the abdominal organs showed no marked changes Unfortunately, it was not possible to obtain the thyroid gland or the thymus The intestinal lymphoid follicles showed no marked hyperplasia The suprarenal glands were both greatly reduced in size because of an extreme loss of cortical substance (fig 1) The cortex contained only a few groups and columns of cortical cells, and these had an unusually homogeneous cytoplasm without the usual granular or vacuolar appearance The nuclei were mostly small and deep-staining Some of the cells were extremely large, as if hypertrophied Considerable areas of the cortex showed no cortical cells, their place being taken mostly by dilated capillaries There was a slight diffuse infiltration of the cortex with round cells, but little evidence of fibrosis The loss of cortical material seemed to be chiefly through selective necrosis of the cortical cells with absorption rather than through any severe inflammatory process In places, traces of the necrotic cells still remained, but generally they had been replaced by dilated capillaries and round cells Seldom were polymorphonuclears found The large number of lymphocytes present in the cortex were not so arranged as to suggest a syphilitic process, and there was no formation of scar tissue The medulla was approximately as thick as normal and showed little change, except that it exhibited several round cell accumulations Chromaffin material was scanty The large blood vessels and the capsule showed no changes The lesions gave no suggestion of tuberculosis, either old or recent Sections from both suprarenals showed similar pictures

Apparently, some agent had led to a specific, selective injury of the cortical epithelium The process seemed to be recent, not all the necrotic material having been removed nor all the cortex destroyed, and little or no evidence of regenerative proliferation being present The destruction of the cortical parenchyma cells, with absorption of the necrotic material and its replacement by dilatation of the preexisting capillaries, resembled in all essentials the changes seen early in toxic necrosis of the liver (miscalled "acute yellow atrophy"), and the later stages of the two processes, as seen in the following five cases, are also of the same character

CASE 2—A woman of 62, a music teacher, whose father was still living at 94, but several members of whose family had died of tuberculosis, had never been strong, but had had no serious illness About fifteen years before, she had night sweats for a period, leading to a suspicion of tuberculosis She rested for a year, with apparently complete recovery and no recurrence of this symptom About two years before death, she began to lose vigor, felt tired and noticed that her skin was slightly yellowish brown One year before, she had an intestinal disturbance, with diarrhea, diagnosed as "intestinal flu," which kept her in bed two or three weeks Six months later, she had an acute infection of the upper part of the respiratory tract, which kept her in bed for several weeks Following this there was a gradual loss of weight Again three months later, she caught

cold, and this time vomiting was a conspicuous feature, and for several weeks before death was of daily occurrence

On examination, three weeks before death, she exhibited marked asthenia, acetone breath and a generalized brownish pigmentation of the skin, especially on the flanks and around the external genitalia, with many dark spots scattered over the face and body The maximum blood pressure was 90 systolic and 70 diastolic in the left arm, and 75 systolic and 60 diastolic or lower in the right arm, where it sometimes could not be obtained The basal metabolism was —29 6 per cent The urine contained albumin, many casts and much acetone Sugar tolerance was increased Acute cystitis and the terminal rise in temperature developed Whole suprarenal gland and an extract of suprarenal cortex were given, without improvement, except a rise in the basal metabolism to —8 and —16

Necropsy—Necropsy, performed sixteen hours after death, revealed conditions indicated by the anatomic diagnosis as follows Addison's disease, with extreme atrophy of the suprarenal glands, slight pigmentation of the skin and gums, aortitis, with a slight aneurysmal dilatation of the ascending aorta and atheroma in the descending aorta, bicuspid aortic valves, with slight diffuse endocarditis fibrosa, fatty infiltration of the wall of the right ventricle, anomalous origin of the left carotid from the innominate artery, brown atrophy of the myocardium, slight chronic glomerulonephritis, slight hyperplasia of the lymph follicles of the colon, healed calcified tuberculosis of the right bronchial lymph nodes, bilateral focal adhesive pleuritis, early acute seropurulent pericarditis, small parovarian cyst, anomalous left suprarenal and renal veins, slight hypostatic pulmonary congestion and edema, lymphoid infiltration of the thyroid, atrophic liver and spleen, and acute esophagitis

The chief observations of interest were the following

The body was slender, but not emaciated There was a distinct brownish-purple pigmentation of the gums, but not of the classic Addisonian type There was a pigmented light brown area in the skin of the upper part of the abdomen in an area about 5 cm in diameter On the sides of the arms, medial thighs and cheeks were small areas of brown pigmentation resembling freckles There were a few scattered patches or freckles over the arms and wrists and a few over the back The superficial lymph nodes were not enlarged The thymus had been replaced by adipose tissue, with no visible remains of thymic tissue The thyroid gland was slightly enlarged and firm and seemed to have little colloid It was slightly nodular and apparently hyperplastic, weighing 60 Gm

The left suprarenal gland was very small, weighing about 4 Gm and measuring 50 mm in length, 15 mm in width and from 2 to 5 mm in thickness It was deep brownish red There were no adhesions or indurations The right suprarenal was even smaller, weighing 2 Gm and being reduced to a thin membrane 27 mm long, 15 mm wide and less than 1 mm thick

Microscopically, the right suprarenal showed many portions in which all the glandular elements had disappeared, only the collapsed fibrous capsule remaining, with the sides in intimate apposition, except for blood spaces and a few small round cells But in considerable areas the medulla remained, either normal or infiltrated with lymphoid cells and in contact on each side with the capsule (fig 2) There was some increase in mature fibrous tissue about the central vein, which otherwise was normal There were also small islands of cortical epithelium, which was far from normal in appearance The normal parallel arrangement of the cells, with the different zones, was entirely lost The cortical cells were in strands or rows of irregular size, contour and direction Often the cells were of remarkably large size, with granular or vacuolated cytoplasm,

again the cells were small, with compact cytoplasm, resembling liver cells They contained a slight amount of yellowish pigment, not present in the medulla The nuclei also varied greatly in size and intensity of staining, some being very large Between these cortical islets were varying numbers of lymphoid and connective tissue cells and a delicate fibrous stroma

The left suprarenal differed from the right in having no loss of medulla and more of the atypical cortical epithelium remaining (fig 3) In its bizarre structure, this epithelium recalled the appearance of regenerating liver tissue after acute toxic necrosis, and undoubtedly represents a process of regeneration or



Fig 2—In this cross-section of the suprarenal gland intact medullary tissue is seen about a central vein (case 2) There is no cortical tissue, the fibrous capsule on each side lying in direct contact with the medullary substance Slight lymphoid infiltration of the medullary tissue is to be seen, × 85

compensatory hypertrophy of the surviving cortical cells[5] The suprarenals in this case showed more increase in fibrous tissue and less lymphoid infiltration than did those in the other four cases

5 The extreme deviation from normal that such regenerating cortex cells may exhibit is indicated in the article by Steinbiss (Virchow Arch f path Anat **262** 286, 1926), which describes what seems to be an extreme case of this type under the title of "Ueber eine eigenartige Degeneration der Nebennieren bei Addisonscher Krankheit"

The thyroid gland presented a most remarkable degree of lymphoid infiltration, some sections being scarcely recognizable as thyroid gland tissue (fig 4) At least two thirds of the tissue was composed of lymphoid elements, forming well defined lymph follicles with germinal centers which often exhibited marked karyorrhexis The remaining acini were small and seldom contained colloid It is significant that in this case, which exhibited a maximum degree of lymphoid infiltration of the thyroid gland, there was nothing elsewhere resembling status

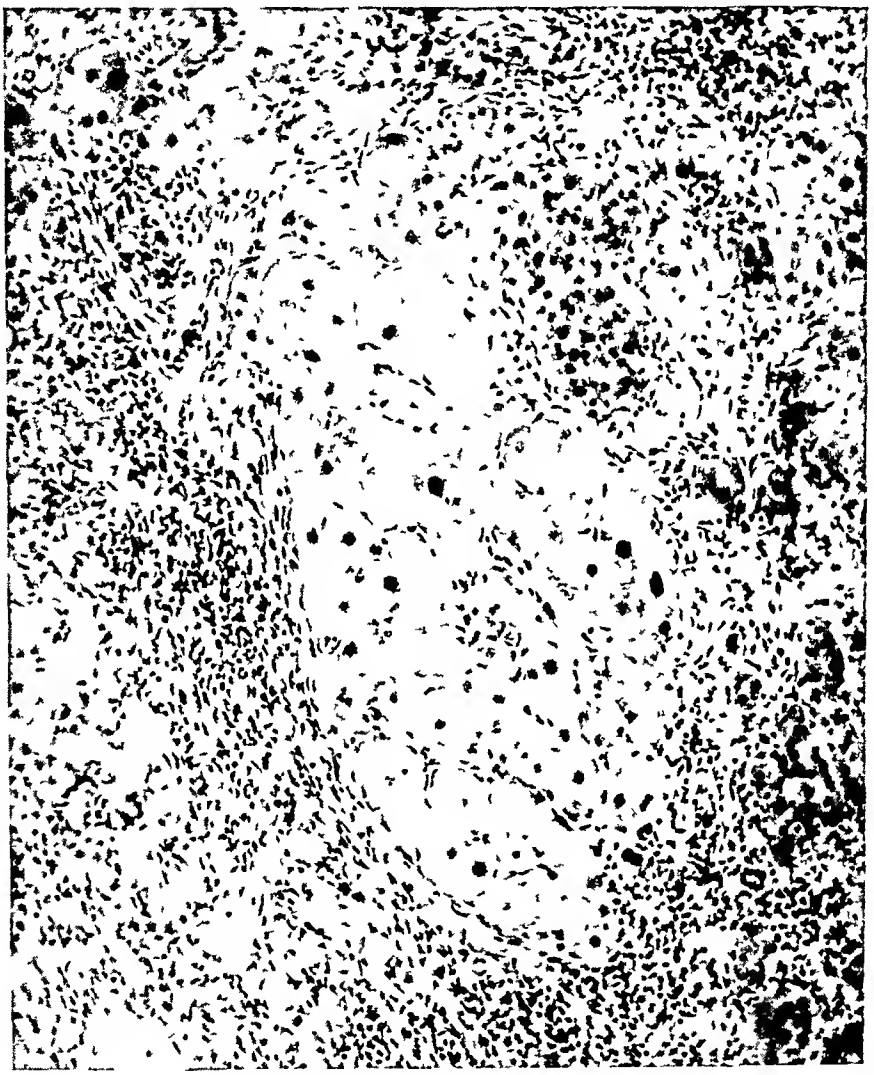

Fig 3—Regenerative hyperplasia of persisting cortical epithelium, seen to greater or less degree in all the cases of this series (from case 2) Two types of proliferating cortex cells are seen one extremely large, often with hyperchromatic nuclei, the other much smaller than normal, seen here adjacent to the group of large cells There is also diffuse infiltration with small round cells, × 150

lymphaticus The lymph nodes were not hyperplastic, and there was almost no lymphoid tissue in the thymic area Also, the suprarenals showed less lymphoid infiltration than in any of the other cases Apparently, the lymphoid infiltration of the thyroid and suprarenal glands of this type of Addison's disease cannot be looked on as merely a part of a general status lymphaticus

CASE 3—A chauffeur, aged 21, was extremely ill with nausea and vomiting and profoundly prostrated, when first seen by his physician, Dr Chester Guy, on Jan 29, 1929 He stated that he had been troubled with attacks of vertigo, nausea and vomiting for two years This condition had been much worse for the last two months, during which he had lost 20 pounds (9 Kg) in weight, with increasing severity of the other symptoms

His previous history included no other illnesses, except influenza The father was a chronic alcoholic, the mother had had cerebral thrombosis at the age of 40, and had chronic arthritis, one sister was living and well, but another sister was of the asthenic, visceroptotic, hypotensive type, a brother died at the age

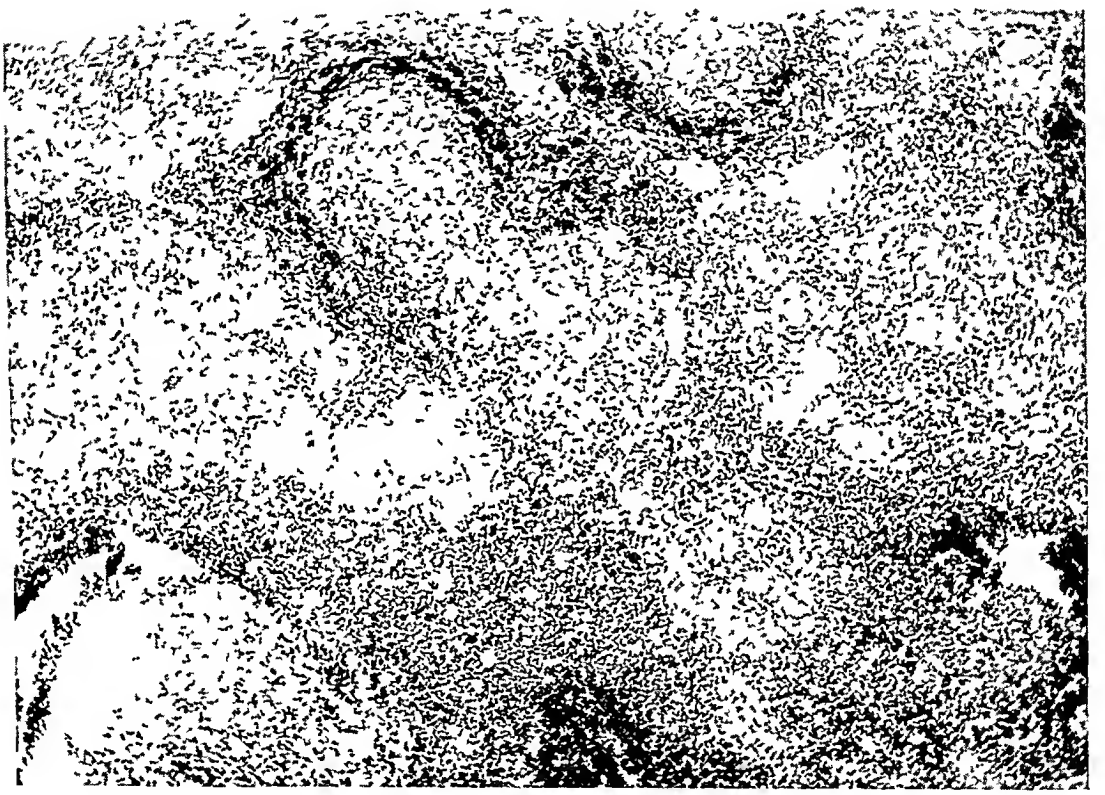

Fig 4—Invasion of the thyroid gland by lymphoid tissue as seen in the cases of this series (case 2) In the field covered by the photograph, only occasional atrophic thyroid acini can be detected in a solid mass of lymphoid tissue The lymphoid tissue presents well developed germinal follicles, so that the picture bears no resemblance to thyroid tissue, × 85

of 18 from 'rheumatism" Nothing could be learned as to habits or past episodes that threw any light on the existing condition

When examined, the patient complained of being cold, and his temperature was subnormal The blood pressure could not be recorded because of the circulatory weakness Physical and laboratory examination revealed little beyond a slightly brownish tinge of the skin without localized pigmentation in either the skin or the oral mucous membrane, a marked dehydration, and albumin and casts in the urine A clinical diagnosis of Addison's disease was made Death occurred the next day, January 30, without further developments

Necropsy—The postmortem examination by Dr E R Long revealed the abnormalities indicated in the anatomic diagnosis, which was as follows profound atrophy of the suprarenal glands and moderate diffuse pigmentation of the skin (Addison's disease), moderate hyperplasia of all abdominal lymph nodes and the lymphoid follicles of the ileum, lymphoid infiltration of the thyroid gland, complete atrophy of the thymus, small scattered scars in the lungs, and hypostatic congestion of the lungs

Fig 5—Complete disappearance of both cortex and medulla, the opposite layers of the fibrous capsule of the gland being here separated by a narrow zone of small round cells with a few endothelial and connective tissue cells (case 3) In other parts of this gland, islands of medullary tissue remain, but no cortex cells, × 150

The skin was generally slightly brown, most markedly so over the abdomen and the inner aspect of the thighs, but there were no areas of marked pigmentation There was no evidence of active tuberculosis The thyroid gland was not enlarged and showed no macroscopically visible alterations

No definite thymus tissue could be recognized in the adipose tissue of the anterior mediastinum, even microscopically Apparently replacing the lymphoid elements were islands of vascular adipose tissue of embryonal type with moruloid fat cells

The lymph nodes in general were not noticeably enlarged, although the malpighian bodies in the spleen and the solitary follicles of the ileum were more prominent than usual, with but slight enlargement of Peyer's patches and none in the lymph follicles of the colon All other organs seemed normal, except the suprarenal glands

The left suprarenal was so extremely small that it could hardly be recognized It lay above the kidney and weighed probably not over 1 Gm The cortex of this suprarenal could not be distinguished The right suprarenal was similar to the left, but smaller, weighing from about 0 5 to 1 Gm The cortex and medulla could not be distinguished The two organs lay in dark adipose tissue There were no scars or other evidences of inflammation in the neighborhood

Microscopically, in the numerous sections examined it was found that the cells of the cortex had completely disappeared In some places, the blood vessels of the cortex remained and between them were a few cells, apparently endothelial and connective tissue cells and lymphocytes, in many places large accumulations of lymphoid cells having replaced the original cortical epithelium There was no evidence of tuberculosis or acute inflammatory changes, nor of old or recent hemorrhage The vessels were not thrombosed or sclerotic There was little if any increase in fibrous tissue, the original stroma remaining unaltered The suprarenals were almost exactly alike In most of the sections, little remained even of medulla, the normal-appearing fibrous capsule having collapsed so that both sides were in apposition for some distance and elsewhere were separated only by blood spaces and small round cells with no trace of glandular elements (fig 5) Some complete transverse sections of the suprarenal showed only small areas of medullary tissue, generally heavily infiltrated with lymphoid cells Frequently, the lymphoid accumulations were large and formed masses a millimeter in diameter, without any evidence of a formation of germinal centers In other sections, large areas of the medulla were well preserved and seemed normal, except for absence of recognizable chromaffin substance As nearly as can be estimated, less than one fourth of the original medullary tissue remained

The only cortical cells found were in a small accessory suprarenal about 2 mm in diameter, which consisted chiefly of lymphoid cells, an island of medullary tissue and a few small groups of cortical cells separated by stroma elements These cells did not show the regenerative hypertrophy often seen in cases of this type

The thyroid gland showed replacement of about 25 per cent of its substance by lymphoid tissue, which existed chiefly in the form of well defined follicles with conspicuous germinal centers that sometimes exhibited karyorrhexis Some diffuse lymphoid infiltration was also shown, and in some lobules diffuse increase in the interstitial connective tissue Some lobules appeared nearly normal, but most of them exhibited lymphoid infiltration In these lobules, the acini were small and poor in, or devoid of, colloid

The lymph nodes showed a marked increase in lymphoid cells with obscuration of the architecture The germinal centers were not conspicuous The nodes showed a markedly nodular surface of mulberry type The lymph vessels in and about the capsule were often packed with lymphocytes As stated previously, not a trace of the lymphoid tissue of the thymus body remained, the thymus was completely replaced by fat

CASE 4—The course of the disease in case 4 was studied with unusual thoroughness, as the patient, a woman, aged 51 at the time of her death, was under observation for more than four years, and being a person of education and intelligence, gave careful attention to the progress of her condition She kept an elaborate record of her symptomatology, which will be recorded more fully elsewhere by the clinicians who cared for her, as it is a unique clinical record

History and Course—The family history revealed only a tendency to obesity and hypertension in both the paternal and maternal lines and the death of the father from carcinoma of the cecum The patient had an attack of bronchopneumonia ten years previously, otherwise, although weighing 225 pounds (102 Kg), she had enjoyed excellent health until four and a half years before her death Under the direction of an osteopath, she underwent a drastic course of weight reduction with a reducing diet reinforced by a series of electric baths and salt rubs During six months of treatment, she lost 40 pounds (18 1 Kg), and at some time in the course of this episode the masseuse noted dark spots on her legs The loss of weight continued until she weighed 170 pounds (77 1 Kg) About one and a half years later, she began to notice that she became fatigued easily, had pain between the shoulder blades and was undergoing a deepening of the color of the skin At this time, twenty-seven months before death she consulted Dr Wilber E Post, who found her blood pressure 102 systolic and 60 diastolic Whole suprarenal gland tablets were given, apparently with some relief However, the pain between the shoulder blades continued, and later stiffness in the joints developed Five months later (Nov 27, 1927), she entered the Presbyterian Hospital At this time, it was noticed that the skin was wrinkled as if there had been a loss of weight Her knees, shins, backs of the hands and finger nails, especially, were brown and black, with black speckled areas of darkened pigmentation There were black areas on the lips and gums The areolae of the breasts were hyperpigmented There was increased dulness on the right side posteriorly from the sixth rib downward on the left There were no râles The heart was normal in outline and sound The abdomen was normal There were scales on the anterior portion of the tibia and an area of scarring on the right knee The pelvis showed retroversion and rectocele with blackened vaginal mucous membranes The chest was normal There was tenderness in the upper left quadrant, with pain radiating to the neck when pressure was applied The patient was discharged on Dec 7, 1927, with the diagnosis of Addison's disease

She continued to take suprarenal tablets until the latter part of January, 1928, when suddenly they caused her to become nauseated She vomited bile and all the food that she ate She then changed to pituitary tablets for two weeks, which did not make her ill, then she changed to Rogoff suprarenal extract for six weeks, which gradually began to cause nausea She took no suprarenal extract for two weeks and then tried Rogoff's extract once more for from three to four weeks On April 1, 1928 the blood pressure was 108 systolic and 68 diastolic

Since Nov 1, 1928, she had pains low in the back These started at the hips and ran down to the sides of the knees, chiefly on the right The pain appeared chiefly at night, rarely before midnight, and occurred every night She had visual and auditory hallucinations, including those of burglars and ghosts The patient thought, however, that she was better than one year before, in spite of the increased pigmentation of her skin At this time, the blood pressure was 115 systolic and 70 diastolic, the basal metabolism was +12, and the other laboratory observations were essentially normal The pigmentation had become general and

unusually marked for Addison's disease, so that her color was that of a full-blooded negress of medium brown type

In January, 1929, she entered the Billings Hospital At this time, the blood pressure was 100 systolic and 68 diastolic She was weak, becoming exhausted on walking from 50 to 100 yards (from 45 7 to 91 4 M), and she complained much of pain in the pelvis and left lower extremity Roentgenograms showed moderate hypertrophic arthritis of the spinal column The basal metabolism was recorded as + 1 on January 29, on February 11 it was + 3, and on March 1, — 18 She began taking Koehler's extract of suprarenal cortex, but no evident improvement resulted At times there was much nausea The blood pressure continued at about 100 systolic and 65 diastolic with slight variation during her stay in the hospital until Feb 8, 1929

During the last two years of life, the pigmentation of the skin, which had before then become unusually dark, slowly and progressively faded, although it was still very noticeable at the time of death There were dark areas in the oral mucosa, especially at the midline of the palate and on the buccal mucosa opposite the gums and teeth

After leaving the hospital, she remained at home under the care of a nurse until her death The final illness began three weeks before death, with collapse, sweating and marked relaxation This was followed by a period of delirium Neurologic examination showed disturbed reflexes and a bilateral positive Babinski sign, together with other evidences of a lesion of the spinal cord This cleared up completely in forty-eight hours Altered reflexes were transiently present at intervals following this During the last week, the patient was delirious and violent, with intermittent rational phases There were phases of delusion and times when the patient would start and scream at the slightest touch The temperature rose during the last week and reached 105 F before death

Necropsy—The anatomic diagnosis as obtained at necropsy was as follows Addison's disease, extreme atrophy of both suprarenal glands, diffuse melanotic pigmentation of the skin of the entire body and of the oral and vaginal mucous membranes, slight cardiac atrophy, bilateral diffuse hypostatic pulmonary edema, with diffuse mucopurulent bronchitis, chronic interstitial inflammation of the lungs, terminal septicemia, with ecchymoses in the pleura and pericardium and in the mucosa of the cecum, acute splenic tumor, acute parenchymatous swelling of the liver and kidneys, with slight fatty changes in the liver, acute cerebral edema, acute hyperplasia of the peribronchial lymph nodes, slight edema of the ankles, two diverticula in the duodenum, adhesions about the gallbladder, two fibroid tumors of the uterus, old scar on the outer aspect of the right thigh, marked thickening of the frontal bone, with eburnation, marked adhesions between the dura and the calvarium, absence of axillary hair, and scantiness of pubic hair

The postmortem observations of particular interest in relation to Addison's disease were as follows

The skin was a uniform brown color, slightly darker over the lower extremities than over the body proper The color was about that of a mulatto—somewhat on the order of cafe-au-lait The areolae were deeply pigmented There were no axillary hairs The pubic hairs were extremely scanty There was no linea gravidarium, but there were transverse atrophic striae at the umbilicus and at a point 4 cm above There was a uniform pigmentation of the mucous membranes of the mouth, comparable in tint to the pigmentation of the skin The tongue and tissues of the pharynx were edematous The thyroid gland was of normal size, weighing about 35 Gm , it was free from nodules, and the cut sur-

face showed no abnormalities beyond a poverty in visible colloid No traces of thymus tissue could be found

On first inspection, no trace of either suprarenal gland was seen in the abundant perirenal fat By following the course of the suprarenal veins, the outlines of the capsules were seen There was no recognizable cortical tissue, merely a small amount of dark substance separating the fibrous capsule on each side The right suprarenal was triangular The suprarenal vein left the organ at the medial angle after a course along the long inferior margin This margin was adjacent to the kidney and formed the base of the triangle The apex pointed cranialward The base was 44 mm, the lateral border 34 mm, the medial 29 mm and the right 17 mm The thickness varied between 1 and 2 mm The weight was 1 2 Gm The left seemed to be about the same size, although longer and thinner, and its cut surface resembled the right

The ovaries seemed normal The vaginal mucosa was diffusely brownish blue The pineal and pituitary glands were of normal size and appearance The frontal bone was much thickened (12 mm) and was composed of dense, hard osseous tissue, but was not abnormally adherent to the dura The other skull bones were not similarly affected The brain tissue was edematous, but no other significant cerebral changes were found The microscopic changes were those characteristic of this type of Addison's disease

A cross-section through the center of the right suprarenal gland showed that little remained besides the capsule This was somewhat thicker than normal and through most of the section the two layers of capsule lay almost in apposition, separated only by the central vessels and a few round cells Occasionally there were small groups of large cells in short cords, not vacuolated like cortex cells and often containing an abundance of brown pigment Occasionally these cells had extremely large, irregular nuclei There was one island of tissue about the size of a 16 mm objective field that seemed to be medullary tissue, which lacked chromaffin There was no typical cortex tissue in this section In places there were large groups of lymphoid cells with occasional larger mononuclears, but no evidence of either granulation or scar tissue No acute inflammation was seen, although there were a few polymorphonuclears infiltrating the capsule There was considerable granular yellow material in the central space looking as if it might be unabsorbed pigment from the original glandular tissue It was not contained in phagocytes and did not resemble hemosiderin There was no evidence of old hemorrhage or thrombosis The large central blood vessels had a free lumen throughout despite their being collapsed In other words, nearly all the glandular elements, both medullary and cortical, had vanished from this suprarenal gland, leaving little to take their place beyond the original vessels and stroma and some infiltrated lymphoid cells

Sections taken through several parts of the left suprarenal gland exhibited much more persisting medullary tissue and more large cells arranged in cords which looked like cortex cells, except that they commonly contained much of the brown pigment that is usually seen in the medulla and they were not vacuolated with lipoids to any marked degree The large size of these cells and their occasional giant nuclei suggested compensatory hypertrophy There were also foci of dense infiltration with small round cells There was a small nodule outside the capsule that apparently was originally an area of accessory cortical tissue This contained a few scattered parenchyma cells looking somewhat like those found in the rest of the gland, but with less pigment In various sections of the suprarenal gland were some cells that seemed to be necrotic cortex cells, suggesting

that a process of regeneration and necrosis was still going on to a slight degree The adipose tissue outside the suprarenal showed slight intercellular edema, and in places islands of primitive adipose tissue could be made out, as the cell structure was not completely obliterated by fat The adjacent large sympathetic ganglions showed no recognizable changes

The thyroid gland showed marked infiltration with lymphoid tissue, often forming well defined lymphoid follicles with large active germinal centers in

Fig 6—The characteristic lymphoid infiltration of the thyroid gland (case 4) In this case, as was the rule, the process is most marked beneath the capsule, the lymphoid tissue invading the thyroid to varying depths, the most central portions showing the least change, although not usually entirely free from lymphoid cells, × 60

which were occasional mitotic figures (fig 6) The thyroid tissue was poor in colloid, the majority of the acini containing no colloid and that which remained was greatly vacuolated, as if undergoing absorption The epithelium was usually large and cuboidal Some of the acini contained masses of large cells, more

resembling endothelium than epithelium The arteries were not noticeably sclerotic There was also much lymphoid infiltration in and about the capsule One small accessory thyroid gland was found, presenting the same lymphoid infiltration as the thyroid gland itself

Several small bodies resembling parathyroids in size and location were dissected out All of these proved to be lymph nodes, except one parathyroid about half replaced by adipose tissue, but otherwise normal It did not exhibit the lymphoid infiltration seen in the thyroid gland

The pineal gland seemed somewhat more cellular and of more juvenile appearance than is usual for the age, otherwise it seemed essentially normal The hypophysis seemed to be entirely normal

In the spleen there were no marked changes, although the malpighian bodies were larger and more cellular than usual for the age, with slight hyaline changes in the center

Although the lymphoid tissues were not noticeably enlarged on gross inspection, the small lymph nodes exhibited a distinct increase in the amount of lymphoid cells

Case 5 —A woman, aged 40, a patient of Dr R K Packard at the Woodlawn Hospital, was referred to the University Clinics A history was obtained of progressive weakness for three months, without confinement to bed, loss of 14 pounds (6 4 Kg) weight in this period, and a darkening of the skin, which was described as "lemon-colored" There was pain in the lower lumbar and sacral regions, and for the last days of life much nausea and vomiting In the past, the patient's health had been excellent, except that six years before she had been injured in an automobile accident She was under observation at the Woodlawn Hospital for three weeks before death, during which she showed continued nausea, vomiting, weakness and some increase in the pigmentation

When admitted to the Billings Hospital, about thirty-six hours before death, she was in an acidotic condition, with reflexes absent, blood pressure 50 systolic and 20 diastolic, blood sugar normal, urine normal, except for a few hyaline casts, and red cell count 3,100,000 She went into coma, with the temperature rising to 105 F before death

Necropsy—The postmortem examination was made twelve hours after death by Dr P R Cannon The anatomic diagnosis was as follows bilateral atrophy of the suprarenal glands, with diffuse generalized pigmentation of the skin and buccal surfaces (Addison's disease), generalized atrophy and golden-yellow coloration of the fatty tissues, atrophy and lymphoid infiltration of the thyroid gland, segmentation of the cardiac muscle, chronic fibrous and calcific mitral endocarditis, hypostatic hyperemia and edema of the lungs with compensatory emphysema, bilateral serofibrinous pleuritis, slight ascites, petechial hemorrhages in the pericardial sac and visceral pleurae of both lungs, acute gastritis with confluent hemorrhages in the fundus of the stomach, marked edema of the serosa of the stomach, atrophy particularly of the kidneys, heart, pancreas, liver and generative organs, marked fibrous thickening of the cortex of both ovaries, fibrous tuberculosis of the pleural surfaces of the apexes of both lungs, moderate hyperplasia and anthracosis of the peritracheal, peribronchial and pulmonary lymph nodes, and moderate osteoporosis

The pigmentation was diffuse, brownish, of moderate degree, without conspicuous dark patches There were a few patches of brown pigmentation in the buccal surfaces The lymphoid tissues were not generally increased, only a few lymphoid follicles in the rectum being enlarged slightly But little recognizable thymus tissue could be found The suprarenal glands were much decreased in

size, the left measuring 30 by 30 by 2 mm, and the right was slightly larger Their combined weight was 4 Gm In sections, no recognizable suprarenal substance could be seen, the appearance being that of a fibrous wall about a cavity

The thyroid gland was extremely small, weighing but 10 8 Gm, and containing little colloid and no nodules

Microscopically, the suprarenals showed almost complete loss of the cortical elements, and apparently less than half the medullary tissue remained In large areas, the capsule, which was somewhat thickened, lay in direct contact with the medulla, there being no remnant of cortex to be found The medulla showed much infiltration with lymphoid cells, which in some areas completely replaced it, but there were many parts of the medulla that seemed to be normal In some portions, the cortex had been replaced by connective tissue elements with abundant hyaline intercellular substance so arranged as to suggest that this represented merely a compensatory hyperplasia of the original stroma elements to replace the lost cortex No vascular changes or evidences of tuberculosis were found There were occasional small groups of cortex cells, sometimes in nearly the normal arrangement in cords, sometimes entirely disarranged These cells were not foamy and often were small and atrophic The total amount of cortex left could not have been more than 1 or 2 per cent of the normal volume No evidence of regenerative or compensatory proliferation was seen

The lymph nodes showed a slight but distinct hyperplasia of the lymphoid elements, but less than is usually seen in Addison's disease Nevertheless, the thyroid gland showed a marked lymphoid infiltration, although less than in the other cases of this series This seldom reached the extent of forming well developed follicles with germinal centers, but in some of the lymphoid areas were groups of unusually large cells with more abundant and more granular cytoplasm than is usual in endothelial cells, and often with large atypical nuclei Such cells were not found in the thyroid glands in the other cases There was little colloid, many lobules contained none, being composed of small collapsed acini and lymphoid cells Two small accessory thyroids, each about 2 mm in diameter, showed the same atrophy and lymphoid infiltration as the thyroid gland The parathyroids showed no lymphoid infiltration and seemed normal, except for marked dilatation of the vessels

Case 6—On May 12, 1930, a woman, aged 47, in extremis, was admitted to the University Clinics She had been vomiting frequently for twenty-four hours, after having been in bed for a week because of nausea and weakness In 1922, she had suffered from a period of illness of unknown nature, characterized by extreme nervousness, dizziness, loss of appetite and loss of from 8 to 10 pounds (from 3 6 to 4 5 Kg) in weight, without localizing pain This lasted about two years Thereafter she had never been well and strong About three months before death she fell and fractured two ribs, after which the weakness began to increase, but no increased pigmentation was noticed by the members of her family A few weeks following her fall, two teeth were extracted under procaine hydrochloride, after which the weakness seemed to increase For the lassitude, she consulted a physician, who gave her iron preparations and on April 9 an injection of sodium cacodylate

When admitted to the hospital, the patient was too ill for complete examination The temperature was 95 F, the pulse rate was 70, and the blood pressure was 80 systolic and 52 diastolic A diffuse slight cutaneous melanosis was present, and a little pigment was seen along the midline of the palate The red count was 5,223,500 The urine contained albumin The next day, the blood pressure could not be obtained, but on the day of death the systolic pressure was

from 55 to 60 Despite intravenous injections of dextrose, the condition grew progressively worse, and shortly before death the temperature rose to 104 2 F

Necropsy—The necropsy was performed one hour after death by Dr Paul R Cannon The anatomic diagnosis was as follows bilateral atrophy of the suprarenal glands, brownish pigmentation of the skin, hypoplasia of the cardiovascular system and partial persistence of the thymus (clinical Addison's disease), bilateral hypostatic hyperemia and edema of the lungs, bilateral focal fibrous pleuritis, atrophic emphysema, bilateral fibrous tuberculosis of the lungs, moderate hyperplasia of the spleen, chronic pericholycystitis, bilateral fibrous perisalpingitis, chronic fibrous endocervicitis, necrotic and suppurating uterine fibroid, healed fractures of the right tenth and eleventh ribs, moderate atherosclerosis, lymphoid hyperplasia of Peyer's patches in the ileum, and lymphoid infiltration in the thyroid gland

The chief observations of interest were that the skin was slightly and diffusely brown, except for a single small spot of brown pigment on the left breast The lymph nodes and lymph follicles of the intestine were not enlarged, although the spleen was slightly enlarged (200 Gm) with visible follicles The thyroid gland was small and poor in colloid, and weighed but 13 7 Gm No active tuberculosis was found anywhere The bone-marrow of the femur was fatty with occasional islands of hematopoietic tissue There were healed transverse fractures of the posterior portion of the right tenth and eleventh ribs

The suprarenals were extremely small, the right weighing 1 5 Gm and the left 1 4 Gm There was no induration or adhesion of the tissues about them, and they were soft and flabby The cut surface showed merely a small amount of dark tissue separating the two layers of the capsule, there being no recognizable cortical substance

Microscopically, the changes were as follows Cross-section of the right suprarenal showed that in about one half of the gland nothing remained of either cortex or medulla, the two layers of fibrous capsule lying in apposition In a considerable portion of the remaining half only medullary tissue remained, with an exaggeration of the chromaffin material in the cells and with much round cell infiltration There were also nodules of hypertrophied cortex cells, often with large hyperchromatic nuclei Here the cell columns were irregular and atypical in shape and arrangement No change occurred in the large vessels and no inflammatory change, unless this was represented by round cells, which were numerous

The left suprarenal showed more marked cortical proliferation in this case than in any other case in this series, with the usual hypertrophic and atypical cell forms characteristic of regenerating suprarenal cortex The amount of persisting medullary tissue was not large and was characterized by an abundance of chromaffin material The amount of round cell infiltration was somewhat less than usual in these cases

The thyroid gland showed extensive infiltration with lymphoid tissue about the periphery, with formation of occasional lymph follicles showing germinal centers A striking feature was the packing of lymph vessels with lymphocytes This lymphoid infiltration was not present throughout the gland, many of the central lobules showing little or none There was generally a slight increase in interstitial fibrous tissue, and the total amount of colloid was small Many of the acini were filled with epithelial cells

The lymph nodes showed a slight increase in lymphoid elements Peyer's patches were distinctly hyperplastic, with large germinal follicles, but the mucosa elsewhere showed no general lymphoid infiltration

The thymus showed much more persisting lymphadenoid tissue than is usual for the age Hassall's corpuscles were numerous, many of which were very cellular From one half to one third of the thymic body was composed of lymphoid tissue

The striated muscles showed numerous hyaline muscle fibers, and in general the normal striations were poorly preserved

COMMENT

These six cases evidently represent examples of clinically typical Addison's disease, diagnosed as such before death, associated only with marked selective loss of suprarenal tissue, especially of the cortex, and independent of tuberculosis or other known agency In the first case, the process seemed to be somewhat more recent than in the others, and indicated that the essential underlying event in all these cases was a selective necrosis of the cells of the suprarenal cortex, with much less visible injury to the elements of the medulla All the other changes seen in these suprarenals seemed to be secondary to such a selective necrosis of the cortical epithelium and consisted of inadequate attempts at regeneration of the cortex by proliferation and hypertrophy of the few cortical cells left with sufficient vitality to make these regenerative efforts There was also a variable amount of loss of medullary tissue, but it was never so marked as that of cortex It is impossible to tell whether this partial loss of medullary tissue was accomplished in the same way as the cortical damage, or whether it may not have been the result of the extensive lymphoid infiltration that has followed the destruction of the cortex There was surprisingly little formation of fibrous tissue in these suprarenals, which supports the other evidence that the primary change was not an inflammatory process Another definite negative observation was that of the absence of any injury or occlusion in the suprarenal blood vessels

The resemblance to the changes seen in "acute yellow atrophy" of the liver was striking There was the same apparent selective necrosis of the glandular epithelium, followed by the appearance of large, atypical cells in the process of regeneration and compensatory hypertrophy There was also a marked infiltration with small round cells of lymphoid character In the liver, however, connective tissue growth is more marked after extensive necrosis than appeared to be the case in these suprarenals

The similarity of the changes in "suprarenal atrophy" and "acute yellow atrophy" of the liver suggests a similarity in etiology It seems to be well established that the latter depends on extensive damage to the liver cells by toxic agents, which may be of most varied character and origin having only in common the capacity to destroy a large proportion of the liver cells without producing a lethal injury in other tis-

sues In some cases, the toxic agent is definitely known, in more it is not and in some cases it seems probable that the severity of the damage depends rather on an unusual susceptibility of the liver cells to the poison than on the amount or quality of the poison In each case, a selective necrosis of the functional epithelial cells occurs with a minimum amount of injury to other cells, followed by absorption of the dead cells, attempts at regeneration and compensatory hypertrophy by the survivors, and death from loss of the specific functioning cells of the organ The fact that in this type of Addison's disease both suprarenals are usually involved in the same way and to about the same degree supports the view that the changes depend on some agent entering through the circulation I believe that the known facts justify as the best designation for this type of suprarenal lesion the term adopted by Kovacs,[6] "cytotoxic suprarenal contraction" rather than "suprarenal atrophy," just as the term "diffuse toxic hepatic necrosis" is to be preferred to the misleading name "acute yellow atrophy" Kovac's views are summarized by Omelskyj [7] as follows

> The conception of the cytotoxic contracted suprarenal concerns a hematotoxic injury selectively affecting the cortex of the suprarenal, while the medullary substance practically escapes Because the unknown harmful agent is brought by the blood the alterations necessarily are bilateral Probably the damage is not accomplished at one time but is continued for a long time, against which loss the regenerative capacity of the suprarenal cortex is not adequate, so that the process leads to an extensive disappearance of the cortex with great reduction in size of both suprarenals The condition may be considered as one in which the cortex cells are slowly damaged, and as the vascular stroma remains unharmed it delivers exudative cells which attend to the removal of the damaged cortex cells, itself remaining and gradually increasing slightly but never being transformed into scar tissue as it is seen to do in those conditions, such as tuberculosis or hemorrhagic infarction, in which the stroma is also destroyed The less prominent medullary changes are, when present, to be attributed chiefly to secondary unfavorable effects of the adjacent, greatly damaged cortex

This conception of the condition seems to be entirely in harmony with the facts observed in the cases of this series

In none of these six cases was there any known episode or condition to account for the destruction of the suprarenal cortex In case 4, the disease seemed to follow a drastic course in weight reduction, but it is not possible to say that there was more than an accidental relation between the two events The first case appeared shortly after an operation for acute appendicitis but suggestive symptoms had been present before, and in case 2, there had been attacks of acute respiratory infections and "intestinal flu" Such events occur too often without any evidence of suprarenal injury to be held responsible, but it is possible

6 Kovacs Beitr z path Anat u z allg Path **79** 213, 1928
7 Omelskyj Virchows Arch f path Anat **271** 377, 1929

that they may have damaged suprarenals unusually susceptible for some unknown reason In all but one of these cases there was a definite history of influenza or some similar condition This fact suggests the possibility of an etiologic relation between influenza and Addison's disease, which would not be impressive, in view of the vast number of cases of influenza without an Addisonian sequel, were it not that it offers a possible explanation of why I have seen all of these cases in the past seven years Against this assumption is to be placed the fact that other pathologists have not as yet reported any striking recent incidence of this type of suprarenal disease

The fact that the regenerative processes, although present, are so inadequate suggests the probability that whatever the agent that destroys the cortical cells, it is continuously or intermittently supplied, so that the regenerated cells are also killed off In case 4, the process was under observation for four years, the cutaneous pigmentation decreased during the last two years, there was much microscopic evidence of regenerative activity in the remaining cortical cells, and yet the course of the patient was slowly downward Neither the carefully kept history nor the postmortem examination disclosed anything that reasonably accounted for such a long-continued destructive action on the suprarenals

Age and sex seem to play no rôle, as the cases so far reported are nearly equally divided as to sex, and they have been observed at ages ranging from 10 to 63 years Fahr and Reiche [8] reported the occurrence of Addison's disease in three brothers in one family, in two of whom the suprarenals showed the atrophic type of lesion (the third was not examined), but there was no information suggesting a common cause, whether hereditary or environmental Such familial occurrence has not been seen in the other cases reported in the literature

At times, certain cases of Addison's disease seem to have followed severe mental shock or stress, and a causal relation has been suggested For example, Marañon [9] reproduced as perhaps the first known case of Addison's disease the description by a priest in the sixteenth century of the sickness of a young priest who died three years after the first symptoms They developed after a fright, the building in which he was was struck by lightning and burned The lay description portrays Addison's disease perfectly, but the pigmentation was ascribed to "smoke getting into the system during the fire" Marañon cited modern instances of an emotional origin One of his patients developed the disease after seeing his child killed by a street car It certainly does not seem possible that emotional shock could produce tuberculosis of the

8 Fahr and Reiche Frankfurt Ztschr f Path **22** 231, 1919
9 Marañon Siglo med **70** 605, 1922

suprarenal, and hence if there really are cases of Addison's disease resulting from mental causes or nervous stimuli they must come into the group under discussion But in none of our six cases was there recorded in the clinical history any severe emotional disturbance prior to the development of the disease, except that in case 5 the patient had been in an automobile accident six years before death and in case 6 there had been an accident with fracture of the ribs three months before death and apparently long after symptoms had begun

From the evidence obtained I can add nothing to the terse summary of Brenner 'The cause is really quite unknown"

It cannot be said that the clinical course of these cases presented any constant differences that make it possible to distinguish such cases during life from Addison's disease due to suprarenal tuberculosis In some of the cases reported in the literature it was noted that the blood pressure remained at a higher level than is usually the case in Addison's disease, until the terminal collapse This naturally was attributed to the integrity of the medulla Most of the cases, however, were not seen until the last stages, in which the blood pressure falls, as it may do in many fatal diseases In this series, only case 4 was studied for a long period and here the pressure varied from 100 to 115 systolic As a matter of fact the long course of this case, with evidence of some amelioration in the form of a markedly reduced amount of pigmentation, the persistence of the systolic blood pressure above 100 despite long invalidism, and the experience in the preceding three cases led me to hazard the prediction that this type of suprarenal disease would be found underlying the clinical manifestations Kovacs accepted the view that when the suprarenal damage is strictly limited to the cortex, the blood pressure is not greatly depressed and that the absence of this important feature from the clinical picture should remove the case from the category of typical Addison's disease and leave cases of the latter to be called cases of "suprarenal cortex insufficiency' which establish the vital necessity of the cortex while recorded cases of bilateral destruction of the medulla with intact cortex without the Addisonian cachexia demonstrate that destruction of the medulla is not the essential feature of this disease,[10] although it contributes an important clinical feature

In any case the fact that in at least some of the cases of destruction of the cortex with intact medulla the blood pressure remains at a good height suggests a reason for questioning the now prevalent acceptance of the doctrine that epinephrine is not a significant factor in maintaining the blood pressure

Changes in the Thyroid Gland—A striking feature in all these cases of Addison's disease with suprarenal atrophy was the marked infiltra-

10 The relative roles of cortex and medulla are well discussed by Omelskyj (footnote 7)

tion of the thyroid gland with lymphoid cells In all instances, this occurred not only in the form of interstitial collections of lymphoid cells, such as often are seen in the thyroid gland in other conditions, but also the formation of large areas of lymphoid tissue, frequently with well developed germinal follicles In one case, this lymphoid infiltration was so marked that most of the glandular tissue had been replaced, and the first impression on glancing at the section was of a lymph node with occasional groups of metastatic adenocarcinoma cells

This infiltration of the thyroid gland with lymphoid tissue has also been described as found in Addison's disease associated with suprarenal tuberculosis,[11] but it seems to be much less marked in this group of cases than in those with selective necrosis of the suprarenal cortex

Lymphoid Infiltration in Cases of Selective Destruction of Suprarenal Cortex and Cases of Diffuse Tuberculosis of Suprarenal Gland

Selective Destruction of Suprarenal Cortex		Diffuse Tuberculosis of Suprarenal	
Case	Lymphoid Infiltration	Case	Lymphoid Infiltration
1	+++	1	0
2	++++	2	0
3	+++	3	0
4	+++	4	0
5	+	5	0
6	++	6	+
7	+++	7	++
8	++	8	0
		9	0
		10	0
		11	+
		12	0

In order to determine whether this impression is correct I compared the thyroid glands in eight cases dependent on cortical atrophy, five of my own series and three sent me from the Mayo Clinic by Dr R G Mills, two of them having been included in Barker's series and one observed more recently I graded the degrees of lymphoid infiltration in these eight and compared them with thyroid glands from twelve cases of Addison's disease with tuberculosis of the suprarenals, of which seven specimens were furnished by Dr Mills and five from my own material

From the comparison (see accompanying table) it is evident that lymphoid infiltration of the thyroid gland is much more frequent and more marked in Addison's disease due to selective destruction of the cortex than it is in Addison's disease due to suprarenal tuberculosis In published reports of cases of Addison's disease, it is noticeable that thyroid infiltration is much more often mentioned and discussed in connection with the nontuberculous cases Brenner noted it in the three

11 Dubois Berl klin Wchnschr 56 1178, 1919

of his cases of cortical atrophy in which the thyroid gland was described, and made the following statement

The thyroid gland is also often diseased in Addison's disease, due both to atrophy and to tuberculosis of the suprarenals In most of the cases described there was some infiltration with lymphocytes and fibrosis In some cases, as in case 1 described above and Schmidt's cases, the lymphoid infiltration was very dense In addition, the gland parenchyma often showed changes, either of diminished or of increased activity In case 1 the changes were as severe as are met with in many cases of myxoedema, yet neither in this case nor in many others described were there any symptoms of deranged thyroid function In some cases, however both of atrophy and of tuberculosis the symptoms and pathological changes of Graves disease as well as of Addison's disease were present, while in other cases there were also symptoms of myxoedema It seems probable that the changes in the thyroid are due to the same cause as the suprarenal lesion, and not to loss of suprarenal function

Apparently this lymphoid infiltration of the thyroid gland is not dependent on the general hyperplasia of the lymphatic tissue that so often is found in Addison's disease, for in two cases that I examined in which suprarenal tuberculosis was associated with marked status thymicolymphaticus there was no infiltration of the thyroid gland Recently I examined the tissues from a case of myasthenia gravis with marked general lymphoid hyperplasia without any lymphoid cells in the thyroid gland None of my five cases of thyroid gland infiltration was associated with any marked general lymphoid hyperplasia, and persistent thymus was present only in one Furthermore, in the third and fourth cases of suprarenal atrophy of this series, no microscopic trace of thymus tissue could be found, despite marked lymphoid infiltration of the thyroid gland It is also to be remarked that in the cases in which they have been examined the parathyroids, hypophysis and pineal gland have not shown similar lymphoid infiltration or other abnormality

The significance of this change in the thyroid gland is not known It is seen in many other conditions and Williamson and Pearse,[12] who described it in some detail look on the thyroid gland showing "lymphadenoid goiter" independent of Addison's disease as "the physiological subnormal gland undergoing hyperplasia" "The lymphocyte reaction is proportional to the failure of the hyperplastic effort and is itself an exaggeration of the normal procedure in the gland" Possibly this condition is related to the low level of metabolism common in these cases of Addison s disease McCarrison[13] reported that he was able to produce a similar condition in the thyroid of rats by keeping them on a diet in which a deficiency in all vitamins was combined with a deficiency

12 Williamson and Pearse J Path & Bact **28** 361, 1925

13 McCarrison Indian J M Research **15** 909, 1928

of certain inorganic elements, especially manganese, a diet that leads to a state of physiologic subnormality As yet there is no evidence that diet plays any rôle in producing this condition in man

SUMMARY

About 90 per cent of all cases of Addison's disease depend on nearly complete destruction of the suprarenal glands, both cortex and medulla, by tuberculosis Such cases give no indication of the respective rôles played by the cortex and by the medulla Approximately 10 per cent of the cases exhibit a marked decrease in the size of both suprarenals, which are usually affected about alike, and this "atrophy" is found to depend on an extensive sometimes an almost complete destruction of the epithelium of the cortex, with less or practically no destruction of the medullary tissues No cases of undoubted Addison's disease seem to have been observed in which the medulla was found to be destroyed while the cortex was for the most part intact, although cases of such selective medullary destruction without the picture of Addison's disease have been observed Therefore, the dependence of Addison's disease predominantly on destruction of the cortex of the suprarenal glands seems to be well established by cases in which this condition is present, of which six typical examples are described in this paper

The cause of the selective destruction of the suprarenal cortex without recognizable corresponding damage to any other tissue in the body is entirely unknown The bilateral character of the lesion indicates its hematogenous origin It is not associated with vascular lesions or occlusions The resemblance both of the tissue damage and the regenerative changes in the surviving cortical epithelium to the processes seen in diffuse toxic necrosis of the liver ("acute yellow atrophy") suggests that the suprarenal condition also is the result of a toxic necrosis by some poison selectively injuring the epithelium of the suprarenal cortex The histories of the cases so far reported, however, give no satisfactory clue as to the source or nature of the hypothetic poison

About the only other anatomic change found outside the suprarenal glands is a marked infiltration of the thyroid gland by lymphoid cells, which often form large lymph follicles with germinal centers, replacing much of the glandular tissue This occurs in the absence of a status thymicolymphaticus and in two of these cases not even microscopic residues of the thymus could be found Although lymphoid infiltration of the thyroid gland has been observed in Addison's disease due to tuberculosis of the suprarenal gland, it seems to be less marked and less frequent than in the cases associated with selective destruction of the suprarenal cortex

CERTAIN SO-CALLED SARCOMAS OF THE THYROID *

LAWRENCE W SMITH, M D
NEW YORK

Two years ago, with Dr Howard S Clute, I had the opportunity to present a summary of observations on fifty-four malignant tumors of the thyroid gland from the Lahey Clinic At that time, we proposed a relatively simple grouping of the cases, based primarily on their histology, supplemented by their clinical behavior This divided the tumors into five groups (1) the rare epidermoid carcinoma of thyroglossal duct origin, (2) the papillary adenocarcinomas probably of ultimobranchial body origin, (3) the simple adenocarcinomas of "foetal" follicular adenomatous origin, (4) the small round cell tumors of debatable origin and (5) the giant cell tumors frequently presenting many of the generally accepted criteria of sarcomatous mesoblastic origin On the basis of rather extensive histologic studies, we advanced the belief that all of these tumors were fundamentally epithelial It was our intention to follow up that preliminary paper with a rather more detailed statement of these individual groups This report is the first of what we hope to be a series of such papers Since that time, through the courtesy of their several pathologists, it has been my privilege to compile the cases from the Massachusetts General Hospital, those from the Peter Bent Brigham Hospital, some of the cases from the Boston City Hospital, single cases from several of the smaller suburban hospitals around Boston and finally, through the kindness of Dr Eugene H Pool, Dr Charles L Gibson and the other staff members of the New York Hospital the cases that have occurred in the latter institution during the past ten years

The present paper deals with eighteen cases of malignant disease of the thyroid gland that at one time or another by one or more pathologists have been diagnosed histologically as sarcoma None of the small round cell tumors most frequently described under the term lymphosarcoma is included in this series, and the term is arbitrarily restricted to that group ordinarily designated as fibrosarcoma

---

* Submitted for publication, May 2, 1930
From Cornell University Medical College

The accompanying table gives the more essential points in respect to the clinical data, as far as it has been possible to secure the facts Briefly, they may be summarized as follows

1 The average age in the sixteen cases in which the age was given was 61 2 years, the extremes being 46 and 72 years, respectively

2 The average postoperative duration in the sixteen cases in which this information could be ascertained was two and four-tenths months In two of the remaining three cases the patients were dead within a year, and in the final case in this series the patient at the time of writing is dying of recurrence or, perhaps more accurately, of extension of the tumor, four months following operation The mortality in this group

Giant Cell Tumors

Number	Reference Number	Sex of Patient	Age of Patient	Pre operative Duration, Months	Post operative Duration	Total Duration, Months	Result
1	S-21-1158	F	59	1*	2 months	3	Death
2	S-21-1665	M	62	3*	2 days	3	Death
3	S-18-1299	F	71	3*	4 months	7	Death
4	S-24-192	F	57	2	1 month	3	Death
5	DS-24-402	F	60	2*	9 days	2	Death
6	DS-26-668	F	46	4*	1 year	16	Death
7	DS-25-1005	F	53	1*	3 months	4	Death
8	DS-25-1083	F	61	2	4 months	6	Death
9	DS-26-2139	F	69	5*	2 weeks	5 5	Death
10	DS-27-649	F	72	2*	3 months	5	Death
11	DS-27-47	F	54	6	1 day	6	Death
12	DS-25-831	F	71	1*	2 months	3	Death
13	131-11	M	?	?	?	?	Death
14	N D	F	69	4	3 months	7	Death
15	M F	F	58	3*	1 month	4	Death
16	H-26-403	M	55	2*	2 weeks	2 5	Death
17	39868	F	65	?	?	?	Patient dying at time of writing
18	25318	M	?	2?*	2 months	4	Death
	Average		61 2			4 8	

* Had been present as a nodule for many months or years, recent rapid growth is indicated by figures

of cases can be considered, therefore, as 100 per cent within a year Of these deaths, four may be considered as hastened by operation, as the patients died within two weeks after the operation

3 The incidence in this series is approximately three and a half times as great in women as in men—14 in women and 4 in men This ratio for the male group is somewhat higher than that of any other type of malignant disease of the thyroid gland that has been studied

4 All of these cases showed evidence of extension from the original tumor, with invasion of the capsule On clinical examination, most of them showed involvement of lymph nodes, but unfortunately histologic studies of the nodes were possible in only three of the cases Three showed definite invasion of the blood vessels, that important histologic criterion of malignancy emphasized by Graham

These cases therefore constitute a fairly definite clinical group, occurring in persons in the age group above 55 years The history is

usually one of a rather long continued symptomless goiter, with a small nodular tumor that after months or years suddenly begins to increase in size The course from then on is rapid, rarely extending for more than six or seven months, and progressing fatally regardless of operative intervention or physical therapy such as that with radium or the x-rays

After careful histologic study there seems to be little question that in sixteen of these eighteen cases the tumor is epithelial In two, the epithelial relationship is not so readily apparent, but areas can be found that support the contention which Ewing, Karsner and numerous other investigators have held that these so-called sarcomas of the thyroid gland are epithelial tumors, and that true sarcoma of the thyroid gland has yet to be demonstrated I have long been of this opinion, and a study of over two hundred malignant tumors of the thyroid gland has tended to confirm this belief

My purpose in this paper is to illustrate by selected areas from the doubtful cases the reasons for this conclusion Of all human tissues with which one has to deal microscopically, there is none which normally presents the complexity and multiple variation that the thyroid gland does And so it is not surprising to find a comparable confusion in the classification of tumors of the gland Dealing as one does with tissue physiologically so unstable, it is not to be wondered at that its pathologic manifestations are of most bizarre form

Certain truisms become understandable in relation to histologic study of the thyroid gland—especially that of the need of multiple sections In the consideration of hardly any other class of tumors, save perhaps of the gliomas, is this so outstanding a necessity Scarcely any two sections of a tumor of any size from the thyroid gland are comparable, hence the need of studying many different areas becomes apparent before one attempts a diagnosis

The gross pathologic features of these cases are perhaps the most nearly constant observations The tumors are usually unilateral, arising from a long standing adenomatous nodule They grow centrifugally rapidly over a period of a few weeks and attain considerable size, not uncommonly becoming as large as a grapefruit They frequently extend to involve the opposite lobe, as well A typical case is shown in figure 3 The rate of growth as has been stated, is rapid, and the clinical evidence of malignancy is often noted at operation, with the penetration of the thyroid capsule and the involvement of the surrounding structures even at times the skin which becomes firmly adherent The tumor tends to be irregularly ovoid or spherical and frequently superficially nodular and at times conforms to the general outline of the thyroid lobe

Fig 1 (case 10) —Spindle cell area from an unmistakable adenoma of the thyroid gland, which in other areas is frankly follicular

Fig 2—Another area from the tumor shown in figure 1 It illustrates the transition of the cells from definite cuboidal epithelium toward the spindle cells noted in figure 1

Fig 3 (case 17) —Cross-section of a tumor, actual size, illustrating its adenomatous origin and character

Fig 4 —A representative field from case 17 (fig 3) This shows an area of transition where the cells, although still spindle form, are attempting to form pseudo-alveoli

Fig 5 (case 12) —A case in which it is extremely difficult to demonstrate the epithelial nature of the tumor Areas of alveolar arrangement can be seen, however, and multiple sections are convincing

Fig 6 (case 8) —A carcinoma frankly of the large giant cell type, with alveolar formation It was diagnosed sarcoma, presumably because of the anaplastic giant cells The gross specimen shows its adenomatous origin

On section, these tumors are usually grayish yellow and extremely firm, except where necrosis has occurred, with resultant softening The architecture is obscure, suggestive strands of trabeculae of connective tissue are visible as a framework for the tumor tissue itself, which is rather more yellow

Histologically, the picture is essentially one of extremely anaplastic spindlecell overgrowth The cells assume all sorts of bizarre forms, often with multilobulated nuclei, some appear as multinucleated giant cells In every one that it has been my privilege to study, I found somewhere evidence of the transition from low cuboidal epithelium to the curious atypical distorted tumor cells In certain other frankly carcinomatous cases, one can find comparable degenerative changes in the stroma, and it is highly probable that in such cases the stroma may be involved secondarily in a pseudosarcomatous picture Just as in the case of similar tumors of the breast, of the uterus or of other organs, there is no question as to the primary underlying carcinomatous nature of the tumor, so in the case of these atypical tumors of the thyroid gland there should be no more confusion as to their epithelial nature

Many obviously adenomatous tumors in which the acinar picture can be easily traced show in portions of the growth a curious spindling of the cells Such tumors are included among those illustrated in this report for comparison, they emphasize the fallacy of single field photomicrographs or even single microscopic preparations since individual cases can easily be selected in which the diagnosis is most confusing (figures 1 to 6) As Boyd so clearly brought out in his brief comment on the confusion of nomenclature and differentiation of the "foetal" and "colloid" adenomas, with these sarcomatoid pictures one must take the composite picture into consideration, before arriving at a conclusion Perhaps the natural history of these tumors is as helpful diagnostically as any other single feature

They behave more like carcinomas than like sarcomas They occur in the sixth and seventh decades of life They metastasize, as a rule, as carcinomas do—by the lymphatic channels and by direct extension, although vascular invasion is by no means uncommon They can usually be traced to an antecedent adenoma Both in architectural arrangement and in cytologic detail, they almost regularly have anatomic features in common with thyroid gland epithelium

Figures 1 to 6 bring out these more important details better than any description can do, and I submit the visual evidence in proof of the contention that an unquestionable mesenchymal type of sarcoma in the thyroid gland has yet to be found

THE LESIONS IN EXPERIMENTAL AMEBIC DYSENTERY

DALE L MARTIN, M D
TACOMA, WASH

(Concluded from page 385)

3 INTESTINAL LESIONS PRODUCED BY INOCULATION IN ANIMALS

DATA FROM THE LITERATURE LESIONS IN MAN

Following the classic experiment of Losch [39] (see study 2), interest in an ameba as one of the causes of dysentery was widely stimulated Kartulis [85] early offered clinical evidence in support of the view that an ameba was concerned in the etiology, while further evidence was presented by him based on a study of the intestinal lesions produced in amebic dysentery, and on the association with these lesions of an ameba corresponding to that described by Losch Kartulis [86] reported the first abscess of the liver known to be amebic He described in moderate detail the pathologic change in amebic ulceration of the intestine and in amebic abscess of the liver and he expressed the belief that the lesions of the liver arose secondarily to the ulcerative process in the bowel and that the amebas were transplanted to the liver by way of the portal system He thought, however, that the lesions, both intestinal and hepatic, were primarily produced by bacteria and that the amebas prevented or hindered the healing of the lesions thus produced by their presence in them He explained the occasional bacteria-free amebic abscess of the liver by assuming that the bacteria present died or were consumed by the amebas after having initiated the destructive changes Kartulis [87] later departed from this view, believing that amebas, acting alone, might produce intestinal and other lesions Kartulis [88] was the first to find amebas in an abscess of the brain

---

85 Kartulis, S Ueber Riesen-Amoben (?) bei chronischer Darmentzundung der Aegypter, Virchows Arch f path Anat **99** 145, 1885, Zur Aetiologie der Dysenterie in Aegypten, ibid **105** 521, 1886

86 Kartulis, S Ueber tropische Leberabscesse und ihr Verhaltniss zur Dysenterie Virchows Arch f path Anat **118** 97, 1889

87 Kartulis, S Die Amobendysenterie, in Kolle, W, and Wassermann, A von Handbuch der pathogenen Microorganismen, ed 2, Jena, Gustav Fischer, 1913, vol 7, p 651

88 Kartulis, S Gehirnabscesse nach dysenterischen Leberabscessen, Centralbl f Bakteriol **37** 527, 1904

Osler[89] confirmed the observations of Kartulis concerning amebic abscess of the liver by finding motile amebas in the pus of a hepatic abscess that had been drained surgically. Dock[90] showed that amebiasis is not strictly a tropical disease, and that amebic lesions of the intestine may be present in persons who are free from dysentery and in those who have no history of dysentery.

Councilman and Lafleur[3] published the clinical histories of fifteen patients ill with amebic dysentery, with detailed observations in eight of them, who came to necropsy. Besides abscesses of the liver which occurred in six of the eight, they described, for the first time, amebic abscess of the lung, which occurred in three. In careful observation and detailed description of the lesions, both primary and secondary, this work stands alone and largely serves to establish the general recognition of amebic dysentery as a specific entity.

Further contributions to knowledge of the pathologic changes in amebic dysentery appeared with increasing frequency, so that an attempt to follow them historically becomes a task of great difficulty and of doubtful value. In the following description of the lesions of this disease, an attempt will be made, however, to give credit to those who have made noteworthy contributions to knowledge of the subject.

Intestinal ulcerative lesions due to amebiasis have not been described as occurring elsewhere than in the colon, lower part of the ileum and appendix. The transverse colon is found most frequently involved, with the ascending colon next (Hutchinson,[91] Kuenen[92]). Doptei[4] found the ileocecal valve involved in every case. When the cecum was not specifically mentioned or when it was included with the ascending colon, the upper part of the colon showed the greatest involvement. In the generalized attack on the colon, the more pronounced lesions are still found in the cecum and the ascending colon (Woolley and Musgrave,[93] 159 times in 200 cases, Bartlett,[94] 29 times in 61 cases,

89 Osler, William: Ueber die Dysenterie und dysenterische Leberabscess vorhandene Amoeba, Centralbl. f. Bakteriol. **7**: 736, 1890.

90 Dock, George: Observations on the Amoeba Coli in Dysentery and Abscess of the Liver, Centralbl. f. Bakteriol. **10**: 227, 1891.

91 Hutchinson, H. S.: Observations on Endamebic Dysentery, J. Lab. & Clin. Med. **13**: 613, 1928.

92 Kuenen, W. A.: Die pathologische Anatomie der Amoebiasis vergleichen mit anderen Formen von Dysenteriae, Arch. f. Schiffs- u. Tropen-Hyg. **13**: 435, 1909.

93 Woolley, P. G., and Musgrave, W. E.: The Pathology of Intestinal Amoebiasis, J. A. M. A. **45**: 1371, 1905.

94 Bartlett, G. B.: Pathology of Dysentery in the Mediterranean Expeditionary Force 1915, Quart. J. Med. **10**: 185, 1917.

Clark[95] in 60 per cent of 186 cases, Rogers,[96] Strong[97]) Next in the order of frequency of localized colonic involvement is the rectum, and then the sigmoid flexure (Hutchinson, Clark), although Kuenen placed the incidence of lesions in the sigmoid flexure before that of lesions in the rectum Bartlett departed from the views of most writers when he described the finding of advanced lesions in the sigmoid flexure more than twice as often as in the cecum The splenic and hepatic flexures are less frequently involved (Hutchinson), whereas localized attack of the transverse colon alone is mentioned but once (Councilman and Lafleur) When the condition is uncomplicated, the mucosa around the ulcers and ulcerated areas of the bowel in amebic dysentery is intact and relatively normal This is held to be typical of intestinal amebiasis (Kaufmann, Rogers,[96] Strong and others)

Amebic ulcers are rarely restricted to one area alone, but may occupy widely separated or contiguous areas in every conceivable combination Councilman and Lafleur described the simultaneous involvement of the ascending and the transverse colon in one case, of the ascending and descending colon in another case, and of the transverse and descending colon in a third case In Bartlett s sixty-one cases there were nine in which the lesions were situated generally throughout the colon, with the exception of the rectum

The appendix is not often ulcerated in amebiasis Kuenen did not see a case in which it was ulcerated in six years of work at Delhi Ulceration of the organ does occur, however, for Clark placed it fifth in point of frequency of attack, and Woolley and Musgrave found appendical involvement 14 times in 200 cases The lower part of the ileum is even less frequently involved than the appendix Clark did not find any involvement of the appendix in 186 cases, although the ileocecal valve was affected in 5 3 per cent of cases in which there was evidence of generalized colonic attack Woolley and Musgrave found the ileum ulcerated in 7 of their cases, Bartlett found ileal changes twice, but no amebas were present, whereas Rogers[96] reported mucosal roughening only Kuenen found the ulcers of the ileum to be smaller than those in the colon, and frequently lying close together

Harris,[98] from an experience with five cases, was struck by the tendency of amebic ulcers to occupy that portion of the intestine opposite its point of attachment

95 Clark, quoted by James, W M Human Amoebiasis Due to Infections with Entamoeba Histolytica, Ann Trop Med **22** 201, 1928

96 Rogers, Leonard Dysenteries, Their Differentiation and Treatment, London, Oxford University Press, 1913, pp 64 and 148

97 Strong, R Amoebiasis, London, Thomas Nelson & Sons, 1920 vol 2, p 331

98 Harris, H J Amoebic Dysentery, Am J M Sc **115** 384, 1898

In a more minute examination of the mucosal inequalities which may help to determine the localization of an intestinal ulcer, it has been found by some observers that the summits of the mucosal folds are places of most frequent attack in amebiasis (Rogers,[96] Kruse and Pasquale [99])

The Preulcerative Period—Among the intestinal changes of amebiasis there have been described very early lesions that may be looked on as preulcerative Kruse and Pasquale [99] described intestinal catarrh in two cases, but at the same time found other conditions present that may have explained the observation Woolley and Musgrave described "red dots," from 0 3 to 2 mm in diameter, visible on the mucosal surface of the bowel, which were due to hemorrhage into the described tissue of the mucosa Bartlett described elevated areas about 1 mm in diameter, with the overlying mucosa not ulcerated Strong found small, raised hemorrhagic areas involving the submucosa, with later loss of the surface epithelium Davidson [100] described circumscribed patches of thickening and necrosis of the submucosa which appeared as sharply defined nodules projecting into the lumen of the bowel He thought the mucosa was involved secondarily Rogers [101] described dots the size of a pinhead on the inner surface of the intestine, due to congestion and to hemorrhage into the mucosa above earlier exudation into the submucosa He found amebas in the mucosal tubular glands and thought they reached the submucosa by perforation of the basement membrane Kaufmann described the initial lesion as infarction-like necrosis of the mucosa, whereas Kartulis [87] found this necrotic plug to be cone-shaped, with its base in the submucosa He further described hemorrhagic catarrh of the mucosa, characterized by swelling of this tissue, congestion and occasional hemorrhage

Dopter [4] described mucosal catarrh characterized by minute areas of interglandular thickening, the result of invasion of the connective tissue by cells that destroyed the glandular parallelism There were found proliferation of glandular epithelium and hypersecretion of mucus, with dilatation of the glandular crypts There was vascular congestion without hemorrhage, while amebas were present in the blood vessels of the mucosa In Dopter's [4] "preulcerative lesion" there was enough destruction of tissue to exclude it from consideration here

Earliest Ulcerative Lesions—Of the early ulcerative lesions of the bowel recognized as amebic, Harris [98] described superficial erosion of

99 Kruse and Pasquale (footnote 44, second reference)

100 Davidson, Andrew Amoebic Dysentery, in Albutt, Clifford and Rolleston, H D A System of Medicine, London, The Macmillan Company, 1909, vol 2, pt 2, p 527

101 Rogers, Leonard Further Work on Amoebic Dysentery in India, Brit M J 1 1315, 1903

the mucosa involving not more than half of its depth and with no changes in the subjacent submucosa He did not find amebas in this region, however, and it is thus open to question whether or not this lesion was amebic Dopter[4] described thickened mucosa with areas of minute superficial erosion He believed the mucosa was attacked first Rogers[102] described raised dots about 1 mm in diameter showing yellow centers, accompanied by great thickening of the subjacent submucosa, above which the mucosal ulcer was narrow Kuenen described superficial erosion of the mucosa with only congestion of the submucosa In a study of one case of amebiasis, Christoffersen[103] injected a solution of formaldehyde into the peritoneal cavity immediately after death in the attempt to prevent postmortem changes Unfortunately, he overlooked the opening of an appendicostomy and applied his fixative solution to the outer surface of the intestine rather than to the mucosa In this case, he described early ulceration of the outer surface of the mucosa, in which the epithelium and the interstitial tissue were equally involved, and from which the lesion merged smoothly into the surrounding normal mucosa The submucosa contained only dilated blood vessels MacCallum[104] stated that the mucosa alone may be involved James[105] described superficial erosion of the mucosa, recognized only on close inspection and identified as amebic by the presence of *Endameba histolytica* in the lesion He described the change as solution and destruction of the mucosa, before any appreciable degree of invasion had begun, and said that it might extend for as much as 15 cm along the surface of the bowel He thought the amebas attacked the epithelial cells and interstitial tissue with equal facility, thus producing, first of all, a lesion restricted to the most superficial portion of the mucous membrane He found the underlying vessels congested and thrombosed

More Advanced Typical Ulcer—In descriptions of the fully developed amebic intestinal ulcer, there appears to be greater uniformity of opinion than prevails concerning the younger lesions (Delafield and Prudden[106]) Once the mucosa becomes destroyed there is presented an ulcerative lesion that had been looked on from the beginning of the present knowledge of amebiasis as typical of the intestinal process and peculiar to it This discrete ulcer varies from 1 to 3 cm in diameter (Rogers[101]), the small ulcers being round and the larger ones oval, the

102 Rogers (footnotes 96 and 100)

103 Christoffersen (footnote 4, second reference)

104 MacCallum, W G A Text-Book of Pathology, ed 3, Philadelphia, W B Saunders Company, 1924, p 770

105 James, W M Human Amoebiasis Due to Infection with Entamoeba Histolytica Ann Trop Med **22** 201, 1928

106 Delafield, Francis, and Prudden T M A Text-Book of Pathology, ed 12, New York, William Wood & Company, 1922, pp 134, 768 and 823

mucosal edges are red, elevated and undermined, the centers necrotic, gelatinous and yellow, while the submucosa is usually more widely involved than the mucosa above The base of this ulcer may reach the circular muscle layer, but rarely extends deeper than this

While the descriptions of the typical amebic intestinal ulcer show remarkable agreement the same is not true of those of the microscopic appearance The mucosa beyond the ulcer is found normal (Woolley and Musgrave, Davidson, Viereck[107]) or shows evidences of mucous catarrh (Dopter[4]) The latter is not always widespread, but is frequently limited to a narrow zone immediately surrounding the ulcer (Dopter,[4] Woolley and Musgrave Viereck) and is characterized by the production of mucous cysts that appear to owe their formation to secretion into glandular crypts that have become occluded at the surface (Viereck) In this zone is found hypertrophy of the mucosa (Woolley and Musgrave) accompanied by an infiltration of small cells between the epithelial columns, increasing in degree as the ulcer is approached (Rogers,[96] Kuenen), dilated blood vessels (Kuenen, Kartulis,[87] Dopter[4]) and occasional hemorrhagic infiltration (Kartulis[87]) The mucosal glands are present and recognizable to the margin of the ulcer (Rogers[96] Viereck) although they are occasionally distorted and dilated (Davidson) Mucosal destructive changes vary from cloudy swelling of the epithelial cells to necrosis (Kartulis[87]) The epithelial cells become loose and fall into the lumen of the gland The cells are granular and the nuclei lose their normal staining reaction, while at the margin of the ulcer the whole becomes a mass of deeply staining detritus (Kruse and Pasquale[99])

The site of *Endameba histolytica* in the mucosal portion of the typical amebic ulcer of the intestine varies widely, according to the experiences of various observers Kuenen found amebas below the necrotic area but never primarily in the glands of the mucosa Likewise Harris[98] found them in and between glands at the edge of the ulcer only and never saw an ameba in an intact mucosal crypt Kartulis[86] however found them in necrotic tissue and within glands as did Rogers[96] Viereck found amebas most frequently in the interglandular connective tissue, and found them rarely in the widened mucosal cysts Bartlett found *Endameba histolytica* in the mucosa rarely, and Kruse and Pasquale[99] never found them there Of particular interest is the description by Woolley and Musgrave of the finding of *Endameba histolytica* in the blood and lymph spaces of the interglandular connective tissue Dopter[4] also found them in the blood vessels of the same region

107 Viereck H Studien uber die in den Tropen erworbene Dysenterie, Arch f Schiffs- u Tropen-Hyg **11** 1, 1907

When the process in the intestine reaches the submucosa, there is developed a necrotic core, which for a time may remain in place (Kartulis[87]) This central necrotic region is composed of granular debris, bacteria and amebas, the whole occupying a space in the submucosa more extensive than that occupied by the mucosal lesions above it (Councilman and Lafleur, Kruse and Pasquale,[99] Harris[98] Dopter[4] and others) Although this resembles a phlegmon of the submucosa (Dopter[4]), it is not purulent (Kruse and Pasquale[99]), and has been described as a coagulation necrosis (Dopter[4]) to which fatty degeneration has contributed a part (Councilman and Lafleur, Kruse and Pasquale[99]) In the older lesions, the central necrotic core is lost, leaving a widely undermined cavity lined with the same necrotic material and surrounded by the tissue of the submucosa, in which are present the changes peculiar to the amebic process, namely, thickening due to edema (Kruse and Pasquale,[99] Woolley and Musgrave, and others), cellular infiltration (Councilman and Lafleur) and dilated blood vessels (Christoffersen and others)

The intestinal thickening in amebiasis may involve all coats (Strong), but it is most marked in the submucosa below and immediately beyond the mucosal lesions (Viereck,[103] Rogers,[102] Strong) Generalized thickening of the bowel has been found more frequently associated with intestinal lesions of bacterial origin than with those of amebiasis (Viereck)

The cellular infiltration of the submucosal portion of the amebic ulcer is largely lymphocytic (Councilman and Lafleur, Harris,[98] Woolley and Musgrave, Rogers,[96] Strong), although polymorphonuclear leukocytes are present in small numbers (Councilman and Lafleur, Kuenen, Harris,[98] Woolley and Musgrave) The presence of the latter in great numbers is looked on as indicating increased bacterial participation (Woolley and Musgrave)

In the necrotic tissue of the wall of the ulcer and within the less changed tissue beyond it, a deposit of fibrin has been observed (Councilman and Lafleur, Kruse and Pasquale,[99] Kuenen), which may reach the surface of the bowel as an attenuated diphtheroid membrane (Dopter[4]) From the evidence presented by special staining methods, however, it has been denied that this material is true fibrin (Viereck)

Beyond the boundaries of the cellular infiltration, the lymph vessels may be found dilated (Davidson), their contents coagulated and unrecognizable (Kruse and Pasquale[99]), and the endothelial lining frequently desquamated (Dopter[4]) More marked changes are found in the adjacent blood vessels, however, which are congested (Woolley and Musgrave, Dopter,[4] Kuenen, Davidson, Bartlett, Christoffersen) and may give evidence of endothelial desquamation (Rogers,[96] Bartlett) endothelial proliferation (Councilman and Lafleur) or thrombosis

(Councilman and Lafleur, Kruse and Pasquale,[99] Viereck, Kuenen, Bartlett) Councilman and Lafleur described obliterative endarteritis of which a feature was thick, edematous walls infiltrated with round cells Their description of the new formation of capillaries makes it likely that they were dealing with chronic or healing lesions

Bacteria in small numbers are present in the early intestinal lesions of amebic dysentery (Hutchinson) and are found superficial to the advancing process (Davidson[100]) They are found in greater numbers in the necrotic tissue of the larger lesions (Councilman and Lafleur, Bartlett, Hutchinson) and have been described also as being present in small numbers in the healthy tissue ahead of the advancing amebas (Kruse and Pasquale[99]) Kruse and Pasquale[99] believed that the continued rapid multiplication of the intestinal bacteria after death killed the amebas present and greatly modified the postmortem observations

In the affected submucosa, *Endameba histolytica* may be found in the necrotic tissue and in the immediate vicinity (Councilman and Lafleur), as well as between the necrotic and near-necrotic portions (Kuenen) In the newly infiltrated regions, they have been found in great masses (Kruse and Pasquale[99]) Although usually found restricted to the immediate region of the ulcer and to the changed tissue of the lesion (Harris,[98] Viereck), they have been described as occurring in the edematous tissue in advance of the acute inflammatory process (Strong) and even, at times, in normal or but slightly altered tissue at a distance (Kruse and Pasquale,[99] Woolley and Musgrave, Christoffersen, Bartlett, MacCallum) Amebas have been found within submucosal lymph spaces (Councilman and Lafleur, Harris,[98] Dopter,[4] Bartlett, Kaufmann, Kofoid,[6] Hutchinson), but even more frequently within the blood vessels of the same tissue (Councilman and Lafleur, Harris,[98] Dopter[4] and others) Harris[98] and Viereck described amebas penetrating the walls of blood vessels, and Viereck found them within blood vessels not thrombosed Kuenen found them within vessels not thrombosed, as well as within those that were thrombosed Christoffersen described the amebas as "crowding" the blood vessels in his case, and MacCallum found *Endameba histolytica* within the lumen of the vessel, as well as between the lining endothelium and the wall of the blood vessel

Late Ulcerative Lesions—Continued growth of the typical amebic ulcer may lead to fusion with others, resulting in the production of large, irregular ulcers that may reach the size of the palm of the hand (Woolley and Musgrave) or may even encircle the bowel (Bartlett) Early fusion of the submucosal process may produce lesions covered in part by bridges of nearly normal mucosa, deprived of its normal

support from below (MacCallum) Should the base of the ulcer reach the circular layer of intestinal muscles, this tissue is infiltrated with leukocytes (Kartulis[87]) and may be converted into a homogeneous hyaline mass (Councilman and Lafleur) Should the process reach the serosa, there may be present severe edema (James[105]), deposition of lymph, even in the absence of perforation (Rogers[96]), or the development of protective intestinal and omental adhesions (Woolley and Musgrave, Kuenen) or combinations of these The large lesions contain fewer amebas than the smaller ones (Councilman and Lafleur, Rogers,[96] Hutchinson) increased evidence of bacterial activity and greater infiltration by polymorphonuclear leukocytes (Bartlett, Rogers[101]) Such ulcers, relatively free from necrotic material, may not contain amebas (Bartlett)

Gangrene—Intestinal gangrene may appear as a complication of the amebic process in the colon (Kartulis,[87] Woolley and Musgrave, Davidson, Kuenen) This change is believed to depend entirely on secondary bacterial invasion of the amebic lesion (Kartulis,[87] Kuenen, Rogers[96]), and the amebas themselves are rarely present in gangrenous regions (Bartlett) and then only in small numbers (Hutchinson) Gangrene may be local or general The local process occurs most commonly in the cecum, and if the process is general, the more extensive changes are in the cecum (Rogers[96]) This severe lesion leads to an increased incidence of intestinal hemorrhage (Kartulis,[87] Woolley and Musgrave) and of intestinal perforation (Kuenen) In the absence of gangrene, Kuenen found intestinal perforation in amebic dysentery in but one of two hundred cases

Healing Amebic Lesions of the Intestine—Healing of the amebic ulcer of the bowel may occur Clark reported the absence of intestinal lesions in 5 3 per cent of 186 cases that gave evidence of secondary amebiasis at necropsy The beginning of this reparative change was probably seen in Dopter's[4] "chronic ulcer" in which there were less necrosis, less inflammatory reaction, less pus, less hemorrhage and fewer amebas than in the more active lesions The floor of the ulcer may be slightly depressed, clean and smooth, and there may be extensive, patchy pigmentation around the partially healed portions (Rogers[96]) Davidson described the formation of clean granulation tissue in the floor of the healing amebic ulcer, and Councilman and Lafleur described the new formation of capillaries in the same region The latter found the surrounding epithelial cells growing down the walls of the ulcer and across its floor Small ulcers may heal without a cicatrix (Kuenen), although in the larger ones there are usually scarring and contraction (Woolley and Musgrave, Kuenen, Rogers,[96] Wenyon[5]), with thickening and puckering of the mucosa about the healed portions (Rogers[96])

Pigmentation of the mucosa around and over healed ulcers has been described (Rogers[96]) Although the ulcerative lesion may disappear there often remain, as evidence of previous inflammation, mucosal thinning, catarrh with hypersecretion of mucus, loss of normal intestinal folds and atrophy of the intestinal wall, leading to increase in the length of the colon (Woolley and Musgrave) In addition, mucosal atrophy (Dopter[4]) and subsequent formation of intestinal polyps have been described (Dopter,[4] Davidson)

In the attempt to explain the transportation of *Endameba histolytica* from the intestinal lesions to remote organs of the body, participation of the solitary lymph follicles of the colon in the amebic process is of particular interest In descriptions of intestinal amebiasis, most authors have failed to mention the solitary follicle, thus easily leading to the impression that ulceration beginning in or involving them is not a conspicuous feature of the disease Kruse and Pasquale[99] did not find follicular change Davidson believed the solitary follicles remote from the ulcerative processes to be normal, but he described follicular hypertrophy surrounding the portions attacked The possibility of follicular hypertrophy in amebiasis was mentioned also by Woolley and Musgrave Specific ulceration of the solitary follicle does occur (Councilman and Lafleur Dopter,[4] Davidson, Kartulis[87]), although Councilman and Lafleur described secondary involvement of follicles in one case only and believed the follicular attack to be accidental and not to represent a special predisposition on the part of intestinal lymphoid tissue to be invaded by *Endameba histolytica* Kartulis[87] found ulceration involving the lymph follicles to be rare When attacked they appeared as small grayish-white points surrounded by a zone of injection In the center of each was a small opening on the mucosal surface, below which was a relatively large hole with undermined, elevated and ragged walls The floor of the follicular ulcer varied from bright red to grayish-yellow, and was occasionally covered with a yellow, fibrinous exudate Dopter[4] described the wall of the invaded solitary follicle as from rough to ragged, with amebas in great masses present in the wall of the ulcer Although Kuenen did not find special participation of the follicles of the colon in the amebic process, he believed that there was a selective amebic attack on the aggregated lymph nodules of the lower portion of the ileum, and ascribed one death in typhoid fever to the perforation of a Peyer's patch by amebas

Regional Lymph Nodes in Amebiasis—In intestinal amebiasis, invasion of the paracolonic lymph nodes by *Endameba histolytica* appears to be rare Kofoid[108] mentioned that the lymph nodes adjacent to

108 Kofoid, C A Human Amoebiasis with Special Reference to the Chronic Phase Texas State J Med **21** 347 1925

the colon may be invaded, although James[105] saw this in but one case, in which a node adherent to the involved bowel was invaded by direct extension of the amebic ulcer through the wall of the bowel Howard and Hoover[109] wrote of a "lymphatic barrier" to the wide dissemination of *Endameba histolytica* by way of the lymphatic system, but they did not describe an attack of the mesenteric nodes by amebas Viereck did not find evidence of involvement of lymph nodes, whereas Doptei[4] described them as red and swollen Councilman and Lafleur described the mesenteric nodes as softened, swollen and possibly purulent, but denied that they ever contained *Endambea histolytica* Rogers[96] mentioned slight changes, and Bartlett described slight enlargement, with proliferation and desquamation of the cells of the lymph sinuses, accompanied by increased infiltration with lymphocytes and neutrophilic leukocytes Among these, the polymorphonuclear cells were relatively few

Amebic Abscess of the Liver—Outside of the intestinal tract, the lesion most commonly associated with amebiasis is tropical or amebic abscess of the liver Descriptions based on postmortem evidence place the incidence of amebic abscess of the liver in cases of amebic dysentery at about 50 per cent (Clark, Knowles), although in a small series of cases the incidence may be as high as six in eight cases (Councilman and Lafleur) Other series have shown, however, that less than half of the patients who die of amebic dysentery have an accompanying hepatic abscess (Strong and Musgrave found fourteen abscesses of the liver in seventy-nine cases, Kuenen, ten abscesses in thirty cases) Among fifty patients who gave but little clinical evidence of intestinal amebiasis and had been free form diarrhea during life, Musgrave[110] found four in whom abscesses of the liver were discovered at necropsy Depending on clinical rather than on postmortem evidence for his conclusions, Strong believed that in 22 per cent of cases of amebic dysentery abscess of the liver developed and that in from 60 to 90 per cent of cases of abscess of the liver a history of previous dysentery was obtainable That the modern treatment of amebiasis may reduce the frequency of amebic abscess of the liver as disclosed by necropsy is indicated by the report of Bartlett, who found tropical abscess of the liver but three times in sixty-one cases in which there were amebic intestinal lesions Nor is this complication peculiar to amebiasis acquired in the tropics Of forty American patients whose cases were reported by Hutchinson, eighteen had amebic abscess of the liver

109 Howard, W T, and Hoover, C F Tropical Abscess of the Liver, with a Consideration of Its Pathology and Clinical History, Am J M Sc **114** 150 and 263, 1897

110 Musgrave, W E Intestinal Amoebiasis Without Diarrhea A Study of Fifty Fatal Cases, Philippine J Sc **5** 229, 1910

Hepatic abscesses due to *Endameba histolytica* are usually single and are found most frequently in the right lobe (Kuenen) Involvement of the left lobe alone seems to be extremely rare, as the abscesses of the left lobe that occurred in 16 4 per cent of Rogers'[96] series were accompanied in all cases by similar processes in the right lobe He found that in from 55 to 59 per cent of cases there was but a single abscess, in from 23 to 27 per cent more than one large abscess, and in from 17 to 24 per cent one large abscess accompanied by several smaller abscesses When multiple small abscesses only are found, they may be numerous and then usually involve all lobes of the liver (Councilman and Lafleur) Of the single abscesses in the two cases of Councilman and Lafleur, one lay near the superior surface, near the suspensory ligament, and one lay near the inferior surface in the region of the hepatic flexure

The amebic abscess of the liver varies in size from a process so small as to be just visible to the unaided eye to one as large as a "child's head" (Kartulis[88]) The small, and probably younger, lesion presents changes in tissue that are looked on as characteristic of the hepatic lesion produced by *Endameba histolytica* The content of this small, typical lesion is thick, glassy, yellowish mucus (Strong) or, at times, it may be red, due to the presence of blood (Kartulis[86]) When examined microscopically, the material is found to be composed largely of granular detritus, with recognizable fixed tissue elements in small number fatty (Howard and Hoover) or swollen, generated hepatic cells (Strong), erythrocytes (Kartulis,[86] Councilman and Lafleur, Howard and Hoover, Strong) and a few leukocytes (Strong) or none (Kartulis,[86] Howard and Hoover) If leukocytes are present, they usually are of the mononuclear variety (MacCallum) Fibrin has been described as being present in the content of the abscess (Kartulis[86]), and amebas in great (Councilman and Lafleur) or small numbers (Howard and Hoover) in the content of small lesions Bacteria frequently are absent (Kuenen, Rogers,[111] Kartulis,[112] Councilman and Lafleur, Kruse and Pasquale,[99] and others), and the material within the abscess cavity is not purulent in the generally accepted sense of this term (Kartulis[113])

---

111 Rogers, Leonard Tropical or Amoebic Abscess of the Liver and Its Relationship to Amoebic Dysentery, Brit M J **2** 844, 1902, The Prevention and Treatment of an Amebic Abscess of the Liver, Philippine J Sc **5** 219, 1910, footnote 96

112 Kartulis, S Zur Aetiologie der Leberabscesse Lebende Dysenterie-Amoben im Eiter der dysenterischen Leberabscesse, Centralbl f Bakteriol **2** 745, 1887, footnotes 86 and 87

113 Kartulis (footnote 112, first reference)

In a postmortem examination held within one hour after death, Kartulis[113] found the amebas obtained from a hepatic abscess to be actively motile, and some of them contained two or three ingested erythrocytes

The wall of the small hepatic lesion is ragged, irregular, soft, grayish white (Howard and Hoover) and without a fibrous capsule (Kartulis,[86] Councilman and Lafleur, Kuenen, Bartlett) The change is that of necrosis of the liver, accompanied by a slight inflammatory reaction (Kuenen) Councilman and Lafleur did not find a definite restricting wall, they found only shrunken and broken hepatic cells, with no encircling inflammatory tissue From within outward, Kartulis[86] divided the wall of the abscess into three zones, the first, or inner, zone was made up of granular debris in which was imbedded fibrin, cellular and nuclear fragments, amebas and, rarely, bacteria By gradual transition, zone 1 entered zone 2, where were found large cells with granular cytoplasm and indefinite nuclei, some granulation tissue and "young" bile ducts Beyond this, in zone 3, he found loosened hepatic cells that had become spindle-shaped as the result of the pressure of the dilated and thickened blood vessels and of the infiltration with leukocytes and plasma cells In the layer of granulation tissue described by Bartlett as forming a part of the wall of the abscess, he observed infiltration with lymphocytes, plasma cells and a few polymorphonuclear leukocytes Kartulis[86] found amebas in the abscess cavity and found them in larger numbers in the necrotic tissue of the wall and among the changed hepatic cells and within the capillaries of the outer zone Bartlett found them in the débris close to the wall, in the layer of granulation tissue and in the blood vessels of it Strong found them mostly in the wall of the abscess, whereas MacCallum described them as seen at the point of greatest change in tissue Koch and Gaffky[114] described an abscess of the liver with cocci present in the wall of the cavity and amebas in the blood vessels outside of it They have also been described as being present in thrombi of the larger branches of the portal veins (Bartlett)

In large amebic abscess of the liver, changes other than differences in size appear Beyond the inner zone of necrosis, which resembles the corresponding layer of the small lesion, may be seen a capsule that Howard and Hoover described as a broad band of fibrous tissue, poor in nuclei and containing small capillaries This capsule may be incomplete, and may show, in places, the advancing destructive changes of the small lesions (Councilman and Lafleur) Beyond the abscess, distortion of hepatic tissue by pressure has been described (Rogers[96]), although

114 Koch, Robert, and Gaffky, Georg Bericht uber die Thatigkeit der zur Erforschung der Cholera im Jahre 1883 nach Egypten und Indien entsandten Kommission, Arb a d k Gsndhtsamte 3 1, 1887

a narrow surrounding border of congestion may be present (Councilman and Lafleur) Amebas are usually present in the necrotic wall of the large cavity (Councilman and Lafleur, Howard and Hoover), but they may be absent from the purulent content (Kuenen) Howard and Hoover described them in the necrotic tissue of the wall of the cavity but not in or beyond the fibrous tissue of the wall or in the deeper capillaries and veins Councilman and Lafleur were of the opinion that *Endameba histolytica* is not usually found deeper than the necrotic layer, but occasionally they found the organisms in the dilated capillaries at the border

Bacteria in Amebic Abscess of the Liver —That the amebic abscess of the liver may be due to the unaided action of *Endameba histolytica* is indicated by the failure to find bacteria in the content of the abscess or in the wall in about half of the cases (Kartulis,[86] Strong and Musgrave, Strong, Knowles) Rogers[115] found bacteria absent from hepatic lesions in half of the cases studied at necropsy and in 86 per cent of those examined at the time of the first operative puncture Bacteria are present most frequently in the large lesions (Councilman and Lafleur), and Kuenen ascribed to the presence of bacteria the formation of the fibrous capsule in such lesions

Origin of Amebic Abscess of the Liver —It is generally agreed that amebic abscess of the liver arises secondarily to the ulcerative process in the bowel (Kartulis, Councilman and Lafleur, Howard and Hoover, Harris,[98] Rogers,[101] and others), even when evidence of amebic intestinal ulceration cannot be demonstrated (Kuenen) Howard and Hoover believed that abscess of the liver was more likely to develop in the chronic cases of amebic dysentery than in the acute cases, although Musgrave in his study of fifty chronic and almost symptomless cases disclosed abscess of the liver in only four In four cases of multiple hepatic abscess, Kuenen found associated gangrenous intestinal changes in all

In the attempt to explain the means by which *Endameba histolytica* is transported from the intestinal lesions to the liver, speculation, based on but scant evidence, largely favors the idea that the blood stream coursing by way of the portal system is the carrier of the infection (Kartulis,[86] Harris,[98] Rogers,[96] Kuenen, Strong, Hutchinson, Knowles) Councilman and Lafleur found amebas in the peritoneal exudate in two cases, in one of which intestinal perforation had not occurred, and they believed that the flow of lymph in the peritoneum might transport the amebas across the abdominal cavity to the liver, which the amebas could then attack from the surface It seemed to them likely, however, that multiple hepatic abscesses could be explained best by assuming an

115 Rogers (footnote 111, second reference)

embolic process in the portal system In 1902 and 1903, Rogers [101] favored the idea of the peritoneal lymph current carrying the amebas to the liver, but he believed later [96] (1913) that this mode of transportation must be rare Boyers, Kofoid and Swezy [116] claimed to have found *Endameba histolytica* in material obtained by duodenal tube

Generalized Hepatic Changes in Amebiasis—More or less generalized hepatic changes in cases of amebiasis have been described, both changes accompanying hepatic abscess and changes occurring in its absence Councilman and Lafleur found the liver larger than normal or, as frequently, smaller They described degeneration about the intralobular veins, hyperplasia of the bile ducts and portal fibrosis Similar changes were described by Strong Howard and Hoover found the portal regions prominent and fibrotic In the absence of hepatic abscess, Bartlett found swelling and fatty changes in the central zone, infiltration of the connective tissue of the portal system with lymphocytes and plasma cells, increased portal fibrosis and occasional parenchymatous necrosis, accompanied by infiltration with pus cells Rogers [96] expressed the belief that the frequent development of hepatic cirrhosis in India might be due to toxic irritation having its origin in intestinal amebiasis

Amebic Abscess of the Lung—Amebic abscess of the lung appears with less frequency than that of the liver and is usually (Clark, Knowles), if not always, due to direct extension of the hepatic lesion into the pulmonary tissue (Councilman and Lafleur, Rogers [96]) The lower lobe of the right lung is most commonly involved (Councilman and Lafleur), although Rogers [96] described an involvement of the lower lobe of the left lung Even when a communication between the amebic abscess of the liver and that of the lung was not readily demonstrated, Rogers [96] felt that it could, nevertheless, be shown to exist In one of his cases of abscess of the lung, the hepatic process producing it was so small and so near the upper surface of the liver that the thin intervening wall had been destroyed, leaving a superficial cup-shaped depression in the surface of the liver, easily leading to the impression that the hepatic change was secondary to the larger pulmonary abscess, rather than the reverse

Councilman and Lafleur described the involved pulmonary lobe as solid, edematous, white and opaque or transparent The alveoli were small and filled with fibrin, and there was an ingrowth of connective tissue, the epithelial cells were cubical and resembled secreting cells The bronchi were thick and filled with erythrocytes, whereas some contained fibrin and pus Connective tissue grew into them from the walls

116 Boyers, L M , Kofoid, C A , and Swezy, Olive Chronic Human Amoebiasis A Review of the Diagnosis and Treatment on the Basis of Encystment in the Liver Area, J A M A **85** 1441, 1925

The cavities were usually empty, and were lined by an opaque, necrotic coat projecting irregularly into the cavity, with here and there a broken layer of connective tissue In places were found well preserved elastic fibers and some large round cells resembling amebas The content of the cavity was composed of granular detritus, lymphocytes, fat droplets and amebas Here, again, a well developed protective membrane or abscess wall was absent

Amebic Abscess of the Brain—Amebic abscess of the brain is exceedingly rare Knowles was able to find reports of only 50 or 60 cases as recently as 1928 During the study of 384 cases of abscess of the liver, Kartulis [88] observed but 11 cases of abscess of the brain, an incidence of 0 3 per cent Of these, 10 were associated with the hepatic lesion Not only is the process in the brain usually accompanied by an amebic abscess of the liver (Kartulis,[88] Legrand,[117] Knowles), but it has frequently appeared to develop following operative drainage of the latter (Kartulis,[88] Armitage,[118] Clark) In 1912, Legrand reviewed the literature on the subject and reported 48 cases of amebic abscess of the brain appearing up to that time The lesion ranged from 2 to 6 cm in diameter All but 3 were in male patients, and all but 10 showed the presence of *Endameba histolytica* Legrand found the distribution of the abscesses of the brain to be as follows 12 solitary abscesses in the right cerebrum, 6 bilateral cerebral abscesses, 6 abscesses opening into the lateral ventricles, 1 abscess in the left cerebellar lobe and 10 indeterminate abscesses

The puslike content of the amebic abscess of the brain has been described as similar to that of the amebic process in the liver (Strong) grumous and reddish (Armitage) or thick and greenish yellow (Sitsen [119]) It is composed of degenerating neuroglia, nerve and myelin fibers erythrocytes and pus cells (Armitage) Amebas may be present in the content of the abscess (Kartulis,[88] Legrand) and in the wall of the cavity (Sitsen) Bacteria are usually absent (Strong)

The wall of the abscess of the brain does not contain a membrane or sac (Armitage), but appears to result from progressive ulcerative necrosis (Legrand) It is ragged, shows projecting and thrombosed blood vessels and remnants of tissue, and is surrounded by an areola of punctate hemorrhages, dilated blood vessels and lymphocytic infiltration (Legrand) Amebas are in the necrotic wall (Legrand, Sitsen), as well as in the deeper tissue (Legrand)

Viereck described a case of multiple, superficial, flat hemorrhagic lesions about 2 cm in diameter They appeared in the frontal region

117 Legrand, quoted by Armitage (footnote 118)

118 Armitage F L Amoebic Abscess of the Brain, with Notes on a Case Following Amoebic Abscess of the Liver, J Trop Med **22** 69, 1919

119 Sitsen, A E, quoted by Armitage (footnote 118)

at the base of the brain, in the corpus striatum and in the right occipital lobe just under the surface Organisms found in these lesions were identified by Schaudinn as *Endameba histolytica*

Legrand described the dura as being more or less engorged with blood, but rarely adherent to the underlying lesions The arachnoid was clear, and spinal puncture gave negative results Legrand found the pia mater sometimes healthy and sometimes edematous, or if the abscess was near the surface of the brain, the pia might be grayish, red or violet, swollen and projecting Occasionally, the convolutions above the lesions were flat and diffusely red, at times, amebas were present in small numbers on the surface of the brain in the region of the inflammatory area

It is highly probable that *Endameba histolytica* is transported to the brain by way of the blood stream (Kartulis,[88] Viereck, Sitsen Knowles) Sitsen described a case of abscess of the brain in which an accompanying abscess of the liver communicated directly with the vena cava Draining an amebic abscess of the liver appears to be a frequent exciting cause of cerebral abscess (Kartulis,[88] Armitage, Clark) At necropsy in cases of amebic abscess of the liver, the hepatic process has been described as "healing" (Kartulis,[88] Sitsen)

Amebic Abscess of the Spleen—Only two cases of amebic abscess of the spleen have come to my attention (Maxwell,[120] Rogers [96]) Both were clinical, only, in both motile amebas were shown in the aspirated fluid and in both the patients were cured, one patient by aspiration combined with the use of emetine Maxwell expressed the belief that in his case the spleen was invaded directly by way of the splenic flexure of the colon Bartlett did not find splenic changes in cases of uncomplicated intestinal amebiasis

Other Complications of Amebiasis—Complications of amebiasis beyond those involving the liver, brain and spleen consist largely of changes resulting from intestinal perforation of amebic ulcers, extension of hepatic abscesses into adjoining structures or rupture into neighboring cavities of the body

Kartulis [113] described empyema of the pleural cavity, with direct communication between the pleural cavity and an amebic abscess of the liver In the case of Howard and Hoover, a case of thoracic empyema of the right side, communication between the pleural cavity and the abscess of the liver was by means of an opening through the diaphragm large enough to admit the hand The lung was flattened and airless, whereas the pleura was thick, covered with a layer of fibrin and infiltrated with lymphocytes and pus cells On and in the exudate,

120 Maxwell J P Two Rare Cases from Fukien Province, South China, Tr Roy Soc Trop Med & Hyg 2 289 1909

superficially, were found a few scattered amebas They were also fairly numerous in the fibrinous exudate within the inflamed pericardial sac Rogers [96] found hepatic abscess communicating with the pleural cavity on each side, with the stomach, with the stomach and the pericardium, and with the omental bursa Lesions of the right lobe were found opening into the right colonic flexure, the cecum, the duodenum the pericardium, the inferior vena cava and the general peritoneal cavity Kuenen reported retroperitoneal rupture of a hepatic abscess, and Musgrave described two cases of abscess of the liver, one of which communicated with the right pleural cavity, the other of which opened into the abdominal cavity

Councilman and Lafleur described peritonitis arising from amebic ulceration of the bowel in three cases, in one case, the peritonitis was local, and in two cases it was general The local process occurred without intestinal perforation, the two general processes were due to perforation, and in the peritoneal exudate of the latter amebas were found Musgrave reported two deaths from perforation of an amebic lesion of the appendix and five from perforation of ulcers of the colon, four of these ulcers were in the cecum and ascending colon and one was in the transverse colon Kuenen described peritoneal irritation resulting in cases in which the ulcer reached the layer of intestinal muscle, whereas Clark reported peritonitis to be slightly more common with nonperforating lesions Perforation explained eighteen of thirty-seven cases of peritonitis Strong mentioned the possibility of amebic cystitis and the possibility of fistulas being attacked by amebas from the deeper process in the liver or bowel, with involvement of the skin surrounding such fistulous tracts Inflammatory adhesions (Doptei [4]) may lead to intestinal distortion and obstruction (Davidson)

Lesions differing widely from those generally accepted as peculiar to amebiasis and involving tissues remote from the ones usually attacked by *Endameba histolytica* were reported by Warthin [121] Kofoid [6] and Panayotatou [122] Warthin's case was that of a young Russian Jew who had had intestinal amebiasis and who died following operative exploration for a suspected abscess of the liver Intestinal changes were present, which Warthin interpreted as the results of healed amebic lesions, and, in addition, amebas were found in the left epididymis, in the dilated ductuli efferentes and in a few of the dilated seminiferous tubules near the rete Some of them contained ingested spermatozoa Kofoid [6] believed that "Ely's second type of arthritis

121 Warthin, A S The Occurrence of Entamoeba Histolytica with Tissue Lesions in the Testis and Epididymis in Chronic Dysentery, J Infect Dis **30** 559 1922

122 Panayotatou A L'amebiase intestinal et ses localisations extra intestinales Monograph Paris, Vigot Freres, 1926, p 1

deformans" was due to the action of *Endameba histolytica* and identified endamebas in the tissues of the joint by the character of their mitotic figures He also described "ameba-like" cells in extirpated glands of patients with Hodgkin's disease[108] and later identified them as *Endameba histolytica* The amebic bronchitis, cystitis, nephritis and mastitis of Panayotatou could not be verified by pathologic examination of tissues, since all of her patients recovered following the use of emetine

Parenchymatous changes not associated with the presence of *Endameba histolytica* in the tissues involved will not be discussed They are not peculiar to amebiasis but resemble those of infection and toxemia in general

AMEBIC LESIONS IN ANIMALS

The experimental production of amebiasis in animals has usually been incidental to the study of *Endameba histolytica* as a protozoon parasite or to attempts to determine its pathogenicity Too frequently, statements that amebic lesions were present in the intestinal tract of the experimental animal have constituted the sole contribution to the knowledge concerning the pathologic changes produced Careful, exhaustive studies of amebic lesions produced experimentally have rarely been made, the descriptions of them frequently have contained just enough detail to establish the amebic nature of the lesions Into experiments in inoculation there have been introduced, also, operative procedures (Sellards and Theiler, Rees[123]) that have of themselves so modified the intestinal changes, at times, as to make it difficult to separate the changes resulting from operation from those due to *Endameba histolytica* acting alone Commonly, a superficial resemblance between the amebic lesion of man and that of animals has been noted, and only rarely have any essential differences been stressed (Viereck)

Amebiasis in Kittens and Cats—In kittens and cats, as in man, intestinal ulceration resulting from the action of *Endameba histolytica* is largely restricted to the colon (Kovacs, Quincke and Roos, Kruse and Pasquale,[124] Marchoux and others), with only occasional involvement of the lower part of the ileum (Sellards and Theiler, Boeck and Dibohlav[10]) Generalized changes of the colon have been described (Kovacs, Boeck and Dibohlav,[10] Wagener, Kessel[67]) Regions of localization of the amebic lesions within the colon most frequently specifically mentioned have been the cecum and rectum (Marchoux, Kessel[67]) The rectum has been named as the region most prone to attack (Wenyon,[5] Sellards and Baetjer,[59] Sellards and Leiva,[57]

123 Rees (footnotes 64 and 67)

124 Kruse and Pasquale (footnote 44, first reference)

Wagener) Dale and Dobell thought the upper and the lower third of the colon to be most frequently involved, whereas Boeck and Drbohlav [10] believed the same to be true of the cecum and the sigmoid flexure In operative ligature of the bowel that has been the site of injection, lesions were always restricted to the bowel above the point of occlusion (Sellards and Theiler, Rees [123]) In these cases, Rees [66] found that the most severe lesions were those that developed in the region of the ileocecal valve

Intestinal Amebic Lesions of the Cat and Kitten Experimental amebiasis in cats and kittens frequently produces a superficial lesion of the mucosa of the intestine (Kartulis,[41] Kruse and Pasquale,[124] Dopter,[1] Baetjer and Sellards,[73] Sellards and Leiva,[57] Knowles) Knowles expressed the belief that this was the only intestinal lesion produced in the cat and that deep and circumscribed ulceration did not occur This was the experience of Kruse and Pasquale [124] Sellards and Baetjer [59] recognized this lesion as "early," and it was described by them as an "acute hyperemia, congestion and edema of the mucosa and submucosa without ulceration," while Sellards and Leiva [57] believed the superficial lesion to be the one most commonly encountered in the very young animal The process may be diffuse, without a trace of normal mucosa in the inflamed region (Sellards and Leiva [57]), or more sharply circumscribed (Craig [46]) Mucosal swelling of such a grade as to approach an obstructive lesion was found by Sellards and Baetjer [59]

In a study of the superficial intestinal lesion of the cat, Kovacs [42] found infiltration of the free surface of the mucosa with round cells, which, in places, reached as deeply as half the thickness of this layer In regions of greatest cellular infiltration, necrosis occurred, which rarely involved the whole depth of the mucosal layer Superficial congestion and hemorrhage were present Changes in the submucosa, vascular congestion and cellular infiltration appeared only below regions of deep mucosal change

St John [125] described a small break in the mucosa, which was triangular in shape on cross-section, with the apex of the triangle reaching the deep mucosa or the muscularis mucosae In this region, the mucosa was destroyed and converted into a debris of changed tissue cells leukocytes, of which but few were pus cells, with an occasional ameba in the necrotic tissue only Below this was found edema of the submucosa, with cellular infiltration about the blood vessels

Continued extension of the superficial ulcerative process may lead to lesions involving the deeper intestinal tissues (Quincke and Roos, Schaudinn, Dopter,[1] Craig,[46] Wenyon,[5] Baetjer and Sellards,[73] Sellards

125 St John, J H Differential Characteristics of the Amoebae of Man in Culture, Am J Trop Med 6 319, 1926

and Baetjer [59] Dale and Dobell, Boeck and Drbohlav [10] and others) and reaching, at times, the muscle layer (Jurgens,[126] Boeck and Drbohlav [10]) Submucosal extension may outstrip the overlying mucosal lesions, producing an undermined ulcer that is covered in part by mucosa and that may resemble the advanced amebic lesion found in the intestinal tract of man (Craig,[46] Jurgens, Wenyon,[5] Sellards and Baetjer [59]) Local and remote defensive inflammation may surround the deeper lesion (Dopter [4]) with vascular congestion and cellular infiltration (Jurgens) Boeck and Drbohlav [10] described moderate inflammatory reaction about the deep intestinal lesions of the cat, however, with but few pus cells in the irritated regions

Rees [66] recently described the changes produced in kittens by the operative injection of cultures of *Endameba histolytica* into the cecum, accompanied by ligature of the bowel below the point of inoculation In one animal, killed ninety hours after inoculation, there was complete destruction of the epithelium lining the colon, with great thickening of the mucosa and submucosa and necrosis of many of the deeper cells Rees expressed the belief that an early and characteristic change of the intestine of the kitten was widely opened mucosal crypts and increased distention of the goblet cells (see also Hadley [127]) In the latter observation, however, Rees failed to draw a sharp distinction between the lesions presented by animals without intestinal occlusion and those accompanying artificially produced obstruction Whether these changes occurred in both groups of animals is not clear

No account of a submucosal lesion unconnected with a lesion of the mucosa, in the cat, such as that noted in descriptions of amebic intestinal ulcers in man, has come to my attention All observers are agreed that the deeper lesions in this animal results from extension of the mucosal process

In the ulcerative lesion of the intestine of the cat and kitten, *Endameba histolytica* has been found in the mucus on the inner surface of the bowel (Kovacs), in regions of superficial necrosis and in the necrotic masses (Kovacs, Dopter,[1] Boeck and Drbohlav [10]) Kovacs found amebas in deep necrotic regions, as did Schaudinn, Quincke and Roos and St John [125] Kovacs found none beyond the bordering infiltration, although Schaudinn described them in distant, healthy tissue Jurgens and Wenyon [5] described them in intact crypts of the mucosa and believed the destructive process was initiated there Dopter,[1] on the other hand, found amebas only in glands the epithelial cells of which had undergone previous change He [1] and Rees [67] believed the first

126 Jurgens Die Amoben-Enteritis und ihre Beziehungen zur Dysenterie, Ztschr f exper Path u Therap **4** 769, 1907

127 Hadley, P B The Part Played by the Goblet cells in Protozoan Infections of the Intestinal Tract, J M Research **36** 79, 1917

attack to be superficial, with simultaneous destruction of the surface epithelium and the interglandular connective tissue In one cat, Boeck and Drbohlav [10] found *Endameba histolytica* within blood vessels of the submucosa

Amebic attack on the solitary intestinal lymph follicles occasionally has been observed (Jurgens, Boeck and Drbohlav,[10] Rees [67]) Jurgens expressed the belief that the only intestinal lesion present in amebiasis of the cat might be widespread and deep invasion of these structures

As in man, amebic invasion of the mesenteric lymph nodes is extremely rare in the cat Wenyon [5] alone described a mesenteric node filled with large numbers of *Endameba histolytica,* some of which contained digested cells of glands Simpler changes are not uncommon Jurgens found them swollen, and Dale and Dobell described them as purulent at times, but amebas were never present in them

Bacteria have been believed to play an important part in the amebic lesion of the cat, if only as a secondary invader (Wenyon [5]) Sanders wrote of terminal bacteremia, and mentioned the likelihood of earlier bacterial sepsis Sellards and Baetjer [59] thought that death in the younger animals was more frequently the result of bacterial invasion of the body by way of the amebic lesions of the bowel than the consequence of the amebic process itself Dale and Dobell believed the death of animals ill with amebiasis was usually due to sepsis, although this view was not based on bacterial studies of the local intestinal lesions nor of distant organs Rees [66] spoke of the possible importance of bacterial modification of the amebic intestinal process

Healing of the amebic lesion in the intestinal tract of the cat and the kitten is rare The older and more resistant cat is more likely to show the chronic and undermined ulcer and has been known to become a carrier of the infection, remaining free from symptoms of amebiasis (Sellards and Baetjer [59]) The recovery of a cat previously infected with *Endameba histolytica* has been described (Schaudinn, Mayer), and Wagener and Thomson mentioned finding healed intestinal ulcers in a cat previously ill with dysentery

Abscess of the Liver in Cats—Amebic abscess of the liver is the only complication of dysentery that has been described as occurring in the cat or the kitten Sellards and Baetjer [59] believed it developed in the more chronic cases, whereas Marchoux found it associated with ulcerative lesions of the rectum and believed its development to be the rule in animals that lived as long as fifteen days Sanders found abscesses of the liver in 3 kittens that died of amebic dysentery after twenty, twenty and twelve days, respectively Of 126 kittens infected experimentally by Mayer (see study 2) later presented abscess of the liver 1 as early as four days after the appearance of the symptoms of

dysentery, others as late as from two to three weeks The abscesses may be solitary (Marchoux, Werner Baetjer and Sellards,[73] Sanders) or, rarely, multiple (Marchoux, Sanders) When they were multiple, Marchoux found them to be small

Meager descriptions of the amebic abscess of the cat indicate that it is similar to the amebic lesion of man It was described by Baetjer and Sellards[73] as "more a necrosis than an abscess," and Boeck and Drbohlav[10] observed it to be free from a surrounding inflammatory reaction Sellards and Baetjer[59] found the content of the abscess to be of such a nature that "none of it could have been aspirated" Amebas are usually present in the hepatic lesion (Marchoux, Werner, Sellards and Baetjer,[59] Dale and Dobell, Mayer Boeck and Drbohlav,[10] Sanders), whereas bacteria may be present (Marchoux) or absent (Boeck and Drbohlav[10]) Strangely, Mayer observed cysts of *Endameba histolytica* in the content of the abscess in two of his four cases

Amebiasis in the Dog—The condition is rare in this animal (see study 2), and few complete descriptions of the intestinal lesions produced by *Endameba histolytica* have appeared in the literature Yet, interestingly enough, the first experimental lesion in an animal was that produced in the dog In the colon of one dog experimentally infected with amebiasis Losch observed intestinal ulcers, in the mucus of which he found amebas similar to those used for the inoculation Harris[65] described two types of intestinal lesions in experimentally induced amebiasis of the dog an "acute" and a "chronic" lesion The acute lesion occupied the summits of the intestinal mucosal folds and began as catarrhal desquamation of the surface cells with later involvement of the basal membrane Early the mucosal crypts were narrowed while the epithelial cells lining them seemed to be intact The mucosa was swollen and hemorrhagic, and the blood vessels and lymph spaces were dilated Later, the glandular crypts were destroyed down to the submucosa, and amebas were present in the mucosa and in the "exudate" In the mucosa outside the ulcerative process were dilated blood vessels and lymph vessels with their lining epithelium swollen and often desquamated Below the mucosa, the submucosa was swollen, infiltrated with lymph and erythrocytes, and contained distended blood vessels In the chronic lesion, the observations were similar to those of the acute lesion, except that more conspicuous submucosal changes appeared, to the cellular infiltration were added mast cells and a few pus cells Two of the animals had abscesses of the liver The lesions here were described as small and bordered by hepatic cells only, and there were but slight surrounding changes In the content of the abscesses was débris, in which could be recognized erythrocytes, pus, hepatic cells and amebas In a dog dead of spontaneous amebiasis,

Darling[72] found the whole colon the seat of minute, punctiform, red erosions of the mucosa surrounded by swollen, pale yellow mucosa covered with flakes of mucus Large ulcers were not present The small, eroded spots were infiltrated with amebas and leukocytes In regions, the superficial epithelium had been replaced by great masses of amebas, which had effected slight penetration of the mucosa Amebas were also present in the lower part of the ileum and had invaded the wall of the bowel at one place without having produced a recognizable ulcer

Amebiasis in the Rabbit—Two observers reported the production of amebiasis in the rabbit Huber described the cecum of the affected animal as hard, thick and opaque, the inner surface was red and ulcerated, but was covered in large part by mucosa This process was confined to the cecum, although the upper third of the colon was inflamed and contained blood-tinged mucus He found the amebas entering the wall of the bowel by way of the mucosa, which showed but little change In the submucosa, which was thickened were cellular debris, leukocytes, dilated blood vessels and amebas He expressed the belief that the surface defect resulted from the more extensive submucosal process, breaking its way through the mucosa from below Thomson found amebas invading the mucosa, the submucosa and the circular layer of muscle of the cecum, to which the process was confined She found *Endameba histolytica* also in the intestinal lymph nodes and lymph channels, as well as within blood vessels and within spaces surrounding them

Amebiasis in the Guinea-Pig—The only full description of the rare amebic lesion in the bowel of the guinea-pig is that of Chatton[81] He found the cecum thick, rigid and contracted, with numerous white spots on the inner surface, which proved to be miliary abscesses In severe cases he found some slight involvement of the rectum, but did not find true intestinal ulcerative lesions The cecal mucosa was thickened, cystic and covered with a diphtheroid membrane Scrapings of this showed much detritus, mononuclear cells and amebas, which, on staining, were recognized as *Endameba histolytica* The submucosa was greatly thickened and more nearly resembled a spindle cell sarcoma than a region of inflammatory hyperplasia

Amebiasis in the Rat—Although the rat has been used frequently in the experimental production of amebiasis and seems susceptible to the disease (Lynch, Brug, Kessel[128] Chiang), descriptions of the lesions produced are few Lynch described the process as usually restricted to the cecal portion of the colon The lesions varied from the typical amebic ulcer to a catarrhal lesion with some superficial erosion of the

128 Kessel (footnote 78, first and second references)

mucosa without gross ulcerative lesions Cysts of *Endameba histolytica* have been described as occurring in the intestinal content of the infected rat (Lynch, Kessel [129])

Amebiasis in Other Animals—Intestinal changes due to amebiasis in other animals will not be considered here With the exception of the monkey, which has been frequently rejected for use in the production of amebic dysentery because of the likelihood that it may develop the disease spontaneously and the expense of using such animals (Sellards and Leiva,[60] Dobell and Laidlaw), amebic changes produced in animals other than those already considered have been exceedingly rare

NATURE OF THE ATTACK

In considering the nature of the attack of *Endameba histolytica* on human and animal tissue, wide differences of opinion have been expressed Schaudinn expressed the belief that destructive changes were largely due to the mechanical action of the hard pseudopodia extruded by the organism Kartulis [86] favored this explanation at first, but later [87] adhered to the idea that the ameba acted on tissue by means of a proteolytic secretion This explanation of the action of *Endameba histolytica* seemed more reasonable to Harris,[98] Dopter,[4] Christoffersen, Dobell [9] Hegner and Taliaferro, James,[130] Knowles and Hutchinson Some experimental evidence in support of the belief now generally accepted, that *Endameba histolytica* acts by the production of a tissue-destroying enzyme, is that of Wagener and that of Craig [131] Wagener was able to show that the blood of animals ill a week or more with amebiasis gave a positive precipitin reaction with an antigen prepared from the scrapings of the amebic ulcers of the intestinal tracts of cats Craig [131] showed that alcoholic extracts of *Endameba histolytica* from cultures presented complement-binding properties and were hemolytic and cytolytic in action In favor of the mechanical action of *Endameba histolytica* Hadley presented evidence that a trichomonas of birds may enter the intestinal tissue by way of the goblet cells of the mucosa, and thought, by analogy, that the same might be true of *Endameba histolytica* in the intestinal tract of mammals Evidence has not been presented to substantiate this belief

Differences of opinion concerning the pathogenicity of *Endameba histolytica* have appeared Musgrave found amebic lesions in all of

129 Kessel (footnote 78, second reference)

130 James, W M Some Observations on Intestinal Amoebiasis Due to Infection with Entamoeba Histolytica, United Fruit Company, Med Dept **1** 185, 1927, footnote 105

131 Craig, C F Observations upon the Hemolytic, Cytolytic and Complement-Binding Properties of Extracts of Endamoeba Histolytica, Am J Trop Med **7** 225, 1927

fifty patients who displayed, during life, few if any of the usual symptoms of amebic dysentery Dobell[9] believed *Endameba histolytica* was always pathogenic for man, and the work of Kessel[63] indicated that this was probably true However he described monkeys harboring *Endameba histolytica,* which seemed to be present in them as harmless parasites That the same may be true of *Endameba histolytica* in man, also, has been suggested by James[130] Knowles and others[132]

The part played by bacteria in amebic lesions has been the subject of controversy At first Kartulis[86] held that bacteria were the true cause of the lesions both intestinal and hepatic, although later he[87] thought that amebas, unassisted, were capable of producing lesions Woolley and Musgrave and James[133] felt that *Endameba histolytica* did not attack healthy bowel but initiated lesions only following irritative changes due to other causes probably bacterial

Concerning the points or regions of the primary attack of *Endameba histolytica* on the intestinal wall, widely diverging views have been held That the mucosa was the tissue attacked first was held by Doptei,[4] Kuenen, Christoffersen, Kaufmann and Wenyon[51] Wenyon[51] expressed the belief that the intact glandular crypts were invaded first whereas Kuenen and Delafield and Prudden thought the first or principal attack of *Endameba histolytica* was on the mucosal connective tissue Kotoid[6] expressed the belief that either the epithelial cells or the connective tissue of the mucosa might be attacked first whereas James[105] found both involved equally Councilman and Lafleur thought the first intestinal change was that of the submucosa To reach it, the amebas traversed the mucosa without changing it appreciably They expressed the belief that the ulcerative destruction of the mucosa that was seen in the larger lesions was due to the extension of the deeper process into the lumen of the bowel With this view Kruse and Pasquale[99] Harris,[98] Rogers[101] and Bartlett also agreed

METHODS

The amebic lesions for this study were produced by introducing motile forms of *Endameba histolytica* from the stools of man into the intestinal tracts of kittens by rectal injection by injecting ameba-containing stools of kittens thus infected into others in the same manner, and by the injection of *Endameba histolytica* from cultures directly into the cecum of kittens following laparotomy (see study 2) In some of the last group, the bowel was ligated near the rectum at the time of inoculation, whereas some received the cecal injection only Two of the former group of kittens and one of the latter became infected with *Endameba*

132 Knowles R Das Gupta B M , Gupta, A K D and Gupta Umapati The Treatment of Intestinal Amoebiasis An Analysis of Results and a Review of the Literature Indian M Gaz **63** 455 1928

133 James (footnote 130, first reference)

histolytica, grown on the medium of Boeck and Drbohlav,[10] to which rice starch had been added as recommended by Dobell and Laidlaw (see study 1)

To prevent the development of intestinal postmortem changes, every animal, that, judged by its actions, seemed about to die soon was killed As quickly as possible after death, within five minutes, the tissues to be examined were placed in Schaudinn's fixative solution, and, after being sectioned, were stained with iron-hematoxylin and eosin Some of the kittens used in the beginning of this work were killed as soon as it was determined by an examination of the stool that infection was probably present This was done so that the earliest amebic lesion might be studied Later, others were permitted to live until it seemed that they were about to die of the infection It was hoped that an abscess of the liver might develop in one of the animals However, none developed, although four kittens lived from six to eleven days following the development of dysentery

Only one kitten with amebic dysentery died of the infection This animal was young, and amebas had been present in the stool less than twenty-four hours following an incubation period of one day Postmortem changes here were so pronounced that it was with difficulty that a diagnosis of amebiasis could be made from an examination of the intestinal tract My experience with this animal and with others subjected to necropsy as early as one hour after death makes me feel that any delay in obtaining and fixing intestinal tissue after death may result in definite postmortem changes, at least so far as the superficial mucosal epithelium and the amebas are concerned

RESULTS AND OBSERVATIONS

Of the nine kittens in which intestinal lesions resulted from the rectal injection of stools of human beings or of animals that contained motile forms of *Endameba histolytica,* four showed amebic lesions throughout the colon In one of these, cecal involvement was most pronounced whereas, in two, the most conspicuous changes were in the rectum Of animals presenting less extensive involvement of the colon, one showed many small cecal ulcers, associated with similar processes in the rectum, the remainder of the bowel being free In three of four older kittens, about half grown, lesions were restricted to the rectum, in the fourth there were small ulcers throughout the colon and more conspicuous lesions in the rectum When lesions were noted throughout the colon, only small ulcers were found in the middle portion of the bowel In none of these kittens was there amebic involvement of the ileum

In two kittens infected by the operative cecal injection of *Endameba histolytica* from cultures, in which intestinal obstruction had been produced artificially, ulceration of the colon was not evident to the unaided eye, although later histologic examination revealed almost complete amebic destruction of the superficial portion of the mucosa throughout the region In one animal, similarly inoculated with *Endameba histolytica* from cultures, but without ligation of the rectum there developed in the cecum many superficial amebic ulcers, which decreased in size

and numbers as the middle portion of the colon was approached Beyond the middle portion of the colon lesions were not seen

Early Amebic Lesions in Kittens—Kitten 28, about a third grown and not previously used experimentally, was killed and examined twenty-four hours after the onset of dysenteric symptoms, which were accompanied by the appearance of *Endameba histolytica* in the stools There was generalized involvement of the colon with superficial ulcers varying in size from those just visible to the unaided eye to lesions 1 or 2 cm in diameter For study by serial section, there was selected a very small isolated ulcer of the middle portion of the colon It was the smallest lesion recognized as ulcerative that was far enough removed from the other lesions to be surrounded by a moderately wide margin of normal



Fig 5—The earliest intestinal lesion of kitten 28 (serial section), × 350 Three amebas are in the field, two with nuclei showing The reaction in tissue is limited

looking mucosa In the sections of this tissue cut and mounted serially, there appeared not only the macroscopic ulcer chosen originally for study, but several other ulcers, the smallest of which was included in fifteen sections each of which was 8 micromillimeters thick

This ulcer occupied the depth of a crease in the mucosa [134] and was so sectioned that the adjacent mucosal glandular crypts were cut trans-

134 A careful description of the configuration of the mucosa of the colon of the cat has not come to my attention Certainly, in the young cat, the saccules, haustra, resulting from the action of the longitudinally placed taeniae coli are very inconspicuous In the empty bowel there appear, however, mucosal folds or rugae which, in great part, assume a direction transverse to the longitudinal diameter of the bowel Although roughly transverse in direction, three or more such folds may meet to produce a crater-like pocket, as well as the commoner groove-shaped crease It is not unlikely, therefore as seem at times to be the case, that the ameba may initiate changes in this minute circular cavity, as well as in the depths of the longer creases between rugae

versely or obliquely (fig 5) Although the lesion was surrounded by mucosa and appeared to occupy a position below the mucosal surface, study of the sections on either side showed that the process was actually limited to the surface epithelium at the bottom of a mucosal crevice, microscopic in size The small central area of necrosis was composed largely of small cells (lymphocytes?) with small, deeply staining nuclei and a few amebas, not more than two or three of the latter to each section (fig 5) In one wall of the lesion, glandular crypts bordering the exudate contained shrunken cells with pyknotic nuclei on the sides of the crypts in contact with the central necrotic area, whereas cells of

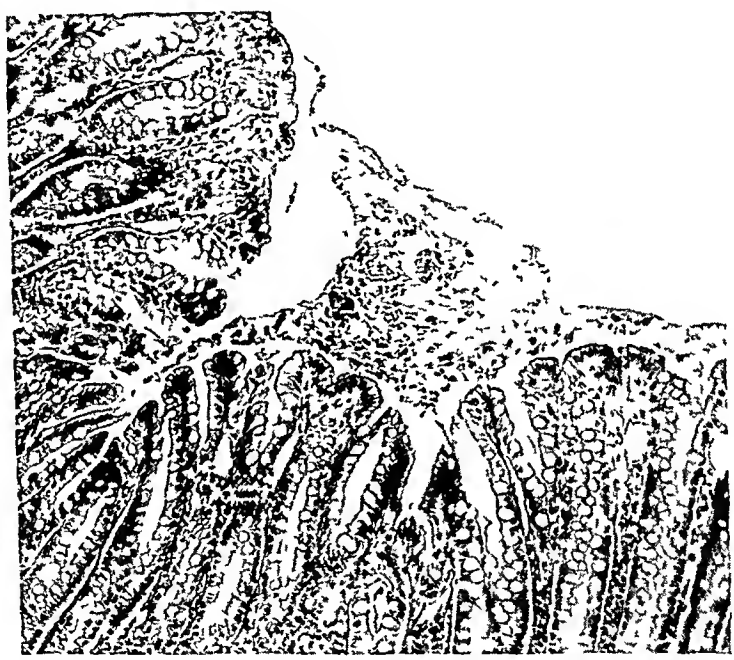

Fig 6—Early amebic lesion in the middle portion of the colon of kitten 28 (serial section) showing invasion of the depth of a mucosal crease, × 100

normal appearance were found in the same glands no farther away than a fraction of the diameter of a mucosal crypt Goblet cells were visible in a mucosal crypt directly on the exudate In the opposite mucosal wall were more marked changes, namely, thickened interglandular connective tissue and infiltration of this with cells, mostly lymphocytic This inflammatory reaction was extremely limited and extended for but a portion of the thickness of the mucosa in any direction, whereas epithelial and connective tissue cells were equally involved in the process Amebic invasion of unchanged tissue or glandular crypts was not evident In appearance the tissue changes seemed to result from the action of a lytic substance, local in its extent, but destructive, nevertheless out of all proportion to the number of amebas present

A second and larger amebic ulcer still microscopic in size was disclosed by the same serial sections It showed clearly the tendency for amebic lesions at least in the middle portion of the colon, to begin in grooves produced by normal mucosal folds (fig 6) A section near the margin of this ulcer suggested an early lesion, with the amount of change so slight as to raise the question whether a lesion was present, until it was examined under higher magnification (fig 7) Further study of the sections including this ulcer showed that, although recent, it was far more advanced than the first lesion described There was more destruction of tissue and amebas were present in the exudate and

Fig 7—The area indicated in figure 6, magnified five hundred times One ameba with nucleus is in focus One wall shows change in staining reaction of epithelial cells, with slight beginning destruction

in the necrotic tissue in larger numbers and cellular infiltration was more pronounced and more widespread At one point, five amebas were seen to occupy a mucosal lymphatic space that still was lined, in part, by what appeared to be intact endothelium (fig 8) Here, again, the attack of the amebas seemed to be by means of a lytic secretion that involved epithelial cells and connective tissue equally, and without the invasion of unchanged tissue or glandular crypts by the amebas Infiltration of the tissue immediately surrounding the area of attack was slight whereas just below the ulcer and between it and the muscularis mucosae were column-like portions of interstitial tissue showing marked

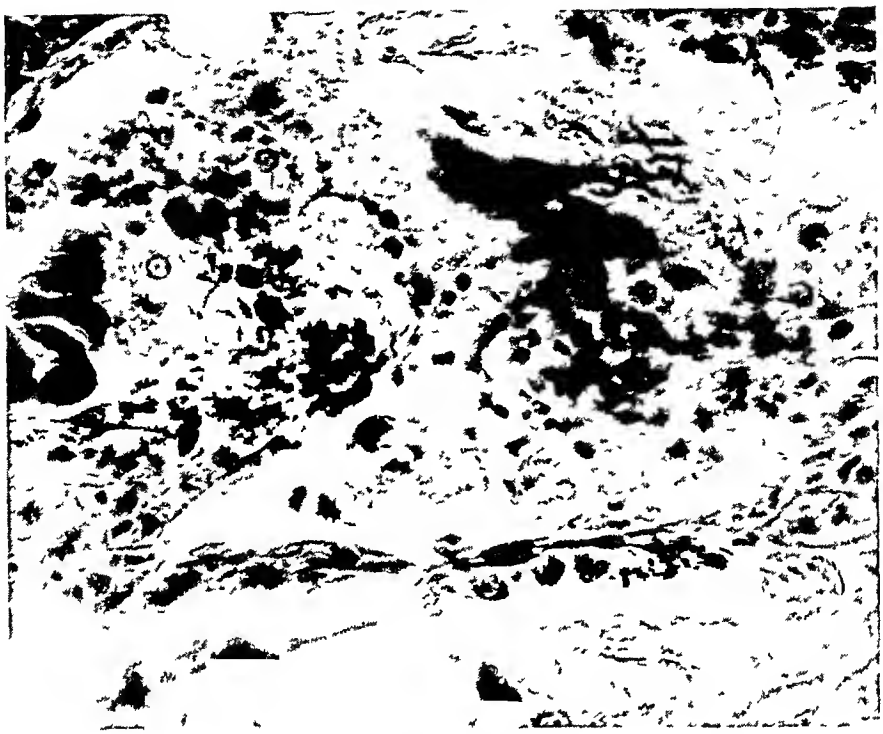

Fig 8—A deeper section of the ulcer pictured in figure 6, showing five amebas within a mucosal space lined with endothelium, × 500 Other amebas in changed tissue are surrounded by cellular infiltration



Fig 9—Middle section of an ulcer, showing occlusion of crypts of mucosal glands at their juncture with the necrotic tissue, × 150 It is not evident in this section that the attack was determined by a mucosal crease

infiltration with lymphocytes In less degree, the latter change sometimes occurred in portions of the bowel that were free from lesions, and in the intestines of cats in which there were no amebic lesions Surrounding the lesion was about the degree of production of mucus commonly seen in the colons of kittens that are free from demonstrable lesions of any sort Only at the point of amebic attack was there no production of mucus

Reconstruction of a third ulcer disclosed by this series of sections showed it to be bluntly cone-shaped, with the circular base at the free border of the mucosa, and the rounded apex approaching, but not reaching, the muscularis mucosae The necrotic core, still in place, was composed of structureless, granular debris in which were recognizable amebas and erythrocytes The study of sections through one edge of the ulcer showed that it, too, had its beginning in a mucosal fold This impression would not have been gained, however, by an examination of sections from the center of the lesion alone or from the opposite margin (fig 9) The line of demarcation between the necrotic center and the surrounding tissue was not sharp The floor of the ulcer was ragged Destructive changes increased gradually as the lesion was approached, with cellular infiltration so marked that the only recognizable tissue present at the necrotic border was an occasional, loosened, shrunken and deeply staining epithelial cell The infiltration was largely lymphocytic, was below the ulcer rather than around it, and so compressed and distorted the mucosal crypts that near the points where they entered the necrotic zone they appeared occluded Production of mucus in the mucosa surrounding the ulcer was normal and persisted to the margin of the ulcer Goblet cells were entirely absent in these crypts, only the superficial portion of the mucosa was destroyed by the ulceration No amebas were in the glandular crypts or in tissue outside the area of necrosis In this lesion, extending but little deeper than half the thickness of the mucosa, submucosal changes were absent

Serial sections of the larger lesion originally selected for macroscopic study showed it to extend more widely over the mucosal surface, although its depth was but little greater than half the thickness of the mucosa The necrotic tissue more a cap than a corklike core, flowed out over the mucosa at one side of the lesion as a thin, ameba-containing cover Below the central necrotic mass and below the exudate extending over the mucosa there were marked lymphocytic infiltration of the interstitial tissue of the mucosa and absence of goblet cells Beneath the thin ameba-containing sheet there was patchy destruction of the most superficial epithelial cells only In the region of the ulcer and in the depths of the necrotic tissue were amebas in large numbers Following the sections from the margin of the ulcer toward its center, one found that the mucosal crypts, closed in their more superficial portions

by the surrounding cellular infiltration, finally opened directly into the central exudate as the destructive process approached their more deeply placed and slightly expanded blind ends Thus it appeared that amebas might enter mucosal crypts after the ulcerative process had reached a depth a little greater than half the thickness of the mucosa (fig 10) Although there usually were marked changes in the invaded crypts, with loosened and shrunken epithelial cells showing modified staining reactions (fig 11 *A*), amebas occasionally were found in the depths of glands that showed but little local change other than the absence of goblet cells (fig 11 *B*) In all instances, however, it was found that the invaded crypts, appearing but little changed in their deeper portions, were but remnants of glands destroyed superficially by the ulcerative process In all other particulars, this larger lesion corresponded with those already described

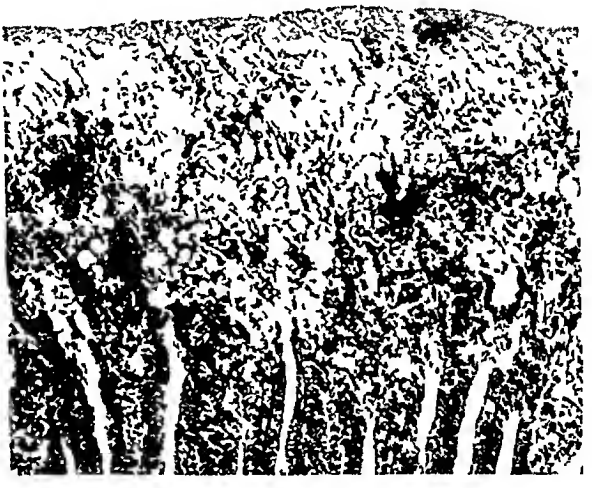

Fig 10—Larger amebic ulcer in the middle portion of the colon of kitten 28, showing necrosis of about half the depth of the mucosa, × 100 A few glands are seen to open into the necrotic tissue

In this kitten there was no involvement of the solitary lymph follicles in the amebic process and no amebas were found in the mesenteric lymph nodes draining the colon

Kitten 26, previously inoculated with material from the stool of a human being containing *Endameba histolytica* (see study 2), was infected following rectal injection of the dysenteric stool of the first kitten Three days later, on the first day that symptoms of infection were present and the stool was found to contain *Endameba histolytica,* the kitten was killed and examined The lesions were small, from 1 to 3 mm in diameter, superficial and restricted to the cecum There was superficial involvement of the mucosa, in the natural creases, as well as at the summits of mucosal folds Below the destroyed surface the mucosa was markedly infiltrated with lymphocytes and pus cells, in the same region vascular congestion was evident, and the lymph spaces were

filled with lymphocytes and pus cells Some portions of the bowel were covered with heavy sheets of exudate containing amebas, erythrocytes, detritus and fibrin-like threads, below which there was patchy destruction of the surface epithelium only (fig 12) In the mucosa involved in the ulcerative or exudative process, production of mucus was absent (fig 12), although it was normal or increased in regions free from amebas (fig 13) Moderate lymphocytic infiltration of the superficial portion of the submucosa immediately below the destructive mucosal lesions was observed

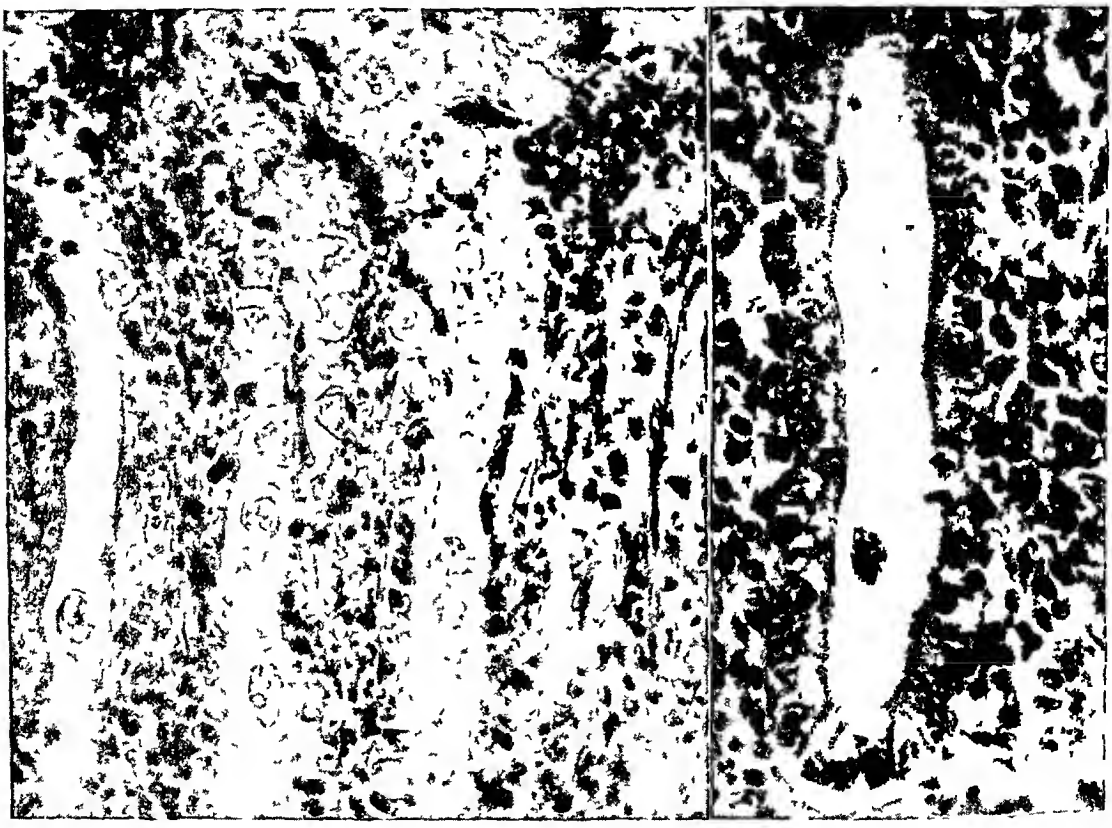

A B

Fig 11 —*A*, a deeper section of the ulcer shown in figure 10, × 350 There is amebic invasion of the mucosa crypts, with destruction of the epithelial cells lining them Several amebas contain erythrocytes *B*, mucosa below the ulcer pictured in *A* and in figure 10, showing two amebas in a normal-appearing mucosal crypt, × 500 A mitotic figure is shown in the epithelium adjacent to one of the amebas

Similar results were presented by kitten 32, killed the day after the appearance of amebas in the stool except that involvement of the rectum, as well as of the cecum, was present and that in the rectal lesions there was a greater degree of lymphocytic infiltration of the involved mucosa than was shown by similar lesions in the cecum

Fig 12—A superficial lesion of the colon of kitten 26, showing a fibrin-like exudate, containing amebas, which cover the mucosa and two areas of superficial destruction The crypts are closed near the surface, the mucosa is infiltrated, and goblet cells are almost entirely absent, × 75



Fig 13—Mucosa of the colon of kitten 26, away from an amebic lesion, showing increased production of mucus, × 75

Kitten 14, previously used experimentally, was operated on under ether anesthesia and motile forms of *Endameba histolytica* from a starch-containing medium were introduced into the cecum by means of a hypodermic needle (see study 2) The rectum of this animal was not occluded, and at the end of four days, when the animal was killed, examination of the stools showed amebas There were small, superficial ulcers, restricted to the cecal half of the colon In the middle portion of the colon was found, on section one wedge-shaped lesion of the mucosa reaching about two thirds of the distance to the muscularis mucosae, but without loss of the necrotic tissue (fig 14 *A*) In the deeper portion of the ulcer were great masses of amebas (fig 14 *B*), a few of which had invaded glandular crypts (fig 14 *A*) The cecal



A B

Fig 14—*A*, colonic ulcer in kitten 14, showing invasion of mucosa by great masses of amebas and marked cellular infiltration of mucosa below the necrotic area, × 100 *B*, the area indicated in *A*, showing morphologic details in the mass of amebas, × 500

lesions were similar to this and all were free from submucosal infiltration

In four kittens lesions developed in layers deeper than the mucosa These animals were older than those used previously, being about half grown On the same day all received rectal injections of the ameba-containing stool of a patient who had active symptoms of dysentery All became infected after an incubation period of from six to nine days, and were killed six to eleven days later, when it seemed that they were not likely to live much longer In all, large, deep, sloughing ulcers of the rectum were found and in three the amebic lesions were restricted to this region In the animals with rectal lesions only, the

colon above the ulcers was packed with formed material that varied from a putty-like to a chalklike hardness But little moisture was present in the portion of the bowel containing the solid content, and the solid content was removed from the wall of the bowel with difficulty The kitten with lesions in the upper portion of the colon had an intestinal content that was small and fluid The deep rectal lesions were similar in all four kittens The wall of the bowel in the region involved was greatly thickened, and section showed that this was due largely to changes involving the submucosa The ulcers were from 2 to 3 cm in diameter, crater-like and denuded of mucosa The greatly thickened necrotic submucosa was in place in part, although the destruc-

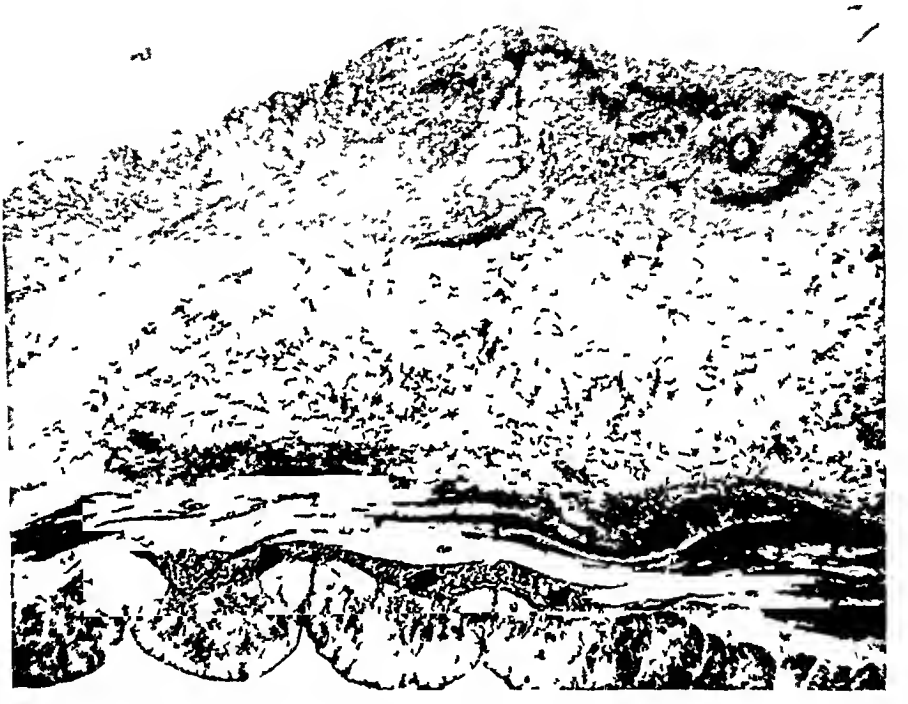

Fig 15—A rectal lesion in kitten 37, showing amebic destruction of the greatly thickened submucosa and undermining of the mucosa, × 25

tive changes reached the circular muscle of the wall of the bowel and extended laterally beneath the mucosa, surrounding the central defect, thus producing at least potentially, the undermined lesion so frequently described as typical of the amebic ulcer of man (fig 15) Surrounding the necrotic submucosa, which was so changed as to show no recognizable elements other than amebas and the occasional shadows of blood vessels, there appeared a rough, fibrin-like border in which were embedded lymphocytes and pus cells, and changed, but distinguishable, tissue cells Extending widely beyond the border of the deep portion of the lesion and deeply into the muscle layers of the bowel were numerous invading cells, many of them polymorphonuclear leukocytes

In this region were dilated lymph spaces and blood vessels filled with erythrocytes and leukocytes In the walls of the blood vessels and surrounding them was a region heavily infiltrated with leukocytes, the greater numbers of which were pus cells The mucosa surrounding the ulcer was the site of patchy surface involvement, mucosal crypts were distorted and destroyed cellular infiltration was present and amebas were found in great masses, the amebas were found in the deeper necrotic zones, centrally placed, rather than at the margins, occasionally within an involved solitary lymph follicle, but not in tissue beyond the region of complete necrosis Amebas were not present in any of the mesenteric lymph nodes draining the rectum or colon

Kitten 8 was anesthetized with ether the abdomen was opened and an injection of *Endameba histolytica* from culture (strain H) was made into the cecum with a needle At the same time, the colon was ligated in the region of the rectum This animal had been used experimentally before, but was free from symptoms at the time of the operative inoculation, and the stool, examined just before, had not contained amebas Two days later the kitten was able to walk around, but was evidently sick It was killed, and necropsy was performed at once Old lesions were not found to suggest that the infection might have arisen from an inoculation other than the last one The abdominal wound had healed without suppuration, the omentum was glued lightly to the posterior portion of the abdominal incision but fluid was not present in the peritoneal cavity The rectal ligature was in place, and the bowel was occluded at this point, and, above this, the whole of the colon was so enormously distended by a content of fluid and gas that it hardly seemed possible that there could have been room for it in the abdominal cavity The distention reached as high as the lower 10 cm of the lower part of the ileum, and manipulation revealed that the ileocecal valve was widely open The lymph nodes along the colon and the lower part of the ileum were large, pale and soft, as if edematous When the bowel was opened it was found filled with a thick, brownish fluid which extended up the ileum for 10 cm and which was teeming with amebas The inner wall of the colon was covered with a thin, mucoid exudate, but ulceration was not visible to the unaided eye The lower part of the ileum presented a similar appearance except that here the exudate was in small patches, whereas one area, about 1 cm in diameter, looked like a minute mucosal hemorrhagic infiltration

Besides the studies of the intestinal tract and of other organs of this animal, serial sections of the dotlike hemorrhagic lesion of the ileum were made and of an area of the middle portion of the colon, with a mesenteric lymph node adjacent to it The ileal lesion proved to be an amebic invasion of a solitary follicle The follicle had been entered by way of its tip, which projected into the ileum of the bowel

(fig 16), although sections taken near the edge of the lesion showed the invaded follicle covered by relatively normal and intact mucosa (fig 17) A single section of this small lesion might have failed to show that the invasion of the deeper tissue was by way of the mucosa and might have led to the belief that the amebas reached the depth of the follicle without injury to the overlying mucosal layer

The nature of the amebic involvement of the solitary follicle was that of widespread necrosis, with destruction of the whole of the interior of the follicle by amebas, which occupied the necrotic abscess-

Fig 16—A central section of a solitary follicle in the lower portion of the ileum of kitten 8, showing the amebic invasion from the mucosal surface, and great central follicular destruction, with amebas present in large numbers, × 75

like detritus in great numbers They did not extend into the unchanged surrounding tissue and were not found outside the follicular limits

In the ileum, beyond the involved follicle, were many small, superficial areas of mucosal destruction In some of these, amebas occupied the depths of crypts relatively normal in appearance The connective tissue of the villi, the interglandular areas and the lymph spaces in the same regions were infiltrated with lymphocytes The dilated lymph spaces of the submucosa and the tissue surrounding them contained leukocytes, which were mostly mononuclear

In the colon from the ileocecal valve to the rectum, were lesions that in their extent and degree of destruction of tissue far outstripped any

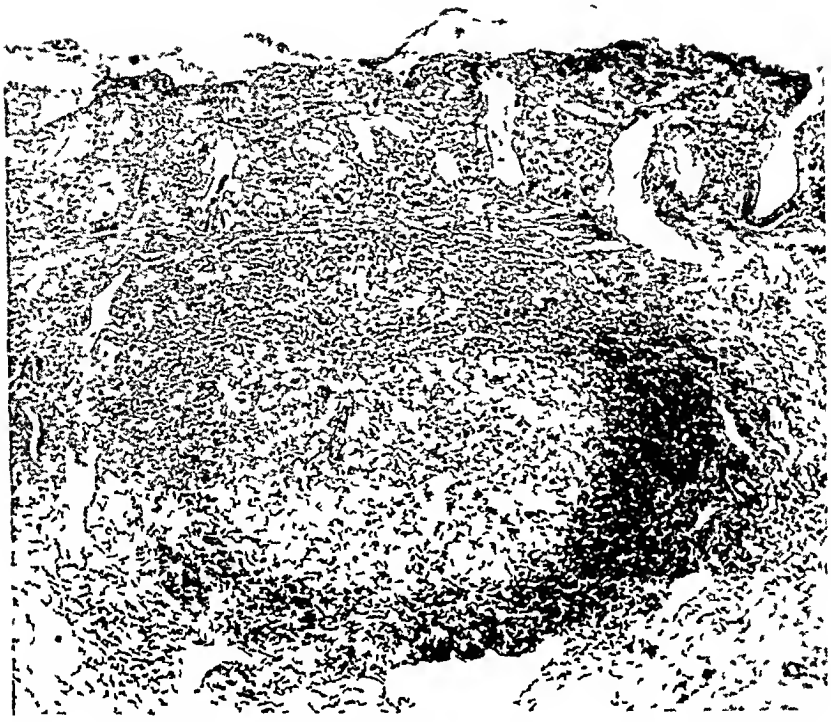

Fig 17—A section near the edge of the follicle shown in figure 16, × 75 The destroyed center of the follicle apparently is covered by relatively intact mucosa



A B

Fig 18—*A*, the colon of kitten 8, showing the severe nature of the destructive process in the presence of intestinal obstruction, × 100 *B*, another portion of the colon, showing marked dilatation, invasion and destruction of mucosal crypts with leukocytic infiltration of the muscularis mucosae and submucosa, × 100

amebic lesions observed in animals in which operative occlusion of the bowel was not present It might well be said that there was no ulceration in the usual sense, since the bowel throughout presented one unbroken expanse of mucosal invasion and destruction (figs 18 *B* and 19) Almost no areas of mucosa remained free from amebic attack, and all showed evidences of irritation Where the mucosa was involved in the amebic process, marked changes in it occurred Great masses of amebas were present in all parts of it, in the superficial necrotic portions and in the deeper, dilated and greatly changed mucosal crypts (fig 18)

Fig 19—A solitary follicle in the colon of kitten 8, showing the amebic invasion of the follicle by way of the mucosal surface, with marked central amebic necrosis, × 100

Where these were recognizable, usually in their deeper parts only, the lining epithelial cells were flat and small, with deeply staining cytoplasm and pyknotic nuclei or they had fallen into the dilated crypt, where they appeared as deeply staining fragments Some dilated crypts were recognizable only by their shape, since they were not lined by epithelium and did not contain it within them (fig 18) The whole thickness of the wall of the bowel was heavily infiltrated with leukocytes, many of which were pus cells They occupied the connective tissue of the

mucosa and extended into the necrotic material on its surface, they were among the fibers of the muscularis mucosae, which at times was hard to identify They were found in large numbers in the submucosa and in the dilated lymph and blood spaces of it In some regions, the cellular invasion involved the muscular coats and was found among the fibers of this coat, while at one point in the rectum an exudate of fibrin and pus cells was found outside the visceral peritoneum

Occasional invasion of a solitary lymph follicle was observed, but this was by no means selective, since the mucosa surrounding each

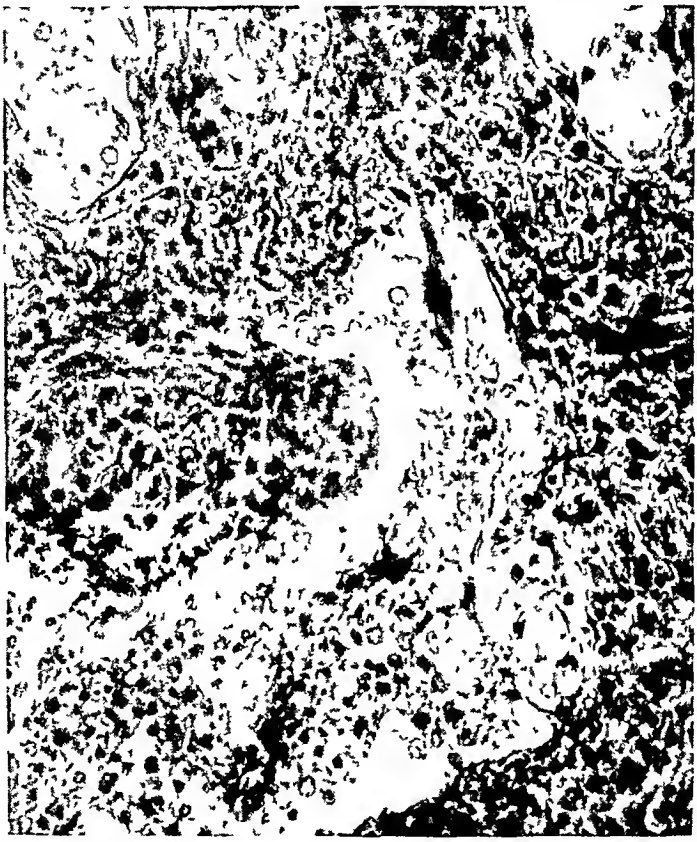

Fig 20—Endameba histolytica entering the submucosa by way of a lymph space in kitten 8, × 350

invaded follicle was involved in marked degree The invaded solitary follicles of the colon presented changes comparable with those of the corresponding ileal structure (fig 19) Here, too, the attack could be traced from the surface to the interior, the destruction was extensive, almost furuncular, with amebas present in great numbers As in the ileum, there was no invasion of the deeper tissue by extension of the follicular process

In several places amebas were found in lymph spaces leading from the mucosa to the submucosa (fig 20) Rarely such a space containing

amebas, could be traced in serial sections from the superficial portion of the mucosa to the deeper submucosa These spaces frequently were filled with leukocytes, as well as with amebas, and often the endothelial lining was injured or destroyed

In the cecal regions of this animal there were found great spaces outside the mucosa and between the muscle bundles of the circular layer of the bowel (fig 21) They were sharply defined, were lined in part by a flattened epithelium (endothelium?), and contained finely granular material resembling that found in some of the smaller lymph spaces of the submucosa Embedded in this granular mass were some leukocytes and pus cells and a few scattered amebas Exact interpreta-

Fig 21—A greatly dilated space (lymph?) in the muscular wall of the cecum of kitten 8, × 75

tion of this unusual observation is lacking, but I believe it represents a great dilatation of the lymph spaces found normally among the bundles of the muscular coat, that the condition is not strictly amebic in origin, but, rather, that it grew out of those changes initiated by ligation of the bowel The same changes were not found in any other animal of my series, and no description of similar lesions has come to my attention

Careful examination of the greatly swollen mesenteric lymph nodes of this animal, in the course of which one node was cut serially and examined throughout, failed to reveal amebas

Kitten 7 was given intracecal injections with cultural *Endameba histolytica*, but the lower part of the bowel was ligated and the animal

was otherwise treated as was kitten 8 It was killed three days after inoculation, and at necropsy the pathologic changes were similar to those of the other kitten, except that they were less severe The colon was not so greatly distended, the ileocecal valve was closed, and the mesenteric lymph nodes were but little, if any, changed When the bowel was opened, lesions were not evident to the unaided eye, although sections from various regions disclosed superficial amebic destruction of the rectal mucosa in patches In the regions of amebic attack, as well as in all portions of the colon remote from ulcerative areas, marked vascular congestion appeared, and there was from severe to moderate infiltration of the mucosa and submucosa, with lymphocytes and polymorphonuclear leukocytes Although less extensive than the lesions presented

Fig 22—Endameba histolytica within the necrotic tissue of an intestinal lesion of a kitten showing ingested erythrocytes, × 1000 One ameba with the nucleus in focus contains eight erythrocytes, some partially digested

in kitten 8 the amebic changes found in this animal varied greatly in nature and extent from those shown in infected kittens without intestinal obstruction

Kitten 6 had received rectal injection of the ameba-containing stool of a patient and four times it had been subjected to injection of *Endameba histolytica* from culture, infection had not resulted (strain H, see study 2) This kitten was anesthetized and intracecal injection of the same cultural strain was made, at which time the rectum also was ligated Four days later, the animal was killed and examined At the time of necropsy a small number of sluggishly motile amebas were found in the fluid content of the colon but neither inspection by the unaided eye nor section and microscopic examination of tissues from various



A B

Fig 23—*A*, colonic mucosa of kitten ill with diarrhea but free from amebiasis, showing increased production of mucus, × 75, stained for mucus Just below the surface are lymph spaces lined by endothelium *B*, colonic mucosa of same kitten, showing great increase in the number of goblet cells and production of mucus, × 75

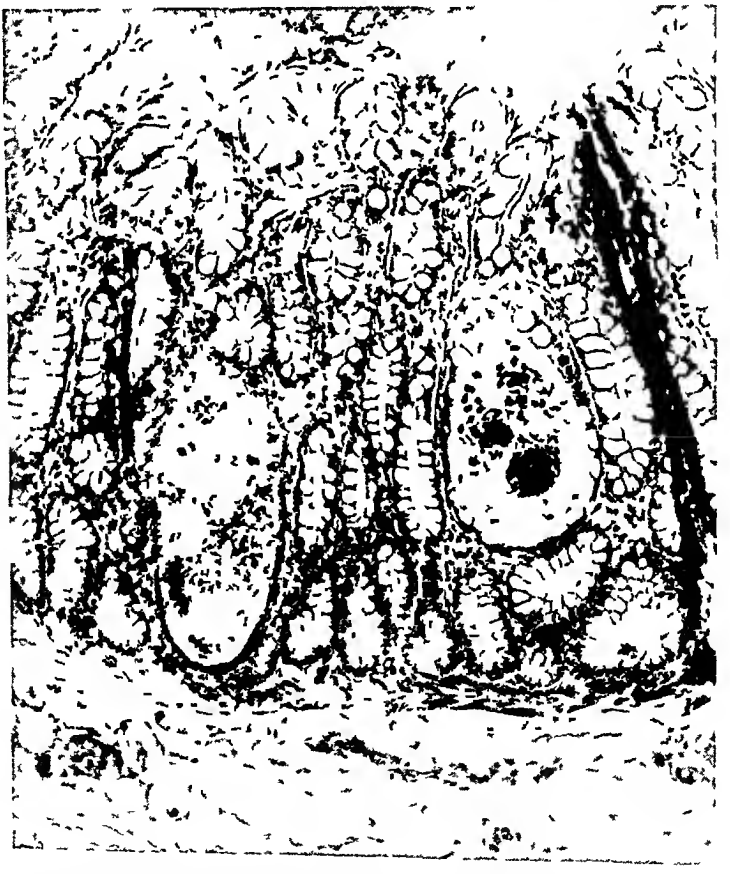

Fig 24—Mucosa of colon of kitten ill with diarrhea, but free from amebiasis, showing mucosal crypts containing secreted material, desquamated epithelium and glandular material, × 100

portions of the bowel revealed amebic lesions A preparation of the stool that was fixed at the time the necropsy was performed and subsequently stained with iron-hematoxylin showed the amebas present to have the morphologic characteristics of *Endameba histolytica* It seems more reasonable to suppose that, in this instance, the occluded bowel acted as a living culture tube and that the organisms introduced were able to live and multiply within it, than to believe that those recovered at necropsy were *Endameba histolytica* simply surviving the inoculation as long as four days

In amebic lesions of the intestines of kittens, the ingestion of erythrocytes by amebas in the deeper portions of the necrotic tissue was commonly observed (figs 11 *A* and 22) No other recognizable tissue elements were seen within them

In some of the animals inoculated with *Endameba histolytica* from the stools of man and other kittens, intestinal infections developed that were accompanied by diarrhea, but amebas were not present in the stools and amebic lesions were not present in the bowel The principal intestinal changes shown by these sick kittens that were free from amebiasis were increased production of mucus (fig 23 *A*), greatly increased numbers of goblet cells (fig 23 *B*) and the development of mucosal crypts (fig 24) These mucus crypts seemed to result from occlusion of mucosal crypts in their superficial portions This produced, below, a dilated space lined with flattened epithelium and filled with a granular material containing shrunken, desquamated epithelial cells and lymphocytes Cellular infiltration was usually slight, rarely diffuse and never deeper than the mucosa No ulcerative intestinal lesions were observed

COMMENT

Amebic Lesions in Man—A review of the medical literature dealing with amebiasis, as it appears in man, leads to the opinion that here is an entity of known etiology presenting distinctive intestinal lesions and, in the main, distinctive complications, both in the tendency to attack certain organs only and in the nature of the pathologic changes produced in them Disregarding slight differences of opinion concerning the site and nature of the destructive intestinal lesion which results from the action of *Endameba histolytica,* it is agreed that the lesions produced are of a peculiar nature, differing essentially from all other intestinal ulcerations that they are produced by the cytolytic action of a secretion of the ameba and are accompanied by slight inflammatory reaction, that the lesions wherever found, present the same destructive changes whether the amebic attack is intestinal hepatic, pulmonary or cerebral, that the solitary follicles of the intestine although occasionally involved in the process, are not predisposed to attack, that the changes here vary in no particular from the amebic process elsewhere, unless

it is to show even more widespread destruction than the adjoining intestinal tissue, that the mesenteric lymph nodes are rarely, if ever, invaded by *Endameba histolytica,* unless it is by direct extension of the intestinal process into a node adherent to the bowel as the result of peritoneal irritation, and finally, that the presence of *Endameba histolytica* in the stools means that intestinal lesions are present even in the absence of symptoms of intestinal infection

Concerning that portion of the bowel first attacked by *Endameba histolytica,* two distinct views have been held one, that the mucosa is first attacked, and one, that the first or principal change is submucosal This latter conception was held by the earlier investigators in the field, and probably represents the impressions gained from the study of more advanced lesions in which the mucosa was widely undermined This might easily lead to the impression that the less extensive mucosal destruction must have arisen secondarily to the more extensive deeper process Single sections through small, undermined ulcers could disclose a destructive submucosal lesion apparently covered by an intact and nearly normal mucosa However, a description of a submucosal process covered by mucosa which was not injured by *Endameba histolytica* has not come to my attention

Among the more recent investigators of amebiasis in man, the belief largely prevails that the intestinal mucosa, rather than the deeper structures, is involved first Whether the attack is on the superficial epithelium or on the deeper portions of the mucosa, by way of the invaded mucosal crypts, is open to controversy The lapse of a few minutes in time may determine the presence of the ameba at the bottom of a mucosal crypt Postmortem destruction of mucosal epithelium is so frequently encountered that it can rarely be interpreted as amebic, even in the presence of the parasite

It is often difficult in a review of articles in the literature to distinguish between descriptions of lesions that are small and presumably recent and attempts to explain the first tissue changes by the appearances presented at the edges of the advanced lesions Slight changes in the tissue bordering a deep ulcer are a part of the advanced process and do not necessarily represent the nature of the primary amebic attack

Amebiasis in the Kitten—Controversy over the point of primary intestinal attack in amebiasis artificially produced in the kitten has been reduced to that over the portion of the mucosa first involved

No one has described destruction of the submucosa, except secondarily to lesions of the mucosa Aside from differences of opinion less vital than those which prevail concerning the exact structures primarily involved in the amebic process, the nature of the intestinal lesion

that results from the action of *Endameba histolytica* in the kitten is believed to be similar to that of man Here too, cytolysis, rather than inflammatory destruction, characterizes the lesion Amebic involvement of the solitary follicles of the colon is incidental only and results, as in man, in an extensive destructive lesion containing amebas in great numbers In amebic abscess of the liver, the only amebic lesion described as complicating intestinal amebiasis in the kitten, the changes produced are similar to, if not identical with those in the hepatic lesions of man Differences presented by amebic lesions in man and the kitten depend, in part on the tendency for amebiasis in the kitten to remain an acute process with death often resulting before involvement of the submucosa occurs, so that the deeper, undermined intestinal ulcer is less frequently seen The distribution of intestinal lesions in the kitten, as well as the evidence produced by intestinal occlusion, indicates that stasis is a factor in the production of amebic infection Slight evidence has been introduced to indicate that *Endameba histolytica* may occupy the intestinal tract of the kitten without producing ulceration

SUMMARY

Intestinal stasis, minute or gross, is an important factor in making it possible for *Endameba histolytica* to initiate its destructive attack Examination of very early amebic lesions in the middle portion of the colon revealed that, outside the usual regions of physiologic intestinal stasis the cecum and the sigmoid, the lesions begin at points of microscopic stasis, i e, the depths of grooves produced by normal mucosal folds

In the kitten, *Endameba histolytica* attacks first the most superficial portion of the intestinal mucosa, and destroys the epithelial cells of this region and the mucosal interstitial tissue with equal facility

In the absence of intestinal obstruction, *Endameba histolytica* does not invade the mucosal glandular crypts until their deeper, expanded portions have become opened by a process of necrosis that has destroyed the superficial half of the mucosa

In the kitten tissue is destroyed by the action of a secretion produced by *Endameba histolytica* Cytolysis at a distance from amebas and out of all proportion to their number is commonly found Among the conspicuous remote effects of the action of *Endameba histolytica* should be mentioned the absence of mucosal goblet cells at the point of actual necrosis of tissue, as well as in the depths of the glands involved in their superficial portions

In the kitten destruction of tissue is not produced by the mechanical action of *Endameba histolytica* Except that the ameba may invade an occasional mucosal crypt that has been opened by destruction of the

more superficial portion, or except that it may be found in a lymphatic space relatively unchanged, the organism occupies only the necrotic zone resulting from the destruction of tissue

Solitary lymph follicles are not predisposed to the attack of *Endameba histolytica* If these follicles are involved, the invasion can be traced into them from the mucosal surface, whereas the lesion produced is an extensive destruction of tissue accompanied by the presence of amebas in large numbers

A deep amebic intestinal lesion was not observed unaccompanied by superficial destruction of the mucosa above it The invariable association of the deep lesions with superficial ulceration was occasionally disclosed only by a study of serial sections

In no case of intestinal amebiasis in the kitten was there invasion of the mesenteric lymph nodes by *Endameba histolytica,* nor did these nodes show cells within them that could easily be confused with *Endameba histolytica*

In kittens infected by the intracecal injection of cultural *Endameba histolytica* accompanied by the occlusion of the bowel by ligature, the intestinal lesions that developed were so different from those presented by kittens free from intestinal obstructions that conclusions concerning the pathologic changes in amebiasis could not be drawn from them

Increase in the number of goblet cells, overproduction of mucus and the development of mucosal crypts are nonspecific reactions and were not found more frequently associated with amebiasis than with diarrhea due to other causes

In the absence of intestinal occlusion, the resistance of the kitten apparently may be so lowered by anesthesia and laparotomy that infection may result from the injection of *Endameba histolytica* grown on starch-containing medium

Although living *Endameba histolytica* was found at the end of four days in the intestinal content of an occluded colon free from amebic lesions, the highly artificial nature of the experiment, as here conducted, does not warrant the conclusion that *Endameba histolytica* might occupy the intestinal tract of the kitten as a harmless commensal

Conclusions cannot be drawn concerning the rôle of bacteria in the production or modification of amebic lesions, intestinal or hepatic, in the kitten

Conclusions concerning culture mediums for the ameba and the results of animal inoculations are given on pages 366 and 385

CAVERNOUS HEMANGIECTASIA OCCURRING WITHIN A NODULAR GOITER *

GEORGE M CURTIS, M D
AND
P A DELANEY, M D
CHICAGO

The usual occurrence of pathologic changes, more commonly of the degenerative type, within the blood vessels of nodular goiters is well recognized Gutknecht [1] observed the formation of hyalin in the vascular walls and even a marked deposition about the capillaries He also noted other changes, particularly calcification, and pointed out that these involve all the vessels, especially the smallest Jores [2] found arteriosclerotic changes within the arterial walls independent of a generalized arteriosclerosis These consisted of intimal thickening and fragmentation of the internal elastic membrane, with the consequent formation of granules and nodules, and calcification Isenschmid [3] added that in regions where goiter is severely endemic, these arteriosclerotic changes may occur in the thyroid gland early in childhood He noted, too, that these same changes in the vessels of the thyroid gland are not uncommon after the first year of life Similar degenerative changes likewise calcification, occur within the fibrosed and hyaline connective tissue of the stroma These changes were most common in the nodular goiters occurring in endemic districts, and were much less frequent in the thyroid glands in regions where goiter is more rarely seen Hesselberg [4] even described arteriosclerotic changes in the superior arteries of the thyroid glands of infants, one a new-born infant She also figured the dilated blood spaces of the so-called "struma vasculosa" of the new-born infant

Endemic cretinism may exist with or without goiter When it exists with goiter, the latter is, as a rule, nodular Wangensteen [5] described the changes occurring in the blood supply of these cretinous nodular goiters as being associated with an apparent effort to eke out a sufficient amount of thyroid gland secretion from what would seem to be a most barren supply

---

* Submitted for publication April 25, 1930

' From the Departments of Surgery and of Pathology of the University of Chicago

1 Gutknecht Virchows Arch f path Anat **99** 419, 1885
2 Jores Beitr z path Anat u z allg Path **21** 211, 1897
3 Isenschmid Frankfurt Ztschr f Path **5** 205, 1910
4 Hesselberg Frankfurt Ztschr f Path **5** 322, 1910
5 Wangensteen Surg Gynec Obst **48** 613, 1929

Vascular changes, particularly the degenerative types, are thus common in nodular goiters (struma nodosa) While these have been well recognized, described and figured, the particular condition that we are presenting at this time is evidently rare So far as we have been able to determine, it has been recognized and reported by four previous observers, all pupils of Langhans Gutknecht, studying a series of sixty goiters removed by Kocher, frequently observed dilatation of the capillaries, particularly those of the goitrous nodules He noted within the nodules, and especially at their peripheries, that the capillaries became greatly dilated, even becoming cavernous spaces Von Sinner [6] studied these dilated vessels more extensively and figured one of the areas, which closely resembled a cavernous hemangioma She also noted the association of the condition with the formation of hematogenous hyalin ("Kautschukhyalin"), as previously described and figured by Wiget [7] Wegelin [8] has briefly described the entity in his excellent monograph and figured one of these unusual areas of cavernous blood vessels (his fig 63) Thus far we have been able to find no other references in the literature Apparently, the condition does not occur in diffuse goiters If it did, it would seem that it should have been recognized before, particularly in view of the large numbers of thyroid glands that are being removed in this country

REPORT OF CASE

History—A housewife, aged 46, entered the University of Chicago Clinics on Nov 5, 1928, complaining of a recent speech disturbance and weakness in her right arm and leg After examination, her condition was regarded by Dr Roy Grinker as due to a transient hemiplegia, probably subsequent to the rupture of a small cerebral vessel The blood pressure was high, 230 systolic and 130 diastolic, and there had been some edema about the ankles There was present a large nodular and cystic goiter, involving particularly the right lobe and isthmus

The patient's mother had a goiter that did not require operation At the age of 23, the patient first noticed an enlargement of the neck during pregnancy and following the birth of her first child This increased in size during the second pregnancy and after the birth of her second child At the age of 26, she had a partial thyroidectomy, in which the left lobe was removed The enlarged right side and isthmus, however, remained and slowly increased in size During the past few years, there was increasing dyspnea on exertion, with an occasional mild stridor, and likewise slight dysphagia, particularly when the patient swallowed rather large or irregular masses of food There was moderate compression of the cervical veins, with some congestion She noticed cardiac irregularity at times and also that the heart was rapid However, she was not aware of the symptoms of thyrotoxicosis as ordinarily recognized

6 Von Sinner Virchows Arch f path Anat **219** 279, 1915

7 Wiget Virchows Arch f path Anat **185** 416, 1906

8 Wegelin, in Henke-Lubarsch Handbuch der speziellen pathologischen Anatomie und Histologie, Berlin, Julius Springer, 1926, vol 8, p 219

Physical Examination—Roentgen films of the chest were made, which demonstrated calcification within the wall of a large cyst and an intrathoracic extension of the goiter on the right The trachea was sharply deviated to the left and compressed by this partially intrathoracic lobe The cardiac area was estimated as 40 per cent oversize There was albuminuria Owing to the recent vascular accident, the patient was not regarded as a good risk, and operation, while considered advisable because of the partial intrathoracic goiter and the pressure symptoms, was postponed for some months The basal metabolic rate was essentially normal, plus 12, and remained about the same, save for an elevation to plus 18 just previous to operation

Operation and Subsequent Course—On March 6, 1929, the right lobe and isthmus were removed under local anesthesia There was a marked fall in blood pressure, from 220 systolic and 110 diastolic to 132 systolic and 82 diastolic during the luxation of the intrathoracic lobe, which arose from the right side of the isthmus and extended into the superior mediastinum 6 cm below the clavicle Convalescence was uncomplicated save for hoarseness, and the patient was dismissed on the sixth day following the thyroidectomy During the luxation of the partially intrathoracic lobe under local anesthesia, huskiness of the voice developed This continued after operation, and laryngoscopy on the day following revealed that the right vocal process was fixed in the cadaveric position Recovery did not ensue, and one year later, in spite of the disappearance of hoarseness, the patient had a paralyzed right vocal cord The trachea, however, had returned to its normal position and was of normal caliber The basal metabolism was plus 3 on Oct 18, 1929, with the pulse rate 80 per minute and the blood pressure 150 systolic and 110 diastolic in the basal state

Pathologic Observations—At the time of operation, one of us (P A D) was making a thorough study of our goiter material In removing large numbers of blocks of tissue for section from the various parts of both excised lobes, and examining them, he discovered the unusual pathologic condition that we report

The goitrous tissue, removed as two separate lobes of approximately the same size, weighed a total of 410 Gm The lobes were similar in gross structure, each containing a spherical, firm-walled, cystic mass about 5 cm in diameter in the superior portion (fig 1) The walls of the cysts were stiff and fibrous, varying from 1 to 6 mm in thickness Each contained calcified granules and plaques Within the cysts was a firm, elastic, almost rubbery substance, ranging in color from yellow to greenish-brown (fig 1, *K*) This was slightly adherent to the walls of the cysts Wiget called this substance "Kautschukcolloid," but stated that it arose from erythrocytes, after hemorrhage Von Sinner's chemical studies showed that it was essentially hematogenous hyalin and not derived from the glandular colloid, hence it has since been called hematogenous hyalin ("Kautschukhyalin") The remainder of the goitrous tissue, constituting its greater part, consisted of numerous large and small, firm, colloid nodules, varying in diameter from 2 mm to 4 cm Within some of these nodules there was evidence of hemorrhage (fig 1, *A*), both old and recent The thyroid gland tissue between the nodules was scanty and largely fibrous

Microscopic sections from different portions of the two excised lobes revealed that the nodules were colloid, with both large and small follicles The internodular thyroid gland tissue showed evidence of hyperplasia, with extensive areas in the colloid or resting stage Groups of thyroid gland alveoli, lined by tall cuboidal to columnar cells, and with scanty or totally deficient colloid content, were in close proximity to extensive groups of larger alveoli with colloid filling their distended lumina Portions of some sections showed close intermingling of

the two types of alveoli It is of interest to note that the colloid of many of the larger alveoli displayed a conspicuous vacuolization at its periphery Fibrosis, edema and hyaline changes were common, and there were numerous hemorrhages into the stroma There was frequent lymphocytic invasion Special fixations and special staining procedures showed contrasting mitochondria-rich and mitochondria-poor alveolar cells

Fig 1—The excised isthmic lobe, hemisected to show the cyst (above) with hematogenous hyalin ("Kautschukhyalin"), *K* The intrathoracic portion, composed of colloid nodules, is below A sectioned nodule, *N*, reveals fresh hemorrhage

Although areas of cavernous hemangiectasia (fig 2) were observed in both lobes, they were far more common in the intrathoracic portion of the isthmic lobe, and it was in this location that the material to be described and figured was found In the posterior portion of the region representing the thyroid capsule, there was considerable increase in the white, fibrous connective tissue of the stroma Within

this were several rows of moderately large, round to oval thyroid alveoli, with a generous colloid content, conspicuously vacuolated The branches of the inferior thyroid arteries in this region showed marked arteriosclerotic changes (fig 3) Inside this glandular tissue, which was changed by pressure atrophy, was a thick

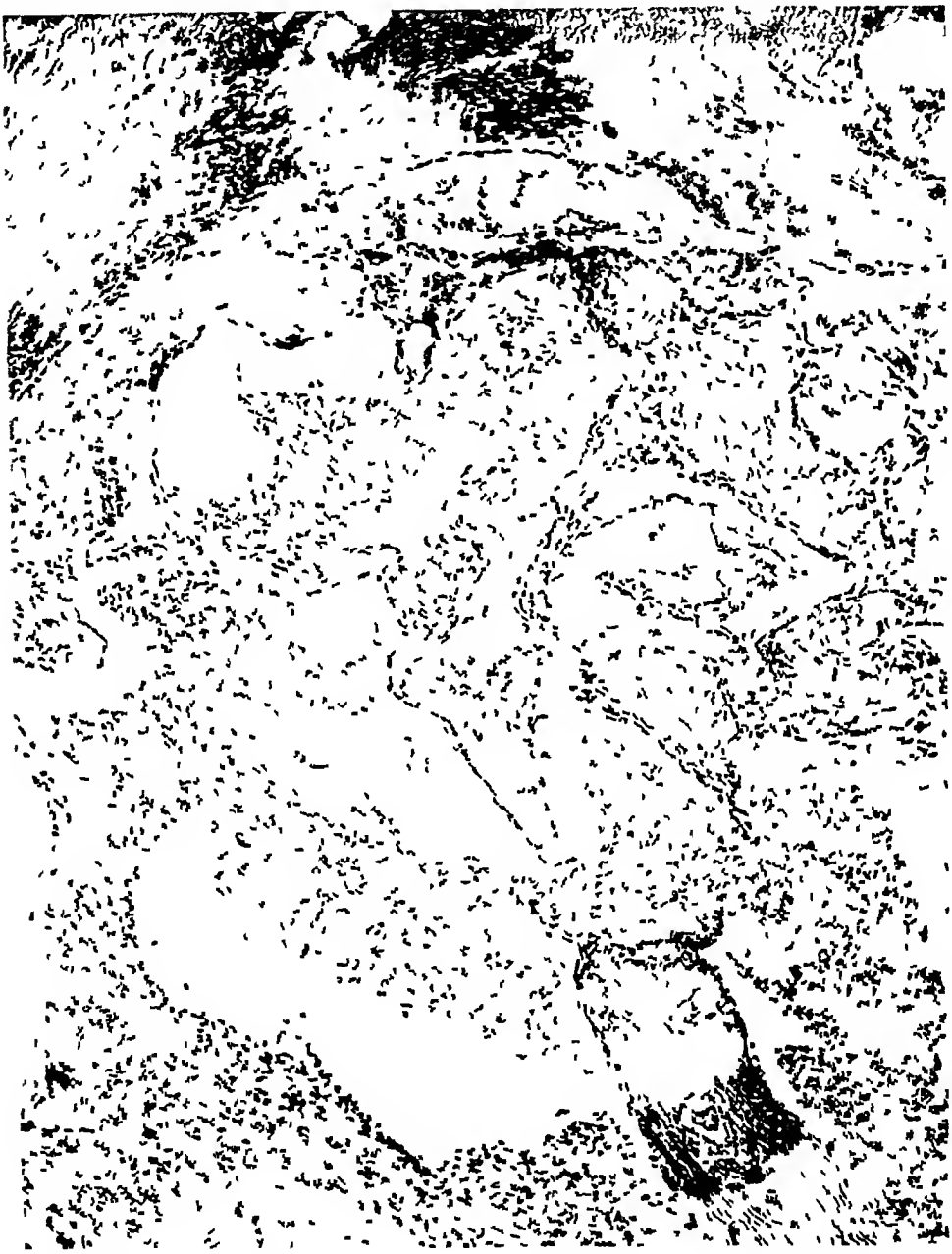

Fig 2—Cavernous dilatation of blood vessels at the margin of a colloid nodule within the intrathoracic portion of a partially intrathoracic nodular goiter

capsular layer of fairly dense, white, fibrous connective tissue in which were many small capillaries and occasional small groups of thyroid gland alveoli The inner margin of this fibrous tissue layer gave rise to large trabeculae that separated extensive areas of hemangiectasia These dilated blood spaces were of widely varying sizes with thin trabecular walls lined by endothelium Many of the larger

spaces were divided into smaller blood-containing compartments by thin strands of fine connective tissue lined by endothelium Some contained distinct capillaries free among the blood cells Recent organized fibrin thrombi were numerous These were usually small in comparison with the capillary spaces and were but partially obstructive The blood in the dilated vascular spaces interestingly displayed erythropoietic tendencies, normoblasts were numerous Cells of the myelocytic series could not be identified, although mature leukocytes were plentiful

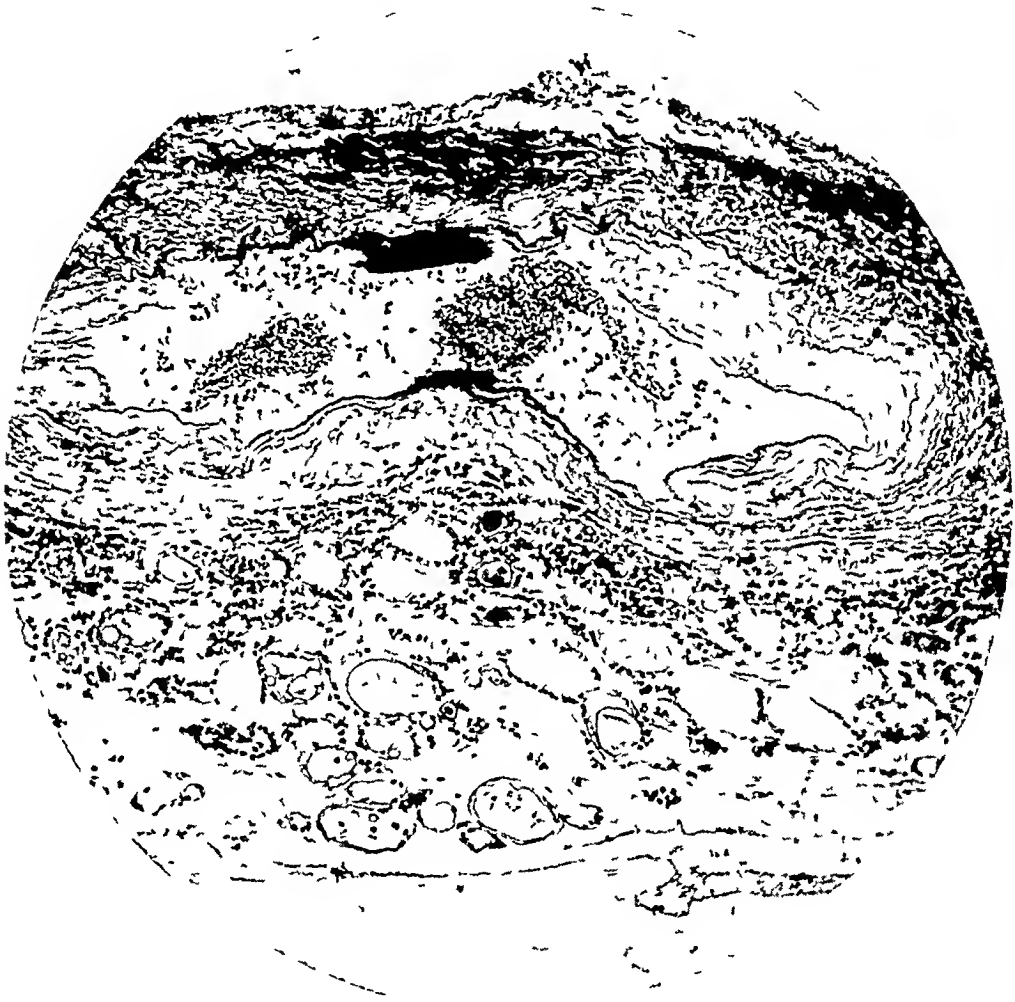

Fig 3—Arteriosclerotic changes within one of the inferior thyroid arteries in the region of the cavernous hemangiectasia

COMMENT

In considering the nature of this pathologic condition, we have primarily the problem of its origin Did the cavernous blood spaces originate by proliferative changes of the blood vessels within the goiter, or were they formed by a dilatation of preexisting vessels, associated with some obstruction to the outflow of blood? In short, was it hemangioma or hemangiectasia? There was but little evidence, either in those cases which have been described or in our case, that

there were associated proliferative changes of the vascular walls On the contrary, the surrounding vessels showed degenerative changes, with obliteration of the lumina and thickening of the walls rather than those neoplastic changes associated with true hemangiomas There were several factors that indicated that the dilatation was subsequent to an obstruction First, the cervical veins were large and distended, as the result of pressure of the intrathoracic portion of the goiter This resulted in venous congestion within the goiter, as noted at the excision The growing nodule and likewise the obliterative vascular changes themselves possibly resulted in an increase of the venous pressure The thyroid gland is the most vascular of the larger organs of the body [9] There was also marked hypertension with the increased vascularity It is thus understandable how obstruction to the venous outflow might have caused capillary dilatation Similar conditions however, occur frequently in goiter, and the condition that we are presenting is apparently rare Possibly it is more frequent than has been recognized In the case of hepatic hemangiectases, Moise [10] suggested the persistence of capillaries that normally undergo regressive changes Both Wiget and von Sinner noted the presence of associated "Kautschukhyalin" degeneration The presence of hematopoiesis within the cavernous blood spaces argues for a slowing of the circulation as blood coursed through them This has frequently been recognized in cavernous hemangiomas [11]

In conclusion, it would appear that the condition is mechanical in its origin and should be regarded as a local hemangiectasia rather than as a neoplastic growth of goitrous blood vessels

9 Tschuewsky Arch f d ges Physiol **97** 280, 1903

10 Moise Bull Johns Hopkins Hosp **31** 369, 1920

11 Schmieden Virchows Arch f path Anat **161** 373, 1900

Laboratory Methods and Technical Notes

A METHOD OF PRODUCING CHRONIC FOCAL INFECTIONS*

V H Moon M D and F W Konzelmann M D Philadelphia

In experiments bearing on the pathogenicity of bacteria the usual methods of animal inoculation are entirely at variance with conditions occurring in the human body The conditions resulting from intravenous or subcutaneous inoculation have little in common with the presence of infected teeth tonsils or other foci of chronic infection in man. Usually animals so inoculated either succumb or recover promptly rarely do they manifest the evidences of chronic focal infection

Several methods have been devised for producing chronic foci of infection in animals Rosenow and Meisser[1] removed the pulp from root canals in teeth implanted bacterial inoculation in the canals at the apexes then closed the canals as in ordinary dental procedures In dogs so inoculated there developed manifestations of disease similar to the clinical phenomena observed in patients Dochez and Sherman[2] in their investigations on scarlatina produced chronic foci by injecting a mass of soft agar subcutaneously and inoculating it with bacteria Rhodes and Apfelbach[3] devised the method of implanting surgically small bits of bone impregnated with bacteria into the spleen or elsewhere in dogs They reported the production of certain phenomena resembling chronic focal infection in human subjects

A new method both simple and effective is the subject of this report Applicators of cotton similar to those commonly used for throat swabs are made on no 20 or 22 rustless wire rather than on wood The cotton is wound rather loosely so that moderate force will slip it off the wire A trocar and cannula are inserted into the region to be inoculated The trocar is then withdrawn leaving the cannula in place The cotton applicator is dipped into the material to be inoculated and is inserted through the cannula The swab is pushed beyond the end of the cannula then on withdrawing the wire the end of the cannula pushes off the cotton into the tissue or cavity desired to be infected The cannula is then withdrawn

* Submitted for publication July 11 1930

* From the Department of Pathology Jefferson Medical College

* This work was made possible by funds from the Martin Research Foundation

1 Rosenow E C and Meisser J G The Production of Urinary Calculi by the Devitalization and Infection of Teeth in Dogs with Streptococci from Cases of Nephrolithiasis Arch Int. Med **31**:808 1923

2 Dochez A R and Sherman L Tr A Am Physicians **39** 136 1924

3 Rhodes G B and Apfelbach C W J Infect Dis **43**:215 1928

The method is merely a simplified procedure for implanting infection in a porous foreign substance within the tissues The foreign substance serves to maintain the infection against effective body resistance The method is well suited for producing chronic foci in subcutaneous and intramuscular areas and in the body cavities By exposing the abdominal viscera the infection may be implanted easily in the spleen, liver, gallbladder or other structures In such instances, a smaller cannula and correspondingly smaller applicators are used In small animals a spinal puncture needle of large size makes a suitable cannula The cotton swab, on fine stiff wire, is wound small enough to pass readily through the lumen of the needle In some experiments a small intravenous inoculation, consisting of the sediment from 1 or 2 cc of a twenty-four hour broth culture, was made at the time of the implantation of the infected cotton plug

Dogs are so resistant to ordinary inoculations that they are seldom used for the purpose Chronic foci are readily produced in them by this method When inoculated with streptococci, masses of inflammatory granulations, from 3 to 5 cm in diameter, develop in a few weeks On examination weeks or months later the organism inoculated is found in large numbers in the mass about the cotton plug Occasionally it is found in the blood and in the substance of other organs *Streptococcus hemolyticus* and *Streptococcus viridans* have been recovered in pure culture regularly after from six to ten months' implantation

Most of the animals under experimentation have received the inoculation intraperitonally Contrary to expectations, such inoculation has no tendency to produce generalized peritonitis, except in rare instances when a viscus has been punctured The peritoneum in animals, as in man, is highly resistant to ordinary methods of infection The cotton plug is promptly surrounded by folds of the omentum and an immediate local inflammatory reaction results in a growing mass of infected granulation tissue Such a mass situated in the peritoneal region is a suitable source for the absorption and dissemination of infection or its products to other parts of the body

The pathologic conditions found in animals inoculated by this method have been varied A report dealing with rheumatic lesions will follow The method is described in the hope that it may be of use to those who are interested in chronic infections

General Review

YELLOW FEVER

A FILTRABLE VIRUS DISEASE*

LEON BUCHBINDER, M A
NEW YORK

With the publication of the conclusive paper of Stokes, Bauer and Hudson[1] in 1928, the era of speculation as to the nature of the etiologic agent in yellow fever, lasting almost half a century, apparently drew to a close From 1880, when Freire[2] reported a staphylococcus, until 1901, when Durham and Myers[3] described a bacillus, at least six other organisms were held to be the cause of the disease Undoubtedly, most of these so-called discoveries were greatly influenced by the pure culture method of isolating bacteria described by Koch in 1882 As the disease had been proved to be infectious, and since several diseases by that time had been ascribed to filtrable agents, it does not now seem strange that Reed, Carroll and Agramonte[4] after the failure of their predecessors to name a correct bacterial agent, should have attempted to filter the causative virus However, their results, too well known to be described in detail here, seemingly closed the field to further endeavor Nevertheless, in 1919, Noguchi[5] described his *Leptospira icteroides* (*interrogans*) as the causative agent His work was accepted, and the organism was named in the textbooks as the cause of yellow fever, but this theory soon met with opposition and now appears to be permanently abandoned since the report of Stokes and his collaborators, which confirmed once more the original work of the American Commission in 1900

EPIDEMIOLOGY

It is well known that yellow fever is a disease existing in endemic, epidemic and sporadic form The work of Marchoux and Simond,[6]

* Submitted for publication, July 26, 1930

* From the Department of Bacteriology, College of Physicians and Surgeons, Columbia University

1 Stokes, A , Bauer, J H, and Hudson, N P Am J Trop Med **8** 103, 1928

2 Freire, D, cited by Agramonte A Ann Int Med **2** 138, 1928

3 Durham H E, and Myers, W Brit M J **1** 450, 1901

4 Yellow Fever, a Compilation of Various Publications, Document 822, Sixty-First Congress Third Session 1912

5 Noguchi H J Exper Med **29** 565, 1919

6 Marchoux, E, and Simond, P L Ann de l'Inst Pasteur **20** 104, 1906

published in 1906 which has been amply confirmed, showed that the disease was endemic in those countries where adult *Aedes aegypti* could live the whole year through, that it was epidemic in those countries where the mosquitos could survive part of the year, and that it was sporadic in those places where a focus of infection was set up by immigrants infected aboard ship or in some foreign country They also demonstrated that the virus was propagated in endemic areas by benign cases in children, and in epidemic areas by infected mosquitos accidentally admitted to the country The same authors stated that no race appeared to possess natural immunity, nor did any age group, and that the disease was benign in children and severe in adults Hanson,[7] in a statistical report on an epidemic in 1921, found the lowest death rate between the ages of 5 and 15, however, the highest rate was in children between the ages of 1 and 3, and the incidence of infection seemed to be slightly higher in males than in females

INSECT VECTORS

One of the principal observations made by Stokes, Bauer and Hudson,[1] and since confirmed by Mathis, Sellards and Laigret,[8] Aragao[9] and Hindle,[10] was that yellow fever is transmissible from man to monkey and from monkey to monkey by the bite of *A aegypti* *A aegypti* is the mosquito which was found able to transmit the experimental disease from man to man by both the American and French Commissions and has accordingly been accepted as the insect vector of the disease An excellent review on the historical aspects of the relation of insect vectors to yellow fever has been recently written by Agramonte[2] With the rebirth of investigation in 1927 it is not surprising that new possible vectors were found Accordingly, Bauer[11] in 1928 named three new species that he found capable of transmitting the infection from rhesus to rhesus They were *A luteocephalus*, *A stokesi* and *Eretmopodites chrysogaster* The experimental infection was caused by biting in each case, and also by injection of a macerated suspension of the last named insect Since then eleven new species able to transmit the infection have been described *A vittatus*, *A africanus* and *A simpsoni* transferred the infection, both by biting and by injection according to Philip[12] *A scapularis*, *A serratus* and

7 Hanson, H Am J Trop Med **9** 233, 1929

8 Mathis, C, Sellards, A W, and Laigret, J Compt rend Acad d sc **186** 604 1928

9 Aragao, H de B Mem do Inst Oswaldo Cruz, 1928, no 2 (supp), p 35

10 Hindle, E Brit M J **1** 976 1928

11 Bauer, J H Am J Trop Med **8** 261, 1928

12 Philip C B Am J Trop Med **9** 267, 1929

A taeniorhynchus, reported by Davis and Shannon,[13] have been infectious by injection in all instances and also in the case of the first by biting *A mitans, A nigricephalus, A punctocostalis, Culex thalassius* and *Taeniorhynchus africanus* have been able by injection, in all cases, to transmit the infection, as recently announced by Philip[14] The last named could also infect by its bite

On the other hand, the following mosquitos have not been able to produce the disease either by biting or by injection *A apecoargentus, A longipalpis, A welmani* and *C nebulosus*, according to Bauer,[11] *A hastatus*, as reported by Davis and Shannon,[13] and *Anopheles gambiae*, according to Philip[14b] Davis and Shannon[13] also announced doubtful results with *C quinquefasciatus* It is interesting to recall that in 1906 Marchoux and Simond[6] obtained negative results in man with *A taeniorhynchus* and also with *A scapularis, Psorophora ciliata, P ciliata* and *P posticata* The significance of the successful work reported by the investigators named in the preceding paragraph is made clear by the recent observation of Hudson and Philip,[15] who showed that rhesus monkeys experimentally infected could transmit the disease to mosquitos two days before the onset of symptoms By analogy it may be that human beings, before they themselves have become sick, can and have transmitted the infection to some of these tree-breeding mosquitos hitherto not considered as actual insect vectors

It is generally assumed that the female mosquito is the intermediate host, and so most, if not all, of the experimentalists have used that sex for their work However Aragao[16] recently made two interesting and perhaps significant contributions, namely, that the males of *A aegypti* are capable of transferring the experimental disease and that if infected females are kept with uninfected males, the latter acquire the ability to infect monkeys On the other hand, if infected males are harbored in the same container as uninfected females the latter too become infected The significance of the last observation is evident the disease can be transmitted from insect to insect without the necessity of the intervention of a human host, as has hitherto been believed necessary Theoretically, then, it is possible for the virus of yellow fever to be present in a given vicinity without any clinical or subclinical cases existing The possibility of an outbreak of yellow fever in India is a conclusion that might be drawn from the recent work of Dinger,

13 Davis, N C, and Shannon, R C J Exper Med **50** 803, 1929

14 Philip, C B (*a*) Am J Trop Med **10** 1, 1930 (*b*) Science **71** 614, 1930

15 Hudson, N P and Philip, C B J Exper Med **50** 583, 1929

16 Aragao, H de B Mem do Inst Oswaldo Cruz, 1929, no 9 (supp), p 193

Schuffner, Snidjers and Swellengrebel,[17] who have found that an Indian species of *A aegypti* is capable of transmitting the disease to monkeys of the species *Macacus rhesus* As the species is indigenous to that country, the stage is set for a possible epidemic More recently Pettit Roubaud and Stefanopoulo,[18] working with species of the same insect from Java, Tunis and Cuba, reported similar success, and previously Hindle,[19] working with an Indian strain, was able to do the same but in neither investigation were the positive results regularly obtained

It has been known since the beginning of the century[20] that mosquitos cannot infect human beings by biting until the twelfth day after an infectious meal This observation has been corroborated by Stokes Bauer and Hudson,[1] and by Bauer and Hudson,[21] who found, in their experimental work on monkeys, that the extrinsic period was from eight to sixteen days or slightly longer No developmental cycle of the virus, with a possible noninfectious stage in the mosquito has been mentioned in the literature Moreover, it has been shown by Bauer and Hudson,[21] Aragao,[9] Aragao and da Costa Lima[22] and Davis and Shannon[23] that macerated mosquitos, during the entire so-called extrinsic incubation period and different body parts such as the head thorax and abdomen and even the dejecta for part of the incubation period, are infectious for monkeys by injection However, the question as to why the saliva is noninfectious for at least eight days has not been answered Perhaps, according to some preliminary work by Aragao and da Costa Lima, the answer lies in the fact that this secretion is actually infectious at an earlier time than has been believed In a previous report[20b] they had shown that a watery suspension of the feces of an infected insect placed in the conjunctival sac or on the unabraded skin in the inguinal region can sometimes produce yellow fever in the rhesus Accordingly, in an experiment to determine the minimum incubation period in mosquitos,[24] in which the possible error of fecal contamination was obviated they were able to show that this period

17 Dinger J E Schuffner W A P, Snidjers E P, and Swellengrebel, N H, cited by Pettit, Roubaud and Stefanopoulo, footnote 18

18 Pettit, A Roubaud, E, and Stefanopoulo, G Compt rend Soc de biol **104** 60 1930

19 Hindle, E Tr Roy Soc Trop Med & Hyg **22** 405 1929

20 Footnote 4 Marchoux, E Salimbeni, A, and Simond, P L Ann de l'Inst Pasteur **17** 665, 1903

21 Bauer, J H, and Hudson, N P J Exper Med **48** 147, 1928

22 Aragao, H de B, and da Costa Lima, A Mem do Inst Oswaldo Cruz, 1929, (*a*) no 8 (supp) p 105 (*b*) no 9 (supp) p 136, (*c*) no 9 (supp), p 142, and (*d*) no 10 (supp) p 253

23 Davis, N C and Shannon R C Am J Hyg **11** 335, 1930

24 Aragao, H de B, and da Costa Lima A Mem do Inst Oswaldo Cruz **23** 102 1930

could be as low as four days However, they have not, in one attempt, repeated their result and final decision must be held in abeyance

A question which has arisen in the minds of present investigators is How long does a mosquito remain infectious after a blood virus meal? The answer appears to be that infectivity is lifelong, as demonstrated by Stokes, Bauer and Hudson,[1] Hindle,[19] Aragao and da Costa Lima [22] and Davis and Shannon,[23] the whole insect or various parts thereof, such as the head, thorax, salivary gland, hemocelic fluid, abdomen, ovaries, midgut and hindgut, are infectious for the periods of time studied The maximum survival time of the virus reported for any single experiment was 113 days, reported by the first named authors Incidentally, no statement has been found in the published works that the virus is harmful for the mosquito and so brings about its demise A second question asked is Do adults transmit the infection to their progeny? The answer is in the negative Marchoux and Simond [6] reported successful transfer of infection from the adult mosquito to the first generation However, Rosenau and Goldberger [25] and more recently Stokes, Bauer and Hudson,[1] Philip [26] and Davis and Shannon [23] obtained negative results

YELLOW FEVER CONTROL

In 1911, Boyce [27] said that if in areas in which yellow fever was present piped water supplies were installed the disease would soon disappear This statement is still held to be true, as evidenced by the methods of control employed At the beginning of the century, such methods as the destruction of larvae in endemic areas, the screening of domiciles, the destruction of mosquitos in the homes of the sick, the prevention of breeding by mosquitos on shipboard and the quarantine of immigrants from endemic and epidemic areas were resorted to [20] In the last decade, emphasis has shifted to other measures In areas of endemic and epidemic disease, according to Connor [28] and Hanson,[29] the primary steps taken are the hermetic sealing of water receptacles wherever possible and the placing of bottom-feeding fishes in cisterns, wells and water barrels and top-feeding fishes in fountains In addition, in epidemic areas, as reported by Carter [30] and Dunn and Hanson,[31] the mosquito-breeding areas are destroyed in ports, centers of travel and large towns

25 Rosenau M J, and Goldberger, J Bull Yellow Fever Inst, 1906, no 15
26 Philip, C B J Exper Med **50** 703, 1929
27 Boyce, R W Yellow Fever and Its Prevention, New York, E P Dutton & Company, 1911
28 Connor, M E Am J Trop Med **2** 487, 1922, **3** 105, 1923
29 Hanson, H Am J Trop Med **5** 393, 1925
30 Carter, H R Am J Trop Med **2** 87, 1922
31 Dunn L H, and Hanson, H Am J Trop Med **5** 401, 1925

THE NATURAL INFECTION IN MAN

The clinical manifestations of yellow fever have been too well described in the past to need repetition here[32] However, in the last few years some new diagnostic aids have been reported Davis and Burke[33] stated that doubtful cases can be diagnosed by injecting into a monkey blood taken during the early febrile period and then observing the result of the inoculation Aragao[9] also mentioned a method of postdiagnosing doubtful cases If some convalescent serum is injected into a monkey and followed in twenty-four hours by a certainly fatal dose of virus, the animal should survive if the disease is yellow fever

In the past few years, clinical studies of the urine were reported by Penido,[34] of the cerebrospinal fluid, by Lacorte and Villela,[35] of the coagulability of the plasma, by Vellard and Vianna,[36] of the serum alexin, by da Costa Cruz,[37] and of the heart, by Chagas and de Freitas[38]

Instances of cerebral complications were pointed out by Hanson[39] and more recently by Theiler[40] Similar symptoms have appeared in numerous filtrable virus diseases,[41] but the cause of this manifestation is a matter of dispute

In 1890, Councilman[42] described the morbid anatomy of the liver and kidney Since then the pathologic changes have also been well described by Otto and Neumann,[32] da Rocha Lima,[43] Elliott[32] and others More recently Hoffmann,[44] Klotz and Simpson,[45] Hudson[46] and

32 Footnote 4 Boyce (footnote 27) Otto, M, and Neumann, R O Ztschr f Hyg u Infektionskrankh **51** 357, 1905 Thomas, A W Ann Trop Med **4** 119, 1910 Seidelin, H Bull Yellow Fever Inst, 1911, no 1, p 55 Elliott, C A Arch Int Med **25** 174, 1920

33 Davis, N C, and Burke, A W J Exper Med **49** 975, 1929

34 Penido, J C N Mem do Inst Oswaldo Cruz, 1928, no 2 (supp), p 69

35 Lacorte, J G, and Villela, G G Mem do Inst Oswaldo Cruz, 1928, no 2 (supp), p 63

36 Vellard, J, and Vianna, M Mem do Inst Oswaldo Cruz, 1929, no 7 (supp), p 86, Compt rend Soc de biol **101** 952, 1929

37 Da Costa Cruz, J Compt rend Soc de biol **101** 948, 1929, Mem do Inst Oswaldo Cruz **23** 131, 1930

38 Chagas, E, and de Freitas, L Mem do Inst Oswaldo Cruz, 1929, no 7 (supp), p 79

39 Hanson, H Am J Trop Med **6** 261, 1926

40 Theiler, M Science **71** 367, 1930

41 McIntosh, J Brit M J **2** 334, 1928

42 Councilman, W T Pub Health Bull, 1890, no 2, p 151

43 Da Rocha Lima, H Verhandl d deutsch path Gesellsch **15** 163, 1912

44 Hoffmann, W H J Trop Med **27** 235, 1924

45 Klotz, O, and Simpson, W Am J Trop Med **7** 271, 1927, Am J Path **3** 483, 1927

46 Hudson, N P Am J Path **4** 419, 1928

Cannell[47] redescribed the changes in various organs Intranuclear inclusions described a short time since will be considered in the discussion of the experimental disease

THE EXPERIMENTAL DISEASE IN ANIMALS

Stokes, Bauer and Hudson,[1] in 1928, first reported the successful transmission of yellow fever from man to *Macacus rhesus* Their work has been amply verified by Aragao,[9] da Cunha and Muniz,[48] Mathis, Sellards and Laigret,[8] Sellards and Hindle,[49] Pettit, Stefanopoulo and Aguessy[50] and Kuczynski and Hohenadel,[51] and the rhesus has become the animal of choice in yellow fever research An interesting fact in this connection is that most, if not all, of the successful transfers of the infection from man to monkeys have been with the blood from relatively benign cases, whereas attempts to transmit the disease with material from severe cases have generally resulted in failure[52]

Other monkeys have been found susceptible to yellow fever by several routes of infection with various infectious materials A tabulation of monkeys that have been found to be sensitive is as follows *Macacus sinicus,* by Stokes, Bauer and Hudson,[1] whose results were confirmed by Pettit, Stefanopoulo and Kolochine,[53] *M cynomolgus* and *M speciosus,* by Aragao,[9] the susceptibility of the first named being confirmed by da Cunha and Muniz[48] and by Pettit and Stefanopoulo,[54] *Cebus macrocephalus,* by Davis and Shannon,[55] *Ateles ater, Saimiri sciurea* and possibly *Lagothrix lagotrica,* by Davis,[56] and *M inuus,* by Pettit and Stefanopoulo[57] In 1907, Thomas[58] obtained apparently positive results with the chimpanzee, but Stokes, Bauer and Hudson,[1] working with the same animal, had doubtful success Mosquitos and monkey tissues containing the virus have been employed to infect

47 Cannell, D E Am J Path **4** 431, 1928

48 Da Cunha, A M, and Muniz, J Mem do Inst Oswaldo Cruz, 1928, no 2 (supp), p 51

49 Sellards, A W, and Hindle, E Brit M J **1** 713, 1928

50 Pettit, A, Stefanopoulo, G, and Aguessy, C Compt rend Soc de biol **99** 258, 1928

51 Kuczynski, M H, and Hohenadel, B Klin Wchnschr **8** 9 and 58, 1929, Lancet **1** 180, 1930

52 Stokes, Bauer and Hudson (footnote 1) Mathis, Sellards and Laigret (footnote 8) Aragao (footnote 9)

53 Pettit, A, Stefanopoulo, G, and Kolochine, C Bull Acad de med, Paris **102** 98, 1929

54 Pettit, A, and Stefanopoulo, G Compt rend Soc de biol **102** 561, 1929

55 Davis, N C, and Shannon, R C J Exper Med **50** 81, 1929 Davis, N C Am J Hyg **11** 321, 1930

56 Davis, N C J Exper Med **50** 703, 1930

57 Pettit, A, and Stefanopoulo, G Compt rend Soc de biol **104** 63, 1930

58 Thomas, A W Brit M J **1** 138, 1907

monkeys Infected insects were allowed to bite the monkeys or their macerated and emulsified bodies were injected into the animals [59] The subcutaneous intraperitoneal, intrahepatic and percutaneous routes have been used for infection with monkey blood or serum taken during the first days of fever, when virus is found in those tissues, or with organs such as the liver, kidney, spleen and brain of animals dead of yellow fever [60] That very small amounts of virus can produce infection has been definitely established [61] The bite of a single mosquito or the injection of 1 cc of a 1 1 000 000 saline suspension of macerated mosquito or monkey blood virus has proven fatal

In contrast with the relative ease with which monkeys can be infected by organs of animals dead of the disease, it has not as yet been found possible to infect these animals with organs of human beings dead of yellow fever,[62] all successful transfers from man to monkey having been obtained by means of blood virus No explanation for this phenomenon has been advanced

The disease in monkeys is similar to that in man, and the incubation period is generally from one to fifteen days, although it is sometimes slightly longer [63] The terminal stage of fatal cases is marked by extreme prostration and subnormal temperature, most animals dying in from four to ten days [1] Some authors have considered 104 F as a significant temperature, although it has been shown that animals often have died of yellow fever without ever having a febrile reaction [64] Recently Pettit and Stefanopoulo [65] corroborated this observation

The pathology is similar to that of man,[66] and as in the human disease, nuclear inclusion bodies are found

---

59 Stokes, Bauer and Hudson (footnote 1) Mathis, Sellards and Laigret (footnote 8) Aragao (footnote 9) Da Cunha and Muniz (footnote 48) Sellards and Hindle (footnote 49)

60 Stokes, Bauer and Hudson (footnote 1) Aragao (footnote 9) Hindle (footnote 19) Da Cunha and Muniz (footnote 48) Pettit, Stefanopoulo and Aguessy (footnote 50) Davis and Shannon (footnote 55) Davis (footnote 55) Bauer, J H, and Hudson, N P Am J Trop Med **8** 371, 1928 Cowdry, E F, and Kitchen, S F Science **69** 252, 1929, Am J Hyg **11** 227, 1930 Theiler, M, and Sellards A W Ann Trop Med **22** 449, 1928

61 Bauer (footnote 11) Philip (footnote 12) Aragao and da Costa Lima (footnote 24) Lewis, P A J Exper Med **52** 113, 1930

62 Aragao (footnote 9) Pettit, Stefanopoulo and Kolochine (footnote 53)

63 Stokes, Bauer and Hudson (footnote 1) Aragao (footnote 9) Hindle (footnote 19) Davis, N C, and Shannon R C J Exper Med **50** 793, 1929

64 Stokes Bauer and Hudson (footnote 1) Da Cunha and Muniz (footnote 48) Theiler and Sellards (footnote 60)

65 Pettit, A, and Stefanopoulo, G Compt rend Soc de biol **102** 719, 1930

66 Stokes, Bauer and Hudson (footnote 1) Hudson (footnote 46), Am J Path **4** 395 and 407, 1928

A number of primates and lower animals have been found to be refractory to yellow fever Rabbits, white mice, white rats, puppies, kittens, goats and several species of African monkeys are insusceptible, according to Stokes, Bauer and Hudson[1] *Pseudocebus azarae,* as reported by Aragao,[9] and *Papio sphinx, Cercopithecus callitrichus, Cynocephalus hamadryas* and *Cercopithecus griseovridis,* as stated by Pettit and Stefanopoulo,[67] resist infection

However, Theiler[40] a short time since reported successful transfer of the virus to white mice He claimed that by the intracerebral, intra-spinal and intra-ocular routes, he had passed the virus through this species at least forty-two times and had secured a fixed virus He was not as successful, however, with the intraperitoneal and subcutaneous routes At death, virus was recovered from the brain, spinal cord, peripheral nerves and adrenal glands There were few macroscopic changes in the dead mice, except for hemorrhage into the stomach, which occurred in about 50 per cent of the cases The significance of this adaptation of the virus to the brain is not as yet clear, although it is a well known fact that some filtrable viruses can be readily adapted to that organ Herpes simplex, vaccinia, rabies and, as shown more recently, psittacosis[68] are capable of producing death in some primates or lower animals following intracerebral inoculation

Kuczynski and Hohenadel[51] recently reported successful transfer of the infection to guinea-pigs, although da Cunha and Muniz[18] and Mathis, Cazanove and Bacque,[69] among others previously reported negative results with the same animal

INTRANUCLEAR INCLUSIONS

Torres[70] in 1928, first described inclusion bodies in the nuclei of the liver cells of diseased monkeys However, Stokes, Bauer and Hudson,[1] in referring to the pathology of *rhesus* liver cells, said that "in some specimens the nuclei of altered cells contained small acidophilic granules," and in 1890 Councilman[42] in a pathologic description of the liver apparently also saw these bodies Torres' work on the *rhesus* was verified by Cowdry and Kitchen[60] and by Penna and de Figuerrido[71] The former found nuclear inclusions in the adrenal glands and showed

67 Pettit and Stefanopoulo (footnote 54) Pettit, A , Stefanopoulo, G , and Kolochine, C Compt rend Soc de biol **99** 260, 1928

68 Rivers, T M , and Berry, G P Proc Soc Exper Biol & Med **27** 802, 1930

69 Mathis, C , Cazanove, F , and Bacque, M Bull Soc path exot **20** 1025, 1927

70 Torres, C M Mem do Inst Oswaldo Cruz, 1928 (supp) no 2, p 55, Compt rend Soc de biol **99** 1344, 1655, 1660, 1669 and 1671, 1928, **101** 951, 1929, **102** 410 and 414 1929

71 Penna, O , and de Figuerrido, B Compt rend Soc de biol **103** 1346, 1930

also that the inclusions exist in human liver cells The latter observation was confirmed by Torres [70] and by Hoffmann [72] Recently Theiler,[40] in his work on the mouse, said that in the brain "the ganglion cells undergo necrosis and there are invariably present eosinophilic nuclear changes resembling those present in the liver of man and monkey dead of yellow fever and described as inclusions by Torres and Cowdry"

The inclusions are diagnostic for the experimental disease in monkeys, being almost constantly present, although Cowdry and Kitchen [60] found them in only ten of thirty-seven specimens of human liver Torres [70] also reported the inclusions as being rare in the human disease

In the experimental infection, the acidophil changes are found in animals killed on the first day of the febrile reaction and continue to increase until the period of hypothermy is reached In recovered animals, no trace of the inclusions are found, and the organs usually have a normal appearance,[73] a fact that may explain why recovery from the disease usually has no sequelae Torres [70] reported that his inclusions corresponded to those described for herpes zoster, symptomatic herpes, varicella and virus III, and Cowdry and Kitchen [60] stated that their inclusions were of the same general type as those of herpes, chickenpox, submaxillary disease and virus III, but different in detail Intranuclear inclusions were not found in mosquitos (Cowdry and Kitchen [60]), which might be an explanation for the fact that the virus has no effect on the insect

IMMUNITY

Active Immunity—It has been known for a long time that human beings who have recovered from benign or severe attacks of yellow fever seldom suffer recurrences, and that immunity lasts a long time, if not for life [74] Experimental confirmation of this fact was presented recently in the work of Bauer and Hudson and their collaborators [75] and that of Sawyer Kitchen Frobisher and Lloyd [76] The technic of this work is as follows A small quantity of serum from a human being who has recovered from the disease is injected into a *rhesus* monkey a short time before the animal is infected with a fatal dose of virus If the monkey survives the injection of the virus or has only a very mild

72 Hoffmann, W H Arch f Schiffs- u Tropen-Hyg **33** 411, 1929

73 Cowdry and Kitchen (footnote 60) Torres (footnote 70)

74 Marchoux and Simond (footnote 6) Carter, H R Ann Trop Med **10** 153, 1916

75 Hudson N P, Bauer, J H, and Philip, C B Am J Trop Med **9** 1, 1929 Hudson, N P Philip, C B, and Davis, G E Am J Trop Med **9** 223, 1929 Bauer, J H, and Hudson, N P J Prev Med **4** 177, 1930

76 Sawyer, W A Kitchen, S F, Frobisher, M, Jr, and Lloyd, W J Exper Med **51** 493, 1930

illness, the serum is regarded as having protective properties By the use of this method it has been shown that serums taken from human beings as late as twenty-three or even twenty-six years after recovery from the disease can protect monkeys [77]

It is not surprising in view of these facts that monkeys which have recovered from the experimental disease are immune to further infection This has been shown by Davis,[78] Hindle,[19] Sawyer and his collaborators [76] and others

The French Commission (Marchoux, Salimbeni and Simond [20]) in 1903 showed that human virus-containing serum heated at 55 C for five minutes and virus-containing blood kept under a petrolatum seal for eight days protected human beings against the disease Recently Frobisher [79] showed that monkey virus-containing serum heated at 60 C for twenty minutes and injected in large quantities protected animals of the same species, although no passive protective properties were demonstrated in the serums of these monkeys Using the same animals, Hindle [19] and Pettit, Stefanopoulo and Kolochine [53] corroborated the observation on the protective properties of virus attenuated by storage Hindle also protected monkeys by the injection of diluted virus and prepared vaccines of formaldehydized or phenol-glycerinated livers and spleens of monkeys dead of the disease, which protected the animals when they were tested for immunity as late as six months after vaccination Aragao [9] used this vaccine in Brazil on 300 people with no untoward results, and Hindle himself stated that he intended to submit his vaccine to a practical field test

Passive Immunity—It has been shown that serum of artificially immunized animals, as well as that of recovered human beings, as mentioned, exhibits protective properties In 1928, Pettit, Stefanopoulo and Frasey [80] prepared antiserums by the injection of monkey virus-containing livers into such naturally refractory animals as the horse and monkeys of the genus *Cynocephalus* and of the genus *Cercopithecus* If some of this serum was mixed with a fatal dose of virus and thirty minutes later injected into susceptible monkeys, or if the virus and serum were injected separately, the monkeys were protected Later the same authors prevented the death of monkeys by the use of the serums as late as five days after the experimental infection

Antibodies—That neutralizing antibodies are present in immunized animals was pointed out in the work mentioned in the preceding para-

77 Bauer and Hudson (footnote 75) Sawyer, Kitchen, Frobisher Lloyd (footnote 76)

78 Davis, N C J Exper Med **49** 985, 1929

79 Frobisher, M, Jr Am J Hyg **11** 300, 1930

80 Pettit, A, Stefanopoulo, G, and Frasey, V Compt rend Soc de biol **99** 541 and 1114, 1928

graph, and a short time ago Theiler [40] confirmed this observation when he noted that both human and monkey immune serum could neutralize mouse virus-containing brain It is almost unnecessary to reiterate that protective antibodies are present in the serums of recovered human beings

There is some controversy as to the presence of alexin-fixing antibodies In 1928, Aragao [81] reported negative results, using as antibody human convalescent serums taken from eight to fifteen days after recovery, and as antigens either human serums taken on the first and second days of illness or phenolated saline emulsion of monkey yellow fever liver However, in 1929, Frobisher [82] claimed successful results in 78 per cent of his attempts to demonstrate the same antibodies He used both human and monkey convalescent and immune serums as antibody, and as antigen a saline suspension of monkey yellow fever liver and spleen Nevertheless, he reported unsuccessful results with the precipitin and nonspecific agglutination tests [79] As antigens for his precipitin tests he used urine of monkeys which had succumbed to the disease, aqueous extracts of monkey liver and alcoholic extracts of the liver and heart For the nonspecific tests he used as antigen various members of the *proteus* group of organisms members of the colon-typhoid group and various species of micrococci The antibody used in both tests was the same as in the complement-fixation tests

As regards the presence of any local immunity, Hindle [19] reported that the liver and the spleen of recovered animals protected other monkeys against infection, whereas the brain and the kidney did not This author stated it as his belief that protection was not secured by the residual virus remaining in these tissues but that the phenomenon is an example of special tissue immunity However, the spleen and the liver are two organs that do harbor virus during the disease, and it has been shown that fowlpox virus is recoverable from fowls immune to that disease, and more recently, that vaccine virus is recoverable from animals immune to that virus [83] Certainly there is no local skin immunity, as shown by Frobisher,[79] who reported negative results using yellow fever serums, virus-containing tissue extract and fresh virus-containing blood in sick, recovered and normal monkeys

The possibility of a state of hypersensitiveness to yellow fever virus was also pointed out by Hindle [19] He cited the case of four monkeys that had had mild infections and had recovered and had then been hyperimmunized without any untoward reaction On retesting these animals with the virus over a period of from two to seven months after

81 Aragao H de B Compt rend Soc de biol **99** 1341, 1928

82 Frobisher, M, Jr Proc Soc Exper Biol & Med **26** 846, 1929

83 Sanfelice, F Ztschr f Hyg u Infektionskrankh **107** 357, 1927 Olitsky, P K, and Long, P H J Exper Med **50** 263, 1929

the last injection, they all died with some symptoms of yellow fever However, the course of illness ran only for two days, a much shorter period than in normal animals experimentally infected, and no virus was recovered from their organs In contrast with these monkeys, two others that had also been hyperimmunized did not react when tested at the same intervals

THE VIRUS

As the strains of yellow fever virus now in use have been isolated both in Africa and in South America, it has been of interest to ascertain whether or not they are identical, so far as the means for determining their unity permits That there is no discernible difference has been readily proved This was shown by cross-immunity tests in monkeys, with strains from both continents, by Aragao [9] and by Sawyer, Kitchen, Frobisher and Lloyd, [76] and by cross-protection tests with convalescent serums by Hudson, Bauer, Philip and Davis,[75] by Sawyer, Kitchen and Frobisher,[76] by Davis [78] and by Theiler and Sellards [84] Klotz and Simpson [45] and Hoffmann [85] showed by anatomic comparison that the lesions of the liver were identical in human beings dead of the disease in Africa and in the Western Hemisphere Cowdry and Kitchen [60] showed that the inclusion bodies were also identical

Blanc, Caminopetros and Giroud [86] could not protect human beings against experimental dengue fever by injections of yellow fever serums prepared in rabbits or obtained from human convalescents, thus showing that these two viruses are not related

Since it has become apparent that the causative agent belongs to the ultramicroscopic group, the effects of various chemical and physical agents on it have been determined in an attempt to classify it with the other filtrable viruses Frobisher [79] showed that mercuric chloride 1 7,500, hexylresorcinol 1 1,500, phenol 1 150 and sodium oleate 1 150 did not inactivate the virus after contact at 30 C for thirty minutes He also asserted that under the same conditions the virus was inactivated, but not necessarily killed, by the following eosin 1 300, liquor cresolis compositus (U S P) 1 200, sodium oleate 1 50, formaldehyde 1 15 and ethyl alcohol 1 6 Recently, Hindle and Findlay [87] showed that the virus never survived for twenty-four hours if kept at a p_H range of from 3 to 4

The effect of heat on the yellow fever virus, which was originally studied by Marchoux, Salimbeni and Simond,[20] who found that a

84 Theiler and Sellards (footnote 60)

85 Hoffmann, W H J Trop Med **31** 1, 1928

86 Blanc, G, Caminopetros, J, and Giroud, P Bull Acad de med, Paris **101** 442, 1929

87 Hindle, E, and Findlay, G M Brit J Exper Path **11** 134, 1930

temperature of 55 C in five minutes destroyed serum virus, was reinvestigated by Frobisher [79] He showed that virus-containing serum heated at 60 C for ten minutes was inactivated, but that heating at 55 C for ten minutes did not always render it noninfectious This author also stated that temperatures below 55 C could not be relied on to inactivate the virus in ten minutes, but that desiccated virus-containing blood heated at 50 C for ten minutes in one case was able to produce yellow fever in a monkey after a prolonged period of incubation Virus-containing serum exposed to the air for forty-eight hours loses its virulence, as shown long ago by the French Commission, but surface tension reducents, such as 0 7 per cent sodium oleate and 0 07 per cent hexylresorcinol, have no effect, as reported by Frobisher [79] The latter also obtained indifferent results with experiments in cataphoresis, but Hindle and Findlay [87] more recently showed that the virus carries a negative charge at a p_H of from 5 2 to 7, and that its iso-electric zone ranges from p_H 4 2 to p_H 5 2

That the virus of yellow fever is filtrable has been known since the original work of the American Commission, which was confirmed by the French Commission and by Rosenau, Parker, Francis and Beyer [88] More recently, Stokes, Bauer and Hudson confirmed this work as regards virus contained in serum, but could not filter the virus contained in mosquitos if they used a macerated saline suspension of the insect However, Sawyer and Frobisher,[89] in repeating the latter work, found that if the macerated mosquitos were suspended in serum rather than in saline solution, the virus would pass the filter

Marchoux and his collaborators in 1903 showed that if defibrinated human blood containing virus was kept under a petrolatum seal, the virus would remain viable for five, but not for eight days This work was confirmed by Aragao,[9] who found that the virus in human blood did not survive longer than nine days, if the blood was kept in the icebox, and by Sawyer, Lloyd and Kitchen [90] The latter showed that the causative agent, when preserved, acts in a manner similar to that of the other members of the group of filtrable viruses They state that if monkey virus, either of the blood or of the liver, is frozen and dried in vacuo and then kept in a sealed glass container in the icebox, it remains viable for at least 154 days, and if dried in the nonfrozen state, the results are practically the same Previous to this, Hindle [19] reported that dried virus if kept in vacuo in the icebox would be virulent for at least three months, and Pettit, Stefanopoulo and Kolochine [53] also reported that they preserved their virus on ice, in the form of dried

88 Rosenau, M J Parker, H B, Francis, E, and Bergen, G E Bull Yellow Fever Inst 1904, no 14 (published 1905)

89 Sawyer, W A, and Frobisher, M, Jr J Exper Med **50** 713, 1929

90 Sawyer, W A, Lloyd, W D M, and Kitchen, S F J Exper Med **50** 1, 1929

blood Sawyer and his collaborators[90] showed that if the virus is stored in 50 per cent glycerin, it will remain virulent for 60 days, and viable, but not virulent, for 100 days Theiler[40] confirmed this work He found that mouse virus-containing brain kept at from 2 C to —4 C in 50 per cent glycerin was viable after 50, but not after 100, days, and that virus containing brain kept at —8 C survived for at least 160 days

Cultivation of the Virus—Since the beginning of the century, when it was shown that the virus of yellow fever was filtrable, no one, except Noguchi[5] and his collaborators, had been able to isolate a visible microorganism until 1929 In that year Kuczynski and Hohenadel[91] claimed to have isolated an organism, *Bacillus hepatodystrophicans,* from cultures of their yellow fever material, which they claimed represented a phase of the life cycle of the virus and produced the typical disease in monkeys and guinea-pigs Their work is too recent to have received extensive confirmation or denial, but in 1930 da Costa Cruz[92] reported negative results in an attempt to produce yellow fever in monkeys with Kuczynski's bacillus Da Costa Cruz expressed the belief that the organism belongs to the diphtheroid group Lewis,[61] whose work showed that the virus could survive in certain mediums for twelve days at 37 C, said that if, as previously mentioned, 0 000,001 cc of blood could cause an infection in monkeys and if the virus could survive at 37 C for that length of time, Kuczynski's success could be traced to the fact that he might always have carried over some virus in his subcultures

No attempts at propagation of the virus in tissue cultures have been reported

---

91 Kuczynski and Hohenadel (footnote 51) Kuczynski, M H, Hohenadel, B and MacClure, E Klin Wchnschr **8** 1960, 1929, **9** 108, 1930, Tr Roy Soc Trop Med & Hyg **23** 439, 1930

92 Da Costa Cruz, J Compt rend Soc de biol **102** 610, 1929

Notes and News

University News, Appointments, Promotions, Resignations, Deaths, etc—Henry Fraser, formerly director of the Institute for Medical Research, Federated Malay States, has died at the age of 57 He contributed to the knowledge of beriberi and dysentery

Howard T Shaughnessy has been appointed chief of the laboratories of the State Department of Public Health of Illinois

In the department of pathology of Albany Medical College, Kiyoshi Hosoi has been appointed assistant professor and Karl Voldeng Littauer fellow in pathology

Charles B McGlumphy has resigned as professor of pathology and bacteriology in the University of North Dakota to become pathologist at the Deaconess Hospital, Evansville, Ind

At Jefferson Medical College, Philadelphia, Harold L Stewart has been appointed instructor in pathology and Starling C Yinger research fellow

F W Konzelmann has resigned as assistant professor in Jefferson Medical College to accept an appointment as pathologist to the Temple University Hospital, Philadelphia

It is reported that Henry Stuart Willis of the Johns Hopkins University School of Medicine has accepted an appointment as pathologist at the Mayburn Sanatorium, Northville, Mich, in the place of Max Pinner

E O Jordan, professor of bacteriology in the University of Chicago, has been elected a member of the board of scientific directors of the International Health Division of the Rockefeller Foundation

C W Muehlberger has been appointed chemist to the coroner's office of Cook County (Chicago), thus succeeding the late Ralph W Webster

Supplement III of *Acta pathologica et microbiologica scandinavica,* is issued in honor of Thorvald Madsen's sixtieth birthday This supplement also constitutes volume 20 of *Communications de l'Institut serotherapique de l'État Danois*

Hedley Duncan Wright, reader in bacteriology in the University of London and assistant editor of the *Journal of Pathology and Bacteriology,* has been appointed to the chair of bacteriology in Sydney University

Alvin E Belden, William F Lawrence and Edna E Nicholson are announced as the successful candidates for the research fellowships of the National Tuberculosis Association for 1930-1931

In the University of California, Charles L Connor has been promoted to professor of pathology and Max S Marshall to associate professor of bacteriology

Society News—At the meeting of the American Medical Association in Detroit, G Novy and Malcolm H Soule were awarded a gold medal for an exhibit illustrating respiration and dissociation of bacteria

At the recent meeting of the American Association for the Study of Goiter at Seattle, William F Rienhoff, Jr, of Johns Hopkins University, Baltimore, received the annual award of $300 for the best essay dealing with the problem of goiter

Matheson Foundation—The income of $600,000 bequeathed by the will of William J Matheson will be used largely for the support of medical research It is reported that the study of epidemic encephalitis, an international survey of which was provided for by Dr Matheson in 1927, will be continued

Ward Burdick Research Gold Medal—This medal, which is presented annually by the American Society of Clinical Pathologists for the outstanding piece of research done by one of its fellows, was awarded this year to H J Corper, Denver, for his work on isolating and culturing the tubercle bacillus Dr Corper was also made president-elect of the American Society of Clinical Pathologists at the recent convention in Detroit

Abstracts from Current Literature

Experimental Pathology and Pathologic Physiology

THE TIME OF OVULATION AS CHECKED BY THE RECOVERY OF OVA FROM THE FALLOPIAN TUBES Q U NEWELL, EDGAR ALLEN, J P PRATT AND L J BLAND, Am J Obst & Gynec **19** 180, 1930

The authors describe a method for collecting ova by irrigating fallopian tubes at laparotomy, which they recommend as being likewise useful in determining the tubal patency Ninety patients were selected for operation at a time in the menstrual cycle shortly after ovulation The latter was estimated to occur on the twelfth or thirteenth day after the onset of the last menses Five ova were identified when sectioned, and their morphology will be described in detail

A J KOBAK

ANTERIOR HYPOPHYSIS IN THE PREGNANT AND NONPREGNANT STATES A R BACON, Am J Obst & Gynec **19** 352, 1930

Although Ascheim and Zondek have demonstrated an increased amount of hormone in pregnant women which they believe arises from the anterior hypophysis, Bacon's work does not entirely support this The latter, on the assumption that if the theories of the former were correct, has compared grafts of fresh pituitary glands of pregnant and nonpregnant cattle, in infantile mice *A priori*, if the views of Ascheim and Zondek are correct, smaller grafts from pregnant cattle should suffice in producing estrus-like changes in the engrafted animals Bacon did not find this, and in fact the hypophyses of pregnant cattle were somewhat poorer in their hormone content Two possible conclusions can be made from these experiments, namely, that the hormone hypophyses is not the sole seat of the formation of hormone, and that perhaps a different mechanism of hormone factors prevails in cattle

A J KOBAK

THE ACTION OF HISTAMINE ON THE BRONCHIOLES AND PULMONARY VESSELS OF THE GUINEA-PIG M E FIELD and C K DRINKER, Am J Physiol **93** 138, 1930

The vasoconstriction of the pulmonary vessels and the bronchoconstriction that follow the injection of histamine could be readily separated only by the use of very small quantities, with which there was obtained a rise of pulmonary pressure without bronchial constriction The latter phenomenon was obtained with doses of from 0 0001 to 0 01170 mg of histamine per kilogram of body weight, the former alone, with doses ranging from 0 000093 to 0 00310 mg per kilogram

H E EGGERS

THE INFLUENCE OF INORGANIC IRON ON THE ANEMIA OF RICE DISEASE IN PIGEONS O W BARLOW, Am J Physiol **93** 156, 1930

The anemia that develops in pigeons on a polished rice diet as the result of the deficiency in vitamins was not affected by the addition to the diet of inorganic iron in the form of ferrous carbonate in amounts ranging from therapeutic to toxic dosages Actually this anemia does not appear to be due to any deficit of iron in the body, as it is associated with considerable increase in the disposition of hemosiderin in the liver Since this same effect is shown, though to a less degree, by fasting birds, inanition is to be regarded as at least one causative factor Remedy of all the known deficiencies of the polished rice diet is without effect on the disease picture, except that of a deficiency in vitamin B, a deficiency which appears to be the single primary causative factor of the disease

H E EGGERS

THE INFLUENCE OF VITAMIN B ON THE INANITION ANEMIA AND BACTERIEMIA OF RICE DISEASE IN PIGEONS O W BARLOW, Am J Physiol **93** 161, 1930

The several phenomena of rice disease in pigeons—loss of weight, anemia and bacteremia—which show a definite parallelism, are not due to the rice diet as such, for they may be duplicated, even exaggerated, by the feeding of any synthetic diet free from vitamin B Individual pigeons vary in their requirement of vitamin B, and with normal animals voluntary starvation plays a large part in this variation, previous fasting or inanition resulting from previous vitamin B deficiency increased the amount of the vitamin necessary to restore the balance in weight or blood picture While there is a sufficiently close parallelism between bacteremia and the development of anemia to suggest a possible causal relationship between the two, there are enough divergences to suggest the operation of other factors as well Addition of lactose to the deficient diet affected both the bacteremia and the anemia favorably, possibly in part by the lessening of intestinal toxemia

H E EGGERS

THE EFFECTS OF X-RAYS ON THE ADRENAL GLAND F T ROGERS and C L MARTIN, Am J Physiol **93** 219, 1930

In dogs with one suprarenal gland excised, the direct application of the x-rays with an intensity estimated as three and one-half times the erythema dose in man was without any effect on the remaining gland except for causing a slight fibrosis There was no functional disturbance during a period of observation of from three to twelve months Application of from six to eight doses was without observable functional effect for three months With excessive doses, symptoms of suprarenal deficiency appeared gradually after a lapse of several months, with a gradual onset of muscular weakness, depression of metabolism and terminal lowering of blood chlorides In the exposed gland, a heavy dosage of the x-rays caused degenerative changes, which appeared first in the medulla and then in the cortical portions, with an extensive diffuse fibrosis

H E EGGERS

POISONOUS FISHES AND FISH POISONINGS, WITH SPECIAL REFERENCE TO CIGUATERA IN THE WEST INDIES E W GUDGER, Am J Trop Med **10** 43, 1930

Certain poisonous fishes have developed spines for stinging or laceration, and in connection with these stings have developed glands secreting poisons These are comparable to the fangs and poison glands of venomous snakes, and like them function as protective devices Probably, also, these glands, like those of the snakes, have by a perversion of metabolism been developed out of what would normally have been perfectly harmless organs Such fishes poison men only when they sting them Comparable is the poisoning which comes from the injection of the blood serum of a fish into the blood stream of a mammal and, by inference, of a man As already indicated, this is an experimental operation and is of no concern here

Finally, there is the fish poisoning by ingestion of the muscular or other tissues of the fish, the ciguatera of the West Indies Here we have undoubtedly two forms of poisoning—that by ptomaines formed in the partially decomposed tissues of the fish, and that by toxins secreted in various organs but particularly in the ovaries and less notably in the testes at the breeding season In the literature, as in ordinary medical practice, the two kinds of poisoning are almost hopelessly entangled

From what has been said, it is clear that in the disease called ciguatera there is an interesting, and, so far as the West Indies are concerned, an almost virgin field for investigations by modern clinical and chemical procedure for the differentiation of these two kinds of poisoning, and for putting the treatment on a sound scientific basis

AUTHOR'S SUMMARY

THE PHYSIOLOGIC EFFECT OF NONLIVING TESTIS GRAFTS CARL R MOORE, J A M A **94** 1912, 1930

The spermatozoon motility test provides a means of revealing the presence of testis hormone in guinea-pigs for periods as short as ten days, yet by means of this test it has been impossible to detect any hormone liberated from two autoplastic grafts of whole testis in subcutaneous pockets

In the rat, a cytologic study of the prostate gland and seminal vesicles affords dependable methods of detecting the absence of hormone for periods of from three to five days Here, also, two autoplastic grafts of whole testis in subcutaneous pockets failed to delay the onset of castration changes for as short a period as two days

The autolysis of nonviable testicular grafts does not liberate hormone in amounts that can be detected by any means at present known Furthermore, the testis hormone is not stored within the body, but is excreted by the kidneys A continuous supply is necessary to maintain the secondary sex characters in a normal condition

There is no known acceptable evidence that nonviable testicular grafts, i e, grafts that fail to incorporate with the body and actively secrete, exert any immediate or remote beneficial effect on the host organism

AUTHOR'S SUMMARY

TISSUE METABOLISM (THE RESPIRATORY QUOTIENT OF NORMAL AND DIABETIC TISSUE) HENRY B RICHARDSON, EPHRAIM SHORR AND ROBERT O LOEBEL, J Biol Chem **86** 551, 1930

The rate of oxidation in excised renal or muscular tissue of the dog varies within narrow limits, and is about the same as is found in the intact organ in situ The respiratory quotients of normal tissues are intermediate between 1 and 0 7, and imply the participation of fat in the oxidation The average respiratory quotient of renal or muscular tissue taken from depancreatized dogs was 0 7 to 0 75, indicating either no oxidation of carbohydrate, or at most a small amount These observations conflict with the theory that carbohydrate is essential as the immediate fuel for muscle and with that theory of diabetes which holds that the waste dextrose originates from fat

AUTHORS' SUMMARY

NATURE AND RÔLE OF FATTY ACID ESSENTIAL IN NUTRITION G O BURR and M M BURR, J Biol Chem **86** 587, 1930

In the rat, fat-free diets produce extensive, even fatal, renal degeneration The disease resulting from fat-free diet is not cured by saturated fatty acids but by linoleic acid, either pure or in olive oil, lard, corn oil, egg lecithin, etc The important conclusion is reached that linoleic acid is essential in nutrition

HETEROGENOUS LEUKOCYTES AS A VEHICLE FOR THERAPEUTIC AGENTS P SPANIER, Beitr z Klin d Tuberk **73** 210, 1929

Dead cells and heterogenous cells are retained and destroyed in the lungs If heterogenous leukocytes are introduced into the venous system, they are retained in the lungs Since leukocytes can absorb certain therapeutic agents, it is possible to use heterogenous leukocytes as vehicles for therapeutic material It is expected that, thus administered, therapeutic material may come in closer contact with pulmonary lesions and may be retained there for a longer time than with the usual modes of administration

MAX PINNER

Pathologic Anatomy

VARIX OF THE UMBILICAL CORD FRED L ADAIR and R E MCDONALD, Am J Obst & Gynec **17** 836, 1929

The case reported is one of ruptured umbilical varix and adds one to the four cases which the authors found recorded

A J KOBAK

NODULAR FIBROSIS OF THE SPLEEN ASSOCIATED WITH FILARIA LOA OSKAR KLOTZ, Am J Trop Med **10** 57, 1930

Groups of microfilariae aggregate in the spleen of some cases of infection caused by *Filaria loa* These areas of localization are associated with an inflammatory reaction and fibrosis A tissue eosinophilia accompanies the filarial inflammation These reactions in the spleen may be analogous to the external chronic Calabar swellings

AUTHOR'S SUMMARY

GIANT CELL TUMORS OF THE SPINE J V SANTOS, Ann Surg **91** 37, 1930

Laminectomy on a white man, aged 27, revealed a dark purple mass on the dorsal aspect of the dura mater extending from the second lumbar to the twelfth thoracic vertebra and into the surrounding muscles This case represents the twenty-third of giant cell tumor, which were most frequent in the lumbar region, although the cervical and dorsal vertebrae may also be involved

RICHARD A LIFVENDAHL

SARCOMA OF THE THYROID GLAND I Arons, Ann Surg **91** 44, 1930

A 3 5 cm node in the right lobe of the thyroid gland was found in a patient, aged 58, who had a paralysis of the recurrent laryngeal nerve but no evidences of hyperthyroidism The microscopic picture was that of fibrosarcoma From the literature, it is recorded that pressure effects on the surrounding anatomic structures are not unusual and that metastases have occurred in the bones, intestines, liver, kidney, lung and regional lymph glands

RICHARD A LIFVENDAHL

CHANGES IN THE INTRAHEPATIC DUCTS FOLLOWING CHOLECYSTECTOMY J E SUTTON, JR, Ann Surg **91** 65, 1930

Fifteen days following the removal of the gallbladder in dogs the intrahepatic ducts showed epithelial disintegration, stratification of the epithelial cells, bud formation and epithelial exfoliation Forty days after operation there were folds projecting as villous-like structures and high columnar epithelium similar to that of the wall of the gallbladder instead of the low columnar epithelium, as normally lines the ducts

RICHARD A LIFVENDAHL

ON THE FORMATION OF EPITHELIOID AND GIANT CELLS R S CUNNINGHAM, E H TOMPKINS and J S LAWRENCE, Bull Johns Hopkins Hosp **46** 323, 1930

The subcutaneous injection of guinea-pigs with olive oil containing yellow phosphorus caused the production of large numbers of typical epithelioid and giant cells, which were indistinguishable from those in tuberculous lesions

AUTHORS' SUMMARY

STUDIES ON VITAL STAINING H P SMITH, J Exper Med **51** 379, 1930

Brilliant vital red injected into the blood stream of dogs is slowly taken up by phagocytes in various parts of the body, but eventually an equilibrium is established, after which the concentration as measured in the plasma remains almost

constant for long intervals of time This equilibrium can be disturbed by injecting more dye, and in this case the phagocytes resume ingestive activity, apparently with normal or nearly normal vigor This activity continues until a rather large part of the newly injected dye has been removed, and as the reaction again slows up, one notes that both plasma and tissues contain more dye than before It is difficult to be certain that the distribution ratio of dye between plasma and tissues remains unaltered with dosage, but evidence indicates that for nontoxic doses, at least, that is approximately true This study of this partition ratio is complicated by the fact that the liver slowly excretes dye into the bile and this helps to reduce the amount of dye in the body Partial correction for this factor can be made by ascertaining the output of dye in dogs with a biliary fistula The latter studies show that elimination of dye into bile is relatively less efficient when large doses of dye are given to the animal than with smaller dosage This undue retention of dye in the body with large dosage helps to maintain the dye concentration in the plasma at unduly high levels These peculiarities in excretion of the liver have an important bearing on the physiology of that organ in general, and in addition they also have an important application in connection with the theory of "blockade of the reticulo-endothelial system" It is now obvious that prolonged retention of dye in the blood stream does not of itself prove that this group of phagocytic cells is "blocked" against the entrance of foreign material Altered excretion by the liver, kidney, etc, must be ruled out before one can accept such data as evidence of "blockade"

AUTHOR'S SUMMARY

STUDIES ON VITAL STAINING H P SMITH, J Exper Med **51** 395, 1930

When large amounts of brilliant vital red are injected into the blood stream of dogs, the dye is gradually removed from circulation, and most of it is deposited in numerous phagocytic cells which are scattered throughout various organs and tissues The dye occurs largely in the form of tiny red granules crowded together in the cytoplasm of these cells If Niagara sky blue, a closely related dyestuff, is injected, it too is taken up and stored in these same cells It is shown that the presence of red dye in the tissues does not inhibit the cells from taking up the blue one The normal ability of the phagocytes to take up Niagara sky blue is observed also when this dye is injected simultaneously with brilliant vital red This normal response toward the blue dye is seen even though the phagocytes are busied at the same time in the process of engulfing and storing the red dye These experiments show that it is difficult if not impossible to "block" the cells with one dye so that their ability to take up another is even slightly impaired The two dyes employed in these studies are shown to be particularly suitable for experiments of the sort here reported

AUTHOR'S SUMMARY

CONGENITAL DISLOCATION OF THE HIP H A T FAIRBANK, Brit J Surg **17** 380, 1930

The study was founded on thirty-five museum specimens, comprising forty-six dislocated hips and fifty open operations The primary fault was found to be the poor development of the upper margin of the acetabulum, including malformations of the cotyloid ligament, the cartilaginous margin and even the bone As the condition progresses the acetabulum later assumes a triangular shape with a sharp, straight and not uncommonly undercut edges, the cavity being filled by cartilage or fibrofatty tissue Secondary changes include a triangular outline of the obturator foramen and an increase in the public angle, the ilium is shorter and broader than normal, and a false acetabulum forms on the dorsum ili which may be located high low, anteriorly or close to the sciatic notch The tuber ischii shows roughening and thickening of the bone The femoral head is smaller than normal, though relatively larger than the acetabulum, and is flattened on its inner and posterior aspects with erosion and lipping in adults The femoral neck is usually longer and more slender

than normal and is associated with varying degrees of coxa vara The capsule migrates upward, blends with the periosteum of the acetabulum and becomes thickened The ligamentum teres is frequently absent in cases of long standing

RICHARD A LIFVENDAHL

SPONTANEOUS RUPTURE OF THE NORMAL SPLEEN H BAILEY, Brit J Surg **17** 417, 1930

A large subcapsular hematoma of the spleen was found in a white man, aged 20, who presented no history of an injury The microscopic picture of the organ was normal

RICHARD A LIFVENDAHL

A REMARKABLE MECKEL'S DIVERTICULUM H B YATES, Brit J Surg **17** 456, 1930

In a woman, aged 37, who was three months pregnant, was found a huge tumor mass that filled the entire right side of the abdomen, and was covered by peritoneum on the anterior aspect and the right side The posterior surface was located directly on the posterior abdominal wall It is described as a rising 8 cm proximal to the ileocecal valve, forming a huge diverticulum, the walls of which, microscopically, presented the picture of the ileum, except that the muscles were hypertrophied and there was very little lymphoid tissue The contents consisted of brown fecal material

RICHARD A LIFVENDAHL

STRANGULATED INTERNAL HERNIA IN A RETRO-APPENDICULAR PARACECAL POUCH C DONALD, Brit J Surg **17** 463, 1930

A partially collapsed, hernial pouch, 10 by 9 cm, was found on the inner side of the ascending colon just above the ileocecal junction extending to the line of attachment of the mesentery proper Its anterior wall was thin and vascular, and fused to it posteriorly was the appendix which was pointed toward the spleen The cecum was not fixed posteriorly, the pouch being located on its inner border This sac contained 16 inches (40-64 cm) of congested ileum The hernia was associated with an ileo-appendicular fossa of funnel shape, with the fold running from the terminal 2 inches (5 cm) of the ileum to the appendix itself, losing itself on the anterior margin of the hernial opening The other fossae of this region and the embryologic aspects are discussed

RICHARD A LIFVENDAHL

A SOLITARY PLASMA-CELLED MYELOMA H ROGERS, Brit J Surg **17** 518, 1930

A tumor, 4½ by 2¼ inches, with a honeycombed appearance, led to the spontaneous fracture of the right femur in a white man, aged 34, There was a cavity filled with a soft, white material which consisted, for the most part, of plasma cells Reexamination of the same material during the two following operations showed only a structural matrix or well formed fibrous tissue or vascular granulation tissue

RICHARD A LIFVENDAHL

THYROID METASTASIS IN BONE W K CONNELL, Brit J Surg **17** 523, 1930

In two women, aged 45 and 50, respectively, a large tumor mass was noted in the occipital region Microscopic examination revealed a fetal type of adenoma In the thyroid gland of each patient there was a walnut and a hen's egg sized mass From the literature it was noted that the bones, particularly the sternum, vertebrae, ribs, humerus, femur, pelvis and clavicle, are the structures most frequently involved When occurring in the cranial bones, the metastases tend to follow the suture lines

RICHARD A LIFVENDAHL

GENERALIZED OSTEITIS FIBROSA WITH PARATHYROID HYPERPLASIA A M DRENNAN, J Path & Bact **33** 65, 1930

A case is recorded of osteitis fibrosa with cystic changes in the bones and a large mass of parathyroid tissue The bone changes consist of absorption of existing trabeculae replacement of preexisting bone by fibrocellular tissue, with or without calcification of this tissue, and formation of osteoid tissue and new bone In places where loss of original bone is marked, e g, in the lower end of the tibia, areas of hemorrhage occur with invasion by fibrocellular tissue and giant cells (osteoclastic type), giving rise to the so-called cystic areas, although many of these are really solid masses but deficient in bone tissue The distribution of all these changes is general throughout the skeleton, but the type of change in any part varies considerably, e g, tibia as compared with humerus or with skull As already mentioned, the bony changes in this case are exactly the same as those described in the case of Dawson and Struthers There is nothing in the history to suggest a cause for the condition The thyroid changes are degenerative and are unlikely, per se, to have any relation to the bone disease, as changes of this type are often found unassociated with any bone lesions The failure to find normal parathyroids is interesting The mass of abnormal parathyroid tissue present in the position of the right lower parathyroid would seem to be either tumor growth or hyperplasia of the preexisting gland to compensate for the absence or loss of the other parathyroids In Dawson's case, the parathyroid mass was regarded as an adenoma of parathyroid The mass in this case seems to be similar as far as gross and microscopic appearances show As pointed out by Vines (1924), Korenchevsky (1922) and others, the relation of the parathyroids to calcium metabolism is still obscure, but the effect of their absence would appear to be somewhat similar to the effect of deficiency of vitamin A and of calcium Conversely, enlargement of the parathyroids has been observed in rickets and osteomalacia by many authors Unfortunately, the data in any one case of disease are frequently deficient, in this case there is no record of calcium intake or output, and no chemical examination of the blood or organs was attempted Therefore, only morphologic data are recorded

AUTHOR'S SUMMARY

MILIARY ANEURYSMS IN THE BRAIN F H K GREEN, J Path & Bact **33** 71, 1930

A technic is described for the search for miliary aneurysms in the brain During an examination of the brains of ten arteriosclerotic subjects only three undoubted "miliary aneurysms" were found One of these could not be classified from the few sections obtained, the other two were shown to be respectively saccular (or dissecting) and fusiform Each arose from a grossly diseased parent trunk Two of these aneurysms had ruptured, giving rise to small hemorrhages in the brain substance The third was completely thrombosed and lay in relation to a zone of ischemic softening It is suggested that miliary aneurysms only arise where atheroma involves the media of an artery to an extreme degree The process responsible for the production of "saccular" aneurysms would appear to be a stretching and rupture of the necrotic intima and media leading to effusion of blood into the Virchow-Robin space, and followed by condensation and distention of the adventitia The latter may undergo secondary rupture, and so give free communication between the lumen of the parent artery and the surrounding tissues In this way miliary aneurysms may be responsible for some cases of cerebral hemorrhage Complete thrombosis of miliary aneurysms may cause foci of ischemic softening in the brain

AUTHOR'S SUMMARY

THE PATHOLOGY OF DISSEMINATED ENCEPHALOMYELITIS OF THE DOG (THE "NERVOUS FORM OF CANINE DISTEMPER") J R PERDRAU and L P PUGH, J Path & Bact **33** 79, 1930

Demyelination of the type commonly found in subacute disseminated sclerosis was found in four of fourteen cases of disseminated encephalomyelitis of the dog

(the "nervous form of canine distemper") The parts of the central nervous system where demyelination was most commonly found were the cerebellar peduncles and adjacent portions of the cerebellum and of the brain stem Distemper is not apparently an essential antecedent of the encephalomyelitis, as the association of the two conditions was noted in only seven of fourteen cases observed The time interval which has been recorded in the disseminated encephalomyelitis of man between the onset of the acute infection and the appearance of the nervous phenomena is fairly constant, this has no parallel in this condition of the dog where it varies widely from case to case

AUTHORS' SUMMARY

THE LATE RESULTS OF INTRAVENOUS INJECTION OF COLLOIDAL IRON D F CAPPELL, J Path & Bact **33** 175, 1930

Colloidal iron injected intravenously is taken up first by certain cells belonging to the reticulo-endothelial system and by certain of the circulating leukocytes in the same way as suspensoid substances, e g, carbon is Later, the iron undergoes transformations which result in its redistribution The most important of the later changes is believed to consist in the entry of iron into some compound—possibly a loose combination with the plasma proteins, and it is probable that this linking is brought about through the activity of reticulo-endothelial cells This loosely bound iron is capable of passing through capillary walls, and thus iron storage appears later in lymphatic glands and in the parenchyma cells of the liver and kidney In the mouse, the liver, spleen and lymphatic glands are the most important sites of iron storage, and of these the liver contains the greatest amount of iron in the later stages Excess iron administered parenterally is dealt with similarly to excess iron derived from hemolysis occurring in the circulation It is important that no ill effects follow massive accumulation of iron in the liver cells The pancrease does not participate in the storage of iron Accordingly, nothing analogous to the lesions of hemochromatosis in the human subject has been observed in the organs of animals subjected to excess iron over prolonged periods

AUTHOR'S SUMMARY

PRIMARY DIFFUSE ENDOTHELIOMA OF SOFT MENINGES S S VAIL, Virchows Arch f path Anat **273** 441, 1929

A man, aged 30, suffered from increasing headaches, vomiting and attacks of unconsciousness, became blind, and psychosis of the schizophrenic type developed At autopsy, diffuse thickening of the soft meninges was found, with dense yellow layers along the fossae Sylvii The gross diagnosis was chronic leptomeningitis Microscopically, the whole brain was covered by strands of homogeneous round ovoid cells, which partly surrounded the blood vessels The brain substance was invaded

ALFRED PLAUT

MULTIPLE MALFORMATIONS IN A HYPOPLASTIC PERSON VOJIN LAZAREVIC, Virchows Arch f path Anat **273** 445, 1929

An idiotic girl, aged 13 years, had a family history that was irrelevant There were five other healthy children At the age of 3 paralysis of the left arm and leg developed She often choked while eating, palpitations were always present, menstruation had not begun The clinical diagnosis was spastic infantile hemiplegia, mitral insufficiency and stenosis, defect of septum Death occurred from cerebral embolism The antomic diagnosis was primary microgyria of the right cerebral hemisphere, defect in the septum of the ventricles and auricles, congenital insufficiency of the venous ostia, thymus persistens, hypoplasia of the arteries, hyperplasia of the lymphatic apparatus, extensive polyposis adenomatosa of the large intestine, abnormal lobulation of the right lung, liver, spleen and kidneys, large ovaries with follicular cysts, pigmented nevi of the skin

ALFRED PLAUT

IDIOPATHIC NECROSIS IN THE MEDIA OF THE AORTA J ERDHEIM, Virchows Arch f path Anat **273** 454, 1929

This disease is characterized by necrosis in the media without any inflammatory reaction The picture originally was mistaken for syphilitic aortitis without accompanying arteriosclerosis Defects in the media are seen through the intact, hence transparent, intima, they may be compared to striae gravidarum, but they are never purplish as in aortitis syphilitica—they are gray The wall becomes thin, and rupture may take place At the edge of such a lesion, defects in the elastic lamellae are found, the lamellae themselves may be preserved but without elastin The defects appear red in the van Gieson stain Cavities form, sometimes containing coagulated material, the muscle tissue disappears to a greater or lesser extent True necrosis may occur Inflammation is entirely absent

Nearer the center of a lesion necrosis prevails in the outer layers, partly with coalescing but well stained elastic lamellae If one does not pay attention to the staining of the nuclei, one can easily overlook the necrosis In spots the tissue of the media is completely supplanted by connective tissue The necrotic material disappears slowly, in the inner layers it disappears more rapidly, probably carried off by the blood stream There is very little regeneration Nearer the intima, rarefaction of elastic layers is found without necrosis, later the muscle tissue disappears Thus the process in the innermost layers of the media is different from that in the outer strata The intima is thickened and contains newly formed muscle cells

The complete absence of inflammation forces one to assume an entirely "humoral" removal of the necrotic material The cause for the absence of inflammation, as well as the etiology of the whole disease, is unknown Different toxic factors have been mentioned The disease was unknown before the World War

ALFRED PLAUT

NIEMANN-PICK DISEASE (LIPOIDOCELLULAR SPLENOMEGALY) H SMETANA, Virchows Arch f path Anat **274** 697, 1930

In a first born Jewish girl, enlargement of the liver was noted at age of 3 months together with increasing brownish discoloration of the skin The blood was normal At the age of 20 months, the child could not sit and was unable to support her head She was idiotic, but not blind The spleen was much enlarged Death occurred from pneumonia Autopsy showed soft, edematous meninges and a firm brain with thick convolutions somewhat similar to a brain in familiar amaurotic idiocy, a firm spleen (222 Gm), reddish-white pulp, yellowish intestinal mucosa and mesenteric lymph nodes, reddish-yellow marrow of the femur, and a firm, yellowish-gray liver (1,140 Gm)

Large, vacuolized cells from 20 to 60 microns in diameter were found in all the organs, most of them having one nucleus They were numerous in the spleen, liver, lung, thymus, lymph nodes and brain With sudan III stain, all colors from light yellow to brown red were found With the Smith-Dietrich stain, gray to black granules were found in all the cells Doubly refractive material was present in large amount in the thymus, bone-marrow and lymph nodes, and small amounts in the ovaries, intima of the aorta and perivascular tissue in the brain The liver and spleen contained no doubly refractive material In the liver, the large cells protruded into the capillaries, endothelial cells separating them from the liver cells All transitions from normal Kupffer cells, containing a few vacuoles, to the large, completely vacuolized cells, were traced In the lungs the large cells contained up to twenty nuclei and occasionally large fat droplets It is possible that large amounts of the lipoid material resulting from the breaking down of the large cells in all the organs, were carried into the lung and thus were responsible for the different appearance of the large cells in the lungs

Chemical examination of fresh liver, spleen and brain showed much increase in lecithin and phosphorus-containing lipoids No kerasin could be found The chemical examination is the best means of differentiating between Gaucher's disease

in infants and Niemann-Pick's disease For the Smith-Dietrich stain the author recommends mordanting and staining in bulk, followed by celloidin embedding and differentiation under the control of the microscope

ALFRED PLAUT

EXPERIMENTAL STEATOSIS OF THE EYE OF THE CHICKEN T UCHIYAMA, Virchows Arch f path Anat **274** 803, 1930

The cholesterol content of the blood varies much in the chicken and more so in hens A detailed description is given of the distribution of fat substances in different parts of the cock's eye under normal conditions and after feeding cholesterol oil No true senile arcus could be produced The distribution of the fat substances is different from that in man or rabbit

ALFRED PLAUT

UNIVERSAL CONGENITAL HYDROPS H HARTMANN, Zentralbl f Gynak **52** 299, 1928

Hydrops congenitus is characterized by anasarca, hydrops of all cavities and myeloid foci in liver, spleen, kidney, suprarenal gland and intestine The etiology is unknown Syphilis is not the cause, but may produce similar changes The frequent coincidence of congenital hydrops with maternal nephritis points to the existence of an etiologic connection between these conditions A toxemia for which the fetus is probably responsible is regarded as the primary cause

W C HUEPER

THE HISTOLOGIC DIAGNOSIS OF CERVICAL EROSION H U HIRSCH-HOFFMANN, Zentralbl f Gynak **52** 2013, 1928

The histologic changes present in the healing stage of a true cervical erosion may resemble closely carcinomatous conditions Masses of more or less undifferentiated squamous epithelial cells may replace the columnar epithelium of the cervical glands and may fill partially or entirely the glandular lumen A positive mucin reaction indicates the origin of these benign epithelial formations The presence of an inflammation may cause a certain degree of irregularity of the epithelial cells A correct diagnosis requires great experience

W C HUEPER

SQUAMOUS EPITHELIUM IN HYPERPLASTIC ENDOMETRIAL GLANDS O HINTZE, Zentralbl f Gynak **52** 2209, 1928

Small circumscribed areas of stratified squamous epithelium growing in nests or strands were found in nine cases of hyperplastic mucosa of the corpus uteri or in glandular polyps The squamous epithelium was present in glands, replacing the cylindric epithelium, forming sproutlike projections, or filling the lumen completely These formations are apparently rare, if one considers the large material of the clinic in Berlin and the fact that these nine cases represent the total number observed during a five-year period As their benign character is not generally recognized, Hintze points to the fact that in four of his cases the patients remained well after a simple curettage

W C HUEPER

THE KIDNEY DURING PREGNANCY W NONNENBRUCH, Zentralbl f Gynak **53** 514, 1929

During pregnancy there may be a special, diffuse type of lipoid nephrosis (glomerulonephrosis) in which mainly the epithelium of the main tubules and especially of the glomeruli shows degenerative changes The inflammatory reaction is by far less marked Increase of nuclei is in general absent Blood is usually not present in the urine The cause is either a direct effect of a toxic substance on the kidney, a conception supported by the occurrence of hemoglobin casts, or

the nephrosis is due to an ischemia of the glomeruli on account of arteriolar spasms Capillary microscopy shows the existence of spasm in the arterial branch, a factor considered as the cause of the hypertension in nephrosis of pregnancy Arteriolar spasm is also present in eclampsia affecting the vessels of the brain Eclampsia is not produced by the existing dyscolloidosis and cholesteremia of the blood The edematous fluid in eclampsia is almost free from albumin and rich in sodium chloride The edema may be caused by circulatory disturbances The function of the kidney is not, or only slightly, impaired in the nephrosis of pregnancy Absolute rest and a nonirritating dry diet are recommended as a therapeutic measure The intake of liquids has to be restricted Large bleedings are well tolerated, but subsequent injections of solutions of sodium chloride are contraindicated Dextrose has to take the place of sodium chloride

W C HUEPER

Pathologic Chemistry and Physics

THE CALCIUM IN THE SERUM IN JAUNDICE A M SNELL, C H GREENE AND F WALES, Am J Physiol **92** 630, 1930

In clinical cases of jaundice there was found a slight decrease of serum calcium, probably without significance to the patient No significant disturbance was found in either the amount or the proportion of diffusible calcium, nor was there any correlation between either total or diffusible calcium and either serum bilirubin or prolongation of clotting time There evidently is no clinically significant change in the relations of blood calcium during jaundice

H E EGGERS

CHEMICAL DETERMINATION OF THE GLYCOGEN RATIO IN THE BUNDLE OF HIS AND THE CARDIAC MUSCLE IN MAN AND IN THE HORSE WALLACE M YATER, ARNOLD E OSTERBERG and HANS W HEFKE, Arch Int Med **45** 760, 1930

The ratio of the percentage of glycogen in the muscle to that in the tissues of the conduction system was determined by a new microchemical technic in twenty-one hearts of human beings and in four hearts of horses The ratio of the percentage of glycogen in the muscle to that in the bundle of His of the hearts of human beings varied between 1 0 50 and 1 1 17, with the probable average ratio of 1 0 9 The ratio of the percentage of glycogen in the muscle to that in the radicles of the left bundle branch of the hearts of horses varied from 1 1 95 to 1 10 10, in spite of the much greater fibrous tissue content of the tissues of the conduction system in the horse Why there should be such a difference in this ratio between the heart of the human being and the heart of the horse cannot be explained at present Glycogen disappears slowly both from the cardiac muscle and from the tissues of the conduction system in specimens that are first studied within a half hour after death (hearts of horses), but the percentage of glycogen in the hearts (both of human beings and horses) varies markedly without any ascertainable reason

AUTHORS' SUMMARY

THE DIFFUSIBLE CALCIUM AND THE PROTEINS OF THE BLOOD SERUM IN JAUNDICE LEWIS GUNTHER and D M GREENBERG, Arch Int Med **45** 983, 1930

The indirect method of calcium replacement therapy in jaundice should be discarded as a means of proof that the diffusible calcium is low in jaundiced patients, since a direct analytic method is available for the measurement of the diffusible calcium Analytic studies of the blood of jaundiced patients show that there is no deficiency in the diffusible calcium of the blood serum, regardless of the degree of jaundice between icteric indexes of 17 5 and 200, and regardless of

the absence or presence of abnormal bleeding phenomena The serum albumin may be low in jaundice The nondiffusible fraction of the serum calcium may be low as a result of the fall in the serum albumin The value of the diffusible calcium of the blood serum is a more accurate measure of the physiologically available calcium than the value of either the nondiffusible or the total calcium Factors other than the amount of available calcium, as measured by the concentration of the diffusible calcium, must be sought to explain the abnormal bleeding phenomena seen in jaundiced patients

AUTHORS' SUMMARY

WATER CONTENT OF INTERVERTEBRAL DISKS JOHANNA PUSCHEL, Beitr z path Anat u z allg Path **84** 123, 1930

Since the shock-absorbing properties of the intervertebral disks probably depend largely on the water content of the tissue, the author undertook an investigation of the latter at the suggestion of Schmorl, in whose institute a necropsy usually includes the removal of the vertebral column and of one or both femurs The water content was estimated separately for the annulus fibrosus and nucleus pulposus by determining the loss of weight after drying to constant weight at 103 C A preliminary investigation having shown no appreciable differences in the water content of the various disks of the same person, the determination was limited to four disks in each case, usually the third and tenth thoracic and the first and fifth lumbar Twenty-two cases in which the disks revealed no gross changes and four in which alterations were visible to the naked eye were included in the investigation The water content is highest at birth, having an average value of 78 per cent for the ring and 88 per cent for the pulp It decreases with age, the loss being greatest during the first year of life At 3 years of age, the water content of the ring is 70 per cent, that of the pulp, 76 to 78 per cent The water content of the annulus remains practically constant at from 68 to 70 per cent from the third year on, whereas that of the pulp continues to decrease with age, falling to 70 per cent in the ninth decade Disks that appeared swollen and abnormally moist had essentially the same water content as normal disks of the same age period Disks that appeared abnormally dry or brittle or fissured had a decreased water content

O T SCHULTZ

CHEMICAL INVESTIGATIONS OF THE BLOOD AFTER DEATH F JACOBY, Virchows Arch f path Anat **274** 392, 1929

The thrombin content after death is much lower than during life, it decreases rapidly, after twenty-four hours very little thrombin is left Thus, late formation of postmortem thrombi is improbable The results speak in favor of Ribbert's theory of agonal thrombosis There are no basic morphologic differences between intravital thrombi and postmortem clots The nonprotein nitrogen in the blood of the cadaver generaly is high, it increases slowly The p_H was found to be about 7 11 High figures for nonprotein nitrogen were obtained in blood with an unusually strong acid reaction The calcium figures do not differ from those found in the living subject Twenty-six bodies were examined

ALFRED PLAUT

Microbiology and Parasitology

FETAL BACTEREMIA A CONTRIBUTION TO THE MECHANISM OF INTRA-UTERINE INFECTION AND TO THE PATHOGENESIS OF PLACENTITIS ALFRED J KOBAK, Am J Obst & Gynec **19** 299, 1930

The occasional presence of streptococci and other organisms in the blood from the umbilical cord, sent to the laboratory for use in mediums, prompted an investigation on a large scale to determine in what manner the fetus becomes infected

before or during labor Thus 374 consecutive fetal blood cultures, aseptically drawn from the umbilical cord in the third stage of labor, were studied Positive cultures were found in thirty-four cases, or about 9 per cent In most instances these cases were associated with a prolonged rupture of the bag of waters The organisms were found to be the type that usually frequents the vaginal canal in late pregnancies Thus it is believed that they find their way into the amniotic fluid from which they get into the fetal circulation The placentas were studied in all cases in which three cultures were positive, and also in any cases that had membranes unduly long ruptured and in which there was suspicion of utrapartum maternal infection This study showed that the inflammatory reactions of the placenta is most often due to organisms in the amniotic waters The organisms most likely break through the superficially placed chorionic blood vessels and enter the fetal circulation In most instances this was only a transient bacteremia with no clinical significance In a few instances of difficult birth, with a traumatism of the child from obstetrical procedures, severe and even fatal infection occurred Four of the infants who died had the same bacteria in the heart blood as in the blood of the cord Maternal infection also may take place in difficult labor

A J Kobak

Experimental Tuberculous Meningitis in Rabbits Willard B Soper and Morris Dworski, Am Rev Tuberc **21** 209, 1930

The previous observation that the protective action of an already existing infection is manifested in the meninges of the rabbit is confirmed Two rabbits vaccinated with living human tubercle bacilli successfully overcame a small intrameningeal dose of virulent bovine bacilli fatal to controls Rabbits subcutaneously vaccinated once with heat-killed tubercle bacilli showed a pronounced degree of protection against virulent bovine bacilli injected intrameningeally This protection was less than that conferred by living bacilli The white cell count of the cerebrospinal fluid following meningeal superinfection with small doses of tubercle bacilli was strikingly low in comparison with counts after similar infection with large doses Differences in the immediate white cell reaction to intrameningeal infection on the part of vaccinated as compared to unvaccinated animals were negligble when the small dose of 200 bovine bacilli was employed

H J Corper

An Attempt to Grow Tubercle Bacilli in Gross Tissues H J Corper, Am Rev Tuberc **21** 252, 1930

These studies on the growth of tubercle bacilli in normal and pathologic tissues have a practical bearing in that they offer an explanation for the inability of tubercle bacilli to grow directly on tuberculous tissues and excretions in vitro at incubator temperature, they indicate the futility of trying to increase the number of bacilli by this means for diagnostic purposes without overcoming the fundamental obstacles to such an increase in numbers, and they point out certain important precautions to be observed in the application of culture methods for diagnostic purposes In the sulphuric acid-crystal violet-potato cylinder method previously recommended for diagnostic purposes, the thorough grinding or breaking up of the tissues or pathologic material was more or less empirically emphasized, as was a light well distributed planting over a number of culture tubes, which serves to bring the bacilli into intimate contact with the potato medium At incubator temperature, the acid-treated tissues develop toxic autolytic products that destroy the tubercle bacilli, and intimate contact with the potato inhibits the formation of these toxic products in sputum, tissues, etc This study also throws light on some of the apparent discrepancies between the in vivo and the in vitro growth of tubercle bacilli and stresses the importance of quantitative consideration in evaluating growth conditions in the body Any attempt to study in vivo condi-

tions in tuberculosis by in vitro methods must take into consideration the possibility of the formation of toxic autolytic products for tubercle bacilli by the tissues under the conditions of the experiment, and, if possible, must take measures to obviate their formation or overcome their action by appropriate neutralizing or counteracting procedures

H J CORPER

THE REACTIONS OF THE TISSUES TO THE LIPOID FRACTIONS OF THE TUBERCLE BACILLUS STRAIN H37 FLORENCE R SABIN, C A DOAN and C E FORKNER, Am Rev Tuberc **21** 290, 1930

The tissue reactions to five lipoid fractions from the tubercle bacillus are described All of the lipoid substances were found to give a marked proliferative reaction in the connective tissues, which reaction was in part specific and in part nonspecific The reaction may belong to the so-called foreign body type

H J CORPER

ARACHNIDISM J B ELLIS, Ann Int Med **3** 924, 1930

In three of five cases of arachnidism the offending spider was caught and identified as *Latrodectus mactans,* which is thought to be the only poisonous spider in the United States The symptomatology was practically identical in all of the cases burning pain at the site of the bite, followed in approximately thirty minutes by severe backache, headache, pains in the abdomen and legs, profuse perspiration, extreme restlessness with rapid and difficult breathing The symptoms gradually receded but did not disappear for several days There were no deaths The fact that one patient, who was bitten a second time two weeks after the first bite, developed a much milder illness following the second bite caused Ellis to assume that the patient developed some immunity as the result of the primary inoculation

WALTER M SIMPSON

POSTVACCINAL (COWPOX) ENCEPHALITIS GEORGE B HASSIN and J C GEIGER, Arch Neurol & Psychiat **23** 481, 1930

In a case observed in January, 1926, a white boy, aged 7, with a condition diagnosed as tetanus, had been vaccinated against smallpox two weeks previous to admission to the hospital Twelve days after the vaccination he began to have severe frontal headaches, soon followed by convulsions and lockjaw The clinical picture was that of a typical tetanus, the patient was treated with tetanus antitoxin intramuscularly and intravenously, the condition grew worse, the temperature rose to 107 7 F , a blood count showed 26,000 white cells per cubic millimeter, and the spinal puncture yielded a normal spinal fluid Respiratory difficulties set in, and the patient died twenty hours after admission Histologic studies revealed hyperemia of the blood vessels, mild infiltration of the perivascular spaces of the larger blood vessels mainly with glia cells which formed a much denser infiltration outside the adventitia the so-called extra-adventitial infiltration The capillaries showed no infiltrations The infiltrated areas sometimes coalesced, forming extensive islands The extra-adventitial areas exhibited no axons or myelin, the English authors named them areas of demyelination Outside these the nerve substance was preserved, but the microglia was changed throughout, it was swollen and hypertrophied, the processes were tumefied, shortened and reduced in number and the nuclei were pyknotic and hypertrophied The subarachnoid space was distended and contained fibroblasts, lymphocytes, polyblasts and macrophages The ganglion cells were practically normal The changes were similar to those described by others but were unique in taking place within twenty-three hours after the onset The clinical picture of postvaccinal encephalitis may vary but the anatomic picture is the same, it differs from other forms such as epidemic encephalitis From the histologic studies of the case and analysis of the views

as to the probable cause of the postvaccinal encephalitis, the authors come to the conclusion that it is not of infectious but of toxic origin, and that some toxin occasionally too virulent is contained within the vaccine lymph and invades the brain

GEORGE B HASSIN

COCCIDIOIDAL GRANULOMA OF THE SPINAL CORD CARL W RAND, Arch Neurol & Psychiat **23** 502, 1930

Coccidioidal granuloma much resembles chronic tuberculosis In California 143 cases have been reported to the State Board of Health against 98 cases reported in the literature In Rand's cases the process involved the spinal cord In the first case, that of a Mexican woman, aged 31, recurring pain of five years' duration was followed by weakness and spastic paralysis of the lower extremities with anesthesia up to the ninth dorsal segment of the spinal cord, exaggerated tendon reflexes, double Babinski sign and urinary incontinence Spinal puncture showed a partial block A coccidioidal granuloma, extradural, was found on operation at the level of the sixth vertebra The patient recovered completely from the paraplegia, and there was no recurrence eight months later Histologically, the growth resembled tuberculous granulation tissue, and *Coccidioides immitis* was present, with numerous giant cells of the Langhans type In case 2, a man, aged 38, presented symptoms of tuberculous meningitis and infectious arthritis for about a year Several infected teeth, the appendix and the gallbladder were removed Shortly before death a quadraplegia developed which necropsy showed was due to a coccidioidal granuloma This was subdural and surrounded the cervical region of the spinal cord like a cuff, especially at the level of the third and fourth segments No apparent involvement of the cord itself was present but the pia was involved around the cervical cord, inferior surface of the cerebellum, pons and the Sylvian fissures

GEORGE B HASSIN

HODGKIN'S DISEASE IN A CHILD ELISE S L'ESPERANCE, J Immunol **18** 127, 1930

Chicken inoculations of Hodgkin's material again resulted in typical avian tuberculosis, and reinoculation from this into other chickens caused a more extensive tuberculosis with marked involvement of bones Cultures of material from a reinoculated chicken gave a pure growth of tubercle bacilli, culturally of avian type Treated guinea-pigs inoculated with the original material developed extensive lymphatic tuberculosis and cultures on egg mediums showed many of the characteristics of a growth of avian tubercle bacilli Subcutaneous inoculation of a rabbit with the original material caused no infection, as frequently happens with pure culture of avian tubercle bacilli

AUTHOR'S SUMMARY

A CASE OF PEL EBSTEIN'S SYNDROME OF TUBERCULOUS ORIGIN ELISE S L'ESPERANCE, J Immunol **18** 133, 1930

The observations in the present case are of value from two angles First, as offering evidence of the avian tuberculous nature of a condition which presents a histologic relationship to typical Hodgkin's disease, and secondly in indicating that in man as well as in lower animals, especially birds, avian infection may be exhibited in various pathologic lesions

AUTHOR'S SUMMARY

EXPERIMENTAL TYPHUS FEVER H A REIMANN, J Immunol **18** 153, H A REIMANN AND C J WU, ibid **18** 159, 1930

The administration of india ink, sodium chaulmoograte, trypan blue and collargol before the inoculation of typhus virus in guinea-pigs usually prolongs the incubation time and shortens or diminishes the febrile reaction of typhus fever The probable explanation of the results is discussed Typhus fever in guinea-

pigs, rabbits and monkeys vaccinated with typhoid bacilli had no influence on the Widal reaction in these animals Typhus fever had no influence on pneumococcus agglutinins or immunity in vaccinated or normal guinea-pigs

AUTHORS' SUMMARY

COWS INFECTED WITH STREPTOCOCCUS EPIDEMICUS (DAVIS) W D FROST, R C THOMAS, MILDRED GUMM and F B HADLEY, J Infect Dis **46** 240, 1930

Seventeen cows are reported in this paper which were shedding in their milk *Streptococcus epidemicus* Davis Two of them were associated with an epidemic of septic sore throat The other fifteen cows were giving milk which was mixed with a considerable quantity of other milk and used as food Eight of these cows were found, during the course of four years, in certified herds of approximately 1,200 cows, which have been regularly tested at monthly intervals The other seven were accidentally discovered in small herds Our work would indicate that cows infected with *Streptococcus epidemicus* are rather generally and widely distributed, and that this streptococcus undoubtedly occurs quite generally and frequently in milk used for direct consumption, as well as that which is used for cheese and butter making without producing disease The infection of cattle with this human type of streptococcus apparently begins as a mild disease, which may become very severe or apparently continue a mild course There is a tendency for the infected portions of the udder to lose their milk secreting function In the group of mild cases to which most of our cows belong, there is little or no change from the normal in either the udder or the milk, although *Streptococcus epidemicus* may be shed in large numbers Of the thirteen cows in which the extent of the infection was determined, seven cows, 53 per cent, were infected in only one quarter, four cows, 31 per cent, were infected in two quarters, and two cows, 16 per cent, were infected in three quarters, although the infection in the different quarters did not always occur simultaneously The strains of *Streptococcus epidemicus* are apparently all virulent and are identical with those strains isolated from epidemics from either man or cow

AUTHORS' SUMMARY

DISSOCIATION OF ORGANISM RESEMBLING BACILLUS VULGATUS JOEL G WAHLIN, J Infect Dis **46** 253, 1930

An organism resembling *B vulgatus* morphologically and culturally has been studied This organism undergoes spontaneous dissociation The tendency to dissociate is not readily destroyed and is transmitted in the spore Two variant types have been isolated which differ morphologically and culturally but not biochemically, so far as demonstrated

AUTHOR'S SUMMARY

ENDEMIC TYPHUS OF THE SOUTHEASTERN UNITED STATES (THE REACTION OF THE WHITE RAT) KENNETH F MAXCY, Pub Health Rep **44** 1935, 1929

The observations are interpreted, therefore, as indicating that the temperature rise which occurred in rats from three to six days after intraperitoneal injection of tissues containing the Wilmington virus, were due, at least in part, to the virus itself Subsequent to this time, and quite regularly up to the thirteenth day, although the animal was afebrile and gave no outward evidence of infection, the virus was present and widely distributed in his body It was demonstrated to be still present in the brain as late as the twentieth day after inoculation The fever curve in rats, therefore, does not afford an indication of the course of the infection such as is usually the case in guinea-pigs and monkeys The infection in the rat was, except for a brief period at the time of onset, afebrile and inapparent

During this same brief febrile period at the beginning of the infection, it was found that the cells lining the tunica vaginalis were being extensively invaded

with the minute, Rickettsia-like micro-organisms which have been demonstrated to be associated with the virus These were at first almost entirely intracellular and apparently multiplying rapidly After a day or two, however, they were largely extracellular Thereafter, they disappeared entirely from this location

It seems not unlikely that the febrile reaction may have been in part associated with this rapid multiplication of the virus in the tunica After this local reaction had subsided and the virus had become generally distributed in the various tissues, the fever disappeared and the infection ran an inapparent course

These studies have shown that the white rat is a susceptible host to the Wilmington strain of typhus from the southeastern United States, and affords a particularly favorable species in which to study the Rickettsia-like micro-organisms

AUTHOR'S SUMMARY

VIRUS III IN TISSUE CULTURES C H ANDREWS, Brit J Exper Path **10** 273, 1929

Virus III has been carried on in twenty-three serial in vitro cultures of rabbit testis in rabbit serum or plasma, it appears to have multiplied in vitro at least 8 by 10^{27} times The conditions under which inclusion bodies form in such cultures have been further studied Virus III will not survive nor form inclusions in cultures of immune testis in immune serum or plasma Virus III will not survive nor form inclusions in cultures of normal testis in immune serum or plasma, provided that the immune fluid is added to the tissue in the culture before the virus Virus III will survive and form inclusions in cultures of immune testis in normal serum or plasma, particularly if the immune tissues are subjected to a brief preliminary soaking in Tyrode's solution If virus and tissue are incubated together for a short time before immune serum or plasma is added to culture, the virus can infect the cells and form inclusions, despite the presence of antibody in the fluid bathing the cell Experiments are described which seem to indicate that Virus III can infect cells within ten minutes at 37 C, but that it cannot do so even after five hours at 6 or —2 5 C

AUTHOR'S SUMMARY

EXPERIMENTAL BRUCELLA ABORTUS INFECTION IN MAN P MORALES OTERO, Porto Rico Rev Pub Health & Trop Med **5** 144, 1929

Of five normal persons fed *Brucella* cultures in milk, two developed fever-like undulant fever In these two cases the cultures introduced were of the porcine variety, the blood yielded cultures of this strain on the fifth and seventh day of disease respectively

THE ETIOLOGY OF SEROUS EFFUSION IN ARTIFICIAL PNEUMOTHORAX W STOBIE, Tubercle **11** 253, 1930

From the literature serous effusions in artificial pneumothorax may be caused by the local anesthetic, the cold air, too rapid filling, irritation of the gas, too much gas, pressure on the pulmonary vessels at the root of the lung, intercurrent diseases, the introduction of minute portions of the tissues through which the needle has passed, overexertion, menstruation, injury of the visceral pleura, stage of the disease, separation of adhesions and so on, while on the opposite side it is generally agreed that age, sex, type of disease and resistance have little or nothing to do with the onset of an effusion Seasonal incidence has little or no effect on the number of cases There is one common factor, viz, the separation of the pleural surfaces by the inflowing gas, and the one outstanding feature in those in which fluid developed was the presence of adhesions, generally in the upper part of the lung Extension of the disease in the other lung sooner or later results in hematogenous or other methods of spread and greater likeliness to effusion

H J CORPER

GLANDERS OF THE LUNGS SIMULATING PULMONARY TUBERCULOSIS E H A PASK, Tubercle **11** 257, 1930

Glanders of the lungs is a rare disease and is usually acute and rapidly fatal, being part of a general septicemia The case reported was of a more chronic type, closely simulating pulmonary tuberculosis with death six months after the onset of the symptoms in the chest The patient was a man, aged 35 The sputum was negative for tubercle bacilli, but glanders developed in the guinea-pigs

H J CORPER

A CASE OF HERPETIC URETHRITIS PAUL DURAND and R DELEUIL, Arch Inst Pasteur de Tunis **19** 36, 1930

Urethritis was noted in a young man four or five days following several days of chills and fever, during which herpetic vesicles had appeared on the lips A small ulcer appeared, not preceded by any noted vesicular stage, which was accompanied by a tingling sensation, exaggerated at the time of micturition Bacteriologic examination gave entirely negative results Following a strong and painful pressure on the urethra, a large drop of grayish, viscous fluid was secured, containing numerous polymorphonuclear and endothelial cells, but no organisms Inoculation by scarification of the cornea of a rabbit was followed progressively by inflammation of the iris, fever, intense keratitis and chemosis, paraplegia and finally a rapid drop in temperature to 30 C (86 F) and death on the twelfth day Cultures were negative The brain was preserved in 50 per cent glycerin Subsequent serial passages through rabbits by intracerebral inoculation of glycerin brain suspensions produced the typical syndrome of encephalitis apparently due to a very potent strain of virus

M S MARSHALL

THE LOCAL NEUTRALIZATION OF RABIES VIRUS CLAUDIO FERMI, Zentralbl f Bakteriol **112** 73, 1929

The dissemination of rabies virus subsequent to its subcutaneous injection can be prevented in rats if solutions of 1 10,000 mercuric chloride, 1 1,000 silver nitrate, 2 per cent phenol or 1 200 methylene blue (methylthionine chloride, U S P) are injected immediately around the point of injection After fifteen minutes, however, such injections are of no avail The absorption of the virus through the nasal mucosa and the rectum is so rapid that in fifteen minutes no method will prevent rabies Amputation of the tail, even five hours after inoculation, was successful, as was also local passive hyperemia by means of elastic binders, which saved all of the animals tested, even when employed four hours after infection

PAUL R CANNON

EXPERIMENTAL MEASLES IN RABBITS P BELIKOFF, P P DWIJKOFF AND E TRUSCHINA, Zentralbl f Bakteriol **112** 78, 1929

The authors injected rabbits with blood and filtrates of the pharyngeal mucosa from patients ill with measles, and in some instances fever, slight leukopenia and mucosal and skin reactions appeared Similar results were also observed subsequent to the injection of a pure culture of a diplococcus recovered from patients with measles Inflammation was found around the blood vessels with proliferation of the adventitial elements, frequently mixed with polymorphonuclear leukocytes These changes were most marked in the skin, to a lesser degree in the larynx and trachea with, at times, hemorrhages in the mucosa These changes were not observed following the injection of blood and mucosal filtrates from patients free from measles Several photographs illustrate the changes

PAUL R CANNON

THE NATURE OF THE ANTIVIRUS OF BESREDKA H ALDERSHOFF, Zentralbl f Bakteriol **112** 273, 1929

As a result of studies in vitro on Besredka's "antivirus," Aldershoff concludes that this is not specific and is not even dependent on growth of the virus itself, as the same effect can be demonstrated after several filtrations of uninoculated broth through Chamberland and E K filters The degree of inhibition varies directly with the number of times the broth has been filtered This inhibiting substance is thermostable and is not the result of the removal of colloidal substances, fat, sugar or salts The author thinks it probable that repeated filtrations lead to a colloidal-chemical change in part of the protein in the broth so that it is not available for bacterial growth and even inhibits growth

PAUL R CANNON

Immunology

TUBERCULO-ALLERGY IN SKIN TRANSPLANTS A H W CAULFEILD, M H BROWN and WILLIAM MAGNER, Am Rev Tuberc **21** 127, 1930

The results obtained indicate that in each experiment marked differences are manifest in the reactions that take place in the immune and normal grafts to tubercle bacilli and to a less extent to tuberculin, and that the usual reaction of the immune graft approximates that which takes place in the immune skin rather than in the normal skin and is demonstrable in three ways 1 Following injection, tubercle bacilli are immobilized in the immune graft and their extension throughout the lymphatic system is delayed in a manner comparable to what takes place in the immune animal 2 Following the injection of bacilli into immune grafts the usual reaction is relatively rapid and intense and more closely resembles that induced in the skin of the immune animal than that in the normal skin or graft 3 Evidence of persisting sensitization of the immune graft to tuberculin was found in that gross swelling and microscopic infiltration were present The difference between reactions so obtained in the immune and normal grafts has not been as constant or as marked in degree as that which occurred with the use of tubercle bacilli

H J CORPER

THE INHIBITIVE REACTION OF CAULFEILD A C NORWICH, M F MACLENNAN and M F BASSINGTHWAIGHTE, Am Rev Tuberc **21** 142, 1930

The inhibitive reaction of tuberculosis (*J M Research* **24** 100, 1911, and *Am Rev Tuberc* **11** 508, 1925) is specific for tuberculous serum and appears more frequently in the tuberculous than in the supposedly nontuberculous The reaction is a valuable aid, occasionally in diagnosis but more frequently in prognosis The test is a type of complement fixation in which the amount of hemolysis is used as an index of the degree of reaction, that is, the amount of hemolysis as indicative of the amount of "inhibitin" present in the serum (The original technic is given in *Proc Roy Soc*, Sec B, 1911, vol 84) The test brings together a lipoidal tuberculo-antigen, the inactivated serum to be tested, complement, and, after an interval, sensitized corpuscles The anticomplementary strengths of the antigen used bar it from being regarded as a modification of the tuberculo-complement-fixation The test is done by adding serum to three multiple dilutions of tuberculo-lipoidal antigen (accurately titrated as to anticomplementary strength), and the end-results show as degrees of hemolysis or no hemolysis The hemolytic system is guinea-pig complement, sheep's corpuscles and antisheep rabbit serum for hemolysin The serums to be tested are inactivated by immersion in a water-bath one-half hour at 56 C

H J CORPER

THE CHEMICAL COMPOSITION OF THE ACTIVE PRINCIPLE OF TUBERCULIN FLORENCE B SEIBERT, Am Rev Tuberc **21** 370, 1930

It is possible to produce antibodies to the proteins from acid-fast bacteria Precipitins were produced in normal guinea-pigs and rabbits by immunizing them with small doses (about the same as of other proteins) of the proteins obtained from culture liquids of human, bovine and avian tubercle bacilli and the timothy bacillus The precipitin test can serve as a reliable diagnostic method for tuberculosis in the guinea-pig, since no normal unusued guinea-pig serum contains precipitins for the tuberculin protein, and practically all tuberculous serums do contain them The precipitin test is not an adequate test for diagnosing human tuberculosis, only six serums out of fifty-one from cases of active tuberculosis showed precipitins By means of cross precipitation reactions it is possible to distinguish easily between the proteins from the human, bovine and avian tubercle bacilli and the timothy bacillus

H J CORPER

SENSITIZATION IN EXPERIMENTAL TUBERCULOSIS RUBY M BOHART, Am Rev Tuberc **21** 383, 1930

Tubercle bacillus filtrates, such as the tuberculins, and proteins derived from them do not cause sensitization in guinea-pigs when tested by the old tuberculin intracutaneous skin reaction Killed tubercle bacilli are effective sensitizers under certain conditions Light-killed tubercle bacilli were found to be less efficient than heat-killed bacilli, while bacilli killed by certain chemicals, such as carbol fuchsin or ether, were the most efficient

H J CORPER

THE IMMUNOLOGICAL SIGNIFICANCE OF COLOSTRUM THEOBALD SMITH, J Exper Med **51** 473, 1930

The protective antibody content of normal cow serum is below that of colostrum of the same animal The method used does not permit the titration of the actual amount of the antibody in serum Quantities up to 2 cc have no protective effect The same limitations apply to the titration of milk owing to the introduction of large quantities of foreign protein into the peritoneal cavity of the guinea-pig When cows were immunized and a serum of high titer obtained, the antibodies in the milk of such cows rose to within the range of the method of testing The relation of the protective capacity of serum to that of milk was approximately 1/120 and 1/40 in the two animals These figures do not differ much from those obtained by early investigators titrating the antitoxic content of serum and milk of animals undergoing immunization with diphtheria toxin In the two experiments on calves, 2¼ and 18 days old, respectively, fed a highly protective serum, no increase in agglutinins or protective antibodies could be demonstrated The postponement of colostrum to the twelfth and eighteenth hour, respectively, did not prevent normal growth

AUTHOR'S SUMMARY

THE IMMUNOLOGICAL SIGNIFICANCE OF COLOSTRUM THEOBALD SMITH AND RALPH B LITTLE, J Exper Med **51** 483, 1930

Under certain safeguards, such as isolation, calves from a large dairy herd have been raised by feeding normal and immune cow serum in place of colostrum The losses were about one of ten in the later experiments This outcome may probably be improved by the subcutaneous injection of serum during the first day This loss may be no greater than that under ordinary conditions, since sporadic deaths among calves are not infrequent However, no satisfactory statistics are available for comparison with results as given

AUTHORS' SUMMARY

MODE OF ACTION OF A VIRICIDAL SERUM S P BEDSON, Brit J Exper Path **10** 364, 1929

The experiments demonstrate that collodion particles are capable of absorbing either herpes virus or herpes antibody It is further shown that there is an increased avidity for the virus possessed by the particles which have been sensitized with herpes antiserum The antibody is not liberated when the sensitized particles are soaked in phosphate buffer or normal guinea-pig pad suspension Hence, it is argued that its liberation in the presence of virus would mean a specific and powerful attraction of virus for antibody Therefore, it is concluded that herpes virus and antibody unite in vitro

J N PATTERSON

IMMUNITY TO HAEMOLYTIC STREPTOCOCCI RONALD HARE, Brit J Exper Path **10** 375, 1929

Hemolytic streptococci from broth cultures near the logarithmic phase are better fitted to withstand the bactericidal power of normal human defibrinated blood than those from cultures in the phase of decline This is probably due, in part, to the ability of streptococci from cultures in the logarithmic phase to multiply faster in the serum moiety of the blood than those from cultures in the phase of decline and, in part, to the assumption by growing streptococci of some degree of resistance to phagocytosis and its disappearance when the cocci become senescent The importance of this principle in experimental work on immunity and also in the epidemiology of streptococcal infections is commented on

AUTHOR'S SUMMARY

ELECTRIC CHARGE IN ITS RELATION TO COMPLEMENT FIXATION H C BROWN and J C BROOM, Brit J Exper Path **10** 387, 1929

Under normal conditions the various components of complement-fixation reactions all carry negative charges The effect of electrolytes in suitable concentrations is to lower the negative charge of the antigen-antibody complex to a degree dependent on the valency of the cation and the concentration of the immune serum Electrolytes with polyvalent anions inhibit hemolysis because they maintain the negative charge of the sensitized cells We are of the opinion that the reduction of charge of the antigen-antibody complex is an essential preliminary in the process of complement-fixation

AUTHORS' SUMMARY

COMPLEMENT-FIXATION WITH FILTERABLE VIRUSES S P BEDSON and J O W BLAND, Brit J Exper Path **10** 393, 1929

Specific complement-fixation with the viruses of vaccinia and herpes can be obtained with hyperimmune serums prepared in the guinea-pig A prolonged period of fixation is necessary for the satisfactory demonstration of this reaction Evidence has been obtained that bacterial contamination of the virus antigens plays no part in this reaction Some evidence has been produced to show that zoster vesicle fluid gives specific fixation in the presence of zoster convalescent serums

The evidence adduced is further proof that virus and antibody unite outside the animal body

AUTHORS' SUMMARY

THE ACTION OF CERTAIN DYES ON THE BACTERICIDAL ACTIVITY OF NORMAL SERUM AND ON HEMOLYTIC COMPLEMENT J GORDON, J Path & Bact **33** 47, 1930

Congo red and similar dyes prevent the bactericidal and hemolytic activities of serum This is not associated with destruction of complement or of immune body Sensitization of red blood corpuscles takes place in the presence of congo red The addition of magnesium sulphate increases the action of this dye Congo red

inhibits bactericidal activity in small concentrations than those in which it inhibits hemolytic activity Charcoal removes congo red from an inactive mixture of complement-containing serum and dye, restoring to its hemolytic activity

AUTHOR'S SUMMARY

THE SPECIFICITY OF ACTIVE IMMUNITY AGAINST SNAKE VENOMS C H KELLAWAY, J Path & Bact **33** 157, 1930

The specificity of active immunity to snake venoms, like that of passive immunity, depends on two factors the zoological relationship of the reptiles yielding the venoms, and the "toxic constitution" of the venoms themselves In active immunity against snake venoms, specificity appears to be somewhat less strict than in passive protection with univalent serums, active protection against a single venom also provides protection, in some cases by no means inconsiderable, against the venoms of closely related species Close species relationship between the reptile supplying the venom used for immunization and that whose venom is used for testing appears to be even more important in determining nonspecific protection than close similarity between the venoms in regard to their toxic behavior

AUTHOR'S SUMMARY

TISSUE-CULTURE IN THE STUDY OF IMMUNITY TO HERPES C H ANDREWES, J Path & Bact **33** 301, 1930

Herpes virus will multiply in "tissue-cultures" of the testis of a rabbit in dilute rabbit serum, this virus has been carried on in twenty-three serial cultures Even though cultivated in testis, it has not changed its neurotropic properties during the course of eighteen passages Herpes virus will regularly form in "tissue cultures" inclusion bodies like those that it forms in the testis and other organs of a living rabbit Herpes virus will not multiply, or form inclusions in "tissue cultures" in the presence of immune serum, provided that this is added to the culture before the virus, or together with it Antibodies develop readily in rabbits infected with herpes Hyperimmunization is not necessary for their demonstration Herpes virus will grow and form inclusions in cultures of immune testis in normal serum Herpes virus can infect normal tissues in the absence of imune serum within half an hour at 17 5 C or 37 C , it can then grow and form inclusions in spite of the subsequent addition of immune serum It can also infect immune tissues very quickly (forty-five minutes at 37 C) A strain of herpes passaged in rabbits for five years will infect cultures of guinea-pig tissues, apparently as readily as those of the rabbit Cross-immunity experiments in tissue cultures show that herpes and virus III are immunologically distinct

AUTHOR'S SUMMARY

A CRITICAL REVIEW OF THE SCHICK TEST AND ITS APPLICATION S F DUDLEY, Quart J Med **22** 321, 1929

This article is a scholarly and concise review of the Schick test, giving a historical outline, technic and interpretation It is divided into twenty-six small chapters, and an extensive bibliography is attached

N ENZER

THE BLOOD GROUPS IN THE DIFFERENT RACES IN TUNIS LOUIS CAILLON and CAMILLE DISDIER, Arch Inst Pasteur de Tunis **19** 41, 1930

A significant difference in the distribution of different blood groups among the inhibitants of Tunis is noted which "confirms what is already known regarding the history of the mixture of races" living in this region A succeeding paper (p 50) by the same authors considers more in detail the blood groups of the Berbers, a more strictly localized group

EXPERIENCES WITH DIPHTHERIA ANATOXIN MARCELLE NICOLLE, Arch Inst Pasteur de Tunis **19** 55, 1930

Over a period of eighteen months, 907 persons were given injections of diphtheria anatoxin or toxid, 789 of whom received the full three injections, 0 5, 1 0, and 1 5 cc, spaced respectively at three week and fifteen day intervals The age group ranged from 1 to 37 years, the younger ages predominating Following the first injection, low fevers were noted in approximately 1 per cent of the cases, lasting a maximum of three days Reactions were more marked following the second injection, occurring in some 4 per cent of the persons, with higher temperatures No reactions were noted after the third injection Reactions in children under 5 years of age were not observed

M S MARSHALL

EXPERIMENTAL ALLERGIC ARTHRITIS F KLINGE, Beitr z path Anat u z allg Path **83** 185, 1929

In previous work of the author, the injection of horse serum into the joint cavity of rabbits sensitized by the subcutaneous injection of horse serum led to acute, purulent and destructive inflammation of the joint He believed that by modifications of the experimental procedure it should be possible to bring about changes in the joints comparable with those of rheumatic polyarthritis The present report relates to such experiments conducted during the course of two years The procedures were varied in a number of ways, and the resulting process in the joint tissues was studied microscopically The rabbit was the animal used A single injection of from 1 to 2 cc of sterile horse serum into the knee joint of the normal rabbit caused only slight hyperemia of the synovial membrane, in which a few leukocytes were sometimes found microscopically The injection of heterologous serum into the joints of animals sensitized to horse serum also caused little reaction, but somewhat more than that with the previous procedure If the animals were sensitized during the course of four weeks by repeated subcutaneous injections and then received a single injection of horse serum into the joint, there resulted the acute purulent destructive arthritis noted in the earlier series of experiments In a fourth series, the animals received two sensitizing subcutaneous injections of horse serum separated by a three day interval Four weeks later, each animal received into the joint the first of a series of five injections distributed over a period of about four months There resulted a productive monocytic and histiocytic inflammation of the synovia, with subendothelial hyaline necrosis that led to ulceration Areas of waxy necrosis and focal areas composed of large mononuclear cells were present in the skeletal muscles Focal subendothelial necroses occurred in the walls of the arteries and veins The heart valves were thickened by edematous young connective tissue The heart muscle contained periarterial nodules of large mononuclear cells and larger areas of muscle cell necrosis surrounded by cellular infiltration Sensitization by five injections of horse serum, followed by two injections into the joint, led to a similar reaction in the joint and to necrosis and the formation of nodules or large cells in the periarticular muscles Sensitization with a single dose of 2 cc of serum, followed by nine intra-articular injections of 0 25 cc serum in the course of five months led to destructive joint lesions, the progress of which could be followed roentgenologically for long periods after the last injection Of two animals that received repeated small subcutaneous injections of serum during the course of six months, one developed a polyarthritis that involved most of the large and many of the small joints Klinge concludes that by the proper gradation of sensitizing and intra-articular injections of horse serum it is possible to cause changes in the joints, perivascular tissues and muscle that have great similarity to those of human rheumatic arthritis

O T SCHULTZ

THE NATURE OF IMMUNITY IN RELAPSING FEVER W K BELEZKI and R M UMANSKAJA, Virchows Arch f path Anat **272** 305, 1929

In four cases of relapsing fever in human beings the inner organs were examined with a special silver method In all organs many more spirochetes, in more or less disintegrated condition, were found in the blood than within cells Phagocytosis played no important rôle Granulocytes did not contain spirochetes, as far as there was phagocytosis it was done by histiocytes The organs that have many reticulo-endothelial cells contained the largest number of spirochetes (spleen, suprarenal glands, liver) In the central nervous system and its vessels nearly all the spirochetes were unaltered Phagocytosis was by neuroglia cells and by Hortega cells These results correspond to those in experimental relapsing fever in mice But in the mouse phagocytosis is still more scanty, and the spirochetes are more localized in the tissue than in the vessels

ALFRED PLAUT

THE HEREDITARY TRANSMISSION OF ACQUIRED IMMUNITY THROUGH THE GERM PLASM OTTO HERRMANN, Zentralbl f Bakteriol (Abt 1) **112** 460, 1929

The author finds that the acquired immunity in rabbits to rabies virus is transmitted to the young and may persist for six to eight months This immunity has been transmitted by females even when the pregnancy began from six to nine months after the termination of the immunization The immunity has also been transmitted by the males as long as from one to seven and one-half months after the termination of the immunization When both parents are immune a greater proportion of the young are immune Apparently the immunity may even be transmitted to the third generation, although more animals must be studied to confirm this point

PAUL R CANNON

THE KAHN REACTION IN EXPERIMENTAL SYPHILIS IN RABBITS T SAITO, Ztschr f Hyg u Infektionskr **110** 603, 1929

Saito reports that in normal rabbits the Kahn reaction with dilute serum is always negative while in animals infected with syphilis the result is distinctly positive

W OPHULS

HEMOGLOBINURIA IN MALARIA M K EBERT, Ztschr f Immunitatsforsch u exper Therap **65** 161, 1930

The degree of hemolysis has no relation to any of the blood groups

PHYSICOCHEMICAL PROPERTIES OF ISO-AGGLUTININS AND THE MECHANISM OF ISOHEMAGGLUTINATION VERA SCHRODER, Ztschr f Immunitatsforsch u exper Therap **65** 81, 1930

This is an effort to explain isohemagglutination on the basis of electrochemical and colloidochemical processes

THE FORMATION OF ANTIBODIES IN RABBITS PREVIOUSLY INFLUENCED BY THE INJECTION OF SERUM GLOBIN P VON GARA, Ztschr f Immunitatsforsch u exper Therap **65** 176, 1930

Rabbits, in which globulin fractions of immune serum have been injected about five or six weeks before the introduction of antigen—typhoid bacilli, blood corpuscles and foreign protein—responded with a much more liberal production of free specific antibodies than rabbits not subjected to any preliminary treatment

ORAL TYPHOID AND PARATYPHOID INOCULATION O OTTOLENGHI and G BROTZU, Ztschr f Immunitatsforsch u exper Therap **65** 195, 1930

The value of oral antityphoid inoculation in human beings is not established, but the method is not without some action Rabbits are immunized easily by mouth

against fatal typhoid and paratyphoid infections, the immunity reaches its height in about two weeks at the same time as agglutinins and other antibodies in the blood are at the climax Claims to the contrary notwithstanding, oral inoculation calls forth the new formation of antibodies—the organism as a whole reacts

INTRACUTANEOUS TEST FOR MALARIA O HERRMANN and M LIFSCHITZ, Ztschr f Immunitatsforsch u exper Therap **65** 240, 1930

Using an antigen, extracts of clotted blood from malarial patients, cutaneous reactions were obtained in most of the malarial patients that were tested, but not in healthy persons or patients suffering from other diseases than malaria

QUANTITATIVE STUDIES OF HUMAN ISO-AGGLUTININS K KETTEL and O THOMSEN, Ztschr f Immunitatsforsch u exper Therap **65** 245, 1930

In groups O and B the curves of the agglutinins for Groups A are practically identical In group O the agglutinin for group A has a higher titer than the agglutinin for group B Other details must be sought in the original article

INFLUENCE OF SPLENECTOMY IN TRYPANSOMIASIS IN DOGS O NIESCHULZ and F K WAWO-ROENTOE, Ztschr f Immunitatsforsch u exper Therap **65** 312, 1930

Splenectomy was without effect on the disease in dogs infected with *Schizotrypanum cruzi,* but in dogs infected with *Trypansoma gambiense,* splenectomy deprived the animal of its main protection against the infection

COMPLEMENT IN RELATION TO THE RETICULO-ENDOTHELIAL SYSTEM J LANDSBERGER, Ztschr f Immunitatsforsch u exper Therap **65** 385, 1930

No relation could be established between the content of complement in the serum and the functional variations on part of the reticulo-endothelial system

GROUP SPECIFIC ANTIGENS IN HUMAN ORGANS I L KRITSCHEWSKI and R E MESSIK, Ztschr f Immunitatsforsch u exper Therap **65** 405, 1930

Alcoholic extracts of the brain of persons belonging to groups II and III contain group antigens A and B These antigens are not the same as the Forssman antigen and their lipoid nature is not established

ISOHEMOPSONINS P L RUBINSTEIN, Ztschr f Immunitatsforsch u exper Therap **65** 431, 1930

Human serum contains in addition to iso-agglutinin also isohemopsonin (isohemotropin)

Tumors

PRIMARY CARCINOMA OF VAGINA FOLLOWING BALDWIN RECONSTRUCTION OPERATION FOR CONGENITAL ABSENCE OF VAGINA R N RITCHIE, Am J Obst & Gynec **18** 794, 1929

A woman, aged 26, who complained of pelvic pain and vaginal discharge was found to have an adenocarcinoma of the posterior vaginal wall which was in communication with the rectum through a small incision The external genitalia were normal, but investigation revealed that at the age of 13 years the patient had had an artificial vagina made from a loop of bowel due to congenital absence of a vagina

GEORGE RUKSTINAT

SANGUINEOUS DISCHARGE FROM THE NIPPLE AND ITS RELATION TO CARCINOMA F E ADAIR, Ann Surg **91** 197, 1930

Forty-seven and two-tenths per cent of 108 cases having a sanguineous discharge from the nipple were found to be malignant, which concurs with the previous reports of Miller, Judd and Lewis It is emphasized that microscopic examination is essential in concluding that the discharge is really blood Usually intracanalicular papilloma results in a serous or blood-stained discharge, whereas carcinoma causes the appearance of frank blood, and chronic mastitis produces a chocolate, green or yellow discharge In this group it was noted that papillary cysto-adenoma was frequently a precursor of adenocarcinoma

RICHARD A LIFVENDAHL

MALIGNANT TUMORS OF THE NAIL BED R H JAFFÉ, Surg Gynec & Obst **50** 847, 1930

In persistent ulcerative lesions of the nail bed, melanoblastoma and squamous cell carcinoma must be considered Although the lesions are rare, the author reports the pigmented tumor on the great toe of a woman, aged 69 years, who presented an oval ulcer with sharp, indented, and occasionally undermined edges and a gray purple granulated base extending down close to the bone, near the posterior border there was a thin brown line due to intracellular accumulations of melanotic pigment Squamous cell carcinoma is exemplified by a second case in which a raised ulcer with a firm, dry, scaling, and waxy-appearing floor replaced the nail and extended over the anterior upper part of the toe Benign tumors do not break through the nail

RICHARD A LIFVENDAHL

OAT-CELL TUMORS OF MEDIASTINAL GLANDS J B DUGUID AND A M KENNEDY, J Path & Bact **33** 93, 1930

Barnard's suggestion, that the "oat-cell sarcoma" of the posterior mediastinum is a medullary carcinoma of the bronchus, is recalled A tumor of the thymus and a tumor of the mediastinal lymph glands, both showing oat cell features, are reported The conclusion is that oat cell forms in a mediastinal tumor must not always be interpreted as indications of a bronchial origin

AUTHORS' SUMMARY

PRIMARY MALIGNANT INTRATHORACIC TUMORS JAMES MAXWELL, J Path & Bact **33** 233, 1930

A series of 239 cases of primary malignant intrathoracic tumors is discussed, and the histologic appearances are recorded in 135 of these cases Primary bronchial carcinoma was found to occur in 184 cases The chief morbid anatomic observations are described, and the microscopic observations in 111 cases are discussed, reasons are given for accepting all of these cases as carcinomas in two main groups, an obvious columnar cell group with a tendency to squamous metaplasia and a small oval cell group which is slightly commoner The oval celled carcinomas are discussed in detail, and reasons are given for the conclusion that they spring from the basal layer of the bronchial epithelium It has not been shown that any of the tumors in this series arose directly in the epithelial lining of the pulmonary alveoli The mediastinal tumors are shown to be a heterogeneous group, some being the result of infiltration or metastasis from a small primary bronchial focus, others being accepted as sarcomas arising in the mediastinal glands No conclusive evidence could be found to show that any arose within the thymic remnants Primary pleural tumors are shown to be a rare but well-defined group and are briefly discussed

AUTHOR'S SUMMARY

AN EMBRYONIC TUMOR OF THE LIVER CONTAINING STRIATED MUSCLE H L SHEEHAN, J Path & Bact **33** 251, 1930

In a young girl the liver contained a number of papilliferous cysts lined by bile duct epithelium The substance of the papillae consisted of undifferentiated cells These cells in one cyst became malignant and formed a large tumor, destroying every other tissue except bile duct epithelium and showing a tendency to intravascular growth but not to metastasis outside the liver They also differentiated into four types of more mature cells, including striated muscle They are considered to be rest cells of mesoblast

AUTHOR'S SUMMARY

MULTIPLE MALIGNANT NEOPLASMS JOHN W ORR, J Path & Bact **33** 283, 1930

Three cases in which two independent carcinomas were present are described A study has been made of the frequency of the occurrence of multiple malignant neoplasms The view is expressed that there is no etiologic relationship between such tumors, and that they occur purely as the result of coincidence

AUTHOR'S SUMMARY

SPINAL METASTASES OF ASTROCYTOMA FIBRILLARE DOROTHY S RUSSELL and HUGH CAIRNS, J Path & Bact **33** 383, 1930

The case described here is one of astrocytoma fibrillare of the right optic thalamus The tumor gave rise to no serious symptoms until four months before death, when hydrocephalus set in and advanced rapidly This hydrocephalus was due to the obstruction of the aqueduct of Sylvius The tumor was firm, and in its edge were numerous calcified areas which in life had revealed the outline of the tumor in x-ray films On histologic examination, the tumor was found to be composed entirely of fibrillary astrocytes It had invaded the subarachnoid space by way of the right pulvinar Miliary metastatic nodules were found in the subarachnoid space over the superior medullary velum and in the subarachnoid space of the spinal cord These metastases were entirely composed of fibrillary astrocytes, and thus presented the same degree of differentiation as did the primary tumor, they gave rise to no recognizable clinical symptoms

AUTHORS' SUMMARY

A TRANSPLANTABLE MELANOMA OF THE MOUSE HAROLD E HARDING and R D PASSEY, J Path & Bact **33** 417, 1930

This melanoma behaves like any other transplantable mouse tumor, it grows progressively on grafting into other mice, it recurs after an incomplete operation for removal, it is invasive and sometimes gives rise to metastases A large proportion of the cells in the tumor are extraneous phagocytic cells full of melanin

AUTHORS' SUMMARY

CONGENITAL MALIGNANT TUMOR OF THE LIVER (PLACENTAL TRANSMISSION) F P WEBER, E SCHWARZ and R HELLENSCHMIED, Munchen med Wchnschr **77** 624, 1930

A woman with a malignant melanoma was delivered by cesarean section at the thirty-eighth week of a seemingly healthy male child The placenta contained many tumor nodules The mother died three months later The child had an enlarged nodular liver at 8 months of age and died at 11 months There were found melanotic tumors in the liver and lymph nodes

EDWIN F HIRSCH

ON HETEROGENEOUS NEOPLASTIC IMPLANTATION G DE GAETANI, Tumori 4 1, 1930

The author has studied various factors influencing resistance and receptivity toward the subcutaneous and intracerebral inoculation of an adenocarcinoma of the mouse in rats by means of splenectomy, blocking of the reticulo-endothelial system, irradiation, and splenectomy plus injection of testicular extract From the macroscopic, histologic and biologic results, as well as from the control of the lytic power of the serum, he concludes that the oncolytic power first exercises its injurious influence on the inoculated heterologous tumor, and that a decrease of oncolytic power favors the attachment of the tumor, in the second place, the unreceptivity of a different species, as an expression of a different biochemical condition of the host comes into play and provokes arrest of growth, involution and necrosis of the heterologous tumor The oncolytic power can be decreased by splenectomy, while it remains high in spite of irradiation in increasing doses and in spite of blocking of the reticulo-endothelial system

W OPHULS

THE RESULTS OF A STUDY OF HOSPITAL STATISTICS OF TWENTY-FIVE YEARS IN REGARD TO THE AGE AT WHICH MALIGNANT TUMORS ARISE A BONANNO, Tumori 4 67, 1930

From the study of 5,344 cases of malignant tumors observed from 1901 to 1925 at the Mauritian Hospital in Turin, it appears that the greatest frequency of occurrence is in the age period from 40 to 50 However, in persons under 30 years of age there were observed 342 cases of malignant tumors In the last five year period there was observed, for women, a lowering of the level of age at which cancer is contracted Important also is the recognition of the different distribution of malignant tumors of certain organs in regard to age

AUTHOR S SUMMARY

Medicolegal Pathology

FATAL EMETINE POISONING, DUE TO CUMULATIVE ACTION, IN AMOEBIC DYSENTERY FRANK J LEIBLY, Am J M Sc **179** 834, 1930

Emetine is a protoplasmic poison acting on the host, as well as on the parasite, and there is no established course of treatment with this drug that can be accepted with impunity The minimal lethal dose of emetine has not been satisfactorily determined for man Conclusions drawn from laboratory animals are not applicable, owing to differences of species and of individual susceptibility Death due to the cumulative action of emetine can occur without the advent of sufficiently severe symptoms to warn the physician before the minimal lethal dose has been passed Cases of susceptibility to emetine cannot be recognized in advance, to prevent the occasional cases of fatal emetine poisoning, each patient must be considered as a possibly susceptible person Emetine in much less than the minimal lethal dose for man is amebacidal, and emetine in very small doses, with frequent and sufficiently long rest periods should be employed Failure on this basis to clear up the infection indicates emetine-resisting strains of amebas, and other forms of treatment must be devised The action of emetine on the human system is at the present time but poorly understood Neither is its action on amebas definitely known There is no known antidote for emetine poisoning

AUTHOR'S SUMMARY

USE OF DERMATOGRAMS IN LEGAL MEDICINE BETTMANN, Deutsche Ztschr f d ges gerichtl Med **15** 1, 1930

With a procedure similar to the dactylographic technic, one is able to secure exact copies of any area of the human skin during life and after death and to

study the changes of the cutaneous relief thus obtained under various circumstances With the aid of this method, it was found that the skin in various regions of the body shows certain characteristic patterns, and that one and the same skin area examined in different persons presents definite variations The changes in the dermatogram of the abdominal skin taken at various time intervals after death appear to be of particular interest, as they may indicate the time that has elapsed since death ensued The different kinds of scars can be studied with accuracy, and their individual characteristics can be observed Also, tattoo marks offer in the dermatogram certain peculiarities which can be easily analyzed and registered

E L MILOSLAVICH

VITAL REACTIONS OF WOUNDS WALCHER, Deutsche Ztschr f d ges gerichtl Med **15** 16, 1930

Agonal injuries, as well as those that rapidly lead to a lethal end, constantly show hemorrhages with or without fibrinous threads Stasis and a relative dilatation of the blood vessels are occasionally observed If life persists for fifteen minutes or more, activities of the leukocytes can be readily observed The longer the time between injury and death, the more pronounced are the actions of the leukocytes and the changes of the nuclei of the epidermis cells (traumatic necrosis) In two hours, the inflammatory processes commence to increase gradually and become more and more pronounced with the advance of time These reactions may be inhibited or nearly absent in instances of severe shock, in trauma of the brain and in old age Hemosiderin appears after nine days, and hematoidin crystals are formed after eleven days Similar reactions occur in new-born infants, with the exception that fibrin perhaps plays a smaller role than in adults Post-mortem and vital excoriations which do not show hemorrhagic suffusions cannot be differentiated grossly, but their character can be established microscopically The histologic examination of the lungs in cases of drowning may disclose a more or less marked leukocytosis in the blood vessels, erythrocytes (apparently escaping from the torn septums) within the alveoli and hemolysis Fibrinous exudation on the pleura or peritoneum following an injury, and development of pneumonic foci in instances of contusion of the lung, can be seen within several hours after the trauma

E L MILOSLAVICH

ANATOMIC CHANGES IN BRAINS OF NEW-BORN INFANTS PH SCHWARTZ, Deutsche Ztschr f d ges gerichtl Med **15** 58, 1930

More than fifty years ago, Virchow described "interstitial encephalitis" as a common cause of death in new-born and older infants This condition is characterized by a fatty degeneration of glia cells of the white matter of the cerebral hemispheres and of the corpus callosum These changes can be readily demonstrated in a frozen section with ordinary fat stains One can distinguish two types of cells, namely, star-shaped cellular elements containing fat globules and round-shaped cells loaded with fat droplets Both kinds of cells are declared to be pathologic, which is in contrast with the opinions of Merzbacher, Wohlwill, Ceelen and others Within these areas, one may notice disintegration of the nuclei of the glia cells, degenerative changes of the axis cylinders and also disturbances of the circulation, such as stasis and minute hemorrhages surrounding the capillaries and small veins These changes are commonly noted in stillborn infants and infants who died within the first four weeks after birth The gross picture is characterized by punctate or linear hemorrhages in the frontoparietal portion of the white matter expanding in radial fashion (fanlike) from the wall of the lateral ventricles Identical changes may be encountered on the cut surfaces of the occipital portion of the white matter

E L MILOSLAVICH

Technical

THE SEDIMENTATION RATE OF BLOOD IN OBSTRUCTIVE JAUNDICE R R LINTON, Ann Surg **91** 694, 1930

The sedimentation rate of the red blood cells is regarded as a more reliable test for the detection of a hemorrhagic tendency than any other method in cases of obstructive jaundice Based on seventeen cases, studied before and after operation, it is concluded that an increase in the rate of sedimentation, in the absence of fever, indicates a tendency to bleed

RICHARD A LIFVENDAHL

SPECIFIC GRAVITY OF URINE AS TEST OF RENAL FUNCTION F H LASHMET and L H NEWBURGH, J A M A **94** 1883, 1930

The determination of the specific gravity of the urine under properly standardized conditions detects a lowering of the functional power of the kidneys long before lowering is discernible by the phenolsulphonphthalein test or by the estimation of the nonprotein nitrogen of the blood

DIFFERENTIAL BLOOD CULTURES REUBEN OTTENBERG, J A M A **94** 1896, 1930

Differential blood cultures are simultaneous blood cultures taken from vessels in several different parts of the body By counting the number of colonies per cubic centimeter of blood in each vessel, it is hoped to establish from which region the bacteria are entering the blood

That the principle is correct is shown by a study of twenty cases of sinus thrombosis or phlebitis, proved at operation or at autopsy The principle can undoubtedly be applied to other regions of the body In a case of suspected sinus thrombosis the finding of a much greater number of bacteria in the blood of one internal jugular vein than in the other confirms the diagnosis But it is impossible from the count alone to tell on which side the thrombosis is located The finding of large but equal numbers of bacteria in the two internal jugular veins with a much smaller number in an arm or leg vein also confirms the diagnosis of sinus thrombosis Totally negative blood cultures from all three veins do not rule out sinus thrombosis Mild cases of sinus phlebitis in which recovery can occur without tying off the jugular vein or operative opening of the lateral sinus may occasionally cause a bacteremia of the same type as that in the severe cases Transient postoperative bacteremia is not infrequent (perhaps the result of transient phlebitis) following operations on the mastoid region in which the lateral sinus has been exposed at operation

The finding of approximately equal numbers of bacteria in the two internal jugular veins and in the arm or leg vein indicates that the bacteria are not coming from the regions drained by any of these veins In our limited experience (five cases) this finding occurs regularly in bacterial endocarditis, but one might expect it in many other clinical conditions, such as pneumonia or kidney suppuration From the observations presented it is evident that the lungs and liver filter out enormous numbers of bacteria, so that relatively few of the bacteria which get into the blood stream ever reach the periphery It would seem, therefore, that in the study of obscure infections blood cultures should be made, wherever possible, from a vein directly draining the involved region This principle should be applicable to the study of focal infections

The possibility exists that sudden liberation of a shower of bacteria from an infected focus can cause errors in the interpretation of differential blood cultures It is recommended that for future investigation the multiple cultures be made as nearly as possible simultaneously The observation that there are sometimes no bacteria detected in the blood of the arm vein, although there are bacteria in the veins directly draining the lesion, leads to the conclusion that the new type of blood cultures ought to be taken early in suspicious cases without waiting for a report of a positive result from an arm vein

AUTHOR'S SUMMARY

UNLAKED BLOOD AS A BASIS FOR BLOOD ANALYSIS O FOLIN, J Biol Chem **86** 173, 179, 1930

A revision of the Folin-Wu system of blood analysis is proposed in order to eliminate the errors, especially evident in the uric acid procedure, which arise from the presence in the final blood filtrates of products of the osmotic disintegration of erythrocytes A new technic is described whereby protein-free blood extracts can be prepared without a preliminary laking of the blood sample Uric acid determinations may be carried out on such extracts with a greatly improved accuracy

ARTHUR LOCKE

HOHN'S METHOD OF CULTURE OF TUBERCLE BACILLI T MATTHIES, Beitr z Klin d Tuberk **73** 84, 1929

The method of Hohn has been used in more than 600 experiments and has yielded excellent results

MAX PINNER

A NEW METHOD FOR STAINING RETICULUM T PAP, Centralbl f allg Path u path Anat **47** 116, 1929

Pap fixes tissues in formaldehyde and then stains frozen, paraffin or celloidin sections by a combination of the methods of Bielschowsky-Maresch, Achucarro and Foot The various steps in the staining process are performed in the following order

1 Aqueous, 0 25 per cent potassium permanganate, for from five to eight minutes

2 Rinse in distilled water for from fifteen to twenty seconds

3 Oxalic acid, 5 per cent, for from eight to ten minutes

4 Rinse in three changes of distilled water for one minute

5 Aqueous, 2 per cent, silver nitrate for twenty-four hours

6 Wash in two changes of distilled water

7 Ammoniacal silver nitrate, 1 per cent, for one-half hour (Note—1 grain (065 Gm) of silver nitrate is dissolved in 10 cc of distilled water to which 11 drops of 40 per cent sodium hydroxide are added The precipitate formed is then dissolved by the addition of sufficient 26 per cent ammonium hydroxide and the solution made up to 100 cc with distilled water)

8 Wash in two changes of distilled water

9 Immerse in 4 per cent neutral formaldehyde for from five to fifteen seconds

10 Wash in tap water

11 Gold chloride solution, 0 2 per cent, five minutes

12 Wash in tap water

13 Sodium thiosulphate, 5 per cent, for from five to ten minutes

14 Wash in tap water for one minute

15 Dehydrate in series of alcohols

16 Chloroform

17 Mount

This method has proved economical because four or five sets of slides may be run through the same reagents The fibrillae are graceful because the silver apparently is reduced within them rather than on their surface

GEORGE RUKSTINAT

Society Transactions

NEW YORK PATHOLOGICAL SOCIETY

Regular Meeting, April 24, 1930

LEILA CHARLTON KNOX, *Presiding*

ACUTE ULCERATIONS OF THE STOMACH IN CHILDREN BENJAMIN RICE SHORE (by invitation)

An acute, fatal, perforated ulceration of the stomach wall was reported in a girl, aged 22 months The history of ill health for only two days, the site of the ulcer on the posterior wall near the fundus of the stomach, and the lack of all signs of a chronic ulcer lead one to assume that the changes noted are of an acute and rapidly destructive nature The markedly hemorrhagic edges of the necrotic area suggest that the primary lesion was one of hemorrhage, from either local injury, overdistention or vascular thrombosis, and that gastric digestion of this area caused the perforation This case is of especial interest in that the perforation was found and measured at operation before postmortem digestion became manifest

A CASE OF MULTIPLE ARTERIAL THROMBOSES MILTON HELPERN

Advanced arteriosclerosis occurred in a seemingly healthy white man, aged 37 Sudden death was initiated by the perforation of a duodenal ulcer which, within twenty-four hours, was complicated by acute thrombosis of the right iliac and right coronary arteries which previously had been severely damaged by the sclerotic process The lesions in the stomach and duodenum were unusual

The patient was admitted to the wards of the fourth medical division of Bellevue Hospital, complaining of severe pain in the upper part of the abdomen which came on suddenly several hours before He stated that he had been troubled with "sour stomach" for two years He said that he had not had a syphilitic infection

Physical examination revealed a well nourished and well developed man with a normal temperature, a rapid thready pulse, poor heart sounds and tenderness and spasticity of the upper part of the abdomen The white blood count was 8,000, with 81 per cent polymorphonuclear leukocytes A surgical consultation was called, but the diagnosis was deferred Several hours later, the patient complained of a numb, cold feeling in the right lower extremity His pulse and respiration became more rapid and about two hours later he died His illness lasted twenty-three hours from the time of its acute onset

Necropsy revealed an acute generalized peritonitis due to a perforated duodenal ulcer A normal-sized heart showed extensive eccentric intimal sclerosis of both coronary arteries, with a fresh thrombus occluding the right vessel about 2 cm from its origin The myocardium did not show evidence of recent infarction The aorta was narrowed and exhibited a diffuse atherosclerosis with calcification Both iliac arteries were markedly sclerosed and narrowed and the right one was occluded by a dull red thrombus, 1 cm in length The larger branches of the abdominal aorta exhibited a moderate intimal sclerosis In the kidneys microscopic examination revealed a mild degree of arteriolosclerosis with an occasional hyalinized glomerulus, but the parenchyma, on the whole, was well preserved Histologic examination of numerous sections through the coronaries, the aorta and the iliac arteries confirmed the gross observations

The stomach was interesting both grossly and microscopically It was greatly enlarged, although contracted The entire mucosa was markedly hypertrophied and the rugae were extremely prominent In the anterior wall of the duodenum,

near the poorly defined pyloric duodenal junction, there was a perforated, punched-out, triangular, funnel-shaped ulcer with reddened and elevated mucosal edges measuring 1 cm on each side On the serosal aspect, a mound of granulation tissue surrounded the slitlike perforation of the thin fibrous base To the right of the perforated ulcer there was a smaller deep ulcer, distally there were several pitted erosions in the mucosa, which were seen on microscopic examination to extend down to the subserosa The blood vessels along both curvatures did not appear grossly abnormal, except for an intense congestion of all the vessels incident to the acute peritonitis

Numerous sections of the stomach were taken through the ulcers and also at intervals along the lesser and greater curvatures from the cardia to the pylorus The mucosa was markedly hypertrophied, and most of the serosal arteries showed a mild degree of eccentric intimal thickening An artery in the base of the perforated ulcer was occluded in some sections by an adherent thrombus, and in other sections by a proliferation of endothelium into the lumen Seven millimeters from the edge of the nonperforated ulcer, in the thickened submucosa, there was a thickened vessel showing a marked obliterating endarteritis

The most striking vascular lesion was found in a section through the lesser curvature of the stomach, 6 cm proximal to the perforated ulcer In the serosa there was an artery with a media of normal thickness and with a lumen completely occluded by the organization and canalization of an old thrombus This vessel presented a solid appearance much resembling a nerve, but the presence of a well preserved internal elastic lamina, several canalizing vessels with their elastic laminae and a few scattered particles of blood pigment indicated that the structure was an organized and canalized thrombosed artery In one section taken 14 cm proximal to the ulcer, a very small serosal artery showed a marked concentric intimal thickening with the formation of a new internal elastic lamina In all the sections studied, the submucosal vessels were well preserved Bacterial and spirochetal staining of the various tissues gave negative results except for a few scattered cocci on the acutely inflamed peritoneum

It is not altogether unlikely that the ulcers in this case may have followed nutritional disturbances due to the distant thrombosed vessel In infarct formation elsewhere, the process commonly occurs in tissues removed from the immediate point of vessel occlusion depending on the distribution of the end arteries

DISCUSSION

PAUL KLEMPERER Were these thrombosed vessels found in all the sections of the stomach? Were they found in the serosa?

MILTON HELPERN The organized thrombosed vessel was seen in the serosa in one section, about 6 cm proximal to the ulcer The other serosal vessels showed moderate intimal thickening, but were not thrombosed There was considerable intimal thickening in the section taken about 14 cm proximal to the ulcer near the esophageal junction Sections from the greater curvature also showed moderate thickening of the intimal layer All these vessels were found in the serosa

PAUL KLEMPERER These changes are unusual, and I am not inclined to consider them as multiple atherosclerotic thromboses The intima was thickened and in only one of the sections did I see what I thought was interference with the elastica Are not the lesions in the stomach unusual for atherosclerosis?

MILTON HELPERN The designation of multiple arterial thromboses in the title referred more to the thrombi in the iliac and coronary arteries There was a moderate degree of ordinary arteriosclerosis in the vessels of the stomach, but as Dr Klemperer pointed out, the other vascular lesions were unusual for arteriosclerosis In all the sections through the arteries it was possible to trace the elastic lamina, although it was interrupted in places Just what the etiology of the organized thrombosis in the artery on the lesser curvature was, we do not know, but the lesion was evidently not a recent one Of course, the other partially thrombosed vessel in the base of the perforated ulcer which was occluded by an endothelial proliferation might be considered a reaction to the ulcer

CLARENCE DE LA CHAPELLE As Dr Klemperer pointed out, the picture of the vessels in the stomach does not look like ordinary arteriosclerosis It brings up the point as to the frequency of ordinary arteriosclerosis in the gastric vessels In young persons, according to Ophuls, arteriosclerosis in the gastric vessels alone is a common observation, however, in this patient there was a generalized arteriosclerosis It is unfortunate that he did not live a week or so longer so that one could have seen what developed in the clinical picture with regard to the thrombi It would have been of great interest to see what the outstanding clinical signs were

PAUL KLEMPERER Of course, severe atherosclerosis in the stomach is unusual We have examined a considerable number of stomachs in cases of nephrosclerosis, because we were interested in the condition of the vessels throughout the body I do not remember the actual figures, but a very small number of these cases showed lesions in the stomach similar to those in the kidneys and pancreas In routine material, even in cases of severe atherosclerosis, one finds that the stomach is frequently spared There is no question but that the lesions in the coronary artery and iliac vessels are atherosclerotic The question still remains in my mind whether the lesion in the stomach is atherosclerotic or not Of course, the absence of a similar lesion in the submucosa speaks against the possibility that there is a previous inflammation of the stomach responsible for the arterial damage In healed phlegmonous gastritis, I should imagine, similar lesions could be produced, but one would expect them in the submucosa It still remains a question whether the lesion in the stomach vessels is of the same nature as the atherosclerosis in the iliac vessels

One point deserves some discussion It was interesting to hear that Dr Helpern believes that the thrombosis in the vessels was due to the peritonitis One can imagine that the toxemia brought about the thromboses The question might be asked, why is it that in severe atherosclerosis one sometimes finds thromboses but that more frequently one does not find them? There must be an additional factor present to cause the thrombosis One can realize that the toxemia in peritonitis causes some immediate acute endothelial damage, and that this leads to thrombosis One can think of the explanation suggested by Dr Libman, that some of the cases of coronary thrombosis in subjects with severe atherosclerosis may be due to a sudden rise in the blood platelets Such attacks of thrombocytemia seem to occur I do not think that this has even been actually followed up clinically I remember one case that suggested this possibility, in which the patient had a platelet count of over 400,000 I observed other cases in which there was no question but that venous thrombosis was caused by thrombocytemia In a few cases in which the thrombotic tendency was evident I have examined the bone-marrow to find whether there was an increase in the megakaryocytes present I do not think that I have any definite evidence, but it might be worth while to examine the bone-marrow in cases in which a thrombotic tendency exists

MILTON HELPERN The organized thrombosed vessel in the stomach certainly does not seem to be the same type of lesion as that found in the sclerosed vessels elsewhere Apparently it appeared some time before, judging by the canalization that took place in the obliterated lumen This lesion would therefore not have any relation to the sudden pain that ushered in the patient's last illness

Regarding a hypertrophic gastritis following a phlegmonous gastritis, that does not seem likely from the sections There was no scarring The mucous membrane was hypertrophic, but otherwise in excellent condition The submucosa appeared intact and the submucosal vessels normal In this case the kidney, surprisingly enough was well preserved There were only one or two small arterioles that showed any thickening at all and the parenchyma was in a good state of preservation, whereas the lesions in the stomach seemed to be extensive The etiology of the old thrombotic lesion in the artery on the lesser curvature is not clear The more recent thrombotic lesion in the vessel in the base of the perforated ulcer might be considered as secondary to the ulcerative process Thickened and sometimes thrombosed vessels are not infrequently found in the base of ulcers

A CASE OF SO-CALLED ACUTE ISOLATED MYOCARDITIS (SUBACUTE PRODUCTIVE MYOCARDITIS) CLARENCE DE LA CHAPELLE and IRVING GRAEF

Recently, Scott and Saphir reported the first two cases of acute isolated myocarditis to be recorded in the English language In their paper they mentioned reports of thirty-six other cases recorded in the Continental literature since 1888, when Steffen described two cases of acute myocarditis which probably belonged in this group

It has been noted by practically all authors that the outstanding clinical feature is progressive myocardial insufficiency In none of the cases has the etiology been demonstrated, nor have any cases been diagnosed correctly during life

The following case is reported in order to add another example of what appears to be Fiedler's myocarditis to the small group already recorded

A M, a white laborer, aged 21, born in Argentina, was admitted to Bellevue Hospital, third (New York University) medical division, on Jan 25, 1930, complaining of pain in the chest and dyspnea His family history was irrelevant He gave a history of occasional colds, but no history of polyarthritis or venereal disease

The patient appeared chronically ill, but well nourished He had slight dyspnea, orthopnea, and a cafe-au-lait color The sclerae were icteric There were pulsating veins in the neck and one of the superficial veins of the left arm could be seen pulsating The apical beat of the heart was visible and palpable in the sixth space, 14 cm from the median line, at a point in the anterior axillary line A 2 meter roentgenogram of the heart, taken five days after admission, showed marked enlargement in the transverse and long diameters The first sound at the apex was of poor muscular quality The sounds at the base were faintly audible The rhythm was regular The heart rate was 92 per minute The radial pulse was small, it could not be palpated on the left side, owing to edema of the arm The blood pressure was 105 systolic and 82 diastolic There were signs of fluid over the area of the right lower lobe, with crepitant and subcrepitant rales and dulness above the eighth rib posteriorly The edge of the liver was palpable 8 cm below the costal margin, it was tender but did not pulsate The spleen was not palpable There was no evidence of ascites Both lower extremities presented slight edema

On admission, examination of the blood showed 10,400 leukocytes, with 79 per cent polymorphonuclears, 20 per cent lymphocytes and 1 per cent transitionals The red blood cells numbered 3,700,000 with 70 per cent hemoglobin The Wassermann reaction of the blood was negative Blood cultures taken on two different occasions yielded no growth The systolic blood pressure never exceeded 112, the diastolic ranged between 82 and 92 Electrocardiograms revealed prolongation of the P-R interval (from 0 2 to 0 24), there was complete intraventricular block of the right bundle branch, there was low voltage in all three leads, normal sinus rhythm was present Examination of the sputum revealed an unclassified pneumococcus On the patient's admission to the hospital the urine was normal, subsequent examinations revealed a slight albuminuria and the appearance of numerous hyaline and finely granular casts, an occasional red blood cell was found on one occasion, the day before death Blood chemistry tests performed two days after admission showed 64 mg of nonprotein nitrogen and 119 mg of sugar per hundred cubic centimeters Three days before death the nonprotein nitrogen was 100 mg and the creatinine 4 7 mg per hundred cubic centimeters

The temperature ranged between 98 and 100 F, and the pulse rate between 68 and 100 per minute Thoracentesis was performed two days after admission, yielding 80 cc of clear straw-colored fluid with a specific gravity of 1 008 The cell count was 1,940, the differential count including chiefly lymphocytes and endothelial cells The patient progressively gained weight, with increasing edema of the lower extremities and of the left arm and hand Facial edema became marked about four days before death There was no change in the cardiac observations Cyanosis, which was of a fairly marked degree, was intermittent During the last few days, as the congestive heart failure became more marked, slight icterus,

oliguria, Cheyne-Stokes' respiration and stupor supervened The patient died twelve days after admission to the hospital, presenting a picture of heart failure and uremia

Necropsy showed a well nourished and well developed white man, aged 21 Except for moderate pitting edema of the legs, trunk and left arm and slight icterus of the skin and sclerae, external examination gave negative results The peritoneal cavity contained about 500 cc of clear straw-colored fluid Each pleural cavity contained about 300 cc of clear fluid The pericardial sac contained about 75 cc of clear fluid Otherwise the serous sacs were intact

The heart was large, weighing 600 Gm Its external measurements were 16 by 13 by 9 cm It was so soft and flabby as to spread like a mushroom over the supporting hand All the chambers were markedly dilated The papillary muscles of both ventricles were flattened The mitral valve and its chordae tendineae were normal The valve orifice measured 10 cm in circumference The aortic orifice measured 6 cm in circumference, the cusps were normal The tricuspid orifice measured 11 5 cm in circumference, the valve and its chorae tendineae were normal The myocardium of the left ventricle measured 18 mm in thickness at the base of the ventricle, 10 mm near the apex and from 2 to 3 mm at the apex The right ventricle measured 6 mm in thickness at the base and 3 mm at the apex The epicardium was normal, except for a few smooth, glistening points of thickening, the size of a pinhead, over the right auricular appendage The endocardium was intact throughout except at the apex of the left ventricle, where a firm, grayish-red thrombus was found attached to the endocardium The right auricular appendage was filled by a firm, attached, grayish-red thrombus

On section, the myocardium, particularly that of the left ventricle, appeared remarkably altered, brownish and brownish-yellow streaks being scattered throughout, nearby were seen irregular bands of gray and grayish-yellow firmer tissue The linear markings of the muscle bundles, on section, were barely visible The coronary orifices and arteries were normal

Both lungs were heavier than normal, the pleural surfaces were smooth The cut surface was reddish blue and oozed frothy serosanguineous fluid, they were otherwise normal The liver weighed 1,300 Gm The capsule was smooth The cut surface was firm, showing the markings of chronic passive congestion, which gave the organ a nutmeg appearance The spleen was normal in size and shape weighing 220 Gm On section, the pulp appeared firm and red, and the follicles fairly prominent The kidneys were somewhat enlarged, weighing 420 Gm together The capsules stripped easily, leaving a smooth surface On section and inspection they were normal except for slight hyperemia and one small grayish, apparently healed infarct in the right kidney The pancreas, suprarenal glands, bladder, prostate and testes appeared normal

Sections were taken from both ventricles, both auricles, the auricular appendages, valves, papillary muscles, aorta and pulmonary artery The stains used were hematoxylin-eosin, van Gieson's, Mallory's connective tissue, Weigert's elastic tissue, sudan III Nile blue, Gram-Weigert's methyl-violet, Unna-Pappenheim's, Levaditi's and Warthin-Starry's stains

Sections from various portions of both ventricles revealed marked hypertrophy of the muscle nuclei and fibers, both of which were many times larger than in normal circumstances The interstitial connective tissue was increased in amount Newly formed blood vessels were abundant and were injected They were seen growing into and between muscle bundles and fibers

The lesion noted was widely distributed and more marked in the myocardium of the left ventricle Areas of considerable dimension were found consisting of degenerated, edematous muscle fibers and nuclei, infiltrated by large numbers of lymphocytes, endothelial cells, fibroblasts and newly formed blood vessels These areas were irregular in outline and poorly demarcated, they did not present a constant picture, as the several elements varied in number and location In some places there was an abundance of young connective tissue cells with a few lymphocytes and an occasional plasma cell, in other places focal collections of

lymphocytes, a few plasma cells and large endothelial cells were found in and around edematous muscle fibers Some of the endothelial cells presented sharply outlined nuclei, and in their cytoplasm a fine granular pigment was occasionally seen No giant cells or Aschoff bodies were found in any of the sections One coronary arteriole was found to contain a partial parietal thrombus composed of fibrin, in the meshes of which a few leukocytes could be seen Near the well marked areas of inflammatory reaction, small focal areas of muscle necrosis were encountered, with no surrounding inflammatory reaction The cross-striations of the muscle fibers were normal, except in the areas of degeneration Fat was not markedly increased in amount, with the sudan III stain it could be seen in fine droplets in most of the myocardial fibers Sections stained by the van Gieson and Mallory connective tissue methods showed scattered foci of fibrous connective tissue These were chiefly interstitial With these stains the interstitial elements in the areas of muscle degeneration were seen as fine fibrillar bands with no intervening stained sarcoplasm Polymorphonuclear leukocytes and eosinophils were scarce No areas of hemorrhage were seen At the apex of the left ventricle, section revealed a fairly advanced organizing process involving the endocardial thrombus and the adjacent muscle Sections of the valves and endocardium, except at the apex, as noted, revealed a normal structure Sections of the aorta and pulmonary artery showed no changes The stains for amyloid, bacteria and spirochetes yielded negative results Sections from the other organs confirmed the anatomic diagnosis

Progressive heart failure was the outstanding clinical feature in this case This is in accord with the observations of previous authors Of great clinical interest is the data obtained by electrocardiograph, which gave further evidence of the extensive distribution of the lesion, i e, first-stage auriculoventricular block and complete intraventricular block of the right bundle branch variety Careful search for an etiologic factor revealed nothing There was no history of any of the well known infectious diseases, including rheumatic fever, diphtheria, scarlet fever, syphilis or tuberculosis, nor were we able by any means available to demonstrate an etiologic agent post mortem The exact onset of the lesion in this case is doubtful The embolic phenomena noted during life and their evidence at necropsy are particularly noteworthy and possibly give a clue as to the onset and duration Thus, the cerebral accident about eight and one-half months before death, the healed infarct in the kidney and the probable pulmonary infarct about six weeks before death suggest that the intracardiac thrombi were present for some time

A detailed report of this case will be published

DISCUSSION

CLARENCE DE LA CHAPELLE From a clinical point of view this case was interesting and most unusual as is noted, no diagnosis was made We knew that we were dealing with congestive heart failure, but in the absence of a history of any of the usual causes of heart disease, we had no etiologic factor We were unable to correlate our observations on progressive marked heart failure in a subject aged 21 with those in any of the ordinary types of acute heart failure I refer to those associated with rheumatism, subacute bacterial endocarditis and diphtheria We could see from the electrocardiographic observations that there were extensive changes in the muscle We therefore inferred that we were dealing with an unknown form of heart disease showing marked enlargement and no signs of pericardial or valvular disease The first physician to see the case thought of lobar pneumonia, as the patient gave a history of cough and spitting of blood Another diagnosis was acute pleuritis The possibility of subacute bacterial endocarditis was thought of, because the patient had a distinct cafe-au-lait color, but he had no clubbing of the fingers splenic enlargement or petechiae As to the possibility of rheumatism there was no history and no clinico-anatomic evidence of rheumatic fever The outstanding feature was the confusion in diag-

nosis owing to the absence of an etiologic factor and the rapid downhill course despite treatment

From the pathologic point of view, we report the case because it is unusual, only two other cases having been reported in the English language A total of thirty-eight cases has been recorded in forty-two years Possibly other cases have been observed but not reported This disease may be more common than we think it is It makes one wonder, after seeing the changes microscopically, and particularly the last two slides in which there were practically no cellular elements — merely fibrous replacement — what the end-result of this disease might have been if the patient had lived a little longer I think that we have a partial answer to this About three months before the present meeting an autopsy was performed by the medical examiner on a boy of the same age as the one in our case He was a messenger who dropped dead while delivering a package At autopsy everything appeared normal except the heart, which showed only a diffuse replacement fibrosis The coronary arteries were normal There was no inflammatory lesion on the valves, myocardium or pericardium There was a healed osteomyelitis of the right radius, which was definitely an old lesion The disease may have been similar to that in the present case, possibly the end-result of the same process

M A Kugel Were any lesions noted in the neuromuscular bundle?

Irving Graef One section through the bundle showed no change located directly in it There were changes near it

Paul Klemperer This case reminds me of two cases, one of which apparently conforms fully to the description of Dr de La Chapelle's second case In this case, which I observed many years ago, a young boy died suddenly, at autopsy we found the same picture a diffuse fibrosis without any etiologic clue The Wassermann test performed on the blood of the cadaver gave negative results The other case, in which I performed autopsy only six months before the present meeting, may have possibly shown a more acute stage of the same disease I say "possibly" because we have no other explanation for it In this case a woman, aged 32, underwent splenectomy for thrombocytopenic purpura two years before her death Two months before death hemorrhagic diathesis again developed, for which ergot was given She was then admitted to the hospital with profound anemia, a transfusion of blood was given, and she died rather suddenly It was thought that death was due to anemia, however, the heart presented distinct gross lesions and smaller and larger areas of gravish color, contrary to the present case, histologic examination revealed chiefly polymorphonuclear leukocytes Bacterial stains, including Gram's stain, gave negative results We found no other evidence of inflammatory lesions throughout the body The spleen had been removed, but, from the anatomic standpoint, there was no evidence of a septic condition Examination of the heart blood was omitted because of our experience with postmortem bacteriology This case may have represented an early stage of the condition under discussion It is possible that if the patient had lived longer, the acute inflammation would have changed into the picture of a granulation tissue as in the case reported The patient died of anemia There had been no outstanding cardiac symptoms during her life

Clarence de La Chapelle In reference to the cellular reaction in Dr Klemperer's case, it is interesting to note in the other cases reported that there does not seem to be any characteristic histologic picture A few describe polymorphonuclear leukocytes and a few mention giant cells, but there does not seem to be any uniform picture

Paul Klemperer Of course, one has to be careful in searching through the other organs I had a third case which was just as puzzling as those mentioned The heart presented a picture that reminded one of Fiedler's myocarditis because of the localization of severe inflammatory lesions in the myocardium without endocardial or pericardial involvement There were some giant cells, but the same changes were found in the spleen and liver

ANOMALOUS ORIGIN OF THE RIGHT SUBCLAVIAN ARTERY VERA B DOLGOPOL

In a woman, aged 36, the branches of the aortic arch were (1) the right common carotid, (2) the left common carotid, (3) the left subclavian and (4) the right subclavian The innominate artery was missing The origins of the first three branches were situated on the anterior aspect of the aortic arch, the right subclavian artery arose on the posterior aspect of the aortic isthmus The course of the right subclavian artery was behind the trachea and the esophagus, on the vertebral column in the region of the third and second dorsal vertebrae and then over the dome of the right pleura It passed in front of the scalenus anterior, and from then on the course and the branches of the artery were normal

The portion of the right subclavian artery between its aortic origin and the scalenus anterior is a remnant of the right dorsal aortic root

The anomaly did not give any symptoms during the patient's life

---

Stated Meeting, May 22, 1930

LEILA CHARLTON KNOX, *Presiding*

PLACENTA INCRETA BORIS KWARTIN and NATHAN H ADLER

Placenta accreta and increta are among the most serious complications of the after-birth period The authors were able to collect only seventy-four cases in the literature One case came under their direct observation which was of great interest because of the clinical history and pathologic anatomy, which resembled those of tubal pregnancy

A secundigravida, unipara, 28 years old, was admitted for cesarean section two weeks before term with symptoms of threatening rupture and complaining of severe abdominal cramps and a dark brown, bloody discharge She had had a cesarean section two years before with postpartum endometritis and pneumonia At operation the placenta was found to be adherent, for the greater part at the site of the old scar, and a hysterectomy was performed The patient made an uneventful recovery On pathologic examination, grossly, the chorionic villi were seen to extend deep into the muscularis, and in the region of the previous scar, with no muscle fibers, the chorionic villi penetrated to the serosa Microscopically, the decidua was completely absent in the region of the placental inflammation The chorionic villi broke through the hyaline layer of Nitabuch In places the cells of the upper layers of the muscularis showed a decidua-like transformation Elsewhere the decidua vera was almost completely absent

The etiology of placenta accreta is still debated on the following points

1 The most important factor is the condition of the uterine mucosa at the time of nidation of the ovum Maldevelopment of the uterus, an infantile uterus with hypoplasia of the endometrium, repeated curettages, septic endometritis, diverticular pregnancies, atrophic endometrium above the uterine myomas, and the persistence of operative scars from previous cesarean sections are etiologic factors of great importance

2 A primary tendency toward excessive growth on the part of the chorionic villi is another etiologic factor

3 Insufficient production of antiferment against the arrosive power of the trophoblasts, possibly owing to the deficiency in the hormonic cycle of the maternal organism, is a third factor in the etiology of placenta accreta

DISCUSSION

ALFRED PLAUT This is a clearcut case of placenta increta In years of experience in gynecologic pathology I have more frequently seen placenta increta diagnosed and not found than not diagnosed Often the clinician says that the

removal of the placenta has been difficult, or that some hard things have been felt while the placenta was being removed, but the diagnosis should not be made unless the chorionic villi are seen directly on the myometrium or growing into it without any spongy layer between The demonstration by Dr Kwartin showed a typical case of true placenta increta

ARTERIOLAR NECROSIS OF THE KIDNEY PAUL KLEMPERER and SADAO OTANI (by invitation)

Essential hypertension with renal insufficiency is associated with atherosclerosis of slow progress, with gradual constriction of the vascular bed and subsequent advanced destruction of the functioning parenchyma or with a more rapidly developing vascular alteration without severe renal atrophy The latter form, the malignant phase of hypertension, must be divided pathologically, according to the nature of the vascular lesions, into an accelerated atherosclerotic and an arteritic form

The rapidly developing constriction of the vascular bed, which cannot be overcome by the maximal elevation of the blood pressure, is responsible for the sudden onset of the fatal renal insufficiency

The etiology of the vascular condition has not been determined The pathologic picture and clinical analysis suggest that the accelerated atherosclerotic form may be caused by a constitutional or acquired angiospastic factor The arteritic form is most probably caused by the influence of various toxins on the vessels already affected by a degenerative simple atherosclerotic process

This paper will appear in full in a future issue of the ARCHIVES

DISCUSSION

ALFRED PLAUT How far were the corresponding arteries in other organs, notably in the pancreas, the spleen and the suprarenal glands, observed?

PAUL KLEMPERER In all of our cases we found arteriolosclerosis in one or the other organs, mainly in the pancreas, the liver and the suprarenals, in about the same percentage as one used to find it in simple hypertension The spleen cannot be taken into consideration because of the extreme frequency of arteriolar hyalinization found in this organ during routine examination We examined the abdominal muscle and the diaphragm in the last six cases only, and we did not find any arterial lesion, either in the intima or in the media, as claimed by Keith and Kernohan

Regarding the type of vascular alteration, we seldom found cellular intimal thickening in other organs than in the kidneys, except in the choroid where we found it in every case in which the eye had been examined

BENJAMIN SACKS Some years ago Dr Baehr and I reported before this society several cases of endocarditis of a peculiar type in which there was a necrotizing arteriolitis of the kidneys similar to that in one of the cases that Dr Klemperer illustrated on the screen In this particular case we searched in vain for Aschoff bodies in the heart We finally were forced to come to the conclusion that this type of verrucous endocarditis was similar in many respects to that which is seen in rheumatic cases, though such an etiology could not be established, and we had to put the case in the atypical group All of the patients in our three cases died of uremia

ARTHUR M FISHBERG (by invitation) Dr Klemperer brought up the point that there is a difference of opinion as to whether so-called malignant hypertension is always preceded by "benign" hypertension He is not convinced that there is such a preceding stage, and I gather that he believes that there usually is not I personally am of the contrary opinion, and I think that the so-called malignant hypertension is merely one of the phases of essential hypertension, which invariably follows a period of hypertension clinically and anatomically characterized by the features we are accustomed to associate with "benign' hypertension The following evidence favors this view First, the clinical histories of many of these

patients show that asymptomatic hypertension had been present for some years—for two or three years or even considerably longer Furthermore, on the first examination of these patients, albuminuria is often absent and may be missing for years I am referring to the patients who when seen years later at necropsy exhibit the typical necrotizing arteriolar lesions in the kidney that Dr Klemperer has so well demonstrated Despite the fact that some of these patients, when first examined, have no albuminuria, we often know that some day they will come to necropsy with necrosis of the renal arterioles because of the presence of characteristic changes of the eyeground with papilledema Whenever you see these ophthalmoscopic changes with papilledema in a patient with essential hypertension, you can predict, with a high degree of confidence, that at necropsy you will find necrosis of the renal arterioles The fact that at this stage these patients have no albuminuria seems to me good evidence that there is no necrosis of the renal arterioles with its inevitable consequences to the glomeruli At this period, the renal changes can be at most those of arteriolosclerosis, else the patients would have albuminuria As Dr Klemperer has brought out very clearly, in kidneys with arteriolar necrosis, one usually does not find a great number of hyalinized glomeruli, and the hyaline changes in the arterioles of the kidney are generally not excessive However, these changes are always present to some extent and are sometimes marked Moreover, one finds arteriolosclerosis in the pancreas, the liver, the spleen and other organs One does not find necrosis, but only arteriolar sclerosis in these organs The mere fact of the presence of this arteriolosclerosis with its characteristic distribution points to a long-standing hypertension For these reasons, I regard malignant hypertension as a phase of essential hypertension I cannot explain why only a small proportion of patients with essential hypertension advance into the malignant phase However, one can see that youth is a strong predisposing factor, the average age of death of patients with necrosis of the renal arterioles is much younger than that of other sufferers from essential hypertension The situation is analogous to that in diabetes mellitus, in which the younger the patient, the more severe the disease is apt to be But quoting an analogy does not explain the phenomenon

PAUL KLEMPERER The question of Dr Fishberg's discussion is, of course, the one that puzzled us most There is no doubt, and I hope that every one understood me, that all of our patients had a preceding stage of hypertension On an average this lasted, as far as we know, for about two and a half years We had one patient who was refused life insurance, three years before his death, because of elevated blood pressure He was examined at that time at the Cornell Clinic, and his urine was found to be free from albumin After an interval of nearly three years the clinical picture became serious, and he died of uremia It is possible that this is the longest duration of the malignant form of nephrosclerosis, but it is also possible that this patient had had hypertension a long time before it was actually detected We do not know, either, how long the lenta form of nephrosclerosis lasts It is evident however, that it lasts much longer than three and a half years

The question is whether or not in the malignant form, the atherosclerotic process advances from the very first at a more rapid tempo than in simple hypertension It is, of course, evident that even with a rapid development of the atherosclerosis there is not immediately a complete constriction of the blood vessels leading to renal insufficiency and necrosis of the arterioles, and it is conceivable, therefore, that in the first years of such a development the clinical picture will in no way be different from cases in which the atherosclerosis develops slowly The main fact on which one must base one's opinion that atherosclerosis in the malignant form starts from the first at a more rapid tempo and need not go through a period of slow progress is the more extensive atrophy of the parenchyma which one finds in such cases, in contrast to that found in the early forms of simple arteriolosclerosis In this instance the tubular atrophy is dependent on glomerular fibrosis In our observations there is an incongruity between glomerular lesions and parenchymal atrophy

Book Reviews

HYPERTENSION By LESLIE T GAGER, M D Price, $3 Pp 158 Baltimore Williams & Wilkins Company, 1930

In this book Gager reviews the important work on hypertension in the past few years He believes that hypertension is a "primary disorder of vasomotor function," and traces briefly the development of knowledge of hypertension from Traube's first description of increased arterial tension in 1856 to the present time Adequate consideration is given to the various etiologic factors that other workers have championed A chapter is devoted to the relation of hypertension to renal disease and another to various chemical factors that have been considered by some to bear on the etiology Gager does not, however, express his opinion as to either and leaves an impression with the reader that he does not consider them important as causative factors In the chapter on the functional basis of hypertension he gives his own ideas clearly He holds that the so-called "stress and strain" of modern civilization play an important part in the development of hypertension Statistics are cited revealing that hypertension among certain tribes of African natives is extremely rare, although their diet consists mainly of meat, and chronic infections are frequent The symptomatology and the incidence of hypertension are considered fully In clinical work Gager stresses the importance of studying the retinal vessels to determine the stage and to follow the progress of the disease Because only a small percentage of patients with hypertension die of renal insufficiency, Gager emphasizes the importance of signs pointing to the more frequent occurrence of death from cardiac or cerebral conditions as well as the more easily obtained tests of renal function Prognosis is dealt with mainly from a statistical standpoint The author believes that much can be done for patients in the early stages of elevated systolic pressure Knowledge of the patient's personality, environment, heredity and adjustment in the mode of living is especially helpful Moderate exercise in some cases, a simple diet and the reduction of weight in the obese are also recommended in this group Gager has used the sulphocyanates with better results than obtained with other drugs, and potassium iodide and bromide in combination are the next most effective The book gives a concise yet comprehensive presentation of the recent investigations in this field

TEXTBOOK OF PATHOLOGY By DHIRENDRA NATH BANERJEE, M D, Demonstrator of Pathology, Carmichael Medical College, Radiologist, Chittaranjan Hospital, Radiologist, Calcutta Polyclinic, Ltd Second edition Pp 636, with 305 illustrations and 9 colored plates Calcutta The Medical Bureau, 1929

As an outline of pathology and allied subjects, to be properly supplemented by comprehensive lectures, this text should be very useful to students, not only in the Orient, but elsewhere The author has attempted to cover morphologic pathology, bacteriology, animal parasitology, laboratory methods in general and epidemiology — all in one volume In addition, he correlates the morphologic observations in each disease condition with the pathologic physiology and the clinical picture Therefore, the presentation of the various topics is of necessity rather sketchy, and of doubtful value to those approaching the subject for the first time A few diseases are treated in more detail, especially those that are prevalent in the East such as malaria, kala azar and the dysenteries For the most part the author's point of view on disputed subjects is orthodox, although he has accepted the newer use of the term nephrosis to include all types of renal degeneration not accompanied by inflammatory changes His discussion of the etiology of atherosclerosis reveals familiarity with the results of recent experimentation in fact most of the subjects are brought well up to date

Probably the least convincing parts of the book are the lists of definitions, many of which are not entirely accurate in detail For example, congenital and hereditary diseases are not clearly differentiated, and the only hereditary disease mentioned, namely, hemophilia, is classed as pseudohereditary However, in spite of a few such defects, the book may well be a valuable addition to the medical student's library

THE CREED OF A BIOLOGIST A BIOLOGIC PHILOSOPHY OF LIFE By ALDRED SCOTT WARTHIN, PH D, M D, LL D, Professor of Pathology, University of Michigan Cloth Price, $1 50 Pp 60 New York Paul B Hoeber, Inc, 1930

This is a frank and dignified statement of a philosophy of life which has brought deep inward satisfaction to the author The good of the race, the progress of the race and the future welfare of the race loom large in his mind and credo The transmission of acquired characters is a leading article of faith, and the author stands firm in his conviction that the course of evolution can be determined by man's will It may occur to some readers that if the inheritance of acquired characters were as well established by scientific evidence as, say, the mendelian law, no one would feel called on to express a "belief" in it

The purpose and spirit of the book as a whole are admirable and will unquestionably touch sympathetic strings in many persons Not all men are born believers, and there should be a place somewhere for those who feel the impulse of the ironic smile, but do not want to "commit suicide" And is it so certain that all the evils in the world are man s and none nature s?

Books Received

A System of Bacteriology in Relation to Medicine Medical Research Council Volumes 1 to 5 Cloth Price, per volume, 1 pound, 1 shilling, net London His Majesty's Stationery Office, 1930 (May be obtained from the British Library of Information, 551-5th Avenue, New York)

Hypertension By Leslie T Gager Cloth Pp 160, with illustrations Price, $3 Baltimore The Williams & Wilkins Company

A Compilation of Culture Media for the Cultivation of Micro-Organisms By Max Levine and H W Schoenlein Cloth Price, $15 Pp 969, with 7,000 formulas and four indexes Baltimore The Williams & Wilkins Company, 1930

Naissance, vie et mort des maladies infectieuses By Charles Nicolle, Directeur de l'Institut Pasteur de Tunis Prix Nobel de Medecine 1928 Paper Price, 15 francs Pp 219 Paris Librairie Felix Alcan, 1930

Die Wechselbeziehungen zwischen der Tuberkuloseerkrankung und den Generationsvorgangen im weiblichen Organismus Von Privatdozent Dr Joachim Granzow, Oberarzt der Staatlichen Frauenklinik Danzig-Langfuhr Paper Price, 10 80 marks Pp 196, with 28 illustrations Berlin S Karger, 1930

ARCHIVES OF PATHOLOGY

VOLUME 10 NOVEMBER, 1930 NUMBER 5

CELL TYPES IN THE GLIOMAS

THEIR RELATIONSHIP TO NORMAL NEUROHISTOGENESIS [1]

CYRIL B COURVILLE, M D

LOS ANGELES

Tumors of the brain substance, commonly known as gliomas, have offered a fascinating field of study since they came to be recognized as a pathologic entity Classed at first with "cancers" and sarcomas as a whole, they tended later to be segregated into a group by themselves, based on the idea that they had a peculiar origin from the brain tissue Without the aid that the microscope could give as to the nature of their constituent tissues, pathologists of the early decades of the nineteenth century designated them as encephalomas or cerebromas These names were short lived, however, for after his earlier histologic studies on the neuroglia, Virchow came to associate this group of tumors with the supporting tissues of the nervous system and called them gliomas His classic descriptions of the gross appearance of the various types of gliomas remain unsurpassed, although many of his conceptions as to the character of their cellular elements must be disregarded In spite of recent advances in knowledge regarding their structure and growth characteristics, the problem of their histogenic processes has not been entirely solved In the hope of contributing in a small way to the study of the problem, this investigation was undertaken

It soon became obvious that the problem presented two distinct features (1) a study of the morphologic aspects of the cells composing the various tumors and (2) the determination of the essential nature of these elements and their relationship to the stages of normal neurohistogenesis The first phase of the problem has been more or less completely investigated even by the pioneers in the field, who described and illustrated the occurrence of apolar, unipolar, bipolar and multipolar

Submitted for publication, April 12, 1930

[1] From the Neurosurgical Service of Dr Carl W Rand, Los Angeles County General Hospital

1 Virchow, R Die krankhaften Geschwulste, Berlin, A Hirschwald, 1864-1865 vol 2, pp 125-151

2 Klebs, E Beitrage zur Geschwulstelehre II Die Geschwulste des nervosen Centralapparates, Vrtljsschr f prakt Heilk **133** 1, 1877

3 Osler, William Structure of Certain Gliomas, Philadelphia M News, Feb 20, 1886, quoted by Mills and Lloyd, in Pepper System of Medicine, Philadelphia, Lea Brothers & Company, 1886, vol 5, p 1047

tumor cells Virchow,[1] Klebs[2] Osler,[3] Bramwell[4] and Stroebe[5] considered these various forms in detail, so that there is little to be added by way of description

The second cytologic feature includes the proper interpretation of these various cell forms This portion of the field is by no means unexplored, for Bailey and Cushing by the use of the specific metallic methods, laid a broad foundation for future investigation in their recent epoch-making contribution They attempted to associate the cellular elements of a given glioma with a stage in the normal histogenic process This presents a difficulty, because, as these authors fully realized,[6] each tumor contains not one, but often several different types of cells If a plan could be devised in which a certain degree of latitude could be allowed for the histogenic process as it occurs within the growing tumor itself, a nearer approach to the solution of the problem may be made

Furthermore, the question not only of their development but also of their possible origin is less complex if one notes the normal histogenic process as it occurs in the brain rather than in the cord The essential differences in cellular development in the pallium as contrasted with that in the embryonic cord may be considered under three headings (1) the greater migratory activity of the developing cells (2) the more complex morphology of the gross structures and (3) the elaboration of intricate commissural, association and projection systems A prolonged discussion of pallial development is not in order in this connection, and it will suffice to say that undifferentiated cells are to be found as late as the third and fourth months of fetal life well out in the looser tissues of the mantle layer These bipotential cells are undoubtedly the origin of many of the glial and ganglionic elements of the cortical and subcortical regions of the adult brain It is possible that such indifferent elements may be isolated from their normal paths by the development of the corpus callosum, the fibers of which are already beginning to intersect the paths of such corticifugally coursing elements

MATERIAL AND METHODS

In order to study the cell types of the gliomas, specimens of fifty tumors were collected, with the available clinical records A large proportion of the material was contributed by the resident pathologists of the Los Angeles County General Hospital, the remaining portion

4 Bramwell, Byrom Intracranial Tumours, Philadelphia J B Lippincott Company, 1888, pp 17 and 222

5 Stroebe, H Ueber Entstehung und Bau der Hirnglome, Beitr z path Anat u z allg Path **18** 405, 1895

6 Bailey, P, and Cushing, H A Classification of the Tumors of the Glioma Group on a Histogenetic Basis with a Correlated Study of Prognosis, Philadelphia, J B Lippincott Company, 1926, pp 53, 54, 101 and 102

in great part, by the pathologists of the laboratories of the College of Medical Evangelists and of the Good Samaritan, Children's, White Memorial and Pasadena Hospitals A few specimens were given to me by physicians in private practice

In addition to the routine methods, I utilized the following staining and impregnation processes Mallory's phosphotungstic acid-hematoxylin and aniline blue methods, Cajal's gold sublimate and reduced silver (the latter being used to demonstrate neuroblasts), and Hortega's silver carbonate and fourth variant methods Penfield's combined method for the study of oligodendroglia and microglia in formaldehyde-fixed tissues was also used

Early in the course of this investigation it was realized that a complete report of the study could not be included in this paper I have therefore limited myself here to a general survey of the field in a brief consideration of the various types of gliomas More specific studies have been made the subject of further contributions, which will be forthcoming

FUNDAMENTAL CONCEPTIONS

It is evident that two factors largely influence the histologic architecture and composition of a given glioma (1) the rate and degree of differentiation of its constituent elements and (2) the stage and apparent situation of the parent cells at the moment of the assumption of neoplastic activities Many of the developmental stages can be morphologically and specifically demonstrated within the tissues of a single tumor, so that a more or less complete review of the normal process is presented Furthermore, the extent of the process varies greatly in the individual tumors of a given group The tissue architecture is influenced largely by the tendency of its cells to assume primitive arrangements or altered by accompanying degenerative changes Such primitive tendencies are manifested by the formation of cell rings ("annulation forms" of Tooth) or pseudorosets of various types In a few rare tumors, the grouping of the cells suggests the arrangement found in the neural tube in the early period of embryonal life

It seems fairly clearly demonstrated also that in the embryonal gliomas the earliest and most primitive type of cell is a round or oval form with a mere ring of cytoplasm about a chromatin-rich nucleus The cells of this type are much alike in the various members of the group, and in many of the medulloblastomas and neuroglioblastomas they compose the greater mass of the tissue This cell seems to be a counterpart of the indifferent cell of the developing pallium, having bipotentialities as far as the proliferation of glioblasts and neuroblasts

are concerned This seems to be proved by the fact that preparations by specific methods demonstrate neuroblasts, as well as glioblasts

The mode of cell division in the various tumors is interesting and sheds some light on their biologic activities In a general way, it is evident that in the more embryonal forms, cell division takes place largely by mitosis In the less malignant individuals of the neuroglioblastomas, the astroblastomas and the gangliogliomas, there are marked evidences of amitotic division as manifested by tumor giant cells and indented and constricted nuclei In the astrocytomas, cell division takes place entirely by this method From this standpoint, the type of cell division gives a rough estimate as to the degree of malignancy of the tumor in question

A SUGGESTED CLASSIFICATION OF THE GLIOMAS

With these fundamental characteristics of gliomas in mind, the following classification is suggested, based necessarily on the concept that the tumors of this group have their origin in embryonal cell "rests"[7]

Group 1—Gliomas the cellular arrangement of which to a greater or less degree is suggestive of that of the primitive neuro-epithelium In some instances, it is probable that some of the cells are capable of differentiating into neuroblasts and glioblasts

Group 2—Gliomas arising from embryonic or adult ependymal tissue, growing into the ventricular system instead of the brain substance

Group 3—Gliomas apparently arising from cells that have migrated from the environs of the neural cavity The mother cell of such gliomas resembles the migrating undifferentiated cells of the pallium and like them is bipotential, capable of forming glioblasts or neuroblasts The malignancy of the various types depends on the degree of cellular differentiation

Group 4—Gliomas that develop in consequence of the division of fully developed cells, usually of glial type Fully matured ganglion cells are probably not capable of neoplastic proliferation

---

7 It must be admitted that while, in many respects, Cohnheim s theory of the origin of tumors as applied to those arising from brain substance, seems almost conclusive, it lacks much of being definitely proved Most of the investigators on the subject, particularly the Germans stress its importance, and according to Bielschowsky it is indispensable in explaining the origin of the gliomas Their association with congenital malformations of the brain, with malformations of the viscera and the extremities and with atypical development (status thymicus), as well as their occasional multiplicity, are strong arguments in favor of this conception

Group 5—Tumors arising from the appendages of the brain, the pineal and the pituitary glands [8]

Group 1—It has not been my good fortune to find a case of the kind of gliomas included in group 1 They are rare, and for their essential characteristics I am dependent on reports of cases in the literature Such tumors have a greater or less tendency to form primitive arrangements of their constituent cells Bailey and Cushing included them in the terms of medullo-epithelioma and neuro-epithelioma

The medullo-epithelioma is evidently a tumor composed of reduplications of bandlike masses of cells that suggest the medullary tube in the early days of embryonic life These cells may be anticipated as being too immature to be classified in most instances, but it is possible that some of them might have differentiated later into stages suggestive of glioblasts or neuroblasts These tumors are usually malignant, and mitoses are numerous, hence it is unlikely that the cells progress far in the histogenic process

The second type, the neuro-epithelioma, presents a somewhat different picture While in some instances the cells may be arranged in layers about cavities of various sizes, the tendency is to form rosets of what are evidently primitive ependymal cells, as cilia have been demonstrated in some instances In reporting a case of this type, Ribbert [9] mentioned the occurrence of both glioblasts and neuroblasts and suggested the name of spongioneuroblastoma for it If his observations were correct, this tumor presents some tendency to differentiate into the various essential constituents of embryonal nervous tissue Bucy and Muncie [10] reported the presence of cells impregnated by the reduced silver method, but since they considered the method as utilized to be nonspecific, they attached no significance to the observation With Bailey and Cushing, I am inclined to believe that this tumor is less primitive than the medullo-epithelioma, and further that it is capable of some degree of differentiation into glial and ganglionic daughter elements

Group 2—Tumors of this group, arising from embryonal or adult ependymal cells, grow internally into the canal system rather than externally into the brain substance They show no tendency to differentiate into cells other than of their own type In specific preparations

8 The word "pituitary" is here used advisedly, as tumors of the posterior lobe, the only portion of the organ of neural origin, are practically unheard of The adenomas and carcinomas of the pars anterior and the congenital cysts arising from the remains of the craniopharyngeal canal are not true tumors of the brain

9 Ribbert H Ueber das Spongioblastom und das Gliom, Virchows Arch f path Anat **225** 195, 1918

10 Bucy, P C, and Muncie, W C Neuroepithelioma of the Cerebellum Am J Path **5** 157 1929

of typical ependymal gliomas (ependymoblastomas), I found nothing suggestive of glioblasts or neuroblasts Bailey[11] originally divided ependymal gliomas into ependymoblastomas and ependymomas, but the tendency of others is to group them all under ependymomas[12] Roussy, Lhermitte and Cornil included them under the term of ependymogliomas[13]

It is reasonable to include tumors growing from the choroid plexus in this group, as the mother tissue is modified ependyma Recent studies have elaborated the details of this rather interesting but rare form of intracranial tumor[14]

Group 3—Tumors of this group consist essentially of round or oval indifferent cells the progenitors of which have become separated in a variable degree from the neural cavity If they show any tendency to differentiate, owing to a slower rate of growth, embryonal forms of glioblasts and neuroblasts are frequently found The various members of the group will be considered separately

The medulloblastoma, introduced as a distinct entity by Bailey and Cushing,[15] is a tumor that characteristically arises from the roof of the fourth ventricle It likely has its beginnings in the indifferent cells of the anterior medullary velum found in a large percentage of normal brains It seems evident that the primary cell is round or oval and is fairly uniform in size and shape Its daughter cells, medulloblasts, develop tails, which are not impregnated for the most part by the specific methods A few cells seem to evidence their bipotentialities by developing into glioblasts or neuroblasts Bailey and Cushing observed that the spinal metastases are composed of the small round or oval cells, which is further evidence that they are the primary and hence more malignant form of cell In one of my cases, I found pseudorosets that resembled those of the ependymoblastomas and that may have been due to an inclusion of ependymal "rests" in a developing

11 Bailey, Percival A Study of Tumors Arising from Ependymal Cells, Arch Neurol & Psychiat **11** 1, 1924

12 Penfield, Wilder Principles of the Pathology of Neurosurgery, Nelson's Loose-Leaf Living Surgery, New York, Thomas Nelson & Sons, 1927, vol 2, pp 329 and 333

13 Roussy, G, Lhermitte, J, and Cornil, L Essai de classification des tumeurs cerebrales, Ann d'anat path **1** 333, 1924

14 Davis L E, and Cushing, H Papillomas of the Choroid Plexus, with a Report of Six Cases Arch Neurol & Psychiat **13** 681, 1925 Van Wagenen, W P Papillomas of the Choroid Plexus Report of Two Cases, One with Removal of Tumor at Operation and One with "Seeding" of Tumor in the Ventricular System, Arch Surg **20** 199, 1930

15 Bailey, P and Cushing, H Medulloblastoma Cerebelli A Common Type of Midcerebellar Glioma of Childhood, Arch Neurol & Psychiat **14** 192, 1925 1925

medulloblastoma[16] This group of tumors is to be made the subject of further study

The tumor long known as the gliosarcoma and more recently as spongioblastoma multiforme[17] or glioblastoma multiforme[18] I have come to call neuroglioblastoma because in most of the twenty-eight cases of this type that I have studied, I have been able to find neuroblasts, as well as glioblasts While this fact has not been considered by recent writers, many of the earlier observers had in mind the possibility that embryonic forms of nerve cells occurred in the various gliomas[19] Not unlike the medulloblastoma, it has for its essential cell an apolar bipotential cell, which in some cases constitutes the greater mass of the constituent elements In the slower growing tumors, apolar, unipolar and bipolar (and occasionally multipolar) glioblasts and neuroblasts are to be found From analogy, this type of tumor is derived from an indifferent cell that has migrated farther from the environs of the neural canal and, after lying dormant until adult life, has assumed neoplastic characteristics (according to the cell rest theory of origin) These cells may have been cut off and isolated by the developing fibers

16 It is not to be surprised at that ependymal tissue should be found occasionally in medulloblastomas, when it is realized that the roof of the fourth ventricle seems to be the common site of origin of both types of tumors In the case referred to, it was difficult to determine what the nature of the tumor was Its cells were largely those of medulloblastoma, some of which had differentiated into neuroblasts It contained many pseudorosets typical of ependymoblastoma (with central blood vessel), and many of its cells contained blepharoplasts suggestive of ependymal cells

17 Globus, J H, and Strauss, I Spongioblastoma Multiforme, a Primary Malignant Form of Brain Neoplasm Its Clinical and Anatomic Features, Arch Neurol & Psychiat **14** 139 (Aug) 1925

18 Bailey, Percival Further Remarks Concerning Tumors of the Glioma Group, Bull Johns Hopkins Hosp **40** 354, 1927 Buckley, R C Tissue Culture Studies of the Glioblastoma Multiforme, Am J Path **5** 467, 1929

19 The conception that gliomas contain nervous elements is an interesting one to trace in the literature It had its birth, apparently, in the studies of Klebs, who, wrongly interpreting the nature of the engulfed and degenerating ganglionic elements in the margins of invasive gliomas, applied the name of neurogliomas to this group of tumors Since that time the presence of neuronic elements has been occasionally suggested but stressed little In the drawings of Bramwell and Stroebe can be seen cells with vesicular nuclei and enclosed darkly staining nucleoli, evidently neuroblasts Such elements were presumed to be present in neuro-epithelioma by Ribbert, and are now proved to be present in gangliogliomas (ganglioneuroma, gangliogliomeuroma) Bailey and Cushing further found them in the medulloblastomas, and my investigations seem to establish their presence in most cases of neuroglioblastoma in this series (those in which the cells tended to differentiate) and in the few cases of astroblastoma the tissues of which were suitable for study The presence of neuronic elements in gliomas has been considered in an abstract way by Storch, Borst and Meyer and more recently by Roussy, Lhermitte and Cornil[13]

of the corpus callosum, which the tumor so frequently involves Its close relation to the medulloblastoma is further suggested by the occasional tendency of its cells to form pseudorosets, identical in appearance with those of the latter tumor Tooth[20] found them in great numbers in one of his cases, and he described them under the term of "annulation forms"

The position of the astroblastoma is not entirely clear There were but three cases in the series under consideration, and I do not feel free to draw positive conclusions From its tendency to radiate about the blood vessels, from the presence of cells similar to those in the neuroglioblastoma, and from its less malignant characteristics, the relative position assumed for it by Bailey and Cushing seems logical In the few cases that have come to my attention, I have been able to find local "developing nests" of neuroblasts with the reduced silver method These cells seemed to be largely unipolar In this sense, the astroblastoma has a similar origin in an indifferent cell which has a tendency to differentiate more completely The tumor demands further study

The last of the tumors in this group, commonly but incorrectly known as the ganglioneuroma, has been shown to be composed of embryonal and adult forms of both glial and ganglionic elements The presence of both types of cell has been recognized by the German investigators for many years, and they indicate this fact by calling the tumor a "ganglioglioneuroma" In the series of gliomas under consideration, I have found three unquestioned cases and two others that seem to be a combination of it and a neuroglioblastoma multiforme To specify the nature of the constituent cells, I have adopted the name suggested but not utilized by Ewing,[21] that of ganglioglioma It is undoubtedly more common than usually supposed and should be thought of when a small, fairly well circumscribed glioma is encountered in the cerebral hemispheres or the floor of the third ventricle It is likely that many of the cases described in the literature as cases of "neuroma centrale" must be of this type (see especially those of Josephy[22] and MacPherson[23]) The studies on this tumor will appear in forthcoming contributions[24]

---

20 Tooth, H H Some Observations on the Growth and Survival Period of Intracranial Tumours, Based on the Records of 500 Cases, with Special Reference to the Pathology of the Gliomas, Brain **35** 61, 1912

21 Ewing, J, quoted by Perkins, O C Ganglioglioma, Arch Path **2** 11 1926

22 Josephy, H Ein Fall von Parobubie und solitarem zentralem Neurom, Ztschr f Neurol u Psychiat **93** 62, 1924

23 MacPherson, D J Studien uber den Bau und die Lokalisation der Glom, mit besonderer Beruchsichtigung ihres Missbildungscharakters, Arb a d neurol Inst a d Wien Univ **27** 123, 1925

24 Courville, C B Ganglioglioma Tumor of the Central Nervous System, Arch Neurol & Psychiat **24** 439, 1930 Ganglioglioma, a Further Report, with Special Reference to Those Occurring in the Temporal Lobe ibid to be published

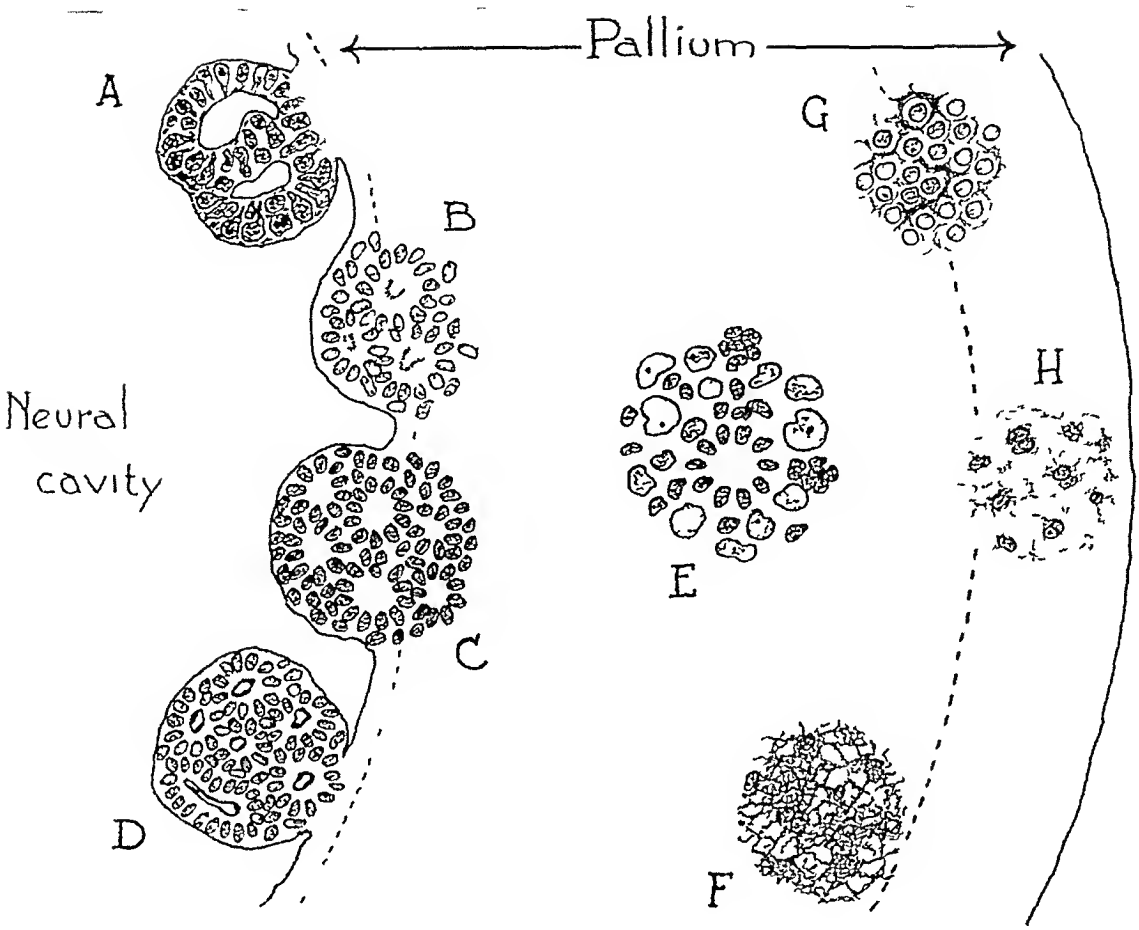

Fig 1—Diagrammatic schema indicating the point of development of the various gliomas as compared with the embryonal pallium *A* is a medullo-epithelioma, which is formed of reduplications of cell layers suggesting the structure of the embryonal neural tube They usually project into the ventricular system *B* is a neuro-epithelioma, which usually grows into the brain substance, and its cells tend to form rosets *C* is a medulloblastoma, which grows into the cerebellum as well as downward into the fourth ventricle *D* is an ependymal glioma (ependymoblastoma, ependymoma), which grows into the ventricular system, its cells forming pseudorosets by grouping themselves about the blood vessels *E* represents a group of gliomas (neuroglioblastoma, astroblastoma and ganglioglioma), which consist of developing glial and ganglionic elements They vary in degree of differentiation and make feeble attempts to form pseudorosets *F* is an astrocytoma protoplasmaticum, developing probably from amitotic division of adult cell forms *G* illustrates the oligodendroglioma, which is composed of adult and possibly embryonic forms of oligodendroglia *H* represents astrocyoma fibrillare, which is formed by amitotic division of adult fibrillary astrocytes

The gliomas in this group, then, are composed of small round or oval cells apparently corresponding to the indifferent cells in normal neurohistogenesis These elements have a variable tendency to differentiate into glioblasts and neuroblasts The impression gained from a study of them is that there is a greater propensity to form glioblasts

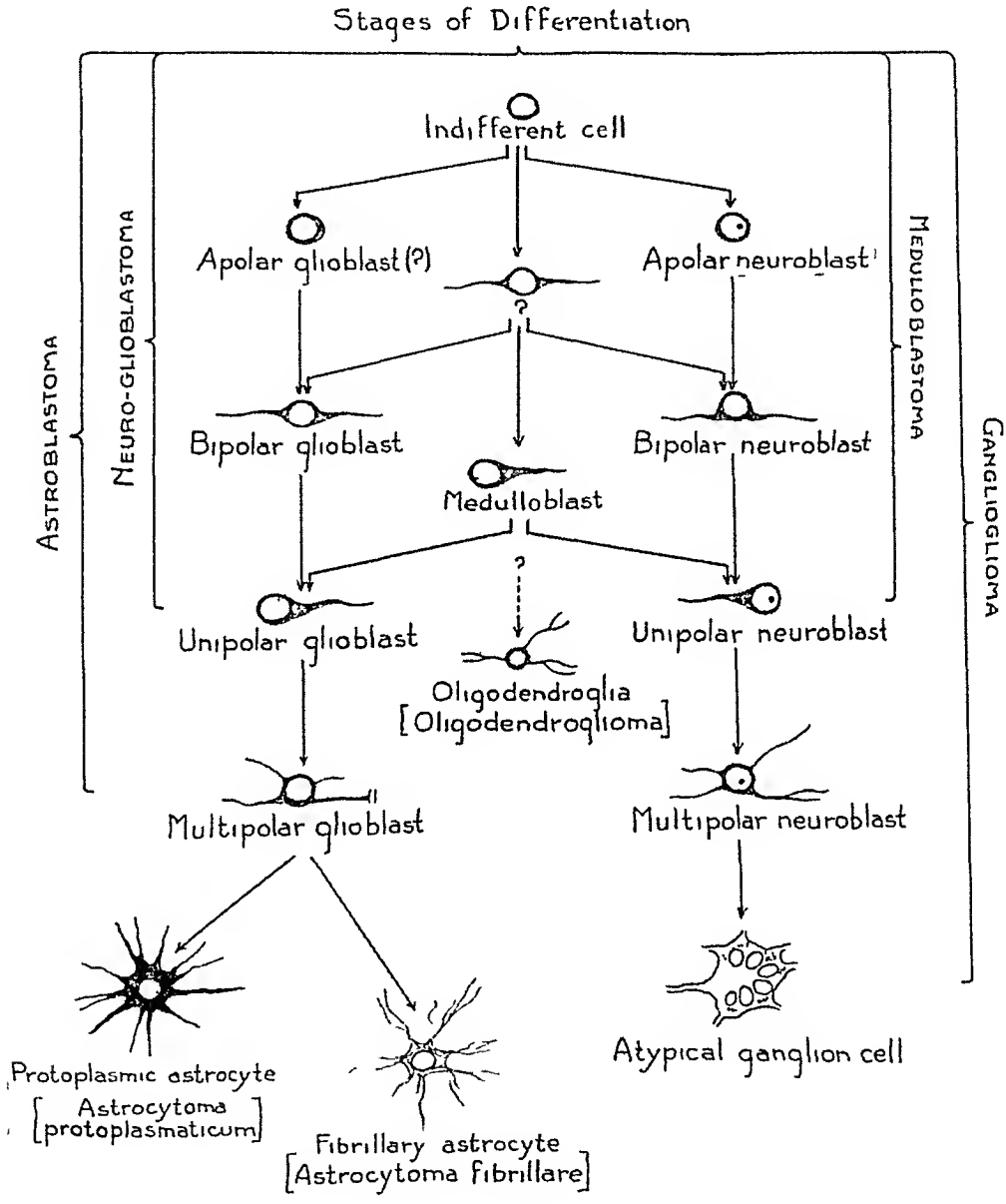

Fig 2—Schema indicating histogenic stages that may be demonstrated in the gliomas studied in this series The extent of differentiation in the various tumors is indicated by brackets The various tumors are shown to contain both developing glioblasts and neuroblasts, except those in which the name of the tumor appears below an individual cell

than neuroblasts, the proportions found in normal nervous tissue being roughly maintained This seems to be true even in the case of the ganglioglioma, according to the German investigators, though the greater size of the ganglionic elements make them the more conspicuous

Group 4—The fourth group of gliomas is composed of tumors having their origin from adult cell forms, no embryonal elements being found in their tissues The group is composed largely of astrocytomas, which structurally are made up of adult fibrillary or protoplasmic astrocytes or both From the descriptions given, it is likely that the tumor originally described by Bailey and Cushing and investigated further by Bailey and Bucy[25] under the term of oligodendroglioma should be included in this group, both from the adult character of its cells and from its apparent slow growth In tumors of this group, proliferation takes place by amitotic cell division and, as Bailey and Cushing have suggested, the tumors may be heterotropias

Group 5—This group is composed of the rather rare tumors of the pineal body which have been described by Horrax and Bailey[26] and the literature on which has been reviewed by Haldeman[27] In Bailey and Cushing's scheme, they have been included under the terms of pineoblastoma and pineoloma, depending on the resemblance to the embryonic or to the adult pineal parenchyma

COMMENT

In a general consideration of intracranial tumors, the author previously divided the gliomas into two large groups the embryonic cell and the adult all types,[28] which embraces the foregoing classification in a condensed form The conception, somewhat differently applied, was suggested by Carmichael,[29] whose line of division was not clearly drawn either from the standpoint of histogenesis or from that of gross morphology of the tumor In general, tumors of the adult cell group have a good prognosis if they admit of surgical removal Tumors of the embryonic cell group offer an increasingly good prognosis with their tendency to differentiate into adult elements

The classification described in this study undoubtedly has its imperfections, but it seems more satisfactory than one in which the effort is

25 Bailey, P, and Bucy, P Oligodendrogliomas of the Brain, J Path & Bact **32** 735, 1929

26 Horrax, G, and Bailey, P Tumors of the Pineal Body, Arch Neurol & Psychiat **13** 423, 1925

27 Haldeman, K O Tumors of the Pineal Gland, Arch Neurol & Psychiat **18** 724, 1927

28 Courville, C B Intracranial Tumors Their Pathology, Symptomatology, Diagnosis and Prognosis, to be published

29 Carmichael, E A Cerebral Gliomata, J Path & Bact **31** 493, 1928

made to place each type under a single stage in the histogenic process This cannot be done either from the standpoint of the most primitive or from that of the most advanced type of cell, for in either case overlapping must occur In the groups that I have been able to study, the classification fits with a reasonable degree of accuracy the tumors that have a similar tissue architecture This must be the ultimate criterion in any classification, for to be useful any nomenclature must suit the needs of the general pathologist, who cannot concern himself with the minutiae of all portions of the field of tumor pathology [30]

The consideration of atypical or transitional forms, as has been suggested by Bailey,[18] does not militate against the scheme, in fact, the scheme has helped in the more accurate placing of certain individual gliomas that I have encountered Furthermore, the predominance of a certain type of cell, either of glioblastic or neuroblastic type, should not be a cause for confusion, for such variations are the rule in neoplastic proliferations elsewhere in the body Bailey and Cushing found a variation in the proportion between the glioblasts and neuroblasts in the medulloblastomas, showing that they do not follow any prescribed course in their formation This is undoubtedly true of other tumors, and in the end the few cases in which the observations do not coincide with the usual ones must be judged on their tendencies and resemblances as a whole

A possible objection to this scheme of classification which must be considered is that illustrated by cases not infrequently described in which there is an apparent transformation of a benign glioma into a more malignant one The modus operandi of this change is difficult to conceive until it is decided whether gliomas have their origin in embryonic cells, according to the theory of Cohnheim, or whether they result from the assumption of embryonal characteristics by adult cells, as suggested by Ribbert It is difficult to interpret the presence of neuroblasts in a glioma by Ribbert's hypothesis, for it seems most unlikely that cells as highly differentiated and specialized as the nerve cells can form apolar, unipolar or bipolar neuroblasts As far as the gliomas are concerned, the weight of evidence seems to be in favor of their origin from embryonal cell "rests" If this is true, the malignant transformation from benign gliomas may be due to activity of undifferentiated portions of the tumor or the arousal of adjacent latent undifferentiated cells This is in accord with the frequent observation of areas of embryonal type in benign forms and vice versa It is evident that present knowledge does not permit the drawing of positive conclusions, and the ultimate solution of the problem must await further observations

30 Courville, C B, and Adelstein L J Histologic Diagnosis of Tumors of the Glioma Group, California & West Med, to be published

and experimentation There is little at hand to be used as argument against the classification proposed The conception presents a slightly different aspect of the problem and may lead to the development of further important details of the histogenesis of this group of neoplasms

SUMMARY

Based on the study of the cell types in a series of fifty gliomas, a classification of tumors of the group is suggested, which is based on the course of development of the constituent cells In the embryonal gliomas, the differentiation of the various elements is compared to stages in normal neurohistogenesis as it is now understood The histologic aspects of the tumor are dependent on the stage reached in the histogenesis of the fundamental cell and the location of the hypothetical "mother cell" when it assumed neoplastic activity Regressive changes may also alter the primary appearance of the tumor

The embryonal gliomas seem to be composed of undifferentiated cells that are bipotential, being capable of forming either glioblasts or neuroblasts in the course of their development Such cells pass through various stages suggestive of normal neurohistogenesis

THE EFFECT OF INJURY ON CELLULAR PERMEABILITY TO WATER *

BALDUIN LUCKÉ, M D
AND
MORTON McCUTCHEON, M D
PHILADELPHIA

Permeability to water is a property of cells in general It may be defined as the amount of water that enters or leaves the cell per unit of time, per unit of cell surface and per unit of osmotic driving force In previous communications, it has been shown that permeability of the living cell to water is affected by a number of factors, such as temperature and chemical composition of the medium [1] In this paper, we shall present evidence that injury to the cell is yet another factor causing alteration of its permeability to water

For a study of the relation of injury to permeability, it is obviously necessary to select a cell permitting both recognition of injury by decisive criteria and precise measurement of permeability The spherical unfertilized egg of the sea urchin, *Arbacia punctulata,* is admirably suitable Injury is readily recognized on the addition of sperm after the cells have been returned to their natural medium, sea water, at the conclusion of an experiment normal cells shortly undergo cleavage, while injured cells divide atypically or not at all

METHOD OF MEASURING PERMEABILITY OF CELL TO WATER

Permeability of the cell to water is determined by the following method [2] Cells from a single specimen of *Arbacia* are placed in sea water of the desired osmotic pressure,[3] at constant temperature In hypotonic solution, water enters under the driving force of osmotic pressure, and the cell swells, conversely, the

* Submitted for publication, June 6, 1930

* From the Laboratory of Pathology, School of Medicine, University of Pennsylvania, Philadelphia, and the Marine Biological Laboratory, Wood's Hole, Mass

1 McCutcheon, M, and Lucke, B The Kinetics of Osmosis in Living Cells, J Gen Physiol **9** 697, 1925-1926, The Effect of Certain Electrolytes and Non-Electrolytes on Permeability of Living Cells to Water, ibid **12** 129, 1928 Lucke, B, and McCutcheon, M The Effect of Valence of Ions on Cellular Permeability to Water, ibid **12** 571, 1929

2 For details of method see McCutcheon and Lucke (footnote 1, first reference) and Lucke and McCutcheon (footnote 6)

3 In this paper, the concentration of the sea water is expressed in per cent of isotonic (100 per cent) sea water Thus 60 per cent sea water means a solution consisting of 60 parts of sea water and 40 parts of distilled water

cell shrinks when placed in a solution hypertonic with respect to the cell's interior The changes of volume proceed relatively slowly and permit accurate measurement of the diameter at intervals of a minute with a filar micrometer Since the cells are spherical, diameters are easily converted to surface area and volume The course of change in the volume is satisfactorily described by certain equations by which permeability may be computed[4] For this purpose, the mean volume of several cells (generally six) is plotted against time, and a smooth curve drawn through the points (chart 1) The rate of passage of water is given by the rate of change in volume, and is obtained from the slope of the curve at a given time (by drawing a tangent to the smooth curve) This value is divided by cell surface and the difference in pressure between the interior of the cell and the medium The resulting numeric quantity is termed the permeability of the cell to water, at a given time, the units here used are cubic microns of water per minute, per square micron of cell surface, per atmosphere of pressure[5]

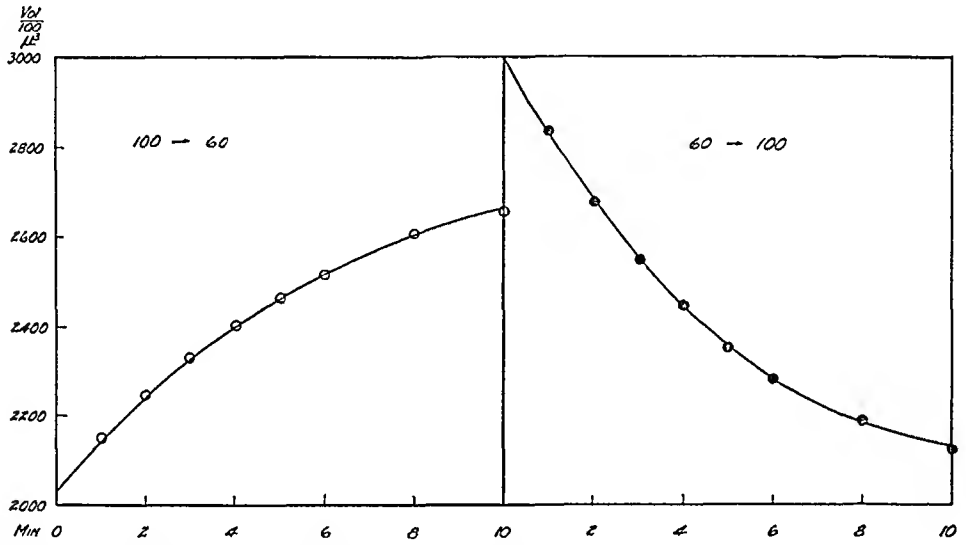

Chart 1 —Graphs illustrating the course of swelling and of shrinking of living uninjured cells in anisotonic solutions at constant temperature (18 C) The mean volume of six cells is plotted against time The left graph shows the course of swelling (endosmosis of water) , cells removed from their natural medium (100 per cent sea water) were placed in 60 per cent sea water, and measured at intervals of one minute In the right graph, shrinking (exosmosis of water) is illustrated Cells were first allowed to swell in 60 per cent sea water for forty-five minutes, the swollen cells were then transferred to 100 per cent sea water, and measured at intervals of one minute

4 McCutcheon and Lucke (footnote 1, second and third references)

5 Mathematically expressed,

$$\text{Permeability} = \frac{\frac{dV}{dt}}{S \quad (P - P_{ex})}$$

where $\frac{dV}{dt}$ is the rate of passage of water into or out of the cell (and hence the rate of change of volume), S is the area of the cell surface, P the osmotic pressure of the interior of the cell, P_{ex} the osmotic pressure of the external medium and $(P - P_{ex})$ the difference in osmotic pressure between the interior of the cell at time *t*, and the medium S is computed directly from the volume (V) read from the curve at time *t* P is calculated from the equation $P_o \ V_o = P \ V$,

By the method described, we have studied the permeability to water of cells injured by exposure to heat and by exposure to anisotonic solutions

THE EFFECT OF INJURY BY HEAT ON PERMEABILITY TO WATER

Cells were placed in sea water of different temperatures (constant to ± 1 C) for a given number of minutes After being cooled in sea water at room temperature, they were transferred to a hypotonic solution and measured at intervals of one minute In a previous study, we had found that exposure to temperatures of 52 and 60 C causes irreversible gelation of protoplasm and increase of volume in isotonic solution [6] In the range of temperature employed in the present experiments (from 30 to 45 C), the cells were definitely injured or killed, but the protoplasm was not so altered as to lead to swelling in ordinary sea water Such cells, however, retained their property of swelling in hypotonic, and shrinking in hypertonic, solution, provided that the exposure to heat was not prolonged For example, cells heated for less than sixteen minutes at 44 C were injured, but remained capable of swelling in hypotonic sea water, while cells heated for as long as sixteen minutes were firmly coagulated and rendered incapable of a change in volume The behavior of these injured cells differs greatly from that of normal cells This is shown in chart 2 Cells injured by heat were placed in different hypotonic solutions, it may be seen in chart 2 that they swelled rapidly for several minutes, after which they shrank Normal cells under similar conditions swell until constant volume (i e, equilibrium) is attained after many minutes or even hours, or until they burst, having reached their elastic limit

From experiments of this kind it is apparent that injured cells do not lose their semipermeability at once or completely In injured as in normal cells, the degree of the change in volume varies inversely with the osmotic pressure of the medium, being greatest in the most dilute solution But while in normal cells the amount of dissolved substances that can enter or leave the cell is inappreciable under the conditions of the experiments, in injured cells escape of contents takes place and the cell may shrink though in a hypotonic medium

---

where P_0 is the osmotic pressure of ordinary sea water (taken as 22 atmospheres), V_0 the volume of the cell in its natural medium, V the volume at a given time, and P the osmotic pressure inside the cell at a given time (For further details see McCutcheon and Lucke [footnote 1, second and third reference]) This differential equation is used in its integrated form in "Further Studies on the Kinetics of Osmosis in Living Cells," to be published In this paper, a theoretical treatment of osmosis is given

6 Lucke B and McCutcheon, M Reversible and Irreversible Swelling of Living and of Dead Cells, Arch Path 2 846 1926

Experiments were now planned to determine whether quantitative differences exist between injured and normal cells in regard to permeability to water

In the first group, we varied the length of time during which cells were exposed to heat The results of a typical experiment are shown in table 1 Here cells exposed to a temperature of 39 C for different periods were caused to swell in a hypotonic solution The table shows

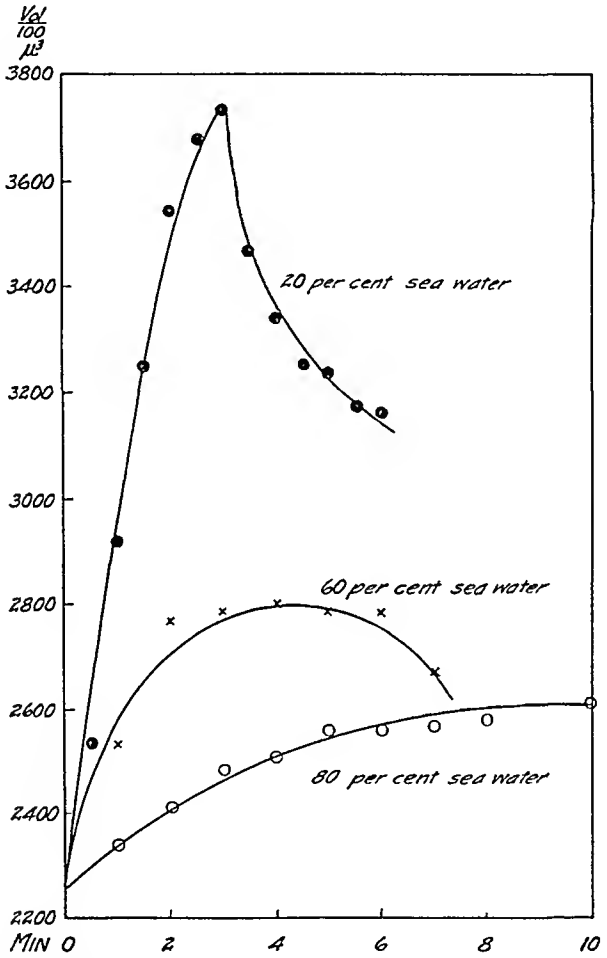

Chart 2—The effect of injury by heat on permeability to water Cells placed for four minutes in ordinary sea water heated to 44 C were transferred to several hypotonic solutions (20, 60 and 80 per cent sea water) and measured at intervals of one minute The mean volumes of three cells are plotted against time It is seen that the injured (or dead) cells swell rapidly in 20 and 60 per cent sea water and then shrink, though in a hypotonic medium

that permeability to water varies directly with the length of exposure to injury This relation is most clearly brought out in the initial measurements, before further changes occurred in the cell membrane Thus the values of permeability determined at the first minute of the swelling process form a regular series, cells heated for two minutes

having the lowest permeability (0 076), while those heated for sixteen minutes showed an increase in permeability of almost 300 per cent over the unheated controls The initial increase in permeability may be followed by a further increase, or the gradual escape of dissolved substances from the injured cells may lead to an apparent decrease

In the next group, the temperature was varied and the time of exposure held constant It was again found that permeability to water varied with the intensity of the injurious factor A typical experiment is represented in table 2 Here cells were exposed for four minutes to different temperatures, and then caused to swell in a hypotonic solution It may be seen that exposure to 39 C causes an increase in permeability,

TABLE 1—*The Effect of Exposure to 39 C for Varying Lengths of Time on Permeability to Water* *

Intervals at which Permeability was Calculated	Permeability Following Increasing Periods of Exposure					
	0	2 Min	4 Min	8 Min	12 Min	16 Min
1	0 069	0 076	0 081	0 084	0 119	0 172
2	0 072	0 080	0 080	0 090	0 119	0 093
3	0 074	0 078	0 079	0 099	0 104	0 058
4	0 070	0 070	0 079	0 108	0 083	
5	0 068	0 066	0 075	0 119		

* Time of exposure is given in the top line, 0 exposure is the control experiment The solution in which the cells were caused to swell after exposure was 40 per cent sea water at 20 C The values of permeability were determined for successive minutes and represent the number of cubic microns of water entering the cell per minute per square micron of cell surface per atmosphere of pressure It is seen that at the first minute (before further changes had occurred in the cell membrane) the values for permeability form a regular series and vary directly with the length of exposure to the injurious agent, at later minutes irregularities in values develop Fertilization tests showed atypical division after two minutes exposure, and no cleavage after longer exposure

exposure to 41 C a still greater increase, while exposure to 45 C brings about coagulation, so that permeability can no longer be measured

From these and similar experiments the conclusion may be drawn that injury of cells by heat manifests itself by an increase in permeability to water, and that this increase is proportional to the degree of injury

INJURY BROUGHT ABOUT BY EXPOSURE TO ANISOTONIC SOLUTIONS

When cells are placed in hypotonic solutions of different osmotic pressures, the rate of increase in volume is of course very different, being most rapid in the most dilute solution and slowest in the least dilute But when the rates for entrance of water are divided by osmotic driving force and cell area these differences disappear, permeability to water, at least for the first several minutes is independent of the osmotic pressure of the medium At later minutes, however, differences in permeability may appear in the sense that while there is a slight decrease

in permeability in higher concentrations,[7] there is a marked increase in lower concentrations When the cells are returned to ordinary sea water and inseminated, it is found as a rule that in cases in which permeability has increased, cleavage fails or is atypical, whereas in cases in which permeability has not increased, there is no prevention of subsequent normal cleavage It is believed that increased permeability in such experiments is an expression of injury due to too rapid entrance of water An experiment illustrating this case is recorded in table 3 In this experiment, permeability was calculated at successive minutes for

TABLE 2—*The Effect of Four Minute Exposures to Varying Temperatures on Permeability to Water*

Degrees of Temperature C	20	31	36 5	39	41	45
Permeability	0 089	0 091	0 083	0 117	0 137	Coagulated

The concentration of sea water employed for swelling was 50 per cent at 20 C The values of permeability were calculated for each series at the third minute It is seen that exposure to 39 and 41 C causes an increase in permeability

TABLE 3—*Permeability to Water Calculated at Successive Minutes for Cells in 30, 40 and 50 Per Cent Sea Water*

Intervals at which Permeability was Calculated Min	Permeability in Various Concentrations of Sea Water		
	30%	40%	50%
2	0 086	0 069	0 069
3	0 089	0 068	0 069
4	0 092	0 064	0 062
5	0 098	0 063	0 064
6	0 103	0 063	0 060
8	0 117	0 076	0 058
10		0 097	0 056
Cleavage	All cytolyzed	50% divided, of these one-half atypical	All divided, 90% typical

The values give the number of cubic microns of water entering the cell, per square micron of surface per atmosphere of pressure The cells in 30 per cent sea water are injured from the beginning and give high values of permeability, which increases from minute to minute, In 40 per cent sea water, permeability increases after the sixth minute, owing to injury, the values for permeability of cells in 50 per cent sea water are normal

cells in three different hypotonic solutions In 50 per cent sea water, permeability was normal, i e, it declined slightly, subsequently, all cells underwent cleavage, which was normal in nine-tenths of the cells In 40 per cent sea water, permeability was the same as in the preceding dilution for six minutes, then it rapidly increased Subsequently, only one half of the cells divided and one half of these were atypical In 30 per cent sea water, permeability was high from the start (this is unusual) and increased continually, no cells remained capable of cleavage, all eventually undergoing cytolysis

7 This decrease is due, at least in part, to the fact that osmotically inactive substances within the cell are neglected in the present method of calculation

We now come to a much more favorable type of experiment for demonstrating the relation of permeability to injury by hypotonic solutions Under the conditions just described, injury occurs only after several minutes and therefore does not affect the initial permeability of the cell We shall now describe experiments in which unheated cells previously swollen in various hypotonic solutions are returned to ordinary sea water and allowed to shrink In such cases, the injury has been inflicted, if at all, during the swelling process, and therefore might be expected to affect the rate of shrinking from the first instant

TABLE 4—*The Effect of Exposure to Hypotonic Solutions of Varying Degree on Permeability of Normal Cells*

Concentration of Sea Water %	Permeability	Per Cent Typically Divided
30	0 123	95
35	0 136	95
40	0 135	95
45	0 139	95
55	0 113	95
60	0 139	95

Cells were swollen for seven minutes in 30 35 40 45 55 and 60 per cent sea water and then returned to isotonic sea water The course of exosmosis of water was studied at 14 C Permeability was calculated at the third minute The values of permeability show no drift On subsequent fertilization 95 of 100 cells divided normally in all cases

TABLE 5—*The Effect of Exposure to Hypotonic Solutions of Varying Degree on Permeability of Injured Cells*

Concentration of Sea Water %	Permeability	Cleavage
35	0 330	Mostly cytolyzed, 10 per cent atypically divided
40	0 227	Many cytolyzed, 25 per cent atypically divided 25 per cent typically divided -
50	0 183	70 per cent typically divided rest not divided
55	0 216	80 per cent divided of which one-fourth are atypical
60	0 107	80 per cent divided all typical

Cells swollen for seven minutes in the various hypotonic solutions were returned to isotonic sea water and exosmosis of water studied at 18 C Permeability was calculated at the third minute The values of permeability are high (except in 60 per cent of sea water) and vary with the degree of injury as shown by the fertilization tests

Before citing an example of this type of injury, it should be pointed out that such injury may often be avoided, even in very dilute solutions, provided that the solution is at low temperature (from 10 to 15 C) exposure is not too prolonged, and the cells are in good condition to start with Under these conditions when cells previously swollen in various hypotonic solutions are returned to ordinary sea water and allowed to shrink, the permeability in shrinking is found to be independent of the osmotic pressure of the solution used to induce swelling Corresponding fertilization tests are normal The data on an experiment illustrating this are given in table 4 Cells previously swollen for seven minutes in six different hypotonic solutions were caused to shrink in ordinary sea water The values of the perme-

ability of cells from the several different solutions show no drift, and in all cases 95 of 100 cells subsequently divided normally

A strikingly different result was obtained if injury occurred during the swelling process In table 5 is recorded an experiment in which cells were allowed to swell for seven minutes in five different hypotonic solutions When the cells were returned to isotonic solution, permeability [8] was found to vary from 0 107 in cells caused to shrink from 60 per cent sea water, to 0 330 in cells caused to shrink from 30 per cent sea water, a difference of threefold A corresponding difference was observed in the results of insemination, though there was evidence of slight injury even in the 60 per cent cells

A final typical experiment is recorded in table 6 Here cells were kept for four and a half hours in several hypotonic solutions, and then caused to shrink in isotonic sea water In four of the dilutions, perme-

TABLE 6—*The Effect of Exposure to Various Hypotonic Solutions for Four and Five-Tenths Hours on Permeability*

Concentration of Sea Water %	Permeability	Cleavage
50	0 150	30 per cent divided, rest cytolyzed
55	0 083	90 per cent typically divided
60	0 089	95 per cent typically divided
65	0 093	95 per cent typically divided
70	0 094	95 per cent typically divided

Cells swollen for four and one-half hours in various hypotonic solutions were then returned to isotonic sea water, and exosmosis of water studied at 18 C Permeability was calculated at the third minute It is seen that the long exposure did not cause injury except in the 50 per cent dilution The values of permeability are normal except those for the injured cells, which are high

ability was normal, and fertilization tests showed no injury In the most dilute solution, the cells were injured and had high permeability

From these and similar experiments it is apparent that injury of cells by hypotonicity of the medium manifests itself by increased permeability to water, and that this increase varies directly with the degree of injury as shown by fertilization tests

COMMENT

Many investigators have studied the morphologic alterations of cells injured by a variety of agents The functional properties of injured cells have received much less attention Of these, the one most intensively studied in relation to injury is permeability of the cell to dissolved substances With a variety of material and by several different methods, the conclusion has been reached that injury renders

8 As has been stated, permeability varies but little during the first several minutes of an experiment as a matter of convenience, permeability was calculated at the third minute The values thus obtained agree closely with the values obtained by the integrated equation (see footnote 5)

cells more permeable to different substances that normally are prevented from entering or leaving the cell[9] However, little precise information is available on abnormal permeability to water One such investigation is that of Landis, who found that injury to capillaries markedly increased their permeability to water[10] Landis here dealt with the transport of water across the capillary wall, in the present experiments, we are concerned with the permeability of cells themselves

It is a well known fact that while cells are normally permeable to water, the degree of permeability is a somewhat restricted one, so that water enters or leaves the cells relatively slowly[11] In the present experiments, it has been shown that injury to the cell increases its permeability to water The results of our experiments are in harmony with studies of other investigators on permeability to dissolved substances

SUMMARY

The unfertilized egg of the sea urchin *Arbacia punctulata,* was used as a cell in which injury can readily be recognized and permeability to water accurately measured

It was found that injury (induced by high temperature and by anisotonic solutions) causes a marked increase in cellular permeability to water, and that this increase in permeablity can be correlated with the degree of injury

The method described affords a convenient measure of injury

9 Osterhout, W J V Injury, Recovery, and Death, in Relation to Conductivity and Permeability, Philadelphia, J B Lippincott Company, 1922, Exosmosis in Relation to Injury and Permeability, J Gen Physiol **5** 709, 1923 Brooks, S C Conductivity as a Measure of Vitality and Death, ibid **5** 368, 1923

10 Landis, E M Micro-Injection Studies of Capillary Permeability I Factors in the Production of Capillary Stasis, Am J Physiol **81** 124, 1927, II The Relation Between Capillary Pressure and the Rate at which Fluid Passes Through the Walls of Single Capillaries, ibid **82** 217, 1927

11 Northrop, J H Kinetics of the Swelling of Cells and Tissues, J Gen Physiol **11** 43, 1927

TRUNCUS SOLITARIUS PULMONALIS

A RARE TYPE OF CONGENITAL CARDIAC ANOMALY*

PHILLIP F SHAPIRO, M D
CHICAGO

From time to time, a congenitally anomalous heart is found that possesses only a single arterial trunk Abbott[1] collected twenty-three such cases It is usually a heart that is severely deformed, biloculate or triloculate, with many other defects associated with the arterial one

At first glance, the single arterial trunk would be considered as a persistent truncus communis, in which the original common arterial trunk issuing from the bulboventricular loop had failed to divide into its appointed aortic and pulmonic parts But cases of the latter are, indeed, rare I have been able to find only two that may be accepted, one reported by Preisz[2] in 1890, and the other more recently by Santa Cruz[3] Incomplete division of the common trunk is seen much more frequently than this total failure to divide

In most of the cases of single arterial trunk that are regarded as cases of truncus communis, complete division has occurred But subsequently one side involutes, leaving the other to carry the load of both The single vessel remaining is therefore not a truncus communis, but a truncus solitarius which has lost its partner Such mishaps can readily occur When, as in the case to be described, there is a large defect in the ventricular septum, flow relationships are so disturbed that the aortopulmonary septum develops irregularly The passage of the bulk of the the circulation through one trunk still further reduces the other until the latter may be completely, or almost completely, obliterated Then only a small vestige of the second vessel or no trace of it may be found

Usually, the pulmonic side is obliterated, and the single vessel left behind is a truncus solitarius aorticus Several such cases have been reported[4] The solitary trunk is identified as the aorta by the origin of

---

* Submitted for publication, April 14, 1930

* From the Department of Pathology of the Cook County Hospital

1 Abbott, M, in Osler, W Modern Medicine, Philadelphia, Lea & Febiger, 1925

2 Preisz, H Beitrage zur Lehre von den angeborenen Herzanomalien, Beitr z path Anat u z allg Path **7** 247, 1890

3 Santa Cruz, J Z Common Ventricular Opening for Aorta and Pulmonary Artery, J Philippine Islands M A **5** 295, 1925

4 Moenckeberg, J G Die Missbildungen des Herzens, in Henke and Lubarsch Handbuch der speziellen pathologischen Anatomie und Histologie, Berlin, Julius Springer, 1924, vol 2 Dickson, W E A Congenital Abnormality of the Heart and Blood Vessels, J Anat & Physiol **48** 210, 1910

the coronary arteries from behind the semilunar cusps The lungs are then supplied by branches arising directly from the aortic trunk or by the ductus botalli or by the bronchial arteries or by anomalous branches from the great vessels of the neck

Much more rarely does the aortic side involute and leave a truncus solitarius pulmonalis In this case, the sinuses of Valsalva are free from coronary openings Abbott [1] referred to such a case described by Farre and to another by Forster In each a single, large vessel, the pulmonic trunk, arose from the ventricle and was connected to the transverse aorta by a widely patent ductus arteriosus This trunk gave off the pulmonary arteries, while the great vessels of the neck and arms arose from the beginning of the transverse aorta They then described "a single vessel arising from the concavity of the aortic arch, and running down alongside the pulmonic trunk to the base of the heart, where it divided into two coronary vessels" This was evidently the vestige of the ascending aorta

Recently, I studied a case of truncus solitarius aorticus,[5] with particular reference to Spitzer's theory of detorsion defect [6] For comparison and also because of its greater rarity, I report the following case of truncus solitarius pulmonalis

A colored boy, R H, was born in a spontaneous, normal delivery at full term The mother was a healthy, young primipara, 18 years of age Her Wassermann reaction was negative The child lived for only four days, and died with the clinical diagnosis of bilateral bronchopneumonia

The heart weighed 30 Gm, as compared with the normal weight at birth of 24 Gm It lay in normal position, but was made up almost entirely of the large right ventricle and the large right auricle There was an intervening, well developed tricuspid valve with its three groups of chordae tendineae The chambers on the left side of the heart were insignificantly small and only a single, large arterial trunk, 27 mm in diameter, issued from the base of the heart

No coronary artery sprang from it The orifice of the trunk was guarded by three semilunar cusps that, according to their position, could be termed as left, anteroright and posteroright As the single trunk ascended it gave off the two pulmonary arteries from its anteroleft aspect It then continued in a widely open, funnel-shaped communication with the transverse aorta At its insertion was a stump of isthmus aortae from which, crowded together, arose the innominate, the left common carotid and the left subclavian arteries

Just distal to its insertion, a single, small artery, 1 mm in diameter, took origin from the aortic arch It ran down the posteroleft aspect of the large arterial trunk and behind the origin of the pulmonary arteries, to divide at the base of the heart into an anterior descending and a left circumflex coronary branch No trace of the ascending aorta could be found other than this vessel which gave off distally

5 Shapiro, P Detorsion Defects in Congenital Cardiac Anomalies, Arch Path 9 54, 1930

6 Spitzer, A Ueber den Bauplan des normalen und missbildeten Herzens, Virchows Arch f path Anat 243 83, 1923

the branches of the left coronary artery and which was entirely independent of the large arterial trunk beside it There was no right coronary artery The left supplied the whole heart

The wall of the large right ventricle was 5 mm thick From the left aspect of the large arterial trunk, there projected into the anterior upper corner of the

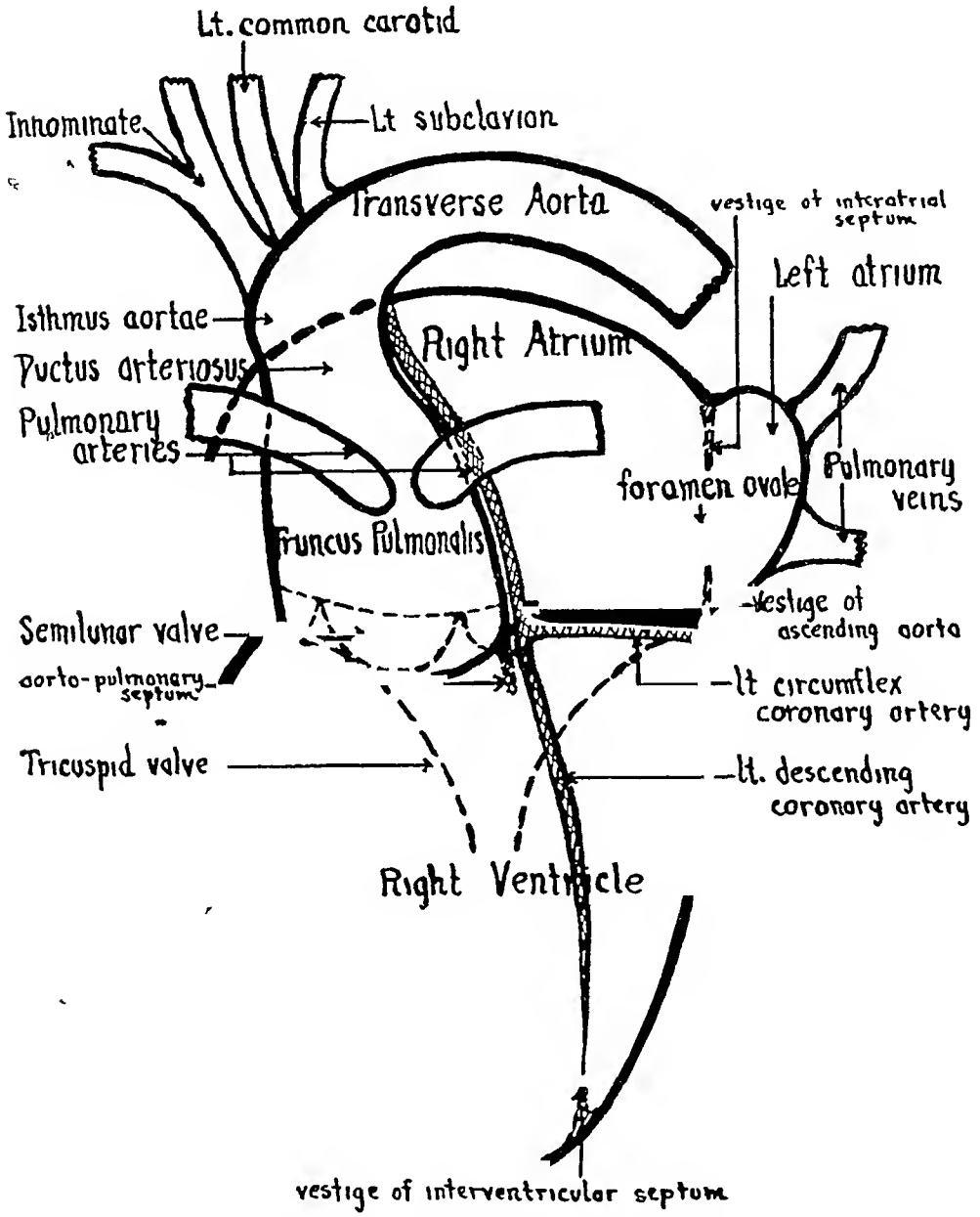

Fig 1—Diagram of heart showing truncus solitarius pulmonalis and other anomalies

ventricular chamber a small ridge of the aortopulmonary septum A small ridge also of interventricular septum was barely discernible at the apex of the large ventricular cavity The rest of the interventricular septum was absent A widely open septal defect led from the huge right ventricle into the insignificant left one

The cavity of the large right auricle was 22 mm in diameter The inferior and superior venae cavae and the coronary sinus opened into it normally It had a well developed auricular appendage The pulmonic veins emptied by two trunks, instead of the usual four, into the left auricle The small left auricle was an antechamber to the large right one It was only 3 mm deep, but carried also a small auricular appendage Inferiorly, its walls fused into the left wall of the common ventricle, so that it was completely cut off below from communication There was no mitral orifice The mitral leaflets, their three groups of chordae tendineae, and their papillary muscles had all been lost in the fusion The left auricle emptied into the right auricle only by an open foramen ovale 7 mm wide

There was no crepitation in the right upper and in most of the right middle and lower lobes The left lower and most of the left upper lobes were similarly noncrepitant The cut surface showed numerous confluent granular areas from which pus could be expressed

The other organs showed nothing unusual

The anatomic diagnosis was Truncus solitarius pulmonalis, persistent ductus arteriosus, hypoplasia of the ascending aorta, with persistence of the left coronary artery and atresia of the right, origin of the great vessels of the neck from isthmus aortae, atresia of the mitral orifice, patent foramen ovale, incomplete inclusion of the pulmonary vein in the wall of the left auricle, hypoplasia of the left uricle and vestigial left ventricle, hypertrophied right auricle and right ventricle, defective interventricular septum, and bilateral bronchopneumonia

COMMENT

This case corresponds closely to those of Farre and Forster The small vessel running from the aortic arch down the left side of the ductus arteriosus, behind the pulmonary arteries, and on down the left side of the pulmonic trunk to the base of the heart was the only vestige of the ascending aorta From it arose the coronary artery

The large single trunk was pulmonic, for it had no coronary arteries Cases are described in which, because of abnormal aortopulmonary division, the coronary arteries arise by a common trunk from the aorta One coronary artery may spring from the aorta and the other from the pulmonic trunk But never has there been reported a shift of both coronaries from the aortic to the pulmonic side An arterial trunk without coronaries is not an aorta, but a pulmonic trunk

Except for the coronary supply that was still maintained by the aortic vestige, the blood flow to the entire body was carried by the truncus solitarius pulmonalis It filled the lesser circulation through its pulmonary arteries, and then carried the systemic flow through the ductus botalli to the transverse aorta and its branches It was therefore rather large But it was truncus solitarius and not a truncus communis, for it was guarded by three semilunar cusps and not by four The aortopulmonary division had already taken place

In the original truncus communis, four proximal endocardial buds develop at the common arterial orifice There are a large pair and a small pair If development stops at this early stage, if the truncus

communis persists, the single arterial trunk arising from the heart is left with its four endocardial swellings to form four semilunar cusps Thus von Huelse,[4] Gierke and Abbott have emphasized that a single arterial trunk may be considered a true truncus communis only if it has four semilunar cusps (fig 2*a*)

If development goes on, fusion of the apposing larger pair of buds forms the aortopulmonary septum (Tandler [7]) But in forming this septum, the pair of large buds is divided into four These, with the undivided pair of small buds, make a total of six, from which six semilunar cusps are hollowed out, three for the aorta and three for the pulmonic trunk (fig 2*b*) This is the normal definite state If one side then subsequently involutes, it carries away with it three of the cusps The solitary trunk remaining is left with only its own three cusps (fig 2*c*)

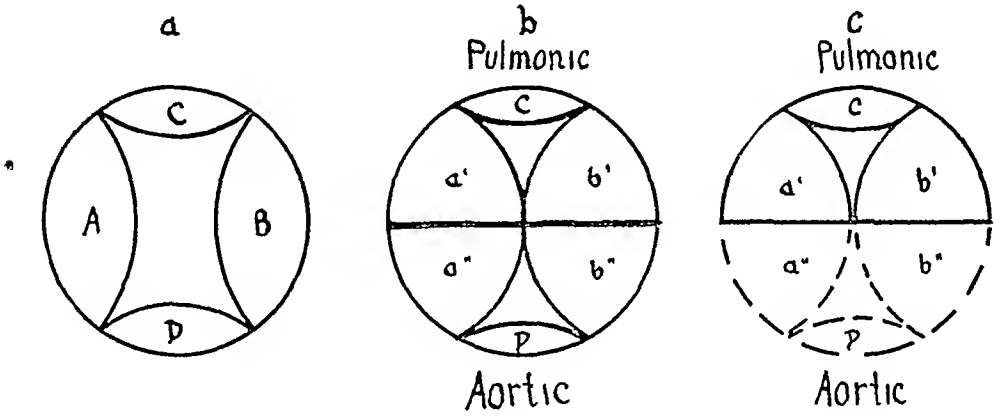

Fig 2—Diagram of orifices of truncus communis (*a*), normal aorta and pulmonary artery (*b*) and truncus solitarius (*c*)

Evidence that division had taken place in the case described was the vestige of aortopulmonary septum that projected from the left wall of the pulmonic trunk into the anteriocranial corner of the large ventricular chamber The common trunk had divided But the aortic side had then almost completely involuted and was retained only as a small vessel for the coronary supply The remaining pulmonic trunk with its allotted three semilunar cusps was left as a truncus solitarius to supply the whole body

This defect was accompanied by so many other severe cardiac abnormalities as to indicate a grave deficiency in cardiac growth vitality It is Spitzer's theory that the landmark and primary mechanism of such deficiency is a defect in the normal clockwise torsion of the pulmonic

7 Keibel, F, and Mall, F Human Embryology Philadelphia, J B Lippincott Company, 1912

trunk about the aortic In the formation of the definitive mammalian heart, the pulmonic trunk swings from above posterior to the aorta, down to the left and anteriorly to take its position in front of the aorta as they issue from the heart When the vis á tergo of cardiac growth is reduced, this torsion partly or completely fails The greater the defect in torsion, the more severely anomalous is the heart

It was difficult to estimate detorsion in this case, but there were three signs of it to suggest a basis for the numerous anomalies encountered The semilunar cusps of the pulmonic trunk were abnormally placed There was a left, an anteroright and a posteroright, instead of the normal right, left and anterior But which cusp correspond to which cannot be stated with certainty If it had been the aorta, the noncoronary cusp would have served as a guide Here, however, all the cusps were noncoronary

A second sign of detorsion was the origin of the pulmonary arteries from the anteroleft aspect of the pulmonic trunk Normally, they should come off posteriorly The third was the position of the vestige of ascending aorta on the left of the ductus botalli and behind the pulmonary arteries Normally this relation is reversed, the ascending aorta is on the right of the ductus botalli and in front of the pulmonary arteries These three facts indicate, at least, that in this severely anomalous heart a marked detorsion defect had occurred

SUMMARY

A case of truncus solitarius pulmonalis is described The distinction from truncus communis and from truncus solitarius aorticus is emphasized There were numerous associated cardiac abnormalities and evidence that these were based on a severe detorsion defect

THE DISTRIBUTION OF LIPOID IN A CASE OF NIEMANN-PICK'S DISEASE ASSOCIATED WITH AMAUROTIC FAMILY IDIOCY *

HARRY SOBOTKA, PH D

EMANUEL Z EPSTEIN, M D
Eugene Meyer, Jr, Fellow
AND
LOUIS LICHTENSTEIN, M D
George Blumenthal, Jr, Fellow
NEW YORK

The peculiar perversion of lipoid metabolism in Niemann-Pick's disease has in recent years aroused considerable interest The clinical and anatomic features of the disease have been amply elucidated and its differentiation from Gaucher's disease established Whereas in Gaucher's disease kerasin has been identified as a lipoid specific for this condition, the scattered chemical analyses of spleens in Niemann-Pick's disease suggest merely a general increase of the normal lipoids, especially of phosphatids and cholesterol The distribution of lipoid in the few livers analyzed has shown a similar tendency

When a case of Niemann-Pick's disease associated with amaurotic family idiocy came to autopsy in this hospital, we undertook the study of the lipoid chemistry of the spleen and liver We also included that of the brain because of the interest in the relationship of amaurotic family idiocy (Tay-Sachs) to morbus Niemann-Pick

REPORT OF CASE

History—A girl, 10 months of age, weighing 5,000 Gm, of Jewish parentage, was admitted to the service of Dr Bela Schick on April 15, 1929, with a history of retarded development for three months, loss of weight and difficulty with feeding The child was born of a first pregnancy, in a normal delivery, and was breast fed until she was 7 months of age She had had chickenpox at 7 months, otherwise the past history was negative

Physical Examination—The patient showed enlargement of the spleen and the liver down to the umbilicus, peculiar red spots in the maculae of both eyes and brownish pigmentation of the skin A tentative diagnosis of Niemann-Pick's disease was made This diagnosis was confirmed by splenic puncture

Laboratory Data—The blood chemistry was total fat 1,430 mg, cholesterol 290 mg, serum calcium 12 2 mg and serum phosphorus 3 mg per hundred cubic centimeters The urine showed doubly refractive bodies The blood showed mod-

* Submitted for publication, May 15, 1930

* From the Laboratories of Mount Sinai Hospital

erate secondary anemia and mild polymorphonuclear leukocytosis The most interesting cells in the blood smear were the lymphocytes, a large percentage of which contained vacuoles The result of the Kahn test was negative

Ophthalmologic and Psychiatric Examinations—The ophthalmologist noted in the fundi a large oval grayish ring in the center of which was the bright red color of the macula, and diagnosed amaurotic family idiocy The psychiatrist noted that the mentality of the child approached idiocy

Course—While the patient was in the hospital, a respiratory infection persisted, associated with bouts of fever and vomiting After two months, the patient was



Fig 1—Section of spleen, hematoxylin-eosin stain

taken home against advice, only to return on Sept 5, 1929, with an exacerbation of symptoms and frank signs of pneumonia, culminating in coma and death On the second admission, the child was markedly underdeveloped and malnourished It presented a bronzed appearance, with extreme pallor and chronic emaciation The anemia was more severe, the cherry red spots in the macula were again noted, as were the other signs typical of Niemann-Pick's disease observed during the previous admission to the hospital

Pathologic Examination—Dr P Klemperer supplied the following pathologic observations The body was that of a poorly developed, emaciated, white female infant, measuring 68 cm The spleen and liver were markedly enlarged, weighing 180 and 500 Gm, respectively All the internal lymph nodes were enlarged and on section presented a distinct yellow color

Microscopic examination of paraffin sections (figs 1, 2 and 3) revealed the presence of large round or polygonal cells with diffuse vacuolization of the cytoplasm, throughout the spleen, between the liver cell cords, in the lymph nodes within the alveoli of the lungs, as well as in the peribronchial and perivascular connective tissue, and, in smaller numbers, also in the alveolar septums Not only the lymphadenoid tissue but also the stratum proprium of the mucosa of the intestines showed the presence of the same cells The bone-marrow was diffusely infiltrated The glomeruli of the kidneys contained the same cells Sudan III did not stain the substance within the large cells, but sections stained according to the method of Lorrain-Smith-Dietrich revealed the presence of grayish-black stained

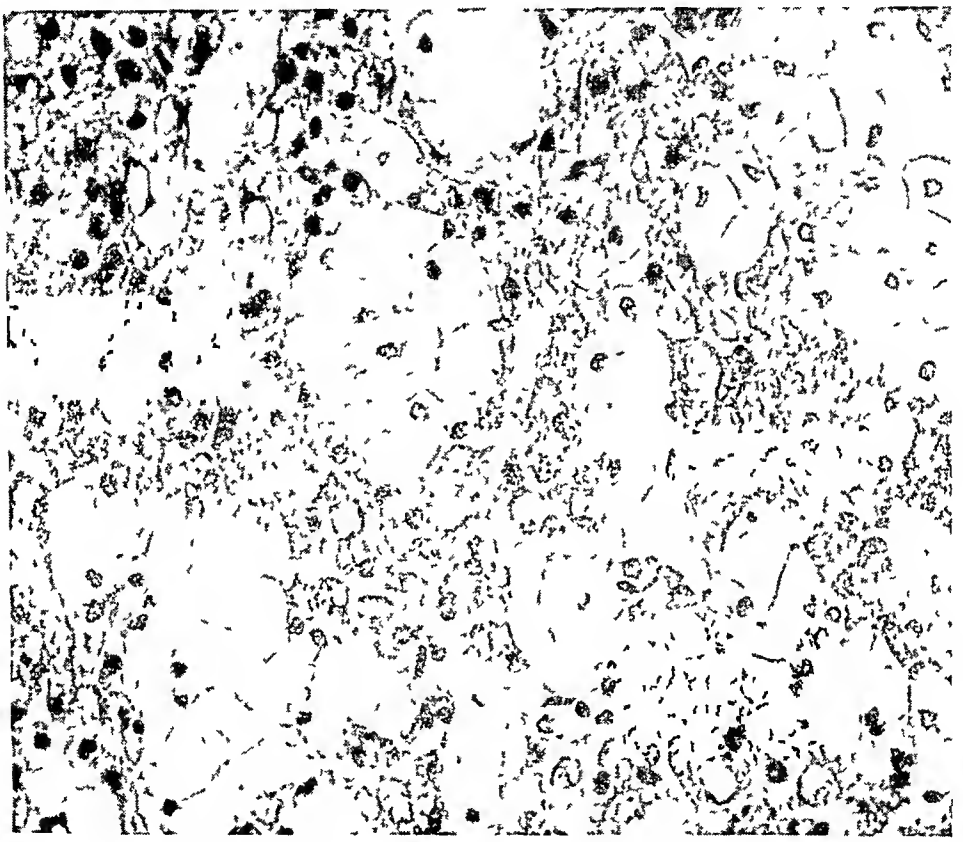

Fig 2—Section of liver, hematoxylin-eosin stain

granules Also sudan stain applied after fixation in potassium bichromate according to Ciaccio gave a positive result Examination under polarized light showed the presence of small crystals, doubly refractive granules, so fine that the entire cell appeared as though filled with mist The epithelium of the convoluted tubules of the kidney, however, contained, in addition to lipoid substances that stained only after the Smith-Dietrich method, small sudan stained droplets From these microchemical staining reactions one can say that the large cells contained no neutral fat, but some doubly refractive lipoids, most probably cholesterol, and large amounts of lipoids that were neither neutral fats nor cholesterol

The microscopic studies of brain and spinal cord by Dr J H Globus[1] revealed alterations typical of amaurotic family idiocy The monstrous and exceedingly

1 Globus, J H Ztschr f d ges Neurol u Psychiat **85** 424, 1923

large nerve cells, with swelling of the dendrites and loss of normal cytoplasmic structure (such as disappearance of fibrillae, accumulation of granules and displacement of nuclei) were uniformly found throughout all parts studied (fig 4)

DISTRIBUTION OF LIPOID

The analysis of organs for lipoids can be carried out by a great variety of methods Alkaline saponification of the material allows the most complete extraction of the derived lipoids as saturated and unsaturated fatty acids cholesterol, etc , but such analysis does not allow any



Fig 3—Section of bone-marrow , hematoxylin-eosin stain

inferences regarding the partition of these fragments among the complex lipoids (neutral fat, lecithin, waxes cerebrosides) as they occur in the living cell The anatomist and histologist are mainly interested in the partition of these complex lipoids with their specific solubility in various solvents, their staining properties and their physiologic significance

Extraction without preceding hydrolysis, although it will hardly accomplish a total exhaustion of the lipoids, is generally used for such investigations We adopted a method for extraction which would afford a picture of the distribution of the lipoids with as little alteration of the in vivo state as possible

The material may be fresh, formaldehyde-fixed or dried Dry material is more easily extracted by such solvents as ether and chloroform, but there is always danger of partial hydrolysis and other autolytic processes during drying The disadvantages of fixed material, e g, hydrolysis due to the treatment with formaldehyde, have been pointed out by Pick[2] and recently by Weil[3] The solvents best adapted for the extraction of fresh organs are acetone and alcohol The

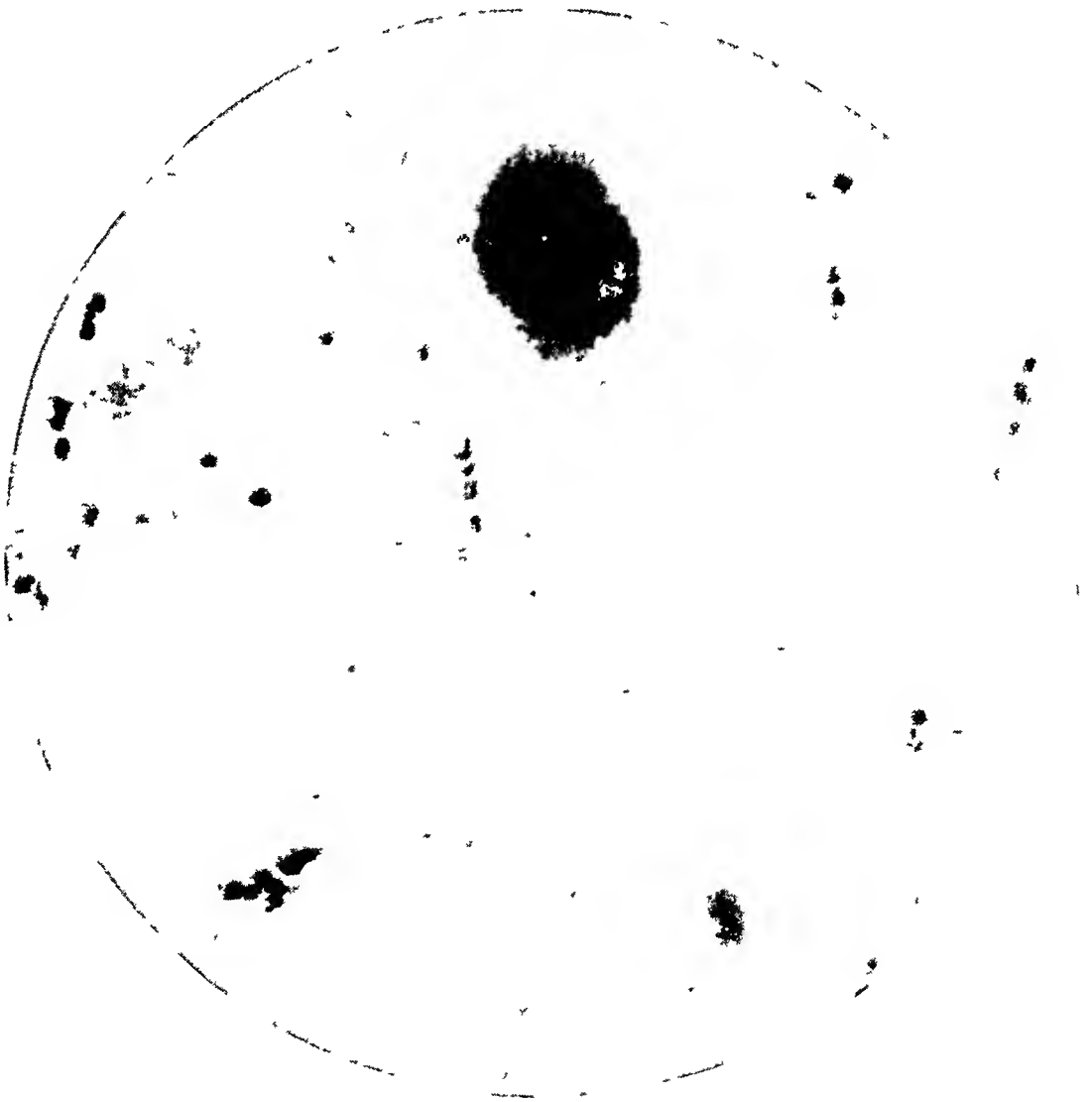

Fig 4—Section of brain, silver impregnation

main disadvantage of the extraction of 'fresh" tissue is the dilution of the solvent with the aqueous juice of the tissue, thus, the first extract contains some non-lipoidic material relatively high in nitrogen This treatment, however, effects an immediate inactivation of the enzymes and also prevents destructive oxidation of unsaturated compounds

2 Pick, L Ergebn d inn Med u Kinderh **29** 519, 1926

3 Weil, A J Biol Chem **83** 601, 1929

We chose acetone for the first extractions, these extracts were evaporated to dryness and taken up with hot absolute alcohol The alcohol-insoluble residue of the acetone fraction was excluded from the computation as consisting of nonlipoidic material The material extracted by acetone and soluble in hot alcohol was assumed to contain all the neutral glycerides and most of the cholesterol The phosphorus found was calculated as lecithin Pure lecithin is rather insoluble in acetone, but its solubility in water, as well as in organic solvents, varies greatly, depending on the presence of concomitant substances Some of the phosphorus content of the acetone fractions has to be attributed to lysolecithins or other degradation products of lecithin The nitrogen content of these fractions is partly due to the phosphatids, the greater part to accompanying nonlipoidic substances of smaller molecular weight and high nitrogen percentage

The acetone extraction was followed by three extractions with ether These extracts contained most of the lecithin and some cephalin and cerebrosides The residue was finally extracted by boiling absolute alcohol for cerebrosides and sphingomyelin The combined ether and alcohol extracts were evaporated and digested with small amounts of cold ether Although the supernatant portion was somewhat high in nitrogen, its phosphorus percentage suggested a lecithin content of 90 per cent and more These fractions were designated "lecithin fractions" The residue was dissolved in warm ether and precipitated with acetone, the white precipitate was designated "fraction 1" The supernatant portion was brought to dryness, taken up in ether and again precipitated with acetone, this process was repeated two or three times, resulting in the isolation of the "fractions 2, 3 and 4" and mother liquor "ML" These, in the order in which they were precipitated, contained decreasing amounts of cerebrosides and increasing amounts of lecithin The mother liquor contained appreciable quantities of combined and free cholesterol The cephalin, because of its lower solubility, accompanied the cerebrosides and probably accounted for a large share of the phosphorus in the less acetone soluble fractions While both cerebrosides and mono-aminophosphatides (lecithin and cephalin) contain only 2 per cent nitrogen, the diaminophosphatides (sphingomyelin) are about twice as rich in nitrogen Their presence was partly responsible for the high nitrogen in some of these fractions We did not attempt to isolate any of these lipoids in pure form because of the small amounts of starting material and because even the isolation of minute amounts of a pure substance would be without significance for the partition of the total lipoids

The dry residues of the various fractions were made up to approximately 1 per cent solutions in alcohol or methyl alcohol-chloroform These solutions were analyzed for phosphorus by a modification of the method of Kuttner and Cohen,[4] for nitrogen by macro-Kjeldahl and micro-Kjeldahl methods, for cholesterol by Bloor's method and for combined cholesterol likewise by Bloor's method after removal of the free cholesterol by digitonin Every analysis was carried out in duplicate The analytic results cannot be given in detail because of lack of space It should be noted that after deduction of phosphatides and cholesterol and after allowing for the fatty acid combined with cholesterol, the balance of the acetone-soluble fraction was considered neutral fat, the undetermined portion of the other fractions, cerebrosides The "fractions 1" containing the largest amounts of cerebrosides were analyzed polariscopically for kerasin The specific rotation in approximately 1 per cent solutions in chloroform-methyl alcohol (3 1) was for the spleen +6 7 degrees, for the liver +6 8 degrees and for the brain +7 8 degrees Phrenosin and sphingomyelin have a specific rotation of from +7 to

4 Kuttner, T, and Cohen, H R J Biol Chem **75** 516, 1927

+8 degrees, under these conditions, and the values for lecithin and cephalin are of the same range, while kerasin exhibits a rotation of —5 degrees Thus the presence of significant amounts of kerasin in our material was excluded Small anisotropic spherolithes were obtained from these fractions, but they were too minute for Rosenheim's [5] test with the selenite plate

Our results are summarized in table 1 The control organs were obtained from autopsies on children in the same age group The results of all available analyses of the lipoids of the spleen and liver in cases of Niemann-Pick's disease on record are presented in figure 5 They are given as percentages of fresh organ The cases of Wahl and Richardson [6] and Siegmund [7] were diagnosed as morbus Gaucher, but Bloom and Kern [8] and Pick [2] emphasized the true nature of these cases as that of morbus Niemann-Pick

TABLE 1—*Distribution of Lipoid in Case of Niemann-Pick's Disease and in Controls*

Organ	Weight of Portion: Total Weight, Gm	Weight of Portion: An alyzed, Gm	Total Solids, %	Extracted Lipoids, Percentage: Wet Organ	Extracted Lipoids, Percentage: Total Solids	Percentage of Total Lipoids: Neu tral Fat	Free Choles terol	Choles terol Esters	Phos pha tides	Cere bro sides	Ratio N P	Ratio Free to Total Choles terol
Brain	630	273	17 0	7 75	45 6	None	3 35	25 55	53 5	17 6	1 37	0 18
Liver	500	310	26 4	12 1	45 8	0 3	4 9	11 25	67 9	15 65	1 03	0 42
Spleen	180	105	25 8	8 6	33 4	1 25	9 6	6 85	62 6	19 7	1 23	0 70
							Total Cholesterol					
Two livers (controls)		208	27 1	6 35	23 3	25 25	6 25		(39 1)*	(29 4)*	1 3	(0 79)†
Three spleens (controls)		45	20 9	2 22	13 55	26 5	11 0		41 5	21 0	3 2	(0 91)†
Brain												(0 65)†

* Approximation
† From Beumer [11]

TABLE 2—*Results of Analysis of Spleen and Liver in Nieman-Pick's Disease and Controls, According to Wahl and Richardson*

	Total Lipoids, per Cent	Neutral Fat, per Cent
Normal spleens	20 5 to 21 8	9 to 14 6
Niemann Pick spleen	52 to 54	1 3
Normal livers	23 to 27 8	12 2 to 19
Niemann Pick liver	37 2	2 8

The case of Wahl and Richardson was not incorporated in figure 5 because these investigators refer their figures to dry material and classify the lipoids in a somewhat different manner Their percentages for the total lipoids and neutral fat of dry material are given in table 2

5 Rosenheim O Biochem J **8** 110 1914

6 Wahl, H R and Richardson, M L A Study of the Lipin Content of a Case of Gaucher's Disease in an Infant, Arch Int Med **17** 238 1916

7 Siegmund, H Verhandl d deutsch path Gesellsch **18** 59 1921

8 Bloom, W, and Kern, R Spleens from Gaucher's Disease and Lipoid-Histiocytosis Chemical Analysis Arch Int Med **39** 465, 1927



Fig 5 —Distribution of lipoid in Niemann-Pick s disease as compared with that in controls, according to various authors The dotted space represents free and combined cholesterol (if not subdivided, total cholesterol), the diagonally ruled space, phosphatides, the horizontally ruled space, neutral fat, and the blank space cerebrosides or undetermined lipoids The values are given as percentages

These figures for neutral fat obtained by a different procedure are in agreement with our own The depletion of fat has been observed clinically as general emaciation, pathologically by Pick[9] and chemically by Wahl and Richardson and by ourselves in the present analysis The disappearance of neutral fat is the most striking chemical feature of Niemann-Pick's disease

The increase in lipoid phosphorus was observed in every analysis on record It may be interpreted as an increase of lecithin or mono-amino-phosphatides in general, but the question as to what part of the increase is due to sphingomyelin and other phosphatides (Epstein[10]) is left for further investigation The relative increase in cholesterol is smaller, but comparable to that of the phosphatides The proportion of free cholesterol in total cholesterol was 18 per cent in the brain, 42 per cent in the liver and 70 per cent in the spleen Brahn and Pick[9] found 71 per cent in the spleen, Siegmund,[7] as much as 85 per cent in the spleen and 82 per cent in the liver

Our figures are considerably lower than those given for normal children by Beumer,[11] who found in an 8 months old child that of the total cholesterol in brain, liver and spleen, 65 per cent, 79 per cent and 91 per cent, respectively, was free cholesterol Brahn and Pick, however, found only 51 per cent in a normal spleen

This increase of both phosphatides and cholesterol esters and the failure of the organs to store or to retain neutral fat suggests the following explanation An equilibrium obtains normally between

```
          /fatty acid                          /fatty acid
glycerol—fatty acid                  glycerol—fatty acid
          \phosphoric acid                     \fatty acid
(lecithin)        choline  <———————      +        (neutral fat)
                           ———————>  cholesterol
                +                          +
cholesterol—fatty acid               phosphoric acid, choline
(cholesterol ester)
```

This equilibrium governs the transport, utilization and deposition of fat It is disturbed in Niemann-Pick's disease perhaps by a failure of the enzymatic apparatus—with the effect that the lipoid partition in the organs is shifted to the left side of the foregoing equation[12]

The analysis of the brain was undertaken with the hope that light might be thrown on the etiologic relationship between Niemann-Pick s and Tay-Sachs' disease According to Pick, the histologic changes are

9 Brahn, B, and Pick, L Klin Wchnschr **6** 2367, 1927

10 Epstein, Emil Virchows Arch f path Anat **274** 294, 1929

11 Beumer, H Monatschr f Kinderh **19** 409, 1921

12 Sobotka, H Ueber Umesterungen im Lipoidstoffwechsel Naturwissenschaften **18** 619, 1930

practically the same whether the degeneration of lipoid occurs in the liver, spleen, spinal cord or brain Bernard Sachs, in discussing the clinical picture in the present case, stated "The resemblance is so great in these diseases that there can be little doubt that they are allied The Niemann-Pick type seems to represent the wide-spread lipoid degeneration and amaurotic family idiocy the same degeneration limited to the central nervous system"

In the study of this brain, no neutral fat was found High percentages of phosphatides and cholesterol, particularly combined cholesterol, were encountered here as in the other organs, this seems less significant, however, because of the relatively high concentrations of these lipoids in normal brains[13] It would be desirable to compare the present observations with those obtainable by analysis of the organs in instances of amaurotic family idiocy without hepatosplenomegaly

The chemical data that clearly differentiate the present case from Gaucher's disease are the absence of relative increases of cerebrosides, corroborated by the low nitrogen-phosphorus ratio, and the absence of unusual amounts of kerasin, proved by the dextrorotation of the fractions involved

We urge pathologists who contemplate analyses of the lipoids of organs in cases of Niemann-Pick's disease, family idiocy, Christian's disease and related conditions not to fix the material with formaldehyde, but to place the minced or chopped material without delay under acetone The material might be kept in this state until its chemical analysis, including that of the acetone supernatant portion, proves convenient

SUMMARY

The analysis of the lipoids of spleen, liver and brain in a case of lipoid histiocytosis (Niemann-Pick) associated with amaurotic family idiocy showed (1) the disappearance of neutral fat, (2) considerable increase of phosphatides and cholesterol, particularly cholesterol ester, and (3) the absence of kerasin

13 Peritz G, in Oppenheimer Handbuch der Biochemie, Jena, Gustav Fischer, 1925 vol 4, p 360

ACTINOMYCOSIS OF THE HEART

REPORT OF A CASE WITH ACTINOMYCOTIC EMBOLI

J A KASPER, M D
DETROIT
AND
MAX PINNER, M D
NORTHVILLE, MICH

Since Israel[1] reported the first cases of actinomycosis in man in 1878, a great number of reports have appeared in the literature A report of a single case is warranted only if the case shows unusual features We believe that the case here described is atypical both in regard to the distribution of the lesions and in regard to their gross anatomic characteristics The most important mode of propagation of *Actinomyces* in the body is by continuity of growth and infiltration similar to those of malignant neoplasms, particularly since it does not respect anatomic boundaries and normal capsules Metastasis through lymphatic channels is extremely rare As a rule, regional lymph nodes may be found enlarged, but not involved by the specific organism In the literature we found only one report of metastatic involvement of lymph glands (von Baracz[2]) Hematogenous metastasis is more frequent, although far from common Local lesions at any place may break into the circulatory system and so give rise to hematogenous propagation Relatively few reports of such cases could be found in the literature Israel did not mention the site of the invasion of the vascular system, the same is true of Abee,[3] but in both their cases there was definite evidence of hematogenous spread Invasion of the blood stream occurred in (1) the myocardium in the cases of Konig,[4] Munch,[5] Paltauf,[6] Lutz[7] and Paetzold,[8] (2) the vena cava in the cases

* Submitted for publication, May 26, 1930

From the Department of Pathology, Herman Kiefer Hospital, Detroit, and the William H Maybury Sanatorium (Detroit Municipal Tuberculosis Sanatorium), Northville, Mich

1 Israel, J Virchows Arch f path Anat **74** 15, 1878
2 von Baracz, R Arch f klin Chir **68** 1050, 1902
3 Abee, C Beitr z path Anat u allg Path **22** 162, 1897
4 Konig A Inaugural Dissertation, Berlin, 1884
5 Munch, A Cor-Bl f schweiz Aerzte **18** 234, 1888
6 Paltauf R Wien klin Wchnschr **3** 487, 1890
7 Lutz, R Inaugural Dissertation, Munich, 1910
8 Paetzold, P Frankfurt Ztschr f Path **16** 415, 1915

of Hanau[9] and Adler,[10] (3) a large hepatic vein in a case of Benda[11] and (4) the coronary artery and the right ventricle in the second case reported by Benda In a number of other cases the reports of which we have studied vascular invasion may have occurred, but the descriptions are not always definite enough to warrant a conclusion Additional cases have quite likely escaped our notice

Kaufmann[12] emphasized the fact that actinomycotic involvement of the heart and pericardium is rare In the accompanying table are summarized some of the larger statistics, showing the incidence of pericardial and myocardial involvement

In a series of about 470 cases of actinomycosis, the incidence of pericardial and myocardial involvement was less than 2 per cent Thirty-two years after Israel's first description of the disease, Lutz was able

Incidence of Pericardial and Myocardial Involvement in Cases of Actinomycosis

Author	Cases of Actinomycosis	Cases Showing Involvement of Pericardium	Cases Showing Involvement of Myocardium
Bostroem (Beitr z path Anat u allg Path 9 1 1891)	12	0	0
Schlange (Arch f klin Chir 44 863 1892)	120–130	0	0
Ruhrah (Ann Surg 30 417 605 and 722 1899, 31 235 1900)	72	0	0
Shiota (Deutsche Ztschr f Chir 101 289 1901)	55	1	0
Baracz[2]	63	0	1
Heinzelmann (Beitr z klin Chir 39 526 1903)	56	1	0
Harbitz and Grondahl (Beitr z path Anat u allg Path 50 193 1911)	37	4	4
Total	465–475	6	5

to collect but twelve cases of involvement of the myocardium, and he added one He did not mention a case published by Paltauf in 1890 and one described by Abee in 1897 Since that time, the following cases have come to our notice one case of actinomycotic pericarditis and myocarditis, one case of incipient actinomycotic abscess in the myocardium, one which showed in addition to an acute serofibrinous pericarditis actinomycotic lesions in the endocardium and one with a purulent infiltration of the pericardium and an abscess in the heart—all described by Harbitz and Grondahl,[13] and one case of generalized actinomycosis in which an adhesive pericarditis and multiple nodules in the myocardium were found, reported by Paetzold

9 Hanau, A Cor-Bl f schweiz Aerzte **19** 165, 1889

10 Adler Deutsche med Wchnschr **16** 596, 1890

11 Benda, C Deutsche med Wchnschr **26** 70, 1900

12 Kaufmann, E Spezielle pathologische Anatomie, ed 8, Berlin, W de Gruyter & Company, 1922

13 Harbitz, F, and Grondahl, N B Beitr z path Anat u allg Path **50** 193, 1911

Involvement of the lung is a frequent occurrence, either as an apparently primary invasion or as a secondary extension by direct contact from lesions of the upper part of the respiratory tract, from abdominal foci, from preexisting pericarditis or from infections of the wall of the chest Embolic involvement is apparently rare, even in cases with myocardial lesions True embolic pulmonary involvements resulting in multiple hemorrhagic infarctions were reported by Paltauf, Benda and Lutz Paltauf's case resembled our case more than any of the others found described in the literature The description of his case in brief, is as follows

The lungs contain metastatic abscesses and hemorrhagic infarctions, the pleura over these lesions shows fresh fibrinous exudations The branches of the pulmonary artery within these foci are filled with pus The pericardium contained 300 cc of thick pus which contained the characteristic sulphur granules In the anterior wall of the right ventricle, there was an actinomycotic abscess, measuring 3 × 1½ cm, extending with small pedunculated granulations into the endocardium which was slightly ulcerated

REPORT OF CASE

History—R R, a white man, aged 30, a coal miner, was admitted to the Tuberculosis Division of the Herman Kiefer Hospital on June 14, 1929, complaining of cough, pain in the chest, swelling of the legs, occasional night sweats and loss of weight His illness began seven months previous to his admission with general malaise and cough About two months later, he suffered from an acute pain in the chest across the upper sternal region Because of weakness he had to give up work and go to bed, but he had no medical care until six weeks prior to admission, then he applied at a clinic for medical aid At that time, he felt a heaviness in his legs and arms Edema of the extremities was noticed at night There were pain and swelling in the right arm and right thigh

Drainage of the gallbladder was performed in 1923 and cholecystectomy in 1928 Otherwise, the history was of no interest The family history bore no relation to the patient's illness

Physical Examination—On admission, marked dulness was present over the base of the right lung No rāles were heard The pulse rate was 132 The abdomen was greatly distended with fluid, particularly the right side, which bulged An old laparotomy scar was present on the right side of the abdomen Both lower extremities and the right hand were edematous A brawny induration was present in the lateral and posterior portion of the middle of the right arm A similar induration was present in the right thigh The scrotum was greatly enlarged and edematous

Laboratory Examination—Slight secondary anemia was found The total white count was 19 600, with 82 per cent polymorphonuclears and 18 per cent lymphocytes On June 18, the white cell count rose to 26,600, with 86 per cent polymorphonuclears and 14 per cent lymphocytes Three examinations of sputum were negative for tubercle bacilli The results of urinalysis were negative, except for occasional red blood cells

Roentgen examination on June 18, 1929, showed thickening of the pleura on the right side and evidence of effusion There was no mottling of the right lung to suggest tuberculosis The left lung was normal The heart was also normal

Diagnostic puncture of the right pleural cavity revealed the presence of clear, straw-colored fluid Cultures of this fluid remained sterile No acid-fast bacilli or other bacteria could be found on smears Inoculations of guinea-pigs gave negative results for tuberculosis

Abdominal fluid examined for bacteria was negative Inoculations of animals gave negative results for tubercle bacilli

Clinical Course—The temperature was irregular, ranging from 97 8 to 100 8 F, being 95 F shortly before death The pulse rate varied between 80 and 140 per minute The rate of respiration was between 16 and 32 per minute, immediately before death, it was 48 Two days before death, the swelling in the arm and thigh broke down, and the purulent discharge was moderately profuse On the morning of July 4, breathing became labored and the pulse weak and irregular The pulse continued to be irregular until July 13 and was thready immediately before death on this day Profuse clammy perspiration occurred on the day preceding, and dyspnea became marked several hours before, death

Necropsy—A necropsy was made thirty-eight hours after death, but permission to open the skull was not granted A description of the major lesions follows

On the posterior aspect of the upper third of the right arm was an induration of the subcutaneous tissues In the skin over this swelling several openings were present The largest of these openings was 5 mm in diameter, and through it much thick, greenish-yellow purulent material could be expressed from the deeper part of the induration A similar induration was present in the lateral portion of the right thigh Around the several small openings in the skin over this swelling granulation tissue was present, and the amount of pus that could be expressed was much less than in the arm

Both pleural cavities contained turbid yellowish-gray fluid in which were suspended particles of fibrin The right cavity contained approximately 1,200 cc and the left about 900 cc The parietal pleura on each side was greatly thickened and fibrous

The pericardial cavity was almost completely obliterated by fibrous adhesions The parietal pericardium was thickened and contained small yellow foci, especially at the apex of the heart, where it was firmly adherent to the epicardium Both ventricular walls at this site were softened by a deposit of white fibrous tissue in which were many small, soft foci, containing a yellow purulent substance (fig 1) These foci resembling abscesses measured approximately 3 mm in diameter There was no apparent rupture into the chambers of the heart, although the inflammatory process involved almost the entire thickness of the ventricular walls The apex of the heart was rounded, owing to the increase in the fibrous tissue, the enlargement being external Where not involved, the myocardium was dull red and very moist It showed some cloudiness The ring of the mitral valve was enlarged and its leaflets did not close the orifice completely At the bases of the leaflets slight sclerosis was noted, while their free margins were thin and smooth The leaflets of the tricuspid valve showed wrinkled margins, but no ulceration or vegetation Small lipoid deposits were present on the surfaces of the cusps of the aortic and pulmonary valves The volume of the left auricle was approximately twice that of the right, and both contained freshly clotted dark blood as well as pale clots with much fibrin

The right lung was completely devoid of air and was of a soggy, beefy consistency The left lung contained few areas which were crepitant Both organs

were covered with dark, bluish-black pleurae in which were several patches of white fibrous tissue, particularly near the bases and over the lower anterior part of the upper lobe of the left lung

On section, both lungs were of an even, almost black color The large trunks near the hili were surrounded by rather dense fibrous tissue Scattered

Fig 1 —The left ventricle of the heart bisected near the apex, showing fibrosis of the wall with small pockets containing yellow purulent material Several of these pockets are empty A portion of the parietal pericardium at the left shows thickening and a rough inner surface The wall of the left auricle is greatly thickened because of fibrosis

irregularly throughout the lungs were many foci of hard tissue The majority of these were wedge-shaped with the broad bases lying directly below the pleura, but a few smaller round ones were seen more centrally located What were appar-

ently the most recent lesions showed densely infiltrated hard tissue markedly protruding above the cut surface of the uninvolved pulmonary tissue They were dark purple and were surrounded by less densely infiltrated and somewhat paler zones The less recent lesions were not so elevated, but hard They showed dark red cut surfaces, mottled with yellow What appeared to be the oldest lesions showed central softening These were dirty gray



Fig 2—A section from a hemorrhagic focus in the lung showing a mass of Actinomyces surrounded by polymorphonuclear leukocytes External to the abscess is a large accumulation of blood

In the lateral portion of the upper lobe of the right lung was a grayish-yellow, hard, round, encapsulated subpleural nodule (Primary focus?)

The terminal portion of the ileum contained several transverse scars in Peyer's patches Small nodules were present in the midportions of these scars The wall of the ileum over these areas was thickened Several mesenteric lymph nodes were hard and contained cheesy material, with deposits of small amounts of calcium

Histologic Examination—A section taken from the peripheral part of the left ventricle of the heart showed the epicardium to be replaced by granulation tissue with numerous newly formed capillaries In this tissue were scattered collections of lymphocytes and plasma cells In the myocardium under the granulation tissue were foci consisting almost entirely of polymorphonuclear leukocytes These leukocytes replaced the myocardial fibers Dense connective tissue separated this leukocytic exudate from the bundles of myocardial fibers bordering the zone of

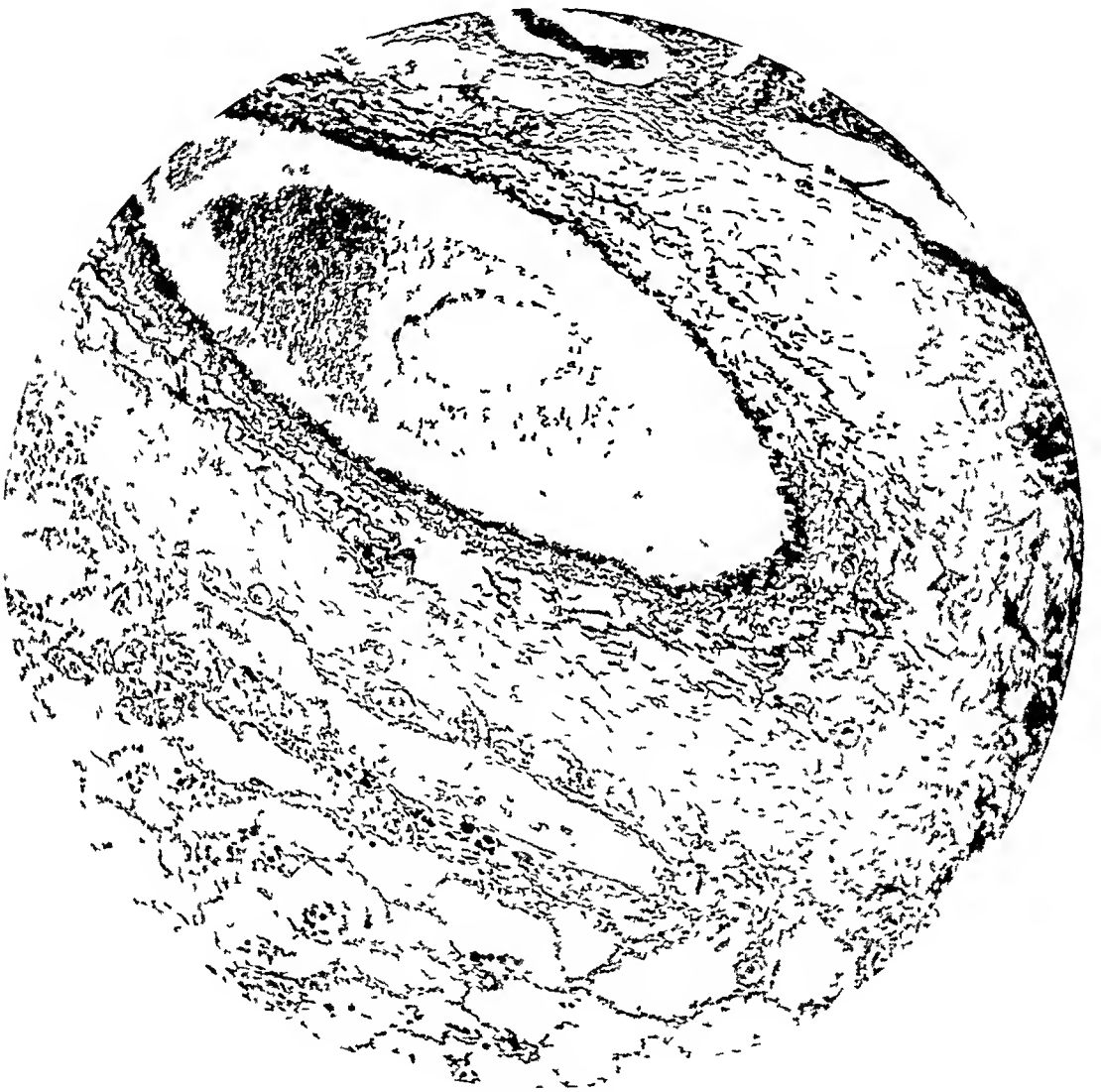

Fig 3—A branch of the pulmonary artery containing Actinomyces with a mass of leukocytes

inflammation A few muscle fibers surrounded by the connective tissue showed degeneration At the centers of several of the foci of polymorphonuclear leukocytes were masses of *Actinomyces* in characteristic arrangement

One section of lung showed a large hemorrhage involving a number of alveoli, in the middle of which were several foci of neutrophilic polymorphonuclear leukocytes At the centers of these purulent foci were masses of *Actinomyces* (fig 2) The alveoli bordering the hemorrhagic area showed congestion of capillaries and there was a slight extravasation of red cells into the air spaces of a few of them

Several other sections showed large collections of leukocytes at the periphery of the lung immediately under the pleura These foci were sharply demarcated from the adjacent normal alveoli In them were masses of the ray fungus On the pleural sides of these infarct-like areas, connective tissue was present in moderately thick layers

Another type of lesion consisted of a leukocytic accumulation at the center of which *Actinomyces* was present Surrounding the collection of leukocytes was



Fig 4—A vein in the ileum containing Actinomyces and much pus The surrounding structures of the submucosa are free from any reaction

a capsule composed of dense hyaline connective tissue External to this capsule was granulation tissue containing numerous capillaries and scattered lymphocytes The alveoli immediately adjacent to the area of inflammatory reaction was normal in appearance

In one section (fig 3) a colony of *Actinomyces* was seen in a branch of the pulmonary artery leaving no doubt as to the etiologic nature of the infarction

Carbon pigment was present in large amounts throughout the parenchyma of the lung in all sections studied

In the submucosa of the ileum were two areas of inflammation characterized by lymphocytic infiltration between proliferating fibroblasts One of these areas was around an artery that contained an organized thrombus obliterating its lumen The other was adjacent to a vessel that was filled with polymorphonuclear leukocytes and contained *Actinomyces* (fig 4) The mucosa of the ileum was intact, except in the region of the thrombosed vessel, where it was denuded and a fibrosed base of the ulcer was exposed

A section from skeletal muscle of the arm showed extensive perivascular accumulations of lymphocytes and plasma cells Abscesses consisting of polymorphonuclear leukocytes and surrounded by walls of dense hyaline connective tissue were noted in several bundles of muscle fibers The adjacent muscle was diffusely invaded by connective tissue Many of the muscle fibers in this mass showed necrosis, one area showed coagulation necrosis

A section of skeletal muscle from the thigh showed essentially the same type of inflammation Masses of ray fungus were found in several of the abscesses

The intima and media of the aorta were normal In the adventitia, scars and granulation tissue were seen Collections of lymphocytes and plasma cells were present around several arterioles An occasional abscess was observed and one contained *Actinomyces*

The liver showed marked passive congestion

The spleen showed passive congestion Branches of the splenic artery showed hyaline thickening

The kidneys presented passive congestion and cloudy swelling of the tubular epithelium

Diagnosis—The essential points of the pathologico-anatomic diagnosis were as follows induration, with central abscess formation and multiple draining sinuses on the right arm and right thigh, bilateral fibrinopurulent pleuritis, bilateral fibrotic pleuritis of parietal pleura, obliterative pericarditis, multiple abscesses in pericardium, myocardial abscess, multiple hemorrhagic infarcts in both lungs, ascites and multiple abscesses in the mucosa of the ileum

COMMENT

As mentioned, the case reported is unusual both in the distribution of foci and in the gross appearance of the latter The portal of entry could not be determined The teeth were noted as showing caries, but there were no mucosal lesions in the mouth The lung did not contain any foci the structure of which suggested a relatively old lesion, in fact, the pulmonary lesions, showing rather fresh hemorrhage and no development of fibrous tissue, were most likely of recent development The subcutaneous abscesses, which were surrounded by more or less marked fibrous interstitial myositis were undoubtedly considerably older than the pulmonary foci or the intestinal lesions, which were free from fibrosis Structurally, the myocardial, pericardial and peripheral lesions were the oldest The myocardial and pericardial lesions cannot possibly be considered to have been primary, and if the peripheral lesions are considered primary, one has to assume two widely separated portals of entry an unsatisfactory solution

All that can be said is that the myocardium or pericardium became invaded presumably by way of the blood stream, since no lesions were seen that might have infected these structures by continuous progression From the myocardial focus, spread must have occurred both by the systemic and by the pulmonary circulations, as attested by recent (endovascular) lesions in the ileum and in the wall of the aorta and by the multiple embolic foci in the lungs As in the case of other infectious emboli, why certain organs were infected and why others (notably the spleen and the kidneys) escaped remains unexplained

There was nothing in the gross appearance of the various lesions to suggest actinomycotic infection The various abscesses looked like products of nonspecific, subacute purulence The exudate was purulent, containing none of the "sulphur granules", the same is true of the pleural effusion In all regards, the pulmonary lesions had the characteristics of recent hemorrhagic infarcts

SUMMARY

A case of embolic actinomycosis with multiple endovascular metastases is reported

THE OCCURRENCE AND NATURE OF SPONTANEOUS ARTERIOSCLEROSIS AND NEPHRITIS IN THE RABBIT *

FRANKLIN R NUZUM, M D

ALBERT H ELLIOT, M D

RICHARD D EVANS, M D

AND

BLANCHE V PRIEST, A B

SANTA BARBARA, CALIF

From the clinical and pathologic standpoints, the study of arteriosclerosis and nephritis is most important These conditions have much to do with efficiency during life Arteriosclerosis is responsible for the death of many persons beyond middle age In a study of 9,149 necropsies performed at the Krankenhaus Charite in Berlin during a period of eight years, Hesse[1] determined that it is the cause of 10 2 per cent of all deaths in persons over 40 years of age From reports issued by the U S Public Health Service we have estimated that of persons of 45 years of age or beyond, 45 5 per cent will die from one of the triad of cardiovascular-renal diseases In this group, arteriosclerosis is a most prominent pathologic observation Although much investigative work has been done and much has been written concerning the etiology of these diseases, few basic facts have been proved The field is a fertile one for investigation

Experimentation on animals is essential in reaching a solution of the problems related to the etiology of arteriosclerosis and nephritis Of the various laboratory animals, the rabbit is, and probably will continue to be, the one most used The rabbit has been maligned as an experimental animal on the ground that it is subject to spontaneous changes that make any experimentally produced alterations difficult of interpretation This is particularly true of the spontaneous occurrence of arteriosclerosis, concerning the incidence of which there is the greatest variance in the relatively few reports available, ranging from 0 per cent to 34 per cent

---

Submitted for publication, May 24, 1930

* From the Laboratories of the Cottage Hospital

1 Hesse, M Zur Statistik der Atherosklerosesterblichkeit Frankfurt Ztschr f Path **35** 477, 1927

The literature on this subject has been summarized by Newburgh and Clarkson,[2] who stated that Steinbliss found no sclerosis in the examination of the aortas of more than 500 rabbits Loeb had the same result in 483 "normal" rabbits Rosenow, examining 1,548 rabbits, found arteriosclerosis in only 3, while in a later series of 300, he found none 'Miles, on the other hand, found aortic lesions in 17 of 49 (34 6 per cent) of supposedly normal rabbits, with primary involvement of the media" Levin and Larkin found spontaneous atherosclerosis in 13 per cent of rabbits, but these animals had been used for experimental purposes the exact nature of which is not clear Of Newburgh and Clarkson's series of 116 rabbits, some of which had been used as controls for their experiments, and the others for the demonstration of the action of drugs and for the obtaining of blood serum, only 4 (3 4 per cent) showed changes in the aortas Grossly, there were small intimal papules of the ascending and transverse portions of the aortic arch Microscopically, the intima was normal, but there was necrosis or calcification of the medial muscle cells True intimal sclerosis was not found in a single animal of this group

It is evident that in addition to wide variation in the reported incidence of arteriosclerosis, there has frequently been the failure to make a careful microscopic study

ARTERIOSCLEROSIS

We have examined the blood vessels and kidneys of approximately 190 rabbits living the year round in outdoor hutches These animals were raised from our own stock, and their age at death varied from 2 to 3 years For the most part, they had been used in the standardization of insulin and as control animals in various experiments Their diet consisted of barley, 52 Gm , and alfalfa, 150 Gm , daily

Two types of sclerosis of the large vessels were found One consisted grossly of a gray depression of the intima, and was found 11 times, or in 5 8 per cent, the other, a yellow elevated lesion of the intima, occurred in 6 instances, or in 3 1 per cent

Grossly, the appearance of the depressed type of sclerosis is as follows There are many shallow pits or depressions of the inner surface of the aorta, which are gray, circular and vary from 1 to 3 mm in diameter They are limited for the most part to the arch of the aorta, and are scattered diffusely, lacking the tendency of intimal arteriosclerotic plaques to be grouped about the ostia of the intercostal arteries Over the edge of these depressions, the intima itself is folded, but otherwise unaltered Some of the lesions are almost umbilicated,

2 Newburgh L H, and Clarkson S The Production of Atherosclerosis in Rabbits by Feeding Diets Rich in Meat Arch Int Med **31** 653, 1923

the circular edges projecting slightly above the surface of the aorta when it is held out flat When the aorta is held up to the light, pronounced thinning at the bases of the depressions is evidenced by the increased transmission of light through them

As seen in histologic sections including the base of a depression, the aortic wall is frequently thinned to one half of its normal thickness



Fig 1—Early spontaneous intimal arteriosclerosis, showing subendothelial lipoid infiltration Grossly, this lesion appears as a yellow papule

The intima is thrown into irregular folds but its histologic structure is unaltered Groups of muscle cells well within the media may be but otherwise unaltered Some of the lesions are almost umbilicated, partly or completely necrosed, or entirely replaced by calcium deposits extending in streaks from 1 to 2 mm wide for some distance along the vessel wall Beneath the intima may be scattered a few fat-laden cells between the muscle fibers, but they are strictly limited to the inner part

of the media This type of arteriosclerosis, a calcification of the media, occurring in 5 8 per cent of our animals, had an entirely different histologic appearance from the second or intimal type

In this intimal type, which involved most frequently the root and arch of the aorta, though commonly extending throughout its course down to the iliac bifurcation, raised yellow plaques are present, which



Fig 2—A more advanced stage of intimal arteriosclerosis Note thickness of intima as compared with media

vary from 1 mm to 1 cm in their greatest dimension Early in the process they are discrete, and tend to be grouped about the mouths of the intercostal arteries, but in advanced instances they may become confluent and entirely cover the surface of the wall In this group, such advanced changes were encountered only twice Calcification of the plaques may occur, as evidenced by a gritty sensation when the knife is passed through them but in our rabbits ulceration was not found

The elasticity of the aorta is decreased in proportion to the degree of involvement of its wall

The histologic picture depends on the degree of development of the lesion Three processes are evident degeneration, infiltration and regeneration, which may go hand in hand Our histologic studies have demonstrated that the first change is a swelling of the intercellular cement substance directly beneath the endothelium The tissue is

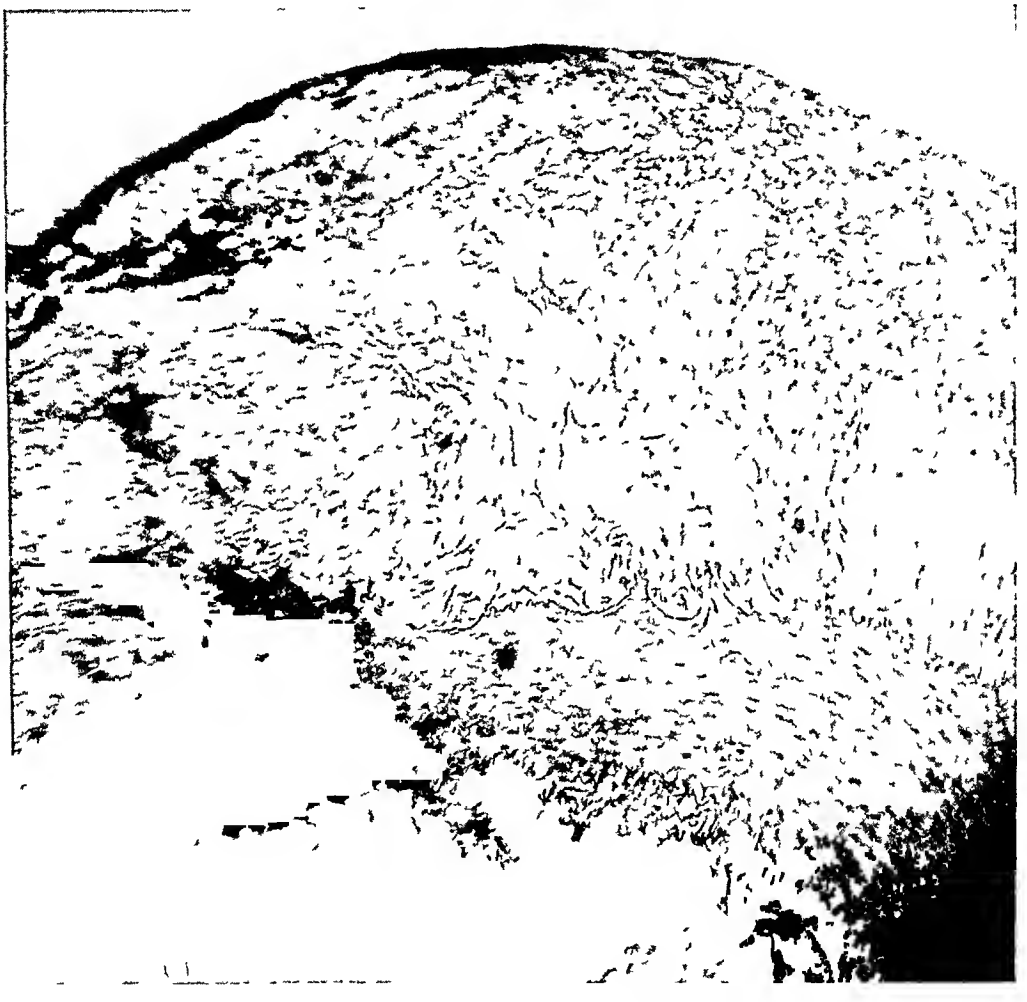

Fig 3—Far advanced intimal arteriosclerosis The media is thinned, but otherwise unaltered

edematous, and the connective tissue fibrils are pushed apart Large fat-laden cells appear, coincident with a beginning necrosis of the connective tissue cells in this region, and are pushed toward the media by a connective tissue hyperplasia which rapidly follows beneath the endothelium as the lesion progresses At this stage there is grossly evident a small yellow papule bulging slightly above the true level of the intima Further necrosis of the subendothelial cells now takes place with replace-

ment by hyaline material and lipoid substances, as the process extends downward and lateralward Spaces having the shape of cholesterol crystals may be seen in some regions just internal to the media, which have resulted from the solution of that substance during the preparation of the microscopic sections The lesion may now measure twice the thickness of the rest of the arterial wall Deposition of calcium may, and often does, occur The internal elastic lamina is frayed and broken Occasionally, the process extends by continuity into the superficial layers of the media, but only in advanced lesions In most instances, the media beneath the lesion appears thinned, but otherwise unchanged

In man, two types of sclerosis of the larger vessels have long been recognized One involves only the intima It consists of yellow or gray lesions that project into the lumen of the vessel and tend to be located near points of stress (i e, about the mouths of the intercostal arteries, at the iliac bifurcation of the aorta, etc) It affects arteries that are primarily of elastic structure, such as the aorta, the iliac and carotid arteries, and those of the brain The media in this type of arteriosclerosis often escapes uninjured

The second type of arteriosclerosis in man presents a different pathologic picture Arteries in which muscular tissue is predominant, such as those supplying the abdominal organs and extremities, are affected by a necrosis of the media with secondary calcification, the lesions tending to be situated in ringlike fashion around the circumference of the vessel wall This Monckeberg type is recognized clinically by the stiffened, beaded or "goose-neck" feel of the radial or dorsalis pedis artery to the palpating finger, and by the tortuosity and prominence of the brachial artery

In the rabbit, differentiation of arterial structure into the elastic and muscular types is not so pronounced Klotz,[3] in 1906, stated that the aorta of the rabbit is partly elastic, partly muscular in structure, and hence can develop both the intimal and medial types of arteriosclerosis It was his opinion that the intimal type in the rabbit has its analog in man in arteriosclerosis of the arteries predominantly of elastic structure, and stressed the fact that the medial sclerosis of the rabbit is similar to the Monckeberg arteriosclerosis of man

NEPHRITIS

Of this same group of 190 animals 4, or 2 1 per cent, on histologic examination, revealed spontaneous nephritis Between the spontaneous nephritis and the spontaneous arteriosclerosis, no relation seemed to exist

3 Klotz, O A Discussion on the Classification and Experimental Production of Arteriosclerosis, Brit M J 2 1767, 1906

as they did not occur in combination in a single instance in the 21 animals with lesions of the blood vessels and kidneys

In addition to this series of 190 rabbits, we had a second series of 20 that were found to have spontaneous nephritis during life as determined by the repeated presence of albumin, cylindroids and casts in the urine on monthly examinations These rabbits were selected from a group of 250 healthy animals in our hutches Their average age at the time the nephritis was discovered was 6 months, and they were followed for a period of three years They were fed 85 Gm of barley and 50 Gm of alfalfa daily, with the addition of greens twice each week This diet proved to be so balanced that their urines were neutral or slightly alkaline in reaction, the p_H averaging 7 During the last year of the three year period, 10 of the 20 animals were placed on a liver diet suggested by McCollum,[4] to determine whether the pathologic alterations already present would be exaggerated by the feeding of a diet having a high content of protein Acid urines with an average p_H of 6 2 were passed by these animals while fed this diet Near the conclusion of the experiment, 12 of the animals died, 6 in the group fed alfalfa and barley and 6 in the group fed liver diet At autopsy, pneumonia was present in 5 animals One had died from a ruptured blood vessel following the passage of a stomach tube In the remaining 6 animals, the cause of death was not evident Death from uremia was a possible explanation Obvious uremic symptoms had not been present, however

The blood chemisty and the phthalein output of these animals were determined at the end of two years and at the conclusion of the experiment The average of the nonprotein nitrogen for the 8 surviving animals had increased from 36 85 mg per hundred cubic centimenters of blood to 49 73 mg, the urea nitrogen from 19 86 to 26 67 mg and the phthalein percentage for one hour had decreased from 62 3 to 53 3 per cent

These changes together with the studies of the blood pressure made throughout the course of the experiment, will be reported in detail in a subsequent communication

It must be recognized that the occasional presence of albumin and casts in the urine does not necessarily signify nephritis in rabbits, but when these are repeatedly present over long periods of time (in our animals, for a period of three years) and when accompanied by a demonstrable change in blood chemistry and decrease in function of the kidney, the presence of nephritis cannot be doubted The results

4 Polvogt, L M, McCollum E V and Simmonds, N The Production of Kidney Lesions in Rats by Diets Defective Only in that They Contained Excessive Amounts of Protein, Bull Johns Hopkins Hosp **34** 168, 1923

of the histologic examination of the kidneys of these animals justify this conclusion

In studying the alterations found in the arteries and kidneys of this group of 20 rabbits, in which a spontaneous and a persistent nephritis had been demonstrated by the aforementioned criteria, it is advisable to divide the group into two subgroups of 10 animals each The first of

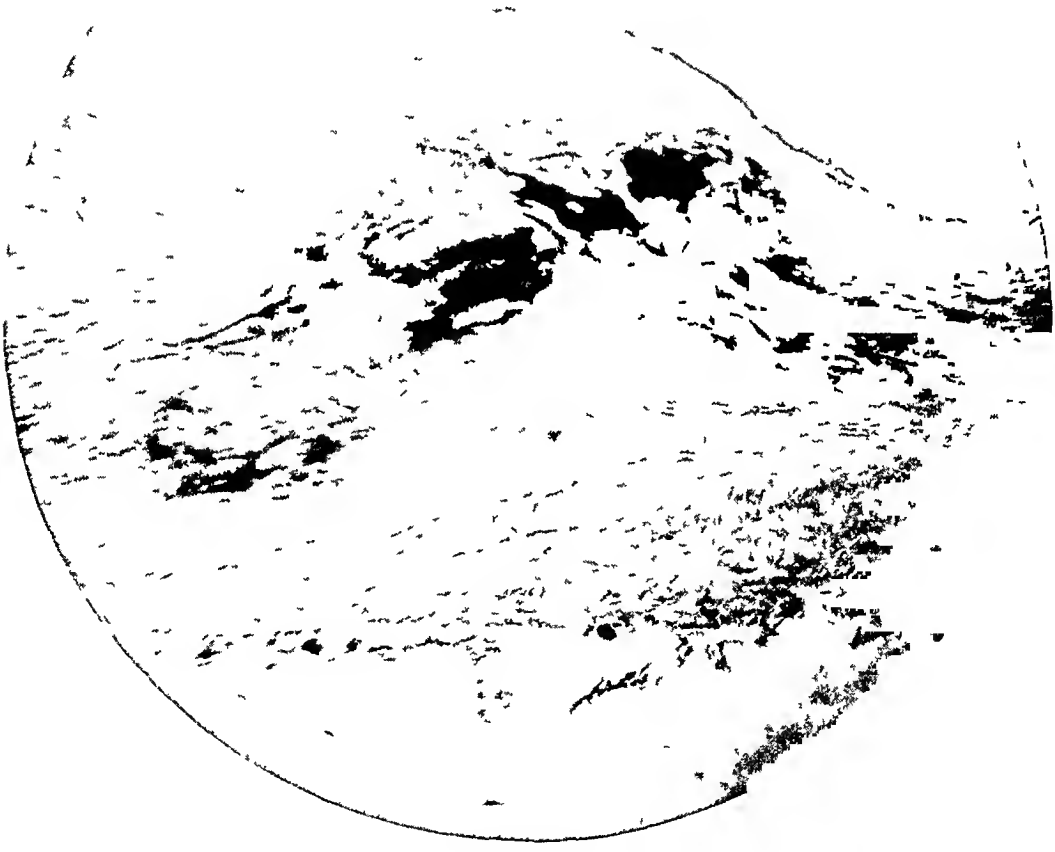

Fig 4 — Arteriosclerosis of both types, showing extensive calcification of media and lipoid infiltration of intima

these received only the barley and alfalfa diet, so that the pathologic changes encountered cannot be attributed to overfeeding of protein In the second subgroup, which was fed the liver diet during the last year of the experiment in an attempt to make more pronounced the spontaneous changes already present, new processes may have been initiated, as it has been amply demonstrated that diets with high content of protein

are capable of causing vascular and renal injury in the rabbit (Newburgh and Clarkson[2] Ignatowski,[5] Steinbliss[6] et al)

In the aortas of 4 of the animals of the first subgroup there was sclerosis of the raised intimal type Medial sclerosis was also present in 1 of these The process in 3 of the animals was limited to the root and arch of the aorta, and consisted of discrete elevated plaques not over 2 mm in diameter, scattered over the surface of the wall The aorta of the fourth animal, in which both types of sclerosis were present was diffusely involved down to the diaphragm very little normal intima remaining, while there was an advanced degree of calcification of the media In one instance, the aortic valve was involved by extension of the process from the vessel wall Marked renal changes were present eight times in this group of 10 animals The histologic picture will be described later

The aortas of 8 of the animals in the second subgroup of 10 (liver diet) were changed similarly, but more extensively The process was confined to the intima, and in 2 instances the wall of the vessel was involved throughout its entire length down to the iliac bifurcation, with a thrombosis of the abdominal portion in 1 In the other 6 instances, the wall of the root and arch of the aorta contained many diffusely scattered arteriosclerotic plaques The kidneys were involved in 9 of the 10 animals comprising the group

A further study was made of the coronary arteries and of the arterioles in various organs (heart, liver, spleen and lungs) of the 20 animals with spontaneous nephritis No coronary sclerosis was encountered in the first subgroup The pulmonary and splenic arterioles were thickened in one of the animals, the pulmonary arterioles alone in another Coronary sclerosis was present in 3 of the 10 that had received the liver diet It consisted of minute yellowish papules, just discernible to the naked eye, limited to the region of the ostium and proximal 2 cm to the left coronary artery The lumen of the vessel was not encroached on, and there was no calcification The splenic arterioles were thickened twice, and those of the lungs four times, in the animals of this second subgroup Histologically, the arteriolar thickening was characterized by medial hypertrophy and intimal hyperplasia

Degeneration of the myocardium or disease of the arterioles and capillaries of the coronary circulation was not found in any of the 20 rabbits

---

5 Ignatowski Ueber die Wirkung des tieren Eiwesses auf die Aorta und die parenchymatosen Organe des Kaninchens, Virchows Arch f path Anat **198** 248, 1909

6 Steinbliss, W Ueber experimentelle alimentare Atherosklerose Virchows Arch f path Anat **212** 152, 1913

Pronounced alterations of the kidneys were encountered histologically in 17 of the group of 20 rabbits They were diffuse, involving all the renal structures in every instance and varying only in degree Newburgh and Clarkson[7] stated that the pathologic process in the spontaneous nephritis of rabbits is characteristically of focal type, being limited to small foci of scarring throughout the kidney with intervening regions

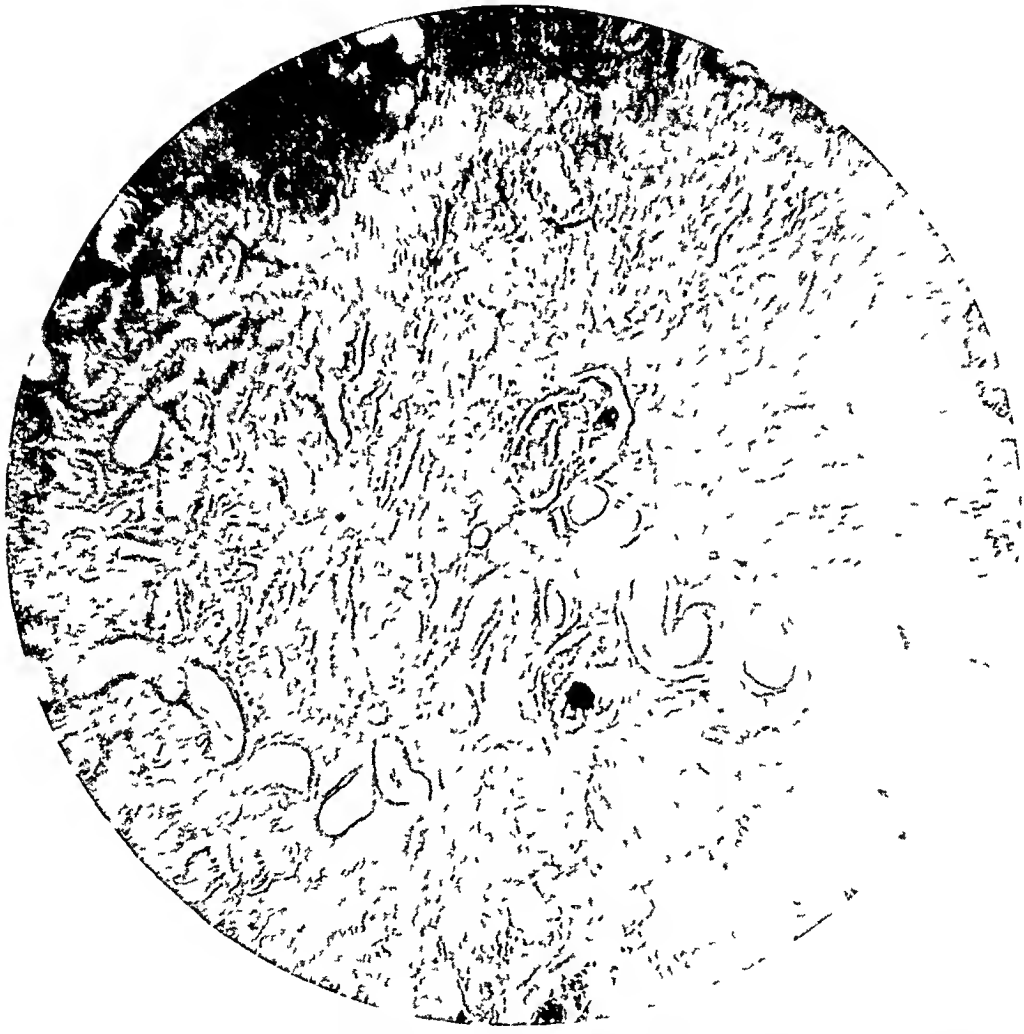

Fig 5—Spontaneous diffuse nephritis The dilated tubules contain hyaline casts Glomerular tufts are adherent to the capsules A diffuse overgrowth of interstitial tissue is seen

of normal parenchyma, whereas the nephritis produced experimentally by feeding a diet having a high content of protein consists primarily of degenerative changes in the tubular apparatus It will be remembered

7 Newburgh L H, and Clarkson S Renal Injury Produced in Rabbits by Diets Containing Meat, Arch Int Med **32** 850, 1923

that in the group of 190 normal rabbits first discussed, spontaneous nephritis was encountered on histologic examination in 4 instances In 2 of these the disease was of a distinctly focal type, corresponding in every detail to the description by Newburgh and Clarkson In the others, however, the process was diffuse and identical with that occurring in 17 of the 20 animals selected because of clinical evidence of nephritis,



Fig 6—Spontaneous focal nephritis Note area of scarring involving all the renal structures

and similar in appearance to the renal changes produced by us in the experimental feeding of diets with high content of protein [8]

Histologically, in this type of diffuse nephritis, there is a thickening of Bowman s capsule and often fusion between it and the glomerular tuft Further changes are manifested by increased cellularity of the tuft absence of red blood cells within the glomerular capillaries and, in

8 Nuzum F R Changes in the Kidney in Animals with Increased Blood Pressures While on High Protein Diets, Arch Int Med **40** 364, 1927

some instances, if the process is progressive, intracapillary thrombosis, hyalinization and, as an end-stage, partial to complete replacement of the glomerulus by fibrous tissue The changes of the tubules consist of dilatation, flattening of the cells lining the tubules, with epithelial desquamation and necrosis in some instances, and the presence of many hyaline casts within the dilated lumina These alterations are usually most evident in the loops of Henle and the collecting tubules, but in many instances no part of the tubular apparatus is spared

A diffuse increase of interstitial tissue with small areas of round cell infiltration about the diseased tubules, is sometimes apparent More often there are focal areas of scarring throughout the cortex, involving all of the renal structures in the fibrous mesh These scars are similar in appearance to the focal lesions of spontaneous nephritis previously mentioned In each instance in which they were present in this group of animals, however, diffuse changes of an advanced degree were also found It is probable that they are distinct from the diffuse process and represent a healed spontaneous nephritis of focal type resulting from an injury of an earlier date to the kidney The fact that this focal scarring was always accompanied by advanced diffuse alterations suggests that it may have predisposed the kidney to further injury by decreasing the tissue reserve Since the diffuse lesion often occurred in the absence of such previous scarring, it is evident that the latter scarring is not a necessary precursor of it Likewise, as noted in the histologic examination of the kidneys of 190 normal rabbits, focal scarring may occur without accompanying diffuse changes

The vessels are typically altered in most instances, especially those of the medullary rays The walls appear almost uniformly thickened, apparently owing to hypertrophy of the media The intima is thrown into folds and the lumen of the vessel is decreased in size (figs 7 and 8) Thrombosis or hyalinization of the renal vessels is not encountered

These histologic changes were encountered in the kidneys of 17 of the 20 rabbits comprising the group with clinical spontaneous nephritis In the kidneys of the remaining 3 animals, the changes were so slight that they could not properly be classified as diffuse nephritis The walls of the vessels showed slight thickening The glomerular capsules were definitely thickened, and in one instance the glomerular tufts were adherent Occasionally, a dilated tubule was seen, but the tubular cells appeared unaltered, and no casts were found Slight though these alterations were, it was felt that they represented a beginning stage of what would have developed later into a typical diffuse nephritis, had the experiment been continued for a longer period of time

We have previously noted the similarity between the types of sclerosis occurring in the aortas of our animals and the common arteriosclerotic

processes affecting the larger arteries of man A further comparison may be made between the arteriolar disease of the rabbit and that described as occurring in hypertensive diseases of man

In the kidneys of the 20 animals with spontaneous nephritis, all of which had elevated blood pressures, medial hypertrophy of the inter-

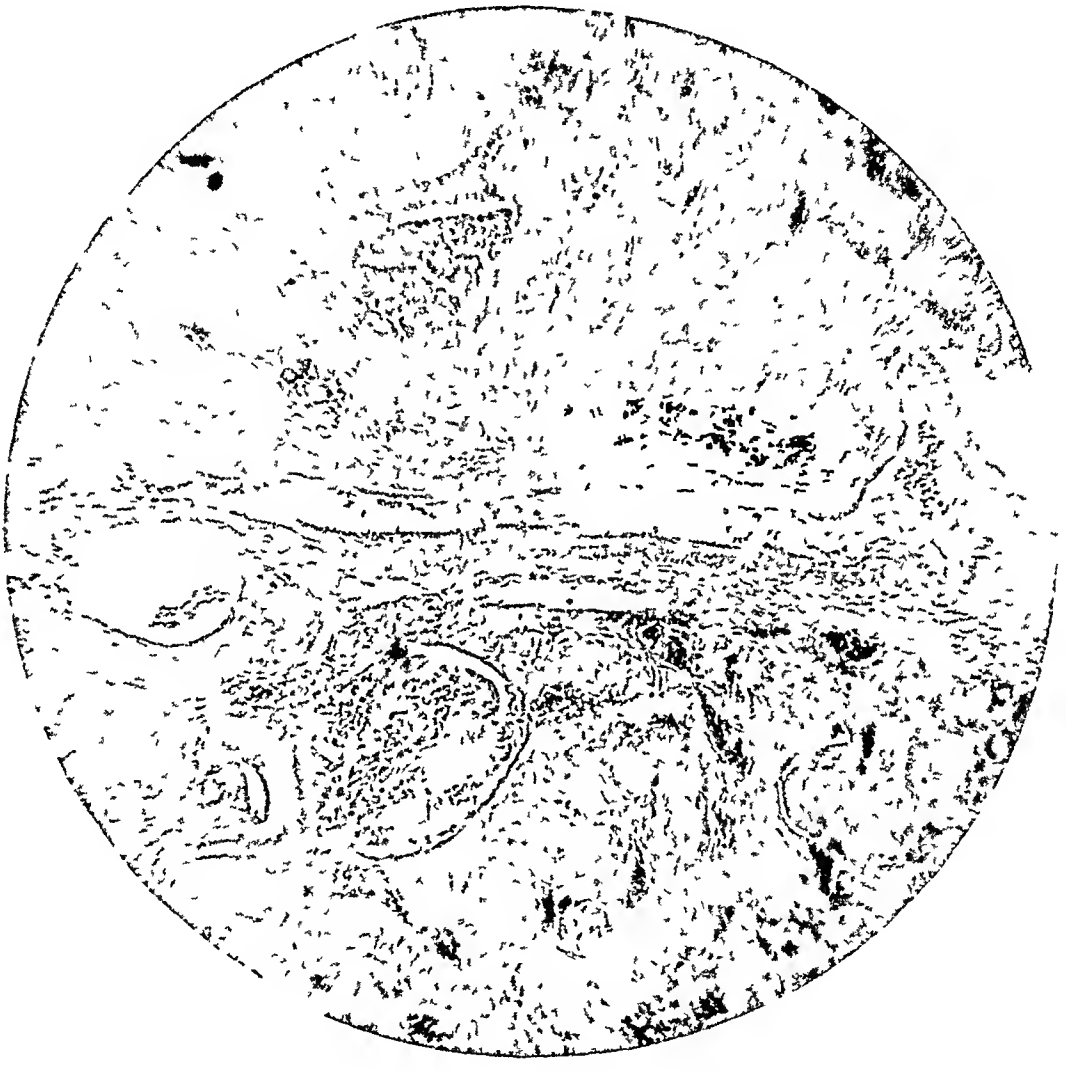

Fig 7—Arteriolar thickening in spontaneous diffuse nephritis Note also round cell infiltration about the diseased tubules

lobular arterioles of the kidney was a constant observation In the lungs and spleen of several of the animals arteriolar thickening was found There were both medial hypertrophy and intimal hyperplasia Fishberg,[9] in a study of the anatomic observations in essential hyper-

9 Fishberg A M Anatomic Findings in Essential Hypertension Arch Int Med **35** 650 1925

tension, found arteriolar changes in the kidneys as a constant accompaniment of the disease The splenic arterioles were affected in two-thirds of his 72 cases, the pancreatic in one-half, the hepatic in less than one-third, the cerebral in less than one-fifth Histologically, the afferent renal vessels first showed a deposition of hyaline material beneath the endothelium, with later fatty changes In the interlobular arteries, a

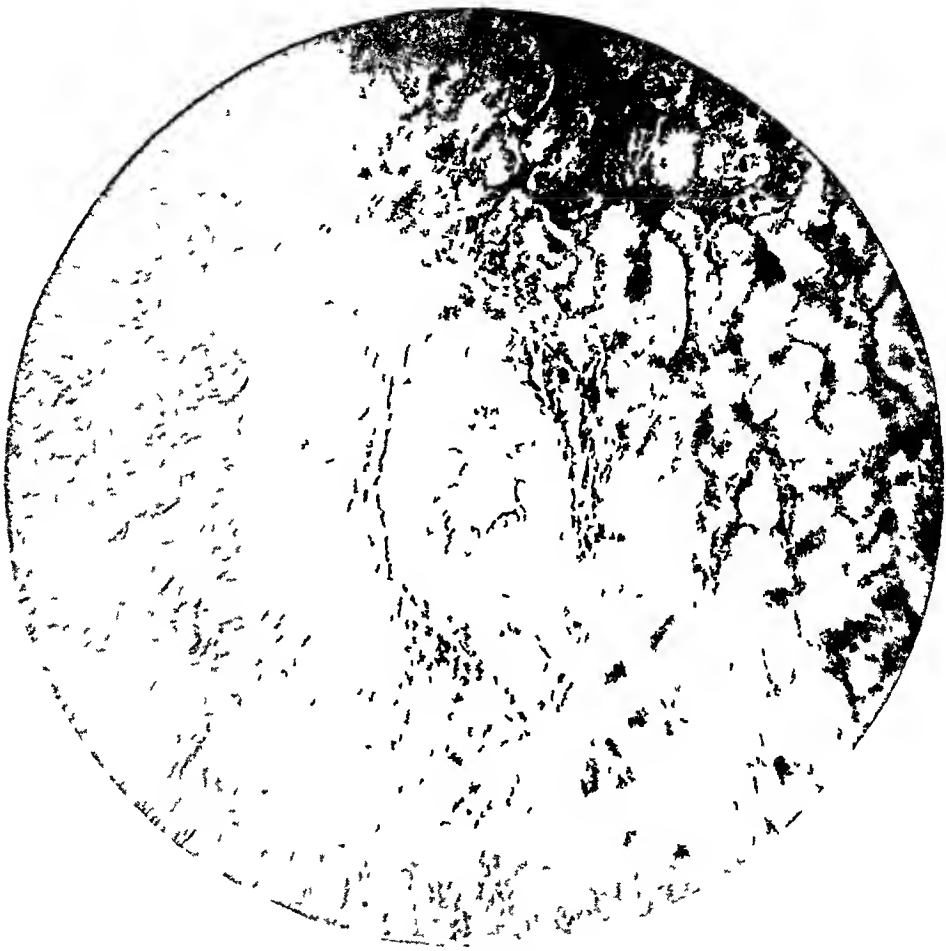

Fig 8—Cross-section of a thickened renal vessel The media is hypertrophied, the intima thrown into folds

hyperplasia of the internal elastic lamina was followed by infiltrative phenomena, connective tissue proliferation medial atrophy and replacement by connective tissue He did not find hypertrophy of the media in this series, but in a later communication [10] stated that he had seen it in the arcuate renal arteries in instances of long-standing glomerular

10 Fishberg A M The Arteriolar Lesions of Glomerular Nephritis, Arch Int Med **40** 80, 1927

nephritis The primary change in the arterioles of other organs was hyalinization

Medial hypertrophy of the arterioles the most frequently occurring lesion in the kidneys of our animals, has been noted as a pathologic feature of hypertension in man by many observers Allbutt[11] said that "in cases of high arterial pressures whether it be a true muscular hypertrophy or not at any rate a thickening of the media is obvious " Volhard and Baehr (quoted by Fishberg) noted both its presence and its absence in essential hypertension Keith, Wagener and Kernohan,[12] in a postmortem study of 7 instances of malignant hypertension (hypertension combined with severe neuroretinitis and normal renal function) found intimal hyperplasia and medial hypertrophy in the arterioles of all organs and tissues of the body We recently studied the microscopic sections from an instance of malignant hypertension, and were struck by the similarity in appearance that the arteriolar lesions occurring in experimental animals bear to the generalized arteriolar-capillary disease characteristic of this condition

While we do not wish to say positively that the arteriolar lesions accompanying long-standing hypertension in man are identical with those occurring in the rabbit, yet it is certain that they are morphologically similar, and it seems possible that the mechanism of production may be the same in both Our rabbits had elevated blood pressures over a period of almost three years, comparable to a duration of half a lifetime in man The response of the vascular tissues to this prolonged strain theoretically might be of the same character as that occurring in man under similar circumstances Although the pathologic process in man and animal may show differences in distribution and minor histologic detail, it is probable that the changes observed in both instances represent a reparative-degenerative response of the vessel wall to increased intravascular tension

COMMENT

The two types of spontaneous sclerosis described by us are not strictly in accord with the results of other observers, who have often failed to distinguish clearly between these two processes, or have simply described calcification of the media as the distinctive pathologic change It is important to recognize the fact that sclerosis of the intimal or raised type can occur spontaneously, because it is the one that results from the experimental feeding of diets having a high content of protein

11 Allbutt T C Arteriosclerosis New York, The Macmillan Company, 1925, p 32

12 Keith M N , Wagener, H P and Kernohan J W The Syndrome of Malignant Hypertension, Arch Int Med **41** 141, 1928

(or cholesterol) That its spontaneous occurrence is comparatively rare, however, is indicated by the fact that it was encountered only six times, or in 3 1 per cent, of our series of 190 rabbits, while medial calcification, or the depressed type, was present spontaneously in 11 instances, or in 5 8 per cent of the group These types of arteriosclerosis, when occurring spontaneously, are for the most part limited to small areas, but in exceptional instances may cover the greater part of the aortic wall This was true of 2 animals, or 1 per cent of the entire group of 190 rabbits

The sclerosis of the aorta that was found in 18 of the 20 rabbits with spontaneous nephritis is identical histologically with these two types The feeding of a liver diet to 10 of these animals served to exaggerate the process If, on the other hand, the sclerosis in this group of 10 is to be regarded as having been experimentally produced (a justifiable inference, because it occurred in 8 instances, or in 80 per cent of the group and because it was marked in degree and extent), it is seen to be identical with that occurring spontaneously The question as to whether or not the thickening of the splenic and pulmonary arterioles is a spontaneous process cannot be answered at this time

We believe also that spontaneous nephritis may occur in two types The first is focal, as described by Newburgh and Clarkson, and is of comparatively rare occurrence, as it was encountered only twice, or in 1 per cent of 190 normal rabbits used in this study It probably does not produce clinical evidence of nephritis The second type is diffuse, little of the renal tissue escaping injury Casts and albumin appear in the urine, there are retention of nitrogen bodies in the blood and elevation of blood pressure It is similar histologically to the nephritis produced by feeding experiments, and is comparable to chronic diffuse nephritis in man

We are uncertain as to the etiologic factors involved in these spontaneous changes It will be remembered that our normal animals were fed a stock diet of barley, 52 Gm , and alfalfa, 150 Gm , daily throughout life On analysis, this diet is shown to contain 14 2 per cent of protein Much evidence has been accumulated that diets with high content of protein are capable of injuring the kidneys and blood vessels of rabbits, but this percentage of protein is less than any used successfully, to our knowledge, to produce such changes In a previous experiment,[13] we produced arteriosclerosis of the raised intimal type in 7 of 11 animals fed an oat diet containing 16 per cent protein over a period of two years

13 Nuzum, F R , Seegal, B , Garland, R , and Osborne, M Arteriosclerosis and Increased Blood Pressure Experimental Production, Arch Int Med **37** 733, 1926

Nine of these animals had renal changes [8] It may be that the high percentage of intimal sclerosis and of nephritis occurring in this group is attributable, at least in part, to the 14 2 per cent protein in the diet

TABLE 1—*Relation of Infection to Changes in the Aorta and Kidneys of Twenty Rabbits with Spontaneous Nephritis*

Rabbit and Diet	Infection: Nature	Infection: Duration, Mo	Infection: Year	Arteriosclerosis of Aorta	Nephritis
Alfalfa and barley					
71	Abscess of feet Infection of ear	10 10	Second First	None	Very marked diffuse
66	Infection of ear Abscess of feet	4 15	First First and second	Arch, small plaques	Moderate diffuse
69	Abscess of breast	15	Second and third	Root and arch, confluent plaques	Very slight*
78	Infection of ear Abscess of foot	5 1	First Third	None	Slight diffuse
75	Infection of ear	5	First	Root to diaphragm (both types)	Slight diffuse
76	Infection of ear	3	First	Arch, two small plaques	Moderate diffuse
68	Abscess of feet	2	Third	None	Marked diffuse
61	Infection of ear Abscess of foot	1 1	First First	None	Moderate diffuse
73	Infection of ear	1	Second	None	Very slight*
62	None			None	Very marked diffuse
Liver					
60	Infection of ear, pneumonia (terminal)	16	Second and third	Entire arch, confluent plaques	Moderate diffuse
63	Infection of ear Abscess of feet	2 6	Second First	Entire aorta, thrombosis abdominal portion	Very marked diffuse
67	Infection of ear	4	First	Arch, scattered plaques	Slight diffuse
70	Infection of ear Abscess of leg, pneumonia (terminal)	4 1	First First	Arch, scattered plaques, aortic valve sclerotic	Moderate diffuse
65	Infection of ear Abscess of foot	2 1	Second Second	None	Moderate diffuse
64	Infection of ear, pneumonia (terminal)	3	First	None	Moderate diffuse
79	Infection of ear	3	First	Entire aorta, confluent plaques	Moderate diffuse
77	Infection of ear Abscess of foot	1 2	First Second	Arch, scattered plaques	Very slight*
72	Infection of ear, pneumonia (terminal)	2	First	Arch, scattered plaques	Slight diffuse
74	Abscess of leg, pneumonia (terminal)	1	First	Arch, scattered plaques	Slight diffuse

* Alterations limited to the vessels and glomerular capsules

The possible rôle of infection in the production of these spontaneous changes should be considered Several observers (Gilbert and Lyons,[14] Klotz [3] et al) have produced arterial lesions in rabbits by the intravenous injection of bacteria Newburgh and Clarkson found renal

14 Gilbert and Lyons, quoted by Klotz (footnote 3)

changes of a focal type "fairly common" in 19 rabbits used as controls for their feeding experiments These animals were purposely exposed to the infections prevalent in their laboratory animals The vascular system in this group, however, was unaltered

Table 1 shows the infections present in our group of 20 rabbits with spontaneous nephritis during the three year period of the experiment The nature and duration of the infection, the year of its occurrence and the pathologic data in brief are presented for each animal In the second column, the infections are arranged in sequence of decreasing severity and duration from above downward this order being followed for the group of 10 animals that were fed the alfalfa and barley diet and for the group of 10 that were fed the liver diet The infection of the ear listed so frequently consisted of a nonsuppurative parasitic disease of the external auditory canal This disease, almost uniformly present in the early months of the experiment, was later eradicated by appropriate treatment Abscess of the foot was a frequent complication Pneumonia was a frequent terminal infection

All the animals suffered from one or more of these infections at some time during the course of the experiment, with the exception of rabbit 62 This animal had, however, marked diffuse nephritis

We were unable to determine any correlation between the character and duration of the infection and the degree and nature of the spontaneous changes in the kidneys and blood vessels

SUMMARY

Spontaneous sclerosis of the arteries of rabbits occurs in two types (1) an elevated intimal lesion and (2) a depression of the intima associated with medial calcification These are pathologically unlike each other, but are identical with lesions produced experimentally The incidence of the former type we found to be 3 1 per cent and of the latter, 5 3 per cent in a group of 190 normal animals Spontaneous nephritis, both focal and diffuse, occurred two times each, or in 2 1 per cent of this series In this same group spontaneous nephritis and arteriosclerosis did not occur together in a single instance

In a second group of 20 animals, selected because of clinical evidence of spontaneous nephritis, the kidneys of 17 showed a diffuse nephritis similar histologically to that encountered twice in the first group, and to that produced experimentally by feeding diets with high content of protein The kidneys of the remaining 3 animals presented slight vascular and glomerular changes

Of these 20 animals, 10 were fed a liver diet for one year, and in the aortas of 8 of these 10 elevated intimal lesions were present There

was no sclerosis of the depressed type Diffuse renal lesions were present in 9 Of the remaining 10 animals, 4 presented elevated sclerosis, 1 both types, and 8 diffuse nephritis

A study of the coronary arteries and arterioles of the heart, liver, spleen and lungs in this group of 20 animals was made In the 10 not fed liver, there was no coronary sclerosis The pulmonary and splenic arterioles were thickened in 1 animal, the pulmonary arterioles alone in another In the 10 fed liver, coronary sclerosis of slight degree was present three times thickening of the splenic arterioles twice and thickening of the pulmonary arterioles four times Histologically, medial hypertrophy and intimal hyperplasia were present

Disease of the coronary arterioles or myocardium was not found in these 20 animals

The possible etiologic factors involved in these spontaneous changes are discussed

CONCLUSIONS

The arteries of rabbits are subject to two types of spontaneous disease (1) elevated intimal lesions and (2) intimal depressions overlying medial calcification These changes occur infrequently in large groups of normal animals They are histologically different from each other, but identical with lesions regarded as of experimental production and similar to the common types of arteriosclerosis in man

The kidneys of rabbits present also two types of spontaneous alteration (1) focal nephritis and (2) diffuse nephritis The renal alterations occur more infrequently than do the arterial lesions These two types of spontaneous nephritis may occur separately or in combination and bear no relation to spontaneous vascular disease

The focal type of spontaneous nephritis gives no clinical evidence of its presence Histologically, it consists of small areas of scarring, involving a minimum of renal tissue, but all the renal structures in the diseased area It may possibly predispose to the development of diffuse nephritis by reducing tissue reserve

The diffuse type is manifested clinically by the presence of persistent albuminuria, cylindruria, alterations of the blood chemistry, decrease in phthalein excretion and increase in blood pressure Histologically, it is identical with the nephritis thought to be produced by feeding of a diet having a high content of protein, and somewhat similar to chronic diffuse nephritis in man

A liver diet with high content of protein fed to an animal with spontaneous nephritis of the diffuse type probably increases the renal injury, as judged clinically and pathologically It also increases the

vascular disease already present spontaneously and initiates new vascular injury

Disease of the arterioles of the lungs and spleen involving the media and intima, and disease of the coronary arteries, may occur in combination with diffuse nephritis The arteriolar disease is morphologically similar to that described as occurring in the hypertensive diseases of man, and probably represents a response of the vascular wall to increased intravascular tension

Infection plays little or no apparent causal rôle in the production of spontaneous vascular and renal disease in the rabbit

SCLEROSIS OF THE PULMONARY ARTERY AND ARTERIOLES

A CLINICAL PATHOLOGIC ENTITY *

SOL ROY ROSENTHAL, M D
CHICAGO

Sclerosis of the pulmonary artery was first mentioned by Vieussens in 1706 It was over a hundred years before it was again described by Bouillaud and then in 1829, by Andral,[1] who noted pulmonary sclerosis in association with mitral stenosis Laennec suspected these lesions in his description of infarcts of the lung, which he thought were of local origin and secondary to local formation of thrombi However, Virchow's theory of their embolic origin was prevalent at that time (1856) It was not until more recently that the local formation of thrombi was proved (Rist and Roland,[2] Letulle and Jacquellin [3])

Romberg [4] and Aust [5] described primary sclerosis of the pulmonary artery, but gave no explanation Marchand [6] believed that increased intrapulmonary pressure resulted in pulmonary atherosclerosis Ayerza [7] suggested syphilis as a factor and described a clinical syndrome of what he termed "black cardiacs" that accompanied this condition Posselt [8] reviewed the conception of Andral and also mentioned primary atherosclerosis of the pulmonary artery

The majority of the aforementioned observations were made macroscopically, and only the larger branches of the pulmonary artery

---

Submitted for publication, May 17, 1930

* From the Department of Pathology, Cook County Hospital, Dr Richard H Jaffe, Director

1 Andral, G Maladies des pulmones, Traite d'anatomie pathologique, 1829, vol 2, p 294

2 Rist and Roland Contribution a l'etude clinique, anatomique et pathogenique des infarctes et des hemorragies pulmonaires au cours de l'endocardite a evolution prolongee, Ann de med **3** 20, 1926

3 Letulle and Jacquellin Aneurysme syphilitique de l'artere pulmonaire Arch d mal du coeur **13** 385, 1920

4 Romberg, E Ueber Sklerose der Lungenarterie, Deutsches Arch f klin Med **48** 197, 1891

5 Aust, C Casuistischer Beitrag zur Sklerose der Lungenarterie, Munchen med Wchnschr **39** 689, 1892

6 Marchand Ueber Arteriosklerose (Athero-Sklerose), Verhandl d Kong f inn Med, 1904, p 23

7 Ayerza, L Ayerza's Disease, Rev Soc de med int **6** 73, 1925

8 Posselt, A Die Erkrankungen der Lungenschlagadern, Ergebn d allg Path u path Anat **13** 298, 1909, Zur Pathologie und Klinik der primaren Atherosklerosis pulmonalis, Wien Arch f inn Med **11** 357, 1925

were considered In 1920, Eppinger and Wagner [9] described five cases of what they believed to be primary atherosclerosis of the smaller and larger branches of the pulmonary artery associated with the clinical syndrome as described by Ayerza, namely, cough, dyspnea, cyanosis, edema and marked hypertrophy of the right ventricle of the heart

Lang [10] then showed that a thrombo-arteriolitis may be the origin of this clinical syndrome, and he believed that some of Eppinger's cases were infective

Von Glahn and Pappenheimer [11] described rheumatic changes of the smaller pulmonary circulation (McClenahan and Paul [12])

Primary arteriosclerosis and arteriolosclerosis of the pulmonary artery is rare Thomas [13] in reviewing the literature found only 10 cases among 500 reported (Monckeberg,[14] Rossle,[15] Tchistovich [16] Vaquez [17] Lowenstein,[18] Durand,[19] Eppinger and Wagner [9] and more recently Bacon and Apfelbach,[20] Warthin,[21] Clark, Coombs, Hadfield and Todd [22] and Steinberg [23] described changes in the intima only)

---

9 Eppinger H, and Wagner, R Zur Pathologie der Lunge, Wien Arch f inn Med **1** 83, 1920

10 Lang, G Zur Frage der thrombo-arteriolitis pulmonaires, Deutsches Arch f klin Med **114** 539, 1924

11 Von Glahn, W C, and Pappenheimer, A M Specific Lesions of Peripheral Blood Vessels in Rheumatism, Am J Path **11** 235, 1926

12 McClenahan, W U, and Paul, J R A Review of the Pleural and Pulmonary Lesions in Twenty-Eight Fatal Cases of Active Rheumatic Fever, Arch Path **8** 595, 1929

13 Thomas Marcel Des affections acquises de l artere pulmonaire, These de Paris, no 474, 1929

14 Monckeberg Ueber die genuine Arteriosklerose der Lungenarterie, Deutsche med Wchnschr **33** 143, 1907

15 Rossle Ueber Hypertrophie und Organkorrelation, Munchen med Wchnschr **8** 377, 1908

16 Tchistovich Thrombo-arterite obliterante pulmonaire chronique, Compt rend Soc de biol **2** 627, 1923

17 Vaquez, M Bull et mem Soc med d hop de Paris **26** 183, 1908

18 Lowenstein, K Ueber Thromboarteritis pulmonalis, Frankfurt Ztschr f Path **27** 226, 1922

19 Durand, P L'endo-arterite primitive de l artere pulmonaire, These de Paris, 1927

20 Bacon, C M and Apfelbach, C W Primary Sclerosis of the Pulmonary Artery and Its Branches, Tr Chicago Path Soc **12** 293, 1927

21 Warthin, A S A Case of Ayerza's Disease, Tr A Am Phys **34** 219, 1919

22 Clark, R C, Coombs, C Hadfield, G, and Todd, A T On Certain Abnormalities Congenital and Acquired, of the Pulmonary Artery, Quart J Med **21** 51 1927

23 Steinberg Ulrich Systematische Untersuchungen uber die Arteriosklerose der Lungenschlagadern, Beitr z path Anat u z allg Path **82** 443, 1929

Because of the lack of the right material it has been difficult to trace the pathologic development of this condition, and indeed some authors have questioned primary atherosclerosis of the pulmonary artery as an entity (Ayeiza,[7] Arrillaga,[24] Escudero,[25] Warthin,[21] Hare and Ross[26]) These authors believed that syphilis plays the most important rôle

The author has had the opportunity to study three cases of primary atherosclerosis of the pulmonary artery showing varying stages of the disease, so that its development could be studied These observations justify primary arteriosclerosis and arteriolosclerosis of the lungs as a definite clinical and pathologic entity

The three cases are presented in the order of their pathologic development

CASE 1

History—A white man, a Canadian, aged 45, complained on entrance into the hospital of dyspnea and cyanosis of one week s duration He had been a tool-grinder, on and off, for fifteen years Some years (?) before, he began to have a cough that was productive of a moderate amount of mucus varying in color from white to black This did not trouble him markedly, and he did not heed it About one year before, he noticed that his finger-tips and face were becoming blue, and three months before, he noted dyspnea on exertion He continued to work, however, until one week before admittance when he became markedly weak and cyanotic No edema had been noted, but there had been some swelling of the abdomen for one month

His past history and family history were essentially negative

Physical Examination—On examination, the patient was found to be obese, dyspneic and cyanotic, and from time to time he coughed The temperature taken rectally was 99 6 F , the pulse rate, 100, the respiration rate, 28, and the blood pressure 150 systolic and 90 diastolic

The essential observations were as follows The face, neck and extremities showed marked cyanosis There was slightly increased resonance over the entire chest, with diminished tactile and vocal fremitus The breath sounds were diminished slightly, but no abnormal sounds were heard Because of the obesity, the borders of the heart were difficult to percuss The tones were of fair quality and intensity and of regular rhythm and rate The second pulmonic beat was accentuated The abdomen was distended and tympanitic, with slight dulness in both flanks, but with no shifting dulness There was no edema

---

24 Arrillaga, F C Esclerosis secundaria de la arteria pulmonar y su cuadro clinico (Cardiacas Negros), These de Buenos Aires, 1912, Sclerose de l'artere pulmonaire secondaire a certains etats pulmonaires chroniques, Arch d mal du coeur **6** 518, 1913, Sclerose de l'artere pulmonaire, Bull et mem Soc med d hôp de Paris **13** 292, 1924

25 Escudero, P Polycythemia and Erythreosis with Sclerosis of the Pulmonary Artery, Rev Soc de med int **1** 463, 1925

26 Hare, C D, and Ross, J M Syphilitic Disease of the Pulmonary Arteries, Lancet **2** 806, 1929

Laboratory Examination—The urine contained a trace of albumin The Kahn reaction of the blood was negative The carbon dioxide combining power was 46 The urea nitrogen was 23 mg, and the creatinine, 1 95 mg, per hundred cubic centimeters of blood No blood count was recorded

Course—The patient remained in the hospital for six days, during which his cyanosis deepened He became irrational, sank into a stupor and died

Clinical Diagnosis—The clinical diagnosis was Pulmonary arteriosclerosis with enlargement of the right side of the heart or pneumonoconiosis

Postmortem Examination (Dr R H Jaffe)—The body weighed 171 pounds (77 6 Kg) and was 159 cm in length

Externally there was marked cyanosis of the face and the chest, and over the neck deep purple patches varying in size from that of a pinpoint to that of a pinhead The lower extremities were slightly edematous

When the chest was opened, the lungs were found collapsed, the pleural cavities contained no fluid or adhesions The lungs were subcrepitant to crepitant throughout The surfaces made by sectioning were deep gray and smooth

The heart weighed 460 Gm The left ventricular wall was 18 mm and the right ventricular wall was 5 mm thick The apex was formed by the right ventricle The myocardium was reddish brown and moderately firm

The aorta measured 60 mm in circumference 1 cm above the cusps The intima was studded by a moderate number of hyaline and fatty plaques

The pulmonary artery measured 90 mm in circumference 1 cm above the cusps The intima of the main trunk and two main branches was smooth In the branches of the first order there were slightly elevated, light yellow plaques which became more numerous and confluent in the branches of the third and fourth order

The kidneys, spleen and liver were deeply cyanotic and moist with blood

The bone-marrow was deep red

Microscopic Examination—In the larger bronchi, the mucosa was slightly thickened by an increase in fibrous tissue and dilated capillaries The epithelium in focal areas was composed of two or three layers of transitional cells The smaller bronchi were filled with desquamated and degenerated epithelial cells and erythrocytes There was no round cell infiltration or peribronchial fibrosis

The alveoli of the lungs were moderately to markedly distended Their walls in some instances were thicker than normal because of capillary dilatation and accumulations of large cells that contained black and brown pigment In other places, the alveolar walls were thin and composed of fibrous and hyaline tissue in which were scattered pyknotic nuclei These walls were poor in elastic fibers

In the intrapulmonary arteries up to 0 2 mm in diameter, the intima in most instances, showed no change In a few of these vessels, the intima was slightly thickened The subendothelial layer contained a hyaline substance that stained red by Van Gieson's method The inner elastic membrane in a few vessels was split The media showed the most constant change There was a definite increase in its thickness, which was due in greatest part to an increase in elastic fibers and to a less extent to hypertrophy of the muscle fibers Occasionally, adjoining the internal elastic membrane were large spaces, each containing a pyknotic nucleus The adventitia was unchanged There was no round cell infiltration An occasional fibrin thrombus was seen in the lumen

Intrapulmonary vessels from 0 2 to 0 4 mm in diameter, in the majority of instances were unchanged Occasionally there was a slight thickening of the intima, especially of the subintimal layer, and also a thickening of the internal

elastic membrane The media was slightly thickened, owing to an increase of elastic tissue The adventitia was unchanged There were no thrombi in these vessels

Intrapulmonary vessels over 0 4 mm in diameter were practically unchanged, except for a slight thickening of the internal elastic membrane

No organisms were found in the walls of the larger or smaller intrapulmonary vessels of the lung by the Gram-Weigert method

In the extrapulmonary arteries, there was an increase in the size of the media due to an increase of elastic tissue and a hypertrophy of the muscle fibers The intima was slightly thickened subendothelially by large pseudoxanthomatous cells The adventitia was unchanged

The intima of the aorta was thickened by large hyaline plaques with central deposits of lipoid material Pseudoxanthomatous cells were scattered focally in the subendothelial layer The media in these areas was reduced in size, whereas in the intervening areas it was of normal thickness The adventitia was unchanged

The veins were collapsed and filled with a small amount of blood No changes in their walls were noted

In the wall of the left ventricle of the heart, the muscle fibers were slightly thicker than normal, and their cross-striations were indistinct There was a marked capillary hyperemia The arterioles were dilated, but their walls were not thickened In the wall of the right ventricle, the muscle fibers were markedly thickened, the nuclei were of irregular shape and rich in chromatin The van Gieson stain showed no evidence of hyaline degeneration or scar formation

The kidneys presented a moderate diffuse capillary hyperemia Bowman's capsules were slightly thickened The arterioles were practically unchanged The medium and larger sized arteries showed no thickening of their walls Sudan III preparations revealed no changes

Throughout the liver and spleen there was marked capillary dilatation The arteries and arterioles were unchanged

Bone-marrow of the femur showed hyperemia and numerous foci of erythropoiesis and granulopoiesis

Anatomic Diagnosis—The anatomic diagnosis was as follows Arteriosclerosis of the pulmonary artery, eccentric hypertrophy of the heart, especially of the right ventricle, moderate sclerosis of the aorta and the coronary arteries, passive congestion of the lung, liver spleen, kidneys and bone-marrow, recent hemorrhages in the gastric and intestinal mucosa and in the pancreas, and slight ascites

CASE 2

History—A white man, an Austrian, aged 48, who was a laborer in a cleaning and dyeing plant, on entering the hospital complained of dyspnea, cyanosis and anasarca of the dependent parts of the body The patient had had a cough for many years, with expectoration of whitish mucus About two years before, he became dyspneic and began to show edema of the lower extremities He was treated at home and his heart soon became compensated In the past two years he had had three similar attacks In the last attack, his distress was more marked, with abdominal distention and marked cyanosis The patient had been cyanotic for some time previously, but he did not know the exact length of time Hematemesis or hemoptysis (the patient did not know which) was present with the last attack

The past history and the family history were essentially negative

Physical Examination—Examination revealed a cyanotic, markedly dyspneic, well nourished man who was acutely ill The temperature was 102 4 F , the pulse rate, 144, the respiration rate, 36, and the blood pressure, 120 systolic and 100 diastolic The chest in cross-section was oval, the expansion was equal on both sides, with normal vocal and tactile fremitus and normal resonance Moist, sonorous inspiratory râles were heard over the entire chest The heart was enlarged transversely The apex was 12 5 cm to the left of the midsternal line, and the right border was 2 5 cm to the right of the right sternal margin The heart tones were regular in rate and rhythm No murmurs were audible The abdomen was distended with fluid There was a pitting edema that extended up to and included the abdominal wall

As the patient died shortly after he entered the hospital, no laboratory studies were possible

Clinical Diagnosis—The clinical diagnosis was Cardiorenal disease with decompensation

Postmortem Examination (Dr R H Jaffe)—The body weighed 175 pounds (79 4 Kg) and was 148 cm in length

Externally there was severe cyanosis of the face, neck and extremities, with recent hemorrhages about the nares There was marked edema of the lower extremities scrotum and abdominal wall

When the chest was opened, the lungs were found moderately distended The pleural cavities were normal, except for few fibrinous adhesions on the left side The lungs were subcrepitant to crepitant and presented numerous small palpable nodules throughout The surfaces made by section were gray, except in the left lower lobe, where there were several discrete red granular areas of consolidation

The heart weighed 520 Gm The left ventricular wall was 14 mm and the right ventricular wall was 7 mm thick The myocardium was firm and reddish brown The right ventricle was dilated The endocardium of the left ventricle was thickened and grayish white

The circumference of the aorta was 70 mm 1 cm above the cusps The intima was smooth

The intima of the coronary arteries contained a few hyaline plaques

The circumference of the pulmonary artery was 90 mm Numerous yellow plaques as much as 4 mm in diameter were found throughout the vessel, but were most marked in branches of the second and third order

The kidneys, spleen and liver were deep purple and moist with blood

Bone-marrow from the femur was deep red

Microscopic Examination—The mucosa of the larger bronchi in places was lined by transitional cells In these areas, the cells were piled up in several layers and showed many mitotic figures The walls were thickened, hyperemic and loosely infiltrated by lymphocytes In the cartilage, the capsules of the cells were calcified The smaller bronchi were filled with degenerated desquamated epithelial cells There were many small, anthracotic fibrotic foci at the angles of the septums

In places, the alveolar walls were moderately thickened by an increase in fibrous tissue and a capillary hyperemia There were accumulations of round and spindle-shaped cells The round cells had large oval nuclei and ample oxyphilic cytoplasm and in many instances contained a granular black pigment In other places the alveolar septums were narrow and composed only of fibrous strands that contained pyknotic nuclei (van Gieson's stain) There was a diminished amount of elastic tissue, and in places it was entirely absent In these areas, the arterioles showed their greatest degenerative changes

In intrapulmonary arteries up to 0 2 mm in diameter the intima, as a rule, was markedly thickened There was a splitting of the internal elastic membrane, with an increase of elastic fibers At times, this was associated with proliferation of fibroblasts, and at other times with hyaline and fatty changes of the subendothelial region Thrombi were seen in varying stages of organization The media was uniformly thickened There was an increase in the elastic and fibrous tissue In a large number of instances, large spaces, each containing a pyknotic nucleus, were evident, with hyaline changes, especially adjacent to the internal elastic membrane The adventitia was unchanged

In intrapulmonary vessels from 0 2 to 0 4 mm in diameter, the intima in many instanecs was thickened owing to subendothelial proliferation of fibroblasts and hyaline degeneration The condition of the internal elastic membrane varied from a moderate thickening to a splitting with an increase of elastic fibers There were occasional nodular thickenings of the intima, which were covered by endothelium and contained spindle-shaped cells, fibrous tissue and fine elastic fibrils In some places, small fibrin thrombi covered these nodules The media was uniformly thickened There was an increase in elastic and muscular tissue Large spaces, each with a pyknotic nucleus, were evident sporadically The adventitia was unchanged

In intrapulmonary vessels over 0 4 mm in diameter, changes were noted similar to those in the medium-sized arteries, but not as marked

Gram-Weigert stains did not reveal the presence of organisms in the walls of intrapulmonary arteries or in their thrombi

In extrapulmonary arteries, the intima was thickened subendothelially There was a proliferation of spindle-shaped cells and fibrous tissue Large pseudoxanthomatous cells were present throughout The internal elastic membrane was thickened and in some instances showed splitting The media was thickened by an increase in elastic fibers and a hypertrophy of the muscle fibers The adventitia was unchanged

In the aorta, the intima was only slightly thickened by pseudoxanthomatous cells and fibrous tissue The internal elastic membrane was slightly thickened The media and adventitia were unchanged

The veins were collapsed The intima was thickened in places and formed crescentic areas that were composed of hyaline connective tissue The lumina were occasionally filled by fibrin thrombi The internal and external elastic membranes sometimes approximated each other and gave a homogeneous purple color by means of the elastica stain

The kidneys revealed a moderate diffuse capillary hyperemia The arterioles were slightly thickened subintimally The medium and larger sized arteries showed similar thickenings Sudan III preparations showed accumulations of fat droplets in the basal portions of the epithelium of the convoluted tubules

The liver and the spleen presented marked capillary dilatation throughout There were no arterial changes

In bone-marrow from the femur, the capillaries were diffusely dilated, and areas of erythropoiesis and granulopoiesis were numerous The nuclei of the megakaryocytes were occasionally pyknotic

Anatomic Diagnosis—The anatomic diagnosis was Arteriosclerosis of the pulmonary artery, eccentric hypertrophy of the heart, especially of the right ventricle, diffuse chronic bronchitis and focal bronchopneumonia, severe chronic passive congestion of the liver kidneys, spleen, gastro-intestinal tract and bone-marrow, and edema of the lower extremities and genitalia

CASE 3

History—A white man, a Pole, aged 43, a stone-grinder, complained of dyspnea, cyanosis, edema of the lower extremities and weakness He had had a cough for many years Four years before admittance to the hospital, he became dyspneic and weak He soon began to show edema of the lower extremities Since that time he had had similar attacks

About one year before, he entered the hospital in a semistuporous condition, with puffiness of the face and marked cyanosis of the face and extremities The essential observation at this time was hyperresonance of the chest, with normal breath sounds, except in the bases, where a few moist râles were heard The heart was essentially normal The red cell count varied from 4,500,000 to 5,500,000 The white cell count was around 12,000, with a predominance of polymorphonuclear leukocytes No abnormal cells were seen The diagnosis at this time rested between polycythemia vera of Vaquez's type and angioneurotic edema The patient remained in the hospital for ten days Under rest and treatment with atropine sulphate, he was soon up and about and comfortable The cyanosis continued, but was of less extent Thereafter the patient fared moderately well until one month before his last admittance, then all of his symptoms returned, and in addition his voice assumed the character of a croak His cyanosis was out of proportion to his dyspnea, which was slight

Physical Examination—The temperature on entrance was 98 4 F , the pulse rate, 104, the respiration rate, 28, the blood pressure, 120 systolic and 105 diastolic The essential observations were marked dilatation of the vessels of the face and neck and deep cyanosis that included the entire body The chest was barrel-shaped and was hyperresonant throughout, and there were moist râles in both bases The breath sounds were slightly diminished The heart was enlarged, especially the right ventricle There was a systolic murmur over the apex The abdomen was distended, with shifting dulness The liver was three fingerbreadths below the right costal margin There was marked edema of the lower extremities and the abdominal wall

Laboratory Examination—The patient remained in the hospital for two weeks During this time, the red blood corpuscles varied from 6,690,000 to 6,280,000 The white cell count was 11,150 The x-ray picture showed marked enlargement of the heart, especially of the right ventricle The Kahn reaction of the blood was negative The urine contained albumin (four plus), but no casts

Course—Under treatment with digitalis, the patient improved for a time, then the cyanosis deepened, the respirations became more labored and on the day of his death, the temperature taken rectally rose to 101 F

Clinical Diagnosis—The clinical diagnosis remained the same as at the time of his previous stay in the hospital, with the addition of failure of the right side of the heart and chronic emphysema Because of the croaking voice, mediastinal tumor, aneurysm of the aorta and mediastinal lymph glands pressing on the trachea and superior vena cava were each considered

Postmortem Examination (Dr R H Jaffe)—The body weighed 154 pounds (69 9 Kg) and was 162 cm in length

The skin over the entire body was deep purplish gray The eyelids were edematous, there were bilateral chemosis and marked conjunctival injection The mucosa of the mouth was deep purple, and the oral cavity was filled with blood The lower extremities, the scrotum and penis and the abdominal wall were all firmly edematous

The abdominal cavity contained 1,500 cc of a clear, straw-colored fluid The liver was 8 cm below the xyphoid process and 5 cm below the right costal arch

The pleural cavities contained, the right, 100 cc, and the left, 600 cc, of clear fluid There were edematous fibrous adhesions about the lateral aspect of the right lobe

The pericardial sac contained 250 cc of clear fluid The heart weighed 530 Gm The apex was formed by the right ventricle The wall of the left ventricle measured 19 mm , the wall of the right ventricle in the region of the conus measured 12 mm and near the apex 11 mm The trabeculae and papillary muscles of the right ventricle were prominent The epicardium showed numerous irregular, anastomosing, whitish plaques and pinpoint-sized deep red patches The myocardium was reddish brown and firm

The circumference of the aorta was 73 mm There were few yellow plaques in the abdominal portion

The circumference of the pulmonary artery was 90 mm The intima of the larger branches was smooth In the branches of third and fourth order, there were hyaline plaques arranged longitudinally

The intima of the coronary arteries was smooth, except for a light yellow plaque in the descending portion

The upper and middle lobes of the right lung were distended and crepitant The lower lobe was compressed and subcrepitant The cut surface was deep purplish gray, mottled with black and moderately moist The lobes of the left lung were distended, and the edges were feathery The cut surface was purplish gray and moderately moist

The mucosa of the bronchi was purplish red and covered by a moderate amount of mucus

The mucosa of the larynx was smooth and light purple

The liver, kidneys and spleen were deep purple and moist with blood

The bone-marrow of the femur was deep red

Microscopic Examination—The mucosa of the larger bronchi was slightly thickened by capillary dilatation and an increase of the fibrous tissue The lumina were wide and filled with desquamated epithelium and red blood cells The smaller bronchi were dilated, the epithelium was flattened and in places desquamated

The alveoli of the lungs were wide and their septums thin In many instances, the septums adjoining the alveoli were absent In places, the alveolar walls were replaced by fibrous and hyaline tissue that contained pyknotic nuclei The elastic content of these was markedly diminished or absent In other areas, the septums were evidenced by dilated capillaries and large cells laden with black pigment These cells in places arranged themselves about vessels and formed nodules that occasionally were transformed into fibrous tissue

In intrapulmonary arteries up to 0 2 mm in diameter, the intima in most instances, was thickened and, in places, completely occluded the lumen This thickening was the result of a subendothelial increase of fibrous tissue or hyaline degeneration of this tissue and accumulations of large pseudoxanthomatous cells In some instances there was a nodular protrusion into the lumen which was covered by endothelium and was composed of young fibroblasts, connective tissue and hyaline material Fine elastic fibrils were numerous In the vessels in which the entire lumen was occluded there were small canals that were lined by endothelium and filled with blood This type of intimal thickening was of a structure similar to that of the intimal nodules described The internal elastic membrane was split, and there was an increase of the elastic tissue, most marked

on the intimal side The media in most instances was reduced in size, owing to a decrease in elastic and muscle fibers and a replacement by hyaline and fibrous tissue The adventitia was unchanged

In intrapulmonary vessels from 0 2 to 0 4 mm in diameter, the intima showed changes similar to those just described The media, however, was thickened by an increased amount of fibrous and elastic tissue In some instances, hyaline changes had taken place, but in the region of the nodules the media was much reduced in size The adventitia was unchanged

In intrapulmonary vessels over 0 4 mm in diameter the intima showed only a subendothelial thickening, but occasionally changes similar to those described were noted, with nodule formation, obliteration of the lumen and canalization In several instances, hyaline thrombi had attached themselves to the nodular protrusions The internal elastic membrane was thickened and occasionally split with an increase of elastic fibers The media was also thickened as a result of this increase in elastic fibers, and in addition there was a hypertrophy of the muscle fibers Large spaces each filled with a pyknotic nucleus, were noted near the internal elastic membrane The adventitia was unchanged

No organisms were found by the Gram-Weigert method in the walls of intrapulmonary arteries or in the thrombi

In extrapulmonary arteries, the intima was thickened in circumscribed areas, which were composed of dense connective tissue, poor in cells, with irregular interstitial spaces Hyaline changes were also present The internal elastic membrane was moderately thickened The media was widened by an increase of elastic fibers and hypertrophy of the muscular elements There was some evidence of fibrous tissue and hyaline changes The adventitia was unchanged

The walls of the veins appeared reduced in width, the elastic membranes in some instances approximating each other There were subintimal circumscribed thickenings due to fibrous tissue and hyaline changes In other instances there were organized thrombi with canalization

In the right ventricle of the heart, the muscle fibers were distinctly thicker than normal Their cross-striations were indistinct, sometimes to the point of absence Several irregular areas within the muscle bundles stained deep red by van Gieson's method The smaller arteries appeared unchanged In the left ventricle, the muscle fibers were slightly thicker than normal Their cross-striations were indistinct

The kidneys showed small subcapsular areas of atrophy of the renal parenchyma In the remaining part, the structure was well preserved In the basal part of the epithelium of the convoluted tubules, fine lipoid droplets were found The arterioles were not more prominent than would be expected at this age There was a slight thickening of the intima of the larger arteries

The liver and the spleen showed marked capillary dilatation throughout No changes were noted in the arteries

In the bone-marrow, the capillaries were much dilated and filled with blood Areas of granulopoiesis and erythropoiesis were numerous

Anatomic Diagnosis—The anatomic diagnosis was Arteriosclerosis of the pulmonary artery eccentric hypertrophy of the heart, especially of the right ventricle, chronic emphysema of the lungs, marked passive hyperemia of the spleen, kidneys, stomach, intestines, liver and bone-marrow, generalized anasarca, and petechial hemorrhages of the epicardium, renal pelvis stomach and large intestines

SUMMARY

Close scrutiny of the clinical and pathologic observations in the three cases reported reveals a definite progression of events, each of which will be discussed

Clinical Aspects Cough—In each case cough was the first symptom It was not severe, as the patients did not mention it of their own volition but rather after specific questioning This accounts for the uncertainty of time element The cough was productive of whitish mucus, and only in case 2 was it associated with a questionable hemoptysis

Cyanosis—Cyanosis was usually the first definite objective observation In the first case, it was noted first one year before entrance to the hospital, in the second case, it was thought to have been present before decompensation, i e, two years before entrance In the last case, the patient did not complain of cyanosis but he was unintelligent and did not speak English He had been in the hospital on four occasions in a year's time, his only symptoms being deep cyanosis of the face, neck and extremities and a semistupor As he stated that his past attacks were of a similar nature, it is taken for granted that cyanosis was present for the same period of time or four years

In every case, then, cyanosis preceded the symptoms of decompensation The time element is in direct proportion to the severity of the pathologic changes

Dyspnea—Dyspnea developed soon after cyanosis and though possibly mild at first soon became marked However it was not proportional to the depth of cyanosis

Edema—With failure of the right side of the heart edema developed similar to that of a left cardiac decompensation In the first case, it was mild, in the second case, moderate, and in the last case, severe The size of the hearts, the dilatation of the ventricles and the thickness of their walls were in direct relation to the severity of the clinical observations

Blood Picture—Unfortunately, the blood pictures in the first two cases were not recorded In the last case, the red blood cell count was 6,690,000, a true polycythemia or erythremia This will be explained later The white cell count was not significant

Age, Sex, Occupation—The age of incidence varied from 43 to 48 years All three patients were well nourished to obese white men The occupation is important in that in each case it was associated with aspiration of either particulate matter or gases This factor aids in the formulation of the pathogenesis which is discussed later

Pathologic Aspects Pulmonary Artery—Grossly, in all three cases, the main trunk of the pulmonary artery was moderately dilated and presented little or no evidence of atheromatous changes Beginning with the second order however, and extending to the smaller branches, the atheromatous changes became more marked These changes were present in all the cases, but most pronounced in the last one

Fig 1 (case 1)—The pulmonary artery is cut open to show the atherosclerotic plaques in the branches of the third and fourth order The intima of the main trunk and its primary division is smooth

Microscopically, the pathologic processes present in the three cases were similar, but in the first case only the small arteries were affected, in the second case the small and medium sized ones, and in the last case all the intrapulmonary vessels

The earliest changes were best noted in the small arteries in the first case These changes consisted of a thickening of the media as the result of an increase of elastic tissue and a hypertrophy of the muscle fibers The internal elastic membrane showed a longitudinal



Fig 2 (case 1) —An alveolus of the lung, showing capillary dilatation, capillary contraction and disappearance of the capillary endothelium with replacement of the alveolar wall by a homogeneous hyaline substance in which are found chromatin granules (Hematoxylin and eosin × 400)

splitting with an increase of elastic fibrils that extended into the media and intima In occasional vessels, the changes in the media were associated with a degenerative process that consisted of large clear spaces, each containing a pyknotic nucleus, hyaline changes and fatty changes Similar degenerative changes were noted in the intima of some vessels Thrombi were present, but uncommon

In the second case, this process had progressed further The intimal thickening was more generalized and showed further changes, with fibroblasts and fibrous tissue formation The thrombi were present in larger numbers and showed various stages of organization, to canalization The media in this case presented further regressive changes and was much reduced in thickness

In the third case, there were arteries in which the lumina were obliterated either by a proliferation of the intima or by organizing thrombi Both of these processes were responsible for the occlusion of the lumina of the arteries as in some instances this mass was rich in elastic fibrils, which would speak more for an intimal proliferation while in other instances only hyaline and fibrous tissue was present, which would speak for organized thrombi It was impossible at times to come to a definite conclusion The small nodular protrusions into the lumina of the arteries were a result of similar changes or of degenerative swellings of the media which caused the intima to protrude into the lumina Young thrombi were at times attached to these nodules The media in this case showed more marked degenerative changes and in some vessels was entirely replaced by fibrous tissue or was composed only of the internal and external elastic membranes, which approximated each other

This progression of events affected the pulmonary artery and its branches in the order and with the severity mentioned

Extrapulmonary Arteries—The extrapulmonary vessels were the last to bear the burden of taxation and thus showed the least changes There were slight thickening of the media and subintimal thickening due to pseudoxanthomatous cells and hyaline and fibrous changes

Aorta—Other than for a slight subintimal thickening with fatty changes the aorta was unchanged

Heart—The heart in every instance was hypertrophic The weights varied from 460 Gm to 530 Gm in direct relation to the severity of the pathologic changes (The three patients were of about the same weight and height) The apexes in the three instances, were made up by the right ventricles The walls of the right ventricle were thickened, the thickening being only slight in the first case (5 mm), moderate in the second case (7 mm) and marked in the third case (12 mm)

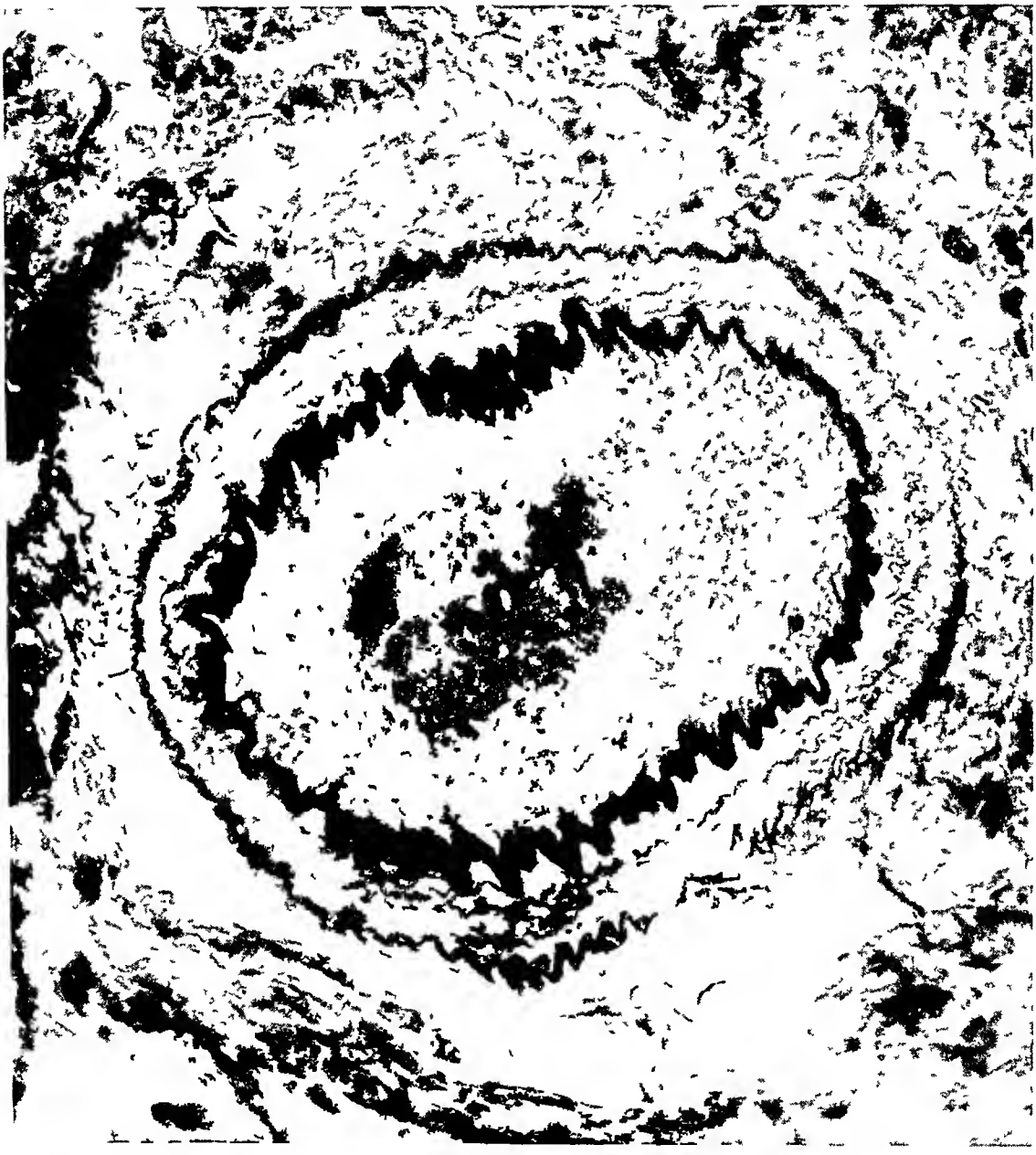

Fig 3 (case 1) —A pulmonary artery, 0 2 mm in diameter The earliest changes which are here noted consist of a thickening of the media due to an increase of elastic fibers and hypertrophy of the muscle fibers The internal elastic membrane is also thickened (Weigert's elastic stain, × 500)

The microscopic picture was that of hypertrophy of the muscle fibers and beginning degeneration, and in the last case large scars were prominent

Lungs—Macroscopically, the lungs were moderately collapsed and subcrepitant, and had a dark gray color Microscopically, the larger bronchi were generally the seat of both mild hyperplastic and degenerative changes The smaller bronchi usually showed a desquamation of the epithelium There was no round cell infiltration or peribronchial fibrosis In the alveoli the underlying pathologic change in all three cases was in the capillaries of the alveolar walls There were capillary dilatation, capillary contraction and endothelial necrosis This process, slight in the first case, was far advanced in the third case Occasionally, anthracotic nodes were situated about small arteries An interesting observation was that the smaller arteries showing the severest regressive changes were found in the parts of the lung in which the distention of the alveoli was greatest Further studies are being carried out on emphysematous lungs to determine the significance of this resolution

Kidneys, Liver and Spleen—The changes in the kidneys liver and spleen were similar in the three cases, being those of passive hyperemia The vessels were slightly sclerotic but not more than would be expected for the ages of the patients

Bone-Marrow—In the bone-marrow, the capillaries were distended by blood with active erythropoiesis and to a less extent granulopoiesis

PATHOGENESIS

Arteriosclerosis or atherosclerosis (Marchand [6]) has been agreed by most authors to be a physiologic deteriorative process resulting from excessive stress and irritation, chemical, toxic or mechanical (Jores [27] Marchand, [6] Aschoff [28]) Each portion of the vascular tree suffers in direct proportion to its taxation

The lung is no longer considered a passive organ in which a simple exchange of gases occurs Eppinger and Wagner [9] showed the rôle of the lung in the metabolism of lactic acid, Roger and Leon [29] emphasized the rôle of the lung in lipoid metabolism When one considers also the pulmonary artery with its immense pulmonary tree and its intimate relation to inspired air, gases and foreign bodies, the burden placed on the reticulo-endothelium is at once evident With increased taxation of

27 Jores L Wesen und Entwickelung der Arteriosklerose Munich, J F Bergmann, 1903

28 Aschoff Ueber Entwickelung Wachstum und Alters Vorgange aus der Gefassen, Jena, Gustav Fischer, 1909

29 Roger, H, and Leon Binet La fonction lipolytique du poumon, Bull Acad de med, Paris 4 129, 1921

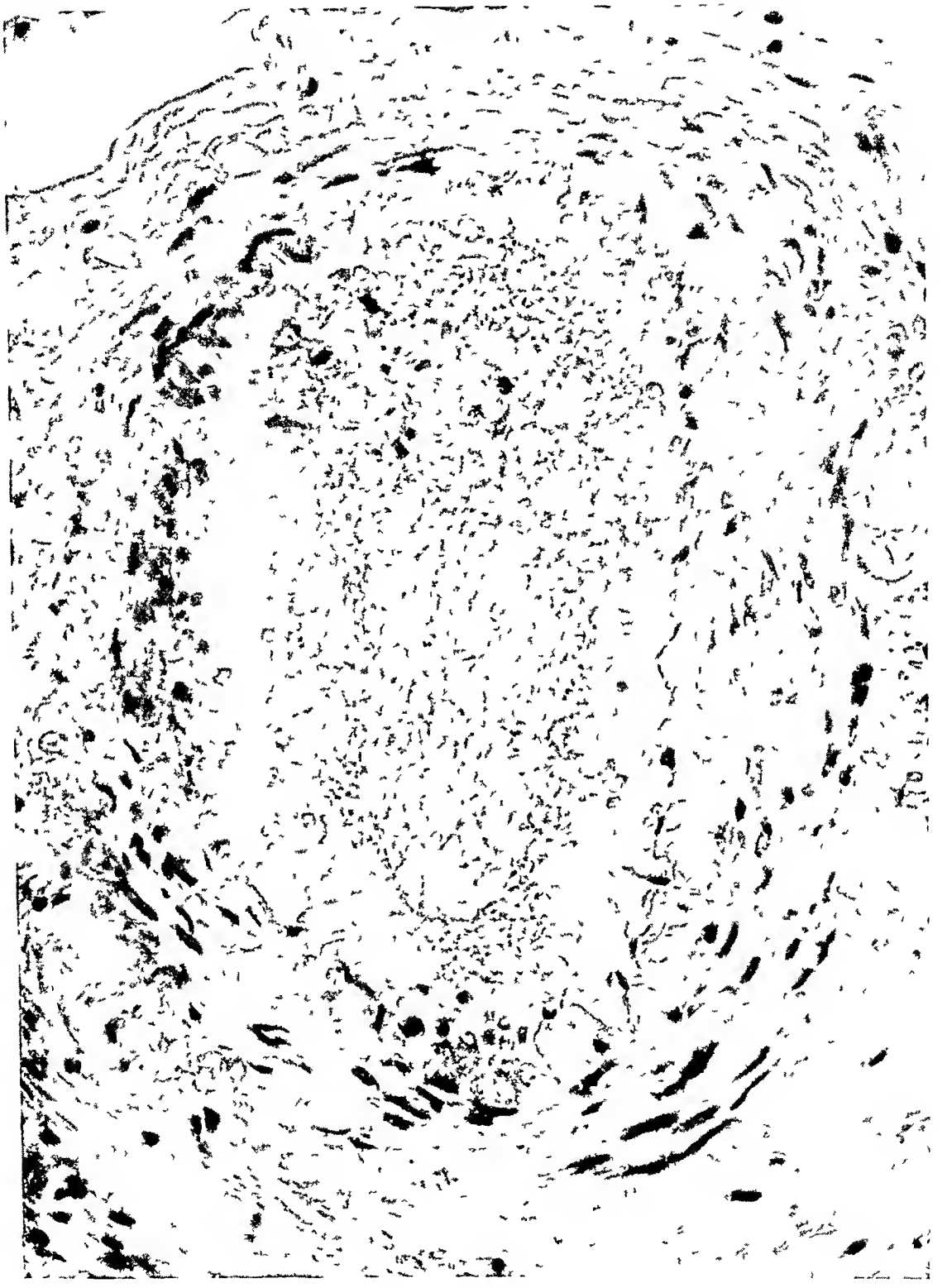

Fig 4 (case 1) —A pulmonary artery, 0 25 mm in diameter, showing the earliest degenerative changes in the media Large vacuoles appear each having a pyknotic nucleus in its center The most marked changes are found near the internal elastic membrane (Hematoxylin and eosin, × 600)

the lung, be it toxic, chemical or physical the normal physiologic changes of the pulmonary artery are exaggerated This process is further hastened by the capillary spasm that results from the irritant, and it terminates in a disappearance of the capillaries and their replacement by fibrous strands in which pyknotic nuclei are evident

In the cases reported the patients were all in the descending stage of life, in which additional factors of strain or irritation tended to hasten the physiologic pathologic process Because of their occupations their lungs were the seat of the severest stress and suffered accordingly The constant aspiration of particulate matter (sand, iron particles) or fumes (naptha, benzine, etc) caused a slight irritation of the bronchi, which probably accounted to a great extent for the cough These foreign materials (when mixed with mucus) reached the finest ramification of the bronchioles and the alveoli, their passage resulting in a mechanical or chemical irritation of the capillaries which led either to a spasm or to actual necrosis of the endothelium This process was continually in effect capillary dilatation coming after capillary spasm Thus it was noted that areas of capillary hyperemia and areas of capillary collapse with necrosis of the endothelium were sometimes present in the walls of the same alveolus

Because of this spasm and necrosis of the capillary endothelium, the arterioles and smaller arteries were called on for greater activity This resulted in hypertrophy of the media of these vessels due to an increase of elastic tissue and a hypertrophy of the muscle fibers The increase of elastic tissue was associated with a splitting of the internal elastic membrane which resulted in an increase in the size of the intima

With the constant increased demand on these arteries degeneration soon set in This began in the media adjacent to the internal elastic membrane The muscle fibers were the first to be involved and their degeneration was seen as large empty spaces, each having a pyknotic nucleus centrally located The intima then became involved, but because it lined a canal the process had more room to progress and thus the intimal proliferation was more marked, sometimes being uniform and obliterating the lumen and at other times nodular These nodules, in some instances may have been the result of the organization of thrombi but in view of their having been rich in fine elastic fibers the probability is that the majority of them were the result of intimal proliferation

The same process that took place in the smaller arteries then took place in the larger ones and for the same underlying reason namely, increased function because of peripheral resistance

With these changes in the arteries, cyanosis set in because of the lack of oxidation of the blood and because of the stasis of the blood in the peripheral veins due to back pressure Dyspnea then appeared, per-

haps from mild acidosis and also beginning failure of the heart, especially of its right side Hemoptysis, which is often described as occurring in this condition, may be explained by rupture of the wall of a vessel as the result of the marked degenerative process that has taken place in the media

Fig 5 (case 2) —A pulmonary artery, 0 2 mm in diameter The media is reduced in size, and at one point the internal and external elastic membranes approach each other The internal elastic membrane is split, with a resulting thickening of the intima (Weigert's elastic stain, × 500)

At this stage, thrombi are apt to form, for the blood has undergone a chemical change (acidosis) and colloidal change (regressive changes in the body) With the additional factors of stasis and endothelial injury most marked in the vessels of the lung thrombi occurred there affecting both the veins and the arteries

The narrowing of the lumina of the smaller vessels of the pulmonary artery accounted for the gray, anemic lung, and, because of the resistance offered, resulted in a dilatation of the right side of the heart, which after prolonged taxation became hypertrophied and finally decompensated Marked passive congestion and edema then made themselves evident clinically

The passive congestion was also present in the bone-marrow, which caused stimulation of the erythropoietic tissue, and polycythemia resulted

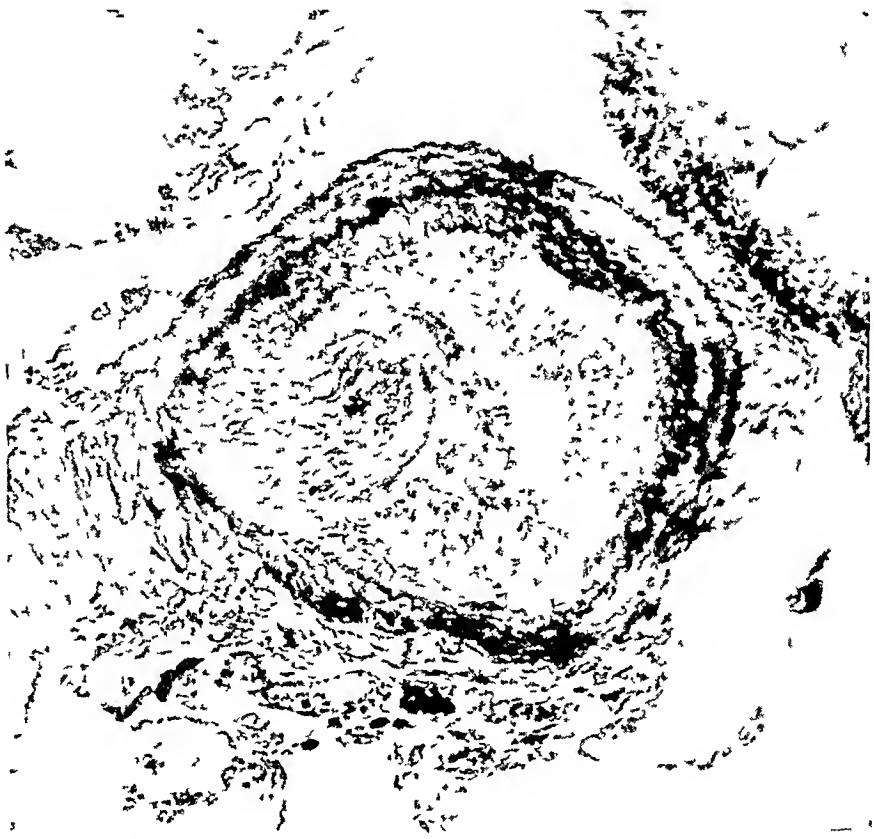

Fig 6 (case 3) —A pulmonary artery, 0 2 mm in diameter The nodular thickening of the intima is the result of an increase of elastic and collagenous fibers (Weigert's elastic stain)

After repeated attacks of decompensation the reserve musculature was exhausted, and the heart failed to compensate The fact that one patient died with only early evidences of decompensation while another had several such attacks and recovered can best be explained by a poor endowment of muscle reserve or an intercurrent infection that affected this reserve

Comparative studies carried out on lungs from patients of varying ages who had met with sudden violent deaths revealed a definite but

slight increase in the width of the media of the arterioles and the arteries of the pulmonary artery in persons between 40 and 60 years of age This was due to thickening of the internal elastic membrane or splitting thereof The intima was at times also thickened subintimally because

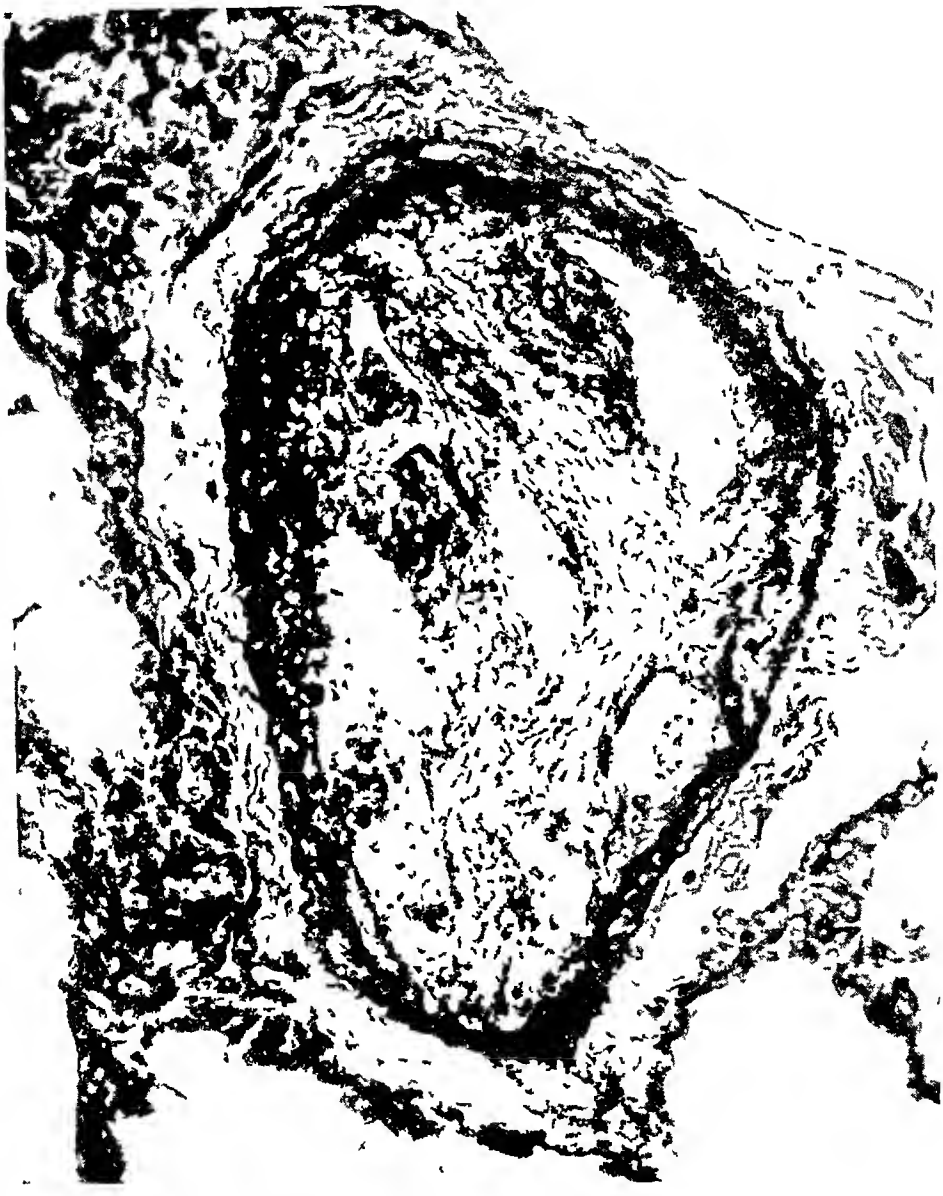

Fig 7 (case 3) —A pulmonary artery, 0 2 mm in diameter The lumen of the vessel has been obliterated and is now canalized Note the preponderance of elastic fibers in the obliterating mass and the narrow media (Weigert's elastic stain, × 400)

of these changes and also because of accumulations of pseudoxanthomatous cells No evidence of nodule formation, obliteration of lumina or thrombi formation was noted

The differentiation between the secondary and the primary changes of the pulmonary artery is sometimes difficult In the secondary form,

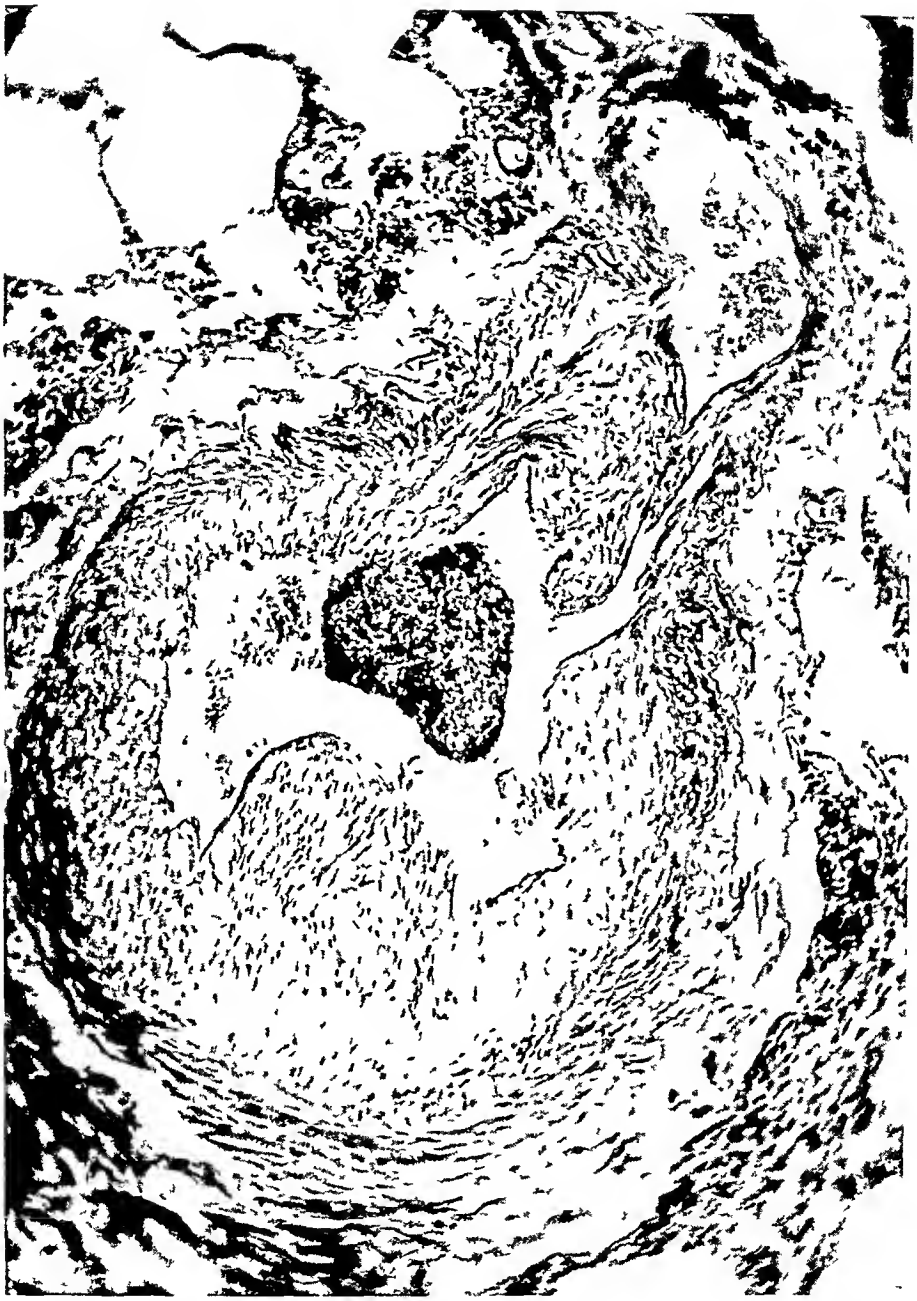

Fig 8 (case 3) —A pulmonary artery, 0 4 mm in diameter, showing a nodular thickening of the intima similar to that found in the smaller sized vessels Note the recent thrombus attached to the intima (Hematoxylin and eosin, × 250)

however, the primary lesion is usually found as chronic pneumonia, stenosis of the mitral valve, obliterative pleuritis, etc Microscopically, the greatest changes are found in the larger branches of the pulmonary artery, whereas the smaller arteries and arterioles may show only slight thickening of the media (Torhorst[30])

CONCLUSIONS

Pulmonary arteriosclerosis has been defined as a definite clinical and pathologic entity The basis of this conclusion is found in studies made in three cases in which the various stages of the disease existed The earliest pathologic changes are in the media of the vessels measuring up to 0 2 mm in diameter The process soon extends into the intima and is both proliferative and degenerative The clinical symptoms are in direct relation to the anatomic changes

30 Torhorst, H Die histologischen Veranderungen bei der Sklerose der Pulmonalarterie, Beitr z path Anat u z allg Path **36** 210, 1904

Laboratory Methods and Technical Notes

A MODIFICATION OF MAC CALLUM'S HEMATOXYLIN METHOD FOR IRON

ROBERT R DIETERLE, M D, WASHINGTON, D C

When reliability and simplicity are combined in a technical procedure, the method becomes available for routine purposes and more efficient as a standard in research work Saving of time and other economic factors are of paramount importance in this sense

In the original method of MacCallum for the staining of unmasked iron, a freshly prepared 0 5 per cent aqueous solution of hematoxylin was used When the investigation of such iron compounds was instituted in this laboratory as a part of routine there was naturally required a fresh solution daily, since the oxidation by the ripening of such a solution occurs within twenty-four hours, and renders it useless for the staining reaction Experimentation was therefore undertaken to produce a solution that could be used over a length of time in order to spare hematoxylin, to strike out the boresome task of making a new solution daily and to point toward standardization of the method itself It logically followed that a reducing agent would prevent the natural oxidation of the required solution of hematoxylin Accordingly, formaldehyde was introduced, and the following method with this slight modification is now presented

1 Fix tissues in 95 per cent alcohol for five days

2 Cut on the microtome after embedding in celloidin or paraffin (brain tissue may be cut unembedded as for Nissl's original method)

3 Treat the sections for one hour at 55 C in nitric acid-alcohol 4 cc of nitric acid plus 96 cc of 95 per cent alcohol

4 Wash twice in distilled water

5 Transfer the sections to the hematoxylin solution 0 5 Gm of hematoxylin, dissolving by heating in 100 cc of distilled water, afterward cooling to room temperature, and then adding 1 cc of Merck's blue label neutral formaldehyde solution The resulting solution is kept in a tightly stoppered bottle at 55 C and immediately before use poured into a Stender dish with a ground-glass cover, to prevent the escape of the formaldehyde At the resulting temperature, the staining reaction occurs almost immediately The sections, however, should remain in the hematoxylin for five minutes As a control, a section untreated with the nitric acid-alcohol is placed in the solution with the "unmasked" sections It will be found that this section does not stain Under conditions in this laboratory the formaldehyde-hematoxylin solution has been used for three months without losing its ability to combine with the iron A flocculent precipitate forms within it in a few days, this is removed by filtration In the course of time another cubic

* Submitted for publication, Aug 23, 1930

From St Elizabeth's Hospital, Blackburn Laboratory

centimeter of formaldehyde can be added to replace the theoretical loss of the same substance The iron of the nuclei stains an intense bluish black owing to the combining of the hematoxylin with the iron salts formed by the previous acid treatment

6 After washing in distilled water, the sections are transferred to equal parts of ether and absolute alcohol for a differentiation, which removes the excess yellow within the tissue

7 Follow with neutral xylene and mount in neutral balsam The preparations are permanent

The method is useful for the study of the iron content of nuclei Its application to tumors and to mitoses is especially important Lately I have combined, or rather superimposed on it, another nuclear stain in the form of a 1 per cent aqueous solution of safranin O (Grubler), for the purposes of studying "acid-nuclei" according to Unna, and have found striking "metachromatic" variations of color in cells of different histologic entity and function Thus, after differentiation in alcohol and ether, the sections are washed in distilled water, stained with the safranin for twenty minutes, rinsed and differentiated in alcohol made acid by the addition of 10 drops of saturated solution of trinitrophenal or of 3 drops of pure hydrochloric acid in 100 cc of 95 per cent alcohol The sections are then washed in tap-water, dehydrated quickly with alcohol, cleared in xylene and mounted in neutral balsam

Hematoxylin thus demonstrates small traces of inorganic iron, and is more sensitive than the prussion blue or ammonium sulphide methods For purposes of comparison, the iron of nuclei after unmasking with acid may be treated with the usual potassium ferrocyanide or the ammonium sulphide-potassium ferrocyanide procedures The blue-colored microchemical reactions thus obtained are too faint for accurate comparative study, and possess physical characteristics less suited to ordinary vision and to photomicrography

General Review

ADDISON'S DISEASE

A STATISTICAL ANALYSIS OF FIVE HUNDRED AND SIXTY-SIX CASES AND A STUDY OF THE PATHOLOGY *

PAUL H GUTTMAN, M D
MINNEAPOLIS

This paper deals chiefly with a study of 566 cases of Addison's disease reported in the literature from 1900 to 1929, inclusive, with particular emphasis on the pathologic anatomy, the pathogenesis and the correlation of clinical and pathologic data The material contributed between 1900 and 1929 is chosen as being more reliable for study than cases from the older literature In addition it affords a comparison with the statistics of Lewin, which were completed in 1892 A study is also made of 29 cases of Addison's disease reports of which were obtained from the protocols of the department of pathology of the University of Minnesota and of Glen Lake Sanatorium

INCIDENCE

Addison's disease is relatively rare In 1924 363 cases were reported in 1,173,990 deaths from all causes in the registration area of the United States In Minnesota, of the 23 034 deaths in 1924, 9 were due to Addison's disease The incidence for 1923 corresponds closely to that of 1924 The frequency of the disease for these two years approaches 0 4 per hundred thousand population in the registration area

It is a common observation that Addison's disease is seldom seen in sanatoriums for tuberculosis This is probably due to the fact tnat the extrasuprarenal tuberculous lesions in Addison's disease are usually small and healed or clinically latent A history of an old tuberculous process occurring many years before the onset of symptoms of Addison's disease is often obtained It is likely that in many patients treated in sanatoriums the symptoms of Addison's disease develop many years after discharge There is no doubt that cases of bilateral suprarenal tuberculosis occur in sanatoriums but it is likely that in many cases the symptoms therefrom are obscured by symptoms of advanced pulmonary tuberculosis, such as weakness, low blood pressure and gastro-intestinal disorders

* Submitted for publication Aug 23 1930
* From the Department of Pathology University of Minnesota

AGE

Tuberculosis of the suprarenal glands follows closely the mortality from tuberculosis in general This is illustrated in figure 1, in which the percentage of the total number of deaths is plotted against five-year age periods The dotted line represents the age incidence of deaths from tuberculosis of all causes as obtained from the mortality statistics

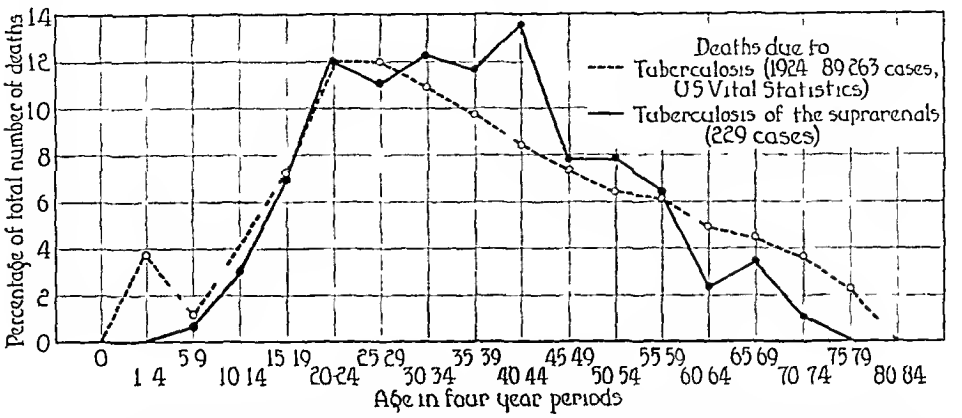

Fig 1—Age incidence of deaths from tuberculosis of the suprarenal glands (solid line) and of deaths from tuberculosis of other organs (dotted line)

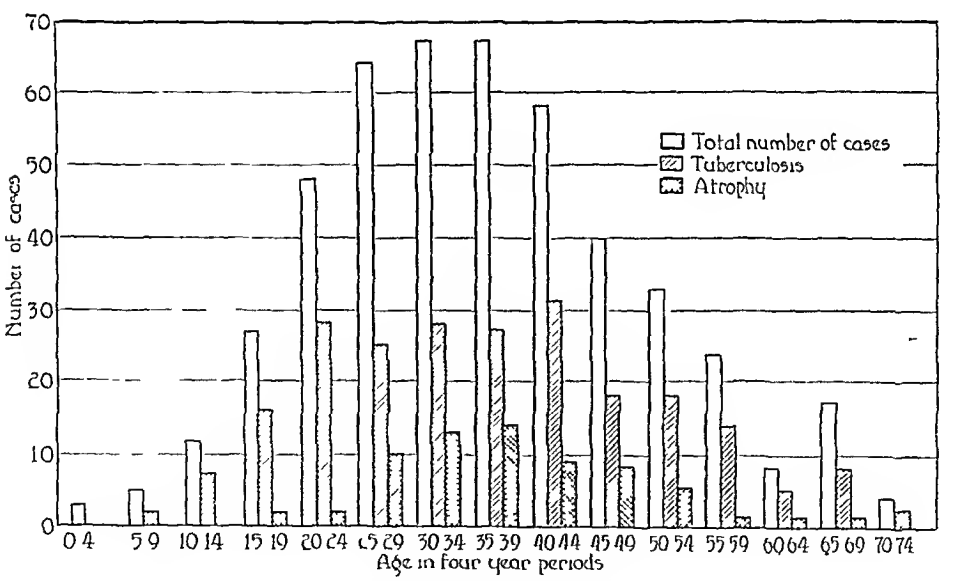

Fig 2—Age incidence of deaths from Addison's disease Comparison of the age incidence of death from atrophy of the suprarenal glands with that of death from tuberculosis of the suprarenal glands

of the United States The other line represents the age incidence of deaths from Addison's disease with tuberculosis of the suprarenal glands The initial rise in childhood is absent in Addison's disease Both reach a plateau at the thirtieth year The plateau is much broader in the cases of Addison's disease The descent in the curve begins at

50 years in the cases of Addison's disease, whereas it begins at the thirtieth year in the cases of death from tuberculosis in general

In figure 2, the age incidence of 478 cases is given in five-year periods In 333 of these, the diagnosis was made at autopsy There are 229 cases of tuberculosis, 66 of atrophy, and 39 of suprarenal lesions of other types The age distribution of the cases of tuberculosis and of atrophy is also shown in figure 2 The disease is rare in the first years of life, only 3 45 per cent occur in the first decade The incidence increases rapidly and reaches a maximum in the fourth decade Following this period, there is a rapid decline in the incidence of the disease Primary contracted suprarenal glands (atrophy) are rare before the third decade The maximum number of cases also occurs in the fourth decade of life The decrease in the incidence is gradual and follows closely the curve of tuberculosis of the suprarenal glands The mean of the entire number of cases is 36 42 ± 0 41 years (the probable error of the mean used throughout) For primary con-

TABLE 1 —*Sex Incidence of Addison's Disease*

	Male		Female	
	Number	Per Cent	Number	Per Cent
Tuberculosis	144	46 00	50	29 07
Primary contracted suprarenal gland	22	7 03	35	20 35
Other cases with autopsy reports	53	16 94	28	16 28
Cases with clinical reports only	94	30 03	59	34 30
Total	313	100 00	172	100 00

tracted suprarenal glands, the mean is 37 92 ± 0 83 years, for tuberculosis, 36 87 ± 0 61 years The difference between the two is 1 05 ± 1 03, which is not significant

SEX

Of the total number of reported cases 313 or 64 57 per cent, occurred in males and 172, or 35 43 per cent, in females The predominance of male over female is evident not only in the reports of cases in which the diagnosis was established at autopsy, but also in the clinical reports (table 1) However, in the case of primary contracted suprarenal glands, the females predominated over the males in the ratio of 1 6 to 1 In the case of tuberculosis of the suprarenal glands the predominance of males over females, as shown by the postmortem records, can be accounted for partly by the fact that, in most laboratories, there are more postmortem examinations performed on adult males than on adult females At the University of Minnesota there are 1 5 times as many on adult males as on adult females, however in the postmortem reports of tuberculosis of the suprarenal glands the predominance of males over females is 2 88 to 1 The clinical

reports, which are free from this error show 1 59 males to 1 female Lewin's statistics[465] give the ratio of male to female as 3 2 to 1

RACE

Seven cases of Addison's disease in the Negro were reported from 1900 to 1929 (Wahl Lemann Goodwin, Evans and Seheult) Increase in depth of pigmentation of the skin and pigment flecks in the mucous membrane of the mouth were noted The color change is often notable, the patient turning from brown to jet black Pigmentation of the mucous membrane, an important diagnostic sign in the white race, is of little importance in the colored race, since pigment flecks often occur normally Because of the difficulty of detecting pigmentary changes in the Negro, it is probable that the disease is more prevalent than one is led to believe by the case reports Busch reported a case in a mulatto Reports of Addison's disease in Jews are rare Statistics are not available for the yellow races Numerous case reports indicate that it occurs in the Japanese (Sakaguchi, Hayashi and Katayama, Gyotoku and Momose)

HEREDITY

Proved cases of Addison's disease in more than one member of a family are exceedingly rare Fahr and Reiche reported symptoms of Addison's disease in three brothers of a family of twenty-three, eleven of whom died in youth One, 23 years of age, was examined post mortem Atrophy of the suprarenal glands was found The other two showed marked pigmentation of the skin and weakness Flemming and Miller described a case of undoubted Addison's disease in a woman who had four children with symptoms of weakness brownish pigmentation of the skin and occasional attacks of diarrhea Unfortunately, further information as to the duration of these cases cannot be found in the literature, and it is impossible to state with certainty that these were true cases of Addison's disease Croom described a case in a girl, aged 9, who had two sisters, aged 6 and 3½, who had pigmentation of the skin and listlessness Pigmentation of the mucous membrane of the mouth was present only in the girl aged 9 In Green's case, the history was obtained that one sister died of a similar malady Pigmentation of the skin of some other member of the family was noted in the cases reported by Bittorf, Boenheim, Catterimole, Aslan, Wakefield and Smith, and Richon These cases are questionable, as insufficient data are at hand to establish the diagnosis with certainty Bittorf cited Saundby's case as the only proved case of Addison's disease in more than one member of a family Lewin in his entire study found three cases in which the disease had been considered hereditary (the cases of Bell, Espagnes and Feuerstein)

It is doubtful therefore, whether heredity plays an important rôle in the genesis of the disease, although it cannot be denied that in rare instances there is an hereditary tendency Bauer believed that a constitutional predisposition may be a hereditary factor in this disease, but that other intercurrent factors are necessary before the disease results

PATHOLOGIC ANATOMY AND PATHOGENESIS

CLASSIFICATION AND FREQUENCY OF LESIONS IN THE SUPRARENAL GLANDS IN ADDISON'S DISEASE

There are 566 cases available for study The authors of these reports are given in the bibliography which is arranged so as to correspond to the foregoing classification In addition, a list of references is given of reports that I could not obtain

TABLE 2—*Classification and Frequency of Lesions in the Suprarenal Glands in Addison's Disease*

Lesions	Cases	Per Cent
Inflammatory changes		
Tuberculosis		
Bilateral	244	60 54
Probable bilateral	33	8 18
Unilateral	4	1 00
Total	281	69 72
Pyogenic infection	2	0 50
Syphilis	1	0 25
Degenerative changes		
Primary contracted suprarenal gland (atrophy)	65	16 1[illegible]
Probable atrophy	13	3 25
Amyloidosis	7	1 75
Fatty degeneration	2	0 50
Neoplasms		
Primary	2	0 50
Metastatic	3	0 74
Vascular lesions		
Venous thrombosis	3	0 74
Arterial emboli	1	0 25
Hemorrhage	1	0 25
Miscellaneous lesions		
Trauma	2	0 50
Metaplasia of bone marrow	1	0 25
Bilateral aplasia	2	0 50
Pressure atrophy	2	0 50
Hypoplasia	1	0 25
Undeterminable nature	10	2 48
Addison's disease without lesions in the suprarenal glands	4 (?)	0 99 (?)
Total	403	100 00
Cases of Addison's disease on which clinical reports only are available	163	
Total number of cases	566	

In 402 cases the autopsy reports are given These are classified according to the pathologic changes in the suprarenal glands

The number and percentage of the various diseases recorded in the literature of the last thirty years are given

Tuberculosis of the suprarenal glands is the most frequent cause of Addison's disease The percentage of cases in the recent literature

is 60 55 Lewin reported 95 of 272 typical cases, or 35 per cent, in which the lesion was considered to be tuberculous Primary contracted suprarenal gland (atrophy) occupies second place, with 65 cases (16 13 per cent), whereas in Lewin's early statistics[466] there are 25, or 8 4 per cent The relative frequency of occurrence of the disease in recent years as judged by the literature is probably too high, owing to increasing interest in this condition in recent years A case of atrophy is more apt to be reported than one of tuberculosis The frequency of primary contracted suprarenal gland in recent individual statistics is as follows Barker, 3 cases of 28 at the Mayo Clinic, University of Minnesota 4 cases of 29 coming to autopsy, Conybeare and Mills, 8 cases of 29 at Guy's Hospital Other forms of degenerative change include amyloid disease, 7 cases, fatty degeneration, 2 cases Neoplasm as a cause of Addison's disease is exceedingly uncommon, only 5 cases are reported in the recent literature Lewin found only 9 typical cases, or 3 3 per cent Vascular lesions consist of venous thrombosis, 3 cases, arterial emboli 1 case, hemorrhage, 1 case In the fifth group there are 2 cases of trauma, 1 case of metaplasia of the bone marrow, 1 case of hypoplasia 2 cases of pressure atrophy and 8 cases of undeterminable nature

In the sixth group there are 4 questionable cases of Addison's disease without lesions in the suprarenals (see page 773) This is in marked contrast with the frequently quoted number placed in this category by Lewin In his first group of statistics there are 28 cases of a total of 311 in which the suprarenal glands are intact In his second group of statistics, the suprarenal glands are stated to be normal in 8 per cent of 561 cases Of the total, Lewin gives 12 per cent normal and 88 per cent diseased

It is clearly evident that, in the older cases, Addison's disease was confused with many other conditions producing pigmentation of the skin, principally vagabond's disease acanthosis nigricans, pellagra bronze diabetes, sprue, pernicious anemia and ochronosis, which are now better understood It is also probable, as pointed out by Furuta, that the suprarenal glands, diagnosed grossly as normal, may have been the site of marked destructive changes

From a review of the literature of the last thirty years, it is evident that Addison's disease is almost invariably accompanied by destructive lesions in both suprarenal glands These lesions are of many types but most frequently are tuberculous This is in accord with Lewin, but opposed to the unitarian point of view of Wilks, Greenhow, and Bramwell,[428] who held that the disease is due to a peculiar fibrocaseous degeneration of the suprarenal glands There is also no support of the neo-unitarian point of view of recent writers Kovacs and Omelskyj,

who stated that they do not regard primary contracted suprarenal gland (their cytotoxic contracted suprarenal gland) as a true form of Addison's disease (this will be discussed in the last part of this article, which will be published in the December issue of the ARCHIVES, and will appear under the heading *Relation of Blood Pressure to the Relative Degrees of Destruction of Cortex and Medulla in Suprarenal Tuberculosis and Primary Contracted Suprarenal Gland*)

TABLE 3.—*Distribution of Tuberculosis in Tissues Other Than the Suprarenal Glands*

	Cases
Lungs	
Healed scars	36
Recently acquired active lesions	7
Limited active tuberculosis	40
Extensive chronic tuberculosis	19
Extent of lesions undeterminable	22
Total	124
Pleura	
Bilateral adhesive pleuritis	14
Unilateral adhesive pleuritis	7
Degree undeterminable	24
Disseminated miliary tuberculosis	16
Genito urinary tract	
Kidneys	
Left kidney	3
Right kidney	7
Bilateral involvement	12
Prostate	5
Epididymis	7
Uterus	1
Uterine tube	3
Lymph nodes	
Bronchial and mediastinal	29
Mesenteric	4
Retroperitoneal	14
Other nodes	7
Other organs	
Pericardium	2
Peritoneum	8
Joints	5
Bones	9
Intestines	7
Thyroid	2
Liver	11
Spleen	7
Total	51

TUBERCULOSIS

Frequency of Primary Tuberculosis of the Suprarenal Glands.—The impression is obtained from the older literature that tuberculosis of the suprarenal gland is often a primary infection. In an extensive review of cases collected from the literature, Lewin found primary involvement in 132, or 26.4 per cent. Elsasser in 1906 collected 549 cases of tuberculosis of the suprarenal glands and found 5 cases that were certainly primary, 62 that were very probably primary and 29 that were doubtful.

The distribution of tuberculous lesions elsewhere in the body in 243 cases of tuberculosis of the suprarenal glands is given in table 3.

In only nineteen cases are the lungs reported normal, and in only seven cases are there no lesions elsewhere than in the suprarenal glands These observations agree well with those of Schwarz [497] who, in a study of sixty-five cases of tuberculosis of the suprarenal glands, found tuberculous lesions of the lung of the same age or older in every case This unusually high incidence is probably accounted for by the painstaking search for tuberculous foci made in Ghon's laboratory In the cases reviewed in the literature, a history of exposure to infection is not infrequent A history of tuberculosis in one or both parents was obtained in thirteen cases, in a brother or sister, in sixteen cases, in

TABLE 4—*The Clinical Relation of Tuberculosis to Addison's Disease*

	Cases
A history of tuberculosis from which complete recovery was made	
Tuberculosis of lung	8
Tuberculosis of lymph nodes	7
Tuberculous pleurisy	10
Bone tuberculosis	3
Joint tuberculosis	3
A history of tuberculosis before the onset of Addison's disease (tuberculosis still active at time of onset)	
Tuberculosis of lung	13
Tuberculosis of lymph nodes	3
Bone tuberculosis	4
Joint tuberculosis	3
Tuberculosis of kidney	1
Pleurisy	2
No history of previous infection	27
Clinical evidence of tuberculosis during the course of the disease	
Lung	
Slight or moderate activity	50
Marked activity	10
Activity indeterminate	9
No evidence of activity	31
Other organs	
Epididymis	2
Bone tuberculosis	34
Tuberculosis of lymph nodes	5
Tuberculosis of prostate	1
Tuberculosis of kidney	1
Fistulas	2
Intestinal tuberculosis	1

near relatives to whom the patients were exposed, in eleven cases The clinical relation of tuberculosis to Addison's disease is shown in table 4

These observations are important in that they emphasize that tuberculosis of the suprarenal glands is seldom, if ever, a primary infection In the majority of cases, however, the extrasuprarenal lesions are not extensive and are clinically latent

Routes of Infection—Three possible routes of infection of the suprarenal glands have been considered by various authors, viz intrauterine, hematogenous and lymphogenous Elsasser concluded that, in cases of isolated suprarenal tuberculosis the infection must find its explanation in a congenital infection followed by a long period of latency There is much evidence opposed to this theory Although it is well known that bacilli may be present in the blood stream and tissues without producing tissue reaction it is highly improbable that the bac-

teria remain latent for many years The low immunity of the tissues of infants furnishes a fertile field for the development of bacilli, and infections in the fetus would not be long in becoming disseminated That tuberculosis is rarely transmitted through the placenta is indicated by the rarity of reports of such cases Hubschmann[451] was of the opinion that transmission via placenta is usually accompanied by tuberculosis of that tissue He considered only those cases congenitally transmitted in which the symptoms of the disease occur shortly after birth, rarely later than the third week of life Schmorl's case of bilateral extensive fibrocaseous tuberculosis in an infant of 12 days is an example of congenital infection, and also illustrates the rapidity of the lesion in the new-born infant

There is little evidence in the observations at necropsy that infection takes place via lymphatic channels Involvement of adjacent lymph nodes is not infrequent, and may be considered as an extension from the lesion in the suprarenal gland The position of the primary lesion in the majority of cases is such that extension through lymphatic vessels is improbable

The anatomic relationship of lesions in the lung and lesions in the suprarenal gland strongly suggests the hematogenous route Schwarz,[197] in a study of sixty-five cases of tuberculosis of the suprarenal glands, both unilateral and bilateral, found lesions of the same age or older in the lungs in every case In almost half of his cases the lungs were the only other organs involved The remainder showed hematogenous involvement of other viscera Schwarz concluded that the suprarenal infection is secondary to lesions in the lung and that the infection is carried by the blood stream It has been pointed out that, in Addison's disease, the lesion is seldom primary, and that it is associated in most cases with active lesions elsewhere in the body There are cases, however, in which the primary lesion is healed, and a small number in which no lesions can be found outside the suprarenal glands These cases have led many to regard the infection as congenital or hereditary However, in the light of recent knowledge of tuberculosis, this assumption is unnecessary Lubarsch Rabinowitsch and others have shown that apparently healed foci may harbor the bacilli Hubschmann[454] also held that these areas are capable of giving off bacteria into the blood stream without local acute exacerbation of the lesion Also Lowenstein showed that bacillemia may occur in patients harboring lesions that anatomically are difficult to find Such hidden foci in parts of the body other than the lung, in many of these cases, must be considered It is also possible that extensive bilateral lesions in the suprarenal glands may produce a state of immunity in the rest of the body, so that lesions elsewhere tend to remain localized and to heal The frequent association of hematogenous infection of other viscera such as the spleen

kidney, liver epididymis, etc, also is strong evidence favoring a hematogenous origin of the lesion in the suprarenal glands

Predisposition and Susceptibility of Suprarenal Glands to Tuberculosis—Tuberculosis of the suprarenal glands is much less frequent than tuberculosis of many other organs Hubschmann [154] gave the frequency of tuberculosis of other organs in association with pulmonary tuberculosis as follows urogenital system 62 per cent, bones and joints, 30 per cent, intestines, 7 per cent, suprarenal glands, 2 per cent, and skin, 2 per cent The frequency of tuberculosis of the suprarenal glands found by other authors is higher Schwarz [497] found 85 cases, or 3 1 per cent, in a series of 2,700 cases of tuberculosis Ophuls found the suprarenal glands involved in 5 per cent of his cases At the University of Minnesota, of 1,050 cases of tuberculosis, 51, or 4 85 per cent, showed tuberculosis of the suprarenal glands

A number of hypotheses have been advanced to explain the occurrence of extensive, apparently isolated, bilateral tuberculosis of the suprarenal glands found in Addison's disease Wiesel,[517] Neusser and Wiesel, Hedinger, Loffler and others held that the suprarenal glands are predisposed to infection by a hypoplastic condition of the chromaffin system which is associated with status lymphaticus Bauer cited an analogous situation in which hypoplastic organs are the site of tuberculosis, but such reports are few compared with the frequency of hypoplasia Schur was opposed to the belief that a developmental hypoplasia predisposes an organ to disease

The inconstancy of lymphatic and thymic hyperplasia in cases of tuberculosis of the suprarenal glands (see page 774) also throws doubt on the etiologic significance of status lymphaticus Lowenthal recently pointed out the meagerness of evidence on which Wiesel based his conclusion that chromaffin tissue is hypoplastic in his so-called cases of status lymphaticus In the majority of cases of primary contracted suprarenal gland, the medullary tissue shows little or no deviation from the normal, the cortex being the main site of the lesion

Hansemann regarded the local predisposition of the suprarenal gland to tuberculosis as the result of a low fat content of the tissues Schur considered that the suprarenal glands are made more susceptible to infection by injury as a result of a previous acute infectious disease

While it is a common observation that a patient dates his first symptom to an attack of influenza, of grip or, less frequently, of typhoid fever, of diphtheria etc, it is improbable that these diseases predispose the suprarenal gland to tuberculosis The influenza epidemic of 1918, 1919 and 1920 had no appreciable effect on the mortality rate of Addison's disease as given in the mortality statistics of the United States (fig 3)

The slight yearly increase in the mortality rate of Addison's disease is apparent before the 1918 epidemic and parallels the increase of reported deaths from all causes

Infectious diseases, particularly acute infections of the upper part of the respiratory tract however, may bring about an acute exacerbation of a preexisting tuberculous lesion, as a result of which a latent process may become clinically manifest, or if symptoms are present, they become more pronounced Also, these effects may be produced in another manner Dietrich and Siegmund, Wulfung Goldzieher, Thomas and others showed that acute infectious diseases are frequently the cause of marked degenerative changes in the cortex of the suprarenal gland It is probable that the surviving cortical tissue of a tuberculous

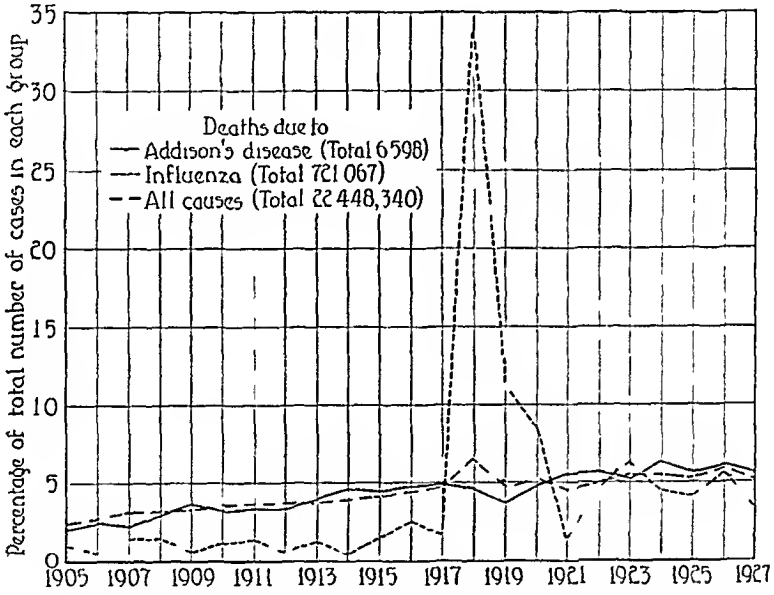

Fig 3—Comparison of incidence of death from Addison s disease with that of death from influenza

gland may be injured by an acute infectious process elsewhere in the body

Lowenstein held that infection of one organ of a pair leads to susceptibility to infection of the other In a study of clinical records at a hospital in Vienna he found that the organic system in which the first metastasis is established is also a frequent site of subsequent metastases Thus, tuberculosis of the eye is first unilateral and later becomes bilateral Renal tuberculosis is usually unilateral in the early stages and bilateral in the later stages He believed that the same applied to the suprarenal glands To explain this phenomenon, he added that tissue destroyed during the tuberculous process serves as an antigen for the production of specific antibodies ("resorbins") which exert an injurious effect on analogous structures and render them more susceptible to subsequent infection Sumiyoshi found in guinea-pigs that infection of

one organ often leads to involvement of the opposite organ Further experimental confirmation of these views is not at hand

From an analysis of forty-nine cases of tuberculosis of the suprarenal glands, there is evidence that the infection is first unilateral and later bilateral It is found that unilateral lesions are seldom extensive and but rarely destroy the entire gland When bilateral, one gland often shows more recent and less extensive involvement than the opposite organ It seems, therefore, that the same conditions apply here as in the kidney and the eye The exact mechanism of the predisposition, however, is not yet clear

TABLE 5—*Degree of Destruction of Suprarenal Glands in Cases of Tuberculosis of the Glands from the Department of Pathology of the University of Minnesota and Glen Lake Sanatorium*

	Partial Destruction		Complete Destruction	
	Right	Left	Right	Left
Unilateral lesions	4	8	2	0
Bilateral lesions without symptoms	2	3	4	3
Bilateral lesions with symptoms	7	4	17	18

TABLE 6—*Degree of Destruction of Suprarenal Gland in Cases of Tuberculosis of the Glands as Recorded in the Literature*

	Cases
Gross appearance of the suprarenal glands	
Total destruction of both	72
Complete destruction of right, left incompletely destroyed	6
Complete destruction of left, right incompletely destroyed	8
Normal tissue recognizable in both	9
Microscopic appearance	
Rests of normal cortex	39
Small cortical adenomas	27
Normal medulla	1
No normal tissue	16

The extensive alterative and exudative change in the glands is strongly suggestive that the inflammation is allergic It is probable that this allergic state is the result of the sensitization of one organ to the tubercle bacillus or its products as the result of a previous primary infection of the opposite organ

Structural Changes in the Suprarenal Glands in Tuberculosis—In addition to a review of case reports, a study was made of fifty-one cases of tuberculosis of the suprarenal glands as recorded in the Department of Pathology at the University of Minnesota and in Glen Lake Sanatorium Of these cases, fifteen showed unilateral tuberculosis, and in these symptoms of Addison's disease were absent Of the thirty-six cases that showed bilateral tuberculosis, twenty-five gave clinical signs of Addison's disease, six were clinically latent and in five the diagnosis could not be made because of insufficient clinical data Table 5 shows the degree of destruction of the organ in these cases In the cases

obtained from the literature, the degree of involvement of the suprarenal gland is determined to be as shown in table 6

In unilateral tuberculosis the destruction of the organ is seldom complete As a rule, the lesion consists of one or more caseous nodules single or confluent There is no predilection for cortex or medulla The lesion may occupy a pole of the gland and cause a nodular swelling Nodules in the cortex tend to be isolated and well delimited, those in the medulla tend toward confluence Destruction of the gland in cases of bilateral tuberculosis without symptoms is not as complete as in those with symptoms, although there are a few cases in the former group in which no suprarenal structures are recognizable grossly Macroscopically recognizable tissue in cases with clinical symptoms of Addison's disease was found seven times in the right and four times in the left suprarenal gland In the remaining cases, no macroscopic suprarenal tissue was seen The exact amount of remaining tissue cannot be estimated from this study because of the marked distortion of the normal markings and the irregular distribution of the surviving tissue

The approximate size of the organs in tuberculosis of the suprarenal glands is as follows both enlarged in eighty-three cases, both normal size in ten cases, one normal and one large in four cases, one large and one small in seventeen cases and both smaller than normal in eight cases

In thirty-one cases, the weight of the left gland is given and in thirty-two cases the weight of the right gland The mean weight of the right gland is 11 72 ± 5 07 Gm , the mean weight of the left is 13 98 ± 5 62 Gm The maximum weight is 45 Gm , the minimum weight is 4 1 Gm The normal weight of the suprarenal gland in a man is 11 2 Gm , and in a woman 10 6 Gm (Scheel)

The organs are firm nodular, and of a mottled grayish-red color The triangular wedge-shaped appearance may be maintained in the presence of extensive lesions The capsule is thickened and adherent to the surrounding tissues Fusion with the stomach liver and kidney is described

In the majority of cases, the substance is replaced completely by semiconfluent caseous nodules, varying in size from a few millimeters to 2 or 3 cm in diameter, separated by septums of grayish-white connective tissue Between the caseous nodules a tissue of reddish-brown color with fine grayish nodules is often present Microscopic sections through these areas often show active miliary tubercles Conversion of the entire gland into a shell containing soft cheesy or semifluid contents is described Normal tissue is usually present in the form of a thin rim of yellow cortical substance, or a portion of intact medulla and cortex may be present at one or more poles of the glands In a small

number of cases one or both glands may be shrunken The substance is composed of a thick layer, often stratified layers, of connective tissue enclosing firm, inspissated, yellow caseous, partially calcareous nodules Suprarenal tissue cannot be identified grossly This form is designated by Dietrich and Siegmund as "indurende (fibrose) Tuberkulose" This is not an independent form of tuberculosis of the suprarenal glands, but represents an older stage, transitions from the larger caseous forms to the small indurated forms may be seen

Microscopically, the glands are replaced for the most part by large homogeneous confluent caseous masses The reaction about these varies considerably Most commonly, areas of caseation are well walled off by a thin zone of connective tissue containing abundant collagenous fibrils and poor in nuclei In other portions of the same gland, the process may be more active, the reaction consisting of marked epithelioid cell formation, giant cells and wide zones of lymphocytic infiltration Less frequently, the proliferative reaction is lacking, and wide areas of caseation are bordered by partially necrotic parenchyma and leukocytes

TABLE 7—*Activity of the Lesion in Tuberculosis of the Suprarenal Glands*

	Acute	Chronic	Both Chronic and Acute	Healed
Unilateral lesions	8	2	2	0
Bilateral lesions without symptoms	1	1	3	0
Bilateral lesions with symptoms	1	3	13	1

In glands that grossly appear healed, areas may be obtained that show marked activity in the form of dense clusters of miliary tubercles Both proliferative and caseous types are seen in about equal frequency The smaller glands are not infrequently the site of widespread fibrosis, and only an occasional area of caseation or of giant cells distinguishes the lesion Hubschmann[494] described acute exacerbation of apparently healed foci in which there is an extension of the process into uninvolved portions of the suprarenal gland The connective tissue wall may be broken down and included in the caseous mass These exacerbations may be repeated several times until the entire suprarenal gland is destroyed In table 7 the activity of the lesion in thirty-four cases studied microscopically is given

In the unilateral lesions, the process appears more active than in the bilateral ones A wide acute caseous form involving both suprarenal glands is rarely observed in Addison's disease In the majority of cases the process is chronic with areas of acute exacerbation Complete healing is rarely observed Complete quiescence of the lesions was present in only one case No proved case of healed tuberculosis of the suprarenal glands has been reported in the literature Kovacs reported a case in a woman aged 27 years in which the organs were

very small and showed a central area of calcification and bone formation, but he was not certain that it was tuberculous Calcification is not uncommonly seen Bone formation has been described

In both unilateral and bilateral lesions, the medulla is frequently completely destroyed, whereas large portions of the cortex may remain This indicates that the medulla is less resistant to the infection than the cortex This is also clearly shown in the experiments on dogs by de Vecchi By injecting virulent tubercle bacilli into the adrenal glands, he was able to show that the medulla was first completely destroyed, and that then the process slowly involved the cortex, which appeared more resistant to the infection than the medulla Small nodules of

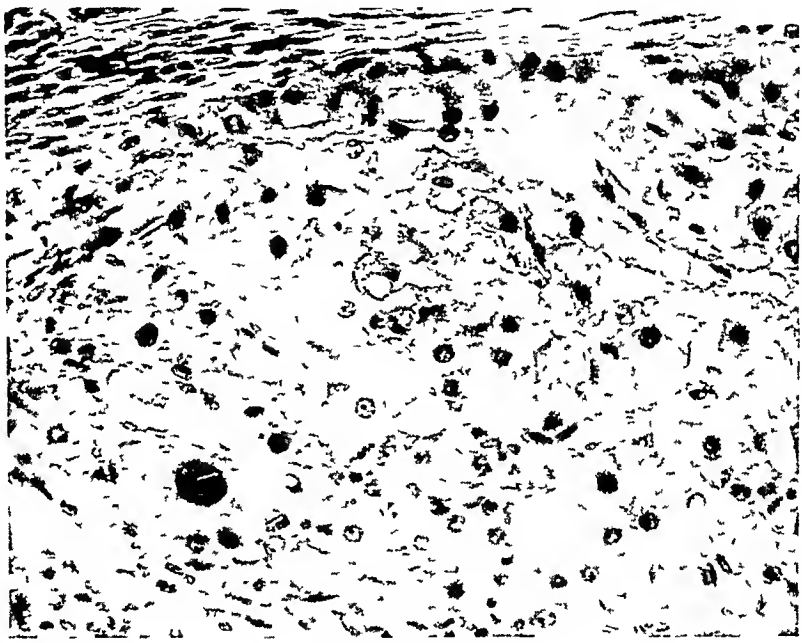

Fig 4—Edge of a small circumscribed area of hyperplastic cortical cells in a case of tuberculosis of the suprarenal glands

cortical tissue may become separated by connective tissue bands These have the structure of zona fasciculata and often show marked degenerative changes Not infrequently small nodules of cortical cells are present near the periphery of the gland and occasionally in the fibrous capsule which are identical in structure with the hyperplastic nodule so frequently seen in atrophy of the suprarenal glands (fig 4) In the more acute lesions, the cortical remains often show marked degenerative changes in the form of swelling of the cells, vascular degeneration, karyorrhexis or karyolysis of the nuclei

Fibrosis of the capsule and the surrounding tissue may be extensive Included in the fibrous mass may be seen sympathetic nerves, blood vessels and small groups of sympathetic ganglions Hyperplastic inti-

mal changes in the smaller arteries are common The veins are not infrequently the site of thromboses

Tubercle bacilli were found in thirteen of twenty-nine cases stained by the Ziehl-Neelsen method The cases in which results were negative were those in which organs had been preserved for many years in 10 per cent formaldehyde Barker reported the finding of tubercle bacilli in eleven of twenty-five cases examined at the Mayo Clinic In the literature reports of finding tubercle bacilli in smears and in sections are given in thirty-one additional cases

SYPHILIS

Syphilis of the suprarenal glands with symptoms of Addison's disease was present in only one case proved at autopsy (Sézary) In this case, symptoms of asthenia and pigmentation followed shortly after primary infection, and death occurred four months later The suprarenal gland showed sclerosis and gumma formation Spirochetes were demonstrated Clinical reports are more numerous Wile, Schaffner and Howard Gaucher and Gougerot and others described cases that were believed to be due to syphilis The diagnoses were based on the favorable response of these patients to antisyphilitic treatment Since spontaneous remissions are often seen in cases of Addison's disease the response to antisyphilitic treatment cannot be accepted as adequate proof of the syphilitic nature of the lesion

The infrequency of autopsy reports of syphilis and the prevalence of clinical cases raise the question whether some cases diagnosed anatomically as tuberculosis may not be syphilitic Demonstration of the tubercle bacillus is not frequently made In cases with widespread fibrosis and extensive lymphocytic infiltration, it is difficult to rule out syphilis on microscopic structure The evidence that these cases are not syphilitic is strongly suggestive, but not conclusive Careful search will often show tubercle bacilli in cases in which the lesion is suggestive of syphilis A history of syphilis or of organic lesions suggesting syphilis is reported in only three cases Congenital syphilis of the suprarenal gland is not infrequent and may result in the formation of interstitial fibrosis, miliary gumma (Guleke, Gierke) and rarely large central necrosis and granulation tissue Simmonds[498] found a perisuprarenalitis in congenital syphilis, but did not find it in the adult Winogradow found on examination of a large number of cases of visceral syphilis that gummas of the suprarenal gland were absent It is highly questionable therefore that syphilis plays an etiologic rôle in cases of fibrocaseous destruction of the suprarenal glands, in which the etiologic agent is not demonstrated

PRIMARY CONTRACTED SUPRARENAL GLAND (ATROPHY)

This condition has been designated by many names Bittorf (1908), in his monograph on Addison's disease, collected a group of cases under the heading of chronic idiopathic (primary) suprarenal insufficiency (cirrhosis atrophy) It has been variously termed "reine" atrophy (Bloch), "einfache" atrophy (Karakascheff), idiopathic atrophy (Simmonds) chronic dystrophy (Kiefer), inflammatory granular atrophy (Rossle) cytotoxic contracted suprarenal gland (Kovacs), cirrhosis (Lampl Lucksch) and hypoplasia (Hedinger, Kraus) The condition is not a simple atrophy in the restricted sense of the term since the organ does not shrink because of atrophy of its cellular elements but because of necrosis and disappearance of cells Rossle suggested granular atrophy because of the marked inflammatory reaction of a hemorrhagic nature seen in his case This case, however differs from the others in the degree of inflammatory reaction secondary to the degenerative changes in the parenchyma The term hypoplasia is erroneous as the disease is acquired The expression "cirrhosis" of the suprarenal gland suggested by Lucksch and Lampl may fit individual cases in which the growth of the reticulum is marked These cases are few and there are transitions from those with marked to those with little or no, connective tissue reaction Recently Kovacs suggested the term cytotoxic contracted suprarenal gland This descriptive term is based on the unwarranted assumption that the disease is due to a circulating toxin that injures and destroys the cells of the suprarenal cortex Unless there is some evidence to support this view, this term should not be used

The term "primary contracted suprarenal gland" is here adopted to include all of these cases since there is little known of the etiology and since the fibrosis consists mainly of a collapse of the reticulum following degenerative changes in the parenchyma

Frequency—It is a rare disease The older reports have been collected by Simmonds (1904) who studied twenty-four cases and later by Bittorf (1908) who collected forty-seven cases Since 1900, sixty-eight cases have been reported, or 16 13 per cent of all the cases that came to autopsy It has already been mentioned that this does not represent the relative frequency of primary contracted suprarenal gland because recently owing to increased interest in the disease there is more tendency to report cases of atrophy than cases of tuberculosis

Classification—Bittorf has separated his cases into two distinct groups simple atrophy and inflammatory atrophy or cirrhosis of the suprarenal gland Simple atrophy is characterized by a small thin organ One suprarenal gland may be more affected than the other Inflammatory changes are lacking and there is no increase of connective

tissue The cortex is lacking in one or more layers, or there may be alteration of the parenchyma in the form of fatty degeneration decrease in fats and, less frequently, necrosis In the inflammatory type, there is often adhesion to the surrounding tissue and a thickening of the capsule, trabeculae and blood vessels Degenerative changes are marked and are accompanied by marked round cell and polymorphonuclear cell infiltration In an analysis of the cases collected from the literature and my own cases, given in later paragraphs, it is found that a sharp separation of the cases into these two groups of Bittorf cannot be made Cases that conform in all details to the two groups are few in number, whereas the majority show characteristics of both groups Sections taken from various portions of one organ may show in places little or no reaction of the reticulum but a simple disappearance of the cortical cells, leaving the collapsed supporting reticulum and a moderate lymphocytic infiltration, while in other places there may be active proliferation of the connective tissue, a marked cellular reaction and thickening of the capsule (see page 765 and fig 9) The degree of reaction of the connective tissue and reticulum is dependent more on the tempo of the degenerative changes and the age of the lesion than on any discernible difference in etiology The uncertainty of classifying these cases into the two aforementioned categories is revealed by the disagreement in the interpretation by various authors Cases, almost identical in structural changes, are regarded as inflammatory by some and as simple non-inflammatory by others

I recently had the opportunity of studying two unusual cases of atrophy, one representing a fairly early, and the other a late, stage of the disease They are given in detail because they illustrate clearly the nature of the changes

CASE 1—*History*—A white woman, aged 27, called a physician on Oct 23, 1929, because of headache, nausea and vomiting She had a marked brownish pigmentation of the skin On October 25, she complained of headache, drowsiness and insomnia She was given morphine On the morning of October 26, she had three spastic convulsions, the temperature rose to 100 F , the pulse rate remained at from 75 to 80, but was weak The urine was normal, the blood sugar was normal The patient died on October 26

Autopsy—The body was well developed, slender, 163 cm long, and weighed 100 pounds (45 4 Kg) There was fairly marked cyanosis of the face Definite brown pigmentation of the skin of the face the anterior axillary folds, the nipples, the umbilicus and of the skin below the knees was present The hands, forearms and face were especially dark The subcutaneous fat was scant The heart weighed 140 Gm The valves were normal The right coronary had three openings into the aorta The heart muscle appeared brown The root of the aorta was normal, except for two small vessels, one having its origin at the arch, between the innominate and the carotid arteries, and one between the carotid and the subclavian arteries These vessels went to the neck The lungs showed

moderate congestion at the bases The spleen weighed 150 Gm The follicles were prominent Each kidney weighed 100 Gm , the appearance of each was normal Numerous small subperitoneal hemorrhages were present throughout the fallopian tubes The mediastinal and mesenteric nodes varied in diameter to 1 cm On section, they showed brownish pigmentation

Both suprarenal glands were very small and thin, the maximum thickness was 3 mm There was a small extravasation of blood in the tissues about these glands The surfaces were fairly smooth and deep reddish brown On section, the surface was extremely dark The normal markings could be distinguished There was no evidence of thrombosis of the vessels

Anatomic Diagnosis—The conditions were diagnosed as primary contracted suprarenal glands, brown pigmentation of the skin, subperitoneal hemorrhage about the fallopian tubes and congenital anomaly of the aorta



Fig 5—Early degenerative changes in cortical cells, slight retraction of cells from reticulum

Microscopic Examination of the Suprarenal Glands—Sections were stained with Harris' hematoxylin-eosin, Heidenhain's azocarmine, and the potassium ferrocyanide stain for hemosiderin The histologic changes were as follows The cortex was about one third of its normal thickness The normal arrangement of the three layers was lacking In places, columns of cells resembling the zona fasciculata were present, and, in places, small subcapsular clusters of cells resembling the zona glomerulosa The medullary tissue was of normal thickness Here and there in small areas the medullary tissue was replaced by dense clusters of lymphocytes The cortex was the seat of marked changes Figures 5, 6, 7 and 8 illustrate the changes seen throughout the gland In figure 5, the cortical cells are seen in the process of contraction and withdrawal from the reticulum The relation of the cells to the reticulum is brought out clearly by the azocarmine stain The cells are decreased in number, their borders are poorly defined and, in places, clusters of these cells give the appearance of multi-



Fig 6—Further advanced stage Cortical cells show marked degenerative changes Reticulum is intact Spaces formerly occupied by cortical cells contain red blood cells, cellular debris and lymphocytes



Fig 7—Far advanced stage Few epithelial cells remain The reticulum is partially collapsed

nucleated giant cells Their cytoplasm contains an occasional vacuole, but, for the most part, it stains more deeply and darker than the normal spongioblast The nuclei vary in size and in staining qualities Karyolysis and pyknosis are present As a result of retraction of these cells, large spaces are present between the reticulum and the cells In places, these are filled in by red blood cells, in other places, they are empty Figure 6 shows a more advanced stage Only a few cells are present, and these are in the process of disintegration The reticulum is closer together, and the spaces left by the disintegrating cells are filled in by red blood cells, lymphocytes and plasma cells In figure 7, the parenchyma is almost entirely absent, leaving only the partially collapsed network of reticulum In other areas, the reticulum is completely collapsed and flattened out into fenestrated laminae, which lie parallel to the capsule Throughout the cortex there is a diffuse infiltration of lymphocytes, plasma cells and an occasional



Fig 8—Area showing almost complete disappearance of cortical cells with marked infiltration by lymphocytes and plasma cells and extravasation of red blood cells

macrophage containing hemosiderin The infiltration is more abundant beneath the capsule The capsule shows no evidence of thickening The larger veins and arteries show no evidence of disease A small amount of extravasation of blood is seen in the pericapsular region

Case 2—*History*—A woman, aged 50, a housewife, had always enjoyed good health She was the mother of four children Eight years before this study she had an attack of influenza from which an uneventful recovery was made An uneventful menopause occurred eighteen months before Fifteen years before, she began to notice a darkening of the skin, first over the face and hands This increased in severity until it became generalized Four or five years previous to examination, the mucous membrane of the tongue and cheek became pigmented She had been troubled since childhood with periodic attacks of diarrhea Shortness of breath on exertion had been present for a few years Until eighteen

months before, her strength was good, but this began to fail and there had been a steady loss of strengh since that time Weakness was very marked in the last few months before examination

Examination—Examination showed a high grade negroid pigmentation, particularly marked over the face, neck, hands, forearms, groin, vulva and areas subjected to pressure There were blackish patches of pigmentation over the lips and brownish patches on the tongue and the buccal mucous membranes The blood pressure was as follows June, 1927, 140 systolic and 90 diastolic, Oct 14, 1927, 130 systolic and 70 diastolic, Dec 7, 1927, 104 systolic and 70 diastolic, April, 1928, 104 systolic and 70 diastolic, September, 1928, 90 systolic and 65 diastolic, Oct 5, 1928, 96 systolic and 70 diastolic Examination of the blood showed hemoglobin, 56 per cent, red blood cells, 4,760,000, white blood cells, 6,000, lymphocytes, 36 per cent, eosinophils, 4 per cent, mononuclears, 22 per cent, polymorphonuclears, 38 per cent The Wassermann reaction was negative The van den Bergh test was negative for bilirubin Blood urea was 10 mg , creatinine, 1 mg, and blood sugar, 0 084 per cent The basal metabolic rate was minus 3 per cent There was absence of free hydrochloric acid, the total acidity was estimated as 10 degrees

Course—In the last few months, the patient rapidly lost strength and weight and died of progressive exhaustion on Oct 12, 1928

Autopsy—The body was fairly well developed, but poorly nourished There was marked pigmentation of the entire body, the color resembling that of a dark mulatto The neck, face, backs of the hands and forearms were especially pigmented The creases of the palms, neck and axillary folds were very dark in color, an accentuation was noted about the hips, knees and lateral portions of the feet The mucous membranes were involved, as noted The skin was smooth and thin, with no desquamation The subcutaneous fat was scant The thymus measurements were 60 by 30 by 25 mm , the weight was 16 Gm The thymus was firm and light reddish brown The heart weighed 180 Gm , it showed brown atrophy The lumen of the aorta was 1 7 cm in diameter at the proximal portion of the arch There was slight hypostatic congestion at the base of each lung The spleen weighed 175 Gm , the markings were normal The liver was small The stomach showed no lesions The pancreas showed nothing of note

The right suprarenal gland was found after considerable search, its dimensions were 30 by 20 by 2 mm The cortex appeared as a narrow zone composed of a glistening, grayish-white tissue The center was grayish brown Although prolonged search was made for the left suprarenal gland, it was not found There was no evidence of accessory interrenal or chromaffin tissue The kidney showed the horseshoe type of deformity The lymph nodes about the aorta and in the mesentery varied in size from a few millimeters to 1 5 cm in diameter The thyroid gland was of normal size and appearance

Anatomic Diagnosis—The conditions were diagnosed as primary contracted suprarenal gland (right), aplasia (?) of the suprarenal gland, pigmentation of the skin, horseshoe kidney, brown atrophy of the heart, hypostatic congestion of the lung and emaciation

Microscopic Examination—A dark granular pigment was present in the rete malpighii of the skin The thymus contained a broad medulla and was rich in Hassall's corpuscles Solitary follicles in the intestines appeared large Their secondary follicles were very active and were surrounded by a broad zone of lymphocytes The semilunar ganglions appeared normal The lymph nodes showed

a marked activity of the secondary follicles The sinuses were loaded with phagocytes The thyroid gland contained large numbers of lymphoid follicles, some of which showed germinal centers, these were situated between the lobules and, in places, within them The acini were poor in colloid Degenerative changes were present in the epithelial cells

Microscopic sections were taken through many parts of the right suprarenal gland and stained with Harris' hematoxylin-eosin, Pappenheim's pyronin-methylene green, van Gieson's stain and Heidenhain's azocarmine and by Mallory s method for demonstrating hemosiderin

The cortex was almost entirely lacking, it was reduced to a thin streak of hyalinized connective tissue, poor in nuclei A few plasma cells and lymphocytes were scattered throughout the capsule Directly beneath the capsule there were, here and there, dense collections of lymphocytes, plasma cells and phagocytes containing hemosiderin granules The capsule appeared slightly thickened In places there were small clusters of cortical cells that occupied the entire thickness of the gland Some of these cortical masses appeared encapsulated The cells varied considerably in size and were atypical in arrangement The nuclei showed marked variation in size and staining qualities Their cytoplasm was homogeneous, pink-staining and poor in fat Small engorged capillaries ramified between these cells In places, these nodules were infiltrated by lymphocytes and plasma cells and often showed marked degenerative changes About these nodules, the collection of round cells was very dense The center of the gland was occupied by clumps of fairly deep-staining cells which had round to oval nuclei Some of these cells were connected to each other by protoplasmic processes Large dilated sinuses and capillaries were in close contact with them In places, they closely simulated the structure of the medulla, but in other portions it was impossible to state definitely whether these were cortical cells or medullary cells (Chromaffin stains were ineffective, as the tissues were not obtained until more than twenty-four hours after death) In places, accumulations of round cells embedded in a loose reticulum replaced almost the entire thickness of the gland

Figure 9 shows a section of the suprarenal gland in which there was an absolute increase of connective tissue, which was fairly vascular and replaced the parenchyma It was sharply delimited from the normal tissue, which resembled the medulla in structure The majority of sections, however, showed no actual increase of connective tissue, the increase was only relative and was due to the collapse of the reticulum Figure 10 illustrates a cross-section of the gland, in which there was little or no evidence of connective tissue reaction (compare with fig 9) The veins showed no evidence of thrombosis About some of the smaller veins were dense accumulations of plasma cells, phagocytes and lymphocytes The pericapsular region contained a small amount of extravasated red blood cells

Case 1 illustrates very clearly the stages in the disappearance of the cells of the cortex The inflammatory reaction was secondary to the degenerative changes and consisted for the most part of lymphocytes and plasma cells The reticulum was not destroyed, but collapsed following the disappearance of the cortical cells The place left by the cortical cells was partially filled by red blood cells, a condition that is very similar to that seen in red atrophy of the liver

Case 2 shows a much further advanced stage of the disease Little cortical tissue remained and only a thin zone of collapsed reticulum



Fig 9—Cross-section through gland showing fibrosis of entire thickness Adjacent to this is normal medullary tissue Cortical tissue is absent

Fig 10—Cross-section through entire thickness of gland, showing medulla of normal thickness Cortex is absent There is no inflammatory reaction

marked the remains of the cortex The medulla was secondarily involved by the inflammatory reaction in the cortex, but a large part of it was preserved Small nodules resembling hyperplastic cortical adenomas were present These adenoma-like nodules also showed degenerative changes

Structural Changes in the Cases Reported in the Literature—The glands are markedly reduced in size Their weight varies from 0 75 Gm to 3 Gm They are very thin, often of the thickness of paper One gland may be smaller than the other, but the difference in weight is not great Aplasia of one gland and atrophy of the other are described in two cases (Arnett, Hempelmann) The color varies from gray to brownish-red In most cases the surfaces are flat and smooth, nodular elevations are prominent in the cases described by Kiefer, Scott, Held, Lucksch, Kovacs and Matras The resemblance to the surface of a cirrhotic liver is often striking Adhesions to the surrounding structures are reported in only one case (Rossle)

On section, the medulla and the cortex are not readily defined The latter may appear as a gray streak, forming a great part of the thickness of the gland Small, well circumscribed nodules varying in color from yellow to brownish-red, may obscure the markings The thickened capsule may appear as a thin, grayish-white membrane Even in extreme cases the trilobed shape of the organ may be retained

Microscopically, the lesions in most cases are limited to the cortex, and the involvement of the medulla appears to be secondary The extent of the involvement of each layer, as far as can be determined, is as follows the cortex partially or completely destroyed and the medulla normal or slightly involved, thirty-three cases, the cortex and the medulla equally diseased seven cases, the medulla and the cortex both diseased the medulla more than the cortex five cases

The microscopic changes in the cortex are variable Little of the normal stratified layer remains, and the cortex is markedly reduced in thickness The cortical tissue in places is completely absent, so that the medulla, when present, lies adjacent to the capsule Occasional remnants of the zona glomerulosa and of the zona fasciculata are present In places only the loose reticular stroma remains, containing dilated and engorged capillaries Kraus and Hubschmann liken this to red atrophy of the liver Remnants of cortical cells may be embedded in a dense infiltration of lymphocytes and plasma cells Degenerative changes in cortical cells are almost constant They are most pronounced in the cases described by Held, Medlar, Kiefer and Lucksch They consist principally in loss of cellular outline swelling of cells, vacuolar and fatty degeneration, loss of lipoid, nuclear degeneration and fusion of cells to form large multinucleated forms

Regenerative changes in the cortical cells are present principally in two forms, namely in scattered islands of cells and in large, well circumscribed, adenoma-like nodules This is more marked in some cases than in others In the cases of Kraus, Bittorf Bloch and others, there is little or no evidence of regeneration Adenoma-like nodules are particularly prominent in the case reported by Kiefer and to a lesser degree in those of Lucksch, Kovacs, Held, Hubschmann, Rossle, Fahr and Reiche These consist of small areas of cortical cells encapsulated by connective tissue The cells resemble the zona fasciculata and at times the zona glomerulosa The nuclei show considerable variation in size, shape and chromatin content An occasional mitosis was observed by Kovacs The cytoplasm is poor in lipoids Degenerative changes are common in the center, and not infrequently the entire nodule is degenerated Infiltration of these nodules by lymphocytes may be marked At times, connective tissue and often a dense cellular infiltration replaces, in part, the area in which the cortical cells have disappeared The cells consist mainly of small lymphoid-like cells, plasma cells and large macrophages, the latter often containing granules of hemosiderin In a number of cases (Bloch, Schmidt, Wahl, Lucksch, Kovacs, etc) there is little or no connective tissue replacement of the cortex Frequently there is a diffuse infiltration of small lymphoid cells in a loose reticulum immediately beneath, and often penetrating, the capsule Bloch believed that these are sympathetic-formative cells Held, Hubschmann, Furuta, Kovacs and others regarded these as inflammatory Paunz expressed the belief that they arise from the reticulo-endothelial cells in response to irritation Large accumulations of lymphocytes may occupy the entire thickness of the glands Small areas of extravasation of erythrocytes are often present In the cases reported by Rossle and in cases 1 2 and 3 reported by Fahr and Reiche, the inflammatory changes are more conspicuous than in the cases reported by others Rossle's case showed hemorrhagic areas of necrosis in the cortex Fahr and Reiche described a perivenous infiltration of granulation tissue Perivascular round cell infiltration was mentioned by Kovacs and Kraus A sharp demarcation between cortex and medulla is often lacking Hubschmann found it difficult to distinguish the surviving medullary from the cortical tissue

The medulla occasionally shows a reduction in size infiltration by lymphoid cells and rarely connective tissue replacement Bloch traced transition stages from the small sympathetic-formative cells to chromaffin cells This was also mentioned by Wahl and Lucksch Complete destruction of medulla was mentioned by Wakefield and Smith The chromaffin reaction is variable

Changes in the pericapsular tissue are slight Small groups of lymphoid cells are occasionally present Small cortical rests in the capsule are described Vascular changes are absent The nerves and sympathetic ganglion cells are not altered

Etiology—In 1903, Simmonds[167] found two cases showing perivascular infiltration and endarteritic proliferation which suggested syphilis as a causative factor In the majority of his cases, however, these changes were lacking Later, Simmonds[498] found in early congenital syphilis inflammatory thickening of the capsule and secondary involvement of the cortex He suggested that this change may lead to the disappearance of the cortex but he was not able to demonstrate the process in older persons He finally concluded that though syphilis must be considered, it cannot be proved to be an etiologic factor Recently Fahr and Reiche described a perivascular infiltration of lymphocytes and granulation tissue, suggesting a syphilitic infection, in three cases In only one case, however, was there a history of syphilis, and in every instance anatomic evidence of syphilis elsewhere was absent Hubschmann's cases did not show vascular alterations, but showed lesions in the liver suggestive of syphilis A history of syphilis of two years' duration was obtained in the case described by Fiessinger and Leroy In the remaining cases, there is no evidence of syphilis There is little proof, therefore, that syphilis is a causative factor, except in rare instances

Still less proof is available that the lesion is tuberculous Granulomatous lesions, tubercles, caseation, calcification and adhesions to the surrounding tissues are lacking In tuberculosis of the suprarenal glands, it has been shown that the medulla is involved earlier than the cortex and that the lesions are more extensive in the former than in the latter The majority of cases of primary contracted suprarenal gland show little or no change in the medulla

A congenital hypoplasia or disturbance in the development of the glands is considered by Neusser, Wiesel, Bloch and Wahl In a detailed histologic study, Bloch found transitional stages in the development of chromaffin cells from small round cells which he regarded as embryonic sympathetic-formative cells He considered that this was an effort at compensatory hyperplasia of the medulla which was retarded in development Paunz opposed the belief that these are sympathetic-formative cells believing that they are histiocytes in the sense of Aschoff which are derived from the reticulo-endothelial system Oberndorfer considered that the cells in the medulla, interpreted by Wiesel as sympathetic-formative cells, are merely collections of lymphocytes and plasma cells, and quoted Aschoff, who also failed to confirm Wiesel Bloch's theory failed to account for the marked degenerative changes in

the cortical cells, which appear to be the primary site of the disease, the medullary changes being secondary It is also difficult to conceive of congenital hypoplasia, or underdevelopment, of the suprarenal gland in which no symptoms are present until as late as the fifth or sixth decade

The susceptibility of the suprarenal glands to acute and chronic diseases elsewhere in the body has been strongly emphasized in recent years Dietrich and Siegmund found degenerative changes in the cortical cells with round cell areas in chronic septic marasmus, and suggested that these changes may lead to replacement by scar tissue and atrophy of the organ with symptoms of Addison's disease Thomas found marked vacuolar degenerative changes in the cortex in diphtheria, and marked edema and granular degeneration in scarlet fever Degenerative changes in the course of infectious diseases were described by Weisenfeld, Wulfung, Goldzieher, Oberndorfer and others More recently, Paunz made a study of histologic changes in the 1,171 suprarenal glands under various conditions He found changes in 197, or 17 per cent These changes consisted principally in the formation of plasma cells, lymphocytes and macrophages from the reticulum, and he distinguished three groups according to the distribution and type of reaction In 7 cases, he found marked connective tissue replacement of the cortex The majority of cases occurred in the third decade and were associated with the following conditions acute inflammation, 20 cases, simple chronic inflammation, 27 cases, chronic caseous tuberculosis, 8 cases, syphilis, 16 cases, lymphogranulomas, 2 cases, tumors 52 cases Bernard and Bigart investigated the suprarenal glands in 30 cases of tuberculosis and found perivascular sclerosis of the zona fasciculata with secondary changes in the parenchyma In several cases marked atrophy of the parenchyma with sclerosis resulted Kioyokawa, in a more extensive study, found sclerotic changes in the suprarenal glands in 20 of 100 cases associated with tuberculosis elsewhere in the body These changes consisted of an increase of connective tissue about the capillaries in the zona fasciculata and degenerative changes in the parenchyma He designated this condition as tuberculotoxic suprarenal cirrhosis

From this brief review it is evident that in a number of acute and chronic diseases the suprarenal gland may be the site of marked degenerative changes The changes are not peculiar to any disease and are not constant They are not comparable to the changes seen in primary contracted suprarenal gland

Perivascular sclerosis which is constant in the "tuberculotoxic cirrhosis" of the suprarenal gland is not present in primary contracted suprarenal gland A marked diminution in size of the organ is striking in primary contracted suprarenal gland whereas it is rarely seen in the

changes associated with an infectious disease As suggested by Kovacs, the changes described by Dietrich and Siegmund in infectious diseases and chronic marasmus are analogous to fatty degeneration of the liver, whereas in primary contracted suprarenal gland the changes are similar to cirrhosis of the liver A history of long standing infection is lacking in the reported cases of primary contracted suprarenal gland In sixty-eight cases of primary contracted suprarenal gland, the past illness as recorded in the histories are as follows rheumatic fever three cases (four years, eighteen years and twenty years, respectively, preceding the onset of symptoms of Addison's disease), empyema, one case pulmonary tuberculosis, one case, influenza two cases, bronchitis and asthma, one case, typhus, one case (thirty years preceding the onset), suppurative angina, one case (three and one-half years previous to the onset), typhoid fever, one case (eleven years previous to the onset), malaria, one case, and syphilis, two positive cases and one questionable case

It is improbable that the incidence of chronic infections is greater in primary contracted suprarenal gland than in any other chronic disease

In summary, it may be stated that the etiology of primary contracted suprarenal gland (atrophy) is still unknown The pathologic changes indicate that the condition is primarily a slow degeneration involving the cortex and leading finally to the disappearance of the cortical cells The inflammatory reaction is variable and may be regarded as secondary, the degree of it depending on the severity and tempo of the degenerative changes Partial function is maintained by regeneration in the form of small adenoma-like islands of cortical cells These later may also undergo degenerative changes There is little evidence that these changes are due to infectious processes in the suprarenal gland The changes may well be likened to subacute atrophy of the liver Kovacs, and recently Omelskyj, suggested that the changes are due to a circulating toxin of unknown nature which has a specific action on the cortical cells They accordingly designated the condition "cytotoxic contracted suprarenal gland" There is as yet little evidence in support of this theory

AMYLOIDOSIS OF THE SUPRARENAL GLAND

Amyloidosis of the suprarenal gland until recent years has not been considered a cause of Addison's disease Similar to metastatic carcinoma amyloid deposits in the suprarenal gland are a common occurrence but the injury to the parenchyma in most cases is not sufficiently extensive to give rise to symptoms of Addison's disease Six cases of Addison's disease associated with amyloidosis of the suprarenal glands are included in the literature (Bittorf Schlesinger Schultz, McCutcheon Hunter and Rush and Philpott) A case reported by Bauer is doubtful The associated lesions are pulmonary tuberculosis, three cases, tertiary

syphilis one case, hypernephroma, one case, tuberculosis and syphilis combined, one case Amyloid deposits in other viscera are usually present In McCutcheon's case, the sympathetic ganglions, thyroid gland, hypophysis and pancreas were similarly involved

Macroscopically, the organs appear normal or slightly increased in size, are firm and vary in color from gray to yellow On section, the two layers are readily distinguishable The deposits are principally in the zona fasciculata and zona reticularis Amyloid is present outside of the endothelium of the capillaries and between the cortical cells, resulting in marked atrophy of the parenchyma and partial closure of the lumina of the vessels The medulla may show a slight diminution in size and small deposits of amyloid, particularly about the small vessels Clinically, the diagnosis is often difficult because of the symptoms of the underlying condition

FATTY DEGENERATION

Fatty degeneration was reported in three cases Loeper and Ollivier described a case of fatty degeneration of both suprarenal glands in a woman, aged 30, who had typical clinical manifestations of Addison's disease In Schnyder's case the clinical picture is not convincing One organ is missing, whereas the opposite organ shows hypertrophy and fatty degeneration of the cortex The cause of these changes is not understood

TUMORS

Primary tumors causing symptoms of Addison's disease are noted in three reports Riemer reported a case of paraganglioma in a woman aged 46 Hertz and Secher noted pigmentation of the skin in a youth 16 years of age, who showed a neuroblastoma of the suprarenal glands with metastases to other organs An endothelioma of the suprarenal glands accompanied by all the cardinal symptoms of Addison's disease was reported by Black Metastatic tumors rarely cause Addison's disease as judged by the recent case reports Bilateral metastatic tumors are frequent and often extensive, but rarely give rise to symptoms of Addison's disease Little suprarenal tissue is recognizable grossly, but microscopically one finds abundant nests of surviving parenchyma The incomplete destruction of the suprarenal glands in metastatic carcinoma may account for the absence of symptoms of Addison's disease

VASCULAR LESIONS

Bilateral massive hemorrhage into the suprarenal glands is not infrequent in adults following acute septic conditions Death is usually rapid and often accompanied by symptoms simulating peritonitis Unilateral thrombosis of the suprarenal vein is not infrequently encoun-

tered, but is usually symptomless Bilateral thrombosis of the suprarenal veins associated with Addison's disease was reported by Straub, Veit and Kovacs In Straub's case symptoms of pigmentation and weakness developed in seventeen days following thrombosis Veit reported a case in a widow, aged 50, in whom symptoms appeared in the course of from four to five weeks In Kovacs' case, the lesion is of longer duration, the symptoms however being manifested only a few days before death

In the early stage, the organ is usually enlarged and dark in color The medulla is first involved and later the cortex The central part is replaced by a dark red firm tissue In the later stages (Kovacs), the organ is shrunken, the capsule is thickened and there is partial organization of a central detritus which contains abundant cholesterol and blood pigment

Anemic infarction was present in a case described by Furuta Destructive cortical lesions resulting from multiple arteriolar emboli in the course of an ulcerative endocarditis was seen on microscopic study Macroscopically, the organ appeared normal

MISCELLANEOUS LESIONS

Aplasia of one gland is rare When associated with Addison's disease, the opposite organ is usually the site of pronounced anatomic changes In agenesis of one suprarenal gland, the right without exception is the side involved (Hecht Miloslavich) There is usually an associated developmental anomaly of the kidney of the same side or of the genital organs (Miloslavich)

There are six case reports of aplasia of one suprarenal gland associated with Addison's disease The right side was involved in four cases and the left in two Four of these cases were associated with atrophy of the opposite organ In one case, the opposite organ showed hypertrophy and venous thrombosis (Veit) In another case (Schnyder), the opposite organ was hypertrophied and showed fatty changes The clinical picture in this case was not convincing

Addison's disease following trauma was reported by Bormann and Durck Bormann's case showed hyperplastic chronic inflammatory changes with degeneration of the parenchyma which was attributed to trauma In Durck's case symptoms followed fracture of ribs Symptoms of varying intensity were present for seven and a half years The suprarenal glands were small and were replaced by scar tissue The presence of blood pigment in the suprarenal glands suggested hemorrhage and thrombosis of traumatic origin Clinical cases of Addison's disease following trauma are reported by Riemer and Lescheziner Abscess formation due to pneumococcus following pneumonia was

described by Roth Fritz described a case in which there occurred bone marrow metaplasia of the suprarenal gland

ADDISON'S DISEASE WITHOUT LESIONS IN THE SUPRARENAL GLANDS

Four cases of Addison's disease without lesions in the suprarenal glands were reported Briefly these were as follows

CASE 1 (Richon) —A girl, aged 10, had always shown a brownish tint of skin The father died of tuberculosis The paternal grandfather and aunt had a remarkable coloration of the skin The father and the mother were not dark During the two months before examination, the patient's skin had become darker The mucous membrane of the mouth was pale For two months, there had been weakness and inability to attend classes Early physical signs of apical tuberculosis were present No gastro-intestinal symptoms were noted The patient was given subcutaneous injection of extract of suprarenal capsule On the fifth day, there were vomiting and an increase of weakness The patient improved and was discharged from the hospital on the twentieth day Three and one-half months later, pigmentation of the skin was almost gone The patient's strength and general condition improved Eleven months later, she was readmitted, with vomiting, abdominal pain, diarrhea, a return of pigmentation of the skin, loss of weight and a yellowish color of the soft palate She was given epinephrine by mouth The coloration of the skin deepened About one month later she died

Postmortem examination revealed tuberculous infiltration of both upper lobes, fibrinous pleuritis, cretaceous change in the bronchial nodes, tuberculous ulceration of the lower ileum, with perforation 5 cm from the ileocecal valve, 200 cc of fluid in the peritoneal cavity, normal sympathetic ganglions of the celiac plexus except for an increase of connective tissue, and an absence of change, either gross or microscopic, in the suprarenal glands

CASE 2 (Nobecourt and Brelet) —A boy, 1¼ years old, showed slight pigmentation of the skin The mother had pulmonary tuberculosis The patient's pigmentation seemed to increase while he was under observation There was no pigmentation of the mucous membranes The patient showed marked asthenia, loss of weight, constipation and bronchitis The asthenia became more pronounced, and the patient died three weeks after admission

Postmortem examination showed marked miliary tuberculosis of the lungs of recent origin, caseous mediastinal and mesenteric nodes, tuberculous meningitis, and no change, gross or microscopic, in the suprarenal glands

CASE 3 (Sbrozzi) —A woman, aged 26, previous to admission had suffered from pain and swelling of the joints accompanied by a high temperature On therapy, the pain and swelling of the joints disappeared, but the high temperature continued Vomiting and diarrhea became marked There was a diffuse bronchial catarrh, with a systolic murmur over the pulmonary area Extrasystole was noted The spleen was enlarged A few days after the patient s admission bronchopneumonia developed The color of the skin turned dark, especially in the folds of the body and in the inguinal region Profuse diarrhea developed and the patient died

Postmortem examination showed red hepatization of the right lower lobe bronchopneumonia of the left lower lobe fibrinous pleuritis, verrucous endocar-

ditis, acute splenic tumor, and no gross or microscopic alteration of the cortex or of the medulla of the suprarenal glands

CASE 4 (Debove) —A man, aged 41, had chronic alcoholism, with symptoms of cirrhosis of the liver, for which he had been treated on a previous admission to the hospital Erysipelas of the face developed, and he reentered the hospital The erysipelas responded readily to treatment Following this, the patient showed the development of pigmentation of the skin He claimed that he had always been brown The color was that of a mulatto Pigmentation was more marked in the groin and axilla Anorexia, pronounced diarrhea, vomiting and loss of weight developed The blood pressure was 90 mm of mercury Marked weakness was shown

Postmortem examination showed ascites, the ascitic fluid contained tubercle bacilli The liver weighed 780 Gm, and showed typical atrophic cirrhosis The left suprarenal gland weighed 22 Gm, the right, 7 Gm There was a mild degree of sclerosis of the capsules of the suprarenal glands On microcopic examination, all layers were intact, there was no evidence of tuberculosis There was an area of fibrosis about the celiac axis which extended laterally over both suprarenal glands

In case 1, the patient had been dark since birth, an increase in pigmentation had been noted shortly before admission The mucous membranes were not involved A deepening of the color of the skin is sometimes seen in cases of advanced tuberculosis It is also probable that in this case the severe tuberculosis of the lungs accounted for the asthenia and the gastro-intestinal symptoms The same objections may be raised in case 2 In case 3, the major symptoms were those of verrucose endocarditis The pigmentation was not typical, as the mucous membranes were not involved Since the gastro-intestinal symptoms and adynamia followed the development of the terminal pneumonia they may be regarded as a manifestation of toxemia In case 4, it is probably that the far advanced cirrhosis of the liver was responsible for some of the symptoms interpreted as those of Addison's disease Here, again, pigmentation of the mucous membranes was lacking The blood pressure was only moderately reduced, and the weakness and the gastro-intestinal symptoms were terminal

These cases therefore, cannot be considered as important evidence for the theory that Addison's disease can occur without changes in the suprarenal glands

CHANGES IN OTHER ORGANS

THYMUS AND LYMPH NODES

The weight of the thymus is given in twenty-nine cases of Addison's disease These are plotted in figure 11 on a thymus weight curve of normal persons who met with accidental death The normal curve was obtained from Hammar's tables

The mean weight of the thymus of normal persons is designated by the continuous line, the second and fourth quartiles by the coarse

broken line, and the maximum and minimum, by the dotted lines The weight of the thymus in normal persons increases rapidly until the fifteenth year, after which there is a fairly steady but slow decline in weight The normal variation in the weight of the thymus is very great, the interval between the mean and the maximum even in well advanced life varies from a few grams to 45 Gm

The cases of Addison's disease in which weights of the thymus are given are divided into three groups, viz (1) cases in which there had been no loss of body weight preceding death, (2) cases in which the state of nutrition cannot be determined from the case reports, and (3) cases in which there had been loss of body weight preceding death Only one case (Rossle) lies above the maximum but this case is com-

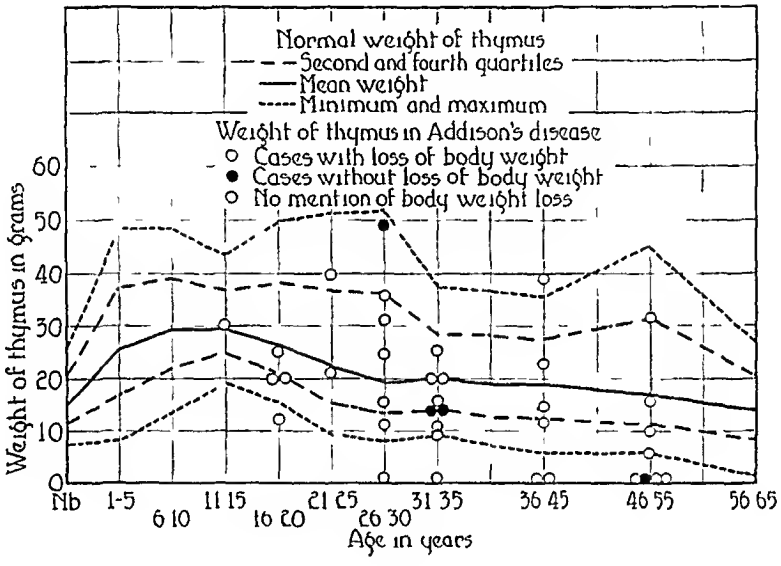

Fig 11—Weight of thymus in Addison's disease

plicated by Graves' disease, which is frequently associated with enlargement of the thymus Five cases lie close to the mean Fifteen cases lie below the mean In the remaining eight cases no evidence of the thymus was found These are given on the base line in figure 11

Judging from the weight of the thymus alone, one readily sees that in Addison's disease the weight of the thymus does not exceed that found in normal persons who have died of accidental causes It is probably higher than in cases of death from infectious diseases and higher than in cases in which there has been a slow and gradual loss of weight It does not reach the large dimensions found in Graves' disease or in myasthenia gravis

However to judge from the weight of the gland alone is misleading as this does not give any information as to the relative proportions of fatty tissue and parenchyma This relation cannot be determined from

the cases at hand, as only few reports of the microscopic appearance of the thymus are given In two cases reported by Hammar, there is an increase in the number of Hassall's corpuscles of the type III, which he attributed to a toxic factor The weight of the glands, however, was within normal limits A few cases were reported in which the thymus contained a broad medulla or in which the appearance of the thymus in childhood was simulated

Lymphatic hyperplasia was more frequently reported than enlargement of the thymus Table 8 gives the frequency of lymphatic enlargement in tuberculosis of the suprarenal glands and in primary contracted suprarenal glands

The condition of the lymph nodes is mentioned in the reports on sixty-four cases of tuberculosis of the suprarenal glands In twenty-one cases, enlargement of all nodes was noted In the reports of nine-

TABLE 8—*Frequency of Lymphatic Enlargement in Tuberculous, and in Primary Contracted Suprarenal Glands*

	Tuberculous Suprarenal Glands		Primary Contracted Suprarenal Glands	
	Number	Per Cent	Number	Per Cent
Generalized enlargement	21	32 81	10	21 28
Localized enlargement				
Follicles at base of tongue and tonsils	6	9 39	5	10 64
Peyer's patches	6	9 39	7	14 89
Mesenteric nodes	5	7 80	5	10 64
Retroperitoneal nodes	5	7 80	5	10 64
Other nodes	2	3 13	6	12 76
No enlargement	19	29 69	9	19 15
Total	64	100 00	47	100 00

teen cases, it is stated that the lymph nodes were not enlarged In reports on primary contracted suprarenal glands, the condition of the nodes is given in a larger percentage of the cases The distribution and frequency of enlarged nodes are somewhat similar to those observed in tuberculosis of the suprarenal glands

As in thymic hyperplasia, the question is raised as to whether or not these enlargements are normal variations I recently collected material for a study of the structure of normal lymph nodes in various parts of the body The material was obtained from normal persons who had met with accidental death It was found that, as in the case of the thymus, there is a wide variation in the size of the nodes in adults, as well as in children Exact standards for comparison, however, are not available and for the present the final answer to this question must be left open

Wiesel[51] Neusser and Wiesel Hedinger and others designated these cases as status lymphaticus They expressed the belief that in this

condition the chromaffin tissue is hypoplastic in the suprarenal glands and other parts of the body

There are several objections to this theory As has been shown, the evidence is not conclusive that the hyperplasia of the lymphatic tissue can be considered abnormal In many cases of primary contracted suprarenal gland in which the lymphatic tissue is reported hyperplastic, the medullary tissue of the gland is not altered in quantity, the cortex being the main seat of involvement In addition, there is little support for the theory that the extrasuprarenal chromaffin tissue, which normally undergoes involution has any physiologic importance

There is experimental evidence that the destruction of the adrenal glands in animals is followed by a hyperplasia of the lymphatic apparatus The experiments of Marine Manley and Baumann in rabbits, and of Jaffe in rats indicate that suprarenalectomy not only prevents involution of the thymus, but produces regeneration of a highly involuted thymus Zwemer found that removal of the suprarenal glands in cats results in a hyperplasia of lymph nodes and enlargement of the spleen and thymus Kahn, Rossle, Medlar and others held that there is a hyperplasia of the lymphatic apparatus in Addison's disease, but that this develops subsequent to the destruction of the suprarenal glands

ENDOCRINE ORGANS

In Addison's disease it is uncommon to find symptoms referable to any of the glands of internal secretion, aside from the suprarenal glands In seven cases symptoms of exophthalmic goiter were reported These are the cases of Rossle, Courmont, Lesieur and Thevenot, and Head, one case from the records of the St Thomas Hospital, London, and the cases of Loffler, Donath and Lampl, Étienne and Richard Held's case showed symptoms of polyglandular involvement The cases reported by Bendix presented symptoms of intermittent polyuria Diabetes mellitus was present in the case reported by Arnett Allan Bonner and Calloway each report a case of cessation of menses at the onset of the disease In most cases, however, there is little or no disturbance of menstruation Impotence in man is not infrequently reported

Pathologic changes in endocrine organs other than the suprarenal glands are frequently reported The thyroid gland is most frequently involved In association with primary contracted suprarenal gland, degenerative changes in the epithelial cells of the thyroid gland, lymphocytic infiltration and foci of lymphocytes containing secondary follicles in the intralobular spaces and not infrequently replacing the parenchyma are reported by Schmidt, Zondek, Bloch, Brenner Kiefer and others Dubois reported three such cases in association with tuberculosis of the

suprarenal glands Hyperplasia of the thyroid gland was reported by Rossle and a colloid goiter by Loffler Involvement of the pancreas was rarely described Chronic interstitial pancreatitis was reported by Phillips and Arnett Skirving and Welsh described hemorrhage into the pancreas, a rare occurrence in Addison's disease, whereas in experimental acute adrenal insufficiency in dogs, it is commonly seen (Stewart [502]) The ovaries and testes rarely show changes Kraus reported degenerative changes in the hypophysis in almost all of his cases of Addison's disease Polyglandular involvement was occasionally reported (Donath and Lampl, one case, Kreibig, one case, Wakefield and Smith, one case, Lucksch, one case, Kraus, two cases, Brenner, one case and Held one case)

The changes in other glands of internal secretion are inconstant and seldom of sufficient extent to give rise to symptoms of insufficiency It is improbable that the changes are the result of a disturbance in the interrelationship of the glands, but, as suggested by Held and Schmidt, the changes are more likely the result of the action of some unknown toxic substance on the suprarenal gland and other glands of internal secretion

GASTRO-INTESTINAL TRACT

In animals, following adrenalectomy, the presence of gastric and duodenal ulcers has been frequently observed Mann found that following the removal of both adrenal glands in sixty dogs and five cats gastric lesions developed in forty cases These consisted of hemorrhages, erosions and well formed ulcers In five cases, duodenal ulcers were also present In animals dying shortly after operation, ulcers did not occur, they occurred only in animals that lived one or more days These results were also obtained by Elliott and Finzi working independently Jaffe reported the frequent occurrence of hemorrhagic erosions of the gastric mucosa following bilateral adrenalectomy Stewart [502] in his recent review of experimental work on adrenalectomized dogs, stressed the marked gastro-intestinal disturbance that ushers in the terminal stage of the disease In most of these animals the gastro-intestinal tract shows a marked hemorrhagic congestion Stewart suggested the hypothesis that some toxic substance that develops following adrenalectomy is eliminated through the gastro-intestinal tract He also suggested that this congestion may be due to deficiency of the regulatory hormone that is normally secreted by the suprarenal glands

In the cases collected from the literature changes were noted in the gastro-intestinal tract, as set forth in table 9 The gastro-intestinal tract is definitely reported to be without changes in only twenty-one

cases but it is probable that a much larger number showed no change, since in many cases absence of changes is not recorded Peptic ulcers are reported in ten cases This comprises 21 2 per cent of the cases in which the condition of the stomach is mentioned, but only 2 2 per cent of the cases in which autopsy was performed It is questionable, therefore that these lesions are of any significance in the genesis of the marked gastro-intestinal disturbances that characterize this disease In only five cases is the stomach reported as congested, ecchymotic or injected This does not agree with the frequent occurrence of hemorrhagic congestion seen by Stewart in adrenalectomized dogs Other lesions are few in number and of varied nature

TABLE 9—*Changes in the Gastro-Intestinal Tract in Cases of Addison's Disease*

	Cases
Eosophagus	
Diverticulum	1
Stomach	
Carcinoma	2
Infection	1
Pallor of mucosa	2
Atrophy	1
Ecchymoses	3
Congestion	1
Chronic gastritis	1
Ulcer	7
No change	21
	40
Duodenum	
Ulcer	4
Hyperplasia of Brunner's glands	2
Mammillation of duodenal wall	2
	8
Jejunum, ileum and colon	
Carcinoma of rectum	1
Ascariasis	2
Appendicitis	1
(Tuberculosis discussed above)	
	4

SYMPATHETIC NERVOUS SYSTEM

Addison first regarded the symptoms of the disease that he described, as being the result of destruction of the suprarenal glands Later, finding that the sympathetic ganglions of the celiac plexus were involved frequently, he suggested that this lesion may be a contributing factor in the production of the syndrome Following his work, in the older literature considerable emphasis was laid on the changes in the sympathetic ganglions, and their part in the production of the clinical syndrome Lewin in his early statistics concluded that the symptoms are dependent not only on suprarenal changes but very likely on other changes, particularly in the sympathetic nerves Von Kahlden [512] in 1891 collected a number of reports of cases and added his own observations stating that he had found marked changes in the abdominal

sympathetic ganglions These consisted of atrophy of the ganglions, thickening of the capsule, mild round cell infiltration and hemorrhage In 1896, von Kahlden [513] reported on fifteen additional cases in which after careful microscopic examination he failed to find changes in the sympathetic ganglions He concluded that the changes in these structures were of no importance in the production of the clinical picture of Addison's disease Bramwell [428] in 1897 favored the sympathetic origin of the symptoms of Addison's disease Bramwell, however, had overestimated the frequency of organic changes in the sympathetic ganglions

A somewhat modified view is held by Alezais and Arnaud, who asserted that pigmentation could be accounted for only by the involvement of the sympathetic ganglions in the capsule of the suprarenal glands Laignel-Lavastine and Halbron, in a study of eight cases of tuberculosis of the suprarenal glands, found destruction of the sympathetic ganglions to a marked degree in three cases The patients in these cases did not show pigmentation of the skin The authors therefore regarded the involvement of the pericapsular sympathetic nerves as of little importance in the production of the pigmentation of the skin This is confirmed in a study of six cases of bilateral tuberculosis of the suprarenal glands without clinical symptoms of Addison's disease, the records of which were obtained from the Department of Pathology of the University of Minnesota In these six cases, marked fibrosis and lymphocytic infiltration of the capsule with involvement of the pericapsular sympathetic nerves was noted In one case, caseous necrosis involved the pericapsular region extensively

In 1903, in an anlysis of the available pathologic data Neusser concluded that the pigmentation, though an important diagnostic feature of Addison's disease, is not an integral part of the disease, but an indirect rather than direct symptom, arising through the agency of local and general disease of the sympathetic system Also, that the symptoms of Addison's disease are brought about by suppression of the functions of the suprarenal glands by the splanchnic nerves and the celiac ganglions Neusser based his conclusions mainly on the unfounded assumptions that the sympathetic nervous system controls pigmentation of the skin and that the sympathetic system is dependent on the suprarenal glands for normal nutrition and tone

From an analysis of cases of atrophy, Bittorf [9] came to the conclusion that morphologic changes in the sympathetic nerves are seldom seen and, when present are insignificant and in no way influence the symptoms

From an analysis of the recent literature, changes in the celiac plexus are noted as in table 10

It is evident from table 10 that the changes in the celiac plexus are inconstant, and that in the majority of cases the ganglions appear normal The clinical syndrome is well developed in those cases in which no demonstrable changes are present in the sympathetic ganglions It is therefore highly improbable that anatomic alterations in these structures have any part in the production of the syndrome It is more likely that, in the majority of cases, the anatomic changes in the sympathetic nerves are secondary to the changes in the suprarenal glands

GENITO-URINARY TRACT

The changes in the genito-urinary tract reported in the literature are as given in table 11 The changes are relatively few in number and can be considered only as accidental

TABLE 10—*Changes in the Celiac Plexus in Addison's Disease*

Changes	Cases
Tubercle in solar plexus (Baucke)	1
Solar plexus embedded in fibrous tissue and caseous glands (Cullan, 2 cases Flemming, Lewis and Langmead, each 1)	5
Cretaceous nodules about solar plexus (Finlayson, Withington, Laignel Lavastine and Porak)	4
Connective tissue increase and round cell infiltration (Wiesel, cases 2 and 4, Aslan, Nicolan and Petresco, Debove, Richon, Skirving and Welsh)	6
Lymphocytic infiltration (Fahr and Reiche)	1
No chromaffin tissue in solar plexus (Hedinger Loffler, 3 cases, Wiesel, cases 1 and 3 Crowell)	7
Chromaffin tissue increase (Hedinger)	1
Infiltration by lymphogranuloma (Warthin, Crowe and Jackson)	1
Amyloid deposites (Philpott)	1
No change in celiac plexus (Miller, Crouzon, Pforinger, St Thomas Hospital report [2 cases], Karakascheff [3 cases], Werdt, Fox, Bendix, Bruno, Conder [2 cases], Steinhaus, Green, Langerhans, Bernard and Heitz, Phillips, Schmidt, Simmonds [2 cases], Kreibig, Fahr and Reiche [2 cases], Brenner [2 cases])	27

HEART AND BLOOD VESSELS

Table 12 gives the changes in the heart and blood vessels as recorded in the autopsy reports As in the kidney in the heart a number of lesions of varied nature are shown, which may be considered of accidental occurrence In Furuta's case, the bacterial endocarditis may be considered the primary cause of the suprarenal injury The heart is frequently reported decreased in size and in the condition of brown atrophy This is, however, by no means constant Barker compared the heart weight and the body weight in twenty of his cases, using Smith's standard He found the weight of the heart more than 25 Gm below minimal normal in seven cases, less than 25 Gm below the minimal normal in seven cases, within normal but less than average normal in nine cases and within normal limits but more than average normal in two cases This is most likely due to the marked emaciation and loss of weight of the patient and partly to the decreased amount of work of the heart owing to the low blood pressure

ACCESSORY CORTICAL NODULES, COMPENSATORY HYPERPLASIA AND ABERRANT CORTICAL TISSUE

The rôle of accessory cortical nodules, compensatory hyperplasia and aberrant cortical tissue as compensatory mechanisms following the destruction of the suprarenal tissue is of considerable importance As these are of different origin, they will be considered separately

TABLE 11—*Changes in the Genito-Urinary Tract in Addison's Disease*

Changes	Cases
Changes in kidney (nontuberculous)	
Atrophy and congestion	1
Chronic nephritis	2
Interstitial nephritis	2
Amyloidosis	1
Granular atrophy	1
Hyperemia	1
Contracted kidney	2
Glomerulonephritis	3
Pyelonephritis	1
Congestion	6
Nephritis	2
Tubular atrophy	9
Hypernephroma	1
Cloudy swelling	1
Bladder	
Purulent cystitis	1
Genital organs	
Hypoplasia	1
Hydrocele	1
Chronic salpingitis	1
Atrophy of the testes, fibrosis	2
Atrophy of both ovaries	1
Myoma of the uterus	3
Parametrial inflammation	1

TABLE 12—*Changes in the Heart and Blood Vessels in Addison's Disease*

Changes	Cases
Marked arteriosclerosis	10
Moderate arteriosclerosis	16
Narrowing of the aorta (hypoplasia)	9
Mitral stenosis	4
Verrucous endocarditis	2
Myocardial degeneration	5
Chronic ulcerative endocarditis	1
Pericarditis	3
Endocarditis	2
Fatty degeneration	2
Hypertrophy of the heart	3
Defect in the intraventricular septum	1
Gumma of the myocardium	1
Small heart	19
Brown atrophy	16
Normal heart	42

Accessory cortical nodules or interrenal organs are of embryonic origin They are composed of small encapsulated rests of cortical cells radially arranged about a central vein The layers are usually arranged in inverted order Accessory interrenal bodies are often seen in the region of the suprarenal glands, in that of the celiac plexus, on the surface of the liver, about the genital organs, in the retroperitoneal space along the intermediary line and rarely on the surface of the

kidney Wiesel[517] stated that accessory suprarenal tissue is present near the suprarenal gland and about the vas deferens in 76 5 per cent of newborn males Hanau observed nodules along the spermatic veins and sex glands in 5 9 per cent of all children under 5 years of age

Hyperplasia of these organs in the presence of destructive lesions of the suprarenal glands were described by Kovacs, Hubschmann, Kaiserling, Karakascheff and others Karakascheff described a case in which there occurred destruction of both suprarenal glands with vicarious hyperplasia of accessory suprarenal tissue in the region of the celiac plexus Symptoms of Addison's disease were absent, and death occurred as the result of peritonitis In Kovacs' case 6 there was accessory tissue with tuberculosis of both suprarenal glands The accessory organs weighed 5 Gm Kovacs attributed the absence of symptoms to the compensatory action of the accessory nodule Kaiserling described a case in which the left suprarenal gland was absent The right was hypoplastic and tuberculous A large accessory nodule on the left side showed tuberculous involvement Also a large accessory nodule was present that was free from tuberculosis This structure was apparently adequate to maintain life for a long period without symptoms of Addison's disease In Hubschmann's case, three small accessory nodules were found along the spermatic vessels Both suprarenal glands were atrophied, and similar changes occurred in the accessory nodules In this case, symptoms of Addison's disease were clearly manifested

Compensatory hyperplasia occurs not only in accessory cortical nodules, but also in the suprarenal gland itself It has been shown both in experiments on animals and in observations on autopsy material that the suprarenal cortex is capable of undergoing marked hyperplasia Mackay and Mackay observed hypertrophy of the cortex in albino rats to the extent of 61 per cent following removal of one suprarenal gland Morelli and Gronchi and Iwabuki found hyperplasia of the zona fasciculata in rats fed on a scorbutic diet The latter observed mitotic figures in the cells of the zona fasciculata In rabbits, Muruta found hypertrophy of the zona fasciculata following a beriberi-like disease Simmonds,[199] after extirpation of one suprarenal gland in guinea-pigs and dogs observed hyperplasia of the middle zone of the intact suprarenal gland This occurred only in young animals

In man hyperplasia of one suprarenal gland in the presence of aplasia or destructive lesions in the other is occasionally seen Simmonds[500] recorded three cases in which hyperplasia of one suprarenal gland resulted from a tuberculous process of the opposite organ and one case in which the opposite organ was destroyed by an old embolic process He also observed hypertrophy of one organ as the result of

atrophy of the opposite organ Hubschmann[150] also observed in an adult a hypertrophy of the right suprarenal gland with atrophy of the left In Veit's case, symptoms of Addison's disease developed in a woman of 50 in the course of ten days The right suprarenal gland was hypertrophied and showed a venous thrombus, the left suprarenal gland was missing Marchetti observed an increase in size of the left suprarenal gland with cystic degeneration of the right Schnyder described hyperplasia and fatty degeneration of the left suprarenal gland in a man 67 years of age, in whom no trace of the left suprarenal gland could be found

In primary contracted suprarenal gland, there is found a compensatory hyperplasia of the cortex in the form of small adenoma-like nodules These were first described by Langerhans and confirmed by Fahr and Reiche, Kiefer, Lucksch, Hubschmann,[150] Kovacs, Kraus and others In these cases, symptoms of Addison's disease were present, but undoubtedly the fatal outcome was delayed for a long period by the compensatory action of these structures Less frequently, similar nodules may be seen in tuberculosis of the suprarenal gland (see page 756) These nodules may share in the retrogressive changes in primary contracted suprarenal gland and in suprarenal tuberculosis

Small aberrant rests of cortical cells are sometimes seen in the region of the capsule of the suprarenal gland They are frequently observed in primary contracted suprarenal glands and in suprarenal tuberculosis They usually consist of small clusters of cortical cells and are not encapsulated Evidence that the chromaffin tissue may undergo compensatory hyperplasia is meager Wiesel[104] described a case of compensatory hyperplasia of extrasuprarenal chromaffin tissue in the presence of destructive lesions of both suprarenal glands, in which symptoms of Addison's disease were absent As pointed out by Karakascheff Wiesel failed to give any importance to the accessory suprarenal tissue which was present in this case and which, Karakascheff held, compensated for the loss of suprarenal tissue Bloch reported a case of compensatory regeneration of the medullary tissue from sympathetic-formative cells The questionable nature of this case has already been pointed out

From the foregoing statements, it is evident that following loss of suprarenal tissue, whether through destructive processes or developmental disturbance a number of compensatory mechanisms may come into play These consist principally of hypertrophy and hyperplasia of cortical cells, chiefly of the zona fasciculata, hypertrophy of accessory cortical nodules and regeneration of cortex in the form of adenoma-like nodules and small rests of aberrant cortical cells In some of these cases, this mechanism is sufficient to maintain life and prevent symptoms of Addison's disease It is probable that the absence of symptoms in

many cases of bilateral destructive tuberculosis of the suprarenal glands is due to the presence of extrasuprarenal accessory cortical tissue that has escaped detection In cases of primary contracted suprarenal gland, regeneration in the form of adenoma-like nodules is not sufficient to prevent symptoms of Addison's disease, but it is likely that these nodules may prolong life for a considerable period

These structures are especially susceptible to injury, as shown in the cases of Kaiserling, Hubschmann, Schnyder, Veit and others Degenerative changes are frequently found in the adenoma-like hyperplasias occurring in primary contracted suprarenal glands It is supposed that these structures are rendered more susceptible to infection and injurious substances because of functional strain

(To be continued)

Notes and News

University News, Appointments, Promotions, Resignations, Deaths, etc—Clay G Huff has been appointed assistant professor of hygiene and bacteriology at the University of Chicago

Bruce K Wiseman has been appointed assistant director of the new department of medical and surgical research recently inaugurated at the Ohio State University under the directorship of Charles A Doan

C C Okell has been appointed professor of bacteriology in the University College Hospital Medical School, London

J W Miller, resident pathologist in the Charity Hospital of New Orleans, has been appointed pathologist at the Gorgas Memorial Institute and Santos Thomase Hospital, Panama City

The laboratory staff of the Charity Hospital of New Orleans consists of Rigney D Aunoy, director J L Bevan and A M Zoeller, senior resident pathologists, J M Miles and R A Robinson, Jr, junior residents, and C J Tripoli and Mary T Demotte assistant resident pathologists

G T Caldwell, formerly professor of pathology in Baylor University, Dallas, Texas, will resume his former post in the place of Morris L Richardson, resigned

At the University of Arkansas, Harvey S Thatcher has been appointed director of the departments of pathology and bacteriology, Joel Wahlin professor of bacteriology, Emmerick von Haam associate professor of pathology and Alphonse Pirnique associate professor of bacteriology and clinical pathology

International Criminologic Institute—It has been proposed to establish an international criminologic institute under the auspices of the League of Nations

Prevention of Cholera—According to *Science* the Indian Government has invited F d'Herelle, R H Malone and M H Latrivi to study the possibility of preventing cholera by means of bacteriophage

Society News—The Society of American Bacteriologists will hold its next annual meeting at the Massachusetts Institute of Technology in Boston, Dec 29 to 31, 1930

The second International Congress of Microbiology will be held in Berlin in 1933

The second International Congress of Comparative Pathology will be held in Paris, Oct 14 to 18 1931, during the French colonial exhibition The general secretary is Dr Grollet, 7, rue Gustave Nadaud, Paris

R R Spencer of the U S Public Health Service, was awarded the gold medal of the American Medical Association at its annual meeting in Detroit "for original work in preparation of a vaccine for Rocky Mountain spotted fever'

At the last meeting of the American Society of Clinical Pathologists, Kenneth M Lynch was elected president, H J Corper president-elect, Clarence I Owen vice-president and A S Giordano (South Bend, Ind) secretary-treasurer

American Journal of Cancer—By means of the financial support of the Chemical Foundation New York a new journal the *American Journal of Cancer*, will make its appearance at the beginning of 1931 under the editorship of Francis Carter Wood It will replace the present *Journal of Cancer Research* and will be the official organ of the American Society for the Control of Cancer and the American Association for Cancer Research

Abstracts from Current Literature

Experimental Pathology and Pathologic Physiology

THE CIRCULATORY MECHANISM IN ARTERIAL HYPERTENSION SOMA WEISS and LAURENCE B ELLIS, Am Heart J 5 448, 1930

In arterial hypertension a disproportion must exist between the cardiac output and the peripheral resistance Such disproportion may develop either because of an increase in cardiac output and velocity of blood flow or because of a change in peripheral resistance A study of the dynamics of the circulation in thirty patients with hypertension revealed no increase in the cardiac output per minute, the circulating blood volume, the arm to face velocity of blood flow or the mean velocity of the circulation The calculated volume of blood in the lungs was increased The peripheral resistance was increased to twice the normal, but the estimated work of the left ventricle was only 41 per cent greater than in normal subjects The mechanism of the circulation in patients with primary nephritis and secondary hypertension was found to be similar to that in patients with primary hypertension

PEARL ZEEK

PAROXYSMAL TACHYCARDIA WITH MYOCARDIAL LESIONS R H MAJOR and H R WAHL, Am Heart J 5 477, 1930

A case of paroxysmal tachycardia is described which, at autopsy, revealed an acute and chronic myocarditis of infectious origin, most marked in the auricular portions of the heart The portal of entry for the infection was thought to have been the tonsils, which were removed one year before the final attack

PEARL ZEEK

HEART STANDSTILL OF VAGAL ORIGIN A M WEDD and D C WILSON, Am Heart J 5 493, 1930

A case is described which exhibited permanent nodal rhythm, with periods of standstill of the whole heart and with a high grade bradycardia These disturbances of rhythm disappeared temporarily following exercise and the administration of atropine, thus indicating their vagal origin

PEARL ZEEK

THE DENSITY OF THE SURFACE CAPILLARY BED OF THE FOREARM SOMA WEISS and WILLIAM R FRAZIER, Am Heart J 5 511, 1930

The number of visible surface capillaries per square unit of forearm skin was found to be essentially the same in persons without demonstrable vascular disease and in patients with arterial hypertension, or arteriosclerosis Therefore, senile involutionary changes in the skin cannot be explained on the basis of an increase in the radius of cell areas supplied by the surface capillaries

PEARL ZEEK

BLOOD VESSELS AS A POSSIBLE SOURCE OF VISCERAL PAIN W K LIVINGSTON, Am Heart J 5 559, 1930

A mass of evidence is presented, including experimental, clinical, physiologic and pathologic data, to support the theory that in "a number of clinical syndromes" so-called visceral pain is caused by changes in the vascular tree

PEARL ZEEK

THE LOCAL AND SYSTEMIC EFFECTS OF ARTERIO-VENOUS FISTULA ON THE CIRCULATION IN MAN LAURENCE B ELLIS and SOMA WEISS, Am Heart J **5** 635, 1930

Two cases of traumatic arteriovenous fistula are described Such injuries may have effects on the general circulation, as well as produce the recognized local phenomena The former may be (1) increased heart rate with immediate slowing on compression of the aneurysm, (2) decreased diastolic arterial blood pressure, with increased pulse pressure, (3) a tendency toward an accumulation of blood in the venous portion of the vascular circuit, with probably an increase in total blood mass, (4) a normal or increased cardiac output, depending on the degree of fistula, and (5) a regional and frequently a generalized arteriolar dilatation

PEARL ZEEK

ANTIRACHITIC EFFECT OF WINTER SUNSHINE THROUGH CELOGLASS THEODORE S WILDER and CHRISTINE VACK, Am J Dis Child **39** 930, 1930

The technic and the results of the exposure of infants to winter sunlight which has passed through Celoglass (cellulose acetate on a wire mesh) are presented In most of the cases, a sustained rise in the phosphorus-calcium ratio begins within two weeks after the start of the exposure Roentgenologic examinations reveal a deposition of calcium in the bones in the same length of time The calcification continues to increase throughout the treatment The authors conclude that infants and children with rickets can be cured in Boston by exposing them during the winter months to sunshine transmitted through Celoglass

J N PATTERSON

ANTIRACHITIC VALUE OF WINTER SUNLIGHT IN THE LATITUDE OF 42° 21′ (BOSTON) EDWIN T WYMAN, PHILIP DRINKER and KATHERINE H MACKENZIE, Am J Dis Child **39** 969, 1930

Additional evidence is supplied by experimentation on rats to substantiate the data contained in the earlier portion of this paper regarding the effectiveness of winter sunlight in Boston in the prevention and in the cure of rickets Aside from a possibility that the sun's rays are least effective in February, and that a marked increase occurs at the end of March, we do not venture to suggest that quantitative differences have been observed Undoubtedly, with more detailed experiments the relative antirachitic potency of sunshine in each of the winter months could be plotted

AUTHORS' SUMMARY

BLOOD REGENERATION IN SEVERE ANEMIA G H WHIPPLE, F S ROBSCHEIT-ROBBINS and G B WALDEN, Am J M Sc **179** 628, 1930

A liver fraction is described which contains 65 to 75 per cent of the potency of whole liver for production of new hemoglobin in experimental anemia due to hemorrhage This fraction represents 3 per cent of the weight of the whole liver Probably a number of active substances are represented in this liver fraction Inorganic substances are important Supplementing this liver fraction with iron may increase the total output of hemoglobin The same thing is true for the feeding of whole liver plus iron, which may give maximal production of hemoglobin in experimental anemia Supplementing this liver fraction with small amounts of whole liver may increase the total output of new hemoglobin above the level due to the liver fraction alone These experimental observations will be of greater interest when compared with similar controlled observations in various human secondary anemias This liver fraction is palatable and can be taken in considerable amounts without clinical disturbance Reasons are given why liver therapy is so spectacular in pernicious anemia and notably less effective in certain secondary anemias We urge that liver therapy should not be considered inert in any type of secondary anemia until it has been given a thorough test All evidence available

points to liver and kidney as supplying the essential factors in most available form for the reconstruction of new hemoglobin and red cells in anemia

AUTHORS' SUMMARY

THE EFFECT OF SINGLE MASSIVE DOSES OF LIVER EXTRACT ON PATIENTS WITH PERNICIOUS ANEMIA MATTHEW C RIDDLE and CYRUS C STURGIS, Am J M Sc **180** 1, 1930

The observed effect of single large doses of liver extract on patients with pernicious anemia confirms the opinion, expressed by Minot, that the response to liver medication depends rather on the total amount of the active liver principle used during a certain period of time rather than on the amount consumed each day The active liver principle seems to be used in a quantitative fashion The magnitude of the reticulocyte response does not appear to be influenced, but the rate appears to be accelerated to a certain extent by the dosage of liver extract That the administration of a single large dose has an intensely stimulating effect on the hematopoietic tissues of the bone-marrow is indicated by the presence of numerous nucleated erythrocytes and immature leukocytes of myeloid origin in the blood during the first two or three days after the liver extract is given

JOHN PHAIR

A TUMOR OF THE ADRENAL GLAND WITH FATAL HYPOGLYCEMIA HORACE B ANDERSON, Am J M Sc **180** 71, 1930

The case herein reported we feel is unique in that it is the only case we can find with typical symptoms of hypoglycemia in which the only outstanding pathologic condition was a tumor of the left suprarenal gland There was also congestion of the pancreas and pituitary gland The symptoms were for a time relieved by the administration of dextrose, but later dextrose failed to relieve the symptoms Epinephrine hydrochloride was given one or two days before the patient died, without effect When the blood sugar fell below 0 07, the patient became restless and mentally confused and sweated profusely The lowest blood sugar was 0 04 per cent

AUTHOR'S SUMMARY

STUDIES IN THE ETIOLOGY OF SIMPLE GOITER IN RABBITS BRUCE WEBSTER and ALAN M CHESNEY, Am J Path **6** 275, 1930

Further investigations into the etiologic factors involved in an epidemic of simple goiter in rabbits are reported A diet which consists almost exclusively of cabbage appears to be the major etiologic factor Fecal and urinary contamination of food seemingly play no role in the present epidemic The addition of water (either tap or distilled) to the diet exerts no appreciable protective influence against the goitrogenic agent Iodine, administered orally in quantities of 7 5 mg per week, will completely protect the animal against the goiter-producing factor There is no evidence that the minute traces of iodine contained in Baltimore city tap water exert any detectable protective influence The goitrogenic agent is much more active in winter than in summer This goiter-producing factor appears to be a nutritional one and may act through the oxidation-reduction systems of the body

AUTHORS' SUMMARY

THE SIMILARITY OF THROMBO-ANGIITIS OBLITERANS AND ENDEMIC ERGOTISM JULIUS KAUNITZ, Am J Path **6** 299, 1930

Thrombo-angiitis obliterans and ergotism (gangrenous form) occur most frequently in people of the same sex, age and social status The symptoms and physical signs may be the same in both conditions The pathologic observations in both may be the same in the earlier stages The main article of diet in both conditions is rye bread Ergot is a common infection of all grains, particularly rye, in every continent of the globe

AUTHOR'S SUMMARY

INSULIN INACTIVATION BY HUMAN BLOOD CELLS AND PLASMA IN VITRO S KARELITZ, S D LEADER and P COHEN, Arch Int Med **45** 690, 1930

Human blood plasma and human blood cells inhibit the action of insulin in vitro Blood from diabetic patients and that from patients with purulent infections, serum sickness or leukemia cause greater inactivation of insulin in a given time than does normal blood This inactivation acts better at a mildly alkaline p_H and is ineffective at p_H 6 After from one to two hours' incubation at from 55 to 60 C, the various kinds of bloods lost their inactivating effect on insulin The inactivation requires time and is not present when the mixture of blood and insulin is immediately injected into the blood stream of the experimental animals

From the properties and occurrence of the inactivating substance it is believed that it is an enzyme or an enzyme-like substance

J W LEICHLITER

PANCREATIC FUNCTION S OKADA, K KURAMOCHI, T TSUKAHARA and T OOINOUE, Arch Int Med **45** 783, 1930

This is one of a series of papers dealing with the secretory function, not only of the pancreas, but of all the digestive glands In a preceding paper it was shown that hypoglycemia provokes the gastric, pancreatic and biliary secretions, and that hyperglycemia inhibits these by humoral action on the secretory centers, from which the autonomic nervous system transmits the impulses to the acting cells This phenomenon is given the name of "humoroneural regulation of the secretion of digestive juices" No such mechanism exists for the salivary secretion or for the intestinal secretion

Amino-acids stimulate the autonomic nervous center and humoroneurally provoke the gastric secretion Fats also stimulate the centers of the pancreatic and biliary secretions

When both vagi are severed, the humoroneural regulatory mechanism disappears, so that the importance of the autonomic nervous center and of the vagus nerves for this mechanism is proved

The hyperglycemia caused by the intraduodenal administration of dextrose thoroughly inhibits the secretory activity of the stomach when a series of test meals is ingested

J W LEICHLITER

THROMBO-ANGIITIS OBLITERANS (BUERGER) S SILBERT, A L KORNZWEIG and MAE FRIEDLANDER, Arch Int Med **45** 948, 1930

A study of blood volume by the dye method was made in eighty-seven persons with thrombo-angiitis obliterans, nine persons with atherosclerosis and twenty-two normal persons An average reduction of 21 per cent in blood volume was found in sixty-nine typical cases of thrombo-angiitis obliterans This fact suggests that a concentration of the blood is usually present in this disease

AUTHORS SUMMARY

CHANGES IN BLOOD DEXTROSE AND INORGANIC PHOSPHATES AFTER INTRAVENOUS INJECTION OF PARATYPHOID B FILTRATE IN DEPANCREATIZED DOGS MAUD L MENTON and HAROLD A KIPP, J Infect Dis **46** 267, 1930

In normal dogs, subcutaneous injections of paratyphoid B toxin result in an immediate rise in blood sugar and in inorganic phosphates followed by a return to normal in both constituents in from four to six hours Large amounts of toxin produce a progressive rise in inorganic phosphates and an early hyperglycemia followed by a fatal hypoglycemia

In depancreatized dogs, subcutaneous injections of this toxin cause a progressive rise in inorganic blood phosphates together with an early hyperglycemia followed by a fatal hypoglycemia Large doses of toxin produce a progressive increase in inorganic blood phosphates and a progressive hypoglycemia ending in death

AUTHORS SUMMARY

THE MECHANISM CONTROLLING MIGRATION OF THE OMENTUM C B SCHUTZ, Surg Gynec Obst **50** 541, 1930

To the previous theories of gravity, intestinal peristalsis, and chemotatic attraction the author adds the following Peritoneal irritation results in active hyperemia of the omentum This is followed by serous and cellular exudate, and the vessels lose their tortuosity with resultant gradual spreading out of the omentum in all directions but when it comes in contact with the focus of irritation it adheres to it The spreading out of the omentum is attributed to the straightening out of the blood vessels due to the increased blood pressure The omentum, being attached to the arteries, is pulled along

RICHARD A LIFVENDAHL

CAROTENE AND VITAMIN A THE ANTI-INFECTIVE ACTION OF CAROTENE H N GREEN and E MELLANBY, Brit J Exper Path **11** 81, 1930

Tests on a specimen of carotin (melting point 174 degrees) showed that in growing rats this substance had the property of conferring complete immunity to the development of spontaneous infection In animals on a diet free from vitamin A and carotin, septic foci invariably developed and the animals died When carotin was given in the food, the amount of protection conferred on the animals was generally proportional to the amount of carotin eaten With the basal diet used in these experiments, 0 005 mg of carotin gave only slight immunity and 0 01 mg partial immunity, whereas 0 02 mg and greater amounts gave complete or practically complete immunity

AUTHORS' SUMMARY

OVARIAN TRANSPLANTATION JOHN H HANNAN, J Obst & Gynæc Brit Emp **36** 569, 1929

Hannan reports the results of his study of ovarian transplantation conducted in two series of rabbit to rabbit, and cat to rabbit, after the recipients had been spayed previously The site chosen for transplantation was an area bounded by the erector spinal muscle and the last rib, this was preferred because of its rich vascularity, accessibility and the landmarks that render easy the removal of the transplant for study Removal was done after two, four, six, eight or twelve weeks There was "a rapid degeneration followed by a total disappearance of all traces of the transplant including necrotic debris No period was observed in which the ovarian tissue regenerated or even remained stationary in amount, and the degenerative changes, which were observed as early as 14 days after transplantation, progressed steadily throughout the period of survival of the transplant On the evidence, therefore, the case for ovarian transplantation as a justifiable procedure must fail"

A J KOBAK

THE TOXICITY OF IRRADIATED ERGOSTEROL J B DUGUID, M M DUGGAN and J GOUGH, J Path & Bact **33** 353, 1930

Viosterol (irradiated ergosterol) is more toxic for rats fed on a synthetic vitamin-free diet of high calcium content than for rats fed on a normal diet of bread and potatoes In preparing a synthetic diet for use in investigating the toxicity of viosterol, attention must be paid to the calcium content of the diet Should casein be used in the diet, precautions must be taken to ensure that the calcium content of the casein does not unduly raise the total calcium content of the diet

AUTHORS' SUMMARY

VISUALIZATION OF EMBOLUS IN EXPERIMENTAL PULMONARY EMBOLISM B MARTIN, Arch f klin Chir **155** 577, 1929

The femoral vein in dogs was exposed and compressed, below the compression a solution was introduced consisting of iron chloride 1 cc, 0 9 per cent sodium chloride solution 1 cc and from 15 to 20 Gm of barium sulphate A rapid coagu-

lation of the blood resulted, and on removal of the compression the clot was carried on, while because of the barium its course could be followed accurately by means of the roentgen ray The method should be of value in experimental study of pulmonary embolism

THE EFFECT OF AN EXCLUSIVE MEAT DIET FOR ONE YEAR W S McCLELLAN, Klin Wchnschr 9 931, 1930

The health of two men was not impaired by an exclusive meat diet for one year

AUTHOR'S SUMMARY

EXPERIMENTAL CHRONIC COPPER INTOXICATION F OSHIMA and P SIEBERT, Beitr z path Anat u z allg Path 84 106, 1930

This is a brief report of a small series of experiments undertaken in an attempt to produce hemochromatosis experimentally by chronic copper intoxication, as reported by Mallory Nine rabbits were given 200 mg of copper acetate daily by mouth, and three rabbits were given zinc acetate in similar dosage The duration of the administration varied from 61 to 249 days The copper content of the livers of the experimental animals varied from 52 to 170 mg per kilogram of liver, as compared with an average of 6 mg per kilogram in six normal control rabbits The liver cells contained much pigment, the amount being greatest in the peripheral zone of the lobules The pigment was not soluble in alkalies and was not stained by fuchsin The necrosis of liver cells and the cirrhosis described by Mallory were not observed Although the authors were not able to reproduce the changes noted by Mallory, they are convinced that Mallory was able to cause hemachromatosis experimentally, but they believe that some unknown factor in addition to copper is concerned in the process

O T SCHULTZ

EXPERIMENTAL ACUTE ALCOHOLIC GASTRITIS A GOTTSCHALK, Beitr z path Anat u z allg Path 84 131, 1930

To study the early stages of gastritis induced by an exogenous factor and as a contribution to the theory of the Aschoff school that peptic lesions result from the action of gastric juice on living tissue rather than on tissue dead as the result of a vascular lesion, Gottschalk introduced 60 per cent alcohol in a dosage of 20 cc into the empty stomach in cats by means of a stomach tube The animals were killed at intervals varying from one-half hour to five days, the stomach was immediately fixed, and submitted to microscopic examination All of the animals became severely intoxicated from the amount of alcohol used, and as a rule, during the interval between the administration of the alcohol and death, they refused food The most marked changes were noted in the dependent portion of the fundus The pyloric portion was markedly contracted, so that a relative protection was afforded this portion of the stomach Great importance is attached to the fact that the resulting lesions were focal They occurred usually on the crests of the mucosal folds, but the furrows between the folds did not escape The earliest change observed was swelling of the epithelium, with localized desquamation of the latter, the desquamation being held to be due to the mechanical action of the swollen epithelium about the area of denudation The capillaries about the superficial erosions were engorged and contained an increased number of leukocytes, evidence of an active inflammatory reaction The exposed supporting tissue was also swollen as the result of the action of the alcohol, but was not killed Death of the exposed connective tissue was caused by the caustic action of the gastric juice, and the injured tissue was digested In this way there were produced crater-like erosions that might extend down to the muscularis mucosae Healing occurred by the epithelialization of the defect The process of healing was identical with that which Konjetzny and Puhl had described for the human stomach The author therefore concludes that erosions of the human gastric mucosa, from which peptic ulcers may result, are due to damage done to the mucosa from its surface

O T SCHULTZ

MALE SEX HORMONE J FREUD, S E DEJONGH, ERNST LAQUEUR and A P W MUNCH, Klin Wchnschr 9 772, 1930

The authors have confirmed the existence of a male sex hormone The growth of the comb of a castrated rooster is used as a test for the presence of the hormone, also that of normal and castrated hens, the diminished involution of the genitalia of adult castrated rats and the increased development of the genitalia of young rats The male sex hormone specifically affects the comb of the chicken regardless of its sex

AUTHORS' SUMMARY

THE SIGNIFICANCE OF THE SKIN IN SALT AND WATER METABOLISM STEFAN GEREB and DANIEL LASZLO, Klin Wchnschr 9 775, 1930

The influence of an injection of hypertonic sodium chloride solution on elimination of sodium chloride in the urine, and the relation of the chlorides of blood and skin were investigated A considerable amount of the injected sodium chloride is taken into the skin and is retained four hours after the injection Pituitary causes a marked excretion of sodium chloride in the urine and a diminished, sometimes entirely absent, absorption of sodium chloride by the skin, while the blood chlorine corresponding to the skin blockade at first increases Because of the increased elimination of chlorine with administration of pituitary, the blood chlorine returns to normal sooner than otherwise Pituitary seems thus to affect also the extrarenal tissues

EDWIN F HIRSCH

CULTURES OF HUMAN SKIN KAETHE BORNSTEIN, Klin Wchnschr 9 1119, 1930

Explants of skin from children were cultured in cover glass preparations and in flasks The 372 cover glass cultures were as follows skin 108, moles 129, condylomas 66 and embryonal skin 69 The medium was autoplasma or homoplasma from children and young adults, some mixed with chicken plasma and, to some extent, with chicken embryo extract (in a few cultures also with rat and mouse embryo extracts and human placenta extract) Human embryo extract was used only with embryo skin explants The cultures were made on the surface of the mediums Skin explants were kept in good living condition for ninety days, in which there was a growth pause of thirty-eight days (in the dark at room temperature) Moles and condylomas grew like skin explants

EDWIN F HIRSCH

LIVER GLYCOGEN AND THE MENSTRUAL CYCLE C KAUFMANN and O MUHLBOCK, Klin Wchnschr 9 1170, 1930

The livers of healthy women during menstruation are depleted of glycogen or have less mobile glycogen

AUTHORS' SUMMARY

Pathologic Anatomy

DISPLACEMENT OF THE LEFT NIPPLE IN MITRAL STENOSIS SIDNEY P SCHWARTZ, Am Heart J 5 344, 1930

In healthy children and in male adults both nipples are usually on the same level In patients with mitral disease of the heart, who have had rheumatic fever in childhood, the dynamics of the valvular lesion cause a deformity of the chest in the region of the left half of the sternum and the adjacent second, third and fourth costosternal junctions Because of this, an upward and outward displacement of the left nipple results This sign is not present in patients with isolated aortic insufficiency or congenital heart disease It was present in over 90 per cent of 200 consecutive patients with mitral stenosis examined at the Montefiore Hospital within the last two years

AUTHOR'S SUMMARY

COMPLETE OCCLUSION OF BOTH CORONARY ORIFICES T LEARY and J T WEARN, Am Heart J 5 412, 1930

Two cases of essential closure of both coronary orifices are reported The lesions indicated a slowly progressive process that had probably taken at least months to reach the point of essentially complete closure No evidences of fatty change, myocarditis or repair were found in the heart muscle The only adequate explanation of the ability of these patients to live and work rests on a belief that the thebesian veins supplied the needed blood

THE ANATOMIC SUBSTRATUM OF THE CONVULSIVE STATE WALTHER SPIELMEYER, Arch Neurol & Psychiat 23 869, 1930

In so-called genuine epilepsy, the usual lesion described is a loss of ganglion cells in Ammon's horn and a corresponding increase in glia elements This so-called gliosis is the terminal stage It differs from what is seen in the early stage of genuine epilepsy In fresh foci, many ganglion cells are lost, or are replaced by proliferated rodlike cells now known as Hortega's cells, or appear as so-called "ischemic" ganglion cells These do not stain with the Nissl stain, but stain well with hematoxylin and eosin The cell body is narrow, and the nucleus is disintegrated Similar changes — sclerosis, loss of Purkinje's cells, shrinkage of the molecular zone — are present also in the cerebellum The earliest changes show here as a branchlike network of proliferating glia cells The fresh changes were observed by Spielmeyer after epileptic seizures and states regardless of the type or cause of the epilepsy Genuine and symptomatic forms of epilepsy caused similar changes The etiologic factor — trauma, tumor, Huntington's chorea, etc, did not influence them In Spielmeyer's opinion, the main cause of the changes is in the vascular disturbances, for he found similar changes in Ammon's horn in a case of tuberculous endarteritis Here they were caused by an organic obstruction to the circulation The vascular, vasomotor disturbances, not organic, producing an impediment to the circulation are the cause of the changes in Ammon's horn and the cerebellum in epilepsy These two organs are singled out because their blood supply is naturally poor

GEORGE B HASSIN

THE EFFECTS OF ANEMIA ON THE CEREBRAL CORTEX OF THE CAT EDWIN F GILDEA and STANLEY COBB, Arch Neurol & Psychiat 23 876, 1930

Gildea and Cobb tried to study, among other phenomena, the condition of the cerebral ganglion cells in experimental anemia Young cats were employed, and light ether anesthesia was used while the blood vessels were being exposed and ligatured The occlusion of the vessels was effected by traction on all ligatures, a procedure which at once produced complete coma The anemia was considered severe when the tissue in general appeared bloodless and when the animals ceased breathing within from one to two minutes after occlusion of the vessels and had convulsions during the period of occlusion (the ether anesthesia was not deep) The brains were hardened in a diluted solution of formaldehyde, U S P (1 10), and stained with cresyl violet, scarlet red and Hortega's silver carbonate methods The changes varied according to the length of time the animals survived, duration of the anemia and other factors The lesions were "areas of devastation" (in animals that survived more than twenty-four hours) in which, owing to cell "necrosis," cells had ceased to be or were abnormal — shrunken, homogeneous, pyknotic, with the nuclei dark, resembling Spielmeyer's ischemic nerve cell change, the oligodendroglia cells were increased, the capillaries became more conspicuous, especially involved were the third and fourth lamina Other changes showed in the processes that appeared like "icicles" or were swollen (especially in animals that lived from three to eleven days), vacuolated or fat-containing cells were rare, more common was satellitosis The meninges and the perivascular spaces were usually dilated, with some lymphocytic infiltration and fat globules Abnormal oligodendroglia were absent The shrunken cells commonly considered as repre-

senting a chronic lesion were found to show an acute change, while the swollen cells, considered as showing acute changes, are looked on by Gildea and Cobb as manifesting a chronic condition The conclusions are that the changes though present are "subtle,' that none can be considered pathognomonic of cerebral anemia and that ten minutes of cerebral anemia is sufficient to impair cortical cells permanently

GEORGE B HASSIN

OCULAR CHANGES IN EXPERIMENTAL BOTULISM CHARLES M SWAB, Arch Ophth **3** 437, 1930

In experimental botulism in rabbits the following changes were observed in the nuclei of the third and fourth cranial nerves round cell infiltration, lymphoid cells packed into parenchyma, extravasation of red blood cells, migration of lymphoid cells, thickening of capillary endothelium, neuronophagia, chromatolysis, satellitosis, necrobiosis, nuclear displacement, nuclear shrinking, vacuolization, powdery granulation of Nissl bodies and complete disintegration of ganglion cells and increase of neuroglia Similar changes were observed in other parts of the midbrain The meninges showed small round cell infiltration beneath the ependymal lining of the third ventricle, diffuse round cell infiltration and massive extravasation of erythrocytes into the meninges The meningeal vessels were distended with red corpuscles Thrombosis was not frequent in the midbrain The optic nerve showed focal infiltration in the parenchyma, diffuse increase of neuroglia and round cell infiltration of pial and arachnoidal sheaths In the optic tract were round cell infiltrations, extravasation of erythrocytes, emigration of lymphoid cells and stagnation of blood The retina showed fat formation in the ganglion cell layer, pyknosis, chromatolysis and vacuolization of ganglion cells, powder-like reduction of pigment granules, engorgement of vessels with red corpuscles, and stagnation of blood

CHARLES WEISS

BONE CHANGES IN HYPERPARATHYROIDISM E L COMPERE, Surg Gynec Obst **50** 783, 1930

A meaty nodule, 1 by 1¾ cm, reddish, semielastic and smooth, surrounded by a smooth capsule, was removed from the vicinity of the lower pole of the left lobe of the thyroid gland in a woman 59 years of age Osteoporosis of the calvaria, osteoporosis and bowing of the femurs, thinness of the cortex of the shafts of the long bones, rarefaction of the pelvic bones and sinking-in of the lumbar bones were still present ten months after the extirpation However, postoperatively the calcium levels of the blood and urine were lowered, the phosphorus was increased to normal, and the general condition of the patient was improved The clinical syndrome in this patient can hardly be regarded as a compensatory hyperplasia of the parathyroid glands, because another parathyroid gland removed from the same side showed normal structure

RICHARD A LIFVENDAHL

THE ABSORPTION AND TRANSFERENCE OF PARTICULATE MATERIAL BY THE GREAT OMENTUM G M HIGGINS and C B BAIN, Surg Gynec Obst **50** 851, 1930

Graphite particles injected into a subcutaneous pouch of the anterior abdominal wall containing the distal two thirds of the omentum of the cat took the following course along the mesothelial surfaces, in the histiocytes about the blood vessels of the omentum, and in forty-eight hours from the hepatic ligaments and the lesser omentum to the coronary ligament and then to the central tendon of the diaphragm, from here, by way of the lymphatics on the pleural surface, into the sternal lymph channels and the anterior mediastinal lymph nodes Thus there are two abdominal drainage systems, the one from the gastro-intestinal tract through the mesentery to the cisterna and the other from the omentum and diaphragm through the anterior mediastinum to the cervical lymph ducts

RICHARD A LIFVENDAHL

FAT NECROSIS OF THE BREAST G HADFIELD, Brit J Surg **17** 673, 1930

Fat necrosis of the breast mimics the clinical signs of carcinoma, in that the overlying skin is adherent and shows the peau d'orange appearance and the lump is hard and in most cases moderately adherent to the underlying tissue The lesion is most frequently composed of a cystic cavity filled by yellow or brown fluid surrounded by a wall of chalky appearance with lipophages, lymphocytes, multinucleated giant cells containing isotropic crystals, and many fibroblasts in the periphery

The process is regarded as a slow aseptic saponification of neutral fat by blood and tissue lipase analogous to pancreatic fat necrosis Some of the forty-five cases recorded occurred after trauma in the form of direct injury or following subcutaneous injections of physiologic solution of sodium chloride or subsequent to radical operations on the breast for carcinoma, in cases of the latter the lesions have been regarded as being a recurrence of carcinoma

RICHARD A LIFVENDAHL

TUBERCULOUS MYOCARDITIS J G THOMSON, J Path & Bact **33** 259, 1930

In a man, aged 41, the subject of uveoparotid fever (Heerfordt), the following lesions were found post mortem tuberculosis of the lungs apparently spread by both the blood and the lymph, tracheobronchial and mediastinal glandular tuberculosis and massive tuberculous infiltration of the septum and of the greater part of the wall of the left ventricle of the heart Microscopically, there was present a tuberculous arteritis, which is suggested as a factor in the wide extent of the lesion

AUTHOR'S SUMMARY

ON TUBERCLE FROM INOCULATION OF THE IRIS WITH REFERENCE TO RETICULO-ENDOTHELIAL CELLS K ALBRICH, Arch f Ophth **123** 694, 1930

The author's former experiments on animals confirmed the results of other investigators, showing that the reticulo-endothelial cells have the same significance in the inflammation of the eye as in that of other organs, viz, the ingestion of tissue debris This they perform as polyblasts (macrophages) and not in their original form Albrich has watched the transition of histiocytes into macrophages in early foci of tuberculous infections of the iris He describes the cell arrangement in such foci This shows to best advantages in the second week of a tubercle bacillus infection in the eye of a rabbit, especially in those cases in which some of the fluid mediums also was introduced into the eye, setting up a severely toxic reaction The center of this focus consists of white blood cells with lobular nuclei, mostly in the stage of disintegration, and covered with a mantle of carmine-containing polyblasts (macrophages) On the outer edge are numerous elongated histiocytes, provided with offshoots containing a great number of intensely red carmine granules These cells lie between fibroblasts that are already beginning to proliferate and, approaching the center, change into a zone of larger epithelioid-like cells which still preserve their histiocyte character Toward the center, as well as within it, are large multiform polyblasts loaded with vacuoles and tissue granules which have completely lost their histiocyte character but still contain pale carmine granules The process is exactly that found in a conjunctival abscess The rôle of other cells is not clear, but he found cell pictures that represented the transformation of lymphocyte into monocytoid cells, which would bear out Maximow's theory

Diffuse inflammations cannot be clearly analyzed as to cell behavior, arrangement and significance, but even in such conditions there are pronounced nodules with caseous nucleus where only polyblasts are assembled in the region of cell detritus

The author tried to eliminate toxic reaction by using washed bacilli from dry medium The subjects were white rabbits which had been given a week's prepara-

tory treatment with carmine If the inoculation takes, the bacilli can be found at any time, in the iris, several hours after infection, and very soon also in the ciliary body This does not indicate an infection by way of the blood, for the bacilli were introduced into the anterior chamber in much greater numbers Acute irritation could not be avoided The author thinks that he has discovered the origin of the carmine-containing cells, morphologically and positionally, they may be adventitial cells Hence there is no essential difference as regards kind and disposition of cells in the toxic specific inflammation and the specific inflammation with least possible irritation (washed bacilli) The carmine-containing polyblasts are derived from the neighboring iris, where numerous similar cells and histiocytes are found Their transition into granular tissue is easily followed The neighboring corneal tissue remains unchanged

CHARLES WEISS

LESIONS OF THE PANCREAS IN FATTENED SWINE J KUP, Beitr z path Anat u z allg Path **83** 64, 1930

The relatively frequent association of diabetes and obesity has led French writers to speak of a "diabete gras" The amount of interlobular adipose tissue in the pancreas of obese persons may be so great as to warrant the designation of pancreatic lipomatosis Balo determined an actual diminution in the amount of parenchymatous tissue in the fatty pancreas of the obese, and Truhart found necroses in the interstitial fat of 50 per cent of such pancreases examined by him The nature of the relationship between such pancreatic changes and diabetes in the obese is not easy to determine Similar fatty infiltration and fat necroses have been seen in the pancreas of a number of species of domestic animals and especially in swine fattened for slaughter A variety of domestic swine prepared for market in Hungary appears to be particularly prone to such changes Kup examined the pancreases of 110 animals of this variety that had been fattened for slaughter and 61 lean animals of the same variety that had not undergone the fattening process The animals were healthy market swine, and the absence of duodenitis or intestinal catarrh was noted Multiple necroses were detected in the pancreas of 41 8 per cent of the fattened swine, whereas no necroses were seen in the pancreas of the lean animals The older and the fatter the animal, the larger was the number of necroses The author believes the sequence of changes to be as follows deposition of fat in the interlobular tissue, separation of the pancreatic lobules by adipose tissue, pressure on the lobular ducts, stasis of secretion, ascending infection, focal parenchymatous necrosis, liberation of lipase and focal necrosis of fat That diabetes is not observed in such swine as the result of the pancreatic lesions is explained by the short life of the fattened animal

O T SCHULTZ

VITAL STORAGE IN THE CONNECTIVE TISSUE IN LOCAL ACTIVE HYPEREMIA AND INFLAMMATION N KUSNETZOWSKY, Beitr z path Anat u z allg Path **83** 649, 1930

The vital storage of colloid substances by the cells of the reticulo-endothelial system is influenced by a number of extracellular factors, in addition to factors inherent in the cells Among these extracellular factors are the path of administration of the material, whether intravenous, subcutaneous or intraperitoneal, the material being stored in largest amounts by those cells with which it first comes in contact, the mechanics of the local circulation of the various tissues and organs, and the degree of dispersion of the colloid material The last named factor makes itself manifest in differences in the storage of a finely dispersed material like trypan-blue and a coarsely dispersed one like india ink The author has previously published the results of experiments undertaken to study the effects of local active hyperemia and inflammation on the vital storage of trypan blue The present contribution presents the results of similar experiments with india ink Rabbits were used To cause local hyperemia, a part of the hind leg was encased in a copper jacket through which water at a temperature of 46 to 48 C was circulated

for a period of forty minutes Twenty minutes after the beginning of the application of heat, dilute india ink was injected into the ear vein The skin and subcutaneous tissue of the warmed area, similar tissues from the corresponding area of the opposite leg and portions of the internal organs were removed at varying intervals and subjected to microscopic examination Local aseptic inflammation was set up by implanting in the subcutaneous tissue of a limb or in the intermuscular tissue of the abdominal wall bits of sterile sponge In some experiments, the sponge was saturated with turpentine In other experiments, local inflammation was produced by cauterization of the skin India ink was injected intravenously during the acute stage of the inflammation or at varying intervals thereafter The tissues were removed for microscopic examination at varying periods after the injection of the carbon suspension Local active hyperemia caused the early deposition of conglutinated carbon particles on the inner surface of the endothelium of the capillaries and venules of the hyperemic tissues A similar condition was not seen in the control tissues The material was attached to the surface of the endothelial cells and was not stored by them, the author disagreeing with those who maintain that ordinary endothelium has the property of phagocytosing carbon particles The material did not pass through the capillary walls and was not seen in the extracapillary tissues When the tissue was removed at longer intervals after the injection, most of the particles of ink had been removed from the surface of the endothelium and had been transported elsewhere by the blood stream In local inflammatory tissues, the observations were much the same as in hyperemia if the tissue was removed in the early stages of the inflammatory process The carbon particles adhered to the inner surface of the capillary endothelium, but were not engulfed by the latter and did not pass out into the surrounding tissues Even during the early stage of active leukocytic emigration, little carbon was seen outside the vessels As the latter became more permeable, however, the carbon particles made their way through the walls of the vessels and were taken up by the polyblasts in the tissues outside the vessels A transformation of endothelium into polyblasts was never seen by the author India ink stored in polyblasts that had come to rest in the scar tissue could be seen at prolonged periods after the acute stage of the inflammation If the india ink was injected during the later, healing stages of the inflammatory process, carbon particles stored in polyblasts could also be seen in the extravascular connective tissue, but the amount was much less than if the injection was made during the acute stage The storage of carbon by the cells of the extravascular tissue of an inflamed area depends apparently on the degree of permeability of the vessels caused by the inflammation Trypan blue passes through the vessels much more readily than do the relatively coarse particles of india ink

O T SCHULTZ

ECHINOCOCCUS CYST OF THE VERTEBRAL COLUMN G GERLACH, Centralbl f allg Path u path Anat **47** 112, 1930

A man, 59 years old, suffering from a transverse myelitis in the region of the eleventh thoracic vertebra, died of ascending cysto-ureteropyelonephritis At necropsy, an echinococcus cyst, 5 5 cm by 5 by 1, was found in the body of the eleventh thoracic vertebra, compressing the spinal cord Nineteen years previously the man had been operated on for a similar cyst of the left side of his back at about this level, but not until seven years before his death did any evidences of compression of the spinal cord appear

GEORGE RUKSTINAT

A PAPILLOMA OF THE PULMONARY VALVE H WEBER, Centralbl f allg Path u path Anat **48** 49, 1930

In a man 38 years old dying four days after developing symptoms of pneumonia of the left lower lobe, a papillary mass, 11 by 6 by 5 mm, was found on the front pulmonary cusp, 2 mm to the right of the nodule of Arantius From serial sections it was decided the mass originated from the subendocardial connective tissue

GEORGE RUKSTINAT

TUBERCULOUS SPLENOMEGALY G LEIDEL, Centralbl f allg Path u path Anat **48** 54, 1930

Leidel thinks that the four types of tuberculous splenomegaly suggested by Lubarsch, namely, indurated, hemorrhagic, diffuse miliary and large nodular, should be supplemented by a tumor-like granulating form

GEORGE RUKSTINAT

WERLHOF'S DISEASE G GERLACH, Centralbl f allg Path u path Anat **48** 81, 1930

Gerlach reports extensive studies of the organs of a 14 year old girl dying from essential thrombocytopenia There were extensive hemorrhages into the kidney pelves, ovaries and serous membranes and hemorrhagic infarction of the auricles From studies of the bone-marrow the disappearance of platelets seemed ascribable to marked alterations of the giant cells of the bone-marrow These varied from one to ten times the size of a myelocyte and had nuclear changes, such as mulberry-like contours and clumping of chromatin

GEORGE RUKSTINAT

PECULIAR GROWTH ON THE CRANIUM FROM TRAUMA W SCHELLENBERG, Frankfurt Ztschr f Path **38** 319, 1930

On the cranium of a man, aged 76, was a crateriform growth the inner margin and cavity of which was formed by remnants of periosteum Below the periosteum, between the outer and inner tables, was a pale red, homogeneous connective tissue containing bone splinters and fragments There was a history of trauma to the head some twenty-six years earlier, and the growth is interpreted as the result of fracture of the external table followed by growth of connective tissue with central shrinking

CHOROIDITIS ALBUMINURICA A FUCHS, Zentralbl f d ges Ophth **22** 785, 1930

The author discusses the various choroiditic pigmentation centers that occur in nephritis and nephrosclerosis, as well as in retinitis albuminurica These include the small peripheral discolorations, large retinochoroiditic foci, the black foci with paler margin that lie peripherally described by Elschnig, and the beadstring pigmented streaks described by Siegrist Fuchs made histologic examination of such a black retinochoroiditic focus in a patient in whom the Elschnig and Siegrist types of foci were present simultaneously Usually albuminuric choroiditis has a different cause than albuminuric retinitis, viz, arteriosclerosis and periarteritis, the causative agent of albuminuric retinitis is not known The choroiditic foci have a great significance in cases of nephritis and nephrosclerosis — they show the poor condition of the choroidal vessels and the serious condition of the patient In the discussion of this paper, Pascheff reported a case of choroiditis serosa during pregnancy The patient's symptoms disappeared without treatment after delivery

CHARLES WEISS

THE STRUCTURAL CHANGES IN METHYLALCOHOL-AMBLYOPIA A E MACDONALD, Zentralbl f d ges Ophth **22** 791, 1930

Reports are made on material from three cases of methylalcoholic poisoning with symptoms of blindness apparent before death The central scotoma and blindness are due to the toxic degenerative changes which the ganglionic cells undergo The changes that arise later and that lead to optic atrophy are due to the progressive degeneration of the nerve fibers, the result of the lesion of the ganglionic cells Ganglionic cell changes in other parts of the body are not as pronounced as those in the eye, the effect of light falling directly on the ganglionic

cells in the retina may play a distinctive rôle Further observations are necessary Injection of formaldehyde into the cavity of the eye should be made immediately after death, and investigation of fatty degeneration proximal to the point of exit of the optic nerve in the retinal portion is recommended

CHARLES WEISS

Pathologic Chemistry and Physics

HYDRION CONCENTRATION AND EDEMA IN PERFUSED HEARTS OF RABBITS J M ORT and J MARKOWITZ, Am J Physiol **94** 60, 1930

Perfusion experiments with Ringer-Locke's solution of varying hydrogen ion concentration on excised hearts of rabbits indicated that there were many points in common between such isolated but working tissues and simple hydrophilic colloids, as the former, like the latter, showed increased imbibition in conditions of increased acidity

H E EGGERS

PLASMA PROTEINS H J WIENER and R E WIENER, Arch Int Med **46** 236, 1930

The two fractions of the serum protein, the albumin and globulin and the plasma fibrinogen together with other blood constituents significant of the clinical condition have been determined in diabetes mellitus, benign glycosuria, localized and generalized infections, diseases of the liver and the gallbladder and in renal conditions The methods used and the physiologic concentrations determined by these methods are stated The plasma proteins are within the physiologic limits in diabetes mellitus and in benign glycosuria In infections the albumin is decreased, slightly in mild cases and decidedly in the more severe infections The fibrinogen is increased, even in slight infections which do not call forth an increased globulin concentration In the more severe infections the globulin is increased, and the increase parallels the severity of the condition In cirrhosis of the liver the albumin is decreased and the globulin is increased The changes in the serum protein concentrations, however, are not so marked as in the infectious conditions The fibrinogen is a low normal or decreased In jaundice without elevation of temperature, the serum proteins are normal or increased, the albumin is generally within the normal limits and the globulin is increased The fibrinogen remains within the normal limits In cholecystitis and in jaundice due to the use of arsphenamine the picture is similar to that found in infections In chronic, glomerular nephritis, in the absence of an infection, the serum proteins are slightly reduced, especially the albumin fraction The fibrinogen is often slightly increased In acute nephritis the changes found are the same as in infections In nephrosis the albumin is materially decreased, the globulin is normal and the fibrinogen is much increased The significance of the changes in the protein concentrations and their bearing on questions of site of formation, port of entry and functions are discussed The importance of complete chemical analytic studies and the recognition of complications which may mask the results expected from the pathologic condition studied are evidenced The difference in relationship of globulin to fibrinogen in infections and disturbed hepatic function is pointed out The diagnostic and prognostic value of changes in the albumin-globulin quotient and in the globulin-fibrinogen quotient is discussed

AUTHORS' SUMMARY

POSTMORTEM BLOOD CHEMISTRY IN RENAL DISEASE S H POLAYES, E HERSHEY and M LEDERER, Arch Int Med **46** 283, 1930

From a postmortem study of the creatinine and urea contents of the blood specimens in 100 cases, the following conclusions may be made 1 Blood creatinine determinations are often helpful as an aid in determining the status of the renal function during life 2 The urea values are not as helpful as the creatinine

figures 3 A creatinine content of 4 mg or more per hundred cubic centimeter of blood obtained post mortem indicates marked creatinine retention during life and therefore severe renal insufficiency

AUTHORS' SUMMARY

FIXATION OF A METAL IN INFLAMED AREAS VALY MENKIN, J Exper Med **51** 879, 1930

Colloidal iron or ferric chloride injected into the inflamed peritoneal cavity is fixed in the cavity and fails to reach the retrosternal lymphatic nodes, whereas, in the absence of inflammation, iron accumulates in these nodes and becomes demonstrable by the Prussian blue reaction Quantitative studies show that after intraperitoneal injection of ferric chloride the retrosternal lymphatic nodes of animals with normal peritoneal cavities contain approximately 56 per cent more iron than do the nodes of animals with inflamed peritoneal cavities Ferric chloride injected into the circulating blood enters an inflamed area in the skin, and the inflamed tissue gives the Prussian blue reaction Quantitative determinations show that the amount of iron in inflamed areas is much greater than that found in inflamed areas of animals that have received no iron

AUTHOR S SUMMARY

THE BLOOD CHEMISTRY OF AN ACUTE TRYPANOSOME INFECTION RICHARD W LINTON, J Exper Med **52** 103 1930

The carbon dioxide capacity of the serum is markedly lowered early in infection with *Trypanosoma equiperdum* The nonprotein nitrogen and uric acid constituents of the blood are increased in the terminal stages The kidneys also show terminal degenerative changes The cholesterol remains unchanged throughout Lecithin is markedly increased, most of the observations showing a 20 to 50 per cent rise in this substance Liver glycogen is lower than normal in the early stages and could not be demonstrated in the later stages of the infection The blood sugar remains normal until a very late period in the disease

AUTHOR'S SUMMARY

CHANGES IN THE SPINAL FLUID FOLLOWING INJECTION FOR SPINAL ANAESTHESIA A H IASON, M LEDERER and M STEINER, Surg Gynec Obst **51** 76, 1930

Comparison of the spinal fluid before and twelve hours after spinal anesthesia showed a polymorphonucleosis as high as 800 per cubic millimeter in eleven of thirty-one cases In twenty instances there was an increase in the sugar content varying from 7 to 135 2 per cent There was no change in the albumin, globulin or colloidal gold curves No correlation was present between the occurrence of postanesthesia sequelae and the changes observed in the spinal fluid

RICHARD A LIFVENDAHL

BLOOD PHOSPHORUS IN HEALTH AND DISEASE H D KAY, Brit J Exper Path **11** 148, 1930

In normal human blood, the usual methods of analysis show no detectable quantity of nucleic acid phosphorus in the red cells In cases of disease in which there is a marked increase above normal in the percentage of reticulocytes in the blood, small, but quite definite, amounts of nucleic acid phosphorus, roughly proportional in quantity to the extent of the reticulocytosis, have been demonstrated It may be concluded that, whatever the nature of the reticulum itself, the reticulocytes occurring in such diseases probably contain nucleic acid, and may therefore be looked on as red cells from which the whole of the nuclear material has not been extruded

AUTHOR'S SUMMARY

Microbiology and Parasitology

THE INFLUENCE OF SURFACE TENSION ON THE GROWTH OF THE TUBERCLE BACILLUS FRANK B COOPER, Am Rev Tuberc **21** 354, 1930

No optimum surface tension was noted at which growth was more profuse or more rapid than on an untreated medium Progressively increasing amounts of sodium soap of castor oil with the accompanying decrease in surface tension caused a corresponding inhibition of the rate of growth Throughout the range of surface tension of from 72 4 to 35 4 dynes, growth was always at the surface of the medium and in typical pellicle formation There was never any indication of growth beneath the surface

H J CORPER

THE INFLUENCE OF UNSATURATED FATTY ACIDS ON THE VIRULENCE OF TUBERCLE BACILLI G PLATONOV, Am Rev Tuberc **21** 362, 1930

Fats of the unsaturated type act bacteriolytically, retard the growth of tubercle bacilli and lower their virulence Guinea-pigs, inoculated with tubercle bacilli the virulence of which has been lower under the action of unsaturated fats, develop a chronic tuberculous process of fibrous character, and show increased resistance to subsequent reinfection The parenteral therapy of tuberculosis, consisting of the introduction of various preparations of unsaturated lipoids, deserves serious attention and study Acids with high iodine value should be assigned a place of honor in the dietary regimen of the tuberculous patient

H J CORPER

EXPERIMENTAL TUBERCULOSIS BY INTRACEREBRAL INOCULATION WILLIAM H FELDMAN, Am Rev Tuberc **21** 400, 1930

By the intracerebral method of injection the resistance of many of the mammals to bacilli of tuberculosis of avian origin is but relative and such animals as dogs and guinea-pigs, which are usually considered to be refractory to infection with avian bacilli of tuberculosis, may develop well defined disease, when the infectious agent is introduced by this route There is evidence that the disease develops with much greater rapidity when the infection is induced intracerebrally as compared to the intravenous or subcutaneous routes of inoculation The pathologic process induced by the intracerebral injection of virulent bacilli of tuberculosis is essentially a specific monocytic proliferation The lesions in the brain appear to originate in the perivascular tissues and most frequently involve the pia mater They extend into the sulci, and occasionally focal lesions may occur in the substance of the cerebrum When the infectious material is introduced into the brain, lesions may develop in distant organs, the liver and spleen are sites of predilection The lungs are less frequently involved and in none of the experimental animals that received intracerebral injections were definite lesions demonstrated in the kidneys In two instances the intracerebral injection of bacilli of tuberculosis of human origin into chickens resulted in the formation of well defined meningeal lesions in the brain The intracerebral method of inoculation offers many interesting possibilities in experimental tuberculosis and should be worthy of trial in the demonstration of the causative micro-organism that may be difficult or impossible to demonstrate by other means

H J CORPER

FOOD POISONING BY STAPHYLOCOCCI E O JORDAN, J A M A **94** 1648, 1930

Strains of staphylococci of diverse origin and cultural character may generate in broth a substance that causes gastro-intestinal disturbances when given by mouth This substance is destroyed by boiling and is destroyed or weakened by being heated at from 60 to 65 C for thirty minutes

BACTEREMIA DUE TO SALMONELLA SUIPESTIFER S E BRANHAM, L J MOTYCA and C J DEVINI, J A M A **94** 1758, 1930

Salmonella suipestifer was isolated from the blood of a patient in an acute febrile condition Most frequently human infections with this organism have presented the clinical picture of gastro-enteritis (food poisoning) or pneumonia

SYPHILIS IN NEGROES IN MISSISSIPPI P S CARLEY and O C WENGER, J A M A **94** 1826, 1930

The examination of 7,228 blood specimens from an unselected group of rural Mississippi Negroes above the age of 9 years by complement fixation tests for syphilis showed positive reactions in 19 3 per cent of all males and in 18 per cent of all females examined The rates of infection in the various age groups reach a maximum between the ages of 30 and 39 for both males and females It is pointed out that the positive results probably represent less than the actual amount of syphilis in the group The infection rates in this unselected group are roughly the same as those discovered at the United States Public Health Service Venereal Disease Clinic at Hot Springs, Ark, in a selected group who were seeking medical aid for previously diagnosed venereal disease These data suggest that, from a public health and economic point of view, syphilis is probably the major public health problem among rural Mississippi Negroes today

AUTHORS' SUMMARY

TORULOSIS OF CENTRAL NERVOUS SYSTEM F B SMITH and J S CRAWFORD, J Path & Bact **33** 291, 1930

A case is recorded, in a woman, of fatal granulomatous infection of the brain and spinal cord by a yeastlike micro-organism, probably *Torula histolytica*

AUTHORS' SUMMARY

THE GENUS WILLIA J F D SHREWSBURY, J Path & Bact **33** 393, 1930

Three species of *Willia* and a variety of one of these species have been observed under various conditions of artificial cultivation over a period of about eighteen months The general conclusions reached from this study are as follows The genus can be identified by the following characters (1) the giant colony growth on a standard medium such as malt agar at room temperature, (2) the surface film growth on aqueous fruit extracts, (3) the sporulation characters, the optimum mediums for sporulation being either carrot or prune agar, (4) the absence of mycelium *Willia* possess only feeble proteolytic and saccharolytic powers, but are able to produce aromatic ethers in mediums containing sugars The genus is indivisible, although *Willia saturnus* (Carlsberg) differs from the other two species studied in its cultural and sporogenic characters *Willia anomala* (Chapman) and *Willia belgica* (Chapman) are closely related organisms, and are possibly varieties rather than separate species, although the ascospores of the latter yeast, as observed in the present study, are not certainly pileate *Willia* are not pathogenic for man or for the laboratory animals, and their presence in human morbid material is merely accidental

AUTHOR'S SUMMARY

"INFLUENZAL" ENCEPHALITIS J G GREENFIELD, J Path & Bact **33** 453, 1930

Two cases of acute disseminated encephalomyelitis following "influenza" are described One was fatal five days and one seven weeks after the onset of symptoms The lesions found in the nervous system were of the same kind as in the encephalomyelitis which sometimes follows vaccination, smallpox and measles These cases are considered to support the view that acute disseminated encephalomyelitis is a disease per se, which may be brought on or directed against the nervous system by certain febrile or exanthematous diseases

AUTHOR'S SUMMARY

EXPERIMENTAL VACCINIAL ENCEPHALITIS E WESTON HURST and R W FAIRBROTHER, J Path & Bact **33** 463, 1930

Vaccinial "encephalitis" can be readily transmitted from rabbits to monkeys by the intracerebral inoculation of virulent material, the resulting reaction, which is primarily meningeal, is figured and described No definite evidence has been obtained that the vaccinia virus, after intradermal inoculation and subsequent general dissemination, is capable of exciting an encephalitis, even when a mild trauma is at the time of vaccination or subsequently inflicted on the nervous system The histology of postvaccinial encephalitis in man is totally different from that of cerebral vaccinia in the rabbit or the monkey, it is highly improbable that the virus of vaccinia plays a direct part in the causation of the former condition The reaction of the central nervous system to the vaccinia virus is to be sharply differentiated from that to the poliomyelitis virus, etc, in that the one is primarily mesodermal, the other primarily ectodermal, the virus of vaccinia is not neurotropic in the same sense as that of poliomyelitis

AUTHORS' SUMMARY

VACCINIAL ENCEPHALITIS J McINTOSH and R W SCARFF, J Path & Bact **33** 483, 1930

Virulent strains of vaccinia can produce in rabbits a definite meningo-encephalitis after intracerebral, intravenous and intradermic inoculation The lesions produced are strictly comparable with the visceral lesions in rabbits and with those of postvaccinial and postvariolar encephalitis in man

AUTHORS' SUMMARY

OCULAR INFECTION OF RABBIT WITH SPIROCHAETA CUNICULI A KLARENBEEK, Ann de l'Inst Pasteur **44** 201, 1930

The inflammatory reaction in the cornea produced by inoculation of *Spirochaeta cuniculi* into the anterior chamber of the rabbit's eye is similar to that from inoculations of *Spirochaeta pallida* The cornea of the rabbit, however, is more resistant to the first organism It is not easy to get an infection of the cornea after either superficial or deep scarification On the contrary, the inoculation of *Spirochaeta pallida* into the intact conjunctival sac gives rise to a typical reaction of the cornea The scleral conjunctiva, on the other hand, and especially the skin of the upper lid are more sensitive to *Spirochaeta cuniculi* than the cornea Several times a primary syphilitic lesion in the skin or in the conjunctiva of the rabbit has followed cutaneous or subcutaneous inoculation of the upper eyelid This sensitivity may serve to differentiate the two varieties of spirochetes

CHARLES WEISS

UNIVERSAL SCLEROSING TUBERCULOUS LARGE CELL HYPERPLASIA K MYLIUS and P SCHURMANN, Beitr z Klin d Tuberk **73** 166, 1929

On the basis of clinical and anatomic observations of two cases and of reports in the literature, a particular type of tuberculosis is described The histologic entity of this type of tuberculosis is usually a miliary focus of large cell hyperplasia which does not caseate, the only form of retrogressive alteration of which is a hyaline sclerosis The clinical course is always chronic The following clinical varieties belong to this type of lesions the benign miliary lupoid of the skin (Boeck), the lupus pernio, the multiple cystoid tuberculous ostitis (Jungling), the multiple spina ventosa of adults (E Fraenkel), a tumor-like, noncaseating tuberculosis of the lymph nodes (Walz), an endurating form of pulmonary tuberculosis (von Gebsattel), a noncaseating tuberculous splenomegaly (von Bebsattel and M Askanazy), and a type of ocular tuberculosis, which is first described in the present paper The localization of the lesion varies greatly The paper is illustrated with good photomicrographs

MAX PINNER

THE INFLUENCE OF LIPOID SOLUTIONS ON THE GROWTH OF ACID-FAST BACILLI T NYRÉN, Beitr z Klin d Tuberk **73** 238, 1929

A large variety of acid-fast organisms were grown on mediums containing various lecithins and cholesterin Lecithin promotes the growth of tubercle bacilli, cholesterin does not Tubercle bacilli from cold-blooded animals and acid-fast saprophytes are not influenced by lecithin All acid-fast bacilli produce strongly granulated forms on lipoid mediums The addition of peptone promotes the growth of all acid-fast bacilli, with the exception of true tubercle bacilli

MAX PINNER

THE COURSE OF HUMAN TUBERCULOUS INFECTION P SCHURMANN, Beitr z path Anat u z allg Path **83** 551, 1930

This is the second part of an extensive and intensive study of human tuberculous infection as encountered in 1,000 successive unselected necropsies on persons dying at all ages The study was undertaken for the purpose of testing the validity of Ranke's hypothesis that tuberculous infection runs a fixed cyclic course, the succession of stages of which depends on four modes of spread and three allergic phases The first part of the study (previously abstracted) dealt with those cases in which the spread and generalization of the infection occurred chiefly by the hematogenous and lymphogenous paths The present study is based on 387 cases, in which the spread was by what may be termed paths of excretion It is a study of chronic pulmonary tuberculosis, the essentials of which are the softening and caseation of an older focus and its rupture into the bronchial system, with a spread of the infectious material within the lung by way of the bronchi These two modes are not necessarily isolated manifestations of the infection in any given case On the contrary, they usually occur together, but one predominates over the other Thus, the person with a generalized infection that runs a protracted course may develop a pulmonary phthisis, in which the spread is along the bronchial system Conversely, the person with chronic pulmonary tuberculosis may exhibit undoubted evidence of the hematogenous spread of the infection, such as isolated tubercles in distant organs, or a terminal miliary tuberculosis or tuberculous meningitis Although one mode of spread may influence, to a certain degree at least, the pathologic process resulting from the other mode, it is in the concomitance of the two modes of spread that the author finds his chief argument against the acceptance of Ranke's hypothesis The latter he holds to be based on theoretic conceptions and not on demonstrable anatomic facts He also can find no morphologic basis for Ranke's three allergic phases This part of Ranke's doctrine is also held to be highly speculative

O T SCHULTZ

INFLUENCING THE SUSCEPTIBILITY OF MICE TO SPIROCHAETA GALLINARUM INFECTIONS BY BLOCKING THE RETICULO-ENDOTHELIAL SYSTEM A PENTSCHEW, Centralbl f allg Path u path Anat **47** 1, 1930

Pentschew found that he could increase the time during which *Spirochaeta gallinarum* was found in the blood by first giving mice intravenous injections of india ink, iron saccharate, and colloidal preparations of gold, silver, and bismuth Copper preparations were too toxic Presumably, these chemicals acted either by mechanically burdening the reticulo-endothelial system by a toxic effect on the mice or by a combination of these factors Injections of colloidal or soluble bismuth preparations seemed therapeutically inert once a spirochetal infection was established Secondary injections of colloidal silver rendered the blood spirochete free within from six to twelve hours

GEORGE RUKSTINAT

INVOLVEMENT OF THE SALIVARY GLANDS IN GENERALIZED MILIARY TUBERCULOSIS E KIRCH, Centralbl f allg Path u path Anat **48** 12, 1930

The salivary glands in six of nine bodies of patients who died of miliary tuberculosis were involved in the disease process The bodies were of eight males and one female from 19 to 22 years of age Nine parotids were examined and only one showed miliary tuberculosis, of thirteen submaxillary glands six were diseased, and of six sublingual glands, two Usually, only one definite tubercle was found and this was almost invariably located in the parenchyma rather than in the interstitial tissue or capsule

GEORGE RUKSTINAT

ASCARIASIS AND SUPPURATIVE PLEURITIS E JENNY, Schweiz med Wchnschr **60** 266, 1930

A suppurative pleural effusion that contained eggs of arscarides developed on the right side in a boy, aged 16 months, who had ascariasis In the course of three months the boy recovered completely The development is explained as follows Ascarides entered the liver by way of the choledochus On the surface of the liver they caused an abscess, which perforated through the diaphragm into the pleural cavity But it is also possible that the pleural ascaris invasion resulted from a lung stage in the development of the parasites

BARTONELLA CANIS (A NEW CAUSE OF ANEMIA) W KIKUTH, Zentralbl f Bakteriol **113** 1, 1929

Kikuth describes a new cause of anemia in dogs which belongs to the *Bartonella* group and is named *Bartonella canis* The parasites are well stained only by the Giemsa stain and are coccoid and rod forms which sometimes resemble *Bartonella bacilliformis* and sometimes *Bartonella muris* They pass Berkefeld —N filters In normal dogs they cause a slight infection which quickly becomes latent but can be activated by splenectomy Splenectomized dogs infected with *Bartonella canis* develop progressive anemia, acute or chronic, which frequently leads to death All attempts to cultivate the parasites have been unsuccessful Transmission of the disease by fleas has also been unsuccessful The administration of neoarsphenamine leads quickly to a disappearance of the parasites from the peripheral blood and to complete healing of the infection

PAUL R CANNON

FILTRABLE FORMS OF TUBERCLE BACILLI E MOROSOWA, Zentralbl f Bakteriol **113** 200, 1929

The author describes experiments in testing the filtrability of tubercle bacilli from tuberculous material and from cultures No tuberculous lesions were found in guinea-pigs into which injections of the filtrates had been made Morosowa suggests that the important factors in this type of investigation are the kinds of filters used, the filtration pressure and the reaction of the material filtered Finer pored filters must also be used before one can conclude that filtrable forms of tuberculosis exist

PAUL R CANNON

MENINGITIS CAUSED BY INFLUENZA BACILLUS STRUNK, Zentralbl f Bakteriol **113** 429, 1929

Two cases of primary meningitis in nurslings caused by *Bacillus influenzæ* are described There were no clinical evidences of influenza, but a pure culture of influenza bacilli was obtained from the spinal fluid in each case In one case, the organisms were also found in the brain, the middle ears and the lungs The organisms were unusually pleomorphic, and were always strongly hemoglobinophilic

PAUL R CANNON

Immunology

INTRARENAL ARTERIAL TUBERCULIN INJECTIONS IN NORMAL AND TUBERCULOUS MONKEYS, GOATS AND SWINE ESMOND R LONG, CHARLES B HUGGINS and ARTHUR J VORWALD, Am J Path **6** 449, 1930

Distinct renal allergic responses were secured on the injection of tuberculin protein into the renal arteries of tuberculous monkeys, goats and swine The allergic nature of the response was established by the fact that similar injection into normal controls did not cause injury (except such as occurred from vascular occlusion) In the monkeys the lesion produced was purely degenerative, in the goats chiefly degenerative but occasionally inflammatory, and in the swine degenerative and of a more inflammatory character than in the goats The inflammation in the goats and swine took the form of an interstitial nephritis The glomerular changes observed in a former investigation in which larger dosage of tuberculin protein was used, were not produced The intensity of renal tuberculin reaction did not parallel the intensity of cutaneous reaction in this series of animals

AUTHORS' SUMMARY

BRUCELLA AGGLUTININS AND BRUCELLINE ERYTHEMA IN VETERINARIANS T FOREST HUDDLESON and H W JOHNSON, J A M A **94** 1905, 1930

Of forty-nine practicing veterinarians, twenty-eight had *Brucella* agglutinins in the blood, but only three gave a history of undulant fever The results indicate a rather low degree of pathogenic power of *B abortus* Veterinarians have observed a peculiar erythema on the skin of the arm following contact with the vagina of cows that have aborted The erythema comes out on the lateral surface of the forearm in about twenty minutes Intradermal injection of *Brucella* culture filtrate caused local reaction with constitutional symptoms in veterinarian with history of this erythema, indicating hypersensitiveness to *Brucella* protein

INFLUENCE OF COMPLEMENT ON SENSITIVENESS OF COMPLEMENT-FIXATION TESTS FOR SYPHILIS LEON C HAVENS and FANNIE MAE FRANK, J Infect Dis **47** 100, 1930

The sensitiveness of complement-fixation tests for syphilis can be increased by closer adjustment of the complement to the conditions of the test Titration of complement with the addition of inactivated human serum yields a smaller unit than when the serum is omitted, owing to the presence of a thermostabile constituent which can be removed by absorption with yeast Tests of 1,066 serums, the unit of complement obtained by titration with serum and antigen being used, yielded 45 positive results which were negative with the standard test Agreement between the complement-fixation test, the serum unit being used, and the Kahn precipitation test was 99 4 per cent, as compared with 95 per cent agreement when the standard Kolmer test with the full unit of complement was used In 106 treated patients with syphilis, 29 positive results were obtained with the standard test, 61 with the serum unit and 65 with the Kahn precipitation test

AUTHORS' SUMMARY

ANTIBACTERIAL FUNCTIONS OF MUCUS N E GOLDSWORTHY and H FLOREY, Brit J Exper Path **11** 192, 1930

The authors review the literature of the lytic substance "lysozyme" and its importance in natural immunity Lysozyme has been shown to be present in the tears, saliva and intestinal and nasal mucosa of various animals, and even in some of the members of the vegetable kingdom Further experiments are reported on the variation in concentration of lysozyme in different portions of the gastroenteric tract of certain animals There appears to be no logical explanation for

these variations from a standpoint of natural immunity The saliva seems to be the most constant source of lysozyme in all animals except the goat However, not all air organisms and few pathogens are inhibited by lysozyme

ALFRED M GLAZER

VIRULENCE, IMMUNITY AND BACTERIOLOGICAL VARIATION IN RELATION TO PLAGUE A S BURGESS, J Hyg **30** 165, 1930

Experiments to determine the prophylactic efficacy of agar-grown vaccine, broth-grown vaccine and carbolized spleen pulp vaccine on African pouched rats inoculated with small doses of plague culture are described The agar-grown vaccine gave a survival rate of 25 per cent the broth-grown vaccine, 56 per cent and the carbolized spleen pulp vaccine, 75 per cent However, the carbolized spleen pulp vaccine is not likely to be of practical value because of its difficult preparation and the undesirable local effects it produces

Experiments are then described in which the virulence of *B pestis* was reduced by passage through immune or partially immune rats, and then increased by passage through normal rats High temperatures also decrease the virulence of the organism No direct correlation between type of colony and virulence of the organism is found

ALFRED M GLAZER

ANTIVACCINIAL SERUM C H ANDREWES, J Path & Bact **33** 265, 1930

Vaccinia virus could be recovered from a mixture with excess of immune serum, even when the mixture had stood for four days at room temperature or for twenty-four hours at 37 C Nevertheless, carefully controlled experiments showed that with prolonged contact, virus was progressively more and more difficult to recover This suggests that a stable antigen-antibody union may occur in vitro but that it is certainly not complete for some days This idea is considered in relation to the fact that antibody is apparently effective in vivo in the course of a few minutes

AUTHOR S SUMMARY

SPECIFIC ANTIBODY ABSORPTION BY THE VIRUSES OF VACCINIA AND HERPES WILSON SMITH, J Path & Bact **33** 273, 1930

Vaccinial and herpes testicular emulsions are capable of absorbing their homologous antibodies from immune serums The specificity of absorption is shown by cross absorption experiments in which vaccinia testis failed to absorb out any herpes antibodies and herpes testis failed to absorb out any vaccinial antibodies, also by the fact that each virus will select for absorption its homologous antibodies from a mixed serum Vaccinia testis emulsion, in which the virus has been destroyed by heating at 58 to 60 C for one hour, shows greatly reduced power of antibody-absorption

AUTHOR'S SUMMARY

THE INHERITANCE OF THE BLOOD GROUP FACTORS G K KIRWAN-TAYLOR, J Path & Bact **33** 313, 1930

The results of the present investigation are without exception in agreement with Bernstein's theory of inheritance, the greater part of the work was carried out without knowledge of Bernstein's theory Taken with the very large number of cases collected by Furuhata they show that the theory of triple allelomorphs may be accepted with considerable safety It must be admitted that exceptions have been recorded, and the possibility of errors in these cases has already been considered It is conceivable, however, that some discordant results are capable of another explanation Although Bernstein's hypothesis admits of only one possible formula for group 1 bloods ABBa, it is perhaps possible for mutations to occur in this grouping so as to give rise to zygotes having the formulae AB and aB Should such a "sport" arise, the probability would be that the AB zygote would

be fruitless owing to the doubling of the dominants, and only the aB zygote capable of reproduction Such a possibility would result in a return to von Dungern and Hirszfeld's original views as to the possible offspring of matings concerning a group 1 individual Even therefore if there is some reluctance to accept Bernstein's theory of inheritance as definitely proved, there is an enormous amount of data in support of the conclusion that no child can possess in its blood (Lattes 1929) an agglutinable substance which is not present in one of the parents The possible medicolegal applications are obvious

AUTHOR'S SUMMARY

THE RÔLE OF THE SPLEEN IN THE PRODUCTION OF ANTIBODIES W W C TOPLEY, J Path & Bact **33** 339, 1930

These experiments, as a whole, would seem to lend further support to the view that the spleen is concerned, not only in the fixation of antigen, but in the elaboration either of antibody itself, or of some intermediate product

AUTHOR'S SUMMARY

MORPHOLOGY OF IMMUNITY REACTIONS OF VASCULAR ENDOTHELIUM W EWALD, Beitr z path Anat u z allg Path **83** 681, 1930

The importance of humoral reactions in immunity and in the protection of the body against infection has long been recognized The importance of participation of the true reticulo-endothelial system in such immunity and protective reactions, especially as related to the formation of soluble immune substances and to the phagocytosis of invading organisms, also appears well established In recent years, Oeller, Siegmund, Domagk, Hammerschmidt, and others have ascribed to the ordinary vascular endothelium phagocytic activity and other important properties that are of the greatest importance in the defense of the organism against acute infection They have claimed that the participation of the endothelium is demonstrable morphologically To proliferation of periadventitial cells and to perivascular infiltration about the smallest vessels, some of the more recent writers have ascribed an equally important role in subacute and chronic infections In his investigation of the reactions manifested by vascular endothelium in acute infection, Ewald used the strain of *Corynebacterium murisepticum* that had been employed by Hammerschmidt, who had considered this organism especially suited to calling forth the endothelial reactions described by him as evidence of the participation of the endothelium in the defense of the host At frequent intervals following injection of mice the leukocytes of the blood were counted and blood smears were examined to detect the occurrence of phagocytosis Beginning with the eighth hour after injection, the animals were killed at intervals of from two to four hours and tissues taken for microscopic study Injection of the bacteria was followed by moderate leukocytosis for from twelve to eighteen hours During the next eighteen to twenty-four hours the leukocytes decreased to about 4,000 per cubic millimeter, and underwent a still further decrease to 1,500 and less during the terminal hours of the infection Clumps of agglutinated bacteria could be detected in the blood at about the twenty-fourth hour, but phagocytosis was not observed until forty hours after infection and later At a much earlier period than this, namely from the twenty-fourth hour on, phagocytosis of the clumped bacteria by the reticulo-endothelial cells of the liver and spleen was evident The morphologic endothelial changes described by others were not seen Ewald concludes that the most important and the most immediately available protective weapons against infection are the humoral and cellular mechanisms of the blood These lead to agglutination of the bacteria, which process is preparatory to the phagocytosis of the bacteria by the leukocytes and by the reticulo-endothelial cells of the liver and spleen His experiments offered no support to the view that phagocytosis of bacteria by ordinary vascular endothelium is important or to the view that there occur in the endothelium morphologic changes that may be interpreted as indicating a participation of such endothelium in the immunity reactions of the body

O T SCHULTZ

AN APPARENT O-GROUP IN A CHILD OF AN AB-PARENT E WORSAAE, Klin Wchnschr **9** 938, 1930

The author found the conditions stated in the title and absorption experiments showed that the child had small quantities of A receptor Subsequent tests demonstrated agglutination by a high titer A serum The agglutination test alone is insufficient to exclude a definite receptor, but must be checked by an absorption test

AUTHOR'S SUMMARY

THE MECHANISM OF IMMUNITY AGAINST TUBERCULOSIS IN RATS I J GOLDENBERG, Ztschr f Tuberk **55** 125, 1929

Although rats have a strong resistance against tuberculous infection, tubercle-like lesions can be demonstrated in them following inoculation of bacilli The extent of these lesions depends on dosage, site of infection and on the strain and age of the rats The histologic picture of these tuberculoid structures is atypical Epinephrine and blocking of the reticulo-endothelial system with trypan blue diminishes the resistance of rats Avitaminosis depresses the resistance markedly Infected rats do not react to tuberculin

MAX PINNER

THE PRECIPITATION REACTION FOR ACTIVE TUBERCULOSIS H SCHULTE-TIGGES, Ztschr f Tuberk **55** 133, 1929

This test is less reliable than complement fixation It is less frequently positive in favorable forms of active tuberculosis It is more frequently negative in far advanced cases Its practical value is limited Complement fixation combined with red cell sedimentation is preferable

MAX PINNER

RESULTS OF BCG INOCULATIONS IN AMSTERDAM M R HEYNSIUS VAN DEN BERG, Ztschr f Tuberk **55** 401, 1930

The oral administration of BCG to two hundred sixty infants showed that the procedure is harmless, according to an observation over four years There does not seem to exist any parallelism between skin allergy and immunity The tuberculosis mortality during the first two years of life in children who had a positive Pirquet reaction within the first year of life was 6 2 per cent in the inoculated group, as compared with 52 3 per cent in the noninoculated group

MAX PINNER

IMMUNIZATION WITH SAPONIFIED TUBERCLE BACILLI A V JENEY, Ztschr f Tuberk **55** 496, 1930

Tubercle bacilli were saponified in a vacuum with concentrated alkali This antigen had a demonstrable immunization effect on guinea-pigs Guinea-pigs that were treated with this antigen showed marked cirrhotic processes, particularly in the liver Evidence is presented to show that the cirrhotic processes are produced by soaplike substances

MAX PINNER

THE PERMEABILITY OF THE INTESTINES IN GUINEA-PIGS FOR VIRULENT TUBERCLE BACILLI AND FOR THE BACILLI IN THE BCG VACCINE A SAENZ, Ztschr f Tuberk **56** 131, 1930

Guinea-pigs that received from 1 to 5 mg of virulent tubercle bacilli by mouth became allergic to tuberculin from thirty to fifty days after the infection Guinea-pigs similarly infected with from 10 to 20 mg BCG became sensitive to tuberculin from fifty to eighty days after the infection

MAX PINNER

THE INTRACUTANEOUS IMMUNIZATION OF RABBITS WITH BACTERIA AND ERYTHROCYTES HANS GROSS, Zentralbl f Bakteriol **113** 452, 1929

Gross finds that good agglutinating and hemolytic serums may be obtained in rabbits by intracutaneous injections Living, toxic cultures have a better antigenic effect than killed or less virulent strains Good results were obtained with typhoid and paratyphoid organisms, poorer with dysentery and coli bacilli, and none with staphylococci and pneumococci

PAUL R CANNON

Tumors

THE INCIDENCE OF PRIMARY CARCINOMA OF THE LUNG PAUL D ROSAHN, Am J M Sc **179** 803, 1930

The postmortem incidence of primary carcinoma of the lung is steadily increasing, and this increase is real and absolute Combined statistics show that from 1910 to 1919 primary carcinoma of the lung was disclosed in 0 44 per cent of autopsies, and comprised 4 39 per cent of all cancers at autopsy Since 1920, primary carcinoma of the lung has been found in 0 89 per cent of autopsies and has comprised 6 98 per cent of all cancers at autopsy Primary carcinoma of the lung is not as rare as was formerly believed Because of its increased frequency, the clinician should give this disease serious consideration in differential diagnosis in patients of the carcinomatous age presenting puzzling lung symptoms and signs An early diagnosis will permit accurate prognosis, and in selected cases perhaps, surgical therapy

AUTHOR'S SUMMARY

EFFECT OF ROENTGENIZATION ON CEREBELLAR MEDULLOBLASTOMAS PERCIVAL BAILEY, Am J Path **6** 125, 1930

These tumors are composed of embryonic undifferentiated cells of neuroepithelial origin, they grow with extreme rapidity and are sensitive to irradiation, but after a time the cells appear to become radioresistant, according to assumption Cases are now reported in which persistent irradiation was practiced after removal of the main tumor, without any local recurrence, and in which, nevertheless, the patients died from intraspinal or intracranial extensions It is assumed that the cells may become scattered into the arachnoid fluid during operation, hence radiation should be applied to the entire cerebrospinal system after operative removal of these tumors

LYMPHOSARCOMA, WITH INVOLVEMENT OF THE CENTRAL NERVOUS SYSTEM CHARLES DAVISON and JOSEPH J MICHAELS, Arch Int Med **45** 908, 1930

Twenty-six patients with lymphosarcoma admitted to this institution since 1922 were investigated, seven of whom presented neurologic signs and symptoms Four of these patients showed signs of compression of the spinal cord The literature on this subject reports only one case In none of the cases was there a direct invasion of the brain or of the spinal cord The symptoms were due chiefly to compression from invasion of the skull, vertebrae or meninges Invasion of the cranial cavity took place only when the cervical lymph nodes were involved, and, as observed in our series, involved early Deep roentgen and radium therapy, while not a cure for the disease, causes some relief from the symptoms during the first few applications The relief is due chiefly to the recession of the tumor which causes compression on the respective organs When these enlargements fail to respond to treatment, improvement in the symptoms may not be expected For a time, however, these patients benefit a great deal by deep roentgen or radium therapy, and at present these are the best forms of palliative treatment

AUTHORS' SUMMARY

HEMANGIOMA OF THE UTERUS E HORGAN, Surg Gynec & Obst **50** 990, 1930

There are twenty cases of hemangioma of the uterus in the literature, and of these there are three of the true cavernous type, to which the author adds one The anterior wall of the uterus contained a typical cavernous hemangioma with an aperture in one of the caverns, allowing the escape of blood into the uterine cavity From the age of 19 to her present age of 46 years, the patient has had six severe hemorrhages Differentiation must be made from hemangiomatous fibromyoma and telangiectatic hemangioma in the pelvis

RICHARD A LIFVENDAHL

STRUCTURE AND HISTOGENESIS OF PRIMARY CARCINOMA OF THE LIVER F ORSOS, Beitr z path Anat u z allg Path **84** 33, 1930

For the two types of primary carcinoma of the liver that he believes it possible to distinguish Orsos prefers the names malignant hepatoma and malignant cholangioma He precedes his minute, detailed and profusely illustrated descriptions of three examples of the former and one of the latter by a brief description of the regenerated liver cells in a case of acute degeneration and atrophy of the liver The malignant hepatoma arises from small interlobular bile ducts and forms epithelial tubular structures like those of the embryonic liver Such structures by differentiation lead to the formation of cell cords with bile canaliculi and even of small pseudolobules The blood vessels are like the sinusoids of the normal lobule, and the stroma is relatively slight in amount The epithelial cells may exhibit functional bipolarity, in that the portion of the cell next to the vessel may store fat, whereas the portion next to the lumen of the canaliculus may secrete bile The malignant hepatoma grows expansively, does not infiltrate peripherally and does not invade the lymph channels It metastasizes by the blood vessels The tumor may have a multicentric origin, especially in cirrhotic livers The malignant cholangioma arises from larger interlobular ducts, the characteristics of which it tends to reproduce The amount of stroma is greater The tumor infiltrates peripherally, invades the lymph channels and metastasizes by the latter Bile formation does not occur in the tumor tissue Transition forms occur, however, between the two tumor types and may be seen in the same tumor The cholangioma described was unusual in that the stroma was sarcomatous The author does not consider the tumor a sarcocarcinoma or a mixed tumor, but a combination neoplasm in which the epithelial and mesenchymal elements arose independently of each other

O T SCHULTZ

THE VALUE OF THE MALIGNANCY INDEX IN THE PROGNOSIS OF TUMORS S P REIMANN, Beitr z path Anat u z allg Path **84** 266, 1930

In the Kaufmann Festschrift number of Ziegler's Beitrage, Reimann discusses briefly the facts that speak against the practical value of any scheme of grading the malignancy of tumors that is based on supposed quantitative variations in the morphology of neoplasms To test the validity of such a system of grading malignancy, 100 carcinomas of the mammary gland operated on at the Lankenau Hospital in Philadelphia were divided into three prognostic groups The histologic characters taken into account in the classification were the size and staining reactions of the tumor cells, the proportion of mitoses, the architecture of the tumor, the invasion of lymphatics and blood vessels and the reaction of the stroma The prognosis thus arrived at was compared with the actual prognosis, as determined by a follow-up of the cases The former was wrong in 50 per cent of the cases Reimann concludes that a prognostic classification based on a mathematic grading of histologic characters is not much better than the impression of the degree of malignancy that the experienced pathologist receives from his usual examination of histologic preparations of tumors

O T SCHULTZ

EXTRATESTICULAR CHORIONEPITHELIOMA WITH GYNEKOMASTIA W H SCHULTZE, Beitr z path Anat u z allg Path **84** 473, 1930

Schultze reports a chorionepithelioma that arose in a retroperitoneal teratoma, and claims it is only the second recorded example of this kind of tumor in the male the origin of which in an extragenital teratoma has been definitely proved It is the seventh case of extragenital chorionepithelioma in the male and the third example of retroperitoneal chorionepithelioma in the male The patient was 22 years old Seven months before his death, he began to complain of pain in the region of the kidney Three months before death, the breasts began to enlarge Seven weeks before death, metastases were detected in the lungs roentgenologically, and colostrum could be expressed from the hypertrophied breasts He lost weight rapidly The tumor was retroperitoneal and extended from the diaphragm to the sacral promontory It contained two kinds of malignant tissue, chorionepithelioma and medullary carcinoma, which had metastasized independently of each other to various organs The chorionepithelioma metastasized chiefly to the lungs, the carcinoma to other organs and especially to the right testis, which had been atrophic as the result of hernia Spermatogenesis was absent in the left testis The primary tumor contained squamous epithelium and cartilage The glandular portion of each breast was 5 cm in diameter and 1 5 cm thick Histologically, the mammary tissue revealed acinar hyperplasia and active secretion Schultze disagrees with Hertzenberg who had claimed that the gynecomastia associated with chorionepithelioma is due to a circulating placental hormone derived from the tumor Schultze maintains that gynekomastia is never associated with tumor formation unless there is damage to testicular function

O T SCHULTZ

TUBULAR AND SOLID TESTICULAR TUMORS OF THE OVARY R MEYER, Beitr z path Anat u z allg Path **84** 485, 1930

Meyer describes seven tumors of the ovary that he considers to be atypical members of the tumor group termed by Pick in 1905 testicular tubular adenoma of the ovary The first of the neoplasms is like two previously reported by Meyer, in that much of the tissue had the characteristic, well differentiated tubular structure of the adenoma described by Pick, but contained also atypical carcinomatous areas In the remaining tumors, the deviation from the tubular character was greater and the tumors contained solid carcinomatous areas, portions of sarcomatous morphology, sometimes tissue similar to that of interstitial cell tumors and sometimes areas that resembled granulosa cell tumors All, however, contained atypical tubular structures that lead Meyer to consider them members of the testicular ovarian tumor group It is not necessary to derive such tumors from an ovotestis Meyer believes that they may arise from indifferent ambivalent cell material that in its proliferation to form a tumor may differentiate into male or testicular tissue He holds it conceivable that twin tumor forms, composed of both ovarian and testicular elements might arise from such indifferent cells The testicular ovarian neoplasms, for which Meyer proposes the name andreioblastoma, cause varying degrees of virilism of the adult woman The degree of change toward the male side in Meyer's series was inversely proportional to the degree of differentiation of the tumor tissue The changes noted were deepening of the voice, hirsutes of the male type and alterations of the sexual psychology

O T SCHULTZ

METABOLISM OF LEUKEMIC LYMPHOCYTES E PESCHEL, Klin Wchnschr **9** 1061, 1930

Leukocytes, especially exudate cells, under aerobic conditions hydrolyze sugar into lactic acid In contrast, Peschel noted that leukemic lymphocytes have a pure oxidation metabolism, and aerobically are not glycolytic The leukemic cells are not tumor cells, according to their metabolism, but rather normal young tissue cells

EDWIN F HIRSCH

CONGENITAL MALIGNANT NEOPLASM OF THE LIVER DISSEMINATED THROUGH THE PLACENTA F PARKES WEBER, E SCHWARZ and R HEILENSCHMILD, Munchen med Wchnschr **77** 624, 1930

A woman, 38 years old, with diffuse and subcutaneous melanotic tumors became pregnant, and at cesarian section an apparently normal child with melanotic lesions in the placenta was delivered At 8 months, the child was admitted to the hospital with an enlarged liver and a progressively developing cachexia It died in the eleventh month from the same condition as the mother This is said to be the first report of tumor metastasis of mother through placenta and thence to fetus

A J KOBAK

Medicolegal Pathology

THE DEMONSTRATION OF GONOCOCCI IN SPOTS FOR MEDICOLEGAL PURPOSES H LORCH, Dermat Wchnschr **89** 1358, 1929

Gonococci may be demonstrated in dried spots of secretion after weeks and months by maceration in acidified distilled water followed by staining with the combined Neisser-Gram-Pappenheim method

DETERMINATION OF AGE OF BLOOD SPOTS SCHWARZACHER, Deutsche Ztschr f d ges gerichtl Med **15** 119, 1930

In the determination of the age of blood spots, several factors have to be considered, such as the mode of development of the blood stain, the absolute amount of blood present, the thickness of the bloody area and the physical qualities of the object on which the blood spot is found The action of heat, light and humidity is also of importance Micro-organisms and fungi may rapidly destroy a blood spot because of their fermentative action Under ordinary circumstances, the oxyhemoglobin and reduced hemoglobin are gradually transformed into methemoglobin, hematin and other products, which cause a change in the color and a decrease in the water solubility of the blood spot One notices, therefore, that an originally dark red blood spot appears first brownish red, then brownish or brownish violet, at last exhibiting a dirty gray tint On transparent objects, one can spectroscopically determine the various hemoglobin derivatives But the changes in color through aging of the blood spot can also be observed with a photometer (Pulfrich) The solubility of a blood spot is best studied by the use of distilled water a definite amount of dried old blood, dissolved within a definite period of time, can then be calculated by colorimetric or refractometric methods The action of light is the main factor that influences the character and the rapidity of the aging process of a blood spot

E L MILOSLAVICH

USE OF POWDERED SERUM-GLOBULIN FOR BLOOD GROUPING P SERFBRJANIKOFF and M LEITSCHICK, Deutsche Ztschr f d ges gerichtl Med **15** 125, 1930

Since fluid serum cannot be preserved permanently, the authors succeeded in preparing a serum-globulin powder which they recommend as a standard dried serum, mainly for purposes of determinations of blood groups The amount of ammonium sulphate necessary to precipitate globulins varies for any given serum, and it is impossible to state individually its quantity in advance

E L MILOSLAVICH

DIFFERENTIATION BETWEEN HUMAN AND ANIMAL HAIR ADALBERT SCHRODER Deutsche Ztschr f d ges gerichtl Med **15** 127, 1930

Various technical procedures for examination of the cuticula are discussed, and a new method, consisting of the printing of hair on the gelatin layer of a photographic plate, without destruction of the hair, is described The entire length

ot a hair should always be examined, as different structural changes occur in various portions of the same hair There are no differences between the cuticular structure of human hairs taken from various regions of the body The hairs of a cat and of a dog are easily determined, while those of cattle, horses and goats are difficult to differentiate From the shape of the euticula cells, one is unable to distinguish between a hair of a cat and that of other domestic animals On account of the large variety of races, the hair of dogs shows greater differences in structure than that of cats The eutieula cells in horses cattle, goats and deer exhibit a comparatively simple arrangement The latest work of Litterscheid and Lambardt is analyzed at length and many of their important statements relating to diagnosis of hair are contradicted One is able to differentiate positively between a human and an animal hair by a study of the cuticula in the entire length of the hair The cuticular structure (narrow wavy lines) found in the basal portion of a human hair is present only at the apical end of an animal hair In examining hairs in their entire length, human hair can be positively identified by its delicate surface structure, the hair of a deer by an absence of such a structure in the apical third The hairs of dogs and cats can be differentiated from those of horses, cattle and goats because elongated cell forms are not present in the hair of the latter animals However, it is impossible to distinguish between a hair of a dog and that of a cat, due to the great similarity in their structure The same is true in trying to differentiate separately between the hair of horses, cattle and goats If one examines only a part of a hair, a definite diagnosis is impossible Should the examined section of hair disclose the presence of elongated cellular forms, one can only deduct that it is hair of a cat or a dog

E L MILOSLAVICH

BULBAR PARALYSIS FOLLOWING INJECTIONS OF COCAINE-EPINEPHRINE E SCHUIT, Deutsche Ztschr f d ges gerichtl Med **15** 149, 1930

A man, aged 65, received injections of a 3 per cent procaine hydrochloride solution containing epinephrine for the extraction of teeth, four times within six weeks He suddenly commenced to show the clinical picture of bulbar paralysis An almost identical case was described by Heinemann It is assumed that epinephrine might have increased the blood pressure, leading to a rupture of the small atheromatous vessels within the medulla oblongata, or that the injected drug produced a spasmodic contraction of the blood vessels with subsequent ischemia and gradual necrosis of the corresponding medullary structures

E L MILOSLAVICH

FRACTURE OF THE EPISTROPHEUS H DURCK, Munchen med Wchnschr **76** 1406, 1929

A laborer, aged 26, who fell down a flight of stairs while carrying a tub on his back, was able to work for three days thereafter, although he experienced difficulty in moving his neck, chills and fever developed Because of pain in the right side of the head a mastoid operation was performed and a thrombosed sigmoid sinus discovered Thereafter the right jugular vein was ligated near its bifurcation, and subsequently the right eye was enucleated because of a purulent panophthalmitis Death occurred forty-two days after the accident, and at autopsy a partially healed fracture of the right arch of the epistropheus was found The bone fragment was displaced to the spinous process of the third cervical vertebra and was carious The presumed course of events was a fracture of the epistropheus, followed by a hematoma which became infected and led to thrombosis of the jugular vein The process extended to the right arm and resulted in multiple abscess formation in both the pulmonary and the systemic circuits because the patient had a patent foramen ovale

In a second case reported by Durck, the fracture involved the dens of the epistropheus of a girl, aged 18 In this case death occurred shortly after the patient had injured her neck while dancing At autopsy the upper portion of the dens

was adherent to the ligamentum transversus atlantis The inferior surface showed evidences of a healed fracture, and subsequent dislocation of this part of the dens had caused myelitis A history of injury to the neck at the age of 11 years explained the unusual postmortem picture on a basis of an epiphyseal separation of the dens

GEORGE RUKSTINAT

"GOLDEN HAIR" F KNUTSSON, Acta radiol **11** 78, 1930

The roentgen examination of the skull of a man, aged 34, showed in the scalp many fine threadlike shadows, a few millimeters in length and of metallic density These shadows were distributed closely over the area where the hair grows The patient had been bald since his nineteenth year, and in 1918, about 2,000 tufts of hair on gold threads had been inserted into the scalp, but these hairs disappeared completely within the next six months The golden roots remained

Technical

A NEW INTERPRETATION OF THE VAN DEN BERGH REACTION HIRAM F SNYDER and JOHN G REINHOLD, Am J M Sc **180** 248, 1930

The type of direct van den Bergh reaction observed in serum depends on the concentration of bilirubin In the cases here reported an immediate van den Bergh reaction was associated with a high icterus index and a delayed van den Bergh with a low icterus index The van den Bergh reaction changed from negative to delayed, then to biphasic, and finally to immediate as increasing amounts of bilirubin were added to human serum Dilution of a jaundiced serum with normal serum changed the van den Bergh reaction of the former from immediate to delayed The temperature of the reacting materials was shown to be an important factor

AUTHORS' SUMMARY

SILVER STAINING OF THE ENDONEURIAL FIBERS OF THE CEREBROSPINAL NERVES GEORGE F LAIDLAW, Am J Path **6** 435, 1930

The endoneurium consists of longitudinal fibers and a closely fitting argyrophil web The distribution of the web is described together with the silver technic necessary for its demonstration

AUTHOR'S SUMMARY

A FURTHER MODIFICATION OF DEL RIO-HORTEGA'S METHOD OF STAINING OLIGODENDROGLIA WILDER PENFIELD, Am J Path **6** 445, 1930

The method described here has been found particularly useful in staining the oligodendroglia of the retina, nerve head and optic nerves Microglia is also stained with varying success by this method

AUTHOR'S SUMMARY

RETICULUM A NEW METHOD OF DEMONSTRATION JAMES F RINEHART, Am J Path **6** 525, 1930

A new method of metallic impregnation is detailed which yields complete impregnation of mesenchymal, reticulum and collagen fibrils An adequate polychrome counterstain may be superimposed on the impregnated tissues The mesenchymal cells possess a rich delicate fibrillar cytoplasm, the fibrils are readily impregnated by the method employed Morphologic support is given for the generally accepted concept that capillaries are formed in situ by a direct differentiation of the mesenchyme This differentiation of capillaries in the mesenchyme is of a very simple character The capillary endothelial cell remains in the embryo as a fiber-producing cell and this property and capacity persists into the mature organism Both reticulin and collagen are fiber products derived from a common fibrillar mother substance and are undoubtedly chemically similar Reticulum

fibers are demonstrated in capillaries in a wide variety of tissues, sufficiently wide to justify the concept that they are of universal occurrence in the capillary endothelium Otherwise stated, reticulum may be identified as the fiber product of capillary endothelium Similar fiber substance is present in the endothelial and reticulum cells of the lymph nodes These cells, as the capillary endothelial cells, are little differentiated, direct descendants of the mesenchyme Reticulum fibers are also present in the intersinusoidal or so-called reticulum cells of the splenic pulp and line the sinusoids of the liver Reticulum fibers are a little changed descendant of the mesenchymal fibers Brief evidence is presented favoring the ability of reticulin to be transformed into collagen Reticulum is the most widespread and important supportive substance in the body It is the scaffolding of cells and cell units It serves the double purpose of microscopic cell support and the lining of capillary vascular channels By identifying reticulum with the capillary endothelium and obtaining sufficiently clear sections, the finer structure of the capillary bed is revealed Reticulum fibers form the immediate lining of capillaries and minute reticulum-lined spaces are shown extending between and connecting the small capillaries as seen in ordinary sections Such channels are considered to serve normally for the transfer of elements contained in the plasma of the blood and to be capable of enlarging or "opening up" under effective stimulus to a caliber sufficient to convey corpuscular elements The endothelial reticulum is identified with the basement membrane in the kidney, pancreas, suprarenal and gastric mucosa, this probably applies to basement membranes in general

AUTHOR'S SUMMARY

PRESERVATION OF SUPRAVITAL STAINING IN PARAFFIN SECTIONS CLAUDE E FORKNER, J Exper Med **52** 379, 1930

A simple, rapid method for staining all the supravitally stainable cells in the body, as in supravital preparations with neutral red, is described, together with a method for faithful preservation of the dye in paraffin sections The essential points of the technic are, first, to secure the reaction of cells to neutral red which corresponds to the so-called supravital technic, involving the reaction of only those substances which respond to the dye while the cell is living, and second, to preserve the stain through the processes of fixation, embedding, and counterstaining

AUTHOR'S SUMMARY

RAPID EXTRACTION OF BACTERIA BY PERCUSSION OF FROZEN CELLS J M JOHLIN and ROY C AVERY, J Exper Med **52** 417, 1930

A method is described for rapidly obtaining fresh extracts of micro-organisms by percussion of the frozen cells Filtrates giving the biuret reaction and yielding heavy precipitates on the addition of acetic acid were obtained from the washed cells of cultures of yeast, hemolytic streptococcus, pneumococcus, *Bacillus coli, B aerosis B diphtheriae* and the bacillus of bovine tuberculosis

AUTHORS' SUMMARY

DIFFERENTIATING BOVINE AND HUMAN TUBERCLE BY INTRACUTANEOUS INJECTION IN RABBITS T TODA, Ztschr f Tuberk **55** 302, 1930

Of the culture to be tested, 0 00001 mg in 0 1 cc is injected intracutaneously A known bovine culture of high virulence should always be used as a control in each animal Injecting one strain into the skin of one leg, three unknown cultures can be tested in one animal simultaneously A caseous tuberculosis develops in the regional lymph glands if a bovine culture is injected, this never occurs with human strains Bovine strains make large and persisting ulcers in the skin, human strains produce small and healing primary infections

MAX PINNER

Society Transactions

PHILADELPHIA PATHOLOGICAL SOCIETY

Regular Meeting Oct 9, 1930

V H Moon, M D, *Vice-President in the Chair*

Juxtapineal Tumor Walter Freeman, Washington, D C

A boy, aged 13, complained of headache and vomiting The margin of both disks was blurred, and the rate of the pulse was 48 per minute A week after the onset the patient became somnolent, and complained of tinnitus and diplopia He staggered somewhat to the right, and movement in the right leg was slightly incoordinate The symptoms cleared under dehydration, but returned when the intake of water was unrestricted The boy rapidly became stuporous, and a bilateral Babinski sign developed Ventriculography showed hydrocephalus The cerebellum was explored, but without disclosing the tumor The decompression helped the patient, but two weeks later convulsions developed, and death followed The entire illness lasted seven weeks

The tumor was lobulated and arose from the roof of the third ventricle close to the pineal gland It distended the ventricle markedly and pressed down on the tectum of the midbrain The pineal body was unchanged Histologically, the tumor was epithelial there were some rather large cavities lined by cuboid epithelium sometimes ciliated and containing colloid material There were also some fairly typical epithelial pearls Other parts of the tumor were more solid with little stroma and showed the structure of adenocarcinoma with large hyperchromatic nuclei and many mitotic figures There were some areas of necrosis and hemorrhage

It is believed that the cystic portion of the tumor was congenital, and that the malignant portion when once started, developed rapidly from it The origin was presumably ependymal

Transmission of Lymphoid Leukemia of Mice J Furth and M Strumia

Spontaneous leukemia in a white mouse was transmitted by intravenous inoculations in eight and in another case in five, successive passages The leukemia produced by transmission was preceded by an aleukemic stage in which the lymph nodes and the spleen were considerably enlarged In films of the blood leukemia is first recognized by the relative high percentage of immature lymphocytes The evidence obtained in studies of transmissible leukemia (Snyders, Richter and McDowell, and Korteweg) suggests that it is a neoplastic disease, and one fundamental problem of leukemia appears to be how immature leukocytes become neoplastic Leukemic cells when introduced into the vein of mice of any age disappear from the circulation and multiply in lymphoid and other tissues favorable for their growth until the mechanism that tends to keep the number of leukocytes at a certain level is overcome

Blood Morphology in Lymphatic Leukemia of Mice Max M Strumia

The cell predominating in the blood of mice suffering from lymphatic leukemia is a large but apparently mature lymphocyte Immature cells which vary from 5 to 25 per cent, closely resemble the lymphoblasts found in the blood of human beings, but are much more difficult to identify The nucleus of these immature lymphocytes in mice have less distinct nucleoli and occasionally possess small azurophilic granules, which are unknown in the typical lymphoblasts in human

beings In general, azurophilic granules are more prominent in the lymphocytes of mice than in those of man

The prolymphocytes, although present, do not occur in large numbers, and apparently have less significance than they do in cases of lymphatic leukemia in human beings Polychromasia is both intense and common, but nucleated red cells are rare Immature granulocytic cells are common, but at present it is not possible to state whether they are increased above normal

THE RÔLE OF INFECTION IN GINGIVITIS ROBERT A KEILTY, Washington, D C

I would emphasize the fact that bacterial infection and protozoal infestation play a most important part in the initiation and progression of gingival changes These gingival changes are of real importance, since they lead to much suffering and occasionally to death in the acute phases and to the unnecessary loss of teeth in the chronic phases The gingivae are a possible focus of infection, this point is almost completely neglected by physicians It has been shown experimentally by Cook that elective localization by streptococci from the gingivae is important

The bacteriologic problem is complex, and many organisms commonly present have never been obtained in pure culture This offers a prolific field for the bacteriologist, but conclusions must be controlled by intelligent dental conceptions The problem as a whole belongs to the dentist, and I have found that when a cooperative spirit exists, results have been obtained by treatment that could not be gained by any other method or means so far advanced The results of treatment based on these conceptions have been a great aid in evaluating the importance of the role of infection in gingivitis

The infectious organisms present in the gingival sulci about the necks of teeth are a most, if not the most, important single factor in the etiology of inflammatory conditions from acute to chronic phases, which we have classified under the inclusive term of gingivitis

THREE UNUSUAL TYPES OF CONGENITAL CARDIAC ANOMALIES S BELLET and B A GOULEY

The first case was that of an infant who lived but twelve hours This case presented multiple, rare, congenital cardiac anomalies The aorta was atresic, its lumen measuring from 2 to 3 mm in circumference as compared to that of the pulmonary artery, which measured 17 mm The left ventricle was aplasic, and its walls were markedly hypertrophied Both the ventricular septum and the foramen ovale were closed The left auricle, like the left ventricle, was diminutive There was a subendocardial fibrous scar in the wall of the left ventricle, involving about one half of the thickness of the wall The branches of the coronary arteries were the seat of sclerosis The theories of the mechanism of production of these anomalies and their frequency were discussed

The second case was that of an infant who died at the age of 7 months This case showed complete (true) transposition of the arterial trunks (Rokitansky, type B), patent ventricular septum, pulmonary stenosis with bicuspid pulmonary valve and hypertrophy of the right ventricle

The third case was that of an infant who died at the age of 4 months This case showed that combination of congenital anomalies known as the tetralogy of Fallot, with pulmonary atresia, dextroposition of the aorta, patent ventricular septum and hypertrophy of the right ventricle

Book Reviews

TRAUMA, DISEASE COMPENSATION A HANDBOOK OF THEIR MEDICO-LEGAL RELATIONS By A J FRASER, M D, Chief Medical Officer, Workmen's Compensation Board, Winnipeg Price, $6 50 Pp 524 Philadelphia F A Davis Company, 1930

Any physician who treats a patient with an industrial injury may be called on to express an opinion of the causation of disability by the injury or of the degree of permanent disability that may result from an injury the compensatable character of which is admitted Any pathologist who makes a necropsy on the body of a workman who dies following an industrial injury, or who helps to establish a diagnosis by means of laboratory examinations, may be required to express an opinion of the relation between cause or injury and effect or disease and death Workmen s compensation, a principle widely adopted throughout the civilized world, presents problems that are important to both society and the medical profession, if justice is to be done to both employed and employer Fraser has discussed some of these problems in the book at hand

The medical reader will probably find the first chapter the most interesting in the book, in that it discusses matters not included in the usual medical text-books, such as the principle of workmen's compensation, the definition of accident, the relation of accident to employment if the injury sustained is to be compensatable and the relation of the injury to subsequent disease if an award is to be made for the latter The underlying principle of workmen's compensation is that loss of wages due to inability to work caused by injury sustained in employment is a direct charge against operating and manufacturing costs and is to be paid to the injured workman or his dependents The cost of medical care and the expense of burial constitute part of the compensation award Occupational disease falls within the scope of workmen s compensation only when specifically provided for by statute

No technical legal definition of accident as related to workmen's compensation exists Unexpectedness, suddenness and lack of intent or design are essential qualities of compensatable accident Distinct from the accident is its result, the injury that causes loss of wages through inability to work The accident must arise out of and in the course of the employment there must be a causal connection between employment and accident "Accident might arise out of the employment, but not be in the course of the employment It might occur in the course of the employment but not arise out of the employment Accidental injury to attach liability to the employer must combine both elements" The injured workman must give notice of his accident within a reasonable time of its occurrence If physical impairment, which has not been incompatible with employment, is aggravated by industrial accident, the resulting condition is compensatable Thus, the loss of a blind eye, which had not interfered with previous employment and which had to be removed because of industrial injury, has subjected the employer to a compensation award because the disfigurement interfered with obtaining other gainful occupation Continuing incapacity for work due to effects of an injury that might be overcome by operation may not be compensatable if the employee refuses to submit to operation Refusal to submit to operation is held to be reasonable if there is substantial doubt of the successful outcome of the operation or if the latter endangers life The opinion of the workman's own physician, if contrary to supposedly even more competent opinion, has been held to constitute reasonable ground for refusing to submit to a corrective operation If continued incapacity for work is the result of improper care and treatment, the employer is relieved of liability, provided he can clearly establish that the incapacity is the result of negligent treatment

Some of the most difficult problems in the adjudication of claims for compensation are those that arise from the allegation that incapacitating disease is the result or sequel of accidental trauma The onset of dementia paralytica or tabes dorsalis or the failure of a traumatically fractured bone to unite because of previously unrecognized syphilis furnishes frequent examples of such claims It is not necessary to establish that the accident was the sole cause of the disease, but only that it was in all probability a contributing factor The fact that trauma may be admitted to be an etiologic factor in the disease under consideration is not sufficient, it must be shown that the trauma was probably a factor in the particular case under adjudication There must be a direct sequence or march of events from accident to the disease alleged to be the sequel of the accident Suicide may be the basis for compensation, under the theory that the person who kills himself is insane at the time, but it must be shown that the insanity is probably the direct result of the accident, either through injury to the brain or through mental shock

In a brief discussion of medical evidence, Fraser states that such evidence may be questioned, added to or overthrown so long as the case is still open and an award has not been made A medical witness must attend if properly subpenaed If he fails to do so, he is in contempt of court and also becomes liable to a civil suit for damages instituted by the side which subpenaed him Medical testimony is privileged and the medical witness does not lay himself open to suit for slander by any statements made while testifying So long as the medical witness testifies only as to the facts in the case he is not an expert, when asked to express an opinion on a medical matter, he becomes an expert witness

The body of the volume consists of nine chapters that take up seriatim the various organ systems and discuss the role of accident in the etiology of the diseases, not injuries, of the systems The subject matter is largely a compilation from standard books The value of the work would have been greatly enhanced by less generalization about the relation of injury to disease and by more specific statements of diseases in which compensation had been allowed because a causal relationship of injury was accepted

The penultimate chapter, entitled "Occupational, Malignant, Glandular and Infectious Diseases,' is of similar character to the preceding chapters and presents little precise information that might help in determining the compensatability of the conditions discussed

The final chapter gives the percentage rating schedule for permanent disability in use in Canada and considers the factors that enter into the rating of permanent disability It is pointed out that while more or less exact figures may be given for injury to tissue and loss of function certain imponderable factors deserve equal consideration Youth and adaptability, the skill required in the work done and physical disfigurement that may decrease the workman's value in the labor market vary in each individual case

Books Received

DIE GLOBULINE Von Mona Spiegel-Adolf Assistentin am Institut fur medizinische Kolloidchemie der Universitat Wien, mit 68 Abbildungen und 300 Tabellen Price, unbound, 33 marks bound, 35 marks Pp 452 Dresden Theodor Steinkopff, 1930

A TEXTBOOK OF HYGIENE By J R Currie, M A (Oxon), M D (Glas), D P H (Birm) M A, M R C P (Edin), Professor of Public Health in the University of Glasgow Price, $8 50 net Pp 844 New York William Wood & Company, 1930

A TEXT-BOOK OF HISTOLOGY By Alexander A Maximow, Late Professor of Anatomy, University of Chicago, Completed and Edited by William Bloom, Assistant Professor of Anatomy, University of Chicago Price, cloth, $9 Pp 833, with 604 illustrations, some in colors Philadelphia W B Saunders Company, 1930

MEDICAL DEPARTMENT, UNITED FRUIT COMPANY, EIGHTEENTH ANNUAL REPORT Pp 451 Boston, 1929

TRANSACTIONS OF THE MASSACHUSETTS MEDICO-LEGAL SOCIETY ORGANIZED OCTOBER 1, 1877 Volume 6 Pp 211 Boston Massachusetts Medico-Legal Society, 1929

UEBER DIE AKUTE UND CHRONISCHE GELBE LEBERATROPHIE MIT BESONDERER BERUCKSICHTIGUNG IHRES EPIDEMISCHEN AUFTRETENS IN SCHWEDEN IM JAHRE 1927 Von Prof Dr Hilding Bergstrand, Stockholm Price, 14 marks Mit 68 Abbildungen im Text und auf 2 Farbigen Tafeln Pp 114 Leipzig Georg Thieme, 1930

J GEORGE ADAMI, VICE-CHANCELLOR OF THE UNIVERSITY OF LIVERPOOL 1919-26, SOMETIME STRATHCONA PROFESSOR OF PATHOLOGY McGILL UNIVERSITY, MONTREAL A MEMOIR By Marie Adami, together with Contributions from others, his friends Introduction by Sir Humphrey Rolleston Bart, G C V O, K C B, M D Price, $3 50 Pp 179 New York Richard R Smith, Inc, 1930

ALLERGIE DES LEBENSALTERS DER BOSARTIGEN GESCHWULSTE Von Dr Clemens Pirquet, O O Professor an der Universitat Wien Price, unbound, 23 marks, bound, 25 marks Mit 142 Abbildungen und 1 Tafel Pp 170 Leipzig Georg Thieme, 1930

MEDICINA FENNICA A ANNO MCMXXIX Edidit Societas Medicorum Fennica Duodecim, Auxilio Professoris Ordin Universitatis Gosta Becker Redigenda Curavit M I Kentele Pp 174 Helsingfors, 1930

THE PATHOLOGY OF DIABETES MELLITUS By SHIELDS WARREN, M D, Pathologist to the New England Deaconess Hospital, The New England Baptist Hospital and the Huntington Memorial Hospital, Boston, Director of Massachusetts State Tumor Diagnosis Service, Instructor in Pathology, Harvard Medical School, Boston Price cloth, $3 75, net Pp 212, with 83 engravings and 2 colored plates Philadelphia Lea & Febiger, 1930

INTESTINAL TUBERCULOSIS, ITS IMPORTANCE, DIAGNOSIS AND TREATMENT A STUDY OF THE SECONDARY ULCERATIVE TYPE By Lawrason Brown, M D Consultant, and Homer L Sampson, Roentgenographer, The Trudeau Sanatorium Saranac Lake, N Y Second edition Price, cloth, $4 75, net Pp 376, with 122 engravings and 2 colored plates Philadelphia Lea & Febiger, 1930

BIJDRAGE TOT DE KENNIS VAN DE OSTEOMYELITIS BACILLOSA BUBALORUM Door F C Kraneveld, Bacterioloog aan het Veeartsenijkundig Institut Veeartsenijkundige Mededeeling no 71 Pp 179 Utrecht Schotanus & Jens, 1930

ARCHIVES OF PATHOLOGY

VOLUME 10 DECEMBER, 1930 NUMBER 6

EXPERIMENTAL LESIONS OF THE BRAIN FROM CARBON MONOXIDE*

C B SEMERAK, M D
CHICAGO
AND
L H BACON, M D
SAN BERNARDINO, CALIF

At about the same time, and working independently, we made experiments to ascertain the effect of carbon monoxide on the central nervous system of animals[1] To avoid overlapping considerations of the literature, it seems best to combine the two reports

Accidents and deaths due to inhalation of carbon monoxide date back to antiquity Some of the clinical symptoms and pathologic changes were reported as early as the eighteenth century In an extensive compilation of the literature, Lewin[2] claimed that Troja in 1778 first described the cherry red color of the blood in carbon monoxide poisoning and that Porry in 1826 also called attention to this Bernard[3] demonstrated this phenomenon in his classes at the College de Françe, from 1847 to 1857 Since that time a voluminous literature has accumulated on this subject, especially as regards its clinical manifestations and morbid anatomy

Profound disturbances of the peripheral nerves and central nervous system following poisoning with charcoal fumes and illuminating gas have been known for a long time, and in many reviews and monographs[4] the early observations are mentioned The symptoms are of such diverse conditions as amnesia, localized paralyses, hemiplegia and com-

* Submitted for publication, June 27, 1930

* From the Norman Bridge Pathological Laboratory, Rush Medical College

1 The experiments performed by one of us (C B S) were aided by a grant (no 109) from the Committee on Scientific Research of the American Medical Association

2 Lewin, L Die Kohlenoxydvergiftung, Berlin, Julius Springer, 1920

3 Bernard, Claude Leçons sur les substances toxiques et medicamenteuses, Paris, 1857

4 The following are frequently cited

Bourdon These sur les troubles nerveux consecutifs a l'emposonnement par CO, Paris, 1843

Siebenhaar and Lehmann Die Kohlenoxydvergiftung, Ihre Erkenntnis, Verhutung und Behandlung, Dresden, 1858

Friedberg, H Die Vergiftung durch Kohlendunst, Berlin, 1866

plete dementia They may follow the poisoning immediately or may appear many days or weeks later Such sequences of gas poisoning, however, are rare They occur in only a few of the many who are poisoned with carbon monoxide

The pathologic changes reported as occurring in the organs in men and animals after carbon monoxide asphyxia are innumerable Peterson Haines and Webster [5] summarized the appearances in the human body as follows Bright patches in the skin, pulmonary edema and bright red froth in the air passages, the gastric and intestinal mucosa may also show small punctiform hemorrhages, occasionally a large hemorrhage in the great omentum and leptomeninges, multiple punctiform hemorrhages and softening of the cortex and lenticular nuclei, notably in the two internal segments, kidneys may show fatty degeneration and necrosis in the convoluted tubules Furthermore there have been reported such changes as the following dilation of the heart with the blood changes of progressive pernicious anemia (Koren [6]), extensive necrosis of the myocardium (Tesseraux [7]), unilateral and bilateral gangrene (Alberti,[8] McLean,[9] Briggs [10]), and multiple sclerosis McGurn [11] and Altschul [12] reported vascular lymphocytic infiltration of the central nervous system in four women who were asphyxiated in a burning theater

The conspicuous changes in the brain when death takes place soon after poisoning with illuminating gas, or carbon monoxide in some other form, are hyperemia, multiple small hemorrhages and the bright

---

Becker, E Ueber Nachkrankheiten der Kohlenoxydvergiftung speciell uber einen unter dem Bilde der multiplen Sclerose des Centralnervensystems verlaufenen Fall, Deutsche med Wchnschr **15** 513, 1889, Zur Lehre von den nervosen Nachkrankheiten der Kohlenoxydvergiftung, Deutsche med Wchnschr **19** 571, 1893

Sachs, W Die Kohlenoxydvergiftung, Braunschweig, 1900

Sibelius, C Die psychischen Storungen nach akuter Kohlenoxydvergiftung Monatschr f Psychiat u Neurol **18** 39, 1905

5 Peterson, F, Haines, W S, and Webster, R W Legal Medicine and Toxicology, Philadelphia, W B Saunders Company, 1923, vol 2, pp 313-314

6 Koren, A Tre tilfaelde af akut forløbende perniciøs anaemi inden samme husstand, Norsk mag f laegevidensk **52** 550, 1891

7 Tesseraux, H Ueber ausgedehnte Myokardnekrosen bei einen Fall von Leuchtgasvergiftung, Centralbl f allg Path u path Anat **42** 344, 1928

8 Alberti Ausgedehntes Gangran der Halsmuskulatur und Lahmung des rechten Beins nach Kohlenoxydvergiftung, Deutsche Ztschr f Chir **20** 476, 1884

9 McLean, A Carbon Monoxide Poisoning with Gangrene in Both Legs, J A M A **56** 1455, 1911

10 Briggs, J E Gangrene Following Carbon Monoxide Poisoning, J A M A **73** 678 1919

11 McGurn, W J Multiple Sclerosis Due to Repeated Inhalation of Carbon Monoxide in Furnace Gas, M Rec **91** 149, 1914

12 Altschul, R Die Einwirkung der Kohlenoxydvergiftung auf das Zentralnervensystem, Ztschr f d ges Neurol u Psychiat **111** 442, 1927

pink or scarlet color of the blood But if the persons poisoned live for several days, bilateral regions of softening are often found in the inner segments of the lenticular nucleus, the globus pallidus Kolisko[13] described such bilateral softening of the lenticular nuclei as a characteristic lesion of carbon monoxide asphyxia Previous to his report, this lesion had already been described by Friedberg,[14] and Poelchen[15] reported symmetrical softening in the anterior part of the lenticular nucleus in twelve brains Hill and one of us[16] reported on the study of thirty-two brains in which bilateral ischemic necrosis was uniformly present In the records of the necropsies made by Dr E R LeCount, who obtained these brains, petechial or punctiform hemorrhages in the brain and leptomeninges, stomach, intestines, peritoneum pharynx, larynx and skin are mentioned These lesions of the brain are almost always present when, as stated, death occurs several days after coma from carbon monoxide, and by many investigators have been regarded as pathognomonic for poisoning with carbon monoxide

None of the explanations of the action of carbon monoxide has been generally accepted The long slender arterioles supplying the lenticular nuclei impressed Kolisko[13] so deeply that he advanced the theory of ischemia to account for the symmetrical softenings Dilation of these arterioles, a slowed blood current edema of the brain, pressure below by the dilated, pulsating carotid arteries and absence of any other blood supply to the globus pallidus were all emphasized by Kolisko He also believed that the right angle at which the vessels arise from the carotids is an additional factor in causing the depleted supply of blood These views have been widely adopted to explain the bilateral symmetrical softening of the basal ganglions in carbon monoxide poisoning The dilation of blood vessels and the atony of the musculature in the walls of the arterioles were demonstrated by Klebs[17] many years before in the first careful study of experimental carbon monoxide poisoning

The theory proposed by Heinecke[18] that carbon monoxide acts like a ferment has not found much support A few have suggested that

---

13 Kolisko, A Die symmetrische Encephalomalacie in den Linsenkernen nach Kohlenoxydvergiftung, Beitr z gerichtl Med **2** 1, 1914

14 Friedberg (footnote 4, third reference)

15 Poelchen, R Zur Aetiologie der Gehirnerweichung nach Kohlenoxydvergiftung, nebst einigen Bemerkungen zur Hirnquetschung, Virchows Arch f path Anat **112** 26, 1888

16 Hill, E, and Semerak, C B Changes in the Brain in Gas (Carbon Monoxide) Poisoning, J A M A **71** 644, 1918

17 Klebs, E Ueber die Wirkung des Kohlenoxyd auf den tierischen Organismus, Virchows Arch f path Anat **32** 450, 1865

18 Heinecke, W Die Fermentintoxication und deren Beziehung zur Sublimat- und Leuchtgasvergiftung, Deutsche Arch f klin Med **42** 147, 1887

it may produce encephalitis [19] It has also been suggested by a number of investigators that carbon monoxide acts directly on the nerve tissues as a tissue poison [20] Haggard,[21] in his studies on carbon monoxide asphyxia, exposed cultures of nerve tissue of the chick to a concentration of 79 per cent of the gas in vitro, as no effect could be observed on the growing nerve cells, he concluded that carbon monoxide has no specific effect on nerve tissue, but acts in the body only through the asphyxia resulting from its combination with hemoglobin

The recent announcement by Haldane [22] that possibly carbon monoxide may act on cellular catalysts, replacing oxygen in this respect, will probably stimulate interest in this theory Closely related to this possibility of direct action on tissues is the conception that some tissues are particularly susceptible to the action of carbon monoxide, being especially vulnerable because of physicochemical characteristics that they possess This theory advanced by the Vogts [23] included the introduction of a new term "pathoklise" to define the predilection of the globus pallidus But this theory, as well as the designation to which it gave rise, found few advocates, in fact, some investigators are definitely opposed to the views advanced by the Vogts A suggestion has recently been made that some parts of the central nervous system are much more vulnerable than others to lowered oxygen tension [24]

The action on the walls of blood vessels to which reference has been made (Klebs [17]) has always received serious consideration in attempts to explain the action of carbon monoxide on the central nervous system The frequency in older persons of symptoms that first appear some time after the poisoning has been explained by the presence in the walls of the vessels of changes due to old age, to which are added those caused by carbon monoxide [25] McConnell and

---

19 Lesser, A Atlas d gerichtl Med **1** 144, 1884 Oppenheim, H, and Cassirer, R Die Encephalitis, Vienna, Alfred Holder, 1907, p 15 Kobert, R Lehrbuch der Intoxikationen, ed 2, Stuttgart, Ferdinand Enke, 1906, vol 2

20 Siebenhaar and Lehmann (footnote 4, second reference) Geppert, J Kohlenoxydvergiftung und Erstickung, Deutsche med Wchnschr **18** 418, 1892

21 Haggard, H W The Growth of Neuroblast in the Presence of Carbon Monoxide, Am J Physiol **56** 390, 1921

22 Haldane, J B S Carbon Monoxide as a Tissue Poison, Biochem J **21** 1069, 1927

23 Vogt, C, and Vogt, O Zur Lehre der Erkrankung der striaren Systems, J f Psychiat u Neurol **25** 633, 1920 Vogt, O Der Begriff der Pathoklise, ibid **31** 242, 1922

24 Mackay, R P Neurologic Changes Following Carbon Monoxide Poisoning, J A M A **94** 1733, 1930

25 Sibelius, C Zur Kenntnis der Gehirnerkrankungen nach Kohlenoxydvergiftung, Ztschr f klin Med **49** 111, 1903 Ruge, H Kasuistischer Beitrag zur pathologischen Anatomie der symmetrischen Linsenkernerweichung bei Kohlenoxydvergiftung (12 Falle), Arch f Psychiat **64** 150, 1921

Spiller [26] found a marked calcification in the walls of vessels supplying regions in the brain softened from carbon monoxide poisoning The patient recovered for a time after being unconscious for ten hours, but about three weeks later returned to the hospital with bilateral motor symptoms, intense spasticity and slight erythematous eruption of the face Feeding with a tube was necessary because of spasticity of the deglutitory muscles The vessels with calcified walls were within the necrotic inner segment of each lenticular nucleus Others have also commented on the calcium deposits in the arterial walls as an effect of carbon monoxide poisoning

An excellent description of some of these lesions of the brain was made by Mott [27] He found small hemorrhages in the white substance of the cerebrum due to stasis and thrombosis, and these he said resulted from the extremely small channels of the vessels, the weakened heart action and the anatomic characteristics of the vessels, their terminality and absence of anastomosis Each arteriole that perforates the cortex from the leptomeninges, as well as each in the white substance directed outward, has a brush-shaped set of capillaries altogether separate from other vessels and a separate emergent vein unconnected with adjacent veins Many writers [28] describe fatty, hyaline and other retrogressive changes in the walls of the blood vessels, for the most part the arterioles and capillaries Such alterations, it is believed, account for the atony of the muscular coats, dilation of the channels, slowing or cessation of the current of blood and also for the thrombosis observed by many who have studied these alterations of the brain The opinion has also been expressed that anoxemia, which after all is at the bottom of all the untoward effects of carbon monoxide as a poison, may first so

26 McConnell, J W, and Spiller, W G A Clinicopathologic Study of Carbon Monoxid Poisoning, J A M A **59** 2122, 1912

27 Mott, F W Punctiform Hemorrhages in the Brain in Gas Poisoning, Proc Roy Soc Med, London **10** 73, 1916-1917, Brit M J **1** 637, 1917, Carbon Monoxide and Nickel Carbonyl Poisoning The Systematic Examination of the Cerebral Nervous System in a Case of Poisoning by Illuminating Gas, and Two Fatal Cases of Poisoning Occurring in the Carbonyl of Nickel Works, Arch Neurol Path Lab, London County Asylum, Claybury, London **3** 246, 1907

28 Klebs (footnote 17) Poelchen, R Gehirnerweichung nach Vergiftung mit Kohlendunst, Berl klin Wchnschr **19** 396, 1882, footnote 15 Cramer, A Anatomischer Befund im Gehirn einer Kohlenoxydvergiftung, Centralbl f allg Path u path Anat **2** 545, 1891 Herzog, G Zur Pathologie der Leuchtgasvergiftung mit macro- und mikroskopischen Demonstrationen, Munchen med Wchnschr **67** 558, 1920 Weimann, W Ueber Hirnpurpura bei akuten Vergiftungen, Deutsche Ztschr f d ges gerichtl Med **2** 543, 1923 Grinker, R R Ueber einen Fall von Leuchtgasvergiftung mit doppelseitiger Pallidumerweichung und schwere Degeneration des tieferen Grosshirnmarklagers, Ztschr f d ges Neurol u Psychiat **98** 433, 1925

influence the vasomotor centers in the brain that dilation of the vessels precedes all the other modifications in their walls or in the circulation through them.[29]

Many attempts have been made to produce cerebral lesions in animals by exposing them to illuminating gas. Mice, guinea-pigs, rabbits and dogs have been used. With acute poisoning, hyperemia of the brain has been regularly observed,[30] and with chronic poisoning bilateral softenings in the basal ganglions. When dogs, monkeys and cats are exposed to illuminating gas,[31] disturbances in gait or vision occur in some of the animals, and degenerative changes in the globus pallidus, the white matter and the cortex have been noted by a few investigators.

In the experiments by Grunstein and Popova,[32] the inhalation by rabbits and cats of carbon monoxide in concentrations of from 1 to 4 per cent was followed by paralysis of the hind legs. Microscopically, marked degenerative changes were found in the cord and cerebellum with, in some of the animals, lesions in the substantia nigra, nucleus ruber and the olive; in one, a focal lesion was found in the cortex of the frontal lobe.

Capillary hemorrhages were observed in the brains of dogs by Claude.[33] Chronic encephalitis manifested by perivascular infiltration was reported by Spirtow and Chardin (cited by Lewin[2]). Sibelius,[34] described acute and chronic encephalitis and also foci of ischemia or degeneration due to changes in the arteries.

EXPERIMENTS

In an effort to produce bilateral softening of the basal ganglions one of us (C. B. S.) made the following experiments. Pure carbon monoxide or illuminating gas in high percentage was given to six rabbits and three guinea-pigs by repeated intravenous, intra-arterial or

29 Ford, F. R.: An Experimental Investigation into the Effects of Asphyxia on the Brain, with Especial Reference to Asphyxia Neonatorum, Bull. Johns Hopkins Hosp. **42**: 70, 1928. Hiller, F.: Ueber die krankhaften Veranderungen im Zentralnervensystem nach Kohlenoxydvergiftung, Ztschr. f. d. ges. Neurol. u. Psychiat. **93**: 594, 1924.

30 Photakis, B. A.: Anatomische Veranderungen des Zentralnervensystems bei Kohlenoxydvergiftungen, Vrtljschr. f. gerichtl. Med. **62**: 42, 1921.

31 Meyer, A.: Experimentelle Erfahrungen uber die Kohlenoxydvergiftung des Zentralnervensystems, Ztschr. f. d. ges. Neurol. u. Psychiat. **112**: 187, 1928.

32 Grunstein, Z. M. and Popova, Nina: Experimentelle Kohlenoxydvergiftung, Arch. f. Psychiat. **85**: 283, 1928.

33 Claude, Henry: On Nature of Nerve Injuries Caused by Carbon Monoxide Poisoning, Tr. Internat. Cong., 1913, London, sect. 11, Neuropath., pt. 2, 1914, p. 343.

34 Sibelius (footnote 4, sixth reference, footnote 24).

intra-abdominal injections, under a glass globe The carbon monoxide used was produced by the action of sulphuric acid on oxalic acid, the carbon dioxide being absorbed by running the gas through a solution of potassium hydroxide, then washing it in distilled water and finally drying it by means of a calcium tube The illuminating gas used contained about 17 per cent carbon monoxide

The amount of gas given intravenously was from 10 to 25 cc , the amount given intraperitoneally or by inhalation was from 120 to 480 cc Two experiments were performed weekly, making from seven to forty-two in the different animals Necropsies were performed immediately if possible, otherwise within a few hours after death Pieces were taken from many organs and hardened in neutral 10 per cent formaldehyde solution Sections of the visceral organs were stained with hematoxylin and eosin The brain, medulla, spinal cord and cerebellum were cut in various regions, and the sections were further stained with the sudan III, hematoxylin-phosphotungstic acid, Weigert-Pal, Marchi Del Rio Hortega and Mann stains There were no changes in the animals that received intravascular injections The intraperitoneal injections produced slight alterations Hyperemia of all organs and cherry red color of the blood were present in all animals gassed by inhalation Capillary hemorrhages in the lungs with fatty infiltration of the liver was found in one rabbit and one guinea-pig, in two rabbits there was a slight perivascular lymphocytic infiltration of the brain, medulla and spinal cord In most animals there were no clinical manifestations except coma, in two rabbits and a guinea-pig, a fleeting paralysis of the hindlegs was noticed The results of these experiments proved unsatisfactory The paucity of changes thus obtained could have apparently only one explanation, that rabbits and guinea-pigs eliminate carbon monoxide before serious pathologic changes take place Therefore other experiments, in which five rabbits four guinea-pigs and three dogs were used, were begun

All the animals were subjected almost daily to a weak current of illuminating gas until they were completely unconscious The exposures lasted for from forty-five minutes to four hours In the course of these experiments, the endeavor was made to ascertain the difference in resistance to the gas and in time of elimination of it, in the different animals

The percentage of carbon monoxide in the blood was measured every fifteen to twenty-five minutes from the moment unconsciousness took place until carbon monoxide hemoglobin was zero A rapid drop was noticed during the first hour, down to 40 per cent in the dogs, 25 per cent in the guinea-pigs and 20 per cent in the rabbits, during the second and especially the third hour the gas was eliminated more

slowly (fig 1) The weight was recorded twice a week, there was considerable loss in the dogs as compared with the rabbits and guinea-pigs

In the fresh and hardened brains there were no visible changes grossly, except hyperemia By microscopic examination, bilateral ischemic necrosis was found in the central nuclei in one dog one rabbit and one guinea-pig

The dog had been gassed for twenty-two hours from November 29 until December 21 and had lost during this period 4 pounds 2 ounces (1 85 Kg) from the original weight, 13 pounds 12 ounces (6 2 Kg) Microscopic examination of the brain revealed a region of marked ischemic softening involving the whole lenticular nucleus and more than one half of the thalamus The ganglion cells in this region consisted

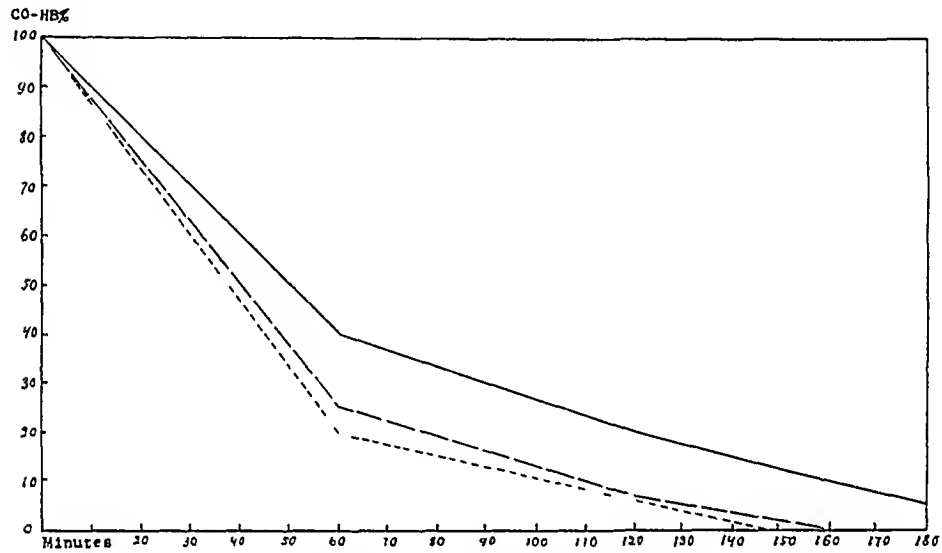

Fig 1 —The rate of elimination of carbon monoxide from the blood of dogs, guinea-pigs and rabbits The solid line represents the rate in dogs, the dash line, that in guinea-pigs, and the dotted line, that in rabbits

of long, narrow, elliptic structures, very dark-staining and in various stages of karyorrhexis, at the periphery of the focus of necrosis the cells were swollen and pale, the Nissl granules had completely disappeared, and in some cells the body was a faint shadow without visible nucleus or nucleolus Many of the Betz giant cells had suffered similar retrogressive changes The pyramidal cells of the cortex were shrunken their nuclei narrow and triangular their dendrites very dark staining and visible for a long distance Purkinje's cells varied in size and shape, their cell bodies were sharp edged, the nuclei pale and vesicular, occasionally a short, swollen, pale dendrite was seen Similar changes were found in the cells of the anterior horns of the spinal cord The glia cells and fibrils were not noticeably changed In all sections of the brain, cerebellum, medulla and spinal cord there were small, perivascular

and capillary hemorrhages, from one to four per square centimeter, a few small hemorrhages were also seen in the cerebral leptomeninges All the veins were distended with erythrocytes, the arteries in general being empty The larger arteries in several sections of the brain stem were fenestrated and sclerosed, many calcified, the lime deposit completely replacing the vascular substance, especially in sections through the brain stem and cerebellum

The microscopic changes in the central nervous system of the rabbit and guinea-pig, where the exposure to carbon monoxide had produced a bilateral ischemic necrosis, were similar in all respects save an absence of calcification of the arteries The rabbit was exposed for sixty hours to carbon monoxide and lost 1 pound (0 5 Kg) in weight during that period, the guinea-pig, gassed for eighty-two hours, lost only 1 ounce (0 05 Kg)

Petechial or perivascular hemorrhages of the brain or leptomeninges were present in two dogs, two rabbits and four guinea-pigs, perivascular lymphocytic infiltration in two dogs and two rabbits, and sclerosis of the cerebral arteries in two dogs and one guinea-pig More or less atrophy of the large ganglion cells was found in all animals, as well as hyperemia of the brain and leptomeninges Except for hemorrhages in the lungs and fatty changes in the liver, the visceral changes were insignificant

From these few experiments it appears as though changes caused by carbon monoxide differ in different animals This may be due to individual variations of tolerance or resistance According to Douglas, Haldane and Haldane [35]

> When a solution of Hb, whether enclosed in blood corpuscles or free, is saturated in the presence of a gas mixture containing O_2 and CO, the ratio of oxyhemoglobin to carbon monoxide hemoglobin is always proportional to the relative partial pressure of O_2 and CO It is not altered by the presence of CO_2 or slight changes in reaction or of reduced hemoglobin or by dilution However, it is appreciably altered by temperature as well as by light and varies distinctly in the hemoglobin of different individuals and species

Furthermore, some of these animals repeatedly gassed to complete unconsciousness for short periods with a high concentration of carbon monoxide suffered only slight organic changes in comparison with those subjected to highly diluted carbon monoxide gas for from one to several hours at a time This confirms the observations of Nicloux [36] that

35 Douglas, C G , Haldane, J S, and Haldane, J B S The Laws of Combination of Hemoglobin with Carbon Monoxide and Oxygen, J Physiol **44** 275, 1912

36 Nicloux Maurice L'oxyde de carbone et l'intoxication oxycarbonique Étude chimico-biologique Paris, Masson & Cie, 1925

the changes in the organs depend not on the concentration of carbon monoxide in the blood, but on the length of time of exposure even to small quantities of the gas

So far as these experiments indicate, rabbits are especially resistant to carbon monoxide, judging by the few lesions after so many and such long exposures That there is a great difference in the hemoglobin's affinity for carbon monoxide and for oxygen in various species and also in the various individuals of a species has also been demonstrated by Anson, Barcroft, Mirsky and Omuma [37] According to one of their charts, the hemoglobin's affinity for carbon monoxide decreases in various animals and man as follows Dog, horse, mouse, cat, man, fowl, rat, tortoise, sheep, lizard, roach, frog and rabbit They also noticed a difference in individual rabbits In experiments carried out in the Bureau of Mines, Burrell and Seibert [38] found that with 0 25 per cent carbon monoxide a small dog was in distress within fifteen minutes, but a rabbit showed no distress after two hours and twenty minutes Guinea-pigs gave variable results, some showing distress within from ten to twenty-two minutes, while one was only slightly affected in two hours and another not at all after four hours

The symptoms in the animals in these first experiments were defecation and urination immediately before loss of consciousness took place In the rabbits there was furthermore a fleeting paralysis of the hind legs, lasting from five to fifteen minutes The dogs were dazed and helpless from thirty to forty minutes after each gassing, tottering about as if intoxicated, and there was repeated vomiting during and after each experiment, nor would they partake of food for several hours afterward The guinea-pigs suffered only rarely a fleeting paralysis of the hind legs, never lasting more than from four to eight minutes All the rodents ate voraciously immediately after recovery That no clinical symptoms were observed in the first series of our experiments may have been due to the quantities of gas used, 480 cc being the maximum that could be administered intra-abdominally without too much distention Lewin claimed that 500 cc of carbon monoxide is necessary for intra-abdominal injections to produce symptoms of poisoning in a rabbit In the second experiment made to ascertain the rate of elimination, marked difference in the metabolism of the dogs as compared with rodents was noted Whereas in the former there was a loss of weight

37 Anson M L, Barcroft, J, Mirsky, A E, and Omuma S On the Correlation Between the Spectra of Various Hemoglobins and Their Relative Affinities for Oxygen and Carbon Monoxide, Proc Roy Soc, London **97** 61, 1924

38 Burrell, G A Seibert, P M, and Robertson, I W Relative Effects of Carbon Monoxide on Small Animals, Bureau of Mines Technical Paper 62 1914

of from 4 pounds 2 ounces to 9 pounds 2 ounces (1 85 Kg to 4 15 Kg), according to their size, in the rabbits the decrease of weight after a much longer period of gassing was only from 8 ounces (0 2 Kg) in one to 1 pound (0 5 Kg) in another, and two rabbits preserved their normal weight throughout the experiments Of the three guinea-pigs, one showed a reduction of 1 ounce (0 025 Kg) in weight This marked loss of weight in the dogs may be attributed to their frequent vomiting during and after each experiment Another explanation has been offered by Glaubitz,[39] who also noticed a decreased weight in his animals after thirteen days and found that the elimination of nitrogen far exceeds the intake of nitrogen from the food He also mentioned a number of other investigators who found a definite increase in the destruction of protein during their experiments with carbon monoxide

Apparently with the exception of the experiments by Klebs,[17] neither illuminating gas nor any of its components has been injected directly into the common carotid artery of animals An attempt was therefore made by one of us (L H B) to determine the nature of the changes produced in the brains of animals with the injection of pure carbon monoxide into one of the common carotid arteries [40] For this purpose, dogs were used, and carbon monoxide was generated by the action of a few cubic centimeters of formic acid (85 per cent) on 10 cc of concentrated sulphuric acid [41] The gas was passed through a soda lime absorption tube, the first 250 cc discarded, and the rest collected, by displacing water, in 50 cc glass tubes These tubes, after the rubber connections were tightly clamped, were stored under water so that any leak would be readily detected This method of making carbon monoxide has the advantage that relatively small quantities, from 1 to 2 liters, are obtained without admixture of carbon dioxide This gas was analyzed for its air content by the Haldane method [27], 1 2 per cent of air was present The amount desired for injections was drawn into a sterile syringe by displacing the carbon monoxide in the tube with sterile water

Under ether anesthesia, and with measures to secure asepsis, the left common carotid artery of dogs was isolated and carbon monoxide injected, some dogs were given a mixture of equal parts of air with carbon monoxide Five of the sixteen dogs receiving carbon monoxide exhibited symptoms Their character and severity apparently were related to a ratio between the amount of carbon monoxide injected and

39 Glaubitz, G Ueber Eiweisszerfall bei Vergiftungen, Ztschr f d ges exper Med **25** 230, 1921

40 Dr G Rukstinat assisted me in these operations L H B

41 Nicloux (footnote 35, p 23)

the weight of the animal Undoubtedly, the amount of hemoglobin in the animals bore some definite relation to weight Several cubic centimeters, e g , 6, caused symptoms in a small, but not in a heavier dog Convulsions occurred a few hours after the injection They were preceded by marked restlessness and irritability, the animal running aimlessly about, then becoming listless and finally lying down Then, without bark or warning cry, convulsions appeared, with the head thrown back and the back arched When the animal stood up on his hind legs, he was thrown over on his back, where he lay panting and jerking spasmodically Sometimes such symptoms were accompanied by a running motion of the front legs, as many as one hundred movements being made a minute, the hind legs quiet, spastic and stretched out straight A convulsion lasted several minutes and was followed by quiet exhaustion and dyspnea, the animal lying on one side Then another convulsion developed As one after another took place, their duration lessened to half a minute Alternating with the periods of exhaustion, the convulsions continued in some animals for from two to twelve hours, or until death During the convulsions the animals were unconscious After such attacks as these none of the animals recovered The symptom in one animal was simply a belligerency not previously shown and disappearing altogether after ten days Another walked exclusively to the right shortly after the operation, but only for a few hours and the next day was normal In a third, the only trouble seemed to be muscular weakness, which came on eight days after the gas was injected The gait was unsteady and the animal was prone to fall to one side or the other

So far as known, the death of one dog was not accompanied by convulsions This death occurred twenty-four hours after a second injection with an interval of eleven days between it and the first When this second injection was made, bubbles of gas were seen in the adjacent jugular vein, as well as in all the other veins exposed by the operation After death, the lining of the rectum was deep purple, and minute, bright red hemorrhages were found in the epicardium at the apex and ventrally, in the superficial substance of the liver and in the papillary muscles of the mitral leaflets [42] Alternating bright red and dark purple blood in the coronary veins gave them a beaded appearance

In two other dogs, gas bubbles were noted in the adjacent jugular vein One was killed several hours after the injection of carbon mon-

42 A number of observers (see Gey R Zur pathologischen Anatomie der Leuchtgasvergiftung, Virchows Arch f path Anat **251** 95, 1924) have noted these hemorrhages in the heart They are probably mechanical and associated with the dilation of the heart, as well as with dilation of the small vessels where bleeding occurs

oxide The capillaries in the anterior papillary muscle of the mitral leaflets were distended The other dog was killed seven days after the administration of pure carbon monoxide One dark, well circumscribed hemorrhage, 1 5 mm in diameter, was on the convex surface of the right lobe of the liver In a dog dying from six to fifteen hours after the injection and in the one with distended capillaries in the papillary muscle, the smallest arteries and veins in the pia mater contained globules of gas

Hyperemia of the outside of the brain was present in dogs dying from six to eight hours after injection or in those killed from three to seven days later The veins were markedly distended and filled with dark red blood, especially the middle cerebral veins Over the entire brain the smallest ramifications of the blood vessels were distinct Only one brain was a bright cherry red It came from the dog dying from six to fifteen hours after receiving carbon monoxide, during the hours before death, there were many severe convulsions A few hemorrhages, from 2 to 5 mm in diameter, in the pia mater were also noted, with hyperemia on each side, more along the top, not far from the longitudinal fissure and a few centimeters posterior to the frontal poles A few were found over the occipital lobes, often in the most posterior portion These hemorrhages were well defined and a dusky reddish brown

With the hyperemia and hemorrhages in the pia mater there was pronounced stippling of the surfaces of segments made by coronal sectioning, the stippling was fairly symmetrical and more prominent in the white matter In about one half of the brains there were also punctate hemorrhages in the white matter and cortex, the larger ones usually in the gray matter, and 1 5 mm in diameter In dogs dying within twenty-four hours, the hyperemia was more marked on the side of injection One dog killed after three days showed engorgement of blood vessels with punctate hemorrhages in the white matter, cortex, caudate nuclei and thalamus, a diffuse grayish-brown color throughout the left lenticular nucleus, scattered similar regions of discoloration in the right nucleus, one brown discoloration in the ventral tip of the left caudate nucleus, and an extremely dark gray area in the cortex, lateral to the right thalamus, with numerous distended blood vessels about it In another brain there was a region of punctate hemorrhages in the middle of the left caudate nucleus The surfaces of the cerebellum, pons medulla and regions of the substantia nigra were frequently peppered with engorged blood vessels and occasional hemorrhages In the medulla of one dog there were four small hemorrhages

The caudate nuclei of normal dogs stand out as well defined regions One change of particular interest in seven of the sixteen brains was a partial or total loss of this sharp demarcation This was observed from three to ten days after the injection of carbon monoxide In the more anterior sections of the brain, the heads of the caudate nuclei were white and readily distinguished from the remaining gray portion but posteriorly the nuclei were colorless and the boundary between them and the adjacent white matter was indefinite This alteration was always bilateral, although more on one side as a rule It was the only change found in the brain of one dog killed after the injection of 5 cc of carbon monoxide A similar discoloration of the gray substance of the thalamus occurred in a few dogs, in one it was complete on both sides, in the others, there was simply a vague external boundary

The lenticular nuclei normally varied in color from pale gray to yellow In the left lenticular nucleus in the brain from one dog there was a cavity, while in the right one there were three, those in the right side being farther anterior These were round or oval and from 1 to 3 mm in diameter, the immediately adjacent brain substance was creamy white The left lenticular nucleus appeared to be connected with the caudate nucleus by a friable band of tissue traversing the middle of the internal capsule In another brain there was a fragmented, depressed, reddish-brown region bounding the caudate nuclei and extending laterally to the ventricle On the left side, the anteroposterior length was 8 mm, on the right, 7 5 mm The gray matter of the lenticular nuclei was poorly defined in the brains from some dogs killed eight days or later after injection In a third brain there was a well circumscribed soft, gray region several millimeters in diameter external to the right lenticular nucleus, with similar softenings outside both thalami (fig 2) In a fourth brain there were cavities or soft places the consistency of curdled milk from 1 5 to 6 mm in diameter in the white substance outside each lenticular nucleus and, on one side, extending down into or close to Ammon's horn

In a fifth brain were found two small cavities in the cortex, a few millimeters in diameter, and several to the right of the midline in the coronal segments that included parts of the thalami They were empty, had ragged walls and were connected by a narrow bridge of friable cortex In another dog killed twenty-four days after the injection of carbon monoxide, the only gross change was a soft cortex of the left occipital lobe not well demarcated from the normal adjacent tissue No gross changes were discovered in the brains of three dogs receiving 3 5, 5 and 15 cc of carbon monoxide and killed after six, nine and sixteen days, respectively

The acute distention of blood vessels in all organs of the body following the breathing of illuminating gas has been attributed to the carbon monoxide in the gas Since this evidently occurs in the lungs, hemorrhages being commonly seen in the lungs of persons who die from carbon monoxide, the question arose whether the poisonous gases containing carbon monoxide or mixtures of such gases with air may enter the blood stream directly through minute lacerations in the vessels and pass along into the circulation by the pulmonary veins as emboli Such emboli of air with carbon monoxide, perhaps, are swept into the general circulation so as to plug the small arteries in the brain On the morning following the injection of an equal mixture of carbon mon-

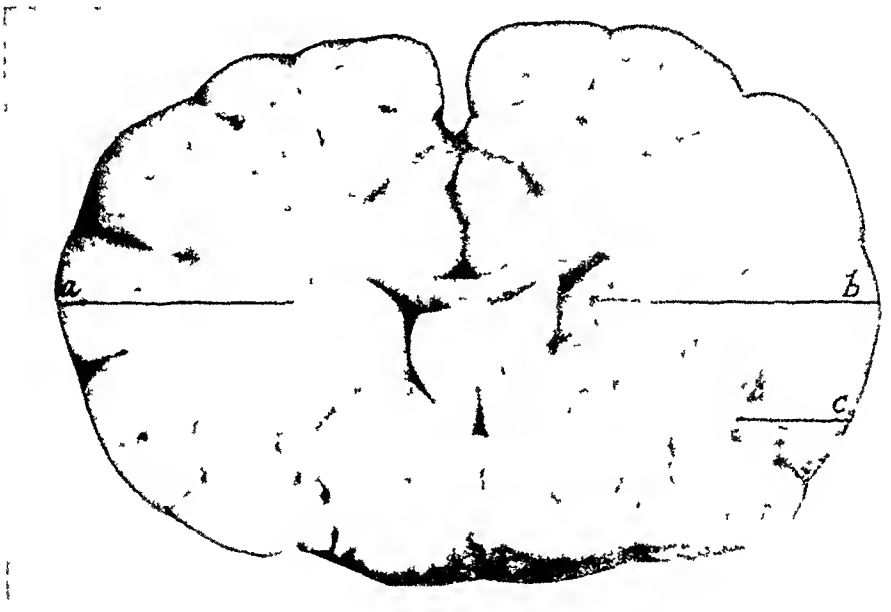

Fig 2—A coronal section 27 mm posterior to the frontal poles in the brain from a dog dying twelve hours after the introduction of 15 cc of carbon monoxide The stippling is marked The letter *a* indicates the grayish-white left caudate nucleus, *b*, distended blood vessels in the right caudate nucleus, and *c*, softening in the cortex lateral to the right lenticular nucleus These softenings are bilateral, but not always at the same front-to-back level

oxide with air, one dog lay in his cage, all four extremities stretched out straight, the respirations were shallow and rapid No one saw the dog during the night, so that it is not known whether there had been convulsions The dog was killed about twenty-two hours after the operation The outside of the brain was hyperemic, but except for engorged vessels in the frontal lobes and the left lenticular nucleus the substance was normal grossly In another dog a similar mixture caused no disturbance This dog was killed four days later There was marked hyperemia in all of the coronal surfaces made by sectioning the brain

Above the left caudate nucleus were two small cavities, 1 mm in diameter, spherical and smooth inside, in the left occipital lobe were two extremely soft regions in the white matter, with anteroposterior diameters of 9 to 20 mm, the longer extending to the most posterior portion of the cerebrum

It has been suggested that the convulsions which occasionally are seen in whooping cough are caused by air embolism,[43] that during such severe spasms of coughing the lung capillaries are torn by the great intrapulmonic pressure and air enters the pulmonary veins Husler and Spatz[44] described degenerative changes in the cortex, especially that of the cornu ammonis, in the brains of children dying of whooping cough, and similar cortical damage in criminal abortion[45] has been ascribed to an embolism of the brain For these reasons, control experiments were made by injecting air into one carotid artery in dogs More pressure is required to force air into circulating blood than is needed with carbon monoxide Air tends to enter spasmodically, and the artery for a time remains distended and colorless With carbon monoxide the blood column remains continuous and no gas is visible

In three of six dogs receiving air convulsions occurred Following a shrill cry, the head was thrown forcibly backward, and there was a rapid running movement in the fore legs In one dog, only the right fore leg had this movement The hind legs were as a rule, motionless but occasionally irregular purposeless movements took place With 10 cc of air, the convulsions were severe, and usually death followed in from two to seven hours In one dog, 10 cc produced no symptoms, in another, marked restlessness Smaller amounts of air (5 cc) caused convulsions in some of the dogs and death from five to ten hours later Dogs in which convulsions were produced died With death after several hours most of the blood vessels in the leptomeninges were beaded with air In one brain, this was so pronounced that there was little blood left in the pial vessels The air was in the smallest arteries, as well as in the veins, and either equally distributed on both sides or more on the side of injection

In one brain, a lesion similar to those following the injection of carbon monoxide was in the outer portion of one thalamus, also a small

---

43 Neuburger, K Ueber cerebral Fett- und Luft- Embolie, Ztschr f d ges Neurol u Psychiat **95** 278, 1925

44 Husler, J and Spatz, H Die Keuchhusten-Eklampsie, Ztschr f Kinderh **38** 428 1924

45 Weimann, W Gehirnbefunde bei septischer Allgemeininfektion (nach kriminellen Abort), Ztschr f d ges Neurol u Psychiat **11** 242, 1928 Spielmeyer, W Ueber die anatomischen Folgen der Luftembolie ins Gehirn, Verhandl d Kong f inn Med **30** 359, 1913

dark hemorrhage, several millimeters in diameter, was in the left dentate nucleus In another, disseminated punctate hemorrhages were in the cortex and white matter of all the coronal segments The last two dogs had no convulsions and were killed after ten and fourteen days, respectively In a third dog dying about six hours after the injection of air one solitary bright hemorrhage, several millimeters in diameter, was in the cortex near the top of the brain In another dying after eight hours a soft region was found in the cortex of the left side, at the level of the thalamus In the fifth there was softening in the cortex The sixth dog lived fourteen days after receiving 10 cc of air, and the brain was unchanged

CONCLUSIONS

These experiments demonstrate that the effect of carbon monoxide varies in different animals, that it is rapidly eliminated by rabbits and guinea-pigs, that rabbits are especially resistant to the gas and that the weight of the animals, the amount of the gas and the manner of administration modify its action

Symmetrical lesions in the brains of the dogs and more rarely in those of guinea-pigs and rabbits, lesions resembling those occasionally found in human brains may be produced experimentally by injecting the gas into the arterial blood stream or by having the animals inhale pure carbon monoxide, or illuminating gas

When pure carbon monoxide is injected into the blood stream it combines so rapidly with the hemoglobin that gas embolism does not occur or at least not with doses such as were injected in these experiments

Ten cubic centimeters of air alone injected into the carotid arteries of dogs causes severe convulsions, is more frequently and speedily fatal than a similar amount of carbon monoxide, and results in fewer gross changes these being rarely in the basal ganglions

A STANDARDIZED PROCEDURE SUGGESTED FOR MICROSCOPIC STUDIES ON THE HEART

WITH OBSERVATIONS ON RHEUMATIC HEARTS *

LOUIS GROSS, M D

WILLIAM ANTOPOL, M D
George Blumenthal Jr, Fellow in Pathology
AND
BENJAMIN SACKS, M D
Emanuel Libman Fellow
NEW YORK

It is exceedingly difficult at present to compare statistical data reported in various histologic studies of pathologic hearts The principal difficulty seems to be due to the fact that the changes are often reported without consideration of their exact location in the heart For example, the discrepancies in the reported incidence of Aschoff bodies, myocardial softening or scarring, vascular lesions, inflammatory foci, etc, may to a considerable extent be accounted for both by the difference in the number of sections studied by the various workers and by the difference in the sites from which the tissues were removed

In the course of examining a large number of human hearts we have developed a simple procedure for cutting tissues, which it is believed shows a maximum number of lesions in a minimum number of blocks of tissue These blocks are cut from definite topographic sites in the heart and are so designed that each block includes certain "strategic" sites, i e areas which experience has shown are frequently the seat of disease It is not suggested that investigators confine themselves to the study of these blocks only They could be considered to advantage, however, as a sort of common denominator for the purpose of statistical comparisons

We shall present the method that we employ, with a brief histotopographic description of the more important structures to be found in each section In this description, it will be necessary to use a terminology that may be unfamiliar or indeed in some instances new We believe it advisable, however that some such terminology be adopted in order to avoid confusion in the future

---

Submitted for publication, April 14, 1930

From the Laboratories of the Mount Sinai Hospital

* This work was aided by a grant from the Lucius N Littauer Foundation

In order to illustrate the advantages of the different sections, we shall indicate the relative incidence of vascular lesions (arteriosclerotic), myocardial scarring and Aschoff bodies in each area as found in a study of thirty-seven rheumatic hearts, all of which contained Aschoff bodies

METHOD

It is desirable that at least two sections from each block be stained, one with hematoxylin and eosin and the other with some good stain for differentiating elastic and fibrous connective tissue, such as Weigert's stain for elastic tissue and van Gieson's for fibrous tissue, or Weigert's for elastic tissue and Masson's erythrosin-saffron, etc We seldom employ the Unna-Pappenheim methyl-green-pyronin stain, as this often leads to greater confusion From time to time it will be necessary to use a good bacterial stain, such as the MacCallum-Goodpasture or azure-B, also a stain for fibrin, such as Weigert s, or Mallory's phosphotungstic hematoxylin

Before the blocks are cut, the heart should be fixed in a neutral formaldehyde sodium chloride solution [1] or a formaldehyde solution of Mueller [2] If the tissues are fresh (less than six hours post mortem), Bouin's fluid will be found excellent For special purposes, small blocks may be immediately fixed in alcohol

The heart is opened in the customary manner, and after fixation the following blocks are cut (1) left auricle (L A) [3], (2) mitral posterior (M P), (3) posterior papillary muscle, left (P P M), (4) aorta, aortic valve and mitral valve (A M V), (5) pulmonary artery and valve (P A V), and (6) tricuspid valve and septum (T V)

In the following descriptions, when referring to "left" or "right" we have in mind the *anatomic* "left" or "right" of the heart As far as possible the terminology of Basle Nomina Anatomica will be used

Left Auricle (L A)—With a pair of scissors, a transverse cut, approximately 3 cm in length, is made from the posterior cut border of the left auricle toward the interauricular septum approximately 1 cm above the insertion of the posterior flap of the mitral valve (fig 1) A cut is made parallel to this, approximately 3 mm [4] above the first The right border of the narrow slab is severed with a knife

Histotopographically (fig 2), this section shows the left auricular endocardium (*A*), the left auricular subendocardium (*B*), the left auricular myocardium (*C*), the pericardium (*D*) and sometimes, the coronary sinus (*E*)

Mitral Posterior (M P)—Starting from the slot from which the left auricular section was removed, a vertical cut is made with a scalpel downward toward the apex of the heart so that the blade passes through the posterior leaflet of the mitral valve and the subjacent myocardium (through its entire thickness) at

---

1 Solution of formaldehyde, U S P, 10 parts, 1 per cent sodium chloride solution, 90 parts This solution is rendered neutral with a weak alkali

2 The formaldehyde solution of Mueller (Formol-Mueller) is prepared as follows potassium bichromate, 2 parts by weight, water, 100 parts, solution of formaldehyde, U S P, 10 parts The "solution of formaldehyde" is added just before use

3 The letters in brackets are convenient abbreviations for designating the sections on the slide

4 All slabs are cut about 3 mm thick

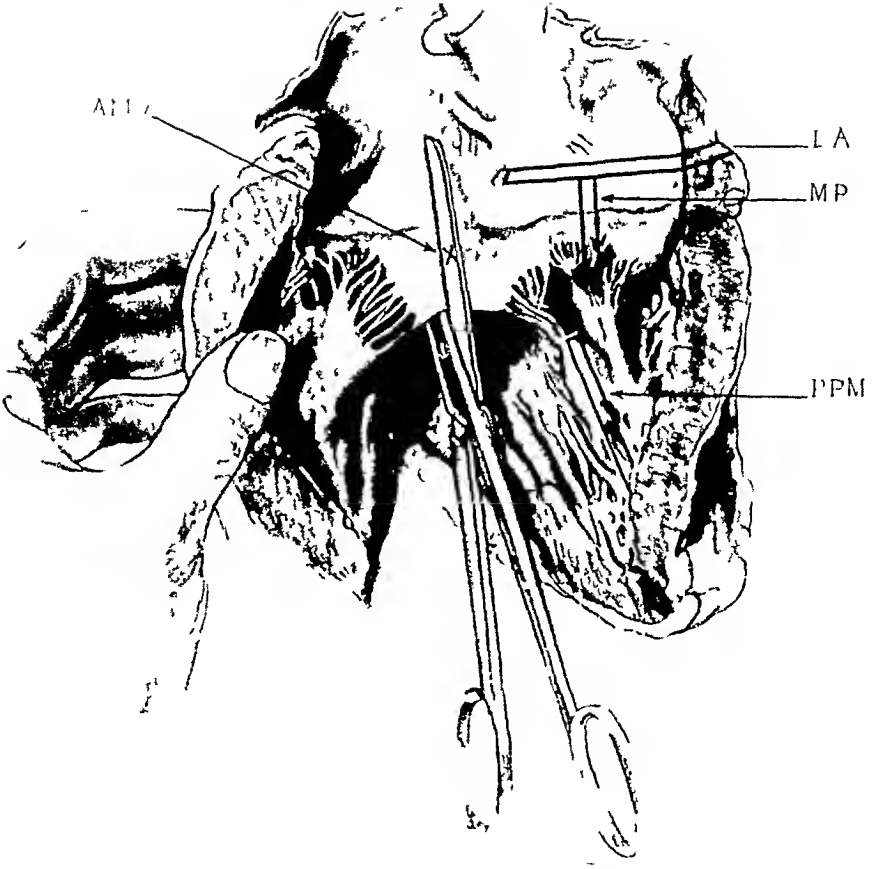

Fig 1—Diagram of left auricle and ventricle (left inflow tract) showing the method of cutting the left auricle mitral posterior, left posterior papillary muscle, and aorta, aortic valve and mitral valve blocks

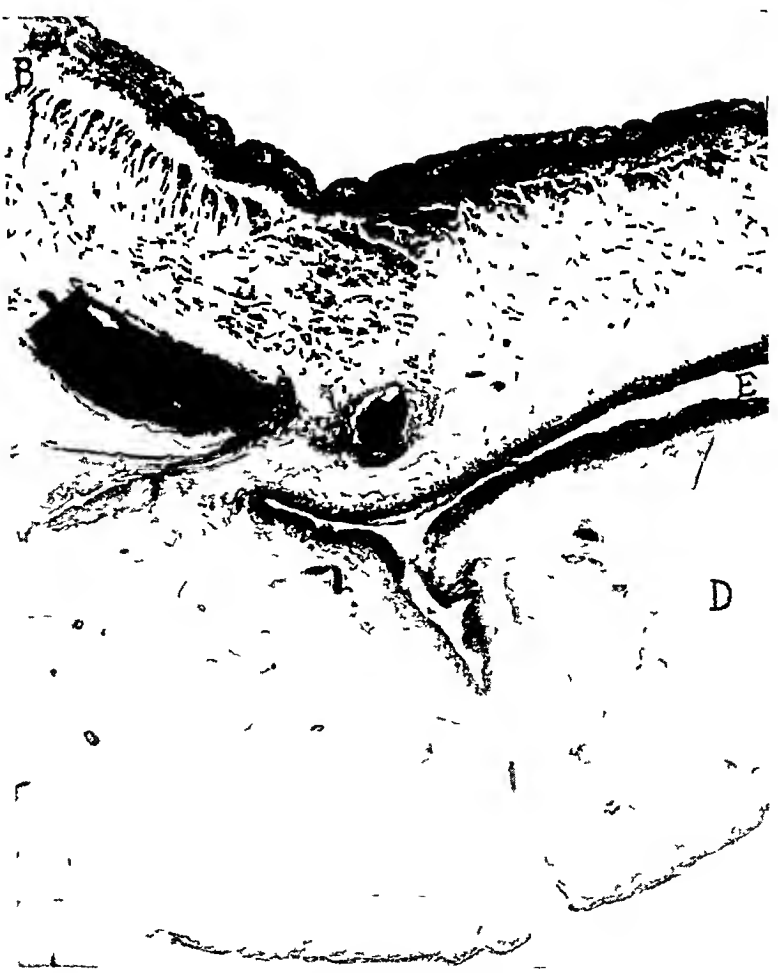

Fig 2—Low power magnification of left auricle (L A) section *A* indicates the left auricular endocardium, *B*, the left auricular subendocardium, *C*, the left auricular myocardium, *D*, the pericardium, and *E*, the coronary sinus

about the region indicated in figure 1 The cut is carried through the myocardium to about 3 mm below the free edge of the valve A parallel cut is then made and the block removed in the usual manner

Histotopographically (fig 3), this section shows Left auricular endocardium (*A*) Left auricular subendocardium (*B*) Myocardial wedge of the

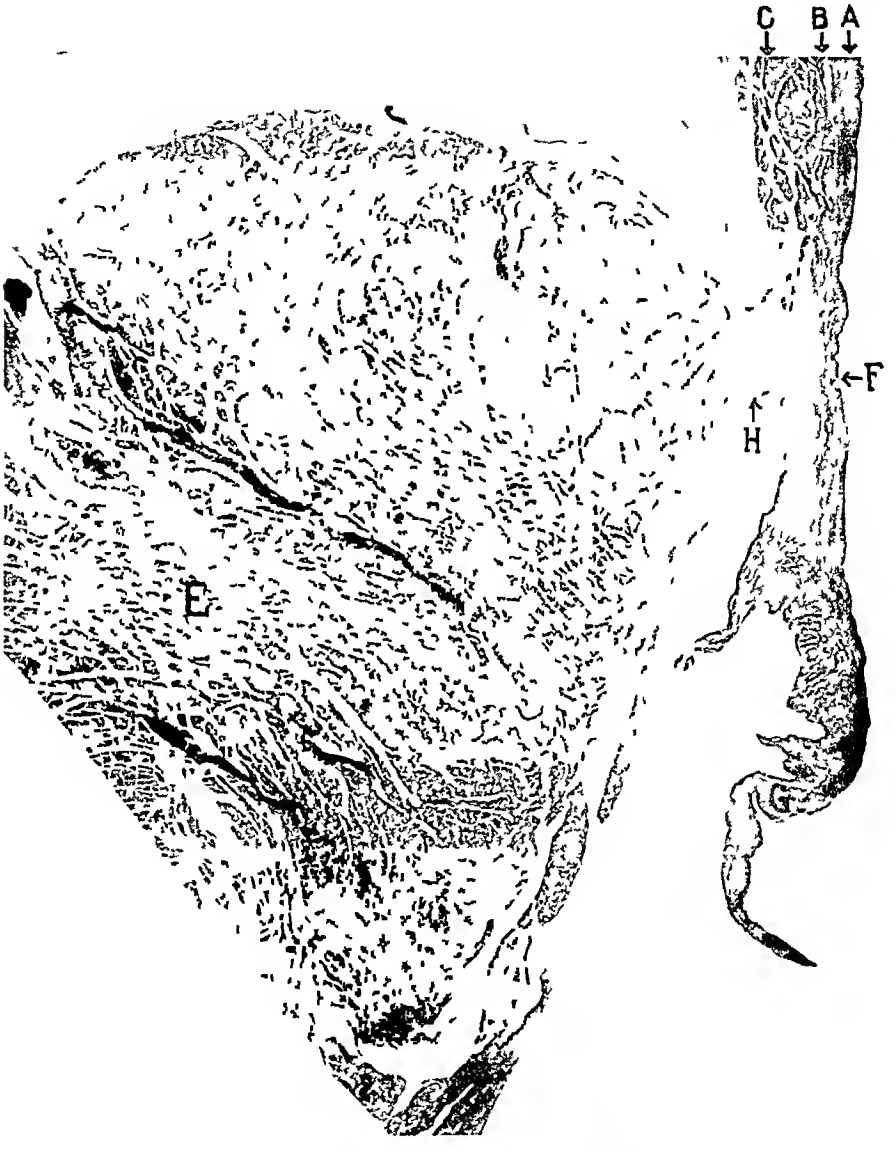

Fig 3—Low power magnification of mitral posterior (M P) section *A* indicates the left auricular endocardium, *B*, the left auricular subendocardium, *C*, the left auricular myocardial wedge, *D*, the pericardial wedge, *E*, the left ventricular myocardium, *F*, the ring of the posterior mitral valve, *G*, the posterior leaflet of the mitral valve, and *H*, the posterior mitral pocket

left auricle (*C*) Note that this inserts into the mitral ring Pericardial wedge (*D*) Note the intimate relation between the pericardial wedge and the mitral ring Left ventricular myocardium (*E*)

The ring of the posterior mitral valve (*F*) It is rather difficult to define accurately the region that we desire to indicate by the term "ring" In this section, it consists of a small area of fibrous tissue into which there is inserted the auricular myocardial wedge, the pericardial wedge and the base of the valve

The posterior leaflet of the mitral valve (*G*)

The posterior mitral pocket (*H*), i e, the tissue lying immediately above, and surrounding, the upper part of the cleft between the valve flap and the endocardium of the left ventricle

Sometimes, the coronary sinus

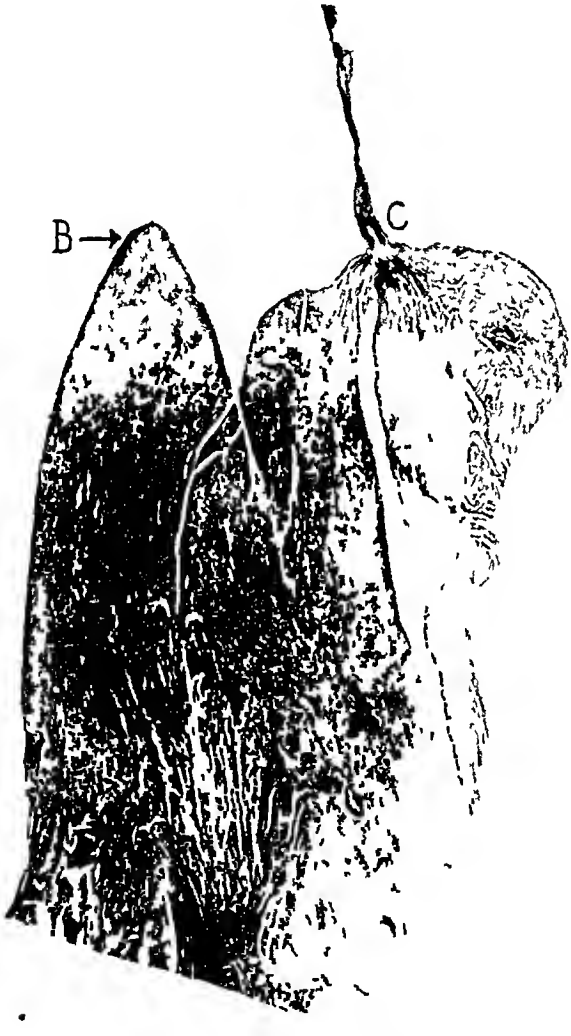

Fig 4—Low power magnification of the posterior papilary muscle, left (P P M) section *A* indicates the myocardium, *B*, the endocardium, and *C*, the insertion of the chorda tendineae

Posterior Papillary Muscle, Left (P P M)—A longitudinal incision is made with a scalpel, starting at the apex of the posterior papillary muscle (when the posterior papillary muscle is forked, the right fork should be used) and continuing down into the base (fig 1) A parallel incision is then made in the usual way and the block removed

Histotopographically (fig 4), this section shows the myocardium of the left posterior papillary muscle (*A*), the endocardial covering (*B*) and, sometimes, the insertion of the chordae tendineae (*C*) This section is valuable in the study of vascular lesions, infarction, fibrosis, Aschoff bodies, etc

Aorta, Aortic Valve and Mitral Valve (A M V)—The section including the aorta, aortic valve and mitral valve is one of the most valuable in the series The anterior segment of the left ventricle is grasped by the left hand (fig 1) A pair of scissors is inserted beneath the anterior flap (aortic) of the mitral valve

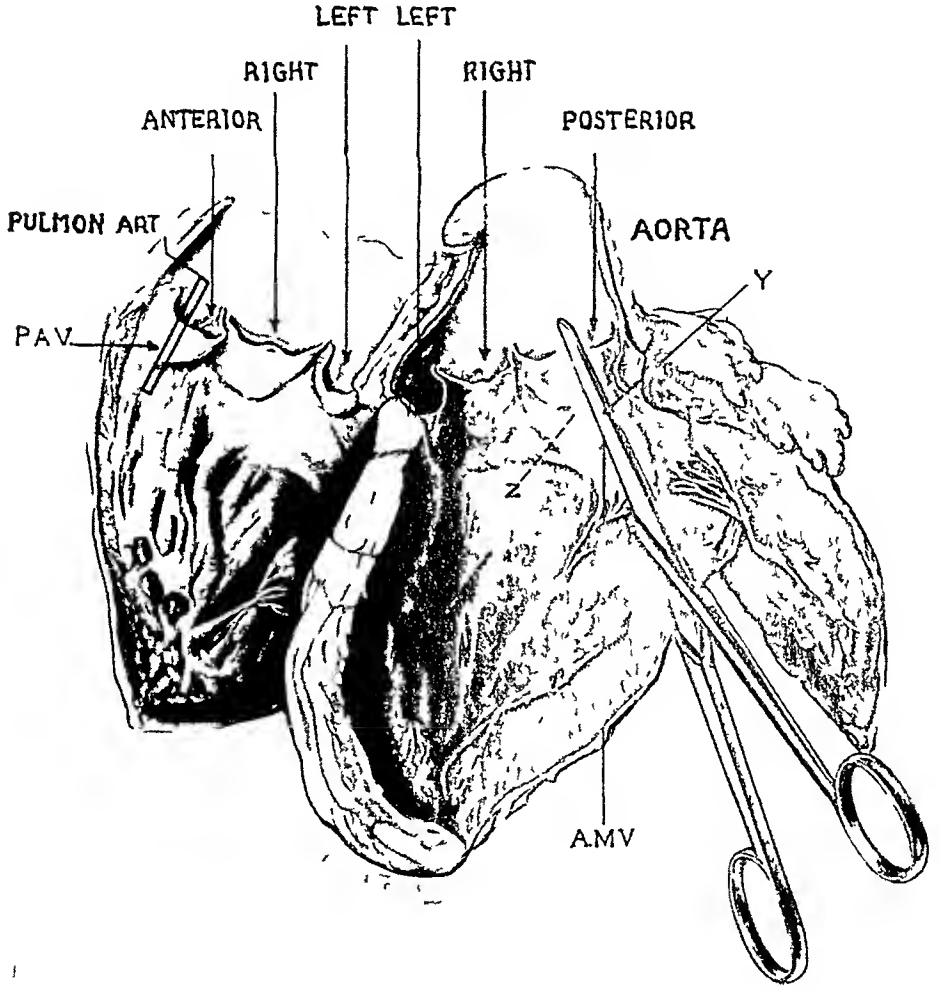

Fig 5—Diagram of the left and right ventricles (outflow tracts), showing the method of cutting the aorta, aortic valve and mitral valve (A M V) and the pulmonary artery and valve (P A V) blocks

so that one blade (*X*) lies against the auricular surface of the aortic flap of the mitral valve and the other blade (*Y*, fig 5) lies against the posterior (non-coronary) cusp of the aortic valve This incision is carried upward through approximately the middle of the posterior cusp of the aortic valve and through the lower portion of the aorta A narrow parallel incision is made and the block removed

Histotopographically (fig 6), this section shows Left auricular endocardium (*A*) Left auricular subendocardium (*B*) Left auricular myocardial wedge (*C*) Pericardial wedge (*D*) The root of the aorta (*E*) The aortic valve (*F*) The sinus pocket (*G*), i e, the junction between the base of the aortic valve and the base of the aorta

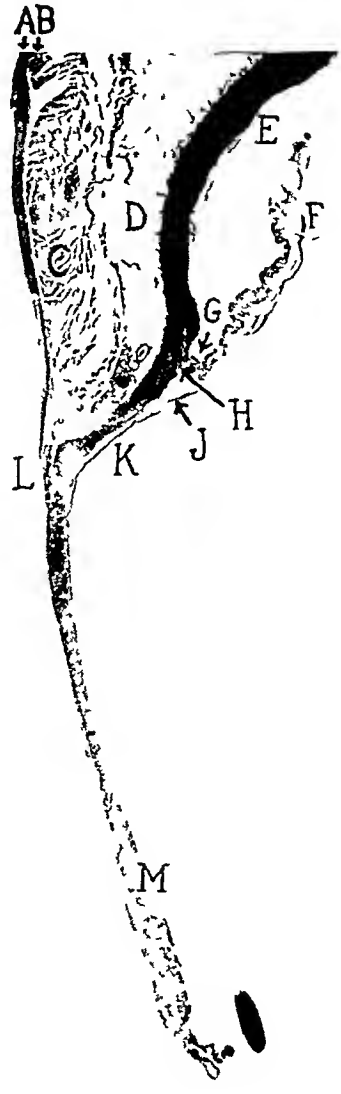

Fig 6—Low power magnification of the aorta, aortic valve and mitral valve (A M V) section *A* indicates the left auricular endocardium, *B*, the left auricular subendocardium, *C*, the left auricular myocardial wedge, *D*, the pericardial wedge, *E*, the root of the aorta, *F*, the aortic valve, *G*, the sinus pocket, *H*, the aortic ring, *J*, the subaortic angle, *K*, the mitral-aortic intervalvular fibrosa and endocardium, *L* the mitral ring, and *M*, the anterior or aortic flap of the mitral valve

The aortic ring (*H*) This consists of a triangular area of connective tissue the base of which rests on the subjacent pericardium and the apex of which merges imperceptibly with the base of the valve

Subaortic angle (*J*) By this term is meant that portion of the endocardium that lies at the junction of the base of the aortic valve on its ventricular aspect and the continuation of the mitral valve on its ventricular aspect

Mitral-aortic intervalvular fibrosa and endocardium (*K*), i e, that portion of fibrous tissue and endocardium the upper limit of which is the aortic ring, the left border of which abuts against the auricular pericardium and the lower limit of which is on a level with the tip of the auricular myocardial wedge (mitral ring)

Mitral ring (*L*) This is rather an ill defined area corresponding to the insertions of the aortic flap of the mitral valve into the mitral-aortic intervalvular fibrosa and left auricular myocardial wedge

Aortic flap of the mitral valve (*M*)

Pulmonary Artery and Valve (P A V)—Before this section is described, it is advisable to state the terminology of the aortic and pulmonary cusps The aortic cusp corresponding to the ostium of the right coronary artery is called the

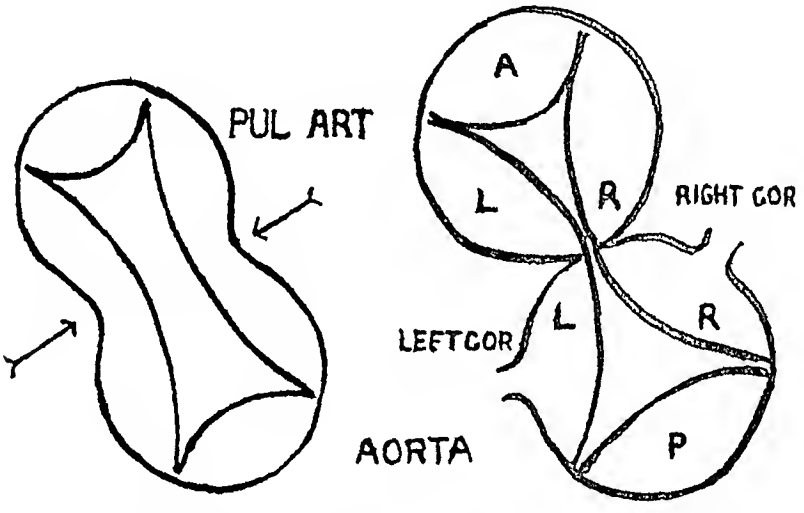

Fig 7—Diagram of the embryogenesis of the pulmonary artery and the aorta illustrating the relationship of right-left pulmonary commissure (R L) to the right-left aortic commissure (R L) *L* = left, *R* = right, *P* = posterior, *A* = anterior, *Cor* = coronary artery

right cusp (figs 5 and 7) That corresponding to the ostium of the left coronary artery is called the left cusp The noncoronary cusp is called the posterior cusp This affords a simple terminology for the commissures, thus, the commissure between the right and left cusps is called R L commissure (right-left commissure) That between the right and posterior cusps is called R P commissure (right-posterior commissure) That between the left and posterior cusps is called L P commissure (left-posterior commissure)

The terminology of the pulmonary cusps is somewhat more difficult to define because of the absence of coronary ostia, but a brief consideration of the embryogenesis of the semilunar cusps gives an excellent landmark for this purpose At one stage in the evolution of the aortic bulb before the pulmonary artery and the aorta have separated from one another, the semilunar cusps are represented by four endocardial cushions At the points marked by the arrows in figure 7 a constriction takes place that eventually separates the two vessels It will be

easily seen from this that only two commissures, one from each vessel, remain in juxtaposition That on the aortic side is the R L commissure That on the pulmonary side opposite the aortic R L commissure separates the right pulmonary cusp from the left pulmonary cusp [5] (fig 5) The remaining pulmonary cusp is called the anterior

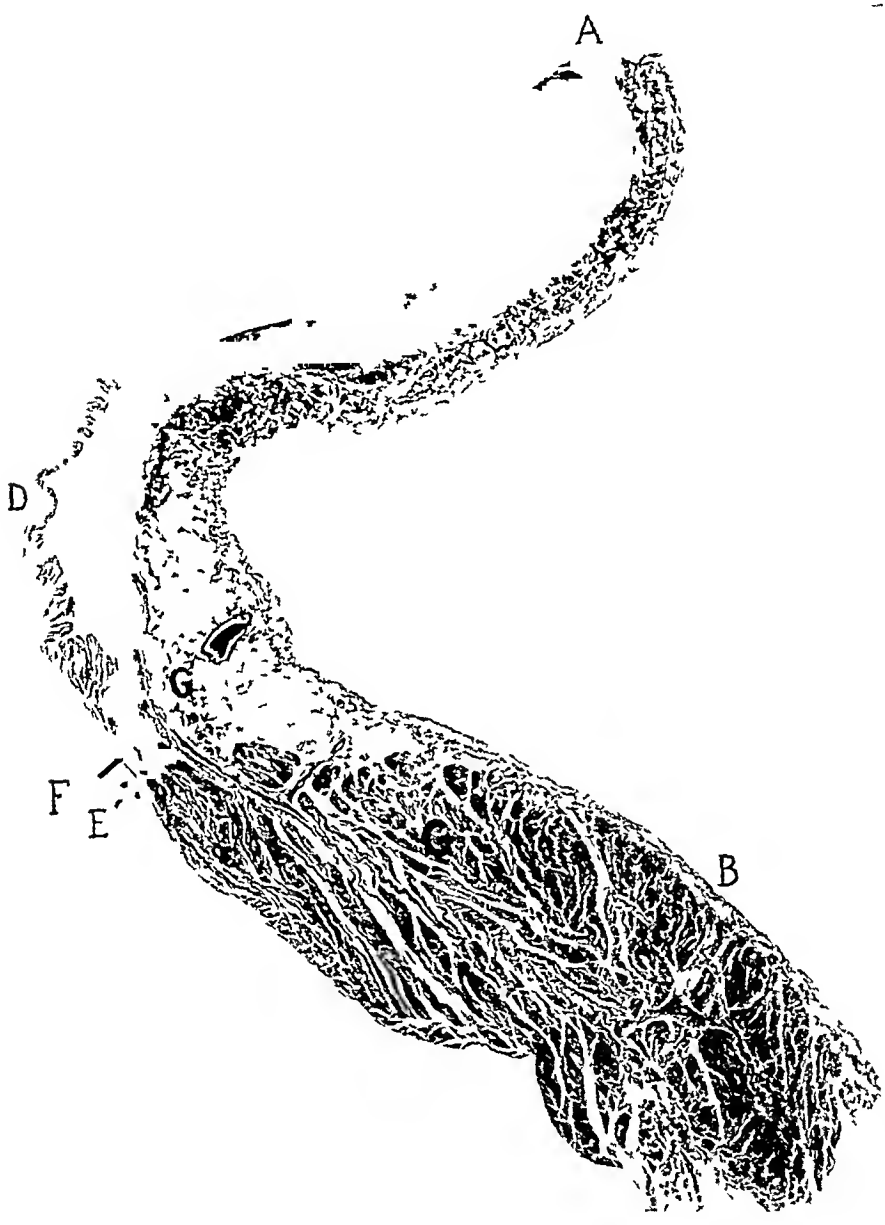

Fig 8—Low power magnification of the pulmonary artery and valve (P A V) section *A* indicates the pulmonary artery and investing pericardium, *B*, the pericardium of the right ventricle, *C*, the pericardial wedge, *D*, the pulmonary valve, *E*, the subpulmonic angle, *F*, the pulmonary ring, and *G*, the right ventricular myocardium

5 The close apposition of these two commissures is not brought out in the schematic drawing, figure 5

It is obvious that by carrying out the same scheme as was suggested for the aortic valve a simple terminology with regard to the pulmonary commissures also becomes available

With a pair of scissors, a cut is made transversely, starting at the right cut border of the pulmonary artery several millimeters above the free edge of the anterior cusp of the pulmonary valve When the incision reaches approximately opposite the middle of this cusp, the scissors are turned downward i e, toward the apex of the heart, and an incision is made through the base of the pulmonary

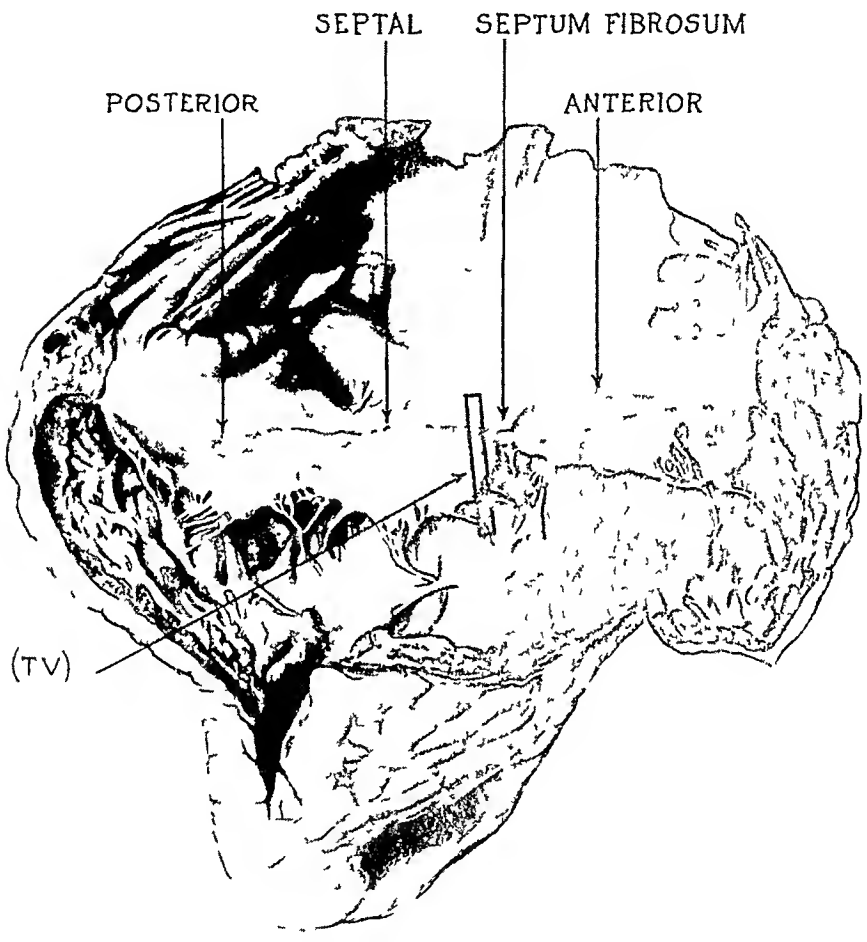

Fig 9—Diagram of the right auricle and ventricle (right inflow tract), showing method of cutting the tricuspid valve and septum (T V) block

artery, the anterior pulmnary cusp and the right ventricular myocardium to approximately 1 cm below the base of this pulmonary cusp Another vertical incision is made parallel to the latter incision and the block removed

Histotopographically (fig 8), this section shows the pulmonary artery and investing pericardium (*A*), the pericardium of the right ventricle (*B*), the pericardial wedge (*C*), the pulmonary valve (*D*), the subpulmonic angle (*E*) (corresponding to the subaortic angle), the pulmonary ring (*F*) (corresponding to what was described for the aortic ring) and the right ventricular myocardium (*G*)

Tricuspid Valve and Septum (T V)—For purposes of completeness, the terminology of the tricuspid cusps and their commissures will be briefly stated The flap that lies over the interventricular septum and is situated below the coronary sinus is called the median or septal flap (fig 9) The free flap anteriorly to its left is called the anterior flap The remaining flap is called the posterior flap It will be noted that the commissure or junction between the septal flap and the anterior flap lies in close proximity to the undefended space (septum fibrosum) This commissure is called the septal-anterior commissure (S A commissure) Similarly, the commissure at the right extremity of the septal

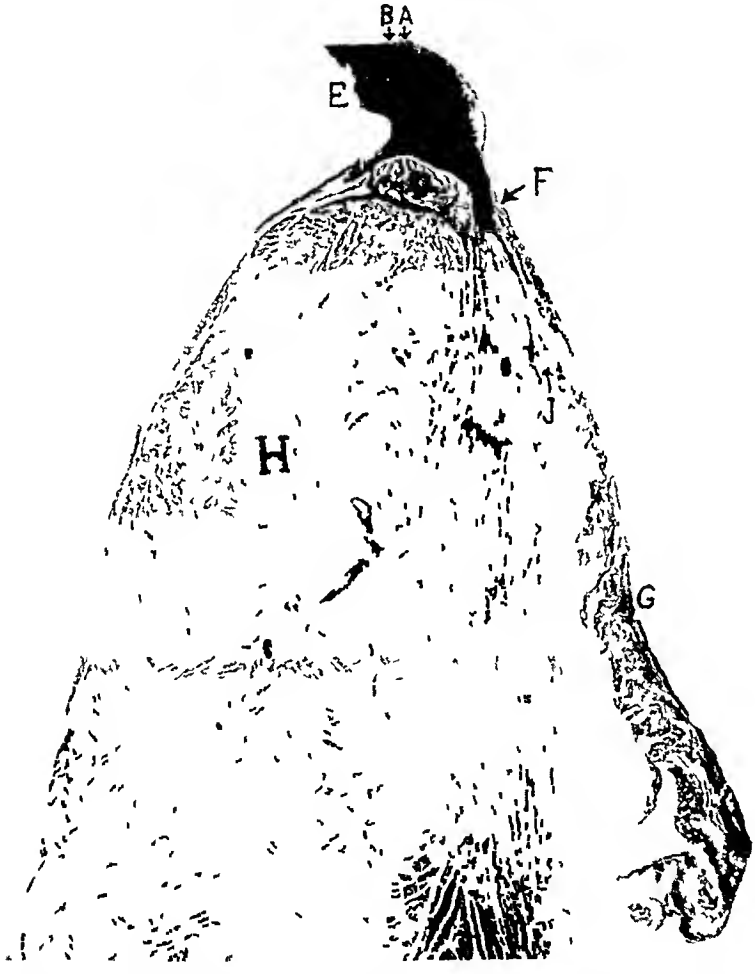

Fig 10—Low power magnification of the tricuspid valve and septum (T V) section *A* indicates the right auricular endocardium, *B*, the right auriclar subendocardium, *D*, the neuromuscular bundle, *E*, the septum fibrosum, *F*, the tricuspid ring, *G*, the tricuspid valve, *H*, the interventricular septum and *J*, the tricuspid pocket

flap is called the septal-posterior commissure (S P commissure) The remaining commissure is called the anterior-posterior commissure (A P commissure)

The section with which we are about to deal is cut from the region of the septal anterior commissure The point of the scalpel is inserted through the right auricle at a point approximately 1 cm above the insertion of the septal flap and 5 mm to the right of the septal-anterior commissure (fig 9) The

point of the knife is pushed through so that it emerges generally below the posterior cusp of the aortic valve (dotted line *Z*, fig 5) The blade is then carried down toward the apex, through the right auricle, the septal cusp of the tricuspid valve and the subjacent interventricular septum to a point approximately 1 cm below the free edge of the septal cusp A parallel incision is made approximately 3 mm to the left of the original cut The block is removed

Histotopographically (fig 10), this section shows Right auricular endocardium (*A*) Right auricular subendocardium (*B*) Right auricular myocardium (*C*)

Neuromuscular bundle (*D*) Note that the removal of this block does not in any way interfere with complete serial sections of the conduction system, since the block constitutes a segment of the standard vertical blocks cut for such purposes

Septum fibrosum (*E*) Tricuspid ring (*F*) (corresponding to what was described for posterior mitral ring) Tricuspid valve (*G*) Interventricular septum (*H*) Tricuspid pocket (*J*) (corresponding to what was described for posterior mitral pocket) Occasionally, a portion of the aortic valve

If it is desired to include in this section the pericardial wedge opposite the tricuspid ring, a section may be taken from the septal cusp of the tricuspid valve closer to its right extremity

COMMENT

It will be seen from this brief description that these six blocks include the following important sites in the heart all four valves, all four valve rings, the pericardium of the left and right sides of the heart (represented in four sections), the left and right auricles, the myocardium of the left ventricle, right ventricle, interventricular septum and left posterior papillary muscle, the bases of the aorta and pulmonary artery, the pericardial wedges abutting against the valve rings, the neuromuscular bundle, and the coronary sinus

It will be noted that the myocardium in practically every section is taken from a site where the vessels can be considered end-vessels, i e, the tip of the left and right ventricles and the interventricular septum It is probably for this reason that early vascular changes and their results are so frequently observed in these sections, and that inflammatory lesions, which may possibly owe their localization to the fact that the vessels in this region are terminal, are so frequently found here

It will also be noted that the left auricle is represented by three sections The possibility of studying rheumatic lesions and arteriosclerotic changes in this region at once becomes apparent

As we stated before, this paper is concerned chiefly with the description of the technic employed However, in order to illustrate the advantages of this method, we may mention the fact that by using these sections only, we have been able to find Aschoff bodies in 90 per cent of forty hearts showing acute verrucous endocarditis[6] and in 15 per

6 We have considered "verrucous material before fibrosis has taken place" as our criterion for acute verrucous endocarditis

cent of thirty-nine hearts showing chronic valvular disease In some of the hearts not showing these lesions, sections from other parts were taken, as well, but failed to show Aschoff bodies It may be assumed, therefore, that if Aschoff bodies are present, they will be found in the standard sections in the great majority of cases

The relative incidence of vascular lesions (arteriosclerotic), myocardial scarring and Aschoff bodies in these sections from thirty-seven human hearts, all of which showed Aschoff bodies, is listed in the table It becomes obvious at a glance that, as judged by these sections, the mitral posterior block (M P) and the tricuspid valve and septum block (T V) are the most frequent sites for Aschoff bodies Indeed, if only these two standard sections had been cut, the incidence of Aschoff bodies in our series would have remained the same, as these structures were found in either one or both of these sections in every case in which they were found in the heart

Incidence of Aschoff Bodies, Scarring and Arteriosclerosis in Thirty-Seven Hearts All of Which Contained Aschoff Bodies *

Site	Aschoff Bodies	Scarring	Arteriosclerosis
Left auricle (L A)	10	17	0
Mitral posterior (M P)	32	21	4
Posterior papillary muscle, left (P P M)	22	26	11
Aorta, aortic valve and mitral valve (A M V)	9	22	4
Tricuspid valve and septum (T V)	30	29	12
Pulmonary artery and valve (P A V)	19	15	0

* Of these hearts, nine were from patients in the first decade of life, sixteen from those in the second two from those in the third six from those in the fourth, two from those in the fifth, one from a patient in the sixth and one from a patient in the seventh

The frequency of scarring in all the sections, except the left auricle (L A) and pulmonary artery and valve (P V) sections is to be noted, as is also the relative frequency of degenerative vascular changes in the tricuspid valve and septum (T V) section and in the posterior papillary muscle, left (P P M) section

In further publications, we propose to present more detailed observations on various lesions of the heart, and in these publications we hope that the usefulness of this method will be more fully brought out

SUMMARY

A simple method for the microscopic study of the heart in standard sections is described The "strategic" sites in each section are briefly reviewed Their importance is illustrated by some of the observations in thirty-seven cases of rheumatic heart disease A standard nomenclature is suggested for certain sites in the heart

ARGENTAFFIN TUMORS OF THE SMALL INTESTINE

A REPORT OF FOUR CASES, ONE WITH METASTASES *

GORTON RITCHIE, M D
MADISON, WIS

Considerable interest has been shown lately in certain tumors of the intestine known as carcinoids, or more accurately as argentaffin cell tumors on account of the affinity for silver of certain granules in their cells These tumors occur in the small intestine and appendix, sites rarely affected by other primary tumors, they are often multiple in origin, they grow slowly, rarely metastasizing, and they usually give rise to symptoms only by causing intestinal obstruction Grossly, they are usually small, seldom exceeding 3 cm in diameter They are sometimes pedunculated, but often flat and almost embedded in the mucous surface of the intestine In the appendix, they escape notice grossly, or are in the form of small nodules The cut surface, whatever the location, is opaque and either gray or yellowish gray Microscopically, the cells are round or oval, the nuclei round and uniform in size, shape and staining reaction Mitotic figures are extremely rare The cells are arranged in more or less solid, coarsely branching groups, with occasional lumen-like spaces These may be empty or may contain small arteries or merely hyaline material The pathognomonic intracellular argentaffin granules are usually more numerous on the peripheries of acini In a cell bordering on a "lumen," the granules are always in the portion of the cell farthest from the opening

The nature of argentaffin tumors is not thoroughly understood, as a brief review of the widely varying opinions in this regard will show They were early confused with true carcinomas Bunting [1] in 1904 called attention to their similarity to basal cell epitheliomas of the skin, in that they are characterized by multiple sites of origin, slow growth and lack of metastases In 1907, Obernderfer clearly differentiated them from true carcinomas and proposed the name "carcinoid" Saltykow in 1912 and 1913 discussed them in two papers, regarding them as pancreatic island rests

In 1914, Gosset and Masson [2] discovered the argentaffin nature of the chromaffin (Kulschitzky) cells of the gastro-intestinal tract and

* Submitted for publication, June 24, 1930

From the Laboratory of Pathology, University of Wisconsin

1 Bunting, C H Multiple Primary Carcinomata of the Ileum, Bull Johns Hopkins Hosp **5** 389, 1904

2 Gosset, A and Masson P Tumeurs endocrine de l'appendice, Presse med **22** 237, 1914

also the chromaffin and argentaffin characters of carcinoids In 1928, Masson,[3] by means of serial sections, proved the origin of these tumors from the argentaffin cells of the intestine This work has been confirmed by several investigators

In 1925, Forbus[4] reported six cases and reviewed the literature thoroughly He summed up the important opinions as to the tumors in question thus

1 The tumors represent true carcinomata derived from the epithelium of the gastrointestinal mucosa

2 They may be included in the group of basalomata analogous to basal-cell cancers of the skin

3 They may be malformations belonging to the general group of tumors developing from pancreatic rests, as adenomyoma and accessory pancreas

4 They may be tumors derived from the chromaffin cells of the crypts of Lieberkuhn, and hence be endocrine tumors or tumors of the paraganglionic system

In view of the limited number of these tumors reported since the discovery of their true derivation, and in view of the fact that one case with metastases is available, it seems profitable to review the cases observed in this laboratory Unfortunately, the tissue from the case in which metastases occurred and that from one other were fixed in Zenker's fluid The argentaffin granules stain poorly or not at all after this fixation An extremely careful morphologic study was made, however, and the histologic features of these tumors were found similar in every respect to those of the proved argentaffin tumors In fact, in searching for any possible similarity to a true adenocarcinoma, I found that the tumors in question showed less glandlike structure than the tumors in which the argentaffin granules stained clearly (fig 1) This is contrary to the views of Forbus, who regarded glandlike alveolar arrangement as a differential point on which may rest the diagnosis of adenocarcinoma

The only other reported case with undoubted metastases was one presented by Gaspar[5] recently In his case there were mesenteric and hepatic metastases in which the argentaffin granules were stained clearly by both Masson's and Hasegawa's methods Barth[6] in 1929 reported

3 Masson, P Carcinoids (Argentaffin-Cell Tumors) and Nerve Hyperplasia of the Appendix Mucosa, Am J Path **4** 181, 1928

4 Forbus, W D Argentaffin Tumors of the Appendix and Small Intestine, Bull Johns Hopkins Hosp **37** 130, 1925

5 Gaspar, Istvan Personal communication to the author concerning a paper presented at the meeting of the American Association of Pathologists and Bacteriologists, New York, 1930

6 Barth, H Untersuchungen am Neuromen und Carcinoiden des Wurmfortsatzes, Virchows Arch f path Anat **273** 62, 1929

three cases of appendical carcinoid In one of these there was metastasis to the ovary It is possible, however, that this was a direct extension as the ovary was the right one and apparently had been bound by adhesions that also involved the appendix

REPORT OF CASES

CASE 1 —At operation for gallbladder disease on a woman, aged 51, a mass, apparently scar tissue, was noted in the mesentery, but was not removed Forty-eight hours after operation, the patient began to show signs of peritonitis and ileus Her condition grew progressively worse, and she died four days after operation

At autopsy, the mass, 5 by 3 by 3 cm, was found to lie in the mesentery of the middle portion of the small intestine The section surface was soft and

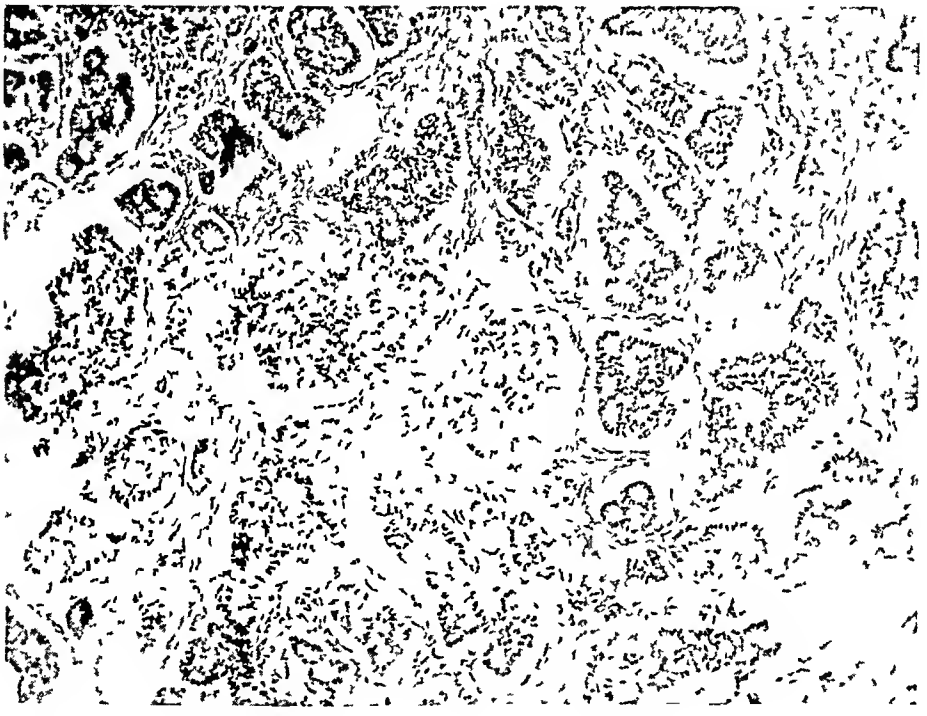

Fig 1 (case 3) —Argentaffin tumor, showing definite alveolar arrangement of cells, × 80

hemorrhagic, and a definite fibrous capsule was present The portion of intestine supplied by the involved mesenteric vessels was gangrenous For a distance of 30 cm proximal to the gangrenous portion, the intestinal wall contained irregular nodules These were in the mucosa and submucosa, most of them being broad and flat and some almost pedunculated Several mesenteric lymph nodes nearby were enlarged On the surface of the liver were seven pearly gray nodules, firm and well demarcated The section surface of the liver also showed several deeper nodules, and all were gray and homogeneous in appearance There was no evidence of metastasis in any other organ

Microscopic Examination—The tumors in the intestine mesentery and liver were composed of solid masses of tumor cells in alveolar formation The cells were so crowded together as to obscure cell outlines in most areas, but where

these could be seen they were round or oval The nuclei were round and uniform in shape and size No mitotic figures were seen At several points were structures resembling lumina of glands Some of these were empty, whereas others contained small blood vessels The dense stroma in the intestinal tumors was made up partly of fibrous tissue and partly of smooth muscle, but in the mesenteric and hepatic metastases (fig 2) it was entirely fibrous It was impossible to stain the argentaffin granules on account of Zenker fixation

Case 2—A woman, aged 71, was admitted to the hospital with symptoms of chronic intestinal obstruction of three months' duration At operation, an annular tumor, apparently carcinoma, was found constricting the lower part of the ileum Ileocecostomy was done The patient died the morning after the operation

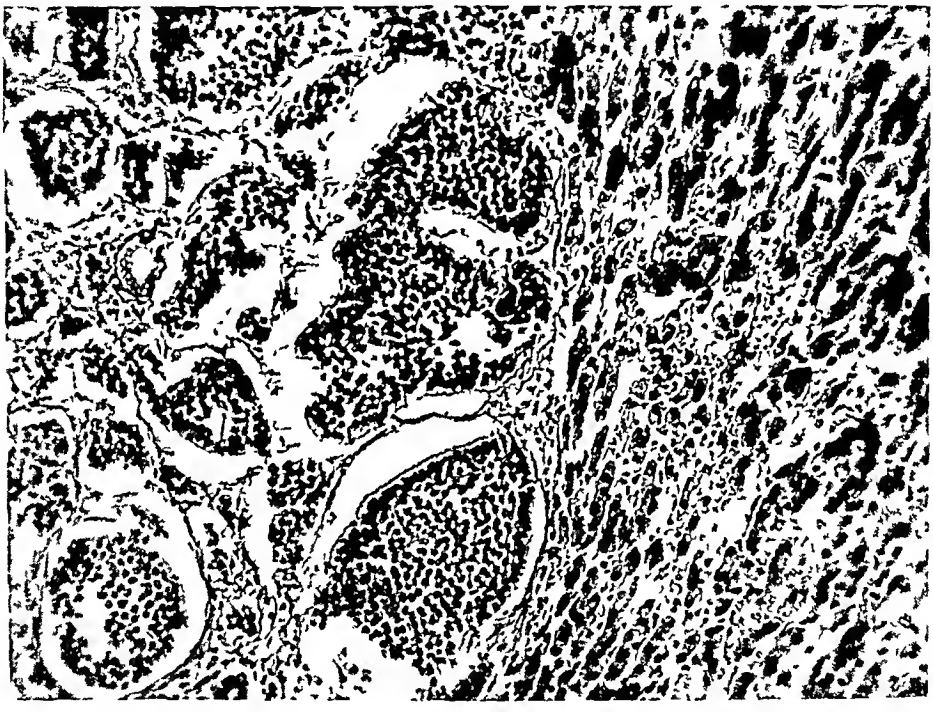

Fig 2 (case 1)—Metastasis of argentaffin tumor in the liver × 130

At autopsy, a constriction of the ileum was found, narrowing the lumen to 4 mm and extending 2 cm along the course of the intestine The lower end of the lesion was 3 cm from the ileocecal valve There was scarring and puckering in the mesentery here kinking the intestine On one side of the constriction there was a pedunculated mass, firm, grayish brown and about 1 cm in diameter There was a similar mass in the mesenteric attachment of this part of the intestine

Microscopic Examination—The histologic appearance here was in all respects similar to that of the intestinal tumors in the preceding case Fixation in Zenker's fluid was used

Case 3—A woman, aged 60, was the source of the third specimen of argentaffin tumor

Case 4—The tissues from this and from case 3 were received from outside as surgical specimens without history, except that they were removed at operation from patients with symptoms of intestinal obstruction Both of these tumors

on staining by Masson's method, showed the characteristic silver-reducing granules in a great majority of the cells The morphologic characteristics of these tumors were similar to those of the other two tumors, the differences being minor only

COMMENT

Of the various hypotheses as to the nature of these tumors, none seems to offer a satisfactory solution of the problem Masson's work in tracing their origin to the argentaffin cells of the intestine invalidates other opinions, and resolves the entire problem into a question of the nature of these cells Masson feels that they form collectively an endocrine organ of entodermic origin He speaks of a "neurocrine" organ in which the normal argentaffin cells of the intestine pour their secretion on the nerve-endings of an autonomic nerve plexus also of entodermic derivation, not demonstrable with the technical methods now available This supposition is based on the fact that many argentaffin tumors, particularly those of the appendix, are intimately associated with neuromas In one of Barth's cases there was an accompanying neuroma with which the argentaffin cells were in close association He does not follow Masson in interpretation of this, but brings up the interesting possibility of an affinity between nervous tissue and that of epithelial tumors analogous to the affinity in von Recklinghausen's disease between nervous and connective tissue The cases investigated in this laboratory were purely epithelial

Kull expressed the belief that their secretion is poured into the blood capillaries, and Parat said that he was in general accord with this opinion

I believe that the evidence in favor of these propositions is not sufficient to justify the acceptance of either The intestinal cells in question contain chromaffin granules as do the chromaffin cells of the suprarenal medulla, this, however, shows merely a chemical similarity and is not conclusive proof of functional analogy Even the chemical analogy is not complete, for the suprarenal granules are not stained with chrome salts after any fixation in which acetic acid is used whereas the intestinal granules stain well after fixation with Bouin's fluid, which includes 5 per cent glacial acetic acid Neither is there any physiologic evidence, for argentaffin tumors either are symptomless or give rise to symptoms only by causing intestinal obstruction, interference with the circulation or other result of position In this they are unlike most endocrine tumors e g, those of the hypophysis, thyroid gland, suprarenal glands, gonads and some even of the islands of Langerhans

Kulschitzky [7] felt that the granules in the cells that he described bore a definite relation to digestion and absorption in the intestine After

7 Kulschitzky, N Zur Frage uber den Bau des Darmkanals, Arch f mikr Anat 49 7, 1897

starvation of his experimental animals (dogs), he found that the granules in the cells were decreased in number, in animals on a plentiful diet that were killed after a few days, the granules were increased over the normal number His observations have been declared incorrect by Kull, Suda and several others

Cordier stated the belief that the cells have a definite exocrine function and pour their secretion into the intestinal lumen

CONCLUSIONS

It is evident in reviewing the varying opinions concerning the nature of argentaffin tumors that an understanding of this question depends on further investigation of the chromo-argentaffin cells of the normal intestine Until these are thoroughly understood one can say only that argentaffin tumors are similar in characteristics and especially in degree of malignancy to basal cell epitheliomas of the skin Even this statement has its exceptions for metastases do occur, though rarely

SUMMARY

Four cases of argentaffin tumor of the small intestine (carcinoid) are reported, one with mesenteric and hepatic metastases A brief review of opinions as to the nature of these tumors is made, and the conclusions drawn are (1) that the nature of the tumors depends on the nature of the chromo-argentaffin cells of the normal intestine not yet understood, and (2) that until this point is decided argentaffin tumors must be placed in the same category as basal cell epitheliomas of the skin, with reference to malignancy and general characteristics

EXPERIMENTAL SUBACUTE AMYLOID NEPHROSIS IN RABBITS *

E M BUTT
SAN FRANCISCO

In the course of studies on chronic metal poisoning, I noted a curious and interesting lesion in the kidneys of rabbits receiving manganese chloride subcutaneously The lesion consisted of a marked subacute nephrosis involving the tubules and glomeruli, accompanied by the deposition of an amyloid-like substance in the glomerular tufts and about the tubular capillaries

To my knowledge such an observation has not been recorded as a result of metal poisoning, and it was thought to be of sufficient interest to be made the subject of a report

Manganese poisoning in man produces a peculiar combination of degenerative lesions in the basal ganglions of the brain and cirrhosis of the liver a condition not unlike that of hepatolenticular degeneration as described by Wilson [1] and others Mainly because of this fact much experimental work has been done with manganese

It is of interest to recall that Mella [2] by injecting manganese into monkeys, reproduced the lesions described as characteristic of manganese poisoning in man Later Findlay [3] reported cirrhotic changes in the livers of rabbits, guinea-pigs and rats poisoned with manganese

Hurst and Hurst [4] summarized the literature and verified Findlay's observations, producing fibrous changes in the livers of guinea-pigs and rabbits with subcutaneous injections of manganese chloride However, they were unable to demonstrate changes in the central nervous systems of their animals

Primarily, my work was undertaken with the idea of disproving or substantiating the possibility that chronic manganese poisoning in rabbits gives rise to a similar deposition of pigment in the livers, as was found by Hall and myself [5] in our experiments confirmatory of Mallory's work with copper

---

* Submitted for publication, June 16, 1930

From the Department of Pathology Stanford University Medical School

1 Wilson Brain **34** 290, 1911

2 Mella Experimental Production of Basal Ganglion Symptomatology in Macacus Rhesus Arch Neurol & Psychiat **11** 405, 1924

3 Findlay Brit J Exper Path **5** 92, 1924

4 Hurst and Hurst J Path & Bact **31** 303, 1928

5 Hall and Butt Experimental Pigment Cirrhosis Due to Copper Poisoning, Its Relation to Hemochromatosis Arch Path **6** 1, 1928

It is perhaps not irrelevant to point out that this investigation acts as a control on our former work with copper Furthermore, it must be stated that in our studies with both copper and manganese, carrots were purposely omitted from the diet

Much work has been done on the production of amyloid disease No attempt will be made to summarize the voluminous literature on the subject In passing, mention will be made of the more recent work of Kuczynski [6] further elaborated by Smetana,[7] in regard to the production of amyloid disease in mice by injections of nutrose More recently Yokoi [8] reported that with intravenous injections of defibrinated blood, serum, or natrium silicate, amyloid disease may be produced in these animals Letterer [9] has made a comprehensive study of the experimental development of amyloid in mice, producing the disease with injections of proteins, colloidal sulphur or colloidal selenium

EXPERIMENTAL PROCEDURE

Young, healthy rabbits of about the same age, 6 months, were selected for the experiment The animals were kept in separate cages and maintained on a diet consisting of barley, alfalfa and lettuce or cabbage leaves

At irregular intervals, twenty-four hour samples of urine were collected, and quantitative tests for albumin and examinations of sediment were made The method of Shevky and Stafford [10] was employed for the quantitative estimation of albumin

Subcutaneous and intravenous injections were made, aseptic precautions and sterile solutions being used

Autopsy was performed on the animals within twenty-four hours after death Sections of the kidneys, liver, heart and adrenal glands were placed in Orth's solution and in 65 per cent alcohol The tissues fixed in Orth's solution were examined for fatty changes The alcohol-fixed tissues were embedded in paraffin sectioned and stained with hematoxylin and eosin or van Gieson's stains Methyl violet and iodine were used to identify the amyloid

RABBITS RECEIVING SUBCUTANEOUS INJECTIONS OF MANGANESE CHLORIDE

Ten rabbits were given injections of manganese chloride two or three times a week See table 1 for the details

Rabbits 1, 2 and 3 were killed by an overdose of manganese after having received injections of smaller doses over a period of twelve weeks Rabbit 4 had an injection of the same dose, but subsequently

6 Kuczynski Virchows Arch f path Anat **239** 185, 1922

7 Smetana Bull Johns Hopkins Hosp **37** 408, 1925

8 Yokoi Tr Jap Path Soc **19** 343, 1929

9 Letterer Beitr z path Anat u z allg Path **75** 487, 1926

10 Shevky and Stafford Clinical Method for Estimation of Protein in Urine and Other Body Fluids, Arch Int Med **32** 222, 1923

recovered Gross examination of the organs revealed no abnormalities, except intense congestion of the lungs and mottling of the livers Histologic examination of the tissues showed numerous small areas of necrosis in the livers, extensive hemorrhage and edema in the lungs

TABLE 1 —*Rabbits Receiving Subcutaneous Injections of Manganese Chloride*

Rabbit	Duration of Experiment, Wk	Number of Injections	Total MnCl₂ Received, Gm	Albumin in Urine, Mg per 24 Hr Specimen at Termination of Experiment	Lesions of Kidney	Amyloid in Kidney	Lesions of Other Organs	Amyloid in Other Organs
1	12	27	0 062		Cloudy swelling, tubular necrosis	None	Liver areas of necrosis, small amount of pigment	None
2	12	27	0 062		Cloudy swelling, tubular necrosis	None	Liver areas of necrosis, small amount of pigment	None
3	12	27	0 062		Cloudy swelling, tubular necrosis	None	Liver areas of necrosis, small amount of pigment	None
4	34	89	0 482	1010 0	Marked tubular and glomerular involvement, moderate interstitial scarring	+++	Liver areas of necrosis, slight increase of periportal fibrous tissue, terminal pericarditis	None
5	39	75	0 500	1094 0	Marked tubular and glomerular involvement, moderate interstitial scarring	+++	Spleen pigment Liver small amount of pigment	None
6	48	107	0 876	86 0	Moderate tubular and glomerular involvement	++	Lung bronchopneumonia Liver moderate increase in periportal fibrous tissue Spleen pigment	None
7	48	103	0 929	110 0	Moderate tubular and glomerular involvement	++	Lung bronchopneumonia Spleen pigment	None
8	17(F) 8(S)	(17)F 13 S	1 050 0 154	1090 0	Marked tubular and glomerular involvement, moderate interstitial scarring	+++	Lung hemorrhage Heart interstitial scarring	Spleen
9	46	78	0 9768	120 9	Moderate tubular and glomerular involvement	++	Lung hemorrhage	None
10	43	54	0 9954	1242 0	Marked tubular and glomerular involvement, moderate interstitial scarring	+++	Lung hemorrhage	None

and congestion, cloudy swelling, epithelial necrosis and casts in the tubules of the kidneys In all three animals, there were small amounts of finely granular, brown pigment in the liver cells about the periphery of the lobules This pigment neither stained with fuchsin nor gave a positive reaction in the test for iron

The remaining seven rabbits of this group received injections over a period of from twenty-five to forty-eight weeks

It is interesting to note that when the kidneys were severely damaged the daily output of albumin in the urine was high, in some cases amounting to over 1 Gm a day The normal excretion of albumin in the urine of rabbits varies from 20 to 80 mg per twenty-four hours

Rabbit 4 died in uremic coma The blood urea just prior to the death of the animal was 258 mg per hundred cubic centimeters of blood

A general description of the gross and microscopic appearances of the organs of these rabbits will suffice, as the changes were identical except for quantitative and minor differences Of all the organs, the kidneys presented the most constant and severe lesions The kidneys were pale and swollen, and when tested with iodine the glomeruli stood



Fig 1 (rabbit 10) —Weekly record of the weights and amounts of manganese chloride injected subcutaneously and the quantities of urine and albumin excreted in twenty-four hour periods

out as small brown dots Microscopically there were extreme changes in the tubules, particularly involving the first, second and third parts of the proximal convoluted portions and the medullary loops These changes consisted of marked fatty degeneration and necrosis of the epithelial cells, accompanied by evidences of regeneration Many of the proximal convoluted tubules were dilated to five and six times their normal size, some were completely denuded of epithelium, while others were irregularly lined with large, clear, oval cells, having pale-staining nuclei or flat, fusiform epithelial cells with large nuclei In a few places the epithelial cells formed small masses projecting into the lumina Some of the tubules contained casts, others granular material



Fig 2—High power photomicrograph of kidney of rabbit 10, showing the amyloid infiltration about the tubular capillaries and the broad inner zone of the medulla



Fig 3 (rabbit 8)—A glomerulus infiltrated with amyloid, seen with high power objective

The changes in the distal parts of the loops of Henle and in the distal convoluted and collecting tubules were negligible There was a definite but moderate proliferation of interstitial fibrous tissue more marked in the kidneys having markedly dilated tubules This was not accompanied by any signs of inflammatory reaction

The glomerular changes were extremely interesting Many of the capsular spaces were filled with granular material and in some places contained small amounts of blood Throughout, the glomerular tufts were infiltrated with varying amounts of an amyloid-like substance that in places completely obliterated the glomeruli This same substance was found about the tubular capillaries and was more in evidence about the capillaries of the medulla This amyloid-like substance stained red with methyl violet and brown with iodine The iodine brown color changed to a greenish blue when treated with sulphuric acid Except for a moderate increase of perivascular fibrous tissue, the arteries were normal

The renal changes in rabbits 6, 7 and 9 were less severe than those in rabbits 4, 5, 8 and 10, but in all there were varying amounts of amyloid

The amyloid degeneration was limited entirely to the kidneys, except in rabbit 8, in which the spleen in addition to the kidneys was found to contain amyloid This rabbit, by the way, was fed manganese chloride daily for a period of seventeen weeks, receiving a total of 1 05 Gm , and then later was given subcutaneous injections, receiving 0 154 Gm of the metallic salt over a period of eight weeks

The changes noted in the livers of these animals were variable and of little consequence Grossly, the livers were normal, except for intense congestion In three rabbits there were a few small areas of necrosis and slight increases of periportal fibrous tissue In two rabbits there were slight amounts of finely granular, brown pigment in the liver cells about the peripheries of the lobules

Only one rabbit of this group presented subcutaneous abscesses as a result of the injections The sites of injections in the remainder of the rabbits presented no evidence of sloughing or of abscess formation

RABBITS RECEIVING INTRAVENOUS INJECTIONS OF MANGANESE CHLORIDE

Three rabbits were given intravenous injections of manganese chloride (table 2) The kidneys of rabbit 11 were slightly swollen and microscopically presented lesions as follows The tubular epithelium was swollen, granular and necrotic in places The tubules and glomerular spaces were filled with granular material Some of the

glomerular tufts appeared shrunken, others were swollen, vacuolated and markedly congested In a few places, the glomerular tufts were replaced by a mesh of fibrin in which there were red blood cells · About a few of the capillaries of the medulla of the kidney there were small amounts of amyloid Lesions in the other organs consisted of areas of necrosis in the liver and hemorrhages in the lungs The spleen was found to contain much iron-bearing pigment In the liver there were small deposits of pigment confined to the liver cells about the lobular peripheries

The remaining two rabbits received injections of smaller doses of the metal over a longer period of time One rabbit showed large subcutaneous abscesses and was killed at the end of the thirty-fourth week

TABLE 2—*Rabbits Receiving Intravenous Injections of Manganese Chloride*

Rabbit	Duration of Experiment, Wk	Number of Injections	Total $MnCl_2$ Received, Mg	Albumin in Urine, Mg per 24 Hr at Termination of Experiment	Lesions of Kidney	Amyloid in Kidney	Lesions of Other Organs
11	10	18	0 242	1101 6	Marked tubular and glomerular necrosis	+	Spleen pigment Liver necrosis, small amount of pigment
12	42	79	0 5104	130 1	Marked cloudy swelling, otherwise normal	None	Spleen pigment Liver moderate amount of pigment
13	34	58	0 2626	156 6	Moderate cloudy swelling, otherwise normal	None	Spleen pigment Liver small amount of brown granular pigment

The other animal was killed at the end of the forty-second week Except for a moderate parenchymatous degeneration, the kidneys of both animals were normal No amyloid was demonstrated The livers and spleens contained moderate amounts of hematogenous pigment

RABBITS FED WITH MANGANESE CHLORIDE

Five rabbits were given manganese chloride, daily, in their food for from eleven to forty-one weeks (table 3) The end-results were negative, and in none of the rabbits of this group were there evidences of damage of the kidneys or liver attributable to the action of the metal Two of the animals (14 and 17) developed bronchopneumonia, accompanied by abscess formation There were areas of necrosis in the liver of rabbit 14, and it seemed most likely that this lesion resulted from the severe pneumonic infection There was a small amount of finely granular, brown pigment in the liver of rabbit 18, a lesion not demonstrated in the remaining four animals

RABBITS RECEIVING SUBCUTANEOUS INJECTIONS OF (1) ZINC LACTATE, (2) MERCURIC CYANIDE

Two rabbits received injections of zinc lactate for thirty-eight weeks, each receiving a total of 1 65 mg (table 4) Both rabbits developed large areas of sloughing at the sites of injection Grossly and microscopically, the organs were normal

TABLE 3—*Rabbits Fed Manganese Chloride*

Rabbit	Duration of Experiment, Wk	Number of Feedings	Total $MnCl_2$ Received, Gm	Albumin in Urine, Mg per 24 Hr at Termination of Experiment	Lesions of Kidney	Amyloid in Kidneys	Lesions of Other Organs
14	12	62	1 05	Test not done	None	None	Liver necrosis
15	16	62	1 05	Test not done	None	None	Spleen pigment
16	11	66	3 12	26 1	None	None	Liver fatty infiltration
17	21	126	9 72	59 4	None	None	Liver fatty infiltration Lung bronchopneumonia
18	41	312	46 92	64 8	None	None	Liver small amount pigment, fatty infiltration

TABLE 4—*Rabbits Receiving Subcutaneous Injections of (1) Zinc Lactate and (2) Mercuric Cyanide*

Rabbit	Duration of Experiment, Wk	Number of Injections	Total Metal Received	Albumin in Urine, Mg per 24 Hr at Termination of Experiment	Lesions of Kidney	Amyloid in Kidneys	Lesions of Other Organs
45	38	33	Zinc lactate, 1 65 mg	46 0	Cloudy swelling	None	None
46	38	33	Zinc lactate, 1 65 mg	57 2	Cloudy swelling, small amount tubular necrosis	None	None
27	44	56	Mercuric cyanide, 0 341 Gm	594 0	Marked tubular necrosis, glomerular changes interstitial fibrosis	None	Liver small areas of necrosis
28	44	56	Mercuric cyanide, 0 278 Gm	518 4	Same as in 27, except less marked	None	Spleen pigment Liver cloudy swelling

The remaining two rabbits received respectively, 0 341 and 0 278 Gm of mercuric cyanide, over a period of fifty-six weeks Both rabbits developed subacute lesions of the kidney, typical of the usual observations in mercury poisoning

No amyloid was found in the organs of the four rabbits

CONTROLS

Suffice it to say that an adequate number of control rabbits, twelve, maintained on the diet given above presented no gross or microscopic lesions

COMMENT

Local amyloid degeneration in kidneys of rabbits severely damaged by subcutaneous injections of manganese chloride is a constant observation, and moreover properly regulated doses of the same metal given intravenously give rise to the same lesion

The production of the lesion of the kidney depends on giving manganese chloride over a long period of time, thus making it necessary to regulate the dose to the individual tolerance of the animal This may be done by following the daily weights and the quantitative estimations of albumin in the urine

At present, I am repeating and varying the experimental procedure with the hope of finding an explanation of the formation of amyloid in this lesion I believe, however, that capillary damage, followed by the exudation and jelling of protein substance from the blood into the peri-capillary spaces, is the most likely explanation Nevertheless, I am mindful of the fact that the production of this amyloid substance may be a local phenomenon

Local suppuration at the sites of injection of the metal may be definitely excluded as the cause of the amyloid degeneration, as only one rabbit of the group receiving subcutaneous injections developed abscesses, and the kidneys of this rabbit contained less amyloid than the kidneys of the remainder of the rabbits This possibility was further controlled by subcutaneous injections of zinc lactate and mercury cyanide into rabbits, the former producing large areas of sloughing subcutaneously, and the latter giving rise to little or no effect locally but causing severe renal tubular damage typical of mercury poisoning, but in neither case resulting in local amyloid degeneration of the kidneys

I am unable to explain why the damage of the liver that I observed was not so extensive as that which other authors have reported It may be that higher doses of manganese chloride than I have employed are necessary to cause such damage

Hurst and Hurst[4] reported the finding of pigment in the livers of their rabbits given manganese and concluded "The pigment in manganese poisoning is like that in phenylhydrazine poisoning, a product of blood destruction, and manganese has in addition to the effect on the liver some slight hemolytic action, the pigment is not hemofuchsin" It will be seen in my tables that some pigment was demonstrated in the livers of the rabbits, a most constant observation in rabbits into which manganese chloride had been intravenously injected The pigment was finely granular and did not stain with fuchsin or by Perl's prussian blue method In fact, it does not resemble the type of pigmentation that copper produces, in quantity or in quality

I was unable after thorough search to find pigment in the livers of the control rabbits The question of the pigment will be considered in a later paper

CONCLUSIONS

A method has been found to produce amyloid nephrosis in rabbits The production of the lesion depends on the regulation of the doses of manganese chloride given subcutaneously so as to permit chronic poisoning The amyloid degeneration is usually limited to the kidneys, except occasionally when the spleen in addition to the kidneys may be involved The identification of this amyloid-like substance as amyloid is based on its reaction with the stains that are considered specific for amyloid, i e, methyl violet and iodine

STUDIES ON THE PATHOGENESIS OF BACTERIAL ENDOCARDITIS II

KURT SEMSROTH, M D
AND
ROBERT KOCH, M D
PITTSBURGH

In a previous communication[1] it was reported that staphylococcus bacteremia of rabbits led to endocarditis in a high percentage of the animals if, previous to the infection, the animals had received ten intravenous injections of sodium caseinate Since the control animals, even when given as many as thirty daily injections of casein, failed to show lesions of the endocardium, we drew the inference that our results were due to an altered capacity of the endocardium to react toward bacteria

Other investigators of the pathogenesis of endocarditis, for example, Dietrich[2] and Freifeld,[3] concluded from their experiments that endocardial localization of bacteria presupposes an "activation" of the endothelium i e, its transformation into endothelial phagocytes

In order to submit the aforementioned theory to an experimental test, we observed the reaction of the endocardium of rabbits that had received injections of casein toward india ink and carmine The technical details of the experiment are recorded in the accompanying table

The histologic observations were identical in all animals that received injections whether of india ink or carmine suspended in distilled water Neither the controls nor the animals previously treated with casein showed phagocytosis of carbon or carmine particles by the endothelial coat of the endocardium All animals that received injections of lithium carmine showed a finely granular deposit of carmine in the histiocytes of the endocardium The amount and the distribution of the carmine deposits in the controls did not differ from those in the animals treated with casein No karyorrhexis of either the endothelium or the histiocytes of the heart valves and no other regressive changes of the endocardium were found Numerous sections of the myocardium, liver spleen and bone-marrow failed to reveal any regressive or progressive

Submitted for publication, June 12, 1930

From the Institute of Pathology of the Western Pennsylvania Hospital, Dr Ralph R Mellon, director

1 Semsroth, K, and Koch, R Studies on the Pathogenesis of Bacterial Endocarditis, Arch Path 8 921, 1929

2 Dietrich, A Deutsche Gesellsch f inn Med 27 188, 1925

3 Freifeld, H Klin Wchnschr 7 1645, 1928

changes In particular, there was no focal proliferation of the Kupffer cells of the liver and no amyloidosis such as that reported by Kuczynski[4] as a sequel of repeated intramuscular injections of casein in mice The theory of endothelial activation in the sense of a transformation of the endothelium into phagocytes can therefore be dismissed as contrary to experimental observations The altered capacity of the endocardium to react toward bacteria has to be explained in some other way

Experiment to Determine the Effect of Injections of Casein on the Function of the Reticulo-Endothelial System

Days of Injection	Intravenous Injections Given Various Groups of Rabbits					
	1	1a (Controls)	2	2a (Controls)	3	3a (Controls)
1st 10th day	2% sodium caseinate, 1 cc increasing to 5 cc		2% sodium caseinate, 1 cc increasing to 5 cc		2% sodium caseinate, 1 cc increasing to 5 cc	
11th day						
9 a m	5 cc india ink (a 1 3 dilution in distilled water)	5 cc india ink (a 1 3 dilution in distilled water)	4 cc carmine (5% suspension in distilled water)	4 cc carmine (5% suspension in distilled water)	5 cc lithium carmine (5% carmine dissolved in saturated lithium carbonate)	5 cc lithium carmine (5% carmine dissolved in saturated lithium carbonate)
4 p m	5 cc india ink (a 1 3 dilution in distilled water)	5 cc india ink (a 1 3 dilution in distilled water)	4 cc carmine (5% suspension in distilled water)	4 cc carmine (5% suspension in distilled water)	5 cc lithium carmine (5% carmine dissolved in saturated lithium carbonate)	5 cc lithium carmine (5% carmine dissolved in saturated lithium carbonate)
12th day						
9 a m	5 cc india ink (a 1 3 dilution in distilled water)	5 cc india ink (a 1 3 dilution in distilled water)	4 cc carmine (5% suspension in distilled water)	4 cc carmine (5% suspension in distilled water)	5 cc lithium carmine (5% carmine dissolved in saturated lithium carbonate)	5 cc lithium carmine (5% carmine dissolved in saturated lithium carbonate)
11 a m	All animals were killed Autopsies were performed on all, and sections of heart liver, spleen, bone marrow and kidneys were prepared					

THE EFFECT OF INTRAVENOUS INJECTIONS OF CASEIN OR OF KILLED STREPTOCOCCI ON THE FUNCTIONAL STATE OF THE RETICULO-ENDOTHELIAL SYSTEM

In a study of the behavior of the vitally stained host against infections Silberberg[5] produced endocarditis regularly when he infected rabbits subsequent to a series of injections of lithium carmine Since lithium carmine is deposited in the cells of the reticulo-endothelial system the assumption that changes in the function of the reticulo-endothelial system are involved in the pathogenesis of endocarditis was considered worthy of

4 Kuczynski, M H Virchows Arch f path Anat **239** 185, 1922
5 Silberberg, M Virchows Arch f path Anat **267** 483, 1928

experimental study The method that we used for demonstrating such a relationship differed from the method that Silberberg used and that is generally applied for the study of the reticulo-endothelial system Commonly, dyes are used as a means for influencing the function of the reticulo-endothelial system, often with the object of a so-called blockade in mind The limitations of such a procedure are evident and have been pointed out repeatedly The more promising way seemed to be to use the dyes as indicators of the function of the reticulo-endothelial cells, after the animals had received parenteral applications of casein

Another series of animals was given injections according to the technic given in the table The animals were killed two hours after the last injection autopsies performed and sections of spleen, liver and bone marrow prepared

The histologic observations were identical in all animals receiving injections of india ink or carmine suspended in distilled water The storage of carbon or carmine particles by the organs of the reticulo-endothelial system—liver, spleen and bone marrow—in the animals treated with casein was not found to differ from that in the controls Rabbits treated with casein, however, and receiving injections of lithium carmine showed only traces of granular carmine, while normal control rabbits showed an ample deposit of finely granular carmine

If this change in the function of the reticulo-endothelial cells, indicated by the absence of carmine deposits, is associated with the pathogenesis of endocarditis and is not due to a specific action of the casein, any procedure that leads to an experimental endocarditis should present this change under controlled conditions Friefeld[7] showed that staphylococcus bacteremia of rabbits leads to endocarditis if the animals have been subjected to six daily injections of killed streptococci previous to the infection

For an experimental test of this assumption, the technic recorded in the table was modified by replacing the injections of casein with six daily injections of killed streptococci The dyes were injected as in the previous experiment, on the seventh and eighth days All animals were killed two hours after the last injection of dye, autopsies performed and sections prepared The results were identical with those of the previous experiments The main features are summarized schematically in figure 1

Further information about this change in the function of the reticulo-endothelial cells was gained by a study of animals killed at varying periods after the last injection of dye

In normal rabbits, the amount of lithium carmine deposited increased up to two hours and then persisted in this quantity for at least a week In rabbits that received ten daily injections of sodium caseinate and

then three injections of lithium carmine, examination after one-half hour revealed absence of the dye, after one hour, about half of the amount of carmine present in the cells of a normal animal could be seen after two hours, the dye had disappeared

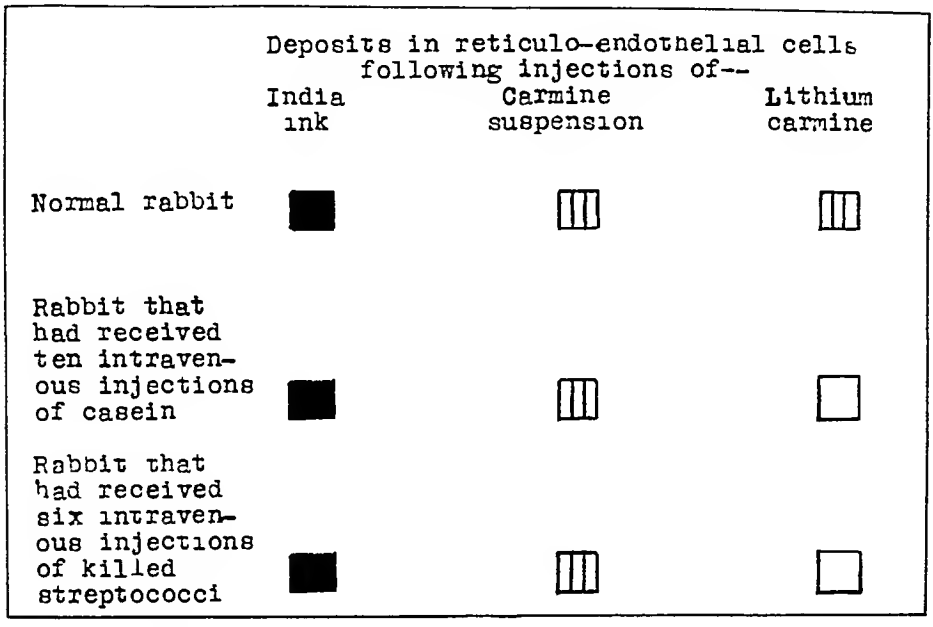

Fig 1—The effect of a series of injections of casein or of killed streptococci on the reticulo-endothelial system of rabbits, as shown by deposition of subsequently injected india ink, carmine suspension or lithium carmine in the reticulo-endothelial cells The solid square represents carbon, the barred square, carmine, and the blank square, a reticulo-endothelial system free from deposits of dye Each animal was killed two hours after the last injection of dye substance

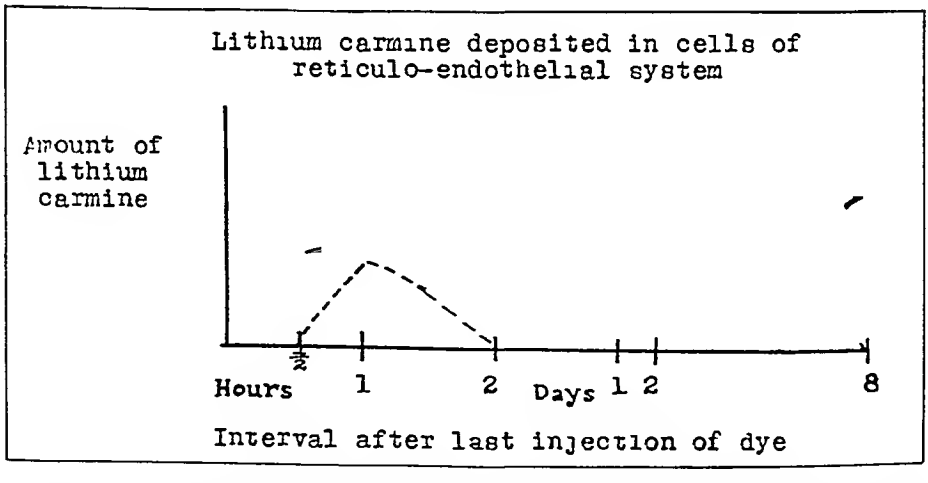

Fig 2—The deposit of lithium carmine in the cells of the reticulo-endothelial system of a rabbit that had received ten intravenous injections of casein The solid line represents the deposit in a normal rabbit (control) and the dotted line that in the rabbit treated with casein

Whether this change in the function of the reticulo-endothelial cells indicated by the variations of their behavior toward lithium carmine is primarily due to a metabolic or to a secretory disturbance of the cells themselves or is secondary to excretory disturbance remains a matter for further study. Repeated injections of foreign proteins led, in the experience of Haendel and Malet,[6] to an increased ability of the reticulo-endothelial system to store india ink. While these authors regarded their results as proof of increased function, our own experience shows that such a conclusion is misleading. When a solution of lithium carmine is used as an indicator—instead of a suspension—repeated intravenous injections of a foreign protein are found to lead to a function that could be termed "decreased," if the amount of dye deposited is taken as a criterion, or "increased," if the rate of disappearance of the dye is made the sole point of interest. This matter is then a relative one, unless other supporting criteria are invoked that will prove physiologically decisive.

EXPERIMENTAL TOXIC ENDOCARDITIS AND MYOCARDITIS

A deleterious effect of bacterial toxic products on the heart valves preceding the endocardial localization of bacteria was considered important by Ribbert.[7] Wadsworth,[8] studying endocarditis in pneumococcus-immunized horses, was led to conclude that "bacterial poisons produce the predisposing injury." Experimental proof of such a predisposing role of bacterial toxic products is, however, extremely scanty.

While the production of endocardial lesions by means of a toxin in a few experimental animals was reported by de Vecchi,[9] these processes were not accepted by Ribbert as truly inflammatory. Experimental investigations into the action of bacterial toxins must take into consideration absorption and fixation of these toxins in various tissues. In this process, the reticulo-endothelial system plays a prominent rôle, as demonstrated by recent investigations.

It was shown previously that intravenous injections of casein or of streptococcic vaccine led to a definite functional change of the reticulo-endothelial system, on the one hand, and to a predisposition of the animal to endocardial localization of bacteria, on the other. We were led to infer that a relationship between this functional change of the reticulo-endothelial system and the endocardial localization of bacteria

6 Haendel, M., and Malet, J. Deutsche med. Wchnschr. **55** 617, 1929.

7 Ribbert, H., in Henke and Lubarsch: Handbuch der speciellen pathologischen Anatomie und Histologie, Berlin, Julius Springer, 1924, vol. 2, pp. 203 and 209.

8 Wadsworth, A. B.: J. M. Research **39** 279, 1918-1919.

9 de Vecchi, quoted by Ribbert (footnote 7, p. 209).

may exist through an increased deleterious effect of bacterial toxins on the heart The validity of this inference was confirmed in the following experiments

Experiment 1—In a first series, four rabbits received ten intravenous injections of a 2 per cent solution of casein They were subsequently given intravenously from 0 0002 to 0 1 cc of a diphtheria toxin Four control animals received like doses of the same diphtheria toxin Autopsies were done on the first, second or fifth day after the injection of the toxin Serial sections of the heart were prepared in all cases



Fig 3—An area (*N*) of homogenization and necrobiosis in a heart valve of a rabbit that had received ten intravenous injections of casein and then an intravenous injection of 1 cc of a 1 1,000 dilution of diphtheria toxin

Histologic Observations In the control animals, a few small areas of necrobiosis were found within the valvular substance No further valvular lesion and no myocarditis was noticed In the animals that had been prepared with injections of casein, areas of hyaline transformation of the valvular substance with scarcity of nuclei were observed (fig 3) At numerous places, focal accumulations of large, oval—in many instances, bizarre-shaped—nuclei were seen Karyorrhexis and formation of multinuclear cells were present (fig 4) In some instances, a valve showed a definite polymorphonuclear leukocytic infiltration, an exudative valvulitis (fig 5)

Fig 4 —A focal proliferative reaction of a heart valve of a rabbit that had received ten intravenous injections of casein and then an intravenous injection of 1 cc of a 1 10 dilution of diphtheria toxin

Fig 5—Acute exudative valvulitis in a rabbit that had received ten intravenous injections of casein and then an intravenous injection of 1 cc of a 1 10 dilution of diphtheria toxin

In all four of the animals treated with casein, the myocardium showed focal interstitial inflammatory lesions They were characterized by accumulations of lymphocytes with a few eosinophil leukocytes and proliferation of large mononuclear elements, presumably histiocytes, i e, they bore a close analogy to the focal myocarditis of human endocarditis

Experiment 2—In a second series, two rabbits received ten intravenous injections of 2 per cent solution of casein and two more rabbits six intravenous injections of a streptococcic vaccine All four animals were subsequently given intravenous doses of killed typhoid bacilli, starting with 0 25 cc and increasing by 0 25 cc with each injection They were killed seven days later

Fig 6—A hyaline thrombus over an area of advanced karyorrhexis and accumulation of finely granular chromatin (vaccine?) in a heart valve of a rabbit that had received ten intravenous injections of casein and then four intravenous injections of typhoid vaccine

Four control animals received the same doses of typhoid vaccine without preceding injections of casein or streptococcic vaccine They were killed seven days later Serial sections of the heart were prepared in all cases

Histologic Observations Moderate hemorrhages into the heart valves and slight valvular edema were found in the controls, which had been treated with typhoid vaccine only There was no further lesion of the heart valves No myocardial change was noticed Valvular hemorrhage and edema were present in the animals previously treated with casein or streptococcic vaccine, as in the controls In addition, however, the valves of all these animals showed focal or more diffuse accumulations of large, oval, frequently bizarre-shaped nuclei with karyorrhexis in many instances (fig 6) At a few places, masses of finely granular

chromatin were found within the superficial, broken-down valvular substance, covered by a "hyaline" thrombus In one instance, the endocardial coat of a papillary muscle showed a definite inflammatory exudative process

COMMENT

Two hypotheses have been advanced in explanation of the pathogenesis of endocarditis (1) that of elective localization of certain bacterial strains and (2) that of endocarditis as an allergic phenomenon Against the preponderant influence of the elective localization theory may be brought the evidence that the infection is not limited to one type of micro-organism, but is due to multiplicity of bacteria The allergic theory offers a reasonable explanation of the divergent bacteriologic observations The experimental investigations of a number of authors (Dietrich, Freifeld, Semsroth and Koch) have led to the conclusion that endocardial localization of bacteria presupposes a change in the reactivity of the host As to the nature of this reactive change, considerable difference of opinion prevails

A sensitization or activation of the endocardium in the sense of a transformation of its endothelium into phagocytes was assumed to be the decisive factor by Dietrich Experimental work by Pfuhl [10] and our own results fail to reveal any evidence of such a transformation

In contrast with this theory of activation stands the conception that some form of damage to the heart valves precedes endocardial localization of bacteria (Ribbert,[7] Wadsworth [8]) Experimental evidence that mechanical injury to the heart valves enables bacteria to localize on them has been available for a considerable length of time On the other hand, it has been shown that repeated injections of casein (or of killed streptococci or of lithium carmine) lead to localization of the bacteria on the endocardium in a high percentage of the experimental animals, but do not lead per se to a recognizable cellular damage of the endocardium In the present paper, evidence has been brought forward that such measures (injections of casein, etc) lead to a definite functional change of the reticulo-endothelial system Furthermore, results have been obtained indicating that in the presence of the functional change the detoxifying effect of the reticulo-endothelial system is interfered with Amounts of toxic bacterial products that in the normal animal fail to exert a deleterious effect on the heart valves lead to cellular damage and reaction In the light of these results, the theory of a preceding cellular damage to the endocardium may well be upheld in a modified manner Our observations suggest that a decisive factor in the pathogenesis of endocarditis is a disturbance of the detoxifying ability of the reticulo-endothelial system In the presence

10 Pfuhl, W Ztschr f mikr anat Forsch **17** 1, 1929

of this disturbance amounts of toxic bacterial products that are practically innocuous to the tissues of the normal animal lead to inflammatory lesions of the endocardium This cellular damage in turn enables bacteria to localize on the endocardium

SUMMARY

Repeated intravenous injections of casein or of killed streptococci do not lead to degenerative changes of the endocardium nor to a transformation of the endothelial coat of the endocardium into phagocytes (There is no activation of the endothelium in the sense of Dietrich)

Subsequent to repeated intravenous injections of casein or of killed streptococci, the phagocytosis of particles of colloidal dye by the reticuloendothelial system is not disturbed

On the other hand, the response of the casein-sensitized reticuloendothelial system to a true solution of carmine (lithium carmine) is definite, the storage of this dye is markedly inhibited in the animals treated with casein in contrast with the control animals, which absorb it readily

In the presence of this functional change, sublethal doses of diphtheria toxin and of killed typhoid bacilli exert an increased deleterious effect on the endocardium and myocardium Such animals show inflammatory lesions of the endocardium and myocardium, while controls fail to show inflammatory lesions

ENDOMETRIOMYOMA OF THE UMBILICUS[1]

NORBERT ENZER, M D
MILWAUKEE

Tumors of the umbilicus are relatively infrequent Among the most interesting are those containing tissue resembling endometrium The resemblance is sufficiently close to entitle such tumors to the name of endometrioma In view of the fact that some of these structures contain smooth muscle the term endometriomyoma is more suitable Adenomyoma may strictly speaking be a more correct term since the proof that the glands and stroma are like endometrium in every essential or at least have the same immediate origin as endometrium is still wanting Study of these tumors may throw some light on the origin of extra-uterine endometrial growths Although it is by no means certain that all ectopic endometriomas have a common mode of origin it seems fairly certain that the endometriomyomas of the umbilicus do not take origin from explanted, fully differentiated endometrium a point which the instance reported here supports

REPORT OF A CASE

A white girl, 18 years of age, noticed a small warty growth in the umbilicus six months before it was removed This tumor was neither painful nor tender A few days before the operation and ten days after menstruation, it oozed blood for the first time The growth did not enlarge or become painful at the menstrual periods, but rather maintained a slow, steady increase in size until it was about 1 inch (2 5 cm) in diameter The menstrual history did not reveal any abnormalities The tumor was excised by an elliptic incision, and was found to extend down to the peritoneum The peritoneal cavity was opened, and the peritoneum lining the umbilical fossa was removed with the lumen The abdominal cavity was not explored

The specimen was a nodular, knobby growth, pouting out of the umbilical fossa and measuring 2 5 by 2 by 2 cm The skin over the tumor followed the convolutions of the surface, dipping into the crevices The cut surface was smooth and of a fibrous structure surrounded by fat The center of the peritoneal surface was deeply dimpled The tumor was not encapsulated, but was rather sharply limited A few small cystic spaces could be discerned with the aid of a hand lens

The sections revealed an adenomatous formation separated from the squamous epithelium by the corium and composed of rather densely packed smooth muscle fibers and cells and occasional strands of connective tissue Glandular structures were scattered throughout the specimen, varying in size from small oval and round glands to larger cystic ones These glandular structures were lined by a single layer of columnar, nonciliated cells, except in a few of the larger glands, in

[1] Submitted for publication, June 23, 1930

[2] From the Laboratories of Mount Sinai Hospital

which the cells were more cuboidal Within several of the glands was hemorrhage, varying in amount from only a few to a considerable cluster of erythrocytes, there were also leukocytes and desquamated epithelial cells Most of the glands were surrounded by a cellular stroma and occasionally there were small hemorrhagic extravasations The stroma cells were elongated, spindle-shaped and closely packed Occasional glands were found surrounded by more loosely arranged stroma and here the cells assumed an oval shape The stroma was not uniformly distributed around the glands, but was generally massed to one side (figs 1 and 2)

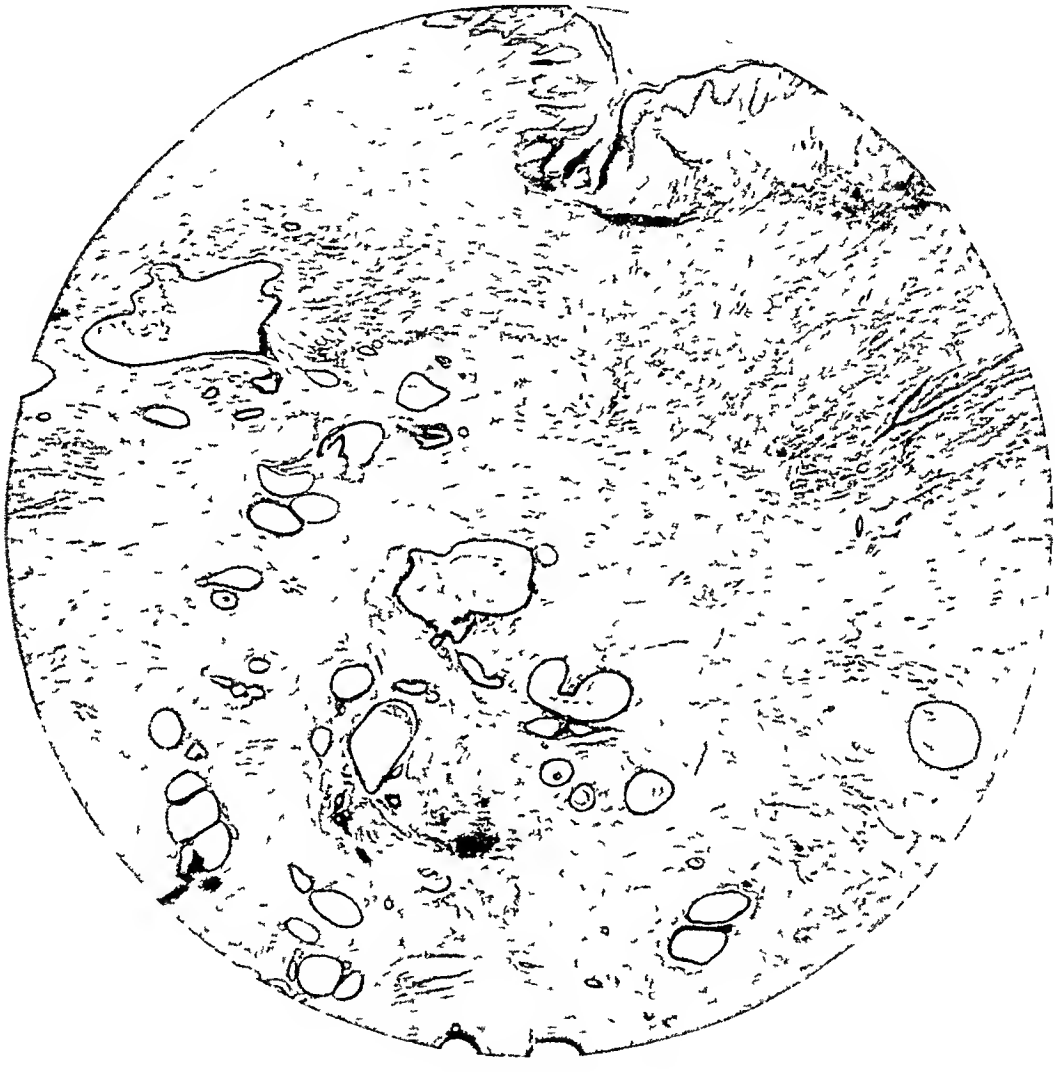

Fig 1—Low power magnification showing general structure and relation of glands to skin

The peritoneal surface of this tumor was of considerable importance and interest The peritoneal cells were hyperplastic and almost columnar These could be noted in the fold of peritoneum dipping into the dimple mentioned Adjacent to the fold was an elongated glandular structure lined by low columnar epithelium, which by serial section could be traced to the peritoneum This gland contained a few erythrocytes, but was not surrounded by endometrioid stroma The lining epithelium resembled the hyperplastic peritoneal cells rather than the columnar cells of the glands first described

One other glandular element was encountered Two glandlike structures were found close to the peritoneal surface Their lining epithelium was different from that of the other glands They were lined by a single layer of large, mucus-secreting goblet cells These glands were surrounded by a loose meshwork of connective tissue, and not by cellular, endometrioid stroma (fig 3)

In some areas, a small amount of myxomatous-like material was found This had the characteristic blurred, amorphous character of myxomatous degeneration,

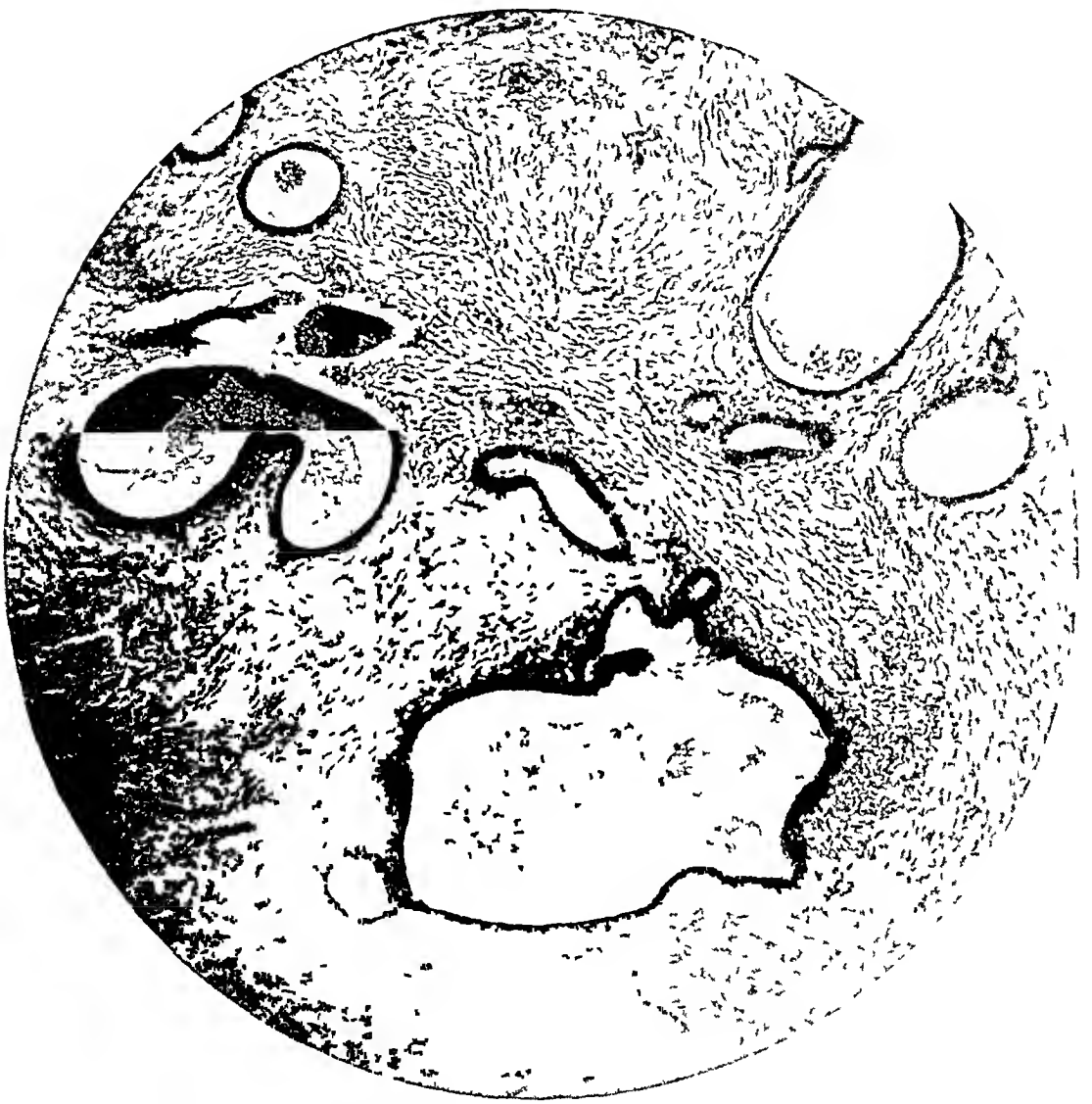

Fig 2—High power magnification showing hemorrhage in glands and periglandular stroma

and took a faint basophilic stain These areas did not contain any cells, and were placed between the muscle and connective tissue fibers

COMMENT

Whether or not one is justified in calling such tumors as this endometriomas may be disputed At least, the resemblance of the glands

and surrounding stroma to endometrium is as close as that of the endometriomas in the broad ligament and in the pouch of Douglas and even of the adenomyomas of the uterus to true endometrium So that until definite cytologic criteria are established for endometrium, the term is justified The resemblance is further strengthened by the

Fig 3—Glands lined by goblet cells

presence of hemorrhage As the literature on this subject shows, many of the tumors bleed at the menstrual periods

Naturally, the most interesting question concerns the origin of the tissues present in the tumor described It seems unreasonable to attribute the tumor to transplanted bits of endometrium, carried either by the blood stream or by the lymphatics If such a transportation occurred, it is difficult to explain how the tissue arrived at the umbilicus and grew in the abdominal wall without producing evidence of implantation else-

where The implantation theory probably is most applicable to the endometriomas occurring in laparotomy scars of which a goodly number have been reported But here, too, this explanation is open to doubt for it seems so unlikely that a needle passed through the outer layer of myometrium could pick up and transplant endometrial tissue, and this explanation certainly would not suffice for the occurrence of endometrioma following operations not involving the uterus

It would seem that the specimen reported here offers evidence in favor of the local origin of the heterologous tissue The direct continuity of peritoneum with one of the glands would point to a metaplasia of tissue of peritoneal origin The finding of the mucus-secreting cells might indicate an origin from the omphalomesenteric duct, and the presence of smooth muscle fibers would lend support to this However, whether one chooses to consider a direct origin from the remnant of the duct or from the peritoneum is of little moment, since their origin is a common one Of course, one could on this basis attribute the origin of endometrial tissue in the umbilicus to a faulty differentiation of the entoderm, allowing that a few cells destined to become endometrium will be isolated at the umbilicus This, however, becomes pure speculation

Two elements in the case reported deserve further comment The presence of the mucus-secreting cells may be considered accidental or they may be considered as evidence of the local origin of the endometrioma Roques[1] pointed out that portions of the vitelline duct occasionally persist at the umbilicus but the epithelium does not possess the function of menstruation, nor are these portions surrounded by endometrial stroma Since the two glands described were the only ones of this type found in a great many sections, it seems reasonable to consider them as remnants of the duct From that point of view, they do not seem to be an integral part of the tumor, but rather were caught in the growth Still, the possibility that these glands are the result of peritoneal metaplasia and have the same histogenesis as the endometrial tissue cannot be ignored, theoretically, especially if one remembers the multiple potencies of entoderm It would be difficult to explain however, why one group of cells went on to endometrial differentiation and another group differentiated into epithelium of the celomic type

The smooth muscle forming an integral part of the tumor is also of importance If endometrium could have been transplanted, it is hardly likely to have carried smooth muscle fibers with it, so that the local origin of the smooth muscle is probably beyond dispute Meyer

1 Roques, F Endometrial Tumors of the Umbilicus, Proc Roy Soc Med **21** 538, 1928

Renesch, Nicholson[2] and others expressed the opinion that the smooth muscle fibers are derived from local tissues In regions in which unstriped muscle is not found normally, its presence has been attributed to a metaplasia of the surrounding connective tissue However having once established an embryologic origin for the epithelial structures it seems more rational to explain the presence of the smooth muscle on the same basis It does not seem likely that one element of the tumor would have one origin and another element a different origin Furthermore there is no proof that explants of endometrium can stimulate smooth muscle metaplasia from connective tissue, or that the stroma cells of the endometrium can give rise to smooth muscle Those who have explanted endometrium did not find smooth muscle cells in the explants, with one exception Michon[3] transplanted minute pieces of endometrium into the ovary of the rabbit There was hyperplasia of smooth muscle around the transplanted epithelium It is possible that he introduced smooth muscle fibers along with the uterine mucosa In experiments on tissue culture with successful growth of endometrium, smooth muscle cells have not been found Transplantation would account for the presence of smooth muscle in endometriomyomas in laparotomy scars, particularly after cesarean section provided one considers the transplantation theory tenable, and it would have application in cases in which the tumor followed an operation during which the uterine cavity was opened

Both the serosal theory and the theory of congenital misplacement seem to be applicable to the tumor reported here and likewise to the other instances reported in the literature

Palmen[4] takes the stand that they probably originate from the embryonic umbilical epithelium, as yet undifferentiated contrary to those cysts and fistulas arising from remains of the fully developed vitelline duct

Weller[5] at the meeting of the American Association of Pathologists and Bacteriologists in 1927, reported two cases of menstruating umbilical tumors Smooth muscle was not found in either instance He stated that the occurrence of these tumors at the umbilicus cannot be satisfactorily explained as being due to endometrial implantation or to lymphogenous or hematogenous metastases from proliferating endometrial

2 Nicholson, G W Studies in Tumour Formation Mixed Tumours, Guy's Hosp Rep **76** 188, 1926

3 Michon, quoted by Jacobsen, V C Ectopic Endometriosis, Arch Path **5** 1054, 1928

4 Palmen, A J Zur Kenntnis der Nabeladenome, Acta chir Scandinav **62** 310, 1927

5 Weller quoted by Jacobsen, V C Ectopic Endometriosis, Arch Path **5** 1054, 1928

growths in the pelvis In his opinion, the occurrence of these tumors at the umbilicus throws doubt on the theories of Sampson in regard to the origin of this entire group, and seems to find its best explanation in a theory based on serosal origin

Smooth muscle has been found by Green,[6] Mintz[7] Goddard,[8] Barker,[9] Cullen,[10] Matthias, Munro and Bottomley,[11] Mahle and McCarty,[12] Edwards and Spencer,[13] Stacy, Drips, Offutt and Moerich[14] Palmer,[4] and Roques,[1] and not found or not mentioned by von Noorden,[11] Giannettasio[15] Herzenberg[16] Ehrlich,[17] Zitronblatt[18] Lauche[19] Tobler,[20] Keitler,[21] Schiffman and Seyfert[22] Le Lievre and

6 Green, C D A Case of Umbilical Papilloma Which Showed Some Activity of Growth in a Patient Fifty Years of Age, and Which Was Due Apparently to the Inclusion of a Portion of Meckel's Diverticulum, Tr Path Soc, London **50** 243, 1898-1899

7 Mintz, W M Das wahre Adenom des Nabels, Deutsche Ztschr f Chir **51** 545, 1899

8 Goddard, S W Two Umbilical Tumors of Probable Uterine Origin, Surg Gynec Obst **9** 249, 1909

9 Barker, A Three Cases of Solid Tumours of the Umbilicus in Adults, Lancet **2** 128 and 130, 1913

10 Cullen, T S The Umbilicus, Philadelphia, W B Saunders Company, 1916

11 Quoted by Cullen (footnote 10)

12 Mahle, A E, and MacCarty, W C Ectopic Adenomyoma of the Uterine Type, J Lab & Clin Med **5** 218, 1919

13 Edwards, C R, and Spencer, H R Adenomyoma of the Umbilicus, Arch Surg **11** 684, 1925

14 Stacy, L J, Drips, D G, Offutt, S R, and Moerich, L M Adenomyoma of the Umbilicus, M Clin North America **10** 677, 1926

15 Giannettasio, N Sur les tumeurs de l'ombilic, Arch gen de med **3** 52, 1900

16 Herzenberg, R Ein Beitrag zum wahren Adenom des Nabels, Deutsche med Wchnschr **35** 889, 1909

17 Ehrlich, H Primares doppelseitiges Mammacarcinom und wahres Nabeladenom, ein Beitrag zur Beurteilung multipler Tumoren, Arch f klin Chir **89** 742, 1909

18 Zitronblatt, A Zur Kasuistik und Histogenese der Nabeladenom, Deutsche med Wchnschr **39** 371, 1913

19 Lauche, A Die extragenitalen heterotopen Epithelwucherungen vom Bau der Uterusschleimhaut, Virchows Arch f path Anat **243** 398, 1923, Zur Pathologie der Nabelgegend, Verhandl d deutsch path Gesellsch **19** 341, 1923

20 Tobler, T Ueber tumorartige entzundliche Uterindriesen ahnliche Wucherungen des peritoneal Epithels in Laparotomienarben und uber ebensolche spontan Wucherungen im Nabel, Frankfurt Ztschr f Path **29** 558 1923

21 Keitler, H Ueber einem Fall von Nabeladenom, Monatschr f Geburtsch u Gynak **64** 171, 1923

22 Schiffman, J, and Seyfert, W Ein Nabeladenom, Arch f Gynak **127** 208, 1925

Montpellier[23] Oberling and Hickel,[24] Kohler,[25] Andrews,[26] Steiner,[27] Busser[28] and Baltzer[29] Fraser[30] reported finding an endometrioma of the umbilicus in *Macacus rhesus* and some twenty-three endometriomas in the peritoneal cavity of the same monkey The umbilical tumor did not contain smooth muscle, nor was it connected with the peritoneum The peritoneum has been reported to be connected with the umbilical tumor by Giannettasio,[15] Barker,[9] Mintz,[7] Herzenberg,[16] Waegelin,[31] and Tobler[20] The latter recorded a deep, funnel-shaped diverticulum of the peritoneum to which the tumor was attached Roques[1] described a peritoneal fold similar to the one found in the specimen reported here The great majority recorded bleeding at menstruation, and sometimes painful swelling and bluish discoloration The tumor is found most often in women between 35 and 45 years of age The patient whose case is reported here was the youngest on record to have had a tumor of this type Kohler,[25] in 1927, reported what he claimed was the thirty-second case on record Since that date nine cases including the one reported here have been recorded, bringing the total number to forty-one

SUMMARY

A case of endometriomyoma of the umbilicus is described The tumor was composed of glands and stroma similar to endometrium and smooth muscle Two mucus-secreting glands were found in the tumor Glands were discovered and traced to the peritoneum Evidence is offered in favor of the local origin of the tissue Both the theory of serosal origin and that of congenital misplacement may be used to explain the origin of the heterologous tissue, since there is some evidence in favor of each The transplantation theory does not seem to be applicable to tumors like this one The immediate origin from a remnant of the omphalomesenteric duct is likewise unlikely A remote origin from the tissues forming the omphalomesenteric duct is possible

23 Le Lievre and Montpellier Sur un cas d'endometriome de la region ombilicale Bull Assoc franç p l etude du cancer **16** 867, 1927

24 Oberling, C, and Hickel, P Le probleme de l'endometriome A propos de deux cas nouveaux (intestin et ombilic), Bull Assoc franç p l'etude du cancer **16** 691, 1927

25 Kohler, R Adenomyosis des Nabels, Zentralbl f Gynak **51** 2201, 1927

26 Andrews, H R A Case of Endometrioma of the Umbilicus, J Obst & Gynaec Brit Emp **32** 545, 1925

27 Steiner, H Ein Nabeladenom, Zentralbl f Gynak **51** 2796, 1927

28 Busser, F, Van der Horst, and Dronhard Endometriome de l'ombilic, Ann d'anat path **5** 229, 1928

29 Baltzer, H Ueber heterotope endometrioide Wucherungen ins besondere am Nabel ("Nabeladenom"), Zentralbl f Gynak **53** 99, 1929

30 Fraser, A D Ectopic Endometrium in Macacus Rhesus, J Obst & Gynaec Brit Emp **36** 590, 1929

31 Waegelin, H Zur Histogenese der Nabeladenom nebst einem kasuistischen Beitrag Frankfurt Ztschr f Path **14** 367, 1913

THE VARIATION IN WEIGHT OF THE THYROID GLAND AND THE FREQUENCY OF ITS ABNORMAL ENLARGEMENT IN THE REGION OF CHICAGO*

R H JAFFÉ, M D
CHICAGO

The statistical reports on the frequency and geographic distribution of goiter in the United States are based chiefly on the systematic examination of certain parts of the population in which such examination can be easily carried out, as for example school children, university students and men encamped through military draft Valuable as the results of these surveys of goiter are, they do not satisfy fully, because in them all age groups are not considered to the same extent, and because they involve a variable factor in the ability, special training and experience of the examining physician Furthermore, no information is given in them as to the type of goiter Anatomic studies of the thyroid gland are therefore of great value in completing the data collected by examination of the living Against anatomic studies, the objection may be made that the cause of death may have influenced the weight and structure of the gland, and that hence the results could not be applied to the healthy population The weight of the thyroid gland, however, decreases only in chronic wasting diseases, and this decrease is part of the atrophy of the other organs The circumscribed enlargements of the thyroid gland in the form of nodes are apparently not affected Critical selection of the material will therefore meet with this objection

MATERIAL OF STUDY

The present study is based on the examination of the thyroid gland in 1,000 autopsies Cases in which there was marked atrophy of the internal organs were excluded The thyroid was dissected out and, after being weighed, was cut into parallel, sagittal sections about 0 5 cm apart and examined for the presence of nodules and nodes The material was divided into two groups One group contained the glands that were free from nodes, while the other group was composed of the glands with nodes

* Submitted for publication, June 30, 1930

* From the Department of Pathology, Cook County Hospital

According to age, sex and race, the glands were distributed as shown in table 1 In addition there were thyroid glands from twenty-eight Mexican men and from twenty-two Mexican women

THE AVERAGE WEIGHT OF THE THYROID GLAND IN THE REGION OF CHICAGO

Before the frequency of enlargement can be determined, it is necessary to determine the average weight of the thyroid gland For compiling this weight, only glands without nodes were used In my series of cases, the weight of the thyroid gland in the first year of life was about the same as that reported from Germany (Wegelin [1]), France (Tourdes,[2] Testut [2]) and Italy (Cavaloni,[3] Maedele [3]) There is no marked difference in weight of the thyroid gland at this age between

TABLE 1—*Distribution of the Thyroid Glands Studied*

	Number of Thyroid Glands				
	White Race		Colored Race		
Age Period	Male	Female	Male	Female	Total
0- 1	9	9	11	8	37
1- 6	13	12	10	10	45
7-17	14	14	12	11	51
18-21	4	6	6	6	22
22-30	18	16	36	31	101
31-40	48	40	48	26	162
41-50	104	27	52	25	208
51-60	85	19	28	9	141
61-70	76	25	18	14	133
Above 70	34	10	4	2	50
Total	405	178	225	142	950

the two races The gland in the females is slightly larger than that in the males This difference disappears in childhood During puberty there is a rapid growth of the thyroid gland in both the males and the females The weight of the thyroid gland increases slightly after the growth of the body has ceased, and in white males reaches a maximum in the third decade Then, under fluctuation, it decreases to start a new rise in the fifth decade May [4] also stated that the thyroid gland of the male becomes enlarged after the age of 50, a new proliferation that does not occur in the female The weight curves of the Negro's thyroid gland is somewhat different, it reaches its maximum in the sixth decade, after which it shows a rather sharp decline The weight curve of the thyroid gland of the white woman is highest

1 Wegelin C Schilddruese, in Henke, F, and Lubarsch, O Handbuch der speziellen pathologischen Anatomie, Berlin, Julius Springer, 1926, vol 8

2 Quoted by Wegelin (footnote 1)

3 Quoted by Riddle O Endokrinologie **5** 241, 1929

4 May, H Arch f klin Chir **149** 501, 1928

between the ages of 30 and 50, when it is slightly above that of the white man Later, it drops continuously In colored women, the curve runs almost parallel, but at a lower level The average weight of the thyroid gland in white men is 27 4 Gm , in colored men, 27 4 Gm , in white women, 28 1 Gm , and in colored women, 24 6 Gm The Mexicans were too few to be subdivided into age groups, and therefore only the average weight of the thyroid gland according to sex is given 23 Gm for males and 26 Gm for females

In the literature on the thyroid gland, the figures for the weight vary considerably Thus, Vierordt[5] in his anatomic physiologic tables gave the weight as 33 8 Gm , Orth[6] as from 30 to 60 Gm , Marchant[2] as from 22 to 24 Gm , Guiart[7] as 25 Gm , Wegelin[1] as from 20 to 25 Gm , Carlaldy as from 16 to 21 Gm , Lucien, Parisot and Richard[8] as 35 Gm , Crile[9] as from 25 to 40 Gm and Schaer[10] as 26 4 Gm for

TABLE 2—*Average Weight of Thyroid Gland*

	Average Weight of Thyroid Gland Gm			
	White		Colored	
Age Period	Males	Females	Males	Females
0- 1	1 6	2 6	1 9	2 9
1- 6	5 2	5 4	4 8	5 1
7-17	13 2	15 4	15 7	15 3
18-21	22 3	20 8	19 5	23 6
21-30	28 6	26 7	25 2	24 3
31-40	29 8	31 7	25 7	25 4
41-50	26 5	31 0	29 0	24 5
51-60	27 5	21 2	30 8	22 3
61-70	23 3	19 5	31 4	21 4
Above 70	26 0	16 0	23 3	21 0

the male gland and 25 5 Gm for the female gland According to Osaki, Horisawa[2] and others, the thyroid gland of the Japanese is smaller than one would expect from the length of body of this race, the gland is only a little more than half the size of that of the white race

DIFFUSE ENLARGEMENT OF THE THYROID GLAND

In all the age groups there is considerable variation in the weight of the thyroid gland, which in my series amounts to from 15 to 140 Gm This holds true for both races and both sexes It is there-

5 Vierordt Daten und Tabellen, Jena, Gustav Fischer, 1893

6 Orth, J Lehrbuch der speziellen pathologischen Anatomie, Berlin, 1887, vol 1

7 Guiart Thèse de Paris, 1896

8 Lucien, M , Parisot, J , and Richard, G Traite d endocrinologie, Paris, G Doin, 1925

9 Crile, G W , and associates The Thyroid Gland, Philadelphia, W B Saunders Company, 1923

10 Schaer, H Frankfurt Ztschr f Path **36** 249, 1928

fore difficult to fix a definite weight above which the gland is to be considered enlarged The figures in the table on the frequency of diffuse enlargement of the thyroid gland are based on a weight above 40 Gm It is not so much the weight that induces me to regard these glands as goitrous as it is their structure The glands show the macroscopic and microscopic picture of diffuse colloid goiter They are rich in colloid and are composed of large colloid-filled follicles with slight or without proliferative changes

The diffuse colloid goiter is most common in persons below the age of 50 In white males the greatest frequency is found in the second and third decades of life, and in colored males in the fourth decade of life There is a distinctly greater frequency among the males than among the females, in my series, no diffuse colloid goiter was found in a white or colored woman past the age of 50

TABLE 3—*Percentage of the Thyroids Weighing Above 40 Gm*

	White Per Cent		Colored, Per Cent	
Age Period	Males	Females	Males	Females
18-21	25 0	16 6		
22-30	16 6	12 5	11 1	9 6
31-40	16 6	12 5	12 5	11 5
41-50	11 5	7 4	15 3	12 0
51-60	11 7		14 2	
61-70	6 5		11 1	
Above 70	6 2			
All age periods	11 3	8 7	11 2	7 8

In regions of endemic goiter, diffuse enlargement of the thyroid is much less common than the nodose type Wegelin (Bern) gave the percentage as 11 6 and Hellwig[11] (Freiburg in Breisgau) as 4 02 per cent Wegelin did not find the difference between the sexes that I observed

NODOSE ENLARGEMENT OF THE THYROID GLAND

The youngest person presenting a nodose goiter, in my series, was a white girl aged 12, then there were a colored boy 14 years of age and a white boy 15 years of age In all four groups there is a constant increase in the frequency of the nodose enlargement of the thyroid gland with progressing age, but the rate of this increase shows marked differences The sharpest rise is found in white women, the thyroids of two thirds of the white women past the age of 60 contain nodes In colored women, the highest level is reached at the ages of from 61 to 70 In the seventh decade there is a decrease In white and colored men, the

11 Hellwig, A Mitt a d Grenzgeb d Med u Chir **32** 508, 1920

increase is much more gradual and lies distinctly below that in the female sex The difference is greatest in the age groups above 40

There is a difference in the frequency of nodose goiter between the white and the colored race, especially if all the age groups are taken together It is then found that the percentage of nodose goiter in white males is 30, in colored males 14 5, in white females 44 7 and in colored females 25 5

Hellwig,[12] discussing the type of North American goiter, stated that in his surgical material the weight of the goitrous gland is on an average from 80 to 100 Gm This is slightly more than I have observed at autopsy The gland with nodes usually is heavier than the gland without nodes, but weights above 100 Gm are rare In my series, there were only twenty goiters the weights of which were above 100 Gm and five the weights of which were above 200 Gm These large glands were found only in women The weight of the largest gland was

TABLE 4—*Percentage of Nodose Goiters*

Age Period	White, Per Cent		Colored Per Cent	
	Males	Females	Males	Females
18-21			2 0	
21-30	5 5	18 7	5 5	6 4
31-40	22 8	30 0	12 5	15 3
41-50	23 0	40 7	11 4	32 0
51-60	29 4	63 2	17 9	44 0
61-70	46 0	72 0	33 0	78 5
Above 70	44 1	80 0	25 0	50 0

400 Gm It was found in a white woman, aged 71 Most of the nodes were small, averaging from 5 to 20 mm in diameter, only 5 per cent of the nodes were more than 30 mm in diameter

COMMENT

The Cook County Hospital draws its material chiefly from the west side of Chicago Composed only of charity patients, this material represents the lower classes of the population The patients come from all parts of the world, but most of them have spent the greater part of their lives in Chicago or its vicinity With certain reservations, the results obtained in this study can be considered as typical of the largest city of the region of the great lakes, which is one of the districts of the United States in which the incidence of goiter is large

In some of the age groups, especially those below the age of 22, my material is small, but it is surprising that among 103 children of both sexes and races there were only 17 with goiters Of these children, 13 3 per cent showed a diffuse enlargement of the thyroid gland and 2 9 per cent a nodose goiter These figures are much lower than those

12 Hellwig, A Arch f klin Chir **154** 1, 1929

given by Olesen[13] in his statistics on the distribution of goiter in the United States, namely, from 6 7 to 25 8 per cent for Chicago boys and from 17 8 to 43 3 per cent for Chicago girls

Comparing my results with a large body of anatomic statistics on a highly goitrous population of central Europe (Bern, Switzerland, according to Wegelin), I find that the figures for Chicago are much the lower Wegelin observed nodose goiters in 73 3 per cent of the men above 20 years of age and in 88 4 per cent of the women above this age, as compared with 30 and 44 7 per cent in my statistics Among 800 people submitting themselves to a medical examination for a position in the civil service in Chicago, Olesen[14] found goiters in from 15 36 to 20 38 per cent of the women and in 6 72 per cent of the men

In Bern, in practically every person above the age of 50 the thyroid gland contains nodes (Clerc) In Freiburg in Breisgau (southern Germany), Kloeppels[2] found the incidence of nodose goiter in persons past the age of 50 to be 81 per cent In other regions of Germany in which goiter is endemic, Heilmann[15] saw nodose goiters in 40 per cent of the population Nodose goiter also occurs in regions free from endemic goiter The formation of the nodes, however, seems to start much later in life than it does in the regions in which goiter is endemic

All investigators agree that goiter is more common in the female sex than in the male sex Biedl[3] gave the ratio as 4 1, Hertzler[16] as from 6 1 to 10 1, Youmans[17] as 4 1 McCarrison[18] said, "Where the endemicity is slight, cases may be met with only among women, but in regions of high endemicity the proportion of women to men affected may approximate as closely as one to one" The difference in frequency of nodose goiter between the female and the male sex is most marked between the ages of 51 and 60 Between these ages, nodose goiter is more than twice as common in women as in men For all age groups together, the relation is 1 4 1, for the white race, and 1 8 1 for the colored race

While the frequency of nodose goiter increases with advancing age, that of diffuse goiter decreases Diffuse goiter is more common in males and nodose goiter in females

In regions of endemic goiter, the nodose outnumbers by far the diffuse enlargement In Bern, 93 per cent of the goiters are nodose, in Freiburg in Breisgau, 77 per cent In regions without endemicity,

13 Olesen, R Pub Health Rep **44** 1463, 1929

14 Olesen, R Illinois M J **27** 16, 1915

15 Heilmann, P Virchows Arch f path Anat **251** 361, 1924

16 Hertzler, A E Diseases of the Thyroid Gland, St Louis, C V Mosby Company, 1922

17 Youmans, J B South M J **22** 966, 1929

18 McCarrison, R The Thyroid Gland, London, 1917

the diffuse goiters prevail Thus in Frankfurt-on-Main, the percentage of diffuse goiters is 56 and in Goettingen 65 Among the goiters of the Heitzler clinic at Halstead, Hellwig found 53 per cent diffuse and 47 per cent nodose Of the goiters in my series, 69 3 per cent are of the nodose type

An interesting observation is the distinctly greater disposition to nodose goiter of the white race as compared with the colored race In white males, this form of goiter is twice as common as in colored males, and in females the difference is but slightly less It is only in the age groups above 50 that the percentage of the colored women approached that of the white women

Youmans, who examined 500 patients of the outpatient department of the University Hospital at Nashville, Tenn , found the incidence of goiter to be less in the colored than in the white subjects, except for certain age periods Olesen,[19] however, saw less goiter among the white than among the colored children in Tennessee In New York, Cohen [20] and Goldberger and Aldinger [21] reported less goiter among the colored children According to Jones,[22] goiter is less common among the Negroes of Atlanta than among the whites

Among Indians, the incidence of goiter parallels that among the white population (Rush and Jones [23]) My material is too small to allow any statement about the frequency of goiter among Indians None of the Mexicans whom I examined showed a goiter, but most of these Mexicans had been in Chicago less than ten years

Among the 1,000 persons on whom autopsies were performed 3 died from hyperthyroidism and 2 from carcinoma of the thyroid

SUMMARY

The average weight of the thyroid gland in the region of Chicago is, for white men, 27 4 Gm , for white women, 28 1 Gm , for colored men, 27 4 Gm , for colored women, 24 6 Gm , for Mexican men, 23 Gm , and for Mexican women, 26 Gm

The greatest weight of the thyroid gland is found in white men between the ages of 20 and 30, in colored men between the ages of 50 and 60, in white women between the ages of 30 and 50 and in colored women between the ages of 30 and 40

---

19 Olesen, R Pub Health Rep **44** 865, 1929

20 Cohen F Goiter in Children in New York City Thyroid Survey of 11,084 School Girls and 783 School Boys, Am J Dis Child **31** 676, 1926

21 Goldberger, I H, and Aldinger, A K Goiter Incidence in School Girls of New York City, Am J Dis Child **29** 780, 1925

22 Jones, E G Goiter, J A M A **71** 712, 1918

23 Rush, H P, and Jones, L F Endocrinology **9** 372 1925

Diffuse enlargement of the thyroid gland is more common in persons below the age of 50 than in those above this age It is more frequent in the male than in the female sex There are no differences in its incidence as between the two races

The frequency of nodose goiter increases with advancing age It reaches its maximum in white men in the sixth, in white women in the seventh, in colored men in the sixth and in colored women in the sixth decade of life Nodose goiter is more common in females than in males, and there is a greater disposition to it in the white race than in the colored race The percentages for nodose goiter are white males, 30, white females, 44 7, colored males, 14 5, and colored females, 25 6

Sixty-nine and three-tenths per cent of goiters are nodose

The majority of nodose goiters are of moderate size, weights above 100 Gm are rare The nodes are usually small, seldom reaching a diameter above 4 cm

General Review

ADDISON'S DISEASE

A STATISTICAL ANALYSIS OF FIVE HUNDRED AND SIXTY SIX CASES AND A STUDY OF THE PATHOLOGY

PAUL H GUTTMAN, M D

MINNEAPOLIS

(Concluded from p 785)

CORRELATION BETWEEN SYMPTOMS AND ANATOMIC CHANGES

A description of the various symptoms of the disease will not be covered in this paper, as little can be added to the excellent works of Addison, Greenhow, Wilks, Lewin, Bramwell, Neusser, Bittorf, Rolleston, Rowntree, Snell and Rowntree and others However, an attempt will be made to correlate the various symptoms with the pathologic changes in the suprarenal gland, and also to discuss the relative importance of the medulla and of the cortex in the production of the syndrome

BILATERAL TUBERCULOSIS OF THE SUPRARENAL GLANDS WITHOUT SYMPTOMS OF ADDISON'S DISEASE

Bilateral tuberculosis of the suprarenal glands without symptoms of Addison's disease is reported from time to time in the literature Laignel-Levastine and Halbron reported three cases Alezias and Arnard, in a study of case reports of Addison's disease, found a number of instances in which bilateral disease of the suprarenal glands existed without clinical manifestations Other cases were reported as follows Von Kahlden, six cases, Goldschmidt, two cases, Cabot, Boyd, Stursberg, Crowell and Karpeles, each one case Keros and Rolleston reported forty-four cases, and Lewin cited sixty-four cases, the extent of involvement in these, however, was not given Of thirty-four cases of bilateral tuberculosis that came to autopsy at the University of Minnesota, six cases showed absence of symptoms of Addison's disease The case described in the following section is given because of its unusual clinical course

CASE A-27-1179—*History*—A colored woman, aged 51, was admitted to the Minneapolis General Hospital on Sept 8, 1927, complaining of shortness of breath, swelling of the legs and tumor of the abdomen Swelling of the feet had been present for five months Nocturia two or three times was present for one month, the bowels were regular, the appetite was good The father died of tuberculosis three years previously, otherwise, the family history was irrelevant

Examination—Physical examination showed coated tongue, cervical adenopathy, hyperresonance in the lower portion of both lungs, increased breath sounds, diffuse apex beat of the heart, maximum impulse in the sixth interspace in the anterior axillary line, a pulse rate of 142, blood pressure 192 systolic and 128 diastolic, and a large tumor filling the greater part of the abdomen

Laboratory report gave specific gravity of the urine, 1 034, albumin, one plus, sugar, absent, hyaline and granular casts, many, red blood cells and white blood cells, few, red blood cells, 3,500,000, leukocytes, 3,950, lymphocytes, 44 per cent, neutrophils, 52 per cent, eosinophils, 2 per cent, monocytes, 3 2 per cent, urea nitrogen of the blood, 9 3 mg

Course—Compensation of the heart returned in from two to three weeks The patient was able to get up and around On November 11, operation for removal of the fibroid tumor was advised to relieve the cardiac strain The blood pressure before operation was 208 systolic and 134 diastolic The patient died suddenly on the operating table during the administration of caudal anesthesia via the sacral hiatus

Necropsy—The body was that of a well developed, obese colored woman Slight edema was shown about the ankles A large, pedunculated fibroid tumor, weighing 3,400 Gm, was attached to the uterus There was 400 cc of fluid in the abdomen The heart weighed 600 Gm, there was marked hypertrophy of the left ventricle, the valves were normal, the myocardium was normal, there was slight thickening of the coronary arteries The root of the aorta showed moderate atheromatous degeneration of the intima The right lung presented marked edema, it weighed 950 Gm The left lung appeared normal There was moderate enlargement of lymph nodes at the hilus of the lungs, no calcification or caseous degeneration was shown Large calcified lymph nodes were seen in the mesentery

The right suprarenal gland weighed 32 Gm, it was firm and nodular, and cut with increased resistance The substance was entirely replaced by irregular caseous areas, which were separated by grayish connective tissue and areas of dark red, less firm tissue The left suprarenal gland weighed 24 Gm and showed similar changes The kidneys showed a finely granular surface and moderate atrophy of the cortex

Microscopic Examination—The suprarenal glands showed the parenchyma largely replaced by irregular conglomerate caseous areas, about which there was a fairly marked reaction of epithelioid cells, an extensive infiltration of lymphocytes and a diffuse fibroblastic proliferation There was a marked diffuse lymphocytic infiltration in wide zones about the caseous areas Small areas of fairly well preserved cortical cells consisting of the zona glomerulosa and peripheral portions of the zona fasciculata were present here and there The capsule showed an extension of the tuberculous process at many points with the involvement of the pericapsular tissue Ziehl-Nielsen stain showed many scattered groups of tubercle bacilli near the periphery of the caseous areas

In this case there was no evidence of Addison's disease during life, but the symptoms were mainly those of cardiac failure secondary to hypertension The blood pressure on the day of death was 210 systolic and 110 diastolic Death occurred suddenly during caudal anesthesia

In many of the cases reported in the literature, death occurred suddenly and without apparent cause It is not uncommon for the patient to complain of severe abdominal pain, and often the abdominal pain is so severe that it is mistaken for acute appendicitis Operative inter-

vention in these cases is usually fatal In another group of cases, the symptoms of suprarenal involvement are masked by widespread tuberculosis of the lung or some other debilitating disease

The extent of involvement of the suprarenal gland cannot be determined from the cases in the literature A comparison was made of those cases showing bilateral tuberculosis of the suprarenal glands without symptoms of Addison's disease and those in which symptoms are clearly manifested These are given in the first instalment of the article which appeared in the November issue p 753 Although accurate estimate of the surviving tissue cannot be made because of the widely and irregularly scattered fragments of cortical tissue, it is probable from the evidence at hand that sufficient cortical tissue remains to offset symptoms of the disease

It is apparent that while a large percentage of patients with bilateral tuberculosis of the suprarenal glands have symptoms of Addison's disease, there are many in whom the symptoms are lacking Many observers are inclined to regard the pathologic changes as synonymous with Addison's disease This is erroneous as Addison did not describe a pathologic condition but a clinical syndrome associated with destructive lesions of the suprarenal glands The term latent tuberculosis of the suprarenal glands was introduced by Oppenheim and Loeper,[487] and Laignel-Lavastine and Halbron This term is satisfactory, but should be used in a clinical sense only, as the lesions in the suprarenal glands in most cases are active and progressive

DURATION OF THE DISEASE AND AGE OF THE PATIENT

It is frequently stated that Addison's disease tends to run a more rapid course in the young than in older persons An analysis of the cases collected from the literature does not support this idea A correlation chart (fig 12) was made in which only those cases are included in which the duration of the disease and the age of the patient are definitely stated There are 178 cases available for this analysis

The correlation coefficient is 0 060 with a probable error of 0 050 The average of the duration is plotted and represented by the coarse continuous line It is irregular and roughly parallels the mean represented by the horizontal line It is therefore evident that there is no correlation between the duration of the disease and the age of the patient

DURATION OF THE SYMPTOMS AND THE TYPE OF LESIONS IN THE SUPRARENAL GLAND

In 194 cases in which autopsy records are given, the duration of the disease is definitely stated in years or months These are divided into three groups (table 13) Group 1 consists of acute cases that are

of two months' or less duration, group 2, of subacute cases that are of less than six months' but more than two months' duration, and group 3, of chronic cases of more than six months' duration The frequencies of suprarenal tuberculosis, primary contracted suprarenal gland, amyloid disease and other lesions are given

There are fifteen cases, or 12 10 per cent of all cases of tuberculosis of the suprarenal glands, in which the duration of the disease is given as of less than two months' duration This is much greater than the number of acute cases of primary contracted suprarenal gland, of which only two cases, or 3 92 per cent, are reported The percentage of subacute cases is also higher in the tuberculosis group than in the primary

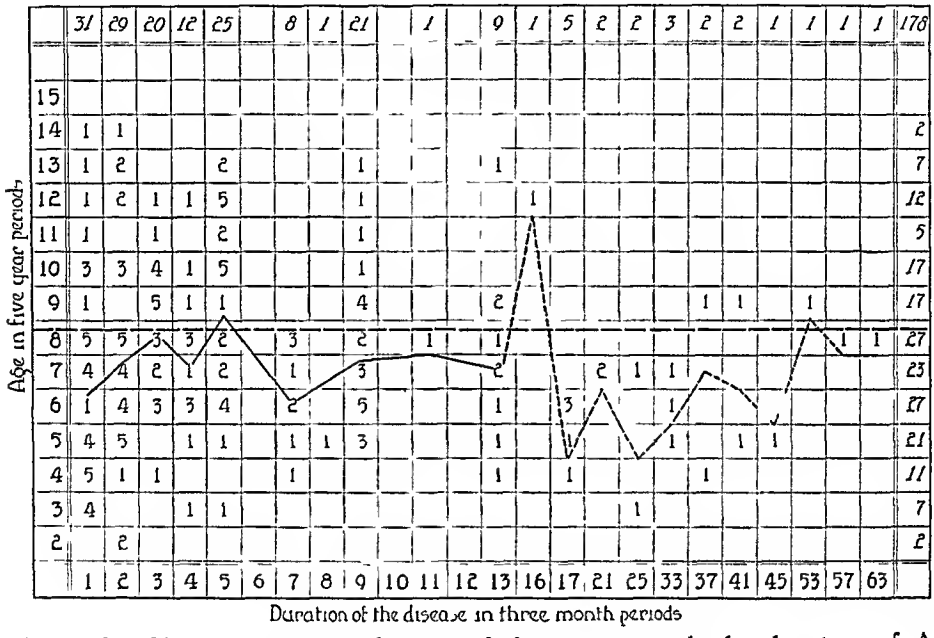

Fig 12—Chart correlating the age of the patient with the duration of Addison's disease The average of the duration is represented by the solid line The mean is represented by the horizontal line

contracted suprarenal group There are forty-two cases, or 33 87 per cent, in the former, and fifteen, or 39 41 per cent, in the latter The percentage of chronic cases of primary contracted suprarenal gland is much higher than the percentage of chronic cases of tuberculosis of the suprarenal glands Cases with amyloid disease tend to run a more chronic course than cases with vascular lesions There are two cases in the subacute group and two in the chronic group in the former, and two in the acute group and two in the subacute group in the latter

In order to determine whether the difference of duration in the cases of suprarenal tuberculosis and cases of primary contracted suprarenal glands is significant, the mean of each group and the probable error of their difference are determined The mean duration of the

cases of tuberculosis of the suprarenal glands is 13 31 ± 2 54 months, and that of primary contracted suprarenal gland is 34 02 ± 4 40 months The probable error of the difference of the means is 5 10 The difference between the means is more than four times its own probable error and, therefore, can be considered significant

TABLE 13—*Duration of Addison's Disease in Relation to Type of Lesion*

Type of Cases	Tuberculosis		Primary Contracted Suprarenal Gland		Amyloid Disease		Vascular Disease		Other Lesions		Total
	No	%	No	%	No	%	No	%	No	%	
Acute*	15	12 1	2	3 9	0	0	2	50	1	9 1	20
Subacute†	42	33 9	15	39 4	2	50	2	50	3	27 3	64
Chronic‡	67	54 0	34	66 7	2	50	0	0	7	63 6	110
Total	124	100 0	51	100 0	4	100	4	100	11	100 0	194

* Of two months' or less duration
† Of less than six months' but more than two months' duration
‡ Of more than six months' duration

TABLE 14—*Duration of Addison's Disease in Relation to Tuberculosis and Suprarenal Contracted Suprarenal Gland*

	Duration
Cases of tuberculosis of the suprarenals	
Cases in which the exact duration is given	
Ferrando and Salo7	8 years
Crowell	11 years
Cases of long duration in which exact duration is not given	
Scheult	Many years
Sakaguchi and associates	Several years
Schur (case 2)	Always dark
Withington (case 1)	Always dark
Loffler	Several years
Kahn	Pigmentation since childhood
Germain	Pigmentation always present
Cases of primary contracted suprarenal gland in which the duration is longer than five years	
Cases in which the exact duration is given	
Phillips	14 years
Munzer	9 years
Fahr and Reiche	8 years
Kiefer	15 years (?)
Held	10 years
Lucksch	9 years
Karakascheff	8 years
University of Minnesota (case 2)	15 years
Conybeare and Millis	10 years
Other cases of which duration is questionable or not stated	
Wakefield and Smith	Pigmentation since birth
Scott	Pigmentation since birth
Medlar	19 years (?)
Green	Always pigmented

There are nine cases of primary contracted suprarenal gland, or 17 65 per cent, having a duration greater than sixty months, and only two cases of tuberculosis of the suprarenal glands, in which the duration is greater than sixty months These are listed in table 14, with the names of the recorders

DURATION OF SYMPTOMS OF ADDISON'S DISEASE IN CASES OF ACTIVE AND MARKED TUBERCULOSIS IN THE BODY OTHER THAN IN THE SUPRARENAL GLANDS, AND IN CASES IN WHICH THE LESIONS ARE HEALED OR MINIMAL

The effect of marked lesions in other parts of the body on the suprarenal glands cannot be determined in this study It is probable that marked lesions exert a toxic effect on the surviving cells in the suprarenal glands Oppenheim and Loeper [486] showed that by injecting dead tubercle bacilli into animals, marked necrosis of the suprarenal glands can be produced Omelskyj and Kovacs held that, in man, in addition to the lesions caused by the tubercle bacilli, hyalinization and even necrosis of the suprarenal glands may be produced by the toxic products of a tuberculous lesion elsewhere Bernard and Bigart, and Kioyokawa described a perivascular sclerosis, an increase in the amount of connective tissue and even replacement of the parenchyma by connective tissue in cases of marked tuberculous lesions in other parts of the body

TABLE 15—*Deviations in Duration of Addison's Disease with Relation to Extrasuprarenal Tuberculosis of Marked Activity (Group 1) and of Healed or Minimal Stages (Group 2)*

	Group 1	Group 2
Maximum	48 months	96 months
Minimum	1 month	0 5 month
Mean	12 04 ± 1 33 months	14 40 ± 1 60 months
Standard deviation	11 65 ± 0 94 months	16 82 ± 1 14 months

To determine whether these factors influence the course of the disease, all cases of Addison's disease with tuberculosis of the suprarenal glands were placed in two groups Group 1 contained thirty-five cases in which there was marked extrasuprarenal tuberculosis, group 2 contained fifty cases in which the lesions elsewhere were healed or minimal The maximum, minimum, mean and standard deviations are as given in table 15

The probable error of the difference of the two groups is 2 088 The difference between the means is 2 35, which is 1 3 times its probable error This cannot be considered significant

DURATION OF THE DISEASE AND NATURE OF THE ONSET OF SYMPTOMS

In many cases it has been observed that if pigmentation is present to a marked degree in the absence of other symptoms the duration of the disease is exceedingly long Also it has been noted that in cases in

which weakness is the dominant symptom and no pigmentation is present, the duration of the disease is exceedingly short This fact was first noted by Fenwick in 1898 He collected thirty-three cases from the literature and observed that the duration of the cases in which marked bronzing of the skin was shown averaged 23 5 months, and that the average duration of the cases in which bronzing was absent was from four to eight months

Marañon in a recent article, divided his cases into two forms, a primary and a secondary form In the primary form, pigmentation is slight as compared with the other symptoms and the course of the disease is rapid In the secondary form, the pigmentation is marked, and the course of the disease is markedly long

TABLE 16—*Duration of Addison's Disease and Nature of Onset of Symptoms*

Duration in Months	Group A*		Group B†		Group C‡	
	Number	Per Cent	Number	Per Cent	Number	Per Cent
0 to 3	1	1 64	10	22 22	21	46 66
4 to 7	8	13 11	13	28 89	9	20 00
8 to 11	2	3 28	4	8 89	4	8 89
12 to 15	12	19 67	7	15 56	3	6 67
16 to 19	4	6 56	2	4 44	0	0 0
20 to 23	3	4 91	0	0 0	0	0 0
24 to 27	5	8 20	5	11 11	4	8 89
28 to 31	0	0 0	0	0 0	0	0 0
32 to 35	0	0 0	0	0 0	0	0 0
36 to 39	5	8 20	1	2 2	4	8 89
40 to 43	1	1 64	0	0 0	0	0 0
48 to 51	4	6 56	3	6 67	0	0 0
60 months and over	16	26 23	0	0 0	0	0 0
Total	61	100 00	45	100 00	45	100 0

* First symptom of onset is pigmentation
† Pigmentation and weakness appear simultaneously
‡ Weakness is the predominant symptom at onset

In collecting the literature, the exact duration of the disease and the degree of pigmentation was carefully noted in all cases While it is true that the onset of the disease is insidious and in the majority of cases the exact duration cannot be determined, a sufficient number of cases is available in which the exact onset of the pigmentation and weakness is given Cases in which there was any doubt as to the exact duration of the various symptoms were rejected

These cases are classified as follows Group A consists of sixty-one cases in which the first symptom is pigmentation, weakness is absent at first, and of late occurrence, group B consists of forty-five cases in which pigmentation and weakness are of simultaneous onset and about equally marked In group C are forty-five cases in which weakness is the predominant symptom, pigmentation is absent or of subsequent onset The frequency of these cases and the duration of the disease in four month periods are given in table 16

The mean, the maximum, the minimum and the standard deviations are shown in table 17

In the cases in which pigmentation is the initial and predominant symptom, the average duration of symptoms is 43 19 ± 4 3 months, as compared with 12 11 ± 1 6 months in the cases in which pigmentation and weakness are of simultaneous onset and equally marked It is 7 71 ± 1 months in those cases in which weakness is the first symptom and in which pigmentation is lacking or of subsequent onset The difference between the means of group A and group B is 33 213 ± 4 417 This difference is 7 5 times its own probable error and, without doubt, significant The difference between the means of group A and group C is 31 085 ± 4 47 This is six times its own probable error and is also, without question, significant The disease is, therefore, much longer in duration in those cases in which the pigmentation is the initial and predominant symptom than in those cases in which pigmentation of the skin and weakness are of simultaneous onset and those in which weakness is the first symptom

TABLE 17—*Deviations in Duration of Addison's Disease of Groups A, B and C*

	Group A	Group B	Group C
Minimum	1 month	1 month	0 25 month
Maximum	180 months	48 months	46 0 months
Mean	43 19 ± 4 3 months	12 11 ± 1 3 months	7 71 ± 1 0 months
Standard deviation	49 83 ± 3 04 months	12 35 ± 0 88 months	9 98 ± 0 71 months

It was decided to determine whether or not the degree of pigmentation, irrespective of the time of onset, has any relation to the duration of the disease The cases are divided into four groups, according to the intensity of pigmentation of the skin In the first group are twenty-one cases, in which there was no abnormal pigmentation of the skin, in the second group are twenty cases with slight increase of pigmentation of skin, in the third group are ninety-five cases with moderate pigmentation of the skin and pigmentation of the mucous membranes of the mouth, in the fourth group are seventy-three cases with high grade diffuse pigmentation of the skin and of the mucous membrane of the mouth The cases are then divided into arbitrarily chosen groups, according to the duration of the disease These are as follows acute cases, which are of two months' or less duration, subacute cases, which are of a duration of between two and six months, and chronic cases, which are of six months' or more duration The frequency of each group is given in table 18

To determine whether the differences in the three groups are significant, the value of *chi* square is determined, and found to be 34 447 The value of *P*, Fischer's value for *n* being used, is 0 000022, when

Pearson's value for n is used, the value of P is 0 000688 In either case, the probability that these results could be obtained through random sampling is almost nil The contingency coefficient is 0 3781 ± 0 1330, which confirms the foregoing statement

To account for the prolonged duration of the disease in the cases in which pigmentation of the skin is the predominant symptom, two possibilities may be suggested (1) that the pigmentation is a manifestation of increased secretory activity on the part of the skin, which compensates in some way for the disturbance in the secretory activity of the suprarenal glands, and (2) that the skin acts as a detoxifying agent and in this way compensates for the loss of suprarenal tissue

Heudorfer offered some interesting suggestions in support of the first theory He brought forth evidence that extracts of the pigment of the skin have mydriatic and pressor effects, and that, in cases of Addison's disease without pigmentation, the blood pressure tends to be

TABLE 18—*Duration of Addison's Disease and Depth of Pigmentation of Skin*

Duration	Depth of Pigmentation of Skin				Total
	Group 0	Group 1	Group 2	Group 3	
Two months or less (acute cases)	13	5	5	0	23
Between 2 and 6 months (subacute cases)	5	9	17	9	40
Six months or more (chronic cases)	3	6	73	64	146
Total	21	20	95	73	209

very low Also he cited a case in which there resulted a marked improvement in the condition of the patient on exposure to sunlight with a deepening in the color of the skin However, there is still lack of evidence that the fall of blood pressure is due to lack of epinephrine secretion (Rogoff and Dominquez, Stewart) The marked drop of blood pressure is also frequently observed in marked pigmentation and appears to parallel the development of muscular weakness

If one accepts the theory that it is the function of the suprarenal glands to neutralize toxic products of metabolism, it may be reasonable to suppose that the skin in some way takes over this function in the process of pigmentation, and in this way prevents, for a time, the appearance of the toxemia that characterizes the later stages of Addison's disease Since it is highly questionable that epinephrine subserves any useful function in the body, it is within reason to look on this substance as a by-product in the detoxifying process of the suprarenal gland Stewart [504a] stated that the relative constancy of the epinephrine output and its strict regulation by the nervous system are as compatible with the view that epinephrine is a poison which must be gradually got rid of and the concentration of which in the blood must not rise above

a certain maximum, as with the view that it is a substance exercising a useful function that could not be adequately performed if the output were permitted to sink below a certain level The fate of this substance in the tissues is not known, but evidence has been brought forth to show that it disappears rapidly in the tissues, and that it is probably converted into some inert substance As a result of interference with the function of the gland, the precursors of epinephrine accumulate and may be transformed by the skin into less toxic substances or neutralized in the process of pigmentation

The final solution of this interesting relation rests on a deeper knowledge of the physiology of pigmentation and its relation to the function of the suprarenal glands

THE RELATIVE IMPORTANCE OF THE CORTEX AND OF THE MEDULLA IN THE PRODUCTION OF SYMPTOMS OF ADDISON'S DISEASE

That the symptoms of Addison's disease are due to a more or less complete destruction of the suprarenal gland is widely accepted However, the relative importance of the cortex and that of the medulla are widely disputed The symptoms of the disease are believed by some to be due entirely to the destruction of the cortex, by others, entirely to the destruction of the medulla, while some believe that the destruction of both cortex and medulla is responsible for the symptoms of the disease

From his early studies Wiesel[104] concluded that the symptoms of Addison's disease are due to loss of chromaffin tissue He based his conclusions on a study of five cases of Addison's disease in which the medulla was markedly diseased and the chromaffin tissue entirely lacking He considered of special significance another case in which destruction of the suprarenal gland occurred without symptoms of Addison's disease, but in which the extrasuprarenal chromaffin tissue was intact

Karakascheff[49] was directly opposed to this theory, believing that the cortex is solely responsible for all the symptoms He pointed out that in Wiesel's cases of extensive destruction of the gland without symptoms of the disease accessory cortical nodules were present, the significance of which Wiesel failed to emphasize Further, he stated that, since the chromaffin organs along the course of the sympathetic ganglions normally undergo retrogressive changes shortly after birth he failed to understand why their absence in cases of Addison's disease should be considered of significance Karakascheff based his conclusions that the cortex was mainly responsible for symptoms of Addison's disease on a study of two cases of atrophy in which the cortex was mainly involved and in which the medulla was normal Similar cases

led Scott and Oberndorfer to conclude that the cortex is mainly responsible for the symptoms of the disease Furuta also observed a marked destruction of the cortex without much involvement of the medulla following arterioiar emboli, and concluded that the symptoms were due to destruction of the former Veit observed a case of thrombosis of the suprarenal vein and believed that symptoms of Addison's disease occurred only when the cortical portion of the suprarenal gland was involved

Most writers are of the opinion that destruction or impairment of function of both portions is necessary before the complete syndrome is produced, but here again there is no unanimity of opinion as to the relative importance of the two portions In the production of the symptoms, Falta regarded the low blood pressure, low blood sugar adynamia and mononucleosis as the result of a lessening of the function of the medulla, the gastro-intestinal symptoms (vomiting, diarrhea), and coma as dependent on the destruction of the cortex More recently he concluded that the pigmentation is due to the insufficiency of the medulla Wiesel,[517] in 1913 altered his former view and stated that asthenia and low blood pressure are the result of an inadequacy of the chromaffin system, whereas the nervous symptoms, the cachexia and lethal end are due to failure of the cortex Neusser, Loffler and Zondek were in accord with Wiesel's views Fenwick stated that as the skin changes occur sometimes after, or sometimes before, the onset of the constitutional symptoms, and sometimes not at all, it follows that they cannot be of identical origin He therefore concluded that the constitutional symptoms are of medullary origin and that the pigmentary changes are of cortical origin Fahr and Reiche also believed that pigmentation is due to cortical insufficiency, but they did not state which part is responsible for the other symptoms They concluded from a study of five cases of primary contracted suprarenal gland in which anatomically the medulla showed little or no change, that functional impairment of the medulla cannot be ruled out Kovacs, from a study of a case similar to those described by Fahr and Reiche, stated that the symptoms of cortical insufficiency and medullary insufficiency are distinct He believed, with Omelskyj, that the low blood pressure and the adynamia are due to medullary insufficiency, and that the pigmentation and lethal end are due to cortical insufficiency Lange, on the other hand, after study of a case with similar pathologic observations concluded that the adynamia is due to cortical insufficiency

There are apparently two reasons for these conflicting opinions (1) too hasty conclusions are reached from the clinical and pathologic observations of a single case of Addison's disease, and (2) experimental evidence offers conflicting views as to the functions of the supra-

renal glands The extreme variability of symptoms, particularly those of blood pressure and pigmentation, could easily lead one to erroneous conclusions from a study of a single case or a small group of cases A correlation is made of the outstanding clinical symptoms and the changes in the suprarenal glands of all the available cases in an effort to determine whether or not any relationship exists between the symptoms and the relative degree of destruction of the cortex and the medulla

It was decided first to determine whether the blood pressure in the cases of primary contracted suprarenal gland differs from that in the cases of tuberculosis of the suprarenal gland, since in the former, the medulla is usually completely destroyed and only small remnants of cortical tissue survive, whereas in the latter, the cortex is the main seat of the involvement and the medulla is usually well preserved

Relation of Blood Pressure to the Relative Degrees of Destruction of Cortex and Medulla in Suprarenal Tuberculosis and Primary Contracted Suprarenal Gland—Kovacs, in 1928, and later Omelskyj, concluded from a study of a case of primary contracted suprarenal gland that this condition is to be distinguished from the true form of Addison's disease, as some of the clinical features, principally the fall in blood pressure and the adynamia, are lacking They decided that these cases should be regarded as representing cortical insufficiency, since the medulla and the extrasuprarenal chromaffin tissue continue to secrete epinephrine despite the structural changes in the cortex, hence, the absence of a drop in blood pressure and the asthenia

An analysis of the clinical observations in sixty-eight cases of primary contracted suprarenal gland invalidates this view In Kovacs' cases, on which his view was partly based, there was a systolic blood pressure of 80 mm of mercury He stated that the fall in pressure was terminal He then cited a few instances of Addison's disease in which the blood pressure was within normal limits, and in which the underlying pathologic anatomy was that of primary contracted suprarenal gland Lange presented a case of Addison's disease in which the pathologic changes were almost identical with those of Kovacs' case, and in which there was a low blood pressure (75 systolic and 45 diastolic) and a marked grade of adynamia He then concluded that the adynamia was dependent on the destruction of the suprarenal cortex, since the medulla was normal The evidence on which Lange based his conclusion is fully as justifiable as that on which Kovacs based his conclusions

An analysis of cases of primary contracted suprarenal gland shows that there are many cases not cited by Kovacs in which repeated examination of the blood pressure showed consistently low readings Kreibig

reported a systolic blood pressure of 55 mm of mercury (Riva-Rocci) occurring three months before death Wahl's patient showed a blood pressure reading of 60 systolic and 42 diastolic five weeks before death Steinbiss' patient showed a pressure of 70 systolic and 50 diastolic eleven days before death, on the day of death, the systolic pressure dropped to 30 A steady fall of blood pressure over many months was present in case 2, page 762 of the November issue Kraus reported a case in which the pressure was 70 systolic and 50 diastolic Certainly, the fall of blood pressure in these cases cannot be regarded as terminal

A comparison of the blood pressure in cases of suprarenal tuberculosis with that in primary contracted suprarenal gland is made, as in the former, the medulla is mainly involved, and in the latter, the cortex is the main seat of involvement Among the cases of tuberculosis of the suprarenal glands there are sixty-five in which blood pressure readings are given and among cases of primary contracted suprarenal gland

TABLE 19—*A Comparison of the Blood Pressure in Suprarenal Tuberculosis with That in Primary Contracted Suprarenal Gland*

Deviations	Systolic Pressure	
	Tuberculosis of the Suprarenal Glands	Primary Contracted Suprarenal Gland
Maximum	155 mm Hg	135 mm Hg
Mean	86 55 ± 2 23 mm Hg	84 08 ± 2 45 mm Hg
Minimum	30 mm Hg	55 mm Hg
Standard deviation	26 73 ± 1 58 mm Hg	17 47 ± 1 74 mm Hg

there are twenty-three The mean, maximum, minimum and standard deviations are as recorded in table 19

The difference between the means is 2 47, which is less than one time their probable error, so that this difference cannot be considered as significant Normal and even increased blood pressure is reported as frequently for tuberculosis of the suprarenal glands as for primary contracted suprarenal gland However, in both groups, the systolic pressure is below normal and about equally decreased

It is clearly evident, therefore, that the blood pressure is not dependent on the relative degree of destruction of one or the other of the two layers of the suprarenal glands Normal and even high pressures are observed in cases in which the medulla is totally destroyed, and markedly reduced pressures are seen in cases with normal medulla

Relation of Symptoms to the Relative Degrees of Destruction of Medulla and Cortex in Primary Contracted Suprarenal Glands—In an effort to determine further whether the extent of involvement of the medulla, on one hand, and of the cortex, on the other, influences in any way the nature of the symptoms, the cases of primary contracted supra-

renal gland are divided according to the degrees of destruction of the cortex and the medulla In group 1 are thirty cases in which the cortex is mainly involved and the medulla only slightly involved or normal In group 2 are nine cases in which both medulla and cortex are about equally involved In group 3 are four cases in which the medulla is more involved than the cortex The frequency of the major symptoms (pigmentation weakness, gastro-intestinal symptoms and changes in blood pressure) are recorded in table 20

In group 1 (cases in which the cortex is mainly involved, the medulla, slightly involved or normal) marked pigmentation is observed

TABLE 20—*Frequency of Symptoms with Various Degrees of Destruction of the Cortex and the Medulla*

	Primary Contracted Suprarenal Gland						Tuberculosis of the Suprarenal Glands	
	Group 1*		Group 2†		Group 3‡			
Symptoms	No	Per Cent	No	Per Cent	No	Per Cent	No	Per Cent
Pigmentation								
Moderate	12	40 0	5	5 6	2	5 0	17	56 7
Marked	11	26 7	2	2 2	2	5 0	7	23 3
Degree not stated	6	20 0	2	2 2	0	0 0	6	20 0
Absent	1	3 3	0	0 0	0	0 0	0	0 0
Weakness								
Moderate		10 0	1	11 1	0	0 0	0	0 0
Marked	15	50 0	5	55 6		75 0	16	53 3
Degree not stated	12	40 0	3	3	1	25 0	14	46 7
Absent	0	0 0	0	0 0	0	0 0	0	0 0
Blood pressure								
Normal or above	4	13 3	1	11 1	2	50 0	5	16 7
Low	11	36 7	0	0 0	1	25 0	12	40 0
Degree not stated	15	50 0	8	88 9	1	25 0	13	43 3
Gastro intestinal symptoms								
Present	25	83 3	7	77 8	3	75 0	27	90 0
Absent	0	0 0	0	0 0	0	0 0	0	0 0
Degree not stated	5	26 7	2	22 2	1	25 0	3	10 0

* Thirty cases in which the cortex is mainly involved and the medulla slightly involved or normal

† Nine cases in which the medulla and the cortex are about equally involved

‡ Four cases in which the medulla is more involved than the cortex

in eleven cases, moderate pigmentation, in twelve cases, and no pigmentation, in one case In group 2 (cases in which the medulla and the cortex are about equally involved), marked pigmentation is present in two cases and moderate pigmentation in five cases In group 3 (cases in which the medulla is more involved than the cortex) there are two cases of marked pigmentation and two cases of moderate pigmentation of the skin [1]

1 The reports on the cases in the various groups are referred to in the bibliography under the following numbers group 1—141, 140, 144 (four cases), 146 (five cases), 149 151, 152 153, 155 (cases 1 and 2), 154 (cases 3 and 4), 157 162, 163, 164 (cases 1 and 2), 167, 168, 171 and case 1 (on page 759 of the November issue) group 2—143 150 156 158, 160 (case 1), 172, 173 182 and case 2 (on page 762 of the November issue), group 3—142 (cases 1 and 2), 145 and 160

There is no discernible difference in degree of weakness and degree of digestive disturbance in the three groups Low blood pressure readings are observed in about equal frequency in the three groups

Because of the small number of cases in group 3, thirty cases of Addison's disease with tuberculosis of the suprarenal gland were picked at random from the cases collected from the literature and compared with the thirty cases of primary contracted suprarenal gland in group 1 [2] As stated, in the former the medulla, as a rule is completely destroyed and only small rests of cortical tissue remain, whereas in the latter the cortex is almost completely destroyed and the medulla is normal or only slightly involved The results are given in column 4 of table 20 Here again it is seen that the frequency of occurrence of the major symptoms differs but slightly and cannot be considered of any significance

These cases offer strong evidence to show that the major symptoms of Addison's disease are not dependent on the degree either of cortical or of medullary destruction All symptoms may be strongly manifested in cases in which the medulla is normal, and there is no apparent difference in the intensity of symptoms in cases in which the medulla is slightly involved or normal and cases in which the medulla is markedly involved

Experimental Evidence as to the Relative Importance of the Cortex and Medulla—The opinion that insufficiency of the suprarenal medulla is responsible for the fall of blood pressure is based on the tonus theory of Oliver and Schafer Experimental investigation has failed to support this theory

Biedl found that extraperitoneal removal of the suprarenal glands resulted in a fall in blood pressure that lasted only a few minutes, after which the blood pressure returned to normal and remained so for from two to three days Later Hoskin and McClure in ligation experiments on dogs, also failed to observe any significant fall in blood pressure The results obtained by Gley and Quinguaud in extirpation experiments agree with those of Biedl The more recent extirpation experiments of Wheeler and Vincent and of Rogoff and Dominquez and the denervation experiments of Stewart and Rogoff furnish strong evidence that the medullary secretion, epinephrine, has little or no effect in maintaining normal blood pressure In experimental adrenal insufficiency, the fall in pressure is observed only as a terminal symptom and coincides with the onset of marked prostration The objection is raised by Goldzieher and others that experimental workers have failed to asknowledge the importance of the extrasuprarenal chromaffin tissue, which may

2 Case reports of tuberculosis of the suprarenal glands are referred to in the bibliography under the following numbers 25, 41, 43, 49, 54, 60, 61, 65, 71, 75, 81, 82, 87, 92, 94, 97, 99, 100, 102, 105 and 127

act as a compensatory mechanism in the event of the destruction of the suprarenal glands Although it has been shown by Kohn, Biedl and others that the extrachromaffin tissue secretes epinephrine, it is highly improbable that the quantity secreted is sufficient to exert any influence on the arterial tension (Stewart)

There is little evidence also that reduction in the amount of epinephrine secretion has any effect on the level of the blood sugar Crowe and Wislocki found little or no change in the carbohydrate metabolism in animals with adrenal insufficiency In the well controlled experiments of Stewart and Rogoff,[503] experimental hyperglycemia could be obtained in the absence of epinephrine discharge from the adrenal glands, and in animals in which both adrenal glands were removed, a fall in sugar level was not observed until terminal symptoms developed This is well in accord with the carefully studied cases of Addison's disease of Gyotoku and Momose, Sakaguchi, Kayashi and Katayama, and Lawrence and Rowe Alimentary hyperglycemia was found to be the same as in normal persons Sakaguchi, Kayashi and Katayama found no significant lowering of the blood sugar in five cases of Addison's disease and their experimental results are in full accord with those of Stewart and Rogoff In the cases studied by Lawrence and Rowe, the blood sugar levels are within normal limits Snell and Rowntree found that hypoglycemia is present in a few cases and only as a terminal phenomenon

The cause of the gastro-intestinal disturbance is not definitely known The gastro-intestinal symptoms are often striking in animals suffering from adrenal insufficiency following removal of both adrenal glands Loss of appetite is one of the earliest signs which usher in the breakdown of the animal (Stewart) Diarrhea is noted only rarely in animals (Hartman) Stewart presented two hypotheses to explain the gastro-intestinal symptoms in animals (1) that the gastro-intestinal tract shares in the elimination of the poisons that accumulate in the course of adrenal insufficiency and may finally be injured by the poisons, and (2) that the adrenal glands produce a hormone necessary for the continued normal function of the intestinal mucosa There is little evidence that disturbance of sympathetic tonus is responsible for the gastro-intestinal disorders Snell and Rowntree stated, "Occasionally gastro-intestinal symptoms are greatly relieved by the administration of epinephrine, perhaps more often the symptoms are not affected or are made worse by its use"

The adynamia frequently seen in Addison's disease is not a prominent symptom in animals suffering from adrenal insufficiency In chronic adrenal insufficiency in cats, Hartman and Blatz and in adrenal insufficiency in dogs, Rogoff and Stewart,[493] noted muscular weakness only as

a terminal event The exact cause of the muscular weakness in man is not understood

It is agreed by most observers that the lethal end is due to the destruction of the cortex Biedl found that extirpation of the cortex in mammals is followed by death Wheeler and Vincent showed that by cauterizing the medulla without removal of the cortex, serious symptoms are not produced, they believed with Biedl that the cortex of the gland is important for life Biedl found that following complete removal of the interrenal bodies in fishes (*Scyllium* and *Elasmobranchii*) in which the interrenal bodies are separate from the chromaffin organ, death results within a few days Later Biedl claimed that he was able to remove the cortex in mammals, leaving the medulla intact, and that death followed The recent work on cortical extracts also supports the view that the cortex is essential for life Rogoff and Stewart [491] found that cortical extracts prolong the life of adrenalectomized animals and they also observed beneficial effects when these extracts were administered to patients with Addison s disease Hartman also claimed to have isolated a substance that prolongs the life of adrenalectomized cats Koehler claimed to have an extract which had a marked beneficial effect in cases of asthenia, which he attributed to suprarenal insufficiency It is highly questionable, however that Koehler was dealing with true cases of suprarenal insufficiency

In cases of Addison's disease due to tuberculosis, the medulla is early destroyed and in most cases only a small amount of cortical substance remains, which can be detected only microscopically in the later stages of the disease (see page 753 of the November issue) In cases of primary contracted suprarenal gland large amounts of medullary tissue may remain and yet not prevent a fatal termination

The disturbance causing the lethal end is not clear The evidence at hand strongly suggests that death is due to an accumulation of toxic substances It has been shown by Abelous and Langlois Biedl and others that the blood of adrenalectomized animals is toxic for other animals Levin, also, working with decapsulated cats and dogs, obtained a rise of blood pressure in normal animals into which blood from the decapsulated animals had been injected He suggested that this action is due to the accumulation of harmful substances in the blood stream of the adrenalectomized animals The nature of this substance is unknown A relation to the byproducts of muscle metabolism is suggested, as animals that are forced to use muscular exercise following adrenalectomy, succumb more rapidly than adrenalectomized animals that are allowed to rest It has also been suggested repeatedly that the cortex is capable of neutralizing toxic substances but proof of the exact nature of this mechanism is still lacking

It is therefore evident that, following the destruction of the medulla alone, the cortex may function and prevent symptoms of the disease It is also clear that all symptoms of the disease may be clearly manifest in cases in which the cortex is destroyed and the medulla is intact However, one cannot assume that an anatomically incomplete medulla functions normally It has been shown by Stewart that even slight edema of the gland results in a complete inhibition of the secretion of epinephrine Moreover, there is evidence that for the normal function of the gland, the two parts are essential and act synergistically Biedl stated that the peculiarity of the vascular supply and the ontogenic and phylogenic development of the suprarenal gland strongly suggest a functional relationship between the two portions Landau stated that in the development of the gland, the infolding of the cortex suggests a functional relationship between cortex and medulla, as in this way a larger area of the cortex is brought into contact with the medulla Cramer claimed to have traced a functional relationship between the cortex and the medulla by using stains by which he was able to trace the functional activity of the gland Hartman and Hartman, using the Folin, Cannon and Denis calorimetric test the inhibition of intestinal contraction and the denervated iris tests, found that epinephrine is present in the cortex

It is probable, therefore, that an anatomically intact medulla may not function normally when the cortex is the seat of marked destruction It is also likely that the extreme variability of symptoms observed in cases of primary contracted suprarenal gland may be due to the varying degree of disturbance in the synergism of the cortex and medulla However, if this relation is shown not to exist one must fall back to the theory that the destruction of the cortex alone is responsible for all the symptoms of Addison's disease

SUMMARY AND CONCLUSIONS

A statistical analysis is made of 566 cases of Addison's disease collected from the literature of the years from 1900 to 1929, inclusive, and from the department of pathology of the University of Minnesota The following points are emphasized (1) the etiology and the classification of lesions in the suprarenal glands, (2) the pathologic anatomy of the lesions in the suprarenal glands, (3) the nature and significance of lesions elsewhere in the body, and (4) a correlation between the clinical manifestations of the disease and the changes in the suprarenal glands

Contrary to the older views Addison's disease does not occur without lesions in the suprarenal glands In most cases both suprarenal glands are destroyed A few cases of unilateral lesions are recorded The pathologic changes, in the order of their frequency are bilateral

tuberculosis, primary contracted suprarenal gland (atrophy), amyloid disease, neoplasms, vascular lesions, fatty degeneration and pyogenic infections Syphilis and metastatic tumors of the suprarenal glands are rarely seen in association with Addison's disease Many other lesions are described, such as pressure atrophy, hypoplasia, trauma, bone marrow metaplasia, etc

The disease is relatively rare Both sexes are affected In the entire series, males are more frequently affected than females In the cases of primary contracted suprarenal gland, females predominate in the ratio of 1 6 to 1 Heredity can be considered a factor only in rare instances The age incidence of primary contracted suprarenal gland and that of suprarenal tuberculosis are approximately the same In the case of tuberculosis of the suprarenal glands, the age incidence follows closely that of deaths from tuberculosis in general

Tuberculosis of the suprarenal gland is seldom seen in the absence of tuberculous lesions elsewhere in the body The primary focus is usually in the lung, and ordinarily it is not recognizable clinically Infection takes place through the blood stream The medulla appears more susceptible than the cortex to the infection, and it is usually completely destroyed Remains of the cortex can be made out microscopically in most cases The disease is progressive and characterized by periods of healing and periods of exacerbation Healing is rarely observed

Primary contracted suprarenal gland is a disease of unknown etiology Two cases are presented which show an early and a late stage of the disease The pathologic changes indicate that the condition is primarily a slow necrosis involving the cortical cells and leading finally to their disappearance The inflammatory reaction is secondary to the degenerative changes The degree of the inflammatory reaction depends on the severity and tempo of the degenerative changes Partial function is maintained by regeneration in the form of small adenoma-like nodules of cortical cells There is no evidence that the lesion is due to infection or to the toxic products of lesions elsewhere in the body

The occurrence of thymic hyperplasia in association with Addison's disease is questionable As far as could be determined, the weight of the thymus in cases of Addison's disease falls within normal limits

Changes in other glands of internal secretion are relatively rare They cannot be considered of importance in the production of the symptoms of Addison's disease

Anatomic changes in the sympathetic ganglions of the celiac plexus are extremely few and variable in nature They are not considered of significance in the genesis of the symptoms of Addison s disease

Gastro-intestinal lesions in Addison's disease are infrequently observed Peptic ulcers occur in only a few cases They do not correspond in frequency with those that occur in adrenalectomized animals

Bilateral tuberculosis of the suprarenal glands without symptoms of Addison's disease is not infrequently seen These cases have been termed "latent tuberculosis of the suprarenal glands"

Accessory cortical tissue and hyperplasia of the cortex of the suprarenal glands may prevent symptoms of Addison's disease in cases of destructive lesions in the suprarenal glands

The duration of the disease is not affected by the presence of tuberculosis elsewhere in the body The duration of the disease in primary contracted suprarenal gland is longer than that in tuberculosis of the suprarenal glands, the mean for the former is 34 02± 4 40, for the latter, it is 13 15± 2 54 months

The duration of the disease is significantly longer in cases in which pigmentation is the first and predominant symptom than in those in which pigmentation and weakness occur simultaneously and in those in which the weakness is the initial and prodominant symptom It is suggested that pigmentation is a mechanism which is compensatory for the destruction of the suprarenal glands

Conclusions as to the relative importance of the cortex and medulla cannot be drawn from a study of a single case or a small group of cases, as the symptoms of the disease are extremely variable Evidence is lacking that the symptoms occurring in primary contracted suprarenal glands differ from those occurring in tuberculosis of the suprarenal glands No appreciable difference in the symptomatology can be noted with varying degrees of destruction of the cortex and medulla Available experimental and clinical evidence points to the fact that the adynamia, gastro-intestinal symptoms and low blood pressure are due to an accumulation of toxic substances subsequent to suprarenal destruction The lethal end is due to cortical failure All symptoms may be present in cases with anatomically normal medulla, however, a functional disturbance of the medulla as the result of disturbance in synergism of the cortex and medulla cannot be denied

BIBLIOGRAPHY

The following references on cases of Addison's disease are arranged according to the pathologic changes in the suprarenal glands The classification given in table 2 is followed

BILATERAL TUBERCULOSIS

1 Acevedo, M Algunas consideraciones sobre dos cases de enfermedad de Addison, Semana med 9 299, 1902

2 Achard, C, and Foix, C Insuffisance surrénale par tuberculose primitive sans melanodermie, Bull et mem Soc med d hôp de Paris 26 1043, 1909

3 Andersen, K Et tilfaelde av Morbus addisonii sine pigmentatione, Norsk mag f laegevidensk **10** 1039, 1912

4 Aslan, A , Nicolan, C , and Petresco, M Acute Case with Secondary Tuberculosis of Suprarenals, Bull et mem Soc med d hôp de Bucarest **10** 182, 1928

5 Balen, M J Addison's Disease, J A M A **74** 82, 1920

6 Barker, N W The Pathologic Anatomy in Twenty-Eight Cases of Addison's Disease, Arch Path **8** 432, 1929

7 Bendix, E Intermittent Polyurie bei Addison'sche Krankheit, Deutsches Arch f klin Med **82** 198, 1904-1905

8 Bietzow, A M Case of Addison's Disease, Illinois M J **51** 471, 1927

9 Bittorf, A Die Pathologie der Nebennieren und der Morbus addisonii, Jena, Gustav Fischer, 1908

10 Black, D R Addison's Disease, J Kansas M Soc **26** 190, 1926

11 Boinet Dangers de l'adrenaline dans certains cas de maladie bronzée d'Addison, Compt rend Soc de biol **55** 1471, 1903

12 Bouchut, Morenas, and Gensollen Tuberculose caseuse totale des surrenales avec syndrome rapid d'insuffisance surrénale à marche rapide sans pigmentation, Lyon méd **132** 162, 1923

13 Bruno, J Ueber Morbus addisonii, Munchen med Wchnschr **49** 36, 1902

14 Burgeas, J C À propos d'un cas de tuberculose des capsules surrenales, J de med et chir prat **94** 887, 1923

15 Busch, F C, and Wright, T Three Cases of Addison's Disease, One with Suprarenal Transplantation, Arch Int Med **5** 30, 1910

16 Buszard, F A Case of Addison's Disease with Associated Leucoderma and Tuberculous Peritonitis, Lancet **1** 453, 1900

17 Cabot, R Tuberculosis of the Adrenals Addison's Disease (Case 12101), Boston M & S J **194** 444, 1926

18 Cabot, R Deep Pigmentation of the Skin Cause? (Case 12231), Boston M & S J **194** 1088, 1926

19 Cabot, R, and Cabot, H Tuberculosis of the Adrenals (Case 12331), Boston M & S J **195** 376, 1926

20 Cade and Barbier, J Insuffisance surrenale a terminasion rapide absence de mélanodermie double abcès froid surrénale, Lyon méd **132** 166, 1923

21 Cheney, W F A Case of Addison's Disease with Autopsy, Philadelphia M J **5** 689, 1900

22 Coleman, J B Diseases of the Suprarenal Capsules, Tr Roy Acad Med **17** 87, 1900

23 Comby, J Maladie d'Addison chez une fille de trieze ans, mort, autopsy, Arch de med d enf **20** 28, 1917

24 Conder, A F R On Addison's Disease, Edinburgh M J **17** 275, 1905

25 Conybeare, J J, and Millis, G C Observations on Twenty-Nine Cases of Addison's Disease Treated in Guy's Hospital Between 1904 and 1923, Guy's Hosp Rep **74** 369, 1924

26 Costa, S La forme pure de l'insuffisance surrénale, etude clinique et critique, Arch de med et pharm mil **47** 89, 1906

27 Crowell, B C Report of Two Cases of Addison's Disease, Proc New York Path Soc **9** 75, 1909-1910

28 Crowell, B C Addison's Disease and Adrenal Tuberculosis, Philippine J Sc **6** 345, 1911

29 Debove Maladie d Addison Tribune med **37** 69, 1905

30 Dempsy M J A Case of Addison's Disease with Rapidly Fatal Termination Tr Roy Acad Med **25** 123 1907

31 Dubois M Ueber das Vorkommen lymphatischer Herde in der Schilddruse bei Morbus addisonii Berl klin Wchnschr **56** 1178 1919

32 Evans L S Addison s Disease in the Negro Am J M Sc **176** 499, 1928

33 Fenwick B On Addison's Disease Indian M Rec **22** 489, 1902

34 Finlayson J, and Muir, R Case of Addison s Disease, Glasgow M J **66** 459, 1906

35 Finley, F G A Case of Addison's Death Followed by Death Montreal M J **31** 972 1902

36 Flasch Ein Fall von Morbus addisonii, Deutsche mil-arztl Ztschr **31** 643, 1902

37 Flemming, C E S Notes on Three Pathological Specimens, Bristol Med-Chir J **20** 222, 1902

38 Ghirst, D G and Rowntree L G Case of Addison's Disease Without Pigmentation, Endocrinology **11** 589, 1927

39 Goldzieher M Die Nebennieren Munich J F Bergmann, 1911

40 Goodwin, R A Addison s Disease A Report of Two Cases, Providence M J **17** 33 1916

41 Gordon A Addison's Disease in a Negro with Involvement of Central Nervous System, Interstate M J **22** 550, 1915

42 Guichard A Un cas de maladie d Addison sans melanodermie, mort tres rapid en hypothermie, Arch de med et pharm mil **48** 271, 1906

43 Gullan A G Two Cases of Addison's Disease and the Effect of the Administration of Suprarenal Extract, Lancet **2** 523 1905

44 Hedinger, E Ueber die Kombination von Morbus addisonii mit Status lymphaticus Frankfurt Ztschr f Path **1** 527, 1907

45 Hewer, E E Histological Conditions in a Case of Addison s Disease Brit M J **1** 235, 1923

46 Higgins, W H Case of Addison s Disease with Unusual Autopsy Observations, J A M A **91** 86 1928

47 Huismans L Ueber Morbus addisonii Munchen med Wchnschr **48** 630, 1901

48 Kahn Ueber der Morbus addisonii und seine Beziehungen zur Hyperplasie der lymphatischen Apparate und der Thymusdruse, Virchows Arch f path Anat **200** 399, 1910

49 Karakascheff K I Weitere Beitrage zur pathologischen Anatomie der Nebennieren, Beitr z path Anat u z allg Path **39** 372 1906

50 Keilty R A A Case of Tuberculosis of the Adrenals, Am J M Sc **163** 282 1922

51 Kovacs Walther Zur Nebennierenpathologie, Beitr z path Anat u z allg Path **79** 213, 1927-1928

52 Kraus J Zur Pathologie der Morbus addisonii Beitr z path Anat u z allg Path **78** 283, 1927

53 Landow M Pseudoperitonitis bedingt durch Morbus addisonii Deutsche Ztschr f Chir **101** 67 1909

54 Lawrence C H, and Rowe A W Studies of Endocrine Glands-Adrenals, Endocrinology **13** 1, 1929

55 Lecky H C Notes on a Case of Addison's Disease Rapidly Fatal with Symptoms of Acute Toxaemia Lancet **1** 439 1906

56 Lemann I I Addison's Disease Report of Three Cases Including One in a Negro New Orleans M & S J **78**·814 1926

57 LePlay Tuberculose caseeuse primitive des capsules surrenales syndrome truste d insuffisance surrenale avec mort rapide Bull et mem Soc anat de Paris **84** 556 1909

58 Lewis C H A Case of Addison's Disease with Autopsy M Rec **75** 47 1909

59 Loeper M and Crouzon O Autopsie d un cas de maladie d'Addison traite par l adrenaline Bull et mem Soc anat de Paris **78** 918 1903

60 Loffler W Beitrag zur Kenntnis der Addison schen Krankheit Ztschr f klin Med **90**·265 1920

61 Mahomed G Sarcomatous Growth Excision Treatment of Scar by Roentgen Rays Prostration and Death Tuberculous Disease of Suprarenals Discovered Post-Mortem Brit M J **2**·70 1904

62 Mann G Ueber einen Fall von Morbus addisonii mit höchst akutem Verlauf Wien klin Wchnschr **31** 1107, 1918

63 Miller H W Clinical and Pathological Report of a Case of Addison's Disease with Terminal Mental Symptoms Am J Insan **63**·309 1906

64 Milne, L S A Case of Addison's Disease with Severe Abdominal Symptoms M Rec **83** 974, 1913

65 Mozer, J J De l influence de la surrenale sur le fonctionnement du rein syndrome azotemique Addisonien Presse med **37** 156, 1929

66 Nordmann M Nebennierentuberkulose mit Durchbruch in den Magen München med Wchnschr **73** 2123 1926

67 Ohensis A E and Mendelson J A Case of Addison's Disease, New York M J **105** 156 1917

68 Ortynsky J Chronic Nephritis Associated with Tuberculosis of Suprarenals and of Urogenital System, Časop lek česk **64** 1321 1925

69 Oudard Insuffisance surrenale latente, Bull et mem Soc med d hop de Paris **46** 184 1922

70 Peiper H Zur Diagnose und operative Therapy des Morbus addisonii Ztschr f Urol **17** 40, 1923

71 Petit L Tuberculose des capsules surrenales et syndrome d insuffisance surrénal aiguë Bull et mém Soc anat de Paris **88** 212 1913

72 Pföringer Zur Entstehung des Hautpigments bei Morbus addisonii Centralbl f allg Path u path Anat **11** 1, 1900

73 Plaschkes S Ein Fall von Morbus addisonii bei Tuberkulose der Nebennieren, Mitt d Gesellsch f inn Med u Kinderh **12** 119, 1913

74 Plozy and Marçon Deux cas d'insuffisance surrenale aiguë Bull et mém Soc med d hôp de Paris **52** 1047 1928

75 Pollak, Leo Untersuchungen bei Morbus addisonii Wien med Wchnschr **60** 865 1910

76 Rashbrook, H M and Carter, F W A Case of Hypoadrenia Simulating Intestinal Obstruction Lancet **2**·240 1918

77 Rowntree L G Studies in Addison's Disease J A M A **84** 327, 1925

78 Sakaguchi K Hayashi I and Katayama K Ueber den Blutzuckergenalt bei der Addison schen Krankheit und bei adrenalektomierten Tieren, Mitt a d med Fakult d k Univ zu Tokyo **23** 33, 1920

79 Schabort J W Case of Addison's Disease with Primary Tuberculous Focus in Fallopian Tubes, Guy's Hosp Rep **77** 102, 1927

80 Schierbeck, quoted by Burgeas (reference 14)

81 Schmidt, H B Addison's Disease Without Pigmentation, Physician & Surgeon, Detroit **35** 510, 1913

82 Schur, H Zur Aetiologie und Pathogenese der Morbus addisonii, Ztschr f ang Anat **1** 443, 1913-1914

83 Seheult, R Notes on a Case of Addison's Disease in a Negress, Lancet **2** 294, 1907

84 Sergent, E L'insuffisance surrenale, Presse med **31** 429, 1923

85 Shoyer, A F Acute Addison's Disease, Brit M J **1** 1120, 1909

86 Siersma, R Adrenal Tuberculosis, J Michigan M Soc **24** 163, 1925

87 Skirving, R S, and Welsh, D A The Clinical Signs and Pathological Changes in a Case of Addison's Disease, Australasian M Gaz **22** 493, 1903

88 Spillmann, L, and Hoche, L Un cas de maladie d'Addison a denouement rapide, contagion genitale de la tuberculose, Arch gen de med **2** 2369, 1903

89 Stauder, A Ueber Nebennierentuberkulose, Munchen med Wchnschr **53** 1837, 1906

90 Steven, J L Specimens from a Case of Addison's Disease, Glasgow M J **55** 112, 1901

91 Swan, W H, and Bortree, L W Addison's Disease Report of Cases, Boston M & S J **194** 712, 1926

92 Symmers, D Report of a Case of Addison's Disease Treated by Means of Suprarenal Extract and Adrenalin Chloride, M News **85** 502, 1904

93 Tapie, J Syndrome d'Addison a marche rapide au cours d'une pleurésie tuberculeuse, Progres med **32** 371, 1917

94 Three Fatal Cases of Addison's Disease, St Thomas' Hosp Rep **31** 87, 1904

95 Tolot Un cas de maladie d'Addison a forme fruste, Lyon med **99** 294, 1902

96 Uhthoff, W Ein Fall von tiefgreifender einseitiger Hornhauterkrankung bei Morbus addisonii mit Sectionbefund, Klin Monatsbl f Augenh **61** 145, 1918

97 Unverricht Insulinempfindlichkeit und Nebenniere, Deutsche med Wchnschr **52** 1298, 1925

98 Vigouroux, A, and Delmos, A Maladie d'Addison et delire, Informateur d alien [etc], Paris **1** 225, 1906

99 von Werdt, F Zur Frage der Beziehung zwischen Status lymphaticus beziehungsweise Thymolymphaticus und Morbus addisonii, Berl klin Wchnschr **47** 2383, 1910

100 Wadi, W Ueber Hypoglykamie bei Morbus addisonii, Klin Wchnschr **7** 2107, 1928

101 Westenhoeffer Ein bemerkenswerther Fall von rapid verlaufener Addison'scher Krankheit, Deutsche mil-arztl Ztschr **30** 82, 1901

102 White, E C, and James, W F Case of Addison's Disease Without Usual Pigmentation of Skin, U S Nav M Bull **25** 122, 1927

103 Whitney, H B An Unusual Case of Addison's Disease, Am Med **8** 1099, 1904

104 Wiesel, J Zur pathologischen Anatomie der Addison'schen Krankheit, Ztschr f Heilk **24** 257, 1903

105 Withington, C F Addison's Disease With and Without Adrenal Tuberculosis, Tr A Am Physicians **19** 316, 1904

106 Zandy Peritonitisartige Symptomencomplex im Endstadium der Addison'schen Krankheit, Ztschr f klin Med **38** 461, 1899

PROBABLE BILATERAL TUBERCULOSIS

107. Barr, C. A Case of Addison's Disease Diagnosed as Such and Verified by Postmortem. Endocrinology 1:326, 1917.

108. Cattermole, G. H. Typical and Atypical Cases of Addison's Disease. Colorado Med. 12:258, 1915.

109. Cattermole, G. H. Typical and Atypical Cases of Addison's Disease. J. A. M. A. 63:1134, 1914.

110. Deglos, E. (Cold Abscess in Addison's Disease). Lyon méd. 130:523, 1921.

111. Detre, L. Der plötzliche Tod eines mit Neosalvarsan behandelten Malariakranken unter Addisonschen Symptomen. Med. Klin. 20:1091, 1924.

112. Eiselt, R. Beitrag zu Stoffwechseluntersuchungen bei Morbus addisonii. Ztschr. f. klin. Med. 69:393, 1910.

113. Evans, J. Acute Addison's Disease Without Pigmentation, Paroxysms of Vomiting Being Main Clinical Symptom, Terminating Three Days After Admission in Sudden Death, etc. Arch. Neurol. Path. Lab. Lond. County Asyl. Claybury 3:290, 1907.

114. Feinblatt, H. M. Addison's Disease Following Vertebral Tuberculosis. M. Clin. North America 11:1075, 1928.

115. Ferrando, H., and Salon. Case of Addison's Disease with Prolonged Survival. Internat. Clin. 3:228, 1928.

116. Germain. Maladie d'Addison congénitale tuberculeuse. J. de méd. de Bordeaux 52:618, 1922.

117. Case of Addison's Disease with Unusual Onset. Guy's Hosp. Gaz. 32:262, 1918.

118. Heninger (reference 44).

119. Holmes, A. O. Defaced Type of Addison's Disease. J. A. M. A. 62:535, 1914.

120. Kaufmann, M. Stoffwechselbeobachtung bei einem mit Nebennierensubstanz behandelten Fall von Morbus addisonii. Centralbl. f. Stoffwechsel- u. Verdauungskr. 2:173, 1901.

121. Lagoanère and Masson, L. Sur quelques particularités de la maladie d'Addison. Paris méd. 49:273, 1925.

122. Langmead, F. Case of Addison's Disease in a Boy Aged Ten Years. Lancet 1:449, 1913.

123. Neer, J. Report of a Case of Tuberculosis of the Adrenals with Pathological Specimens. Wisconsin M. J. 2:231, 1903.

124. Osborne, O. T. Two Cases of Suprarenal Disease. Am. J. M. Sc. 156:202, 1918.

125. Raney, R. B. Case of Addison's Disease. Southwestern Med. 12:244, 1928.

126. Rubino, G. La malattia di Addison e una sindrome plurigiandolare. Riv. osp. 2:145, 1912.

127. Sappemaker, J. N. Treatment of Addison's Disease. J. A. M. A. 36:801, 1901.

128. Sclley, F. P. A Case of Addison's Disease. Death in Collapse. Autopsy. Med. & Surg. Rep. Presbyterian Hosp. N. Y. 8:318, 1908.

129. Steinlans, O. Ein Fall von Morbus addisonii. Wien. med. Wochenschr. 52:2370, 1902.

130. Von Werdt (reference 99).

131. White and James (reference 102).

UNILATERAL TUBERCULOSIS

132 Faber, A (Raynaud's Syndrome in Adrenal Disease), Ugesk f laeger **91** 2112, 1922

133 Goldzieher (reference 39)

134 Rowntree (reference 77)

135 Russell, J Addison's Disease, Brit M J **1** 256, 1903

PYOGENIC INFECTION

136 Roth, N Ein Fall von Morbus addisonii mit seltener Aetiologie, Wien klin Wchnschr **30** 372, 1917

SYPHILIS

137 Sezary, A Syphilis et glandes surrenales, Gaz d hop **87** 1317, 1914

PRIMARY CONTRACTED SUPRARENAL GLANDS (ATROPHY)

138 Arnett, J H Addison's Disease and Diabetes Mellitus Occurring Simultaneously, Arch Int Med **39** 698, 1927

139 Barker (reference 6)

140 Baucke, Ernst Inaug Diss, Gottingen, 1899

141 Bernard, L, and Heitz, J Surrenalite subaigue syndrome d'insuffisance surrenale termine par la mort, Bull et mem Soc med d hôp de Paris **31** 346, 1904

142 Bittorf (reference 9)

143 Bloch, R Entwicklungsstorung und Entwicklungshemmung der Nebennieren bei Addison'scher Erkrankung, Beitr z path Anat u z allg Path **62** 71, 1920

144 Brenner, O Atrophy of the Cortex of the Suprarenal, Quart J Med **22** 182, 1928

145 Donath, J, and Lampl, H Ein Fall von multipler Blutdrusensklerose unter dem klinischen Bilde eines Morbus addisonii, Wien klin Wchnschr **33** 962, 1920

146 Fahr, T, and Reiche Zur Frage der Morbus addisonii, Frankfurt Ztschr f Path **22** 231, 1920

147 Green, E M Report of a Case of Addison's Disease, M Rec **61** 94, 1902

148 Hammar, J A Die Menschen thymus in Gesundheit und Krankheit, Ergebnisse der numerischen Analyse von mehr als 1000 menschlichen Thymusdrussen, Leipzig, 1926

149 Held Pleuriglandulare Insuffizienz, Virchows Arch f path Anat **261** 600, 1926

150 Hubschmann, P Beitrage zur pathologischen Anatomie der Nebennieren, Beitr z path Anat u z allg Path **69** 352, 1921

151 Karakascheff, K I Beitrage zur pathologischen Anatomie der Nebennieren, Beitr z path Anat u z allg Path **36** 401, 1904

152 Kiefer, H Addison's Disease from Chronic Suprarenal Dystrophy with Adenoma-Like Regeneration, Virchows Arch f path Anat **265** 472, 1927

153 Kovacs (reference 51)

154 Kraus (reference 52)

155 Kreibig, W Zur Kenntnis der thyreosuprarenalen Typus der pluriglandularen Erkrankungen (M B Schmidt), Frankfurt Ztschr f Path **36** 668, 1928

156 Langerhans, M Ueber Nebennierenveranderung bei Morbus addisonii, Verhandl d deutsch path Gesellsch **6** 254, 1903

157 Lucksch, F Untersuchungen uber die Nebennieren, Beitr z path Anat u z allg Path **62** 204, 1916

158 Marchand Ein Fall von Atrophie der Nebennieren, Deutsche med Wchnschr **29** 100, 1903

159 Matras Zwei Falle von Addison'scher Krankheit, Wien klin Wchnschr **39** 1347, 1926

160 Medlar, E M Report of Two Cases of Essential Adrenal Insufficiency, Am J Path **3** 135, 1927

161 Mohler, H K Addison's Disease Symptoms and Report of a Case with Autopsy Findings, M Clin North America **4** 1255, 1921

162 Phillips, Carlin A Case of Addison's Disease with Simple Atrophy of the Suprarenals, J Exper Med **4** 580, 1899

163 Rossle Ueber gleichzeitige Addison'sche und Basedowsche Erkrankung, Verhandl d deutsch path Gesellsch **17** 220, 1914

164 Schmidt, M B Ein Biglandulare Erkrankung bei Morbus addisonii, Verhandl d deutsch path Gesellsch **21** 212, 1926

165 Scott, S G Destruction of the Suprarenal Cortex as the Essential Lesion in Addison's Disease, J Path & Bact **18** 419, 1913-1914

166 Short, A R Blood Pressure and Pigmentation in Addison's Disease, Lancet **2** 285, 1906

167 Simmonds, M Ueber Nebennierenschrumpfung bei Morbus addisonii, Virchows Arch f path Anat **172** 480, 1903

168 Steinbiss, W Ueber eine eigenartige Degeneration der Nebennieren bei Morbus addisonii, Virchows Arch f path Anat **262** 286, 1926

169 Wahl, H R Malformation of the Adrenal Glands with Clinical Picture of Addison's Disease, M Clin North America **7** 1357, 1924

170 von Willebrand, E A Morbus addisonii med atrofi af binjurarna, Finska lak-sallsk handl **47** 536, 1905

171 Windholz Vereigung der pathologischen Anatomie, Wien klin Wchnschr **39** 1347, 1926

172 Withington (reference 105)

173 Zimmerman, R Ueber plotzliche Todesfalle bei Atrophie der Nebennierenmarkes, Monatschr f Geburtsh u Gynak **56** 259, 1921-1922

174 Zondek, H Die Krankheiten der endokrinen Drusen, Berlin, Julius Springer, 1923

PROBABLE PRIMARY CONTRACTED SUPRARENAL GLANDS

175 Bazin Mort subite chez un militaire présentant des lesions de surrenalite sclereuse, J de med et chir prat **89** 735, 1918

176 Conybeare and Millis (reference 25)

177 Fiessinger and Leroy Rev gen de clin et de therap **31** 325, 1917

178 Hedinger (reference 44)

179 Hempelmann, L H Addison's Disease, Interstate M J **15** 870, 1908

180 Laignel-Lavastine and Porak, R Syndrome d'Addison sans tuberculose surrénale, par irritation solaire et hypoepinephrie dissocie, Bull et mém Soc med d hôp de Paris **42** 715, 1918

181 Lempl, B Morbus addisonii mit Zirrhose der Nebennieren, Wien med Wchnschr **70** 742, 1920

182 Wakefield, E G, and Smith, E E Addison's Disease, Suprarenalopathies, etc, Am J M Sc **174** 343, 1927

AMYLOIDOSIS

183 Bauer, J Paroxysmal schwerste Adynamie bei Amyloidose der Nebennierenrinde, Klin Wchnschr **1** 1595, 1922

184 Hunter, W C, and Rush, H P Amyloidosis of Adrenals as Cause of Addison's Disease Report of Case with Review of Literature, Ann Clin Med **5** 404, 1926

185 McCutcheon, M Relation of Addison's Disease to Amyloidosis, Am J M Sc **166** 197, 1923

186 Philpott, N W Addison's Disease in Association with Amyloidosis, Ann Int Med **1** 613, 1928

187 Schlesinger Subakute Insuffizienz der Nebenmieren bei Amyloidose nebst Bemerkungen uber den Morbus addisonii, Wien klin Wchnschr **30** 99, 1917

188 Schultz, O T Complete Amyloid Infiltration of Both Adrenals Associated with Addison's Disease, Cleveland M J **11** 40, 1912

FATTY DEGENERATION

189 Loeper, M, and Ollivier, J Fatty Transformation of Both Suprarenals with Melanoderma, Bull et mem Soc med d hop de Paris **50** 312, 1926

190 Peterman, M G Hyposuprarenalism, Am J Dis Child **37** 1239, 1929

191 Schnyder, K Kann die Aplasie einer Nebenniere Morbus addisonii bedingen? Schweiz med Wchnschr **51** 652, 1921

VASCULAR LESIONS

192 Furuta, S H Morbus addisonii durch arterielle Embolien der Nebennieren, Virchows Arch f path Anat **251** 533, 1924

193 Kovacs (reference 51)

194 Straub, H Akuter Morbus addisonii nach Thrombose beider Nebennierenvenen, Deutsches Arch f klin Med **97** 69, 1909

195 Veit, B Ein Beitrag zur pathologischen Anatomie der Morbus addisonii, Virchows Arch f path Anat **238** 269, 1922

TUMORS

196 Bannwart, A Zur Pathogenese der Morbus addisonii, Zertstorung des Nebennieremarkes und des Grenzstranges durch ein Lymphangioendotheliom peritonei metastaticum, Frankfurt Ztschr f Path **26** 307, 1921

197 Hertz, P, and Secher, K A Case of Neuroblastoma Sympatheticus in a Child Suffering from Addison's Disease, Hosp-Tid, København **10** 1093, 1917

198 Riemer, R Sur un cas de syndrome d'Addison produit par un paraganglione de la capsule surrenale, Étude clin et anat path rev neurol, Paris **33** 89, 1926

199 Spangenberg, J J Addison's Disease in Cancer of the Suprarenals, Prensa med argentina **15** 504, 1928

200 Warthin, A S, Crowe, A W, and Jackson, J B Pigmentation of the Skin (Addison's Disease) Associated with Lymphosarcoma Involving Particularly the Retroperitoneal Lymph Nodes of the Solar Plexus Region, Arch Dermat & Syph **10** 139, 1924

MISCELLANEOUS LESIONS

201 Aravandinos, A Das Addisonische Syndrome im Greisenalters, Deutsche med Wchnschr **62** 1006, 1916

202 Beebe, H E Addison's Disease, M Century **12** 110, 1904

203 Borrmann, R Ein Fall von Morbus addisonii infolge entzündlich hyperplastischer Wucherung bei der Nebennieren auf traumatischer Grundlage Deutsches Arch f klin Med **86** 593, 1906

204 Brenner (reference 144)

205 Brower, A B Unusual Addison's Syndromes, Reported at the Annual Meeting of the American College of Physicians, Minneapolis, 1930

206 Debove (reference 29)

207 Durck, H Ueber traumatisch entstandene Addison sche Krankheit, etc Aerztl Sachverst -Ztg **25** 73, 1919

208 Fritz, Paul Knochenmarksbildung in der Nebennieren, Virchows Arch f path Anat **270** 785, 1928

209 Rogoff, J M, and Stewart G N Suprarenal Cortical Extracts in Suprarenal Insufficiency (Addison s Disease) J A M A **92** 1569, 1929

210 Zimmerman (reference 173)

ADDISON'S DISEASE WITHOUT LESIONS IN THE SUPRARENAL GLANDS

211 Debove Sclerose retro-peritoneale pericochaque et syndrome Addisonien, Rev gen de clin et de therap **23** 225, 1909

212 Nobecourt, P, and Brelet, M Maladie d Addison a marche aigue sans lesions des capsules surrenales chez un enfant de 18 mois, Bull Soc de pediat de Paris **7** 251, 1905

213 Richon Un cas de maladie d Addison avec integrite des capsules surrenales, Arch de med d enf **6** 350, 1903

214 Sbrozzi M Reumatismo articolare tubercolare meningite tuberculore sindrome addisoniana frusta, Riv osp **2** 183, 1912

CASES OF ADDISON S DISEASE ON WHICH CLINICAL REPORTS ONLY ARE AVAILABLE

215 Abrahams, R Addison s Disease, Preconstitutional Stage, J Cutan Dis incl Syph **26** 285, 1908

216 Allan, J W Addison's Disease, Glasgow M J **66** 161, 1906

217 Anders, J M Three Cases of Cutaneous Discoloration, M Clin North America **6** 849, 1923

218 Anderson, T McC Case of Addison's Disease Treated by Injection of Tuberculin, Glasgow M J **63** 359, 1905

219 Antonio, S Un caso di morbo di Addison curato con l'adrenalina, Riforma med **39** 900, 1923

220 Aronstam, N E Preliminary Report of a Case of Addison's Disease, Med Age **21** 926, 1903

221 Bittorf (reference 9)

222 Black (reference 10)

223 Boenheim, F Ueber chronische benigne Hypofunction der Nebennieren, Klin Wchnschr **4** 1159, 1925

224 Bomet La médication surrénale dans la maladies d'Addison, Bull Acad de med, Paris **1** 453, 1903

225 Boomer, P C Addison s Disease, Illinois M J **14** 615 1908

226 Bramwell, B Note on the After Progress of a Case of Addison's Disease, etc, Clin Stud, Edinb **4** 76, 1905-1906

227 Bramwell, B Addison s Disease, Clin Stud, Edinb **2** 145, 1903-1904

228 Bramwell, B The Treatment of Addison's Disease, Clin Stud, Edinb **2** 188, 1903-1904

229 Brunecke Grippe als Auslosungsfaktor von akutem Addison, gunstige Beeinflussung dieses durch Partial-Antigenbehandlung, Therap Monatschr **33** 354 1919

230 Bruno (reference 13)

231 Burgess, N, and Warner, E C Case of Addison's Disease Associated with Hyperthyroidism and Vitiligo, Guy s Hosp Rep **76** 280, 1926

232 Calloway, A W Addison's Disease, Clinique, Paris **26** 5, 1905

233 Cannata, S Malattia di Addison nella prima infanzia, Pediatria **30** 585, 1922

234 Castex, M R Osteomalacia por hiposurrenalismo cronico de origen sifilitico, Prensa med **4** 42, 1917-1918

235 Cattermole (reference 108)

236 Caudwell, E Two Cases of Addison's Disease, Westminst Hosp Rep **14** 78, 1905

237 Cerf, F Maladie d Addison, forme fruste, etc, Anjou med, Angers **17** 29, 1910

238 Chameroy Maladie d Addison a forme rare, Soc de med mil franç Bull **6** 666, 1912

239 Chase, A Report of a Case of Addison s Disease, Post-Grad School, N Y **26** 188, 1911

240 Chavigny Maladie d'Addison avec troubles sympathiques, Lyon med **104** 941, 1905

241 Courmont, J, Lesieur, C, and Thevenot L Un cas de maladie d'Addison avec troubles sympathique, Lyon med **104** 939, 1905

242 Crohn, W H Ein seltener Fall von Lues der Nebennieren, Med Klin **18** 1526, 1922

243 Croom, D H Addisonism as a Family Disease, Lancet **1** 603, 1909

244 Daland, J The Use of Adrenal Products in Addison s Disease, Endocrinology **2** 301, 1918

245 Darier J Maladie d'Addison avec tumeur cutanee (sarcoide contenant le bacille de Koch), Bull Soc franç de dermat et syph **19** 313, 1908

246 David, C Syndrome Addisonnien chez une femme atteinte de retrecissement mitral, Tribune med **36** 231, 1903

247 Deaderick, W H Syphilis of the Adrenals, Am J Syph **7** 72, 1923

248 Deeks, W E Addison's Disease Cured by Suprarenal Extract, Montreal M J **31** 509, 1902

249 Deusch Addison'sche Krankheit mit pleuriglandularer Insufizienz, Munchen med Wchnschr **69** 373, 1922

250 Eiselt (reference 112)

251 Étienne, G, and Richard G Exophthalmic Goiter and Addison's Disease Rev franç d'endocrinol **4** 1, 1926

252 Evans, H W Addison's Disease Following Enteric Fever, Lancet **1** 1655, 1900

253 Falco, A Morbo di Addison e gravidanza, Rassegna d'ostet e ginec **24** 434, 1915

254 Fitz-Patrick G Addison s Disease Complicating Pregnancy, Labor or the Puerperium, Surg Gynec Obst **35** 72, 1922

255 Fleming, R A and Miller, J A Family with Addison's Disease, Brit M J **1** 1014, 1900

256 Fox, Howard Addison's Disease, Case Report, J Cutan Dis incl Syph **31** 780, 1913

257 Gardere, C Maladie d'Addison avec troubles mentaux, influence de l adrenaline, Lyon med **132** 745, 1923

258 Glorieux Un cas de maladie d'Addison, Policlin, Brux **18** 321, 1909

259 Golubinin, L Ein Fall von therapeutischer Anwendung der Rontgenstrahlen bei Morbus addisonii, Therap d Gegenw **46** 203, 1905

260 Guisti, G Gravidanza complicata da morbo di Addison, Rassegna d'ostet e ginec **23** 465, 1914

261 Gullan (reference 43)

262 Guthrie, A C Addison's Disease Treated with Friedmann's Tuberculin, Brit M J **2** 1625, 1913

263 Gyotoku, K, and Momose, M Stoffwechseluntersuchungen an vier Fallen von Morbus addisonii, Mitt a d med Fakult d k Univ zu Tokyo **30** 1, 1922

264 Hallopeau, H, and Roy Maladie d'Addison chez un syphilitique, Bull Soc franç de dermat et syph **16** 212, 1905

265 Hansen, A Therapie der benignen Nebennieren Hypofunction, Klin Wchnschr **5** 1282, 1926

266 Head, G D A Case of Addison's Disease, Northwest Lancet **25** 261, 1905

267 Hirtz, E Traitement de la maladie d'Addison par les injections de capsules surrenales, Bull gen de therap **144** 134, 1902

268 Hoegh, K A Case of Addison's Disease, Northwest Lancet **24** 343, 1904

269 Hurst, A F Addison's Disease Treated by Suprarenal Grafting, Brit M J **1** 268, 1922

270 Jellinek Addison'scher Symptomenkomplex, Wien klin Wchnschr **31** 799, 1918

271 Johnston, W Case of Addison's Disease, Philadelphia M J **11** 992, 1900

272 Koehler, A E Differential Diagnosis Between Hypothyroidism and Hyposuprarenalism, J A M A **91** 1457, 1928

273 Lehman, L I Report of Three Cases of Addison's Disease, New Orleans M & S J **70** 814, 1928

274 Leschezmer, H Zur Frage der traumatischen Morbus addisonii, Virchows Arch f path Anat **221** 67, 1915

275 Leschke, Erick Nebennierentransplantation und Organtherapie bei Morbus addisonii, Med Klin **24** 1268, 1928

276 Levin Generalized Pruritus, Pigmentation, and Eczema in a Patient with Adrenalism, Arch Dermat & Syph **2** 97, 1920

277 Loeper and Ollivier (reference 189)

278 Longworthy, S B Addison's Disease, J Kansas M Soc **7** 765, 1907

279 Louste and Thibaut Lichen plan et naevi pigmentes au cours d'un syndrome addisonien, Bull Soc franç de dermat et syph **30** 334, 1923

280 Lucas, H A Case of Addison's Disease with Hyperpyrexia, Lancet **2** 675, 1902

281 Maréchal, I M Un cas de maladie d'Addison, Presse med **55** 553, 1903

282 McCartney, F M A Case of Addison's Disease with Apparent Recovery, Denver M Times **25** 241, 1905

283 Moleen, G A A Recurrent Perinephritic Abscess of Twenty-Six Years Standing and Presenting a Clinical Picture of Addison's Disease, New York M J **81** 179, 1905

284 Mussio-Fournier, J C Syndrome d'Addison fruste avec presence de la ligne blanche, Bull et mem Soc med d hôp de Paris **43** 207, 1919

285 Ness, R B Case of Probable Addison's Disease Associated with Leucodermia and Tuberculosis, Glasgow M J **54** 252, 1900

286 Ness, R B Case of Addison's Disease, Glasgow M J **73** 180, 1910

287 Osborne (reference 124)

288 Peters, E T Report of a Case of Addison's Disease, Virginia M J **15** 141, 1920

289 Petges and Bonnin Maladie de Raynaud avec coexistence du syndrome addisonien, J de med de Bordeaux **41** 149, 1911

290 Piper, F S A Case of Addison's Disease, New England M Gaz **44** 24, 1909

291 Pybus, F C Suprarenal and Pancreatic Grafting, Lancet **2** 550, 1924

292 Quincke, H Zur Behandlung der Addison'schen Krankheit, Therap Halbmonatsh **34** 42, 1920

293 Raven, H M Adrenalin in Addison's Disease, Brit M J **1** 131, 1904

294 Redisch, W Beitrag zur Frage des Zusammenhanges von Hyperpigmentierung und Nebennierenninsuffizienz, Munchen med Wchnschr **70** 1338, 1923

295 Reinhart, A Successful Transplantation of Suprarenals, Munchen med Wchnschr **75** 1027, 1928

296 Reisinger, E W Case of Addison's Disease, Washington M Ann **9** 131, 1910

297 Reuling, R The Tuberculin Test as a Possible Aid in the Diagnosis of Addison's Disease, Maryland M J **45** 299, 1902

298 Rogoff and Stewart (reference 209)

299 Rolleston, H D, and Boyd, F J Addison s Disease in a Boy with Calcification of the Adrenals, Brit J Child Dis **11** 105, 1914

300 Rowntree, L G The Treatment of Three Cases of Chronic Addison's Disease, M Clin North America **7** 177, 1923

301 Sakaguchi, Hayashi and Katayama (reference 78)

302 Schaffner, P M, and Howard, T Addison's Disease of Syphilitic Origin, New York M J **103** 1026, 1916

303 Schittenhelm Addisons'che Krankheit, Deutsche med Wchnschr **39** 53, 1903

304 Schuster Addison'sche Krankheit bei offener Lungentuberkulose, Munchen med Wchnschr **65** 826, 1918

305 Sears, G G A Case of Addison's Disease, Boston M & S J **151** 295, 1904

306 Seitz, L Die Storungen der inneren Sekretionen in ihren Beziehungen zu Schwangerschaft, Leipzig, Johann Ambrosius Barth, 1913

307 Shattuck, F C A Case of Probable Addison's Disease, Boston M & S J **148** 366, 1903

308 Stork, J A Report of a Case of Addison's Disease with General Comments, Gulf States J Med & Surg **16** 92, 1910

309 Teissier, P, and Schaeffer Syndrome d'Addison opotherapie, pression arterielle avant et pendant l'opotherapie, Bull et mem Soc med d hôp de Paris **26** 331, 1909

310 Teschemacher Ein Fall von Geheilten (?) Morbus addisonii, Deutsche med Wchnschr **39** 462, 1913

311 Tibbles, W Addison's Disease, Brit M J **2** 1694, 1905

312 Tieken, T Addison's Disease Report of a Case with Acute Onset, Terminating in Rapid Improvement and Complete Recovery, Am J M Sc **152** 422, 1916

313 Tucker, B R A Case of Addison's Disease with Mental Symptoms, Endocrinology **1** 201, 1917

314 Vanderhoot D Addison's Disease, Old Dominion J Med & Surg **19** 195, 1914

315 Verger, H Syndrome Addisonien très amélioré chez un tuberculeux, Gaz hebd d sc méd de Bordeaux **27** 465, 1906

316 Weber, L A Case of Addison's Disease, M Rec **79** 145, 1911

317 Wells, E F Addison's Disease, Internat Clin **3** 129, 1905

318 Weigall, R E Addison's Disease in a Youth, Australasian M Gaz **24** 545, 1905

319 White, W H Notes from a Clinical Lecture on Addison's Disease Practitioner **82** 190, 1909

320 Wilhoite, R E Addison's Disease Report of a Case, Kentucky M J **8** 2121, 1909-1910

321 Williams, T A The Syndrome of Adrenal Insufficiency, J A M A **63** 2203, 1914

322 Zondek (reference 174)

CASES OF PROBABLE ADDISON'S DISEASE, REPORTS OF WHICH WERE NOT OBTAINABLE

323 Alexeieff, A Contribution a l'etude clinique de la pigmentation de la muqueuse buccale en dehors de la maladie d'Addison, Paris, J Rousset, 1913

324 Allaria, G, and Varanini, M Ricerche sul ricambio in un caso di morbo di Addison, Clin med ital **41** 40, 1902

325 Anderodias Quelques résultats de l'opothérapie surrénale dans le traitement de la maladies d'Addison, J de méd de Bordeaux **30** 467 and 497, 1900

326 Anglade and Jacquin Syndrome addisonien chez un arriérée épileptique de quatorze ans, etc, J de méd de Bordeaux **35** 493, 1905

327 Anglada, J Mélanodermie simple chez un tuberculeux avec tuberculose des capsules surrénales, Montpellier méd **27** 601, 1908

328 Auria, S D Un caso di morbo di Addison, Gior internaz d sc med **23** 493, 1901

329 Austoni, A La policitemia rubra del marbo di Addison rientra nel gruppo della iperglobulie tubercolari Gazz med ital **62** 31, 1911

330 Avanzino, G Terapia surrenale e melanoderma nella sindrome di Addison, Pammatore **9** 119, 1905

331 Bahrs, H Beobachtungen an achtunddreissig Fallen von Addison schen Krankheit, Gottingen, 1905

332 Barraud Presentation de pieces necropsiques d un Addisonien Poitou méd **15** 87, 1900

333 Baylac, J, and Segond, P Un cas de maladie die bronzée d Addison, Echo méd, Paris **15** 148, 1901

334 Becker, W Ueber Kombination des Morbus addisonii mit Sklerodermie, Bonn 1910

335 Bikhmann, E M Clinical Observations of Three Cases of Addison's Disease in Connection with Pathogenesis of the Disease, Vrach gaz **8** 917, 1906

336 Bonnet Maladie bronzée d'Addison, Marseille méd **55** 176, 1918

337 Boismard, E Maladie bronzée d'Addison, amélioration, Arch méd d'Angers **8** 713, 1904

338 Bonilla, F Un caso de enfermedad de Addison postgripal, Med ibera **15** 457, 1921

339 Bouyer, fils Maladie d'Addison, J de med de Bordeaux **33** 238, 1903

340 Buquet, S , Jaurequy, J M, and Castiglioni, J C Sobre un caso de enfermedad de Addison, Ann de Fac de med Montevideo **12** 610, 1927

341 Canali, L Di un caso di morbo di Addison osservato nell ospedale maggiore di Parma, Rendic d Assoc med-chir di Parma **1** 21, 1900

342 Cantineau Cinq cas de maladie d'Addison, J méd de Brux **11** 305, 1906

343 Cavengt, G S Contribución al estudio de la enfermedad di Addison en la infancia Tres casos, Pediatria españ **10** 161, 1921

344 Colat, L P Contribution a l'hematologie de la maladie bronzee d'Addison, Bordeaux, 1905

345 Darkshevich, N Addison's Disease, Russk Vrach **2** 1152, 1903

346 De Blasio, R Su di un caso di morbo di Addison, Riv med **35** 149, 1927

347 Debove Maladie d'Addison, Med mod, Paris **12** 113, 1901

348 Delcour Un cas de maladie d'Addison, Ann Soc med-chir de Paris **42** 579, 1903

349 De Renzi, E Sopra un caso di morbo di Addison, N riv clin-terap **11** 113, 1910

350 De Rita, P Brevi considerizeoni cliniche su di un caso di morbo bronzino o malattia di Addison, Corriere san, Milano **16** 608, 1905

351 Dobiei, J Ueber Morbus addisonii, Inaug Diss, Munich, 1901

352 Drummond, H A Case of Acute Addison's Disease with Postmortem Notes, Northumberland & Durham M J **21** 65, 1913

353 Dumas Une Addisonienne guerie par levure de biere, Echo med d Cevennes **5** 245, 1904

354 Ehret, H Ein Fall Addison'scher Krankheit mit prognostischen Bemerkungen, Strassburg med Ztg **2** 262, 1905

355 Englemann, Karl Ueber die Beziehungen von Erkrankungen der Nebennieren zu Morbus addisonii, Wurzberg, N Philippi, 1906

356 Erdeli, A E Addison's Disease, Trudi i Protok Imp Kavkazsk Med Obsh, Tiflis **45** 31, 1908-1909

357 Fornaroli, E Un caso di morbo di Addison curato con successo con l'opoterapia soprarenale, Gazz med ital **54** 381, 1903

358 Fraenkel, F Ein Beitrag zur Therapie des Morbus addisonii mit Nebennieren Praparaten, Inaug Diss, Breslau, 1900

359 Franzoni, A Sur un cas clinique d'Addison aigu, Rev med de la Suisse Rom **29** 512, 1909

360 Gabarski, J Five Cases of Addison's Disease, Gaz lek Warszawa **30** 1151, 1910

361 Gargano, C L'opoterapia nel morbo di Addison, Riv crit di clin med, Firenze **1** 623, 1900

362 Geeraerd Deux cas de maladie D'Addison, J med de Brux **9** 83, 1904

363 Goldschmidt, L Zur Casuistik der Morbus addisonii, Munich, Kastner & Callwey, 1903

364 Gonzales, O M Sindrome de Addison con hypertonia vago-simpatica, Cron med, Lima **40** 125, 1923

365 Gottlober, L Zur Casuistik der Morbus addisonii, Leipzig, A Hoffmann, 1912

366 Goyena, J R, and Caorsi, L J Melanoderma and Diagnosis of Addison's Disease, Hygiea **88** 359, 1926

367 Groll Un cas de maladie d'Addison contribution a l'etude de cette maladie, Dauphine med **29** 220, 1905

368 Haberfeld, W Un caso de atrophia vermelha das capsulas suprarenaes con molestia de Addison, Arch brasil de med **1** 919, 1911

369 Hall, G R Report of a Case of Addison's Disease Hosp Bull Dept Pub Charity, N Y **1** 39, 1917

370 Hanan, W A A Case of Addison's Disease, Hahneman Monthly Phila **61** 341, 1906

371 Hanus, A Maladie d'Addison avec phenomen vasomoteur particulier des doigts, *Gaz med de Strasb* **80** *378, 1922*

372 Herwig, P Ein Fall von Morbus addisonii Munich, 1906

373 Hultgren, E O Ueber die Addison'sche in Schweden, Nord med Ark, Stockholm **4** 1, 1904

374 Jacques Un cas de maladie d Addison a debut grippal, Rev gen de clin et de therap **18**.530, 1904

375 Josefson, A Morbus addisonii, Hygiea **3** 147, 1903

376 Juarros, M C Tres casos de enfermedad de Addison, Rev san mil, Madrid **17** 461, 1903

377 Kapitz, S Case with Positive Wassermann Reaction, Vrach gaz **32**: 204, 1928

378 Kaufmann Kasuistischer Beitrag zur Addison'schen Erkrankung kompliziert mit Sclerodermie, Vereinsbl d pfalz Aerzte Frankenthal **20** 66, 1904

379 Koppang Morbus addisonii, Forh med Selsk i Kristiania **13** 17, 1914

380 Leonardi, E Del morbo di Addison a le secrezioni interne, Policlin Roma **16** 354, 1909

381 Lucibelli, G Considerazioni intorne ad un caso di morbo di Addison, Gazz internaz di med **8** 187 and 199, 1905

382 Lyle, W C Report of a Case of Addison's Disease, Tr M A Georgia **56** 223, 1906

383 Maiola, B Mastleucocitosi del sangue in un caso di morbo di Addison, Rassegna internaz di clin e terap **3** 137, 1922

384 Majewska, G Case of Addison's Disease Confirmed Post Mortem, Medycyna i Kron lek Warszawa **49** 337, 1914

385 Manuelides Un cas de maladie d'Addison observe chez une femme atteinte de tuberculose pulmonaire et de cancer uterin, Arch orient de med et de chir, Paris **2** 47, 1900

386 Mathhieu, L Un cas de mort subite au cours de surrenalite suppuree double, Arch de med et pharm nav **108** 226, 1919

387 McKendrick, J Case of Possible Incipient Addison's Disease, Glasgow M J **71** 417, 1909

388 Menetrier and Oppenheim Maladie d'Addison a evolution suraiguë, etc, Bull et mém Soc méd d hop de Paris **17** 425, 1900

389 Mensi, E Case of a Child, Therapy by Suprarenal Graft, Clin ed ig infant **4** 4, 1929

390 Montillier and Favardin Sur un cas de maladie bronzée d'Addison, Centre méd et pharm, Gannat **5** 162, 1900

391 Muller, W Beitrage zur Lehre von der Addison'schen Krankheit, Inaug Diss, Freiburg, 1901

392 Murri Morbo d'Addisone sindrome lombare, Gior di med e chir, Napoli **2**·569, 1906

393 Nihill, J E Case of Addison's Disease, Intercolon M J Australas **10** 551, 1905

394 Ninot Un cas de maladie d'Addison a l'evolution tres aigue, Loire méd **24** 235, 1905

395 Pansini, S, and Benenati, U Di un caso di morbo di Addison con revivescenza del timo ed ipertrofia della tiroide e della pituitaria, Policlin, Roma **9** 216, 1902

396 Pizzini, F Un caso de morbo di Addison, Boll d A med tridentina **27** 277, 1908

397 Pospieloff, A T Addison's Disease Russk J Kozhn i Ven Bolnezn **5** 85, 1903

398 Pruszynski, J Addison's Disease Without Bronzing of Skin, Gaz lek, Warszawa **26** 455, 1906

399 Radovanovitch, M Acces paroxystiques d'insuffisance surrenale aigue a la periode terminale de la maladie d'Addison, Geneva, 1923

400 Ravina Maladie d'Addison, Action med **10** 94, 1923

401 Rimbaud, L Insuffisance surrenale aigue au cours d une maladie d'Addison, Montpellier med **26** 577, 1908

402 Rombach, K A Ziekte van Addison met polycythaemie en Milttumor, Nederl tijdschr v geneesk **1** 425, 1907

403 Rudzki, S Ten Cases of Addison's Disease, Czasopismo lek, Lodz **7** 362, 1905

404 Russ, L Un cas de maladie d'Addison, Bull Soc d med et nat de Jassy **19** 29, 1905

405 Rzasnicki, A Case of Addison's Disease, Gaz lek Warszawa **34** 785, 1914

406 Saenz de Santa Maria y Marron, R Enfermedad de Addison tratada con exito la tuberculino, Med ibera **14** 19, 1921

407 Secchi, T Un caso di morbo di Addison con tuberculose incipiente delle capsule surrenali, Gazz med di Torino **52** 222, 241 and 261, 1901

408 Sergent, E, and Bernard, L La maladie d'Addison et la syndrome de l insuffisance capsulaire, XIII Cong internat de med, sect de pathol interne, Compt rend, 1901 pp 515 and 518

409 Speroni, D Enfermedad de Addison y tuberculosis de las capsulas suprarenales, Rev Soc med argent **11** 155, 1903

410 Taylor, S A Case of Addison's Disease, West London M J **8** 314, 1903

411 Tulbendian, M De la maladie d'Addison et de sa forme fruste prolongee a melanodermie primitive, Paris, L Boyer, 1901

412 Turenne, A Toxemia gravidica procoz tipo suprarenal, enfermedad de Addison post puerperal, Rev med d Uruguay **23** 519, 1920

413 Variot Guerison de la maladie d'Addison, J de med int, Paris **9** 108, 1905

414 Vedel, G G, and Ollivier Tuberculose des capsules surrenales, Montpellier med **43** 433, 1921

415 Verger, H, and Carles J Syndrome Addisonien chez un arteriosclereux par surrenalite interstitielle, J de med de Bordeaux **36** 113, 1906

416 Vernescu, D Un cas de formă frustă a maladiei d'Addison, tratat prin opotherapie supra-renală, Spitalul **24** 427, 1904

417 Vincelet, L G Contribution a l'etude de la maladie d'Addison, Paris, C Naud, 1902

418 Whitney (reference 103)

419 Widal La maladie d'Addison, J de med int, Paris **10** 141, 1905

420 Zinninger, G F Addison's Disease with Report of Two Cases, Ohio M J **2** 441, 1906-1907

421 Zuccalo, F Un caso di morbo d'Addison, Gazz med lomb **61** 293, 1902

CITATIONS OTHER THAN OF CASE REPORTS

422 Abelous, J E, and Langlois P Sur les fonctions des capsules surrenales Compt rend Soc de biol **47** 334 1895

423 Alezais, H, and Arnaud, F Etude sur la tuberculose des capsules surrenale et ses rapports avec la maladie d Addison Rev de med, Paris **11** 283 1891

424 Bauer, J Konstitutionelle Disposition zu inneren Krankheiten, ed 3 Berlin, Julius Springer, 1924

425 Bernard and Bigart J de physiol et de path gen, 1906, quoted by Kioyokawa (reference 459)

426 Biedl, A Innere Sekretion Ihre physiologischen Grundlagen und ihre Bedeutung fur die Pathologie, ed 2, Berlin, Urban & Schwarzenberg, 1913

427 Boyd, W Acute Adrenal Insufficiency, J Lab & Clin Med **4** 133, 1918

428 Bramwell, B Two Clinical Lectures on Addison's Disease, Brit M J **1** 67 1897

429 Cramer, W Observations on the Functional Activity of the Suprarenal Gland in Health and Disease Scient Rep Imp Cancer Research Fund 1 1919

430 Crowe S J, and Wislocki, G B Experimental Observations on the Suprarenal Gland with Special Reference to the Function of Their Interrenal Portion, Bull Johns Hopkins Hosp **25** 287, 1914

431 Dietrich A V and Siegmund, H Die Nebenniere und das Chromaffine System, in Henke and Lubarsch Handbuch der speziellen pathologischen Anatomie und Histologie Berlin, Julius Springer, 1926, vol 8

432 Elliott T R Some Results of Excision of the Adrenal Glands J. Physiol **49** 38, 1915

433 Elsasser, O Ueber die Haufigkeit und die Bedeutung der isolierten primaren Nebennierentuberkulose Arb a d Geb d path Anat Inst zu Tubingen **5** 45, 1906

434 Falta, W Ueber den Function der Nebennierenrinde Wien klin Wchnschr **38** 1203, 1925

435 Falta, W Die Erkrankungen der Blutdrusen, Berlin Julius Springer, 1913

436 Fenwick, B On Addison s Disease Brit M J **1** 245, 1886

437 Finzi, O Ueber Veranderungen der Magenschleimhaut bei Tieren nach Nebennieren Extirpation und uber experimentelle erzeugte Magengeschure, Virchows Arch f path Anat **214** 413, 1913

438 French Case of Extensive yet Incomplete Fibrocaseous Disease of Both Suprarenals in Which Symptoms of Addison s Disease Were Not Present, Proc Soc Med **10** (path sect) 93, 1909-1910

439 Gierke Pathologische Anatomie, in Aschoff L Ein Lehrbuch fur Studierende und Aerzte, Jena, Gustav Fischer, 1928, vol 2

440 Gley, E, and Guinguaud A La secretion surrenale d'adrenaline n'est pas necessaire au maintien de la pression arterielle, Compt rend Soc de biol **82** 1175, 1919

441 Glynn, E E The Adrenal Cortex Its Rests and Tumors Its Relation to Other Ductless Glands and Especially to Sex, Quart J Med **5** 157, 1911-1912

442 Goldschmidt, A Beitrage zur Kenntnis der Pathologie der menschlichen Nebennieren, Deutsches Arch f klin Med **98** 186, 1908

443 Goldzieher, M Beitrage zur Pathologie der Nebennieren, Wien klin Wchnschr **23** 809, 1910

444 Greenhow, E H On Addison's Disease, London, 1866

445 Guleke, M Zur Frage des Verhaltnis der Nebennieren bei kongenitalen Syphilis, Virchows Arch f path Anat **173** 519, 1903

446 Hammar (reference 148)

447 Hanau, cited by Glynn (reference 441)

448 Hansemann, D Die Disposition der Nebennieren zur Tuberkulose, Ztschr f Tuberk **27** 140, 1917

449 Hartman, F A, and Blatz, W E Death Produced by Tying the Adrenal Vein, Endocrinology **3** 137, 1919

450 Hartman, F A, and Hartman, W B Production of Epinephrin by the Adrenal Cortex, Am J Physiol **65** 623, 1923

451 Hartman, A D, McArthur, G G, and Hartman, W E A Substance Which Prolongs the Life of Adrenalectomized Cats, Proc Soc Exper Biol & Med **25** 69, 1927-1928

452 Heudorfer, K Ueber das Hautpigment und seine Beziehung zur Addison'schen Krankheit, Munchen med Wchnschr **68** 266, 1921

453 Hoskin, P G, and McClure, C W The Relation of the Adrenal Gland to Blood Pressure, Am J Physiol **30** 192, 1912

454 Hubschmann, P Pathologische Anatomie der Tuberkulose, Die Tuberkulose und ihre Grenzgebiete in Einzeldarst, Berlin, Julius Springer, 1928, vol 5

455 Iwabuki, T Ueber Nebennieren Veranderungen beim experimentellen Scorbut, Beitr z path Anat u z allg Path **70** 440, 1922

456 Jaffe, H L Influence of Suprarenal Gland on Thymus, Regeneration of Thymus Following Double Suprarenalectomy in Rat, J Exper Med **40** 619, 1924

457 Kaiserling Missbildung und vorborgene Tuberkulose der Nebennieren eines Erwachsenen, Berl klin Wchnschr **54** 77, 1917

458 Karpeles, S Ein Fall von Nebennierentuberkulose ohne Morbus addisonii, Inaug Diss Munich, 1902

459 Kioyokawa, W Die Nebennieren bei Tuberkulose, Frankfurt Ztschr f Path **29** 287, 1923

460 Koehler (reference 272)

461 Kohn, A Die Paraganglien, Arch f mikr Anat **62** 263, 1903

462 Laignel-Lavastine and Halbron, P Trois cas de tuberculose surrenale sans melanodermie, Bull et mem Soc anat de Paris **82** 369, 1907

463 Landau, M Zur Entwicklung der Nebennierenrinde, Deutsche med Wchnschr **39** 300, 1913

464 Levin, I Physiological Studies on the Blood of Animals Deprived of Their Suprarenals, Am J Physiol **5** 358, 1901

465 Lewin, G Ueber Morbus addisonii, Charite-Ann **17** 536, 1892

466 Lewin, G Ueber Morbus addisonii mit besonderer Berucksichtigung der eigentumlichen abnormen Pigmentation der Haut, Charite-Ann **10** 630, 1885

467 Lowenstein, E Tuberkulose als Organsystemerkrankung, Wien klin Wchnschr **36** 549, 1923

468 Lowenthal, K Die angeblicke Hypoplasie der Nebennierenmarkes beim sogenannten Status-thymico-lymphaticus, Deutsche med Wchnschr **55** 1099, 1929

469 Lubarsch, O Einiges uber die Localization und die Ausbreitungsweise tuberkuloser Veranderungen im Korper, Festschr f A Schlossmann, Dusseldorf, 1927, p 298

470 Mackay, L L, and Mackay E M Compensatory Hypertrophy of the Adrenal Cortex, J Exper Med **43** 395, 1926

471 Mann, F C A Study of the Gastric Ulcers Following Removal of the Adrenals, J Exper Med **23** 203, 1916

472 Marañon, G L'insuffisance surrénale primative et secondaire, Rev franç d'endocrinol **6** 277, 1928

473 Marchetti, G Ueber eine Degenerationszyste der Nebennieren mit kompensatorischer Hypertrophie, Virchows Arch f path Anat **172** 472, 1903

474 Marine D, Manley, O T, and Baumann, E J The Influence of Thyroidectomy, Gonadectomy Suprarenalectomy and Splenectomy on the Thymus Gland of Rabbits, J Exper Med **40** 429, 1924

475 McKerrow and Rolleston, cited by Rolleston Diseases of the Suprarenals, in Albutt and Rolleston System of Medicine, New York, The Macmillan Company, 1906, vol 4, pt 1

476 McMahon, A, and Zwemer, R L Pathologic Histology of Adrenalectomized Cats, Am J Path **5** 491, 1929

477 Miloslavich, E Ueber Bildungsanomalien der Nebenniere, Virchows Arch f path Anat **218** 131, 1914

478 Miloslavich, E Ueber einseitigen Nebennierenmangel, Centralbl f allg Path u path Anat **30** 465, 1920

479 Morelli, E, and Gronchi, V M Ricerche sulle tiroidi e le surrenali nello scorbuto sperimentale, Sperimentale Arch di biol **81** 127, 1927

480 Muruta, M Ueber Beri-Beri-ähnliche Krankheit beim Kaninchen, Virchows Arch f path Anat **245** 448, 1923

481 Neusser, E Diseases of the Suprarenal Capsules, in Nothnagel Encyclopedia of Practical Medicine, Philadelphia, W B Saunders Company, 1903, pp 307-333

482 Neusser and Wiesel Die Erkrankungen der Nebennieren, ed 2, Leipzig, Alfred Holder, 1910

483 Oberndorfer Discussionsbemerkung, Verhandl d deutsch path Gesellsch **17** 237, 1914

484 Omelskyj, E Zur Nebennierenpathologie II Ueber cytotoxische Schrumpfnebenniere bei hypophysarer Kachexie und über örtliche Schrumpfnebenniere, Virchows Arch f path Anat **271** 366, 1929

485 Ophuls, W A Statistical Survey of Three Thousand Autopsies, Stanford University, Calif, Stanford University Press, 1926, p 370

486 Oppenheim, R, and Loeper, M Insuffisance surrénale chronique par injections intracapsulares des poisons du bacille tuberculeux humain d'auclair, Compt rend Soc de biol **55** 330, 1903

487 Oppenheim, R, and Loeper, M, cited by Laignel-Lavastine and Halbron (reference 462)

488 Paunz, T Ueber die Rundzellenherde der Nebenniere, Virchows Arch f path Anat **242** 138, 1923

489 Rabinowitsch, L Blutbefunde bei Tuberkulose, Berl klin Wchnschr **50** 110, 1913

490 Rogoff, J M, and Dominquez, R Blood Pressure Following Adrenalectomy, Am J Physiol **83** 84, 1927

491 Rogoff, J M, and Stewart, G N Studies on Adrenal Insufficiency in Dogs The Influence of Adrenal Extracts on the Survival Period of Adrenalectomized Dogs, Am J Physiol **84** 660, 1928

492 Rogoff and Stewart (reference 209)

493 Rogoff, J M, and Stewart, G N Studies on Adrenal Insufficiency in Dogs, Am J Physiol **78** 711, 1926

494 Rolleston, H D Addison's Disease, in Albutt and Rolleston System of Medicine, New York, The Macmillan Company, 1906, vol 4, pt 1

495 Scheel, O Ueber Nebennieren Sekretkornchen- Odem,- Gewicht, Virchows Arch f path Anat **192** 494, 1908

496 Schmorl and Kockel Die Tuberkulose der menschlichen Placenta und ihre Beziehung zur fotalen Tuberculose, Beitr z path Anat u z allg Path **16** 313, 1894

497 Schwarz, F Zur Genese der Tuberkulose der Nebennieren, Ztschr f Tuberk **37** 169, 1922

498 Simmonds, M Die Nebennieren bei Syphilis congenita, Virchows Arch f path Anat **218** 153, 1914

499 Simmonds, M Ueber kompensatorische Hypertrophie der Nebennieren, Virchows Arch f path Anat **153** 138, 1901

500 Simmonds, M Weitere Beobachtungen uber kompensatorische Hypertrophie der Nebennieren, Zentralbl f allg Path u path Anat **13** 81, 1902

501 Snell, A M, and Rowntree, L G Clinical Experience with Addison's Disease, Ann Int Med **3** 6, 1929

502 Stewart, G N The Adrenal Glands, Arch Int Med **43** 737, 1929

503 Stewart, G N, and Rogoff, J M The Alleged Relation of the Epinephrin Secretion of the Adrenals to Certain Experimental Hyperglycemia, Am J Physiol **44** 543, 1917

504 Stewart, G N, and Rogoff, J M Quantitative Experiment on the Liberation of Epinephrin from the Adrenals after Section of Their Nerves The Question of the Indispensability of Epinephrin, J Pharmacol & Exper Therap **10** 1, 1917

504a Stewart, G N The Significance of the Suprarenal Gland in Relation to the Vital Processes, Endocrinology and Metabolism, New York, D Appleton & Company, 1922, vol 2, p 128

505 Stewart, G N, and Rogoff, J M The Relation of the Adrenals to Hyperglycemia and to the Glycogen Content of the Liver, Am J Physiol **46** 90, 1918

506 Stewart, G M, and Rogoff, J M Further Observations Showing that Epinephrin Is not Indispensable, Am J Physiol **48** 397, 1919

507 Stilling, H Ueber die kompensatorische Hypertrophie der Nebennieren, Virchows Arch f path Anat **118** 569, 1889

508 Stursberg Ueber plotzlichen Tod bei klinisch nicht erkennbarer Nebennierentuberkulose, Deutsche med Wchnschr **30** 1406, 1904

509 Sumiyoshi, Y Die Nebennierentuberkulose als Organsystemerkrankung, Ztschr f Tuberkulose **41** 325, 1924

510 Thomas, E Ueber di Nebenniere des Kindes und ihre Veranderungen bei Infektionskrankheiten, Beitr z path Anat u z allg Path **50** 19, 1911

511 Vecchi, B de Ueber die experimentelle Tuberkulose der Nebennieren, Centralbl f allg Path u path Anat **12** 577, 1901

512 von Kahlden, C Ueber Addison'sche Krankheit, Beitr z path Anat u z allg Path **10** 454, 1891

513 von Kahlden, C Addison'sche Krankheit und Funktion der Nebenniere, Centralbl f allg Path u z path Anat **7** 464, 1896

514 Weissenfeld, F Zur Pathologie der Nebennieren, Beitr z path Anat u z allg Path **70** 516, 1922

515 Wheeler, T D, and Vincent, S Question as to the Relative Importance to Life of Cortex and Medulla of the Adrenal Bodies, Roy Soc Canada **11** 125, 1917

516 Wiesel, J Zur Pathologie des Chromaffinen Systemes, Virchows Arch f path Anat **176** 103, 1904

517 Wiesel J Krankheiten der Nebennieren in Levandowsky Handbuch der Neurologie Julius Springer 1913, vol 4, pp 348-379

518 Wilks, S, and Daldy On the Constitutional and Local Effects of Disease of the Suprarenals, in A Collection of the Published Writings of Thomas Addison The New Sydenham Society 1868 p 211

519 Wilks S On Disease of the Suprarenal Capsules in Morbus Addisonii Guy s Hosp Rep **8** 1 1862

520 Winogradow Syphilis der Nebenniere Ergebn d allg Path u path Anat **5** 650 1898

521 Wulfung M Die Veranderungen der Nebennierenrinde bei Infektionskrankheiten, Virchows Arch f path Anat **253** 239 1924

Notes and News

University News, Appointments, Promotions, Resignations, etc—Harold Edward MacMahon, London, Ontario, has been appointed professor of pathology and bacteriology in Tufts College Medical and Dental Schools, Boston

K. Terplan has been appointed pathologist to the Buffalo General Hospital in the place of the late Benjamin Roman

Annals of Surgery will publish a special number in honor of James Ewing

In the school of medicine of the University of Texas, Galveston, Texas, Harry L Klotz has become adjunct professor of pathology

Waldemar Haffkine, pioneer bacteriologist, born in Odessa of Jewish parents and best known for his inoculations against cholera and plague, has died at the age of 70 He was Pasteur's assistant when he was invited to India, in 1893, to devise methods for the prevention of cholera The laboratory in which he worked in Bombay is now called the Haffkine Institute Since 1915 he had lived in Paris

Beatrice C Seegal has been made assistant professor of bacteriology in Columbia University

Eustace L Benjamin has been appointed assistant professor and Takejiro Matsui research fellow in the department of pathology in the Loyola University School of Medicine, Chicago

John H Fisher is now professor of bacteriology in the University of Western Ontario

Karl Landsteiner, member of the Rockefeller Institute for Medical Research since 1922, has been awarded the Nobel prize in medicine for his discovery of the human blood groups and for his contributions to the study of fundamental problems in relation to immunity Dr Landsteiner discovered the human blood grouping about thirty years ago, when he was an assistant in the pathologic-anatomic institute of the University of Vienna, under Anton Weichselbaum

Alan Gregg has been appointed to succeed the late Richard M Pearce, Jr, as director for the medical sciences of the Rockefeller Foundation Dr Gregg, who will assume his new duties on Jan 1, 1931, has directed the European work of the Foundation in the medical sciences since 1925

A New Journal in the Field of Pathology—Beginning in January, 1931, the American Society of Clinical Pathologists will publish bimonthly the *American Journal of Clinical Pathology* under the editorship of Thomas B Magath, assisted by an advisory board The new journal will contain papers on all phases of so-called clinical pathology and related subjects, including technical methods

Society News—The Oregon Pathological Society has been organized in Portland, Ore, with Frank R Menne as president and Warren H Hunter as secretary

The next annual meeting of the Federation of American Societies for Experimental Biology will be held in Montreal, Canada, on April 8 to 11, 1931 The secretary is Howard B Lewis, University of Michigan, Ann Arbor, Mich

The thirty-first annual meeting of the American Association of Pathologists and Bacteriologists will be held at Western Reserve University, Cleveland, on April 2 and 3, 1931 The special topic will be "Disease of the Liver, Exclusive of Tumors," which is to be presented by F B Mallory and G H Whipple

Abstracts from Current Literature

Experimental Pathology and Pathologic Physiology

NORMAL URINE SUGAR IN CYSTOSCOPIC EXAMINATIONS RUSSELL RICHARDSON and RUTH S BITTER, Am J M Sc **180** 171, 1930

Specimens of normal urine obtained by ureteral catheterization usually show approximately equal amounts of sugar from the two kidneys in the absence of any disease that damages the efficiency of either kidney When a kidney is badly damaged, the sugar is much decreased compared with that from the normal kidney An increased secretion of sugar may accompany apparently temporary damage, which is demonstrable by decreased results in phenolsulphonphthalein tests A slight reduction in functional efficiency may be evident only when the kidneys are forced to excrete sugar at a higher concentration, as following a meal The damaged kidney cannot excrete urine of as high sugar content as its fellow

AUTHORS' SUMMARY

DIABETIC KETOSIS AND FUNCTIONAL RENAL INSUFFICIENCY A F COBURN, Am J M Sc **180** 178, 1930

In the alleviation of acute ketosis, urinary excretion of acetone bodies is of perhaps greater importance than their oxidation It has been repeatedly demonstrated in the group of patients presented that ketonemia may exist in absence of ketonuria This condition appears at times to precede anuria and should be regarded as a warning to the physician The development of anuria greatly jeopardizes the recovery of a patient with severe ketosis Intravenous fluid has been of far greater value in causing excretion of ketone bodies and in correcting anuria than fluid administered by other routes Recovery from severe ketosis may depend largely on the rapidity with which acetone bodies are excreted by the kidney, and may be prevented by the development of functional renal insufficiency

AUTHOR'S SUMMARY

LEUKOPENIA RESEMBLING AGRANULOCYTOSIS WITH RECOVERY WILLIAM P THOMPSON, Am J M Sc **180** 232, 1930

Seven cases are presented, of an acute, transient, infectious disease associated with high fever, low pulse rate, enlargement of the lymph nodes, leukopenia, relative agranulocytosis, the late appearance of queer whitish spots on the posterior pharyngeal wall and prompt, complete recovery The etiology is unknown The cases represent another variant in the group of infections associated with the agranulocytic type of blood picture

AUTHOR'S SUMMARY

THE ETIOLOGIC RELATIONSHIP OF ACHYLIA GASTRICA TO PERNICIOUS ANEMIA W B CASTLE, W C TOWNSEND and C W HEATH, Am J M Sc **180** 305, 1930

The active constituent of the gastric contents of the normal human stomach during fasting is in all probability secreted by the mucosa of the stomach and is not detectably present in normal saliva or duodenal contents free from gastric juice, or in the secretions of any portion of the gastro-intestinal tract of the patients with pernicious anemia, this substance is probably organic, thermolabile, possibly enzymic and capable of interaction with protein or closely related substances in neutral solution, resulting in the production of material having, when administered to patients with pernicious anemia, a marked hematopoietic effect

It an enzyme, it is certainly not pepsin, its properties, as thus far determined, are only in certain respects similar to those of renin The lack of this particular property of the gastric contents in pernicious anemia is probably the essential defect leading to the development of the disease, through a failure of the normal reaction, occurring in these experiments with beef muscle proteins and normal human gastric juice

It is also concluded that the existing tests for hydrochloric acid and pepsin of the gastric juice are not necessarily of value in determining the presence or absence of the intrinsic factor essential to the reactions between normal human gastric juice and beef muscle described in these papers

ABSTRACT OF AUTHORS' SUMMARY

THE PRODUCTION OF HYPERTROPHIC ARTHRITIS BY INTERFERENCE WITH THE BLOOD SUPPLY A D GOLDHAFT, L M WRIGHT and R PEMBERTON, Am J M Sc **180** 386, 1930

Experiments are reported in which the phenomena of arthritis, chiefly of the hypertrophic variety, were brought about in the region of the patella in dogs by ligation of the blood supply to the patella Control experiments in which an amount of silk ligature equal to that used in the original experiments was placed around the patella, following on an otherwise essentially identical operation, failed to produce any overgrowth after a comparable lapse of time Analyses of the overgrowth and of the original patella giving rise to the overgrowth show that the percentage of magnesium in the overgrowth was higher than that in the control tissues The involvement of the mineral metabolism in the region affected is thus clearly indicated These experiments are in entire consonance with those arrived at, following a different line of reasoning, by Wollenberg, and indicate beyond any reasonable doubt that disturbance of the blood supply must henceforth be regarded as one of the factors capable of producing arthritic change Taken in conjunction with other work referred to early in the present text, these experiments afford strong evidence that interference with the blood supply, probably in the nature of vasoconstriction, constitutes at least a part, probably a large part, of the underlying physiologic disturbance productive of the phenomena of chronic arthritis, especially the hypertrophic type as encountered in human beings

AUTHORS' SUMMARY

PHYSIOLOGIC ACTION OF THE VENOM OF THE HONEYBEE H E ESSEX, J MARKOWITZ and F C MANN, Am J Physiol **94** 209, 1930

The intravenous injection of the venom of the honey bee, *Apis mellifera,* into dogs and rabbits caused reactions closely resembling those described for rattlesnake venom—a rapid fall of blood pressure, diminution of renal volume, increased volume of the extremities and marked hemolysis with greatly increased volume of the erythrocytes The skin reaction following its intradermal injection was likewise practically identical with that following injection of rattlesnake venom, and further similarity to this verom and to histamine was shown by maximal contraction of perfused uterus of a virgin guinea-pig and by occlusive bronchial spasm after its intravenous injection into guinea-pigs

H E EGGERS

CHEMISTRY AND METABOLISM IN EXPERIMENTAL YELLOW FEVER IN MACACUS RHESUS MONKEYS A MAURICE WAKEMAN and CLARE A MORRELL, Arch Int Med **46** 290, 1930

Determinations of total nonprotein nitrogen and the individual nonprotein nitrogenous components (urea, amino-acid, ammonia, uric acid and creatinine) have been made on the blood of normal monkeys (*Macacus rhesus*) and similar animals with experimental yellow fever Uric acid, creatinine, rest nitrogen and ammonia are not constantly altered, although in the terminal stages of the

disease, creatinine and rest nitrogen usually rise to a variable extent The constituents chiefly affected are urea and amino-acids Amino-acid nitrogen rises rapidly in the terminal stages of the disease, urea nitrogen may rise, but sometimes remains constant or falls In any case, amino-acid increases proportionately far more, and urea far less, than total nonprotein nitrogen—evidence that the power of the liver to deaminize amino-acids and to produce urea is greatly impaired or destroyed This functional derangement becomes apparent only during the last hours of life

AUTHORS' SUMMARY

FATAL HUMAN ANAPHYLACTIC SHOCK JESSI G M BULLOWA and MENDEL JACOBI, Arch Int Med **46** 306 1930

A case of fatal anaphylactic shock after a single injection of diphtheria antitoxin is reported The pathologic anatomy is described, consisting chiefly of acute pulmonary emphysema, dilatation of the right side of the heart, general venous stasis and visceral congestion the left side of the heart was contracted and empty Microscopically, the changes consisted chiefly of thickening of the arteriolar wall, especially in the lungs These anatomic changes are presented as corroborative morphologic evidence to substantiate the experimental work on the pathogenesis of fatal anaphylactic shock reviewed This consisted chiefly in overfilling of the lungs, which remained distended a drop in the peripheral blood pressure with a concomitant rise in the pulmonary arterial pressure, a progressive weakening of cardiac contraction and a slowing and final stopping of the heart, with the right auricle and ventricle in diastole and very much dilated The cases of anaphylactic shock which came to autopsy are reviewed in detail Doubt is cast on the role of the thymus in such cases

AUTHORS' SUMMARY

THE CAUSE OF DEATH FOLLOWING RAPIDLY THE TOTAL LOSS OF PANCREATIC JUICE R ELMAN and A F HARTMANN Arch Surg **20** 333, 1930

Using a method that permitted sterile collection of the entire twenty-four hour secretion of the pancreas of the dog, the authors found that death occurred rapidly, generally in about eight days Examination of the blood revealed rapidly progressive and severe acidosis This was particularly so in those animals that did not vomit, but if the vomiting was considerable, there was much loss of gastric secretion, and alkalosis supervened The dogs could be kept alive with daily injections of Ringer's solution The most important factor in the rapidly fatal outcome was the severe dehydration

N ENZER

THE CAUSE OF DEATH IN UNCOMPLICATED HIGH INTESTINAL OBSTRUCTION J C WHITE and F A FLYNDER, Arch Surg **20** 897, 1930

Complete intestinal obstruction was performed in dogs by severing the small intestine 12 inches (30 48 cm) below the pylorus A catheter was placed in the lower segment The vomitus was collected and injected into the lower bowel, diluted with water Later, dextrose was added In spite of the high obstruction, the animals remained in good condition for an entire month There was, however, loss of weight The nonprotein nitrogen remained practically stationary, but the blood chlorides revealed a reduction, which developed rather slowly In the untreated dogs, this reduction would have taken place in from three to five days The animals were killed after one month The experiment pointed out that an animal can be kept alive if the loss of secretion from the upper bowel and stomach is prevented by introducing it again into the intestinal circulation In their conclusion, the authors point out that it is probably unlikely that a toxin formed in the obstructed intestine can be absorbed by the mucous membrane if the blood supply is maintained The fact that salt solution would neutralize the toxin likewise is disputed, because the animals received no salt from outside sources and still became considerably dechlorinated at the end of the month

There was a proportionate loss of salts from the tissues corresponding to that from the blood The nonprotein nitrogen of the blood remained stationary, indicating that there was no destruction of tissue protein The authors conclude that death in uncomplicated high obstruction is due mainly to loss of salts and water in the gastroduodenal secretions

N ENZER

THE RESPONSE OF PLASMA WATER AND ELECTROLYTES TO ELEVATION OF BODY TEMPERATURE RUSTIN MCINTOSH, LASLO KAJDI and DOROTHY MEEKER, Bull Johns Hopkins Hosp **47** 61, 1930

By simultaneous determination in rabbits of the volume of the blood and of the plasma and of the concentrations of the total fixed base, chloride and bicarbonate of the serum, it has been possible to study the movement of water and electrolytes into and out of the circulation in response to elevations of the temperature of the body Fever was produced in a variety of ways—by intraperitoneal injection of two different vaccines, by intravenous injection of a vaccine and by irradiation of the animals with an electric lamp—and with all the methods, an increase in the volume of the circulating blood was brought about, varying only in degree roughly parallel to the change in temperature Fever caused essentially no constant immediate change in the circulating cell volume, the increase pertained to the plasma fraction It caused invariably a diminution in the serum concentration of bicarbonate, usually a diminution of the concentration of total base, and sometimes a diminution, but more often an elevation, of serum chloride concentration The increase in the volume of the plasma, however, represented an influx into the circulation of water and electrolyte of such degree that the total amount of circulating electrolytes was increased over the level existing prior to the elevation of the body temperature Usually, the total amount of circulating bicarbonate was diminished during fever, but this was not invariably the case At these times calculations of the composition of the fluid entering the circulation suggested that it was drawn from reservoirs of intercellular fluid, and this hypothesis was strengthened by the vigorous response of one animal in which the store of subcutaneous fluid had been reinforced by hypodermoclysis of normal salt solution These calculations also suggested that the fluid entering the circulation might at times have a concentration of electrolytes lower than that of normal plasma or of intercellular fluid, which may be offered as a possible explanation of the lowering of the chloride concentration of the plasma often found in pneumonia and other infections The data obtained afford an approximate estimate of normal standards of total base, chloride and bicarbonate in the circulating plasma of rabbits

AUTHORS' SUMMARY

THE OXYGEN RELATIONSHIPS OF UMBILICAL CORD BLOOD AT BIRTH NICHOLSON J EASTMAN, Bull Johns Hopkins Hosp **47** 21, 1930

The oxygen relationships of fetal blood, both in utero and at birth, differ widely from those of maternal blood The principal characteristics of fetal blood in its relation to oxygen are the high capacity, the low arterial content, the very low venous content and, as a result of these three factors, an extremely high capillary unsaturation The greatest difference between fetal and maternal blood in relation to oxygen is found in the mean capillary unsaturation, which in fetal blood at birth is three times, and in utero more than twice, that of adult blood The very high unsaturation of fetal blood in respect to oxygen indicates that the full term fetus in utero exists normally in a state of cyanosis The evidence suggests that the high oxygen capacity, or hemoglobin content, of fetal blood is an adaptive or "acclimatization" phenomenon due to the low oxygen tension to which the fetal blood in the villous capillaries is subjected, a tension that is estimated as being less than 40 mm of mercury Viewed by adult standards, the blood reaching the fetal tissues is low in oxygen, but for the needs of the fetal organism it is evidently adequate

AUTHOR'S SUMMARY

RESPONSE OF BLOOD GUANIDINE BASE CONCENTRATION IN NORMAL INDIVIDUALS AND IN PATIENTS WITH LIVER INJURY TO THE INGESTION OF METHYL GUANIDINE SULPHATE R McL ELLSWORTH, Bull Johns Hopkins Hosp **47**·106, 1930

The administration of 200 mg of methyl guanidine sulphate by mouth did not produce in normal persons a rise of blood guanidine base concentration in four hours In eight cases of diffuse injury of the liver, the initial blood guanidine base was slightly elevated, and ingestion of the amount of guanidine salt stated produced a conspicuous rise of guanidine in the blood Observations of blood guanidine base in the manner suggested may prove to be of assistance in detecting injury of the liver

AUTHOR'S SUMMARY

DISAPPEARANCE OF DIABETES MELLITUS DURING THE DEVELOPMENT OF CIRRHOSIS OF THE LIVER JAMES BORDLEY, III, Bull Johns Hopkins Hosp **47** 113, 1930

A case is reported in which severe and long-standing diabetes mellitus cleared up as portal cirrhosis of the liver developed Attention is called to several similar cases reported in the literature Cases of this nature are apparently rare, and the experience of others has shown that portal cirrhosis of the liver does not usually exert such an ameliorating effect on diabetes mellitus

AUTHOR'S SUMMARY

CORTICAL INSUFFICIENCY OF ADRENALS OTTO SAPHIR and H F BINSWANGER, J A M A **95** 1007, 1930

A clinical and pathologic study of two cases of suprarenal cortical insufficiency was made One case, clinically diagnosed as Addison's disease, showed changes which histologically are similar to the ones found in cytotoxic contraction of the suprarenals (Kovacs) An analysis of this case revealed that the blood pressure reached 106 systolic and 78 diastolic, and that the asthenia developed only shortly before the patient died A possible clinical differentiation between Addison's disease and cortical insufficiency of the suprarenals may be made The second case, in which death occurred shortly after an appendectomy, showed similar lesions, but much less marked There were severe degenerative changes throughout regenerated cortical cells Clinically, the only symptom that could be referred to suprarenal lesions was a diffuse pigmentation of long duration The sudden death of the patient was attributed to an acute incompetence of the regenerated cortical cells following the operation

AUTHORS' SUMMARY

FIXATION OF FOREIGN PROTEIN AT SITE OF INFLAMMATION VALY MENKIN, J Exper Med **52** 201, 1930

Foreign protein, such as horse serum, injected into an inflamed peritoneal cavity, penetrates into the blood stream less rapidly than when introduced into the normal cavity Foreign protein injected into a cutaneous inflammatory area is held in situ for a longer period than when injected into an inflamed peritoneal cavity Foreign protein introduced into the circulating blood stream accumulates in an inflamed area, where it is found in greater concentration than in normal tissue Accumulation of foreign protein at the site of inflammation explains the phenomenon of local anaphylaxis described by Auer in rabbits sensitized to horse serum The antigen accumulating in the inflamed ear reacts with antibody, intensifies a preexisting inflammatory reaction and produces necrosis of the ear

AUTHOR'S SUMMARY

THE INFLUENCE OF ULTRA-VIOLET RADIATION ON THE WEIGHT OF ADULT RABBITS, NORMAL AND SYPHILITIC ALVIN R HARNES, J Exper Med **52** 253, 1930

Normal rabbits living in total darkness and exposed to ultraviolet radiation at regular intervals showed a more rapid rate of increase in weight than animals living under the same condition without treatment by ultraviolet rays, but after an initial period of rapid increase, the irradiated animals maintained a lower body weight than those living in the dark Under the same conditions, animals inoculated with *Spirochaeta pallida* and exposed to ultraviolet light maintained a lower weight than the corresponding control groups living in total darkness Furthermore, the mortality from pneumonic infection was found to be greater in animals exposed to ultraviolet radiation than in those living entirely in the dark It is evident, therefore, that, under the conditions given, ultraviolet radiation is detrimental rather than beneficial

AUTHOR'S SUMMARY

A-AVITAMINOSIS IN CHICKENS O SEIFRIED, J Exper Med **52** 519 and 533, 1930

The principal tissue changes in the respiratory tract of chickens caused by a vitamin A deficiency in the food are, first, atrophy and degeneration of the epithelium of the lining mucous membrane, as well as of the epithelium of the mucous membrane glands This process is followed or accompanied by replacement or substitution of the degenerating original epithelium of these parts by a squamous stratified keratinizing epithelium This newly formed epithelium develops from the primitive columnar epithelium and divides and grows rapidly The process appears to be one of substitution rather than of metaplasia, and resembles the normal keratinization of the skin or even more closely the incomplete keratinization of the mucous membranes (e g, the esophagus or certain parts of the tongue of the chicken) In this connection, changes are described which not only afford an interesting insight into the complicated mechanism of keratinization, but also show probable relations between keratinization and the development of Guarnieri's inclusion bodies Balloon and reticular degeneration of the upper layers of the new stratified epithelium is frequently observed All parts of the respiratory tract are about equally involved in the process, and the olfactory region as well, so that the sense of smell may be lost The lesions, which first take place on the surface epithelium and then in the glands, show only minor differences The protective mechanism inherent in the mucous membranes of the entire respiratory tract is seriously damaged, or even entirely destroyed, by the degeneration of the ciliated cells at the surface and the lack of secretion with bactericidal properties Secondary infections are frequently found, and nasal discharge and various kinds of inflammatory processes are common, including purulent ones, especially in the upper part of the respiratory tract, communicating sinuses, eyes and trachea The development of the characteristic histologic process is not dependent on the presence of these infections, since it also takes place in the absence of infection The specific histologic lesions make it possible to differentiate between A-avitaminosis and some infectious diseases of the respiratory tract

AUTHOR'S SUMMARY

THE PLACENTAL TRANSMISSION OF FOREIGN PROTEINS IN RABBITS FRANCES E HOLFORD, J Immunol **19** 177, 1930

Horse hemoglobin has not been found to pass the rabbit placenta Egg albumin, horse or beef serum, the pseudoglobin fraction of beef serum and the globulin fraction of horse serum, injected into pregnant rabbits near term, have, on the other hand in a number of instances been found to pass the placental barrier in quantity sufficient for demonstration in the serum of the fetus It is suggested that this fact may be of significance in the further investigation and explanation of certain phenomena of modified resistance in other species, including man, which are likewise supplied with the hemochorialis type of placenta

AUTHOR'S SUMMARY

THE INFLUENCE OF CRYPTORCHIDISM AND OF CASTRATION ON BODY-WEIGHT, FAT DEPOSITION, THE SEXUAL AND ENDOCRINE ORGANS OF MALE RATS V KORENCHEVSKY, J Path & Bact **33** 607, 1930

The seminiferous cells secrete hormones that stimulate metabolism and the thyroid gland Leydig's cells produce hormones that are necessary for the normal growth and development of the adrenals and the hypophysis Hormones stimulating the sexual organs are produced by both the seminiferous and the Leydig cells The development of the sexual organs is influenced by the testicular hormones in correlation with (or through) the endocrine glands, namely, the hormones of Leydig's cells with the hypophysis and the adrenals, the hormones of the seminiferous cells with the thyroid The present data are not sufficient for the elucidation of the possible endocrine function of the Sertoli cells

AUTHOR'S SUMMARY

EXPERIMENTAL CRYPTORCHIDISM OF PIGS V KORENCHEVSKY, J Path & Bact **33** 683, 1930

Two domestic pigs were made cryptorchid and compared with two castrated litter mates The final weight of the cryptorchid pigs was greater than that of the castrated pigs by 13 2 per cent The amount of retroperitoneal fat, but not that of subcutaneous fat, was slightly increased in cryptorchid pigs The cryptorchid pigs looked more hairy than the castrates Histologically, in the cryptorchid testes the seminiferous tissue seemed to have disappeared, the Sertoli's cells were normal, while the hyperplasia of Leydig's cells was greater than in any other species of animals made cryptorchid

AUTHOR'S SUMMARY

THE IRRADIATION OF THE BLOOD IN VITRO ALBERT EIDINOW, J Path & Bact **33** 769, 1930

The irradiation of the blood in vitro with rays emitted by a quartz mercury vapor lamp (infra-red-2,200 angstrom units) produces hemolysis of red corpuscles, destruction of leukocytes, alteration of hemoglobin into methemoglobin alteration in fibrinogen and tissue kinase, delay of coagulation, and destruction of hemolysins, complement, amboceptors and agglutinins present in the blood serum The intravenous injection of "irradiated blood" (infra-red-2,200 angstrom units) increases the hemobactericidal power for from one to three hours after injection, and increases the total number of leukocytes per cubic centimeter The effect is due to the irradiation of the blood corpuscles, since "irradiated serum" and "irradiated lipoids" have no effect The intravenous injection of washed blood corpuscles sensitized with eosin and exposed to visible rays has a similar action to that of defibrinated blood irradiated with rays shorter than 3,300 angstrom units The intravenous injection of from 10 to 20 cc of defibrinated blood intensively irradiated (eighteen hours) is toxic to rabbits and causes death by intravascular clotting In this respect the action is similar to that of the cytotoxins and other endothelial cell poisons

AUTHOR'S SUMMARY

WATER METABOLISM IN SKIN DISEASES J K MAYR, Munchen med Wchnschr **77** 1089, 1930

Water elimination in dermatitis is of considerable extent, and exudation is shifted from renal to extrarenal There is only an apparent retention of sodium chloride in pemphigus, because the excretion of salt also is shifted from renal to extrarenal

AUTHOR'S SUMMARY

LOCAL TISSUE RESPONSE TO IRRITANTS IN ACUTE DISEASES OF CHILDHOOD J BECKER, Ztschr f d ges exper Med **71** 621, 1930

During the course of various acute diseases in children, blisters were produced in the skin by means of cantharides plasters, and the contents aspirated at intervals

for study In all cases, the nonspecific reaction in the skin was found to reflect the variations from time to time in the degree of defense preparedness of the organism in general Observations made during convalescence from pneumonia indicated a marked increase in sensitivity of the defense mechanism, which would explain why even minor infections during that period often cause severe reactions with clinical symptoms The complications of pneumonia in childhood may be due to an allergic state caused by the increased sensitivity of the defense mechanism

PEARL ZEEK

CHOLESTEROL METABOLISM A GAAL, Ztschr f d ges exper Med **71** 690, 1930

An attempt was made to determine the origin of urinary cholesterol and the rôle of the kidneys in cholesterol metabolism Cholesterol was not detected in the urine from healthy kidneys even when there was disturbance of cholesterol metabolism in the organism In many renal diseases, cholesterol was found in the urine, in large quantities in cases of nephrosis, but in small amounts in nephritis and malignant sclerosis The quantity was not influenced by the alimentary intake of cholesterol The kidneys appeared to play no active rôle in cholesterol metabolism

PEARL ZEEK

BASAL METABOLISM AND THE SPECIFIC DYNAMIC ACTION OF PROTEIN IN DIABETES MELLITUS A W ELMER, L PTASZEK and M SCHEPS, Ztschr f d ges exper Med **71** 722, 1930

In the majority of diabetic patients the rate of the basal metabolism was found to be normal An increase of over +20 per cent occurred only in cases complicated by a thyroid toxicosis, and was no key to the severity of the diabetes and could not be attributed to any of the diabetic disturbances The specific dynamic action of protein was usually normal or subnormal The administration of insulin had a varying effect on the rate of the basal metabolism, but rarely lowered it Insulin regularly tended to bring the specific dynamic action of protein toward the normal

PEARL ZEEK

KOLPOKERATOSE, A TEST FOR VITAMIN A W HOHLWEG and M DOHRN, Ztschr f d ges exper Med **71** 762, 1930

When castrated female rats are fed on a diet free from vitamin A, cornified epithelium, called kolpokeratose, appears in the vaginal mucosa, which promptly disappears when vitamin A is added to the diet

PEARL ZEEK

FUNCTIONAL TEST OF THE RETICULO-ENDOTHELIAL SYSTEM Y TAKEDA, Jap J Exper Med **8** 399, 1930

The liver excretion paralleled the disappearance of the dye from the blood stream No critical disappearance of the dye occurred as claimed by Adler and Reimann

Pathologic Anatomy

VISUALIZATION OF THE ESOPHAGUS IN THE DIFFERENTIATION OF HEART LESIONS LEO G RIGLER, Am Heart J **5** 574, 1930

Four cases are described, with autopsy reports on three of them, in which diagnosis before death was aided by visualizing the esophagus In mitral disease, the esophagus was compressed by the enlarged left ventricle and displaced posteriorly In enlargement limited to the right side of the heart, the esophagus was not displaced In absence of the interauricular septum accompanied by mitral disease, the displacement was much less than with mitral disease alone

PEARL ZEEK

LIPOID HISTIOCYTOSIS (NIEMANN'S DISEASE) JAMES M BATY, Am J Dis Child **39** 573, 1930

The sixteenth recorded case of this disease with clinical and pathologic observations is discussed Outstanding features in this, as in previous cases, were the alterations in the circulating leukocytes and the changes in the central nervous system seen at necropsy The leukocytes showed striking vacuolization, and many clasmatocytes were present, in the peripheral circulation The ganglion cells throughout the central nervous system were markedly swollen and vacuolated

J N PATTERSON

DUBOIS' SEQUESTRA OF THE THYMUS GLAND OF NONSYPHILITIC ORIGIN E L BENJAMIN, Am J Dis Child **39** 586, 1930

Most of the Dubois sequestra previously reported were associated with syphilitic changes in other organs, such as osteochondritis, pneumonia alba or interstitial hepatitis In this instance there were no such changes In addition, the history did not show any evidences of a syphilitic infection of the mother She had two normal children, and her Wassermann reaction was negative The structure of the thymus gland was masked by hemorrhagic extravasation, myelopoiesis, increase in the reticulum cells and the absence of Hassall's corpuscles Dubois' sequestra, therefore, cannot always be considered as pathognomonic of congenital syphilis As to the etiology of the thymic sequestra in the present case, an intra-uterine intoxication, possibly associated in some manner with the thyrotoxicosis of the gravid mother, as evidenced by the purpura hemorrhagica, is suggested

AUTHOR'S SUMMARY

CHRONIC SUBDURAL HEMATOMA IN INFANTS DAVID SHERWOOD, Am J Dis Child **39** 980, 1930

A comprehensive review of the literature on chronic subdural hematoma, more commonly called pachymeningitis interna hemorrhagica, is presented The anatomy, pathology and etiology are discussed in detail Nine cases of this condition are presented one of which came to autopsy The diagnosis in the other cases was confirmed by subdural taps This condition should be thought of in every case in which there are convulsions and enlargement of the head The prognosis is good if the cyst is drained and if no intercurrent infection takes place Sequelae occur in a high percentage of cases

J N PATTERSON

ARTERIOSCLEROSIS IN THE YOUNG DIABETIC PATIENT H CLARE SHEPARDSON, Arch Int Med **45** 674, 1930

A group of fifty diabetic patients who had had the disease for at least five years and who were under 40 years of age was studied to determine the incidence of arteriosclerosis as evidenced by the roentgen ray The pathogenesis of vascular disease occurring so commonly in diabetes was also investigated The average age of the entire group was 23 4 years, and the average duration of the disease was 6 9 years Eighteen cases, or 36 per cent, gave roentgenologic evidence of vascular sclerosis The data obtained in this investigation are summarized in six tables Neither the severity of the disease nor the presence of associated pathologic changes, with the possible exception of tuberculosis, can be considered as a pathogenic factor in the development of arteriosclerosis in diabetes The duration of the disease is important only because the causative factor must act over a reasonable period of time before its effects are manifest The average values of blood cholesterol found in this group were markedly lower than those heretofore obtained, and, paralleling the reduction of lipemia, the incidence of arteriosclerosis was found to be greatly reduced The definite lessening of the intensity of the damage resulting from prolonged exposure to diabetes, consequent on the addition of

insulin to diabetic therapy, has resulted in a marked lowering of the average blood lipid content The parallel reduction in the incidence of arteriosclerosis apparently necessitates the assumption that altered fat metabolism is the morbific factor in the development of vascular disease in association with diabetes mellitus

AUTHOR'S SUMMARY

LIPOID NEPHROSIS OF UNUSUAL DURATION WILHELM EHRICH, Arch Int Med **45** 749, 1930

A case of genuine lipoid nephrosis has been reported in which the conditions lasted for about seventeen years and showed clinically, as well as anatomically, all the signs of this disease Several questions concerning lipoid nephrosis have been discussed As at autopsy the kidneys were still much enlarged, it seems to be doubtful whether true lipoid nephrosis leads to contracted kidneys

AUTHOR'S SUMMARY

OCCLUSION OF THE AQUEDUCT OF SYLVIUS WALTER D SHELDON, HARRY L PARKER and JAMES W KERNOHAN, Arch Neurol & Psychiat **23** 1183, 1930

In two cases, occlusion of the sylvian aqueduct was due to proliferation of the subependymal glia, without increase in nuclear elements, but with increase of the fibrillary portions of the glia, some areas showed edema of the glia around the aqueduct and an apparently normal choroid plexus Inflammatory phenomena in the brain, ependyma or meninges were absent The ependymal changes resembled here such as are seen around the central canal of the spinal cord

In two cases, the occlusion was caused by minute glial tumors (astroblastoma and spongioblastoma), while in two other cases the lesion was not confined to the aqueduct but was widespread, involving remote regions of the brain Here belong cases of chronic or subacute ependymitis in which the ependyma of the entire ventricular system is affected, including the subependymal tissue In all the cases studied, an internal hydrocephalus was marked A clinical diagnosis was not always possible Even an anatomic diagnosis could be made only after a careful study, for the changes were sometimes minute, while the clinical manifestations were pronounced

GEORGE B HASSIN

INTRACEREBRAL CALCULI RICHARD C BUCKLEY, Arch Neurol & Psychiat **23** 1203, 1930

The patient, aged 44 at the time of death, had been suffering for twenty-three years from periodic attacks of general weakness and inability to walk, mental anxiety, vascular hypertension and epileptic attacks The latter, numbering from one to five a year, dominated the clinical picture and were preceded by muscular twitchings in the lower part of the left leg Roentgenograms showed two calculi in the right cerebral hemisphere, ventriculography revealed normal ventricles Death occurred suddenly, caused, as the necropsy showed, by a hemorrhage (3 cm in diameter) in the right cerebellar dentate nucleus, one smaller focus was found in the basilar portion of the right side of the pons The stones were located in the right subcortex, near the walls of the right lateral ventricle, one in the frontoparietal area, just above the corpus callosum, the other near the wall of the occipital horn The larger stone lay within a cavity the walls of which consisted of connective tissue bordered outside by proliferated astrocytes The blood vessels, except for two small vessels in the pons, and the meninges, were normal

The author considers the calculi to have been the result of deposits of lime salts in an old focus of hemorrhage or degeneration, he does not hold them responsible for the clinical manifestations which thus could hardly have been benefited by their removal

GEORGE B HASSIN

ACUTE SACCULATION OF THE UTERUS W FLETCHER SHAW, J Obst & Gynæc Brit Emp **37** 72, 1930

Fletcher reports a case of uterine sacculation occurring in the fundus between the fallopian tubes The patient presented symptoms of three months' pregnancy plus a cystic tumor extending above the uterus to the umbilicus The sacculated cavity contained the fetus and amniotic waters, and the uterus proper the placenta Fletcher believes that the sacculation occurs at the point of union of the two Mullerian ducts, which represents a weak spot Only three other cases of this sort of sacculation are reported in the literature

A J KOBAK

CHEMICAL STIMULATION OF EPITHELIAL CELLS IN LUNGS J S YOUNG, J Path & Bact **33** 363, 1930

Active proliferation in the epithelial cells lining the marginal alveoli of the lung of the rabbit can be produced by the intrapleural injection of solutions of various electrolytes The epithelial reaction is determined almost exclusively by the nature of the cation, the anion playing a negligible part The alkali metals, lithium, sodium and potassium, and the alkaline earth metals, magnesium, calcium and strontium, are effective only in relatively strong solution, ranging from three-fourths normal to tenth normal, the latter are more potent than the monovalent series The trivalent metals, aluminum, lanthanum and iron, are more efficient than the bivalent metals of the preceding group, being effective in twentieth normal solution Higher concentrations of aluminum chloride (e g, three-twentieths normal) are liable to fail in the production of hyperplasia, owing, it would seem, to the presence of an excess of the reagent The heavy metals, copper, silver, zinc, cadmium, mercury and lead, relatively weak solution, ranging from hundredth normal to thousandth normal occasion active proliferation The order of their efficiency — mercury > silver > copper > cadmium > lead > zinc — indicates that a periodic relationship may exist between the biologic properties of the metals and their atomic weights Generally speaking and subject to certain modifying circumstances, it is suggested that their capacity to produce proliferation is inversely proportional to their solution pressure Each salt possesses an optimum concentration that seems to be most favorable to the onset of proliferation, and any considerable excess of the reagent is liable to interfere with the progress of the reaction Certain principles of physical chemistry are enumerated, and it is emphasized that a remarkable parallelism prevails between the several circumstances that regulate the precipitation of negative charged colloids, on the one hand, and the biologic processes of epithelial hyperplasia on the other It is recalled that the natural adjustment of the hydrogen ion concentration of the tissue fluids in the living animal predisposes the colloids entering into the constitution of the cell membranes to assume a negative charge The significance of these observations is discussed, and a hypothesis is formulated that a precipitation of the colloids of the cell membrane is an essential phase in the sequence of changes that culminate in cell division

AUTHOR'S SUMMARY

ENDOMETRIOMA OF THE CRURAL REGION LAROYENNE, MARTIN, MICHON and MEYSSONNIER Gynec et obst **21** 97, 1930

Endometrioma in the crural region is rare The patient, aged 41, had on the right side a small mass that became painfully enlarged with each menstrual period At operation, this mass was adherent to the skin and to the femoral and internal saphenous veins The mass contained typical endometrial-like tissue

A J KOBAK

VOLVULUS OF UTERINE ADNEXA LOUIS MICHON Gynec et obst **21** 103, 1930

Michon bases his report on a study of five cases three tubal, two tubo-ovarian and one an ovarian torsion The tube or adnexal tissue involved showed marked

circulatory disturbance with infarction or accumulation of blood There was a moderate plastic peritonitis The tube and ovary on the opposite side were not involved The resulting pain was dependent less on the degree of torsion than on the extent of the circulatory changes in the affected tissue A J Kobak

THE EPITHELIAL CELLS OF THE NEUROHYPOPHYSIS N ORLANDI, Arch ital di anat e histol patol **1** 1, 1930

The basophil cells of the posterior lobe of the human hypophysis are described fully on the basis of many observations These cells are traced to the hypophyseal cleft and the ducts of the pars intermedia, which is regarded as an independent structure

MALIGNANT LYMPHOGRANULOMATOSIS OF BONES R MATZIANI, Arch ital di anat e histol patol **1** 31, 1930

In the case described extensive lesions in the skeleton were due to direct localization and not to extension from adjacent organs

ANOMALOUS COMMON BILE DUCT G FILIPPINI, Arch ital di anat e histol patol **1** 97, 1930

The common duct ended in the pylorus

MALFORMATION OF LEFT OLFACTORY BULB AND PEDUNCLE E E FRANCO, Arch ital di anat e histol patol **1** 105, 1930

The left bulb and peduncle were replaced by a cyst containing a clear, colorless fluid The wall of the cyst contained glia tissue

SARCOSPORIDIOSIS OF THE HEART G SCAGLIA, Arch ital di anat e histol patol **1** 156, 1930

In oxen and sheep in the slaughter house at Cagliari, sarcosporidiosis of the heart, especially of the bundle of His, is frequent Only about fifteen cases of myocardial sarcosporidiosis have been noted in man From his study of the bundle of His when invaded by *Sarcosporidia* the author concludes that its function depends on its nervous elements

INFARCTION OF UTERUS F LISI, Arch ital di anat e histol patol **1** 250, 1930

In an old marantic woman there was infarction in the posterior wall of the uterus due to thrombosis of the arterial branches

PERITONEAL ADHESIONS O DIEBOLD, Arch f klin Chir **158** 737, 1930

Peritoneal adhesions were found in 232 of 700 necropsies Adhesions become more frequent as age advances, and the incidence is about the same in the sexes In 106 of the cases with adhesions, no changes were present in the viscera to explain their nature Of the remaining 126 adhesions, 61 were about the gall-bladder, 22 in the lesser pelvis, 20 in the gastric zone, 13 about the appendix and 10 in the duodenal area

THE EFFECTS OF CHOLESTEROL INTRODUCED INTRAVASCULARLY G SEEMANN, Beitr z path Anat u z allg Path **83** 705, 1930

Seemann presents a study of the morphologic changes that resulted from the intravascular injection of colloidal cholesterol He compares these changes with the generalized lipoidosis that follows the feeding of cholesterol and the localized granuloma that follows the local injection of the substance The material used was a finely dispersed sol that contained 25 per cent of pure cholesterol As much as 20 cc of a 30 per cent dilution of the colloidal preparation could be safely introduced intravascularly, whereas smaller doses of the usual coarsely dispersed

suspension of cholesterol were usually immediately fatal In acute experiments, three rabbits and two dogs received the material intravenously, in two rabbits the injection was made into the carotid and the femoral artery, respectively, and in one rabbit into the portal vein In chronic experiments lasting about a month, two rabbits received the cholesterol sol intravenously in repeated doses, the total dosage being 12 and 14 Gm, respectively, four rabbits were fed a mixture of cholesterol and lecithin, and one rabbit received repeated intraperitoneal injections of the colloidal cholesterol Following intravenous injection, the cholesterol was rapidly removed from the circulation by the capillaries of the lung In dogs, twenty hours after a single intravenous injection of cholesterol the latter had already largely disappeared from the lungs and was present in the capillaries and bile ducts of the liver and in the kidneys as cholesterol casts When cholesterol was injected into an artery or portal vein, a slight deposition of the cholesterol was noted in the regional capillaries, but most of the material was again removed by the capillaries of the lung, an observation that the author interprets as evidence of an elective and selective filtration on the part of the capillaries of the lung Repeated intravenous injections caused marked proliferative reaction on the part of the lung Capillary emboli of cholesterol led to an obliterating endovasculitis and to proliferation of the septal tissues, resulting in foreign body granulomas containing cholesterol and cholesterol esters From the lungs, the cholesterol was removed in part by large cells, termed alveolar epithelia, that were free in the pulmonary alveoli In no instance did the intravascular introduction of cholesterol lead to generalized lipoidosis

O T SCHULTZ

ALEUKEMIC RETICULOSIS E UEHLINGER, Beitr z path Anat u z allg Path **83** 719, 1930

Accepting Aschoff's delimitation of the reticulo-endothelial system, the author presents a case that he interprets as a diffuse hyperplasia of the reticulum cells of that system The hyperplasia was not associated with any changes in the circulating blood that could be ascribed to the presence in the blood of the proliferated cells The patient was a man, aged 52, in whose case a diagnosis of tuberculosis of the larynx had been made two years previously Death occurred two days after his final admission to the hospital and was due to a perforated gastric ulcer and peritonitis The spleen was enlarged to 1,930 Gm and the liver to 2,600 Gm The lymph nodes throughout the body were moderately enlarged The enlargement of the spleen and lymph nodes was due to hyperplasia of the reticulum cells, which had largely replaced the lymphoid elements of the tissues A similar condition was present in the bone-marrow Enlargement of the liver was due in part to fatty change of the liver cells and in part to interlobular aggregations of large polyhedral cells, held to be proliferated Kupffer cells The author reviews the small number of previously reported cases of reticulo-endothelial hyperplasia He divides such hyperplasias into two main groups In one group, termed reticulosis, the proliferating elements are reticulum cells In the other group, termed endotheliosis or reticulo-endotheliosis, the hyperplasia involves the reticulo-endothelia The reticuloses are further subdivided into hyperplasias with differentiation of the cells, those in which the proliferated cells exhibit storage of ingested material, those in which the proliferation is the result of stimulation of the protective functions of the cells by infection and those in which the hyperplasia is atypical and may lead to the formation of hematoblastic cells According to their etiology, the reticuloses are divided into those in which the hyperplasia is due to storage, those in which it is due to infection, the spontaneous hyperplasias, and the dysplastic forms that are to be included among the mesenchymal neoplasms Reticulum cell hyperplasias that are the result of reaction to infection occur most frequently in childhood The author's own case and other reported cases lend no support to the view that the monocytes may be derived from the reticulo-endothelial system In the author's case, in which tuberculosis was also present, the tuberculous process presented an atypical histologic picture in the hyperplastic lymph nodes, in that exudation and caseation were absent

O T SCHULTZ

EFFECT OF POTASSIUM SALTS ON CELL PROLIFERATION G MEYER-DORKEN, Beitr z path Anat u z allg Path **83** 747, 1930

The experimental work, carried out under the direction of Leupold, is a continuation of the latter's study (abstr, ARCH PATH **9** 924, 1929) of the effects of certain salts and organic compounds on the regeneration of tissue in the healing of wounds The purpose of the present work was a study of the effect of inorganic salts in promoting local growth of uninjured tissues A variety of inorganic potassium salts was used in dilutions to 0 00001 per cent and ten millionth molar In such high dilutions, the salts were probably completely dissociated Alanine, glycocoll and leucine were used as controls Each substance was injected in a single dose of 0 5 cc into the subcutaneous fat between the scapulae of a white mouse In from four to five days, sometimes seven days, the tissues were removed for histologic study

The inorganic potassium salts caused proliferation of the endothelia of the tissue spaces of the adipose tissue The proliferation resulted in the formation of organoid, glandlike structures The stimulation of growth is held to be the action of an ion and not of a salt, both anions and cations apparently taking part in the effect

O T SCHULTZ

LYMPHOGRANULOMATOSIS OF THE LUNG H WEBER, Beitr z path Anat u z allg Path **84** 1, 1930

Lymphogranulomatosis in which the lung is alone or predominatingly involved is difficult of clinical or gross anatomic diagnosis It is a rare condition, the few reported cases of which are briefly reviewed by the author Wohlwill divided pulmonary lymphogranulomatosis into three types a form in which the involvement begins in a bronchus, spreads along the bronchial tree, surrounds the bronchi by a zone of granulomatous tissue, and simulates bronchogenic carcinoma, a form in which multiple nodules of variable size are scattered throughout the lung parenchyma, the gross appearance being that of metastatic tumor of the lung, and a form in which the lung is invaded by continuity of the process from the lymph nodes of the hilus Weber presents a clinical, gross anatomic and histologic study of seven cases of Hodgkin's disease with marked involvement of the lung In three of the cases, the process was limited to the lungs and the immediate lymph nodes, in four cases, the process was generalized, but the lungs were the seat of the most marked change In one of the cases of the first group, the localization was chiefly peribronchial In the remainder, multiple lesions of variable size were present throughout the lung In no case did the process appear to be secondary to involvement of the lymph nodes of the hilus The author postulates a possible entrance of the causative agent by the respiratory path An associated pulmonary tuberculosis was present in two cases In one case, in which no evidence of tuberculosis could be detected, the lung contained two large cavities that communicated with the bronchial system Weber believes that the cavities resulted from necrosis and softening of lymphogranulomatous tissue The age of the seven patients whose cases are reported varied from 24 to 73 years, most of the patients being of the third decade Only two of the patients were women A correct clinical diagnosis of lymphogranulomatosis was made in only two cases, in one of these on the basis of the histologic examination of a removed superficial lymph node The usual clinical diagnosis was tuberculosis or neoplasm of the lung The duration of the disease was from two to eight years, the longest being seven and eight years, respectively, in two patients who had received intensive roentgenotherapy for supposed tumor of the lung Growth of the tissue in and along the walls of the bronchi leads to marked narrowing of the lumen In one patient, necrosis of the tissue resulted in a fistulous connection between the esophagus and the trachea The pulmonary lesions may be surrounded by a zone of desquamative or catarrhal pneumonia like that often associated with tuberculosis of the lung Intimal lesions of histologically specific tissue, similar to intimal tubercles, suggest the spread of the process by the blood stream As a rule, the blood vessels of the involved tissue were invaded from without

O T SCHULTZ

HUMAN HEMOCHROMATOSIS P SIEBERT Beitr z path Anat u z allg Path 84.111, 1930

Three cases of hemochromatosis are briefly described and discussed All revealed in striking degree the marked pigmentation of the synovia of the joints described by von Recklinghausen in 1889 Especially emphasized are the pigmentation of the epithelial cells of the hypophysis and the presence in the gallbladder in each of the three cases of small pigment calculi that had a high copper content In striking contrast to the pigmentation of the epithelia of organs with excretory or secretory function was the slight pigmentation of the most important of the excretory organs the kidney Concerning a possible relationship of copper to the causation of the condition the author notes that all of his patients came from villages engaged in the wine-producing industry in which copper salts are widely used

O T SCHULTZ

THE OBLITERATING ENDARTERITIS OF GANGRENE DUE TO EXPOSURE TO COLD G B GRUBER Beitr z path Anat u z allg Path 84·155, 1930

In this publication, as in a previous one Gruber disagrees with Buerger s conception of the histology of the condition to which the latter has given the name thrombo-angiitis obliterans The disagreement concerns chiefly two points the histologically specific character of the vascular lesion and the relation of thrombosis to the lesion Since the gangrene of Buerger s disease occurs usually in persons of an earlier age than does the gangrene of senile arteriosclerosis Gruber prefers to term it endarteritis obliterans of younger persons He believes that the true nature of the arterial lesion is to be learned from a study of the smaller arteries rather than from that of the larger ones, and he believes that a study in younger persons of the terminal arteries of the nongangrenous digits of extremities that have been amputated for gangrene following exposure to cold may throw light on the changes that occur in arteries that have been free from arteriosclerotic change He presents a report of a histologic study of such vessels The process is a proliferative inflammatory reaction of the subendothelial tissue that leads to marked thickening of the intima Thrombosis, if present at all is a terminal manifestation and never a primary one The elastic lamella reveals little alteration in the early stages of the vascular lesion In the later organization of the latter new elastic fibrils are formed and grow out into the proliferated intimal tissue Gruber holds the lesion described by him to be a productive endarteritis obliterans of the kind to which Friedländer gave the name arteritis obliterans in 1876 and identical with the obliterating endarteritis described by Winiwarter in 1879 in a case belonging to the group now known as Buerger s disease Neurovascular disharmony in the sense of Ricker may be a factor in the proliferative reaction of the endarteritis due to cold as it may also be in the racial constitutional peculiarity that seems to be present in Buerger s disease

O T SCHULTZ

MORPHOLOGY AND PHYSIOLOGY OF THE TERMINAL CIRCULATORY SYSTEM R MIDSUNO Beitr z path Anat u z allg Path 84.183 1930

The terminal circulatory system the largest and most important part of the blood vascular system, consists in the terminology of Midsuno, of the arteriole the precapillary, the arterial capillary the venous capillary the postcapillary and the venule His observations, chiefly on the capillary part of this system, were made in the living animal in the unstained and in the vitally stained condition For vital staining trypan blue was used To study the movement of the circulating blood, intravascular injections of carmine suspensions were made The tongue of the frog was found to be the most satisfactory object for study For observation of the circulation of the warm-blooded animal the mesentery of the rabbit served best The mesentery of the rat was less useful, and that of the guinea-pig and that of the mouse were unsatisfactory because of the fat contained in the mesentery The animals were narcotized with ethyl carbonate (urethane) In the

arteriole, the layer of adventitial connective tissue that surrounds the artery becomes thin enough to permit the cellular constituents of the wall to be seen The precapillary consists of an endothelial wall with a very thin layer of supporting connective tissue The arterial capillary has no such supporting tissue The lumen of the venous capillary has a zigzag outline in optical section, due to indentations and elevations of the inner surface of the endothelium The same kind of lumen is present in the postcapillary, which has a very thin layer of connective tissue about the endothelium The irregularity of the endothelial surface of the venous capillary and postcapillary is an important factor in the mechanics of the circulation through this part of the system The venule, like the arteriole, has a distinct but transparent adventitial layer Direct capillary anastomoses occur in small numbers between artery and vein These correspond to the derivative canals of Hoyer, but have no structural peculiarities and do not transmit an appreciable part of the blood In the resting tissue, some of the capillaries are contracted and others are dilated In either case, they may be filled with blood or only with plasma. The author believes that endothelial cells may lose their connection with the capillary wall and may appear in the circulating blood Cells closely applied to the outer surface of the capillary endothelium take no part in the movements of the capillary, the identity of such cells with Rouget cells was not investigated by the author Active movements occur only in the arterial portion of the terminal system, namely, in the arteriole, the precapillary and the arterial capillary These movements consist of automatic, spontaneous, ameboid movements of the endothelium The so-called contractility of the capillaries is due to a combination of ameboid movements of the endothelium with swelling of its cells Epinephrine in proper concentration causes contraction of the arterial portion of the terminal system by evoking the active movements of the endothelium described The velocity of the blood flow through the terminal system varies from time to time and in different vessels of the same region The angle at which the branches are given off increases progressively from arteriole to capillary, being often greater than 90 degrees in the latter This facilitates reflux of blood from the capillaries to the arterioles and causes a to and fro movement of the blood frequently seen in the terminal system The velocity of the corpuscles in the capillaries varies with each corpuscle The author is convinced that a stream of pure plasma may occur in the capillaries under physiologic conditions Under cessation of movement of the blood in the terminal system, the author recognizes stoppage of flow of red and of white cells, stasis of plasma, stasis of platelets and stasis of true red and of white cells Stoppage of flow of red and of white cells differs from stasis of red and of white cells in that in the former the outlines of the red or of the white corpuscles can be distinctly seen, whereas in stasis the blood within the capillaries has a homogeneous red or white appearance Stasis was rarely observed under physiologic conditions The regulatory mechanisms of the terminal circulation consist, according to Midsuno, of the ameboid movements of the endothelium, spindle-shaped dilatations of the arterial capillaries, the derivative capillaries, the distensibility and elasticity of the walls of the vessels, the independent movement of corpuscles and of plasma and the angle at which the capillaries are given off

O T SCHULTZ

ROENTGEN ANEMIA C WEGELIN, Beitr z path Anat u z allg Path **84** 299, 1930

A low grade of anemia with slight leukopenia is not uncommon in workers with roentgen rays Severe anemia is rare Wegelin adds a case to three previously reported fatal cases of roentgen ray anemia and nine of radium anemia The condition occurred in a physician, aged 43, who had been active for ten years as a roentgenologist Three months before his death, he began to complain of fatigue, palpitation and dyspnea on exertion Two weeks before death, he had a severe hemorrhage from the nose and was admitted to the hospital His erythrocyte count was 2,000,000, with a color index of 0 78 The leukocyte count was 1,500,

with a relative lymphocytosis and moderate eosinophilia Three days before death, the red cell count had dropped to 800,000 and the leukocyte count to 900 The blood at this time contained many nucleated red corpuscles, chiefly megaloblasts Platelets were few The anemia was of the secondary aplastic type The essential postmortem anatomic observation was exhaustion or lack of regenerative activity of the bone-marrow The testes revealed marked, and the lymphoid tissues slight, atrophy Hemosiderosis noted in the spleen and bone-marrow was ascribed to damage to the reticulo-endothelial system The reported cases of radium anemia have shown greater regenerative capacity of the bone-marrow than have the fatal cases of roentgen anemia

O T SCHULTZ

BLOOD VESSELS IN TUBERCLES W PUTSCHAR, Beitr z path Anat u z allg Path **84** 321, 1930

Contrary to the usually accepted view that the tubercle is an avascular lesion, Putschar found newly formed capillaries to be present in a fairly large percentage of the lesions examined histologically by him They often lie beside giant cells, and he believes that a part at least of the giant cells may be formed from the endothelium of such vessels Vessels may be present in encapsulated caseous tubercles and may be absent in young cellular lesions In tuberculous granulation tissue, the vessels may lie next to areas of caseation

O T SCHULTZ

ANENCEPHALY AND HYPOPLASIA OF THE SUPRARENAL GLANDS G B GRUBER, Beitr z path Anat u z allg Path **84** 335, 1930

The frequent association of anencephaly with hypoplasia of the suprarenal glands led Gruber to make a study of the topography of these glands in a series of anencephalic monsters The suprarenal glands were found to be hypoplastic in twenty-five of twenty-six examples of anencephaly studied In the twenty-sixth case the suprarenal glands could not be found In a case of hemicrania with cerebral hernia, the suprarenal glands were abnormally small In two examples of occipitocervical craniorachischisis, the suprarenal glands were of normal size Hypoplasia of these glands were frequently associated with malposition, the left often lay behind the vena cava, and the right had a position more ventral to the kidney than normal In five of the anencephalic monsters, the cranial and vertebral deformities were associated with ventral abdominal hernia Abnormality in the size and shape of the abdominal cavity due to the deformity caused by defective vertebral closure is probably a factor in this relatively high incidence of ventral hernia in anencephaly In the five examples of ventral hernia, the kidneys had a position higher than normal, the upper pole being situated high up under the diaphragm The diaphragm was closed in each instance, an observation that is not in accord with the theory of Kleine that high position of the kidneys may be a cause of diaphragmatic hernia

O T SCHULTZ

CONGENITAL ABSENCE OF OVARIES WITH INFANTILISM R ROSSLE and J. WALLART, Beitr z path Anat u z allg Path **84** 401, 1930

Rossle and Wallart precede the detailed presentation of a case of congenital absence of the ovaries with infantilism by a discussion of the criteria that must be met before absence of the ovaries may be accepted as congenital, originating in fetal life Following Morgagni's first careful description of the condition, many reports appeared in the earlier literature These cases cannot be accepted because the absence of ovarian tissue was not verified microscopically With the development of histology, the subject disappeared from the literature Only during the past decade have there again appeared reports of congenital absence of the ovaries verified by careful microscopic examination The authors accept as valid only the cases of Olivet, Robert Meyer and Randerath, reported in 1925, the case of Schurmann reported in 1927 and their own case They also accept Morgagni's case

because of the classic completeness of his description They leave out of consideration clinical cases of infantilism supposedly due to absence of the ovaries Their patient was a woman, aged 30 years, whose death was due to a gliosarcoma of the cerebellum She had ceased to grow at 8 or 9 years of age Mentally, she had been normal At necropsy, the body was 133 5 cm long The size of the body and the proportions of the body and of the internal organs were those of a girl before puberty The breasts were not developed, and axillary and pubic hair was absent The internal labia were absent, but otherwise the internal and external genitalia were like those of a girl 11 years old, except that the ovaries were absent Careful microscopic examination of the adnexa, uterus and vagina failed to reveal any ovarian tissue The rete ovarii was present This contained well differentiated tubules and others that resembled the tubules of the primitive kidney With the latter were tubular structures that had the morphology of ducts of the epididymis and others similar to the hydatid of Morgagni At one point, tubules of primitive renal origin formed an adenomatous nodule, and two areas of misplaced cortical suprarenal tissue were encountered The authors conclude that theirs is an example of true congenital absence of the ovaries, and that the infantilism was due to this defect The embryonic period at which the defective development first manifested itself or its cause could not be determined They consider a disappearance of the primitive sex cells in early fetal life most probable The fact that the rest of the genital system was normally developed indicates that the development of the rest is not dependent on the ovary, these sexual characters are predetermined in the zygote The rete ovarii and the rete testis are derivatives of the primitive kidney

O T SCHULTZ

INFILTRATIVE GROWTH OF PLACENTA WITH RUPTURE OF UTERUS M STAEMMLER, Beitr z path Anat u z allg Path **84** 460, 1930

Staemmler asks the question whether infiltrative and destructive tissue growth such as is characteristic of malignant neoplasms and such as is sometimes seen in nonmalignant form in the downgrowth of epithelium into chronically inflamed connective tissue, is always the expression of an increased and abnormal growth activity of the invading tissue, whether it may not at times be the result of lessened resistance of the tissue into which the infiltrating tissue grows In answer to this question, he gives a microscopic description of the placenta and uterus of a patient who had spontaneous rupture of the uterus due to invasive growth of the placenta The patient, who was 32 years old, had had a normal delivery ten years previously At the end of the second month of the pregnancy that resulted in death, uterine bleeding followed the lifting of a weight This was controlled, and she was able to resume her work Toward the end of the fourth month of pregnancy, while at work, she suddenly fell to the floor with intense abdominal pain Immediate laparotomy revealed a ruptured uterus, with the fetus in the abdominal cavity Supracervical amputation of the uterus failed to save the life of the patient In the microscopic examination of the specimen, it was seen that chorionic tissue, in the form of intact villi, of syncytial masses and of masses of cells of the Langhans layer, had invaded and penetrated the uterine wall The invading chorionic epithelium did not appear malignant Only where it came in contact with the uterine muscle did it exhibit greater proliferative activity, and here without any change in cell type The most striking feature, and the one on which Staemmler lays greatest stress in his interpretation, was the absence of any decidual reaction This characteristic Staemmler's case shares with the others reported in the literature Also common to all the reported cases of infiltrative growth of the placenta is the fact that the condition has been noted only in multipara, never in primigravida According to Staemmler, the decidual reaction is the mechanism by which the maternal tissues restrain the histolytic activity of the chorionic epithelium When this reaction is absent, as it is in placenta destruens, the uterine wall is invaded, not because of increased growth activity of the epithelium, but because of the lessened resistance that the maternal

tissues oppose to the chorionic epithelium The failure of the normal decidual reaction to occur is not due to absence of the hormone that incites such a reaction in the tissues, since decidual reaction is usually present in some parts of the decidua, although it is absent at the placental site In Staemmler's case, such a reaction was noted in the endometrial stroma about glands embedded in the uterine muscle and in the subserous tissues Staemmler believed that the failure of the decidual reaction to occur was the result of change in the endometrium

O T SCHULTZ

EFFECTS OF IRRADIATED AND NONIRRADIATED ERGOSTEROL ON ARTERIES W HEUBNER, Beitr z path Anat u z allg Path **84** 559, 1930

A number of investigators have described toxic effects caused by the administration of irradiated ergosterol in large doses to animals, especially rabbits Among the effects produced is calcification in various organs and particularly in the arteries It is also known that the feeding of cholesterol causes arterial changes The question arises whether the effects brought about by irradiated ergosterol are in part effects of sterol, similar to those caused by cholesterol In comparable feeding experiments, ergosterol, irradiated ergosterol and cholesterol were fed to rabbits of a strain that had previously been found susceptible to the action of irradiated ergosterol The latter substance caused degenerative changes in the aorta with marked calcification of the lesions Cholesterol, which was known to be free from ergosterol, caused atherosclerosis of the aorta without calcification Nonirradiated ergosterol had no effect on the aorta Some of the pathologic effects of irradiated ergosterol have been described as reversible, in that they disappear after the administration of the material is stopped The arterial calcification caused by irradiated ergosterol was found by Heubner to be permanent

O T SCHULTZ

Microbiology and Parasitology

CHRONIC MENINGOCOCCUS SEPTICEMIA HARRY VESELL and JOSEPH BARSKY, Am J M Sc **179** 589, 1930

Chronic meningococcus septicemia (chronic meningococcemia) was first described in 1902 Its rarity is possibly more apparent than real (Marie) Scant notice given to this condition is in part due to the title "Epidemic Cerebrospinal Meningitis," which tends to direct all concern to the meninges and ordinary form of meningococcus meningitis Chronic meningococcemia is characterized by a rather sudden onset with headache, intermittent fever, joint symptoms and a typical erythematous skin eruption There is little prostration and the course is long, lasting from two to three months The outcome is usually more favorable than in other septicemias Meningitis is absent in a large number of cases When it does occur it comes on late in the illness and apparently does not unfavorably influence the outcome Other complications are considered Early diagnosis is difficult, especially because the blood culture is frequently sterile until late in the disease The treatment is with specific serum A case is reported

AUTHORS' SUMMARY

INOCULATION MALARIA SEXUAL AND ASEXUAL STRAINS NICHOLAS KOPELOFF, Am J M Sc **179** 800, 1930

The malarial course and therapeutic results in 123 patients (88 females and 35 males) inoculated with a sexual strain were identical with those noted in over 350 patients inoculated with an "asexual" strain of malaria After seven months, the sexual strain of malaria began to lose its capacity to produce gametocytes During the succeeding nine months, this was found to be much more striking in female than in male patients Approximately one third of all the female patients

having malarial parasites failed to reveal the presence of any sexual forms of the plasmodium The sexual strain of malaria becomes biologically adapted to its host on repeated human passage, as evidenced by its increasing failure to produce gametocytes

AUTHOR'S SUMMARY

CYTOPLASMIC INCLUSIONS PRODUCED BY THE SUBMAXILLARY VIRUS E F PEARSON, Am J Path **6** 261, 1930

The cytoplasmic inclusions that are developed in the duct cells of the submaxillary glands of guinea-pigs as a result of the action of the submaxillary virus are formed later than are the nuclear inclusions They are also more restricted in distribution, having been found only in the ducts of the mucous and serous portions of the submaxillary, occasionally in the acini and in the ducts of the parotid, whereas the intranuclear inclusions may, in addition, be produced in endothelial cells, fibroblasts, smooth muscle cells and mononuclear leukocytes The cytoplasmic inclusions are spherical or oval structures, which vary in size from a fraction of a micron to from 6 to 8 microns in diameter In the fully developed state, the average inclusion is about 3 microns in its long axis The inclusions are made up of many much smaller individual particles which are densely packed together Like the cytoplasmic inclusions in other virus diseases, these inclusions are characterized by their relative insolubility in ordinary fixatives They are basophil in reaction and do not contain fat or lipoid in detectable amounts They are, moreover, indistinguishable from certain cytoplasmic inclusions of rare occurrence in human submaxillary glands

AUTHOR'S SUMMARY

MADURA FOOT DUE TO MONOSPORIUM APIOSPERMUM IN A NATIVE AMERICAN DOUGLAS M GAY and JAMES B BIGELOW, Am J Path **6** 325, 1930

A case of Madura foot due to *Monosporium apiospermum* is reported, and the literature on pathogenic *Monosporia* is reviewed Although in the United States Madura foot is a rare disease, it should be considered in chronic osteomyelitis of the foot. It is usually easy to find the grains, and their presence is pathognomonic, but the identification of the infecting organism requires microscopic and cultural study Diagnosis by biopsy is impossible, unless a grain is included in the section, because the lesion is not histologically characteristic It may be a simple chronic osteomyelitis, or it may resemble tuberculosis or occasionally simulate syphilis The patient with Madura foot, especially of the yellow-grain variety, should be started on iodine therapy, unless there is some contraindication for the drug, because of the well known response of *Actinomyces* and *Sporotrichum* infections to iodine Should the organism prove to be some other type, amputation is the only treatment that promises success

AUTHORS' SUMMARY

THE CALCIFICATION OF TUBERCLES BY MEANS OF IRRADIATED ERGOSTEROL TOM DOUGLAS SPIES, Am J Path **6** 337, 1930

The administration of repeated large doses of activated ergosterol to rabbits suffering from acute tuberculosis causes extensive deposition of calcium salts within the caseous lesions The administration of a single large dose produces no demonstrable changes It is suggested that a diet with high content of vitamin D might possibly be useful in some cases of pulmonary tuberculosis

AUTHOR'S SUMMARY

TREPONEMATOSIS IN YUCATAN GEORGE C SHATTUCK and KENNETH GOODNER, Am J Trop Med **10** 177, 1930

Clinical examinations and serologic tests in a series of 271 cases show that among the Maya Indians near Chichen Itzá in Yucatan syphilis is either rare or so exceedingly mild that it fails to produce clinically recognizable lesions or

positive serologic reactions Syphilis is relatively common among neighboring people of mixed Indian and white blood No yaws was recognized clinically in Yucatan and, had it been present among the Indians, positive Kahn tests would have been obtained

AUTHORS' SUMMARY

THE BACTERIOLOGY OF LYMPHANGITIS ASSOCIATED WITH ELEPHANTOID FEVER IN PORTO RICO JENARO SUAREZ, Am J Trop Med **10** 183, 1930

In a study of sixty cases of lymphangitis associated with elephantoid fever selected by the author as being typical of the disease, bacterial infection was the primary etiologic factor The micro-organism usually involved was a hemolytic streptococcus Experience shows that the streptococci are usually found in pure cultures when these are taken directly from the foci of infection, but cultures taken from the subcutaneous tissue are generally negative Filariasis as a factor in the production of elephantiasis is not as important as was formerly thought

AUTHOR'S SUMMARY

HUMAN RABIES AND RABIES VACCINE ENCEPHALOMYELITIS PETER BASSOE and ROY R GRINKER, Arch Neurol & Psychiat **23** 1138, 1930

A woman, aged 48, received the Pasteur treatment, not because she had been bitten by a dog, but because she handled one in which rabies subsequently developed She received fourteen subcutaneous injections of 2 cc each After thirteen injections, which were always followed by considerable local reaction, weakness of the legs developed, followed the next day by complete paralysis, urinary retention, weakness of the upper extremities and slight respiratory, but no deglutitional, difficulties There was a flaccid paraplegia with the loss of all the tendon, plantar and abdominal reflexes Sensibility was not impaired The temperature rose to 103 F, and the leukocyte count was 25,000 on the date of death The necropsy revealed universal changes in the cord, especially in the cervicodorsal region The anterior horn cells were two or three times their usual size, with complete chromatolysis, their number was markedly decreased and many appeared as shadows There was a perivascular infiltration with proliferated adventitial cells, glial cells and lymphocytes, and the vessels were surrounded by areas of demyelinization In the latter, the axons were broken up and numerous large cells filled with fat were present The areas bordering on the softening were covered with numerous microglia cells and their transitional forms Oligodendroglia cells were swollen and many contained mucin Near the blood vessels, clumps of mucin-like material in grapelike structure were scattered free in the tissue In general, the changes resembled those described in cowpox encephalitis

A man, aged 53, was bitten by a sick dog in the right hand No Pasteur treatment was given A year later rabies developed, followed by death in four days Striking changes of inflammatory nature were found in the medulla, in the rest of the central nervous system the changes were slight, but the ganglion cells were swollen and contained Negri bodies They showed chromatolysis and increase in oligodendroglia cells containing mucin bodies The areas of demyelinization seen in the previous case, with accumulation of fat, were absent

GEORGE B HASSIN

CHEMICAL STUDIES ON THE TOXIN PRODUCED BY B PARATYPHOSUS B (AERTRYCKE TYPE) MAUD L MENTEN and C G KING, J Infect Dis **46** 275, 1930

The toxic fraction precipitated by concentrated acetic acid from a Berkefeld filtrate of B paratyphosus B (Aertrycke type) and partially purified was free from phosphorus and sulphur and on hydrolysis yielded a carbohydrate On intravenous injection, this substance caused a hyperglycemia The fraction precipitated by ammonium sulphate was not hyperglycemic

AUTHORS' SUMMARY

VIABILITY OF THE ORGANISM OF ROCKY MOUNTAIN SPOTTED FEVER WHEN FROZEN ARTHUR G KING, J Infect Dis **46** 279, 1930

The organism of Rocky Mountain spotted fever may be kept alive and virulent in well frozen brain tissue for as long as 321 days For preserving the organism, frozen brain is a superior medium to brain in glycerol in the cold Ninety per cent of 52 cases were positive in comparison with 65 per cent of cases with glycerol By combining several infectious brains and using the frozen subdivided parts of the mixture, infectivity may practically be insured It is possible to keep the strain of Rocky Mountain spotted fever alive in the laboratory by successive transfers of infectious brain frozen over a long period of time

The infectiousness of blood well frozen for one month was retained in 85 per cent of thirteen cases, with a dosage of 5 cc After 95 days' freezing, 7 5 cc of blood proved virulent The viability of the organism of Rocky Mountain spotted fever, as expressed by the infectiousness of various quantities of blood frozen over various lengths of time, is represented graphically

AUTHOR'S SUMMARY

THE INCIDENCE OF BACTERIA IN FOUR HUNDRED TONSIL CULTURES HERBERT MARSHALL COBE J Infect Dis **46** 298, 1930

In 400 tonsillar cultures, staphylococci are the predominating organism The streptococci follow the pneumococci in predominance, with the hemolytic streptococci the predominant members of the group Three per cent of the nonhemolytic streptococci recovered are classed as *Streptococcus cardio-arthritidis*

There appears to be a definite relationship between the type of organism recovered from tonsillar cultures and the age of the patient, streptococci being more common in younger patients (under 11 years of age)

There is a definite seasonal difference in the organisms recovered from tonsillar cultures *B influenzae, B mucosus-capsulatus* and the diphtheroids all are more prevalent in the spring and *Micrococcus catarrhalis* in the fall

AUTHOR'S SUMMARY

FUSOSPIROCHETAL DISEASE OF THE LUNGS PRODUCED WITH CULTURES FROM VINCENT'S ANGINA DAVID T SMITH, J Infect Dis **46** 303, 1930

It seems fair to conclude from these experiments that fusospirochetal disease of the lungs can be caused by the organisms commonly associated with Vincent's angina, and that the pulmonary lesions are probably due to a symbiosis of a spirochete, a fusiform bacillus, a vibrio and a coccus It is quite possible that any of the spirochetes of the mouth and a number of the cocci may replace the ones actually used in this experimental synthesis

AUTHOR'S SUMMARY

MICROBIC DISSOCIATION IN THE ABORTUS-MELITENSIS GROUP OBSERVATIONS ON THE MUCOID FORM WAYNE N PLASTRIDGE and JAMES G MCALPHINE, J Infect Dis **46** 315, 1930

The cultural, morphologic, biochemical and serologic characteristics of a new type occurring in the abortus-melitensis group have been described This has been called the mucoid form No attempt has been made to classify it as an S or an R type

AUTHORS' SUMMARY

BACTERIA OF THE UPPER RESPIRATORY TRACT AND MIDDLE EAR OF ALBINO RATS DEPRIVED OF VITAMIN A R G TURNER DOROTHY E ANDERSON and E R LOEW, J Infect Dis **46** 328, 1930

The bacteriologic study of the nasal cavities and middle ear in seventy-nine albino rats is presented for four groups normal stock rats, vitamin A deficient control animals, rats on vitamin A free ration which developed xerophthalmia and those on a like diet which did not develop the disease Four types of

organisms pathogenic to rabbits were encountered. These are classified as *Staphylococcus aureus*, *Bacillus [illegible]*, *Micrococcus aureus* [illegible] *A* and chromogen *A*. The last two are gram-negative cocci.

It is apparent that the pyogenic gram-negative cocci, especially chromogen *A*, are encountered more frequently in the animals that show the most severe symptoms of vitamin A deficiency. It is believed that these organisms gain a pathogenic hold during the depressed state of their host resulting from vitamin A deficiency.

Evidence is given that cod liver oil protects against bacterial invasion of the nasal cavities and middle ear.

AUTHORS' SUMMARY.

SUSCEPTIBILITY OF MONKEYS, GOATS AND SMALL ANIMALS TO ORAL ADMINISTRATION OF BOTULINUM TOXIN TYPES B, C AND D. J. B. GUNTHER and K. F. MEYER. J. Infect. Dis. 46:335, 1930.

Monkeys (*Macaca [illegible]*) are highly susceptible to the oral administration of botulinum type B toxin. Its susceptibility to the toxin of *C. botulinum* [illegible] type C β is somewhat lower. It is resistant to large amounts of botulinum C α and D toxins when these are given by mouth, although readily immunized when the toxins are injected subcutaneously.

Small laboratory animals have a marked susceptibility to botulinum type B toxin when this is administered by mouth. They are less susceptible to the toxins of types C α, C β and D. The ratio of the lethal dose by injection to the lethal dose by feeding is much larger for type C α, C β and D toxins than for type B toxin.

Goats are extremely susceptible to botulinum type D toxin. Type C β toxin is also fatal when fed to these animals but it is less active than type D. The oral administration of type B and C α toxins to goats had no effect in the dosages tested (33,000 and 50,000 M.L.D. respectively).

AUTHORS' SUMMARY.

THE IDENTITY OF BACILLUS SUBTILIS. H. J. CONN. J. Infect. Dis. 46:341, 1930.

On account of recent confusion in the literature as to the identity of *Bacillus subtilis* the writer has studied into the matter and presents three lines of evidence from cultures obtained from different sources; from a study of the literature, and from a study of hay infusion. It proves that two distinctly different types of bacteria have been going under this name, one a small-spored organism designated in this article the Marburg type, the other an organism with distinctly larger spores, here designated the Morgan type. The latter is the organism studied in a recent paper by M. H. Soule on microbic association. All the evidence gathered by the author however, points to the Marburg type, the small-spored organism, as the true *Bacillus subtilis*.

AUTHOR'S SUMMARY.

CULTURAL AND SEROLOGIC REACTIONS OF LACTOBACILLI FROM THE MOUTH. BEATRICE HOWITT. J. Infect. Dis. 46:351, 1930.

Aciduric rods of the *Lactobacillus* group were isolated from the oral cavity of fourteen persons having either paradentitis or a normal condition of the mouth. These organisms showed variations in colony formation and could be placed in several fermentative groups, but there was no correlation between the two. The fermentative reactions with certain strains were subject to change after a long period.

Positive agglutination occurred with strains of the same fermentative type from one host. A certain correlation between the agglutination and fermentation reactions was noted, although it was not sharply enough defined to distinguish any very definite groups.

Because of the many variations and similar differences in reactions shown by both intestinal and oral aciduric organisms, it does not seem justifiable to separate the two groups.

As suggested by Roos, the term *Lactobacillus acidophilus* should be used to cover a group of biologically related strains variable in their cultural and morphologic characteristics, and not applied to any one specific strain

AUTHOR'S SUMMARY

LESIONS PRODUCED IN RABBITS BY LACTOBACILLUS CULTURES BEATRICE HOWITT and MARTHA VAN METER, J Infect Dis **46** 368, 1930

Joint lesions were produced in rabbits by intravenous injections of living aciduric organisms of the *Lactobacillus* group of both dental and intestinal origin An extensive mucopurulent exudate containing numerous polymorphonuclear leukocytes and macrophages, with occasionally a few gram-positive rods, was induced within the joints, usually in those in the shoulders and the hindlegs, less frequently in those in the forelegs and the hips The cultures showing the highest bacterial counts and having a predominance of the solid disk or Y type of organisms were those giving the most extensive lesions, regardless of the strain or of the source Positive cultures could be obtained usually one week after the last inoculation from the liver, spleen, kidney, lungs and several of the joints Cultures of blood from the heart were rarely positive and then only when the material was removed within a few days after the last injection

Positive lesions could be more readily induced in the rabbit by the slower method of inoculation over a longer period of time than by the more concentrated, rapid method

Subcutaneous or intraperitoneal injection of large quantities of the same aciduric strains into the rabbit produced numerous pyogenic nodules at the site of injection or throughout the peritoneal cavity, usually in the greater omentum, on the liver or the capsule of the spleen, on the diaphragm, or on the wall of the bladder No joint lesions were noticed, nor were they induced by feeding the organisms

Certain of the oral and intestinal strains of lactobacilli are thus found to possess a pyogenic property

It may also be asserted, from the evidence given by Holman's review on focal infections and from that portrayed in the present work, that joint lesions in rabbits are more a function of the circulatory system of the invaded host than of any inherent elective localization of the bacteria involved

AUTHORS' SUMMARY

AN EPIDEMIC OF COLDS, BRONCHITIS AND PNEUMONIA DUE TO TYPE V PNEUMOCOCCI M C SCHRODER and GEORGIA COOPER, J Infect Dis **46** 384, 1930

An epidemic of pneumonia bronchitis and common colds in a children's home is reported The more interesting observations were the explosive nature of the epidemic and the short space of time in which it reached its height, fifty-five patients being admitted to the hospital on the seventh day after the first patients were admitted the extreme infectivity of the organism, the prostration and cyanosis which accompanied the apparently milder cases, and the definite isolation of an infecting organism commonly classified as belonging to group IV of the pneumococcus group, but which in the research laboratory has been definitely determined by one of us to be a member of type V

AUTHORS' SUMMARY

THE RESPIRATORY CATALYSTS OF THE DISEASE-PRODUCING BACTERIA ARTHUR LOCKE and E R MAIN, J Infect Dis **46** 393, 1930

Copper may be an essential constituent of the catalytic principle that orients cellular respiration and synthesis It appears to be especially required in cells and tissues accustomed to survive periods of oxygen hunger, and may reach its highest concentration in the respiratory substance of the anaerobic and spore-forming bacteria The production of toxin by the diphtheria bacillus can be

partially inhibited by reducing the concentration of ionic copper available from its culture medium to a level that still supports normal growth The bacterial toxins may owe their poisonous characters to contents of copper-carrying respiratory substance well adapted to further the peculiarly aerobic or anaerobic respiratory processes of the bacterial cells in which they have their origin, but intolerable to the cells of the more highly organized, less aerobic or anaerobic plant and animal tissues into which they may diffuse

AUTHORS' SUMMARY

THE HEAT RESISTANCE OF THE VIRUS OF POLIOMYELITIS H J SHAUGHNESSY, P H HARMON and F B GORDON, J Prev Med 4 149, 1930

The exact thermal inactivation point of poliomyelitis virus apparently cannot be determined at the present time because there is no accurate method for standardizing the potency of virus preparations The results reported suggest that, when a small amount (2 cc) of a virus of moderate potency is used, the thermal inactivation point is low, about 42 5 C for thirty minutes On the other hand, in one experiment the temperature necessary to produce inactivation was higher than 50 C for thirty minutes due probably to chance variation in the strength of the virus preparation In other similar experiments, a temperature of 55 C for all periods of from five to thirty minutes always produced inactivation of the virus This accords with the results of other investigators When large amounts of a virus of moderate potency were used, the thermal inactivation was 52 5 C for thirty minutes Apparently an increase in the amount of virus injected caused the difference in the effect on monkeys These results suggest that at temperatures slightly above 40 C (42 5) the virus is possibly attenuated or, more probably, that part of the virus is destroyed so that a relatively small inoculum becomes ineffective in producing clinical poliomyelitis Furthermore, as is shown in another paper, virus that is innocuous in a single injection may produce clinical symptoms of poliomyelitis on repeated injections

AUTHORS SUMMARY

A PARATYPHOID-LIKE INFECTION DUE TO MORGAN'S BACILLUS LEON C HAVENS and CATHERINE R MAYFIELD J Prev Med 4 179, 1930

In a series of 49 cases clinically resembling paratyphoid fever, *Bacillus morgani* was isolated from the feces in all cases, from the blood in 6 cases and from the urine in 11 It was the only significant organism in the feces Agglutinins for the strain recovered from each patient were present in his serum in significant titers (from 1 40 to 1 2,560) In 21 of the 22 cases in which more than 1 specimen was obtained, the titer increased during the course of the attack Agglutination tests with other organisms invariably gave negative results Three strains of Morgan's bacillus tested with 537 serums from normal persons and persons with other diseases agglutinated in five instances in a dilution of 1 20 As none of these serums agglutinated any of the strains in higher dilution than 1 20, the high titers observed in our series of cases are apparently the result of a specific reaction Examination of the feces of 2,798 healthy adults showed *B morgani* in only 1 2 per cent All 44 strains from our clinical cases proved virulent for mice, both on intraperitoneal injection and on feeding

AUTHORS' SUMMARY

MENINGOCOCCUS MENINGITIS IN DETROIT IN 1928-1929 JOHN F NORTON and JOHN E GORDON, J Prev Med 4 207, 1930

The present outbreak of meningococcus meningitis in Detroit began in the spring of 1928 and reached its peak in May, 1929 Although a rapid decline in the number of cases occurred during the summer of 1929, the morbidity rate has been considerably above the norm up to the end of 1929

The total number of cases reported from Jan 1 to Dec 31 1929, was 867 and the number of deaths was 430—a fatality rate of 50 per cent. This percentage is higher than has been observed in most outbreaks since the introduction of modern

methods of treatment (drainage of the spinal canal and treatment with serum There is no reason to believe that our patients received treatment later than those in other epidemics It must therefore be concluded either that the strain of meningococcus encountered was of unusual virulence or that the therapeutic serums available were not specific against this strain

A study of the age, sex and color distribution of cases shows that a high fatality occurred among infants and adults, that sex was of little importance and that the colored population accounted for more than its share of cases

The distribution of cases in Detroit indicates that congestion of population was a minor factor in the outbreak

PARATYPHOID, PROTEUS AND RELATED ORGANISMS IN HEALTH AND IN MISCELLANEOUS INTESTINAL DISORDERS OF MAN JOSEPHINE MCBROOM, J Prev Med **4** 239, 1930

Fecal specimens were examined from twenty-nine healthy persons and ninety-seven persons ill with a wide variety of intestinal disorders Paratyphoid organisms were not found in any of the specimens Proteus bacilli were found in specimens from one of the healthy persons and two of the ill persons Organisms related to the paratyphoid and proteus bacilli (paracolon, paraproteus and paratyphoid-like) were found frequently in feces from normal persons (41 per cent), from ulcer patients (40 per cent) and from persons with other intestinal disorders of well defined origin (37 per cent) In cases of obscure origin (diarrhea, constipation and bowel distress), these intermediate organisms appeared rarely (in 4 5 per cent of the cases) Green-producing pinpoint colonies, perhaps identical with Bargen's diplococci, were found in 45 per cent of the seventy-six patients examined for these organisms

AUTHOR'S SUMMARY

THE VISIBLE EFFECT OF CASTOR-OIL SOAP ON CERTAIN ORGANISMS R R SPENCER, Pub Health Rep **45** 1354, 1930

Sodium ricinoleate, in appropriate amounts, completely clears the bacterial suspensions of certain species in physiologic solution of sodium chloride, rendering such suspensions water clear

The density of suspensions of certain other bacterial species is increased by appropriate concentrations of sodium ricinoleate

The density of still other bacterial suspensions is increased at one concentration and decreased at another concentration The explanation of such changes is not yet apparent

Certain bacterial species will grow in plain broth containing 1 per cent sodium ricinoleate

LOCALIZED INFECTION CAUSED BY YEAST-LIKE FUNGI T B JONES, Surg Gynec Obst **50** 972, 1930

This represents the third case, recorded, of localized or primary blastomycosis of the spine In a 29 year old man, there was extensive destruction with collapse of the body of the first thoracic vertebra Yellow foci of softening were present in the inner portion of the second and third thoracic vertebral bodies extending inward, lifting up the dura Leading externally, along the second rib, from these destroyed bony structures was an irregular ramifying abscess filled with foul smelling grayish-green, semiliquid material, and in which were many eroded large nerve tracts Due to the fact that the organisms were not numerous, many sections and careful study of the bones were necessary in order to establish a diagnosis A review of the previous recorded localized infections is given

RICHARD A LIFVENDAHL

THE CULTURE OF TUBERCLE BACILLI FROM THE URINE T VON HUTH and F LIEBERTHAL Surg Gynec Obst. 50:985 1930

Based on 1,200 cultures of urine for tubercle bacilli on Hohn's egg medium according to the method of Löwenstein-Sumyeski the conclusion is drawn that this method is more reliable simpler and more rapid than inoculation of guinea-pigs

RICHARD A LIFVENDAHL

CULTIVATION OF VACCINIA VIRUS. H B MAITLAND and A W LAING Brit J Exper Path 11:119 1930

The technic and the results of experiments on the cultivation of vaccinia virus in medium containing either rabbit kidney or testis are presented Little virus is necessary to initiate growth and in almost all cases there is an increase of from 10 to 1 000 times or more The authors conclude In view of the regularity with which cultures have been obtained the potency of culture-virus and the maintenance of its infectivity during storage its freedom from bacterial contamination and the small cost entailed this or a similar method of culture suggests itself as being suitable for the production of vaccine on a larger scale

I N PATTERSON

EXPERIMENTAL SYPHILIS OF RABBITS TANI KARISHITA SANADA and INOUE, Zentralbl f Bakteriol 113.481 1929

Syphilitic material from nine untreated patients in the first and second stages of the disease when injected into rabbits gave 78 per cent positive results Mechanical trauma of the testis of the rabbit seemed to have no influence on the development of syphilitic orchitis or on the further course of the syphilis In young rabbits the incubation period of the local lesion was longer but its persistence shorter than in older rabbits The keratitis appeared later and disappeared earlier and the symptoms were lighter in the young animals The greater the injection dose the shorter was the incubation period of the first lesion the further course however showed no differences The inguinal and popliteal lymph nodes from nineteen syphilitic rabbits in from the one-hundredth to the three-hundredth day of infection when injected into new rabbits gave 47 per cent positive results Similar lymph nodes taken from syphilitic rabbits that had been treated with neoarsphenamine gave negative results on injection into new rabbits Lymph nodes from rabbits that had been given injections of syphilitic material and remained symptomless also yielded negative results on subsequent injection into new animals In studying the localization of spirochetes in various organs of syphilitic rabbits the injection of testicular emulsions gave the highest percentage of positive results followed by the spleen and the lymph nodes No positive results followed the injection of emulsions of brain from syphilitic rabbits

PAUL R CANNON

THE MORPHOLOGY AND GENESIS OF TUBERCULOUS EARLY INFILTRATION H KUDLICH and F REIMANN Ztschr f Tuberk 55:289 1930

This paper is a careful and detailed study of the morphology of a so-called early infiltration. It was observed in a boy aged 19 who died following an operation for a conglomerated tubercle of the brain The x-ray picture of the chest sixteen days before death showed a typical infraclavicular lesion with uninvolved apexes without demonstrable excavation. The pathologico-anatomic examination revealed caseous acinous-nodose tuberculous foci in the middle and lower thirds of the upper lobe of the right lung while the upper third of this lobe was free from lesions All foci were surrounded by nonspecific inflammatory processes which were diagnosed as perifocal infiltrations The lower lobe of the left lung contained a calcified primary focus the lymphoglandular component of which was found in the draining lymph node This case which is apparently the

first complete pathologico-anatomic report on a case of a relatively young so-called "early infiltration," shows that this lesion was a reinfection and that it occurred without previous apical involvement, confirming the clinical and roentgenologic interpretation received in the German literature during recent years

MAX PINNER

FILTRABLE VIRUS IN TUBERCULOSIS J T LEUSDEN, Ztschr f Tuberk **55** 437, 1930

Filtrates were injected into more than forty guinea-pigs In no case was it possible to ascertain definitely the existence of a filtrable virus

MAX PINNER

THE AUTOLYSATE OF SPUTUM A HAVAS, Ztschr f Tuberk **56** 39, 1930

In autolyzing bacilliferous sputum, the tubercle bacilli decreased in number and showed signs of degeneration The sterilized filtrate of autolyzed sputum exerts an inhibiting action on bacilli, and the morphologic characteristics of the cultures are changed Bacilli grown on such a medium are considerably less virulent than the unchanged strain

MAX PINNER

STREPTOCOCCI FROM SCARLET FEVER T AKIYAMA, Jap J Exper Med **8** 195, 1930

Only 5 per cent of the strains of streptococci isolated in Japan fermented mannite compared with 16 per cent as reported by Dick It was possible to increase only slightly the virulence of the organisms by passage through mice The toxin was without demonstrable effect in animals Akiyama found that the toxicity of the toxin varied directly with the quantity of bacteria used to produce it, and that the toxicity increased on passage through mice The toxin and an extract of the streptococci produced similar skin reactions in man The best therapeutic antiserum was produced by immunization of horses with both the toxin and the bacteria

THE BACTERIOLOGY OF ACUTE APPENDICITIS H HIROSE, Tohoku J Exper Med **15** 524, 1930

Bacteriologic examination was made of the contents of the appendix and of the peritoneal pus in a large number of cases of appendectomy Colon bacilli were found in pure culture in the large majority of cases of appendicitis in the acute stages, in addition, the various forms of streptococci and certain bacilli were found also in pure cultures in occasional cases, associations of the different bacteria also occurred in a relatively small number of cases The results on the whole correspond with the results previously obtained by others

Immunology

THE COMPARATIVE VALUE OF TOXOID AND OTHER AGENTS IN THE IMMUNIZATION OF THE PRESCHOOL CHILD AGAINST DIPHTHERIA A B SCHWARTZ and F R JANNEY, Am J Dis Child **39** 504, 1930

A brief review of the literature dealing with the results of immunization against diphtheria is presented The authors have found that the toxoid method of immunization is far superior to any of the other methods It is particularly adapted to the preschool child, for it gives a greater percentage of immune persons than does the toxin-antitoxin method, and it avoids serum sensitization The best age for the toxoid immunization is around 1 year

J N PATTERSON

THE EFFECTS OF MERCUROCHROME AND MILK PROTEIN UPON ANAPHYLAXIS LAY MARTIN and JUSTINA H HILL, Bull Johns Hopkins Hosp **46** 232, 1930

Mercurochrome and milk protein, if given at a certain time before the shocking dose, will protect a definite percentage of animals against anaphylactic death when the amount of antigen injected is about the effective shocking dose

AUTHORS' SUMMARY

INTRADERMAL SENSITIZATION OF GUINEA-PIGS LAY MARTIN and JUSTINA H HILL, Bull Johns Hopkins Hosp **46** 246 and 254, 1930

Guinea-pigs that have received intradermal injections of emulsions of whole bacteria, both alive and dead (*Pneumococcus* type I, *Streptococcus hemolyticus* and *Staphylococcus aureus* 209) develop skin sensitization to the same antigen in the remarkably short period of forty-eight hours This is, so far as we have been able to ascertain, the first time this observation has been made The skin sensitization remained for at least a month, but by that time had diminished The strongest sensitization was developed about ten days after the primary inoculation

Those animals that received daily intradermal injections of milk protein were markedly less sensitive to a second injection of bacterial antigen than the controls Intramuscular injection of milk protein was less effective in inhibiting hypersensitivity to the bacterial antigen

AUTHORS' SUMMARY

LOCAL SKIN REACTIVITY TO VARIOUS BACTERIAL FILTRATES GREGORY SHWARTZMAN, J Exper Med **51** 571, 1930

The specificity and the nature of the phenomenon of local skin reactivity to various micro-organisms have been studied It has been shown that the skin preparatory and reacting factors of various biologically and serologically unrelated micro-organisms are able to substitute for each other, provided they have the power of eliciting the phenomenon for themselves Additional evidence has been brought concerning the antigenic specificity of the factors eliciting the phenomenon A variety of nonbacterial substances which are able to increase the permeability of capillaries, elicit inflammation and "block" the reticulo-endothelial cells failed to induce the state of local skin reactivity to *B typhosus* culture filtrate Nonbacterial protein substances (crystalline egg albumin and normal horse serum) failed to reproduce the phenomenon It was not possible to obtain passive transfer of the local skin reactivity Various conditions influencing the potency of the bacterial culture filtrates have been pointed out The essential nature of the phenomenon has been discussed together with its significance in relationship to disease

AUTHOR'S SUMMARY

IMMUNIZATION AGAINST THE PNEUMOCOCCUS VICTOR ROSS, J Exper Med **51** 585, 1930

Feeding heat-killed pneumococci grown in milk produces a fair degree of immunity Feeding acid-killed degraded avirulent organisms produces little protection Feeding the desiccated, mechanically disrupted organisms creates a high degree of protection Feeding the Berkefeld filtrate of sodium glycocholate dissolved cells produce a high degree of immunity A single ingestion of this material equivalent to between 1 and 5 cc growth is sufficient to protect a rat against from 1,000 to 10,000 fatal doses Among rats fed the equivalent of 0 1 cc, an occasional one survives This degree of protection is present forty-eight hours after the feeding, and to a smaller extent exists in occasional animals at the end of twenty-four hours The treated animals are resistant to subcutaneous as well as intraperitoneal injections A single ingestion of hydrochloric acid-killed pneumococci equivalent to between 1 and 5 cc growth also protects within forty-eight hours against from 1,000 to 10,000 fatal doses intraperitoneally injected Reference is made to results obtained in preliminary experiments with human beings

AUTHOR'S SUMMARY

REACTIONS OF RABBITS TO INTRACUTANEOUS INJECTIONS OF PNEUMOCOCCI LOUIS A JULIANELLE, J Exper Med **51** 625, 633 and 643, 1930

A skin reaction elicited by the injection of the pneumococcus "nucleoprotein," or a solution of the cells from which the acid and heat-coagulable proteins have been removed, is described in rabbits which have previously received repeated intracutaneous injections of heat-killed pneumococci In terms of bacterial specificity, the skin reaction is considered to be not type-specific, but species-specific A similar skin reaction to the proteins of pneumococcus occurs in rabbits following the repeated administration by the intravenous or intracutaneous route of the heat-killed organisms or their protein derivatives The skin reaction may occur independently of resistance to infection The skin reaction appears to be related to the presence of circulating species-specific antibodies

About two thirds of the rabbits injected intracutaneously with suspensions of heat-killed S or R pneumococci develop an increased eye reactivity Eye reactions in these animals may be elicited by the instillation of "nucleoprotein," or of a solution of pneumococcus from which the acid precipitable and heat-coagulable proteins have been removed The eye reactions are not elicited, under the conditions described, by living R cells or the protein-free, type-specific polysaccharides Rabbits do not develop an increased eye reactivity following intravenous injections of the intact cell Rabbits do not develop an increased eye reactivity following injections of soluble derivatives of pneumococcus Experimental infection by pneumococcus may stimulate eye reactivity in rabbits Eye reactivity occurs in animals actively resistant to infection Eye reactions are observed more frequently in rabbits which show the secondary reaction

Rabbits receiving either intracutaneous or intravenous injections of crystalline egg albumin acquire a "skin sensitivity" but not an "eye sensitivity" to the albumin Rabbits receiving either intracutaneous or intravenous injections of the "nucleoprotein" of pneumococcus acquire a specific "skin sensitivity" to the "nucleoprotein" but not an "eye sensitivity" Rabbits receiving intravenous injections of a suspension of heat-killed pneumococci acquire a "skin hypersensitiveness" but not an "eye hypersensitiveness" to the "nucleoprotein" The skin hypersensitiveness to the respective proteins is associated with the presence of antibodies in the blood and is transferable by the injection of serum from an actively sensitized to a normal rabbit Rabbits receiving intracutaneous injections of a suspension of heat-killed pneumococci also acquire a "skin hypersensitiveness" to the "nucleoprotein" of the cell, but they may acquire an eye hypersensitiveness as well Rabbits injected intracutaneously with a suspension of heat-killed pneumococci show a primary and a secondary skin reaction following the first injection The intensity of the reactions increases with subsequent injections up to the fourth or to the sixth injection With later injections these reactions change in character and decrease in intensity These reactions bear no apparent relation to the presence of antibodies in the blood Rabbits injected intracutaneously with a suspension of heat-killed pneumococci develop "eye hypersensitiveness" which, under the experimental condition, is not transferable from "eye reactive" to normal rabbits It appears, therefore, that following the injection of heat-killed pneumococci into the skin a special kind of "eye" and "skin hypersensitiveness" develops which is not related to the presence of circulating antibodies and which cannot be transferred from sensitive to normal rabbits

AUTHOR'S SUMMARIES

PHAGOCYTOSIS OF THE PNEUMOCOCCUS BY WHOLE HUMAN BLOOD HUGH K WARD, J Exper Med **51** 675 and 685, 1930

The phagocytic titer of whole human blood against the three types of pneumococcus was determined in a number of subjects The titer varied over a considerable range in different subjects Contrary to expectation, the titer in early cases of untreated pneumonia was quite high against the infecting organism, pointing to a local rather than a general lowering of resistance in infection with this organism Sia's work was confirmed, that the specific carbohydrate has a

specific antiphagocytic action on the blood This action is more marked in the case of type III than in type I

In vitro phagocytic experiments with human blood, antipneumococcus serum, pneumococcus specific soluble substance and living virulent pneumococci show that there is a definite phagocytic inhibition zone when strong antiserum is used If the antiserum is further diluted, there is a zone where phagocytosis is effective If the serum is diluted still more, phagocytosis gradually falls off, as the very dilute antiserum fails to neutralize the specific carbohydrate, which has a specific antiphagocytic action The inhibition zone is apparently caused by the specific precipitate (formed by the antiserum and the specific carbohydrate) interfering perhaps mechanically, with the ingestion of the pneumococci by the leukocytes The inhibition zone is better marked with type III than with type I pneumococcus As the concentration of antiserum in the zone of effective phagocytosis in vitro does not correspond with the concentration of antiserum generally used in vivo in the serum therapy of pneumonia, this question is discussed

AUTHOR'S SUMMARIES

THE EFFECT OF THE ROUTE OF IMMUNIZATION ON THE IMMUNITY RESPONSE TO PNEUMOCOCCUS TYPE I ERNEST G STILLMAN, J Exper Med **51** 721, 1930

The serums of 80 per cent of the rabbits intravenously inoculated with fixed amounts of heat-killed pneumococci contained agglutinins and all showed protective antibodies The serums of 60 per cent of the intraperitoneally inoculated rabbits contained agglutinins and all showed protective antibodies The serums of 33 per cent of the intramuscularly inoculated rabbits contained agglutinins and 86 per cent also showed protective antibodies None of the serums of the subcutaneously inoculated rabbits contained agglutinins although protective antibodies were present in 71 per cent Although there is a close relationship between the presence of agglutinins and protective antibodies in a given immune serum, these do not run parallel

AUTHOR'S SUMMARY

ACCUMULATION OF ANTIBODIES IN THE CENTRAL NERVOUS SYSTEM JULES FREUND, J Exper Med **51** 889, 1930

Antibodies can be extracted from the brain and spinal cord of rabbits actively or passively immunized with typhoid bacilli The titers of the antibodies in the extracts of brain and cord depend on the titer of the blood serum In actively immunized rabbits the following numerical relationships exist between the titers of the serum and of these organ extracts The ratio of the titer of the serum is to the titers of extract of brain and of the spinal cord about as 100 is to 0 8, the titer of the serum is to the titer of the cerebrospinal fluid as 100 is to 0 3 In passively immunized rabbits the titer of the serum is to the titer of brain and spinal-cord extract as 100 is to 0 7 The antibodies recovered from the brain are not due to the presence of blood in it for perfusion of the brain does not reduce its antibody content appreciably Antibodies penetrate into the spinal fluid from the blood even in the absence of inflammation of the meninges When the penetration is completed the following numerical relationship exists between the titer of the serum and that of the cerebrospinal fluid, 100 0 25 The penetration into the cerebrospinal fluid of antibodies injected intravenously proceeds at a slow rate, being completed only several hours after the immune serum has been injected The penetration of antibodies into the tissue of the brain occurs at a very rapid rate It is completed within fifteen minutes It is unlikely that when the immune serum is injected intravenously the antibodies reach the brain tissue by way of the cerebrospinal fluid, for the antibody titer of the cerebrospinal fluid is lower than that of the brain extract, and antibodies penetrate faster into the tissue of the brain than into the cerebrospinal fluid

AUTHOR'S SUMMARY

THE TITRATION OF SCARLATINAL ANTITOXIN IN WHITE PIGS K ANDO and K KURAUCHI, J Immunol **18** 341, 1930

The relative merits and limitations of various methods of titrating scarlet fever antitoxin reported by many authors have been described and discussed in brief A method of titration of scarlatinal antitoxin with white pigs has been described This method is not only convenient, but also reasonable since (1) the substance that is responsible for the skin reaction of white pigs was proved to be the essential scarlatinal toxin, and (2) this animal does not react to the nucleoprotein contained in the ordinary Dick toxin which may interfere with the results of the skin test method on human beings

AUTHORS' SUMMARY

THE MECHANISM OF SPECIFIC AGGLUTINATION AND PRECIPITATION HARRY EAGLE, J Immunol **18** 393, 1930

Agglutinating and precipitating antibodies are a specifically altered fraction of the serum globulin The antigen-antibody complex, whether sensitized red cells, agglutinated bacteria or the precipitate formed by a soluble protein and the corresponding antiserum, contains this antibody globulin, demonstrable chemically, immunologically and by a change in the cataphoretic, flocculating, interfacial and complement-fixing properties of the antigen toward those of the protein with which it has combined In the case of the cellular antigen, this antibody is present as an invisible film of specificially adsorbed protein, while in the precipitation reaction, it may constitute the bulk of the material formed In both cases, the originally hydrophil globulin has become water-insoluble (denatured), on combination with antigen This change in properties is not a phenomenon peculiar to the immune reactions, but is a commonly observed and as yet unexplained property of adsorbed proteins, responsible for their sensitizing effect on otherwise stable colloidal suspensions It is suggested that in the case of the immune reactions, this denaturation of the antibody globulin is due to the fact that its specificity is determined by hydrophil groups When these combine with antigen, hydrophobic groups necessarily face the water phase, determining the surface properties of the antigen-antibody complex But when normal serum protein is adsorbed, since there are no groups with a specific affinity to antigen, the molecules naturally orient themselves at the interface so that the hydrophil groups face the water, and the adsorbed protein acts as a protective film away from its iso-electric point There are therefore three factors that determine specific flocculation The hydrophil antigen is covered with a film of immune globulin, denatured by its combination with antigen In the absence of electrolytes, the charge due to the ionization of this protein suffices to prevent aggregation Minute concentrations of electrolyte, however, depress this surface charge below the critical value necessary for stability The resultant aggregation is therefore primarily of the immune globulin surfaces, and only incidentally of the associated antigen With insufficient immune serum, only a very small portion of the cell surface is covered with antibody globulin, most of the impacts are between hydrophil antigen surfaces, ineffective in producing cohesion The more immune serum, the greater is the proportion of antigen surface covered with the sensitizing denatured protein, and correspondingly the greater is the proportion of effective impacts The optimum ion concentration for flocculation is intermediate between that of the original cell and that of the antibody globulin, shifting toward the latter as the degree of sensitization is increased (i e, more extensive antibody film) At the optimum reaction, ionization, and therefore the surface charge, are minimal, no added electrolytes are necessary to produce aggregation In more acid or more basic reaction, the surface charge due to the ionization of the adsorbed protein causes a mutual repulsion of the particles, but traces of electrolytes depress this charge and allow the cohesion of the denatured antibody films The flocculating ion is always the one opposite in charge to the ionized protein, and its flocculating efficiency increases enormously with increasing valence The further from the iso-electric zone, the greater is

the degree of ionization, and the more electrolytes are necessary to depress the surface charge below the critical value As will be shown in a forthcoming paper, the kinetics of specific flocculation, the so-called "Danysz" and "zone" phenomena, and the varying proportions of antigen and antibody in the aggregates formed are all in keeping with the theory of specific aggregation as just presented

AUTHOR'S SUMMARY

PARENTERAL DENATURIZATION OF FOREIGN PROTEINS T H BOONE and W H MANWARING, J Immunol **18** 427 and 431, 1930

The accelerated denaturization of horse proteins in homologously hypersensitive dogs is due to some specific factor, the nonspecific effect of sensitization being an inhibition or exhaustion of the normal, alien-protein denaturization function

In dogs, india ink blockade reduces the rate of parenteral alien-protein denaturization fully 80 per cent The capillary endothelium is therefore, presumably, the dominant factor in such denaturization

AUTHORS' SUMMARIES

INCIDENCE OF BLOOD GROUPS AMONG THE MAYA INDIANS OF YUCATAN KENNETH GOODNER, J Immunol **18** 433, 1930

Two hundred and twenty-three pure Mayas and 202 people of mixed Maya and Spanish blood were grouped A high percentage for the incidence of group O was found, in the case of the Mayas amounting to 97 7 per cent This points to the racial purity and antiquity of the Maya stock

AUTHOR'S SUMMARY

HYPERSENSITIVENESS TO PRODUCTS OF THE DIPHTHERIA BACILLUS JAMES M NEILL and others, J Immunol **18** 437, 455, 1930

The hypersensitive man (individual C) previously reported reactive with toxin-containing, and nonreactive with nontoxin-containing, test materials was studied further by a comparison of the hypersensitive reactivity or nonreactivity of the filtrates of highly and of weakly toxicogenic strains of diphtheria bacilli With a constant test dose (3×10^{-4} cc) of filtrate, each of the eighteen highly toxicogenic strains produced a moderate to strong immediate skin reaction, in contrast, none of the fourteen weakly toxicogenic strains gave any reaction at all This sharp demarcation was acceptable proof that the agent of this man's hypersensitive reaction was consistently present in higher concentration in the filtrates of highly toxicogenic, than in the filtrates of weakly toxicogenic, strains When dealing with complex mixtures like bacterial filtrates, it is difficult to assign hypersensitive reactions to any one particular constituent However, in the present instance, significance must be attached to the regular association between toxin and the agent of C's hypersensitiveness, particularly because of the biologic assays of the filtrates for their contents of two other diphtheria constituents (the agent of the delayed "pseudo" reaction and the agent of the immediate reaction on individual A) The fact that some of the weakly toxicogenic strains nonreactive with C were just as potent as any of the highly toxicogenic strains in respect to other diphtheria bacterial substances was important, because it showed that the consistent association between the toxin content and the content of the agent of C's reaction was not due simply to a greater concentration of bacterial substance in the toxicogenic filtrates by virtue of more luxuriant growth or of consistently greater autolysis on the part of the toxicogenic strains While the evidence is of indirect nature, it strongly suggests that diphtheria toxin is the substance involved in the described hypersensitive immediate skin reaction

Previous evidence indicative that toxin is the substance involved in C's hypersensitiveness was based on the consistent association of high toxin content of test material with high degree of hypersensitive reactivity and of low or no toxin content with weak or no hypersensitive reactivity The evidence in this paper

was based on the constant association between the antitoxin content of serum and the capacity of the serum to neutralize the hypersensitive agent when the toxin-containing filtrate was incubated with the serum before injection into individual C Experiments with similar results were obtained with antitoxin-containing serum of horses, rabbits and men With the rabbit serums the use of an "antibacterial," as well as an "antitoxic," serum made it possible to show not only that a serum containing antitoxin was able to neutralize the hypersensitive agent, but also that a serum rich in other antidiphtheria antibodies was unable to neutralize it The most convincing results were obtained with human serums because it was possible by choice from a large number to select for the tests more purely "antitoxic" serums than could be obtained by the laboratory immunization of animals The selected human serums, although containing no precipitins and no or only traces of "group agglutinin," were able to neutralize the agent of the hypersensitive reaction Further experiments demonstrated a quantitative relationship between the antitoxin content and the amount of the respective serum required to neutralize the substance hypersensitively reactive with individual C

AUTHORS' SUMMARIES

AGGLUTINOGENS OF HUMAN BLOOD CLARA NIGG, J Immunol **19** 1, 1930

An extra-agglutinin, demonstrated in several normal serums, is described The extra-agglutinin described was subsequently found to be identical with the extra-agglutinin 1 of Landsteiner and Levine The hereditary transmission of the extra-agglutinin was apparently established The occurrence of an agglutinable factor in human blood was demonstrated by means of suitably absorbed antihuman immune serums The agglutinable factor demonstrated by such immune serums was subsequently shown to be identical with the N factor of Landsteiner and Levine

AUTHOR'S SUMMARY

ELIMINATION OF FOREIGN PROTEIN (EGG-WHITE) IN WOMAN'S MILK HARRY H DONNALLY, J Immunol **19** 15, 1930

Evidence of the elimination in the breast milk of food proteins ingested by lactating women has been clinical Stuart's inability to confirm Shannon's experiments and conclusions casts grave doubt on their validity Walzer's egg absorption work makes it possible to determine when the lactating mother has unaltered egg protein in her blood stream This constitutes a valuable guide as to the time to collect the breast milk for the study of its egg content A human antiegg serum, such as serum F, once found, is available for a long time, and offers considerable latitude to the experimenter Among receptive skins moderate differences in reactivity are found A specific test of great delicacy for egg-white is offered by the site in a reactive skin sensitized by human antiegg serum of high reagin content Serum F sites may react to one part of egg-white in ten billion parts of salt solution or breast milk whey A method for the preparation of concentrated breast milk whey for testing is presented, although its concentration may not be of great importance The concentrated whey of breast milk obtained after raw egg ingestion, on an empty stomach and without other food, from three of eight women, gave the specific reaction for egg-white greater than the control, in sensitized sites in two normal recipients for each whey Four recipients were utilized for the tests By comparison of the skin reactions obtained with the breast milk whey, with those of known dilutions of egg-white, it is estimated that the concentration of egg-white in one of them was one part in a million, and in each of the others one part of egg-white in a billion parts An unsuccessful attempt was made to sensitize a guinea-pig passively to egg-white with 2 5 cc of serum F intraperitoneally, as shown by the uterine strip method of Dale

AUTHOR'S SUMMARY

CERTAIN CHARACTERISTICS OF THE INFECTIOUS PROCESSES IN CONNECTION WITH THE INFLUENCE EXERTED ON THE IMMUNITY RESPONSE L DIENES and E W SCHOENHEIT, J Immunol **19** 41, 1930

The observations described in this paper inform us concerning important properties of the lesions, with the help of which the production of the tuberculin type of sensitiveness is successful Twenty-four hours after the injection of a large dose of the R1 strain into the testicle, the injection of egg-white in the same place produces tuberculin type of sensitiveness When intraperitoneal injections are used, forty-eight hour intervals were necessary between the two injections In the production of the sensitiveness the local reaction at the site of the tubercle bacillus injection played the preponderant role because only the injection of egg-white in this place was effective The intravenous injection of small doses is without effect At the stage when we injected the egg-white an acute inflammatory reaction is present, with large accumulation of leukocytes around the injected bacteria The typical tissue reaction of tuberculosis is not yet developed The latter is not a prerequisite of the development of the tuberculin type of sensitiveness It was possible to produce a tuberculin type of sensitiveness with the injection of egg-white into the testicle of guinea-pigs infected with smallpox vaccine With extensive acute inflammatory processes produced with infusorial earth, tapioca and turpentine, the immunity response of the animals was not influenced The local reactions produced with the antigenic lipoid substances of the tubercle bacilli also remained without effect With the soluble substances of the tubercle bacillus we did not succeed in increasing the antigen response Different considerations make it improbable that the substances of the bacterium are directly responsible for the influence exerted by the lesions on the immunity response We give also a review of unsuccessful experiments in which we tried to transfer passively the increased response toward the antigens with the products of tuberculous lesions

AUTHORS' SUMMARY

ALLERGIC REACTIONS IN VACCINIA-IMMUNE RABBITS RICHARD THOMPSON, J IMMUNOL **19** 63, 1930

Evidence is given to indicate that allergic reactions do occur in a certain percentage of vaccinia-immune rabbits Some evidence is given indicating that the reactions obtained may be partly due to homologous testicle tissue reacting with organ-specific antibodies That the virus does play some part in the reaction is indicated by the fact that the reactions are much greater in virus-immune animals than in animals immune only to testicle tissue While a state of hyperimmunity tends to reduce the amount of induration in the allergic reaction, there is no conclusive evidence that the negative results in some animals are due to this hyperimmunity The chief factor determining the occurrence or nonoccurrence of an allergic reaction is the individual factor in the animal From apparently successful passive transfer — general and local — of the allergic state and from the apparent acceleration of vaccinal reactions by treatment with immune serum, it seems probable that the allergic reactions are the result of antigen-antibody reactions Evidence in a human subject of a local factor in the allergic reaction indicates that the antigen-antibody reaction concerned does not entirely depend on antibodies in the serum

AUTHOR'S SUMMARY

RESISTANCE OF GUINEA PIGS VACCINATED WITH BACILLUS CALMETTE-GUERIN (B C G) S A PETROFF and W STELKEN, JR, J Immunol **19** 79, 1930

Animals vaccinated intraperitoneally or subcutaneously with living B C G developed some degree of protection Guinea-pigs vaccinated by feeding showed no allergy up to four weeks, nor any perceptible immunity These studies confirm Langer's observations that the resistance established with B C G is not greater than that established with heat-killed bacilli

AUTHORS' SUMMARY

A QUANTITATIVE COMPLEMENT-FIXATION TECHNIC HARRY EAGLE, J Infect Dis **46** 231, 1930

To a series of tubes containing arbitrary, but constant, quantities of complement and the known reagent are added increasing amounts of the unknown After one-half hour at 37 C, sensitized cells are added, and the residual complement determined from the time required for complete hemolysis as described in the text The amount of antibody (or antigen) present in the unknown can then be expressed on any arbitrary scale, the unit being taken as the amount necessary to fix 75 per cent of complement in the presence of an arbitrarily fixed quantity of antigen (or antibody) Although it can be used in any type of fixation (by bacteria, red cells or specific precipitate), the method is particularly valuable in the Wassermann reaction, making possible an accurate titration of syphilitic reagin, and allowing a definite evaluation of the so-called "anticomplementary" and "doubtful" reactions, in terms of positive and negative

ANTIGENS FOR THE PRECIPITATION TEST FOR SYPHILIS EMIL WEISS, J Infect Dis **46** 285, 1930

An optimal antigen has been devised, which offers the following advantages It is equally useful in the Wassermann, the Kahn and the author's test, its preparation is simple and every step is well defined, it has a much wider specific zone than the antigens recommended by Kahn, and it does not require additional sensitizing or correcting

AUTHOR'S SUMMARY

AGGLUTINATION OF TYPHOID BACILLI IN SERUMS OF PATIENTS HAVING UNRELATED INFECTIONS RUTH GILBERT and MARION B COLEMAN, J Infect Dis **46** 311, 1930

The observations are of course, too limited to furnish a basis for sweeping conclusions It is evident, nevertheless, that the results of the agglutination reaction with typhoid bacilli must be interpreted in the light of clinical manifestations or of bacteriologic observations, since it has been shown that agglutination may be encountered in specimens collected from patients during febrile diseases other than typhoid fever, even though the patients have never received typhoid vaccine nor to their knowledge had typhoid fever, and that a fluctuation of the agglutination titer, considered by some as definite evidence of typhoid fever, may occur in cases in which this infection is definitely excluded

AUTHORS' SUMMARY

SYPHILITIC ANTIGEN DERIVED FROM BLOOD SERUM R L KAHN, A M MALLOY and M NISHIO, J Infect Dis **46** 413, 1930

Both syphilitic and nonsyphilitic serums contain lipoids that possess specific precipitinogen properties By extraction of serums with ether and subsequent taking up of the lipoids in alcohol, an antigen is obtained in alcoholic solution that can be employed in the Kahn reaction

Powdered beef serum, when subjected to extractions with ether and subsequently with alcohol, yields an antigen possessing a sensitivity similar to that of Kahn standard antigen prepared from powdered beef heart

Lipoids extracted from syphilitic serum act as precipitinogens when mixed with the same serum in vitro

AUTHORS' SUMMARY

RELATION BETWEEN CONCENTRATION OF LIPOIDS IN AN ANTIGEN AND ITS SENSITIVENESS IN THE PRECIPITATION REACTION WITH SYPHILITIC SERUM GLOBULINS M NISHIO, J Infect Dis **46** 420, 1930

An attempt was made to find whether in the precipitation reaction for syphilis the quantitative relation between the concentration of lipoids in an antigen and its sensitiveness with syphilitic serum would hold true if the serum globulins were

substituted for the serum Antigens of varying lipoid concentrations were prepared and precipitation tests made with serums and serum globulins according to the Kahn technic The globulin solutions gave somewhat more sensitive reactions than the unfractioned serums The zone of maximum sensitiveness was the same with serums as with serum globulins This zone corresponded to a given (optimum) concentration of antigenic lipoids An increase or decrease in lipoids beyond this concentration resulted in antigens of lesser sensitiveness

AUTHOR'S SUMMARY

BRUCELLA ABORTUS AGGLUTININS IN PORCINE BLOOD R A BOAK and C M CARPENTER, J Infect Dis **46** 425, 1930

Agglutination tests for *Brucella abortus* agglutinins on 4,014 serums from samples of porcine blood collected in New York State and from seven midwestern states showed 64, or 1 54 per cent, to be positive

The percentage of agglutination for 1,054 samples from New York State was 0 19, while 1 89 per cent of 2,735 samples from Ohio, Illinois, Indiana and Missouri were positive

AUTHORS' SUMMARY

OPTIMUM QUANTITATIVE RELATION BETWEEN ANTIGEN AND SERUM IN PRECIPITATION REACTION IN SYPHILIS M NISHIO and E B McDERMOTT, J Infect Dis **46** 435, 1930

For maximum precipitation with a given antigen, whether "standard" or "sensitized," it is necessary to employ optimum proportions of serum and antigen suspension A 12 1 proportion of serum to standard antigen suspension and a 6 1 proportion of serum to sensitized antigen suspension were found to be the most sensitive An excessive amount of antigen suspension over serum and to a lesser degree of serum over antigen suspension tended to inhibit precipitation The precipitation zones with the two antigens are similar but not identical, sensitized antigen giving a wider precipitation zone than standard antigen Relatively excessive amounts of the former antigen are capable of giving more sensitive reactions than similar amounts of standard antigen When the serum amounts are excessive in relation to the antigen amounts, somewhat more sensitiveness is shown with the standard antigen

Globulin solutions from syphilitic serums react in approximately the same proportions with standard and sensitized antigen suspensions as the unfractioned serums, except that with the former somewhat more sensitive reactions are obtained

Positively reacting nonsyphilitic rabbit serums, when used in varying proportions with standard and sensitized antigen suspensions, show precipitation zones similar to those shown by human syphilitic serums

AUTHORS' SUMMARY

THE MICROSCOPIC AGGLUTINATION TEST IN PNEUMONIA ALBERT B SABIN, J Infect Dis **46** 469, 1930

A method of microscopic agglutination is described in which the organisms are smeared with the serum on a slide, allowed to dry rapidly and stained

By the method described, the type of infecting pneumococcus can be determined in two ways (*a*) with the patient's sputum, usually within from three to four hours after its injection into the mouse, (*b*) with several drops of the patient's blood, by determining the type of agglutinins that are neutralized after the administration of polyvalent serum This procedure is applicable to a limited number of patients, it is especially indicated in cases in which sputum is not obtainable and it is desired to know whether the infecting pneumococcus is of a type for which antiserum is available

The microscopic agglutinin test on a single drop of the patient's blood can be used to demonstrate the presence or absence of active infection, as indicated by the neutralization of homologous agglutinins in the circulation, as well as the active production of antibody, and may thus be used as a guide in controlling the dosage of antipneumococcus serum

AUTHOR'S SUMMARY

THE RELATION OF HEMOLYSINS AND TOXINS IN DIPHTHERIA CULTURES ISOLATED FROM ACUTE CASES RALPH H HEEREN and EMERSON MEGRAIL, J Infect. Dis **46** 485, 1930

Correlation between hemolytic properties and toxicogenicity is not sufficiently marked to make it a reliable laboratory test for the toxicogenicity of *Corynebacterium diphtheriae*

The property of hemolysis in diphtheria bacilli is transient, generally disappearing as the length of time the cultures have been on laboratory mediums increases

A formerly hemolytic organism may be made to regain hemolytic powers by a series of passages through laboratory animals, but the ability is soon lost when cultures are once more transferred to laboratory mediums

For a considerable period, growth on blood agar has little tendency to increase hemolysins

Variations are shown in the susceptibility of the blood of laboratory animals to hemolysis The rabbit's blood offers greater resistance to hemolysis and the blood of different animals is less uniform than that of the guinea-pig

Hemolysis is a factor apart from toxicogenicity and also is not definitely correlated with virulence

AUTHORS' SUMMARY

THE EFFECT OF IRRADIATION ON COBRA VENOM AND ANTIVENIN ALBERT EIDINOW, Brit J Exper Path **11** 65, 1930

As a result of irradiation of cobra venom and antivenin it was shown that the neurotoxin present in a solution of cobra venom in saline solution was destroyed only by rays shorter than 2,800 angstrom units unless sensitized with eosin The photodynamic action of eosin is arrested by the presence of blood and serum Hemolysins and cytolysins were destroyed by rays longer than 2,800 A U, but not by rays longer than 3,300 A U Antivenin is resistant to prolonged irradiation as obtained in serum

AUTHOR'S SUMMARY

THE ANAPHYLACTIC REACTION OF THE ISOLATED UTERUS OF THE RAT C H KELLAWAY, Brit J Exper Path **11** 72, 1930

Experiments indicate that the results of sensitization, as judged by the reaction of the isolated smooth muscle, are very irregular with active sensitization and are extremely regular with passive sensitization It is shown that the anaphylactic reaction of the muscle is one of contraction and not of relaxation, and that this is due to the interaction between the precipitating antibody, fixed in the plain muscle, and the specific anaphylactic antigen The production of symptoms, either in the actively or in the passively sensitized animals, by large intravenous injection of the antigen (crystalline hen-egg albumin) is an infrequent event

J N PATTERSON

A STUDY OF VACCINAL IMMUNITY IN RABBITS BY MEANS OF IN VITRO METHODS S R DOUGLAS and WILSON SMITH, Brit J Exper Path **11** 96, 1930

The white cells of normal blood were shown to take up vaccinia virus in vitro Normal whole blood possesses some degree of viricidal power, which is largely dependent on a thermolabile constituent of the serum Different anticoagulants have different effects on the viricidal activity of the blood Heparin is shown to be a suitable anticoagulant for in vitro experiments of the type recorded The blood spleen and testis of an immune rabbit show far greater viricidal power than those of a normal rabbit Evidence is put forward suggesting that the increase of viricidal power by immunization depends on (1) alterations of the tissue cells themselves — cellular immunity — and (2) an opsonic or perhaps a stimulin action of some of the serum constituents — humoral immunity

AUTHORS' SUMMARY

THE TUBERCULOSIS IMMUNIZATION (B C G) AT LUBECK L LANGE, Klin Wchnschr **9** 1105, 1930

This report contains the results of Lang's investigation of the immunization with B C G at Lubeck, during which seventy-four children received injections, seventeen of which died from acute generalized tuberculosis The bodies of fifteen of those who died were examined Lange pleads against a hasty condemnation of the B C G immunization

EDWIN F HIRSCH

ACTIVITY OF THE RETICULO-ENDOTHELIAL SYSTEM IN ANAPHYLACTIC SHOCK MARCEL HAENDEL, Ztschr f d ges exper Med **71** 675, 1930

A series of guinea-pigs was sensitized to horse serum After an interval of time (from twenty to twenty-five days), various substances were given, preceding the reinjection of a lethal shock dose of horse serum The reticulo-endothelial system was inactivated and shock prevented by the use of each of the following peptone, heterologous serum, milk, bacillary emulsion, epinephrine, calcium, experimental acidosis, glycerin, neoarsphenamine, merbaphen, barbituric acid, alcohol, ether and atropine Other substances stimulated the reticulo-endothelial system and facilitated shock insulin, thyroiodin, potassium, pantopon, choleretic um ataphanyl and physostigmine The effects of experimental alkalosis, hypertonic dextrose solution, hypophysin and ovarin were not clear

PEARL ZEEK

PEPTONE SHOCK AND THE RETICULO-ENDOTHELIAL SYSTEM MARCEL HAENDEL and J MALET, Ztschr f d ges exper Med **71** 683, 1930

When the reticulo-endothelial system of guinea-pigs is blocked with india ink, the administration of peptone does not cause shock as in untreated animals, but produces prostration and loss of appetite, with hyperemia of the lungs, liver and spleen

PEARL ZEEK

Tumors

PAPILLOMAS OF THE CHOROID PLEXUS W P VAN WAGENEN, Arch Surg **20** 199, 1930

The author reports two cases of true papilloma of the choroid plexus, both in the left ventricle The method of demonstrating blepharoplasts was employed as a method of differentiating between ependymal papillomas and papillomas of the choroid plexus In both cases reported here blepharoplasts could not be demonstrated Likewise, no glial fibers were present in either tumor There is evidence in the literature and in one of the cases reported here that this tumor may be seeded by the cerebrospinal fluid into the brain tissue, where it reproduces itself in a papillary formation The implantations were well away from the original tumor The distinguishing feature of such plexus tumors is their benign histologic nature and lack of invasive properties The two cases are reported in detail, and there is a summary of the forty-five cases reported in the literature A curious point discovered in the literature was that 93 per cent of these tumors were in the left lateral ventricle

N ENZER

MULTIPLE MALIGNANT ADENOMAS OF THE KIDNEY E S JUDD and J P GRIER, Arch Surg **20** 240, 1930

The kidney of a man, aged 46, was removed at operation It contained numerous tumor nodules and was about five times normal size The cut surface showed five distinct grayish-red tumors varying in size up to 12 cm in diameter These were surrounded by a small amount of normal-appearing kidney tissue Microscopically these tumors were not encapsulated, but adjoined normal kidney tissue There

was some evidence of compression of the tubules and glomeruli The histology was that of an adenoma, with large polygonal cells This case is the nineteenth to be reported

N ENZER

CHRONIC CYSTIC MASTITIS J S RODMAN and H INGLEBY, Arch Surg **20** 515, 1930

Great stress is placed on the importance of appreciating the normal phases of activity of the tissue of the breast and the importance of differentiating these from pathologic changes Any tumor that does not change with local treatment after one menstrual period should be removed, and if the frozen section does not definitely establish a benign process, the lesion should be treated as carcinoma The senior author has changed his point of view from one held many years ago on the relationship between this disease and carcinoma Formerly, he considered chronic cystic mastitis as definitely precancerous, but at the present time he believes that this disease is a result of the interference of the normal physiologic processes in the breast, and cannot be considered definitely as precancerous

N ENZER

THE INDUCTION OF TUMORS WITH CARBON DIOXIDE SNOW I BERENBLUM, Brit J Exper Path **11** 208, 1930

Experiments on mice with two carcinogenic agents, tar and carbon dioxide snow, are reported It is shown that when the two agents are applied concurrently, the induction of tumors is inhibited, but when either is applied after the other a summation of effect is obtained It is generally held that a carcinogenic agent is ineffective if the intensity of irritation is insufficient The present experiments suggest that it may also be ineffective if the intensity of irritation is too great They also suggest that there is an optimum intensity of irritation for effective carcinogenesis

ALFRED M GLAZER

ROUS SARCOMA NO 1 INFLUENCE OF MODE OF EXTRACTION ON THE POTENCY OF FILTRATES W E GYE and W J PURDY, Brit J Exper Path **11** 211, 1930

There is a rough correspondence between the structure of each example of the Rous sarcoma no 1 and its degree of filtrability There is a rough correspondence between the potency of an extract and the amount of precipitable protein that it contains, but some specimens yield extracts that are very highly potent, although they contain no protein detectable when tested by boiling and addition of acetic acid Extraction with strong salt and subsequent dilution to physiologic strength gives more highly potent extracts than does direct extraction with physiologic solution of sodium chloride By the saturated-salt method some examples of the Rous sarcoma no 1 which once would have been classed as nonfiltrable are now found to be filtrable Since it is shown that in practice the classification is dependent on the efficiency of the technical tests employed, added point is given to the question of whether the strict separation of tumors into filtrable and nonfiltrable groups is not entirely artificial

AUTHORS' SUMMARY

Medicolegal Pathology

CINCHOPHEN POISONING L J STACY and F R VANZANT, Minnesota Med **13** 327, 1930

A woman, aged 52, took cinchophen daily for some six weeks, discontinuing its use because of nausea and vomiting A week later intense jaundice appeared, and death took place sixteen days after she became jaundiced The liver weighed only 903 Gm and presented the typical appearances of acute yellow atrophy

FRACTURE OF THE SECOND CERVICAL VERTEBRA H DURCK, Beitr z path Anat u z allg Path **84** 353, 1930

Fracture of the second cervical vertebra alone is rarely encountered Two kinds of fracture are described, one involving the odontoid process, the other the lamina, the latter being the rarer of the two Durck describes in considerable detail an example of each kind The case of fracture of the odontoid process was of unusual interest It occurred in a girl aged 18 years and followed a fall to the floor while the girl was dancing with her sister Immediate paralysis of the extremities occurred and death followed in a short time It was learned that seven years previously, following a fall, both upper extremities had been paralyzed Complete recovery occurred Examination revealed that the fracture that caused death occurred in the line of a healed fracture that must have been sustained at the time of the previous injury The fracture occurred, as do most fractures of the odontoid process, at the line of fusion of the process, which in its embryologic development represents the body of the first vertebra, with the body of the second vertebra The mechanism of the injury to the cord resulting from such fractures is discussed, and the cord changes due to the previous fracture are described The author applies the name epistropheus to the second cervical vertebra Some readers may find considerable interest in the half page historical footnote that describes the confusion in the older anatomic literature due to the fact that the name epistropheus was first applied to the atlas and later, by Heister, to the axis

O T SCHULTZ

CRIMINAL ABORTION BY INTRA-UTERINE INJECTION OF FLUIDS E FRITZ, Deutsche Ztschr f d ges gerichtl Med **15** 165, 1930

In one case, a powdered soap solution was used, which not only caused local escharotic changes of the vagina and uterus, but penetrated into the general circulation, producing grossly visible alterations of the muscle of the heart, the liver and the kidneys The hemolytic action of the soap is due to its fatty acids In the second case, an alum solution was injected into the uterus Embolic air was found in the small arterial branches throughout the body, while the right ventricle of the heart was not distended and did not contain air, but fluid blood These peculiar results are explained by the presence of a large, open foramen ovale through which the air escaped into the left ventricle and the general circulation Alum solution was also found in the right ovarian vein

E L MILOSLAVICH

AIR IN THE BLOOD FOLLOWING CONTUSION OF THE CHEST O SCHMIDT, Deutsche Ztschr f d ges gerichtl Med **15** 174, 1930

Severe contusions to the thorax often lead to an interstitial emphysema of the lungs, with hemorrhages in the pulmonary tissue, indicating a great increase of air pressure within the lungs, which also may force the air into the blood Of forty-five cases of contusion of the chest, the presence of air in the heart or in the blood vessels was proved in twenty-two instances Air may be found in either ventricle of the heart, because the anterior bronchial veins and the pulmonary veins empty into the left side of the heart while the posterior bronchial veins and the intercostal veins lead into the right side Often, the left ventricle does not show air, because the air rapidly passes into the peripheral circulation Air in the smaller blood vessels is best observed in the coronary vessels (rosary-like arrangement of minute air bubbles), where it was seen in eight instances The minute vessels of the plexus chorioideus may also contain air A simple apparatus for collecting free oxygen from the heart is described with the aid of which the oxygen can be (alkaline pyrogallol) quantitatively determined It seems that the author is not familiar with the important work of LeCount on this subject

E L MILOSLAVICH

CALCIFICATIONS OF THE BRAIN FOLLOWING GUNSHOT WOUND OF THE HEAD. RAESTRUP, Deutsche Ztschr f d ges gerichtl Med **15** 181, 1930

At the autopsy of a man, aged 42, who died shortly after an accident, the brain contained six large areas of calcification, ranging in size from that of a hazelnut to that of a plum These changes are explained as the result of a gunshot wound of the head which the man accidentally sustained at the age of 10 years (calcification of old encephalomalacic or hemorrhagic areas) During life no physical or psychic disturbances were observed

E L MILOSLAVICH

THE FORENSIC SIGNIFICANCE OF GASEOUS DECOMPOSITION AFTER ABORTION P FRAENCKEL, Deutsche Ztschr f d ges gerichtl Med **15** 216, 1930

A case is described of rapid intra-uterine destruction of the soft tissues of the fetus by gas-forming organisms The fetus was at about the sixth month, and the soft parts were destroyed quite completely in from twenty-seven to thirty-six hours A large postmortem rupture of the uterus also developed within the same time The importance of distinguishing between ordinary cadaveric decomposition and the effects of the gas bacilli is emphasized Rapid decomposition of the bodies of young women with gas formation should arouse the suspicion of intra-uterine gas sepsis, an almost certain indication of abortifacient procedures After death it may be difficult, if not impossible, to distinguish between a vital gas sepsis and postmortem invasion of gas bacilli Further efforts should be made to determine whether changes due to the infection can be recognized in spite of the decomposition

THE CONDITION OF HUMAN BODIES RECOVERED FROM PEAT BOGS M GABRIEL, Deutsche Ztschr f d ges gerichtl Med **15** 226, 1930

Acids and other substances in peat bogs have a peculiar preservative effect on the human body The recorded observations on human bodies recovered from peat bogs in northern Germany are reviewed by Gabriel at the same time as she describes a body recently found in a bog in the southern part of the country The most noteworthy effects are a sort of tanning of the skin and decalcification of the bones Usually the bodies are greatly compressed, the skin is deep brown, the bones are brown, elastic and easily cut, the cartilage, teeth and nails are preserved and the soft tissues and organs are not recognizable Woolen clothes remain practically unchanged and afford a means of forming some idea of how long since a given body came to rest in the bog

Society Transactions

CHICAGO PATHOLOGICAL SOCIETY

Regular Meeting, Oct 13, 1930

JOSEPH A CAPPS, *President, in the Chair*

THE PATHOGENESIS OF CARDIAC PAIN JOSEPH A CAPPS

I have chosen this subject for consideration because it is of vital interest to both pathologists and internists Cardiac pain, with its characteristic quality, its location over the region of the heart and its extension to distant parts, is familiar to every physician But the origin of this pain and the factors initiating its mechanism have taxed the ingenuity of the pathologists and physiologists alike

The approach to this problem may be made conveniently by discussing the first pathologic evidence, second, the clinical manifestations, and finally, the physiologic theories that will most adequately explain the facts observed by the pathologist and the clinician

Pathologic Anatomy—The necropsy observations on persons who have suffered from cardiac pain, whether they died of heart disease or of some other disease, bring the lesions of certain structures into focus as probably related to the patient's complaint, viz, lesions in the aorta especially in the vicinity of the aortic valve, in the arteries of the heart and in the myocardium

Frequently degenerative changes are present about the aortic valve with thickening or atheromatous patches, and these changes may so impinge on the orifice of the coronary arteries as to impede the filling of these vessels In many cases sclerosis of the coronary arteries is discovered, sometimes diffuse, but often localized in portions of the main arteries or in the small branches These localized areas of degeneration may be fibrous or they may be calcifications that narrow the lumen In a smaller group actual occlusion of the coronary arteries occurs with infarction of the muscles of the heart The infarcted region, if small, may heal and is recognized by fibrous changes in the wall, or, if larger, may lead to aneurysmal thinning or even rupture of the myocardium Although narrowing of the arteries is the usual condition, there are instances of dilated vessels, at times localized and leading to aneurysm of the artery itself, which may perforate into the pericardial sac

From the pathologic point of view, then, it seems that degenerative changes in the aorta near the ring and in the coronary arteries, with resulting interference with the blood supply of the muscle of the heart, offer a basis for the clinical symptoms of pain

Unfortunately for this hypothesis a considerable number of necropsies exhibit similar damage to the aorta and coronary arteries even with extensive infarcts, without a history of pain Furthermore, a smaller group of patients who have experienced definite severe cardiac pain may have little or no vascular damage post mortem

The pathologist, therefore, must look on these lesions as significant in the interpretation of pain, but not as a full and final explanation

Clinical Observations—It is noteworthy that in most forms of so-called "heart disease" pain is absent Valvular endocarditis, arrhythmias, decompensation with dilatation and hypertrophy are usually associated with dyspnea, but not with pain The reaction of pain seems quite uniformly to be associated with disturbances of the vascular supply to the muscle of the heart Thus one sees cardiac pain in young, healthy persons, during strenouous exercise In older persons with signs of heart trouble, pain is induced by effort or excitement or by excessive smoking i e, factors which greatly increase the normal demand of the muscles of the heart

for blood It is inferred that pain occurs only when this urgent demand cannot be met by a corresponding increase in the flow of blood to the tissues of the heart The second wind of the athlete and the dilating effect of nitrite in the cardiopath are interpreted as a fulfilment of this demand by the delivery of a greater volume of blood

Hence it is that all the theories of cardiac pain implicate the vascular system of the heart The principal theories of the origin of cardiac pain are Nothnagel's (*Ztschr f klin med* **19** 209, 1891) conception of pain arising in the arteries themselves, Allbutt's (Diseases of the Arteries, Including Angina Pectoris, New York, The Macmillan Company, 1915) idea of the aortic ring as the region which provokes pain, the condition of tension playing the important rôle, and Mackenzie's (Angina Pectoris, London, Oxford University Press, 1923) hypothesis of the muscles of the heart as the starting point of pain He believes that the contraction of an anemic muscle is sufficient to explain the pain symptom Most modern writers subscribe to this belief, although the word anoxemia is preferred to anemia

Without further discussion at the moment, it may be said that the belief in the coronary arteries themselves as the actual seat of pain has been losing ground

The aortic hypothesis predicates a rise in blood pressure with stretching of the diseased wall of the aorta Death may ensue from vagal stimulation But aortic disease is not always present, and there is reason to think that death occurs in angina pectoris from ventricular fibrillation, rather than from vagal standstill

Keefer and Resnik (*Arch Int Med* **41** 769, 1928) consider that angina pectoris has but one cause—"anoxemia of the myocardium"—which they think is the one constant in the varying conditions associated with the disease, such as coronary narrowing, aortic regurgitation and pernicious anemia

Physiologic Considerations—The heart is supplied by sympathetic and vagus nerve fibers, the former certainly being capable through afferent impulses of provoking pain in the spinal nerves, the latter probably so It may well be that the heart gives rise also to an intrinsic, or in the sense of Ross, a protopathic, pain localized in the region of the heart (substernal) This is the most constant of all cardiac pains Similarly, the stomach has its protopathic epigastric pain, as well as its pains referred to distant parts

Now, like all the hollow viscera, the muscle of the heart is insensitive to pain from ordinary stimuli, such as scratching, cutting and cauterizing I have found this to be true of the epicardium, and Sutton and King (*Proc Soc Exper Biol & Med* **25** 842, 1929) could tear the myocardium and pericardium of dogs without causing pain But like other hollow viscera, the heart may respond with pain to the adequate stimulus Spasmodic contraction and at times distention are the adequate stimuli in other hollow organs, e g, pyloric spasm, biliary colic, etc

Can cardiac pain be explained on the theory of distention or cramping of the muscles? Swelling of the muscles might set up pain, but localized edema or engorgement does not result from sudden occlusion of an artery, the first effect is anemia Acute dilatation of the chambers of the heart, as is known from fluoroscopic observation, does not take place in attacks of angina

One can be equally sure that during an attack of cardiac pain the heart as a whole does not go into spasmodic contraction Careful studies of the beats of the heart by electrocardiographic tracings and by direct roentgen observations show no such tendency Sudden death comes not by spasm but by ventricular fibrillation

Spasm or cramping of the anoxemic portion of the muscle of the heart, i e, localized spasms, is not so readily excluded However, it may be stated that no direct evidence supporting this view has been offered A pain analogous to cardiac pain, with anoxemia of the muscles, can be seen in the intermittent claudication of the legs, in which a similar background of arteriosclerosis or arterial spasm is present This pain is induced by effort just as is that in the heart The pain

is apparently not accompanied by muscular cramp, or at least there is no obvious knotting of the muscles A localized cramp in the muscle of the heart would certainly disturb the rhythm profoundly As stated, a patient may go through a severe attack of angina with no marked alteration of the electrocardiogram

One is justified, I believe in excluding acute distention or spasmodic contraction of the muscle of the heart, either as a whole or localized, as determining factors in the production of cardiac pain

This brings me to the only tenable hypothesis based on the myogenic origin of cardiac pain viz that the pain is provoked in the anoxemic muscle during contracture In the heart the contractures are rhythmic and continuous If the occlusion of a coronary artery is complete as in thrombosis, the pain is continuously excited If the occlusion is partial, pain comes on only when exercise renders the muscle highly anoxemic

However, this theory is not altogether satisfactory Why is it that in a considerable group of cases of partial coronary occlusion with dyspnea, cyanosis and other signs of anoxemia there is no pain? Why is it that even extensive infarcts take place with aneurysm and rupture of the wall without pain? In these cases there are certainly the two factors of muscular contracture and anoxemia Is it possible that certain parts of the wall of the heart are silent areas with reference to pain response? Why is it that the onset of fibrillation or decompensation in cases of angina tends to lessen or eliminate the pain? Do these complications, which bring further damage to the heart, lessen the anoxemia? One would infer that anoxemia would be increased

It seems that Nothnagel s idea of pain originating in the arteries themselves during constriction deserves further investigation Arteries are hollow organs and may react to pain as other hollow organs A stone in the ureter excites pain not from distention but only during spasmodic contraction of the muscular tube in its effort to propel the stone onward Between attacks of colic, though the stone still distends the duct, the pain ceases Likewise, there are the bearing down pains of the uterus with severe contraction and absence of pains with relaxation, although distention continues

Attempts have been made to produce anginal pain in animals and to determine the mechanism of pain Singer (*Wien Arch f inn Med* **14** 113 1927) found that coronary arteries, when stripped of their adventitial covering were insensitive to clamping, pricking and mechanical and electric stimulation Ligation of the stripped coronary artery, causing anoxemia did not produce pain response The coronary arteries however, left intact in their adventitial coats, were highly sensitive to mechanical and chemical stimulation

On the other hand, Pearcy, Priest and Allen (*Tr A Am Physicians* **42** 243, 1927) reported signs of severe pain in forty of fifty experimental dogs after occlusion of the coronary arteries by clamping or ligature

Sutton and King demonstrated that ligature of the coronaries usually gave evidence of pain while tying of muscle and pericardium only did not induce pain Their experiments might give support to the vascular as opposed to the myogenic origin of the pain

Further study should be pursued to determine these points Is arterial constriction or spasm a constant accompaniment of cardiac pain? Does the absence of pain after ligature of the stripped arteries signify the absence of coronary spasm? Is there severe arterial spasm with most cases of infarct with correspondingly severe pain, and in other cases of occlusion is there little or no spasm and consequently little or no pain? Does the subsidence of pain a few days after infarct indicate simply the disappearance of vasoconstriction? These questions, I believe can be answered by well directed experiments

ADDISON'S DISEASE WITH SELECTIVE DESTRUCTION OF THE SUPRARENAL CORTEX ("SUPRARENAL CORTEX ATROPHY) H GIDEON WELLS

This article was published in full in the October 1930, issue of the ARCHIVES page 499

THE PATHOGENESIS OF MALIGNANT NEPHROSCLEROSIS PHILLIP SHAPIRO

A study is reported of the material on nephrosclerosis available from 1,000 consecutive autopsies at the Cook County Hospital on patients over 20 years of age There were 171 cases of nephrosclerosis, 36 with uremia, 135 without An injection method with india ink was applied to check the observations of direct examination It was found that the histologic changes of malignant nephrosclerosis were intimately and proportionately associated not with ischemia, but with hyperemia, which was direct and not retrograde These observations were analyzed on the basis of Gustav-Richer's views on the hemodynamic changes of sclerosis Malignant nephrosclerosis, in pathogenesis, seems to be only an accelerated form of benign nephrosclerosis, and both are based not on ischemia as such, but on a retardation hyperemia

SPONTANEOUS BILATERAL DECAPSULATION OF THE KIDNEYS WILLIAM M MCGRATH and CARL W APFELBACH

Two kidneys with a watery fluid in their capsules were presented The names commonly given to this condition are perirenal hydronephrosis, perirenal hygroma and renis hydrocele The cases so far reported in the literature of accumulations of fluid in the capsules of the kidneys are explained by the authors as collections of lymph from blockage of the lymph channels and as exudates from inflammation of the renal capsule, from hemorrhage and from the extravasation of urine The gross and histologic evidence in these two specimens points as much to extravasation of urine within the capsules of the kidneys as it does to blockage of the lymph channels The alterations in the capsule are those of encapsulation, and inflammation seems to be a remote etiologic explanation

---

Regular Monthly Meeting, Nov 10, 1930

JOSEPH A CAPPS, M D, *President, in the Chair*

SILVER IMPREGNATION OF GLIOMAS WITH DAVENPORT'S METHOD ARTHUR WEIL

The method, which had been published previously, was described (Arthur Weil and Harold A Davenport Eine Methode zur Silberimpragnierung von Gliomen, *Ztschr f d ges Neurol u Psychiat* **126** 796 1930) Lantern slides were projected demonstrating the resemblance of different cellular elements of an embryonic spinal cord of a rat embryo nineteen days' of age with the tumor cells of different gliomas The classification of Bailey and Cushing was discussed in connection with this comparative material

EXPERIMENTAL GRANULOMA INDUCED BY INFECTION WITH B FUSIFORMIS JACOB KLEIN

B fusiformis is a frequent and important inhabitant of the mouth and is associated with Vincent's spirillum in stained preparations from Vincent's gingivitis, balanitis, abscess of the lungs and infected sinuses The role of fusiform bacilli as pathogenes is uncertain Thus, Varney isolated eighteen strains of *B fusiformis*, and found that they were not pathogenic for dogs and rats Larson and Barron noted that the successful inoculations have been made almost invariably with material taken directly from lesions of patients and not with cultures

B fusiformis is a pleomorphic, granular, Gram-negative anaerobe The strain used in these studies was isolated from a patient suffering from Vincent's gingivitis, and was grown anaerobically in a Varney jar on Rosenow's brain broth medium There is a white flocculent growth in the brain broth medium, and a white pellicle forms on the surface Colonies on serum agar plates are from 1 to 2 mm in

diameter and white or yellowish-white with fringed or saw-tooth contour After repeated subcultivation, it was possible to obtain a growth in the brain broth medium under ordinary conditions without the use of the Varney jar During these studies there was no indication that the spirillum develops from the bacillus, as has been claimed by Tunnicliff

Dogs into which *B fusiformis* is injected or which are fed with the organism in pure culture become ill, and extremely emaciated and die within two weeks or four months, depending on the mode of infection The changes in tissue consist of a reticulo-endothelial hyperplasia of the lymph nodes, lymphocytic infiltration and necrosis of the liver, subacute interstitial inflammation of the lungs associated with foci of necrosis, ulceration of the mouth and, in several instances, necrosis and fibrous changes of the mesenteric lymph nodes

Hitherto *B fusiformis* has been considered innocuous in animals On the basis of the experiments I believe that *B fusiformis* causes a subacute infection and death in dogs The fusiform bacillus in pure culture may cause a bleeding gingivitis in man, as was demonstrated by an accidental laboratory infection sustained by the author

There is clinical evidence that indicates that a Vincent's stomatitis may be associated with agranulocytosis and leukemic reactions, although the exact nature of the relationship is not clear In this preliminary report it was desired to indicate an interesting field for study Detailed hematologic data will be presented later

DISCUSSION

J A Capps There seems to be a relation between agranulocytic angina and infections with *Bacillus fusiformis* Do these organisms have any action on the bone marrow, especially do they cause inhibition in the production of polymorphonuclear leukocytes?

I Pilot Small doses of *B fusiformis* are without effect on animals, but when mixed with *Streptococcus* a putrid lesion results

R H Jaffe It is important to demonstrate the fusiform bacilli by culture or stains in the lesions

J Klein I was unable to demonstrate the organisms in the lesions With other organisms *B fusiformis* has been recovered from the blood

Dissecting Aneurysm of the Aorta Evan M Barton

The clinical diagnosis of dissecting aneurysm of the aorta is infrequently made in the presence of this disease The symptoms often simulate those of more frequent diseases, and in other instances the patients are not under clinical observation long enough to furnish adequate data on which a clinical diagnosis may be made

W B, aged 54, was a business man, and had been under the observation of Dr E E Irons for nine years During the last four years, a progressively increasing essential arterial hypertension had developed

Seventeen days before death, severe pain occurred in the abdomen above the umbilicus The pain was intermittent and radiated to the shoulders and dorsal wall of the trunk Morphine partially relieved this symptom The systolic blood pressure was 270 mm of mercury, the diastolic 170 The pulse rate was 68 per minute The systolic thrust was pronounced Restlessness, sweating and pallor were accentuated during the painful periods There was no rigidity of the abdominal wall, but soreness and tenderness were present in the epigastrium

Within twenty-four hours after the onset, fluid began to collect in the left pleural cavity For six days the patient seemed to be improving A roentgenogram taken on the seventh day demonstrated a widened and tortuous aortic arch and a widened descending portion of the aorta

The abdominal pain persisted so intensely that morphine was required at increasing intervals, day and night During one day the patient complained of

severe precordial pain and oppression in the chest, on another, the complaint was a feeling of oppression around the heart, on still another occasion, the pain radiated to the left lateral wall of the chest

Mental confusion developed during the last few days and increased until the last day, when he became irrational and had a generalized convulsion The systolic blood pressure after the convulsion was 120 Seven hours after the convulsion, while carrying on a conversation with one of the physicians, the patient suddenly collapsed and died in a few minutes

There was no history of syphilis, and a Wassermann test on blood serum in 1926 gave negative results The provisional clinical diagnosis was dissecting aneurysm of the aorta

The anatomic diagnosis was dissecting aneurysm of the thoracic and abdominal portions of the aorta, extensive hemorrhage into the peri-aortic tissues, mediastinum, right and left pleural cavities, root of the neck and right perirenal tissues, marked sclerosis of the aorta, syphilitic (?) aortitis, marked hypertrophy of the wall of the left cardiac ventricle, general anemia

The dissection of the wall of the aorta by blood had begun at a tear of the intima along the inferior margin of a calcified plaque, 1 5 cm in diameter at the obliterated mouth of the ductus botalli The dissection continued downward in the anterior and right and left portions of the wall of the aorta to the level of the renal arteries, only a strip averaging about 1 cm in diameter along the right half of the dorsal wall of the aorta escaped dissection At the upper end of the dissected portion, there was a rupture of the muscular and adventitial coats that allowed the blood to escape into the adipose tissue which surrounded the aorta From here blood dissected its way into the mediastinum, the root of the neck and the fatty capsule of the right kidney

In the left pleural cavity, there was about 500 cc of bloody, watery fluid The blood had escaped from the mediastinum into the pleural cavity through an opening, which was sealed over by fibrin In the right pleural cavity there were 2,200 Gm of clotted and fluid blood that had escaped through a tear in the parietal pleura a few centimeters inferior to the hilus No free blood was found under the parietal pleura that covered the ribs, and only the left intercostal arteries were directly in the pathway of the dissecting aneurysm

In microscopic sections of the arch and thoracic portion of the aorta, there were vascular scars in the media, atrophy of the media, and round cell infiltration about these new blood vessels and also about the vasa vasorum of the adventitia

Summary—Death resulted from acute anemia due to rupture of the dissecting aneurysm into the right pleural cavity The most marked alterations of the aorta were those of arteriosclerosis The dissection of the wall of the aorta began at the inferior margin of a large, elevated, calcified plaque at the site of the obliterated ductus botalli The changes in this region suggested that the lining was torn, because in an aorta stressed by a blood pressure that averaged 250 mm of mercury, the large plaque was forced over the more elastic wall immediately distal to it, and at this junction unusual strain occurred

In the root of the aorta there were histologic changes like those commonly found in syphilitic aortitis Nowhere else in the body were there gross alterations characteristic of syphilis

The clinical diagnosis was based (1) on the pain, which at times resembled the pain associated with thrombosis of the coronary arteries, (2) on the persistence of a high blood pressure, (3) on the absence of an acute abdominal disease, and (4) on the appearance of fluid in the left pleural cavity

DISCUSSION

J A Capps Were roentgen examinations made, and was the patient under treatment for syphilis?

Paul Cannon Was syphilis a factor in the lesion?

E F Hirsch What is the probable duration of the lesion?

E M BARTON The roentgen examination demonstrated a widened and tortuous arch and main portion of the aorta Syphilis is not the cause of the lesion The symptoms began seventeen days before death, and probably the lesion did not occur at once

LEIOMYOSARCOMA OF THE PLEURA LLOYD CATRON

In the body of a white woman, aged 83, who had died from severe coronary sclerosis, a tumor mass that measured 22 by 18 by 8 cm was found incidentally at autopsy, in the left side of the chest cavity The left lung was markedly compressed The tumor, well encapsulated by the pleura, was rounded, firm, smooth and gray white, with small hemorrhages on the surface On section, the mass was seen to be composed of three roughly spherical nodes, the largest of which was 15 by 9 by 7 cm, separated by smaller nodules The superior node was composed of interwoven red-brown and gray tissue Elsewhere there were present yellow and soft small areas, and inferiorly there was an irregularly shaped cavity crossed by trabeculae of yellow-gray tissue There were no metastases Microscopically, the tumor consisted of two distinct types of tissue forming an irregular network In one type the cell contained a large ovoid or fusiform, centrally placed nucleus with a fine chromatin net and a distinct nuclear membrane There were few mitotic figures The cytoplasm, which stained yellow with van Gieson's stain and red with Mallory's aniline blue, was chiefly fusiform, extending from the nuclear poles as homogeneous bands, in some regions, however, fine cytoplasmic processes extended from the nuclear periphery The other tissue was a fibrillar connective tissue with long, flattened nuclei between collagen bands In the cellular portions the connective tissue formed only a scanty stroma composed of fine fibrils In the capsular pleura, which was from 1 to 3 mm in diameter, there were distinct bundles of smooth muscle fibers which apparently passed rather abruptly into the large cells of the tumor Within the growth, disseminated regions of necrosis were found in parts that apparently lacked an adequate supply of blood, and retrogressive changes were present about blood vessels that contained mixed thrombi Elastic fibers were present only in the thin walls of numerous small blood vessels The heterotypic morphology of the tumor, the marked variation in size and shape of the tumor cells and the extreme anaplasia of their nuclei led to the diagnosis of a leiomyosarcoma No report of a smooth muscle tumor originating in the pleura was found in the literature This pleural sarcoma was of the voluminous type without metastases, several of which have been reported

DISCUSSION

I PILOT The huge size of fibrosarcomas of the lungs and the absence of metastases are noteworthy

E R LONG What was the origin of this growth?

R H JAFFE The growth probably originated in the smooth muscle of the pleura

P DELANEY With such fully differentiated tissues, is this growth malignant?

R. H JAFFE Mitosis and other cellular characteristics favor the conclusion that this is a malignant growth

Book Reviews

A System of Bacteriology in Relation to Medicine Medical Research Council Volumes 1 to 5 Cloth Price, per volume, 1 pound, 1 shilling, net London His Majesty's Stationery Office, 1930 (May be obtained from the British Library of Information, 551 Fifth Avenue, New York.)

This work is published by the Medical Research Council as a "comprehensive but not encyclopaedic" survey of the present knowledge of bacteria and other microbes in their relation to medicine Each author deals with subjects in which he has a special interest—it is a cooperative work by specialists The attempt is made to discuss matters that seem "to rest on truth" or are of active concern because they bear on modern practices Even with the limitations thus imposed the complete work will consist of nine volumes and will be the most comprehensive publication of its kind in the English language up to the present It is the product of a posse of writers—nearly 100 British bacteriologists participate—and consequently it becomes impracticable to estimate the merits of each writer The remarks that follow are based mainly on an examination of the first five volumes It is a pleasure to commend the type, the size and format and the exceptional handiness of the volumes And the price is reasonable Volume 1 deals with general bacteriology morphology, physics of bacterial cell, growth and reproduction, nomenclature and variation Volume 6 will deal with the distribution and spread of bacteria, virulence and immunity William Bulloch contributes to volume 1 a valuable summary of the history of bacteriology An innovation is the insertion in the chapters on important bacteria of a brief historical account by the same author The following comment from the chapter on nomenclature by F W Andrewes will meet with a sympathetic response from many "One of its [American classification] chief features lies in the creation of a number of new genera to indicate the natural groups into which the rod-shaped bacteria fall, and new generic names have been formed, on both sides of the Atlantic, from the names of prominent workers in the science Sometimes the result has been not inartistic, such names as *Salmonella, Brucella* and *Pasteurella* are pleasing to the ear and pay a well-deserved compliment to distinguished men Nevertheless, marriage between Northern names and Latin terminations is seldom a happy practice, and we might well have been spared such barbarisms as *'Escherichia'* and *'Mcintoshiella'*"

Arkwright's chapter on variation merits special commendation as a lucid, sane and helpful discussion of an intricate subject. He comments instructively on variability in streptococci as follows "It seems probable that some of the variability described has been due to impurity of the original culture, an accident which is especially likely to occur in dealing with minute colonies of the streptococcus, a class of organism comprising many species and races which occur together and are very similar in morphology"

Volumes 2, 4 and 5 are concerned with pathogenic bacteria, volume 3, with economic bacteriology, plague, gas gangrene, botulismus, tetanus and bacterial food poisoning The single volumes have no indexes, the general subject index will appear in volume 9 The titles on the backs of the volumes are helpful, of course, but in some cases the titles do not indicate the contents fully, for instance, it would be impossible to locate the chapter on tularemia from these titles All references to articles are given without titles, as a rule, references are placed at the end of the chapter, and as most of them are without titles they will have little value by themselves without reference to the text Exceptionally, as in the chapter on tuberculosis, the appropriate references are placed at the end of sections, which has the advantage of an analytic grouping The references at the end of the chapter on streptococci occupy no less than fifteen pages, and in such cases it

would be more helpful if they were listed appropriately with the main sections, which frequently have different authors, as the major chapters commonly are made up of articles by two or more authors Of the first five volumes only the first and third (soil bacteria) contain illustrations, all in black and white Comment on the lack of illustrations is hardly worth while, as it is obvious that more illustrations would have increased the cost unduly in view of the excellent illustrations of bacteria in readily available publications Generally the articles reflect satisfactorily the state and trend of the knowledge of the subjects considered Occasionally recent developments, e g, in toxin production by certain streptococci, in brucellosis and in the cutaneous reactions to gonococci and their products, do not seem to have caught the full attention of the writers On the other hand, too much stress may be placed on matters of little importance To devote nine pages to sanocrysin is hardly worth while—it is not a live subject and the claims first urged so recklessly in its favor did not "rest on truth" In some articles there are too many bald facts cataloged, sometimes in roundabout phrases But taken as a whole the first five volumes of the system present a well considered and helpful summary of the contemporary knowledge in the fields of bacteriology with which they deal

NAISSANCE, VIE ET MORT DES MALADIES INFECTIEUSES By CHARLES NICOLLE, Director of the Pasteur Institute of Tunis, and winner of the Nobel Prize in Medicine for 1928 Paper Price 15 francs Pp 219 One of the Nouvelle Collection Scientifique, Director, Émile Borel Paris Félix Alcan

This volume by Charles Nicolle, whose work on typhus fever resulted in the award to him of the Nobel prize in medicine 1928, is, in the words of the author, addressed to no particular category of readers It is essentially a readable expression of the philosophy of one who has observed infectious diseases from all angles No particular knowledge of infections is assumed, and the numerous examples used as illustrations of various points contain much that is not intended to inform the medical reader Nevertheless, the author's intimate knowledge, obtained at first hand, regarding the matters discussed is such that the interest of any reader is well sustained

The title suggests logically the origin, existence and elimination of infectious diseases per se The contents treat serially of the existence, origin and elimination, arguing from the known to the unknown and philosophical, or, at times, as the author admits, the speculative At no time, however, is one entitled to criticize the author's statements as being fantastic As an experienced investigator, he is ever anxious to support his statements and to admit the weaknesses in his theories And his long struggle with infections has resulted in a ready recognition of the inadequacy of human effort In discussing the purely natural phenomena, however, he treats them scientifically, stressing the point that natural methods are purely random, based principally on chance, and thus the human efforts, though they be weak and impotent for the most part, are valuable in that they are directed Dr Nicolle has not ceased fighting, and he would not discourage his readers His method is not didactic, "ce livre est un *essai*" are his first words

It is difficult even to outline the general subject matter of the volume A long-range perspective toward all infections is attempted The various phases of the evolution of such diseases are considered in nature, as modified by human effort, and as modified by changes in the mode of existence of man and animal hosts It is argued that certain facts have been definitely revealed in modern studies Based on these facts, historical evidence may in many instances be properly interpreted, thus enabling one to picture the trend of infections over long periods "An infectious disease changes, evolves unceasingly" The spread of diseases, as, for example, the importation of syphilis from Mexico, where Bernal Diaz de Castillo recorded the disease, into Europe (sic), illustrated one point of attack Historical study may be complemented by experimental investigation Thus the matter of virulence, of adaptation of pathogenic organisms to special organs, the

variation in the host and the survival of organisms during latent periods are all considered The *"infections inapparentes,"* or invisible types of true specific infection noted experimentally in typhus fever by Nicolle and considered by him to be perhaps relatively common in other diseases, are discussed as indicating evolutionary changes and as reservoirs in the spread of infections Finally, a venture as to the future trends in infections is offered, although it is unfair to the author to convey the impression that he essays the role of prophet He deals primarily with existing and modern data, one infectious disease may have disappeared years ago, others may be developing It appears logical to the author to expect a greater diversity of infections, yet a lower mortality — increasing evolutionary changes in the agent of infection and in its host and environment with more complex civilization, and decreasing mortality with better knowledge of the manner of combating diseases and greater dissemination of gradually acquired immunity The volume ends "We have confidence in those who follow us Peaceful and better, they will know better how to defend themselves, to protect their kind and animals useful in their lives against the dantesque but unintelligent, undisciplined rabble of infectious diseases"

ALLERGIE DES LEBENSALTERS DIE BOSARTIGEN GESCHWULSTE By DR CLEMENS PIRQUET, o o Professor an der Universitat Wien Paper Price, 23 marks Pp 170, with 143 illustrations Leipzig Georg Thieme, 1930

This monograph presents a detailed analysis of the age and sex incidence of 697,515 cases of malignant tumors, contained in the report of the Registrar General of England and Wales, between the years 1911 and 1926 This material is probably the largest that has ever been subjected to such a statistical analysis The contents reveal many facts already well known regarding the age incidence of different forms of cancer and support the conclusions reached by previous authors dealing with a smaller material

The author's final graph (page 120) shows the existence of several notable features in age incidence The tumors of the kidney and suprarenal gland occur mainly in the first fifteen years of life These must be mainly of congenital type The second group, tumors of the bone, finds its peak about the eighth or tenth year The third group, testicular tumors, is most frequent in the thirty-third year Tumors of the brain are most frequent in the forty-sixth year Other varieties reach their peaks at later periods, from 55 to 70 Tumors of the skin are last on the list, with a peak at 76

Lymphogranuloma gives a graph which varies notably from the tumor type, this disease occurring rather uniformly in many decades and without any definite peak

The work contains many separate analyses of the different forms of tumors and extensive tables showing the numbers of cases of each type at different ages

While the size of the material handled renders this study one of much importance, it may be questioned as to what extent the diagnoses on the death certificates were accurate Only a small proportion were proved by autopsies The material naturally does not permit of a separation of the different types of cancer occurring in the same organ, and this deficiency must apply to most statistical material now available Many will find it a serious limitation to the value of statistical studies of this type

The author has taken a strictly mathematical view of his task and has limited himself, perhaps unnecessarily, in the interpretation of the clinical and pathologic significance of the facts which he demonstrates

The figures are not corrected with reference to the total population living at the different periods of life, so that the reader must be warned that the graphs give no indication of the liability to cancer at different age periods

As a volume of reference, the monograph will be of definite value It possesses a peculiar interest as a posthumous publication from the study room of a lamented and highly esteemed worker

A TEXT-BOOK OF PATHOLOGY Edited by E T BELL, M D, Professor of Pathology, University of Minnesota, Minneapolis Contributors E T Bell, M D, Professor of Pathology, B J Clawson, M D, Professor of Pathology, Hal Downey, M D, Professor of Hematology, J S McCartney, M D, Assistant Professor of Pathology, J C McKinley, M D, Professor of Neuropathology and Neurology, and C J Watson, M D, Instructor in Pathology, University of Minnesota, Minneapolis Cloth Price, $8, net Pp 627, with 316 engravings, of which 313 are original, and 2 colored plates Philadelphia Lea & Febiger, 1930

This is a cooperative attempt by several pathologists in the same medical school "to present the essential facts of pathology to medical students" A special effort is made "to bring the structural changes in disease [pathologic anatomy] into close relation with the problems of clinical teaching" The first twelve chapters, all by the editor except the chapter on the mycoses by J S McCartney, deal with general pathologic processes and cover about 272 pages The topics ordinarily included under general pathology are discussed clearly and succinctly, mainly from the morphologic standpoint Hodgkin's disease is included under tumors of the blood-forming tissues and treated as if there were no question about its nature E T Bell also wrote the chapters on the genito-urinary systems, the blood vessels certain acute infectious diseases, the thymus and lymph nodes, the respiratory system, the digestive system, the ductless glands and certain diseases caused by animal parasites The use of the term Malta fever in place of undulant fever or, better perhaps, brucellosis or brucelliasis is unfortunate The chapter on the heart is by B J Clawson, that on the spleen by C J Watson, that on the liver and gallbladder by J S McCartney, that on neuropathology by J C McKinley, and that on diseases of the blood by Hal Downey The presentation is clear, orderly and competent The illustrations, all original, are good and were chosen with discrimination The references to the literature will help the student The principles of microbiology and immunology are not considered Throughout the book, "pathology" is used commonly as synonymous with "pathologic anatomy," and the book s essentially a concise but thoroughly reliable text for medical students on general and special pathologic anatomy

PHYSIOLOGY AND BIOCHEMISTRY OF BACTERIA VOLUME II EFFECTS OF ENVIRONMENT UPON MICROORGANISMS VOLUME III EFFECTS OF MICROORGANISMS UPON ENVIRONMENT FERMENTATIVE AND OTHER CHANGES PRODUCED Cloth Pp 575 By R E BUCHANAN, PH D, Professor of Bacteriology and Bacteriologist of the Iowa Agricultural Experiment Station, Iowa State College, and ELLIS I FULMER, PH D, Professor of Biophysical Chemistry, Department of Chemistry, Iowa State College Cloth Price, $7 50 per volume Pp 709 Baltimore Williams & Wilkins Company, 1930

The jocose remark that scientific men should now proceed to take a vacation of ten years to catch up with science and find out what it is all about has its serious side The mass of detail that is annually published in practically every field of investigation seems at times likely to overwhelm one Fortunately there are still workers who are willing and competent to face the task of compiling, editing and sifting, and who can organize and make accessible the results of thousands of detailed pieces of research Buchanan's successful accomplishments in this field are well known, and the second and third volumes of his monumental work on the physiology and biochemistry of bacteria will be welcomed by all students of microbiology There is little to criticize in arrangement or choice of material The style is clear and straightforward The extensive bibliographies are wonderfully complete The text is slightly marred by the occasional misprinting of proper names, but in general the proofreading is excellent Altogether these two volumes will aid the real progress of science

Books Received

PHYSIOLOGY AND BIOCHEMISTRY OF BACTERIA II EFFECTS OF ENVIRONMENT UPON MICRO-ORGANISMS By R E Buchanan, Ph D, Professor of Bacteriology and Bacteriologist, Iowa Agricultural Experiment Station, Iowa State College, and Ellis I Fulmer, Ph D, Professor of Biophysical Chemistry, Department of Chemistry, Iowa State College Price, cloth, $7 50 Pp 709 Baltimore Williams & Wilkins Company, 1930

PHYSIOLOGY AND BIOCHEMISTRY OF BACTERIA III EFFECTS OF MICRO-ORGANISMS UPON ENVIRONMENT FERMENTATIVE AND OTHER CHANGES PRODUCED By R E Buchanan, Ph D, Professor of Bacteriology and Bacteriologist, Iowa Agricultural Experiment Station, Iowa State College and Ellis I Fulmer, Ph D, Professor of Biophysical Chemistry, Department of Chemistry, Iowa State College Price, cloth, $7 50 Pp 575 Baltimore Williams & Wilkins Company, 1930

LABORATORY MEDICINE A GUIDE FOR STUDENTS AND PRACTITIONERS By Daniel Nicholson, M D, Member of the Royal College of Physicians, London Assistant Professor of Pathology, University of Manitoba, Assistant in Pathology, Winnipeg General Hospital Price, cloth, $6 00, net Pp 437, with 108 engravings and 1 colored plate Philadelphia Lea & Febiger, 1930

A TEXT-BOOK OF PATHOLOGY Edited by E T Bell, M D, Professor of Pathology, University of Minnesota, Minneapolis Contributors E T Bell, M D, Professor of Pathology, B J Clawson, M D, Professor of Pathology, Hal Downey, M D, Professor of Hematology, J S McCartney, M D, Assistant Professor of Pathology, J C McKinley, M D, Professor of Neuropathology and Neurology, C J Watson, M D, Instructor in Pathology, University of Minnesota, Minneapolis Price, cloth, $8 00, net Pp 627, with 316 engravings, 313 of which are original, and 2 colored plates Philadelphia Lea & Febiger, 1930

LANE LECTURES ON EXPERIMENTAL PHARMACOLOGY AND MEDICINE By Rudolf Magnus, Late Professor of Pharmacology and Director of the Institute, University of Utrecht, Utrecht, Holland Price, paper, $1, cloth, $1 50 Pp 108, with 42 text figures Stanford University Press, 1930

THE ANTISCURVY VITAMIN IN APPLES By Mary F Bracewell, E Hoyle and S S Zilva Medical Research Council Special Report series, no 146 Price, 9 pence, net Pp 45 London His Majesty's Stationery Office, 1930

THE ELECTROCARDIOGRAM By W H Craib, Medical Research Council Special Report Series, no 147 Price, 1 shilling, 3 pence, net Pp 57 London His Majesty's Stationery Office, 1930

MONOGRAPHS ON EXPERIMENTAL BIOLOGY OXIDATION-REDUCTION POTENTIALS By L Michaelis, M D, Member of the Rockefeller Institute for Medical Research Translated from the German manuscript by Louis B Flexner, Jacques Loeb Fellow in Medicine, Johns Hopkins Hospital Price, $3 Pp 197, with 16 illustrations Philadelphia J B Lippincott Company, 1930

A SYSTEM OF BACTERIOLOGY IN RELATION TO MEDICINE VII VIRUS DISEASES, BACTERIOPHAGE By the Medical Research Council Price, cloth, 1 pound, 1 shilling, net London His Majesty's Stationery Office, 1930 (This may be obtained from the British Library of Information, 551 Fifth Avenue, New York)

LEGAL MEDICINE AND TOXICOLOGY By Ralph W Webster, M D, Ph D, Late Clinical Professor of Medicine (Medical Jurisprudence), Rush Medical College, University of Chicago Price, cloth, $8 50 Pp 862, with illustrations Philadelphia W B Saunders Company, 1930

INDEX TO VOLUME 10

The asterisk (*) preceding the page number indicates an original article in the Archives Author entries are made for original articles correspondence and society transactions Subject entries are made for all articles Book Reviews, Obituaries and Society Transactions are indexed under these headings in their alphabetical order under the letters B O, and S respectively